

Non-Extraction Aligner Treatment for Moderate Crowding and Flared Upper Incisors in a Female with a Flat Facial Profile and Prominent Chin

Yu-Hsin Huang, Chris H. Chang & W. Eugene Roberts

Non-Extraction Treatment for Excessive Overjet and Deep Bite with Aligners and IZC Screws

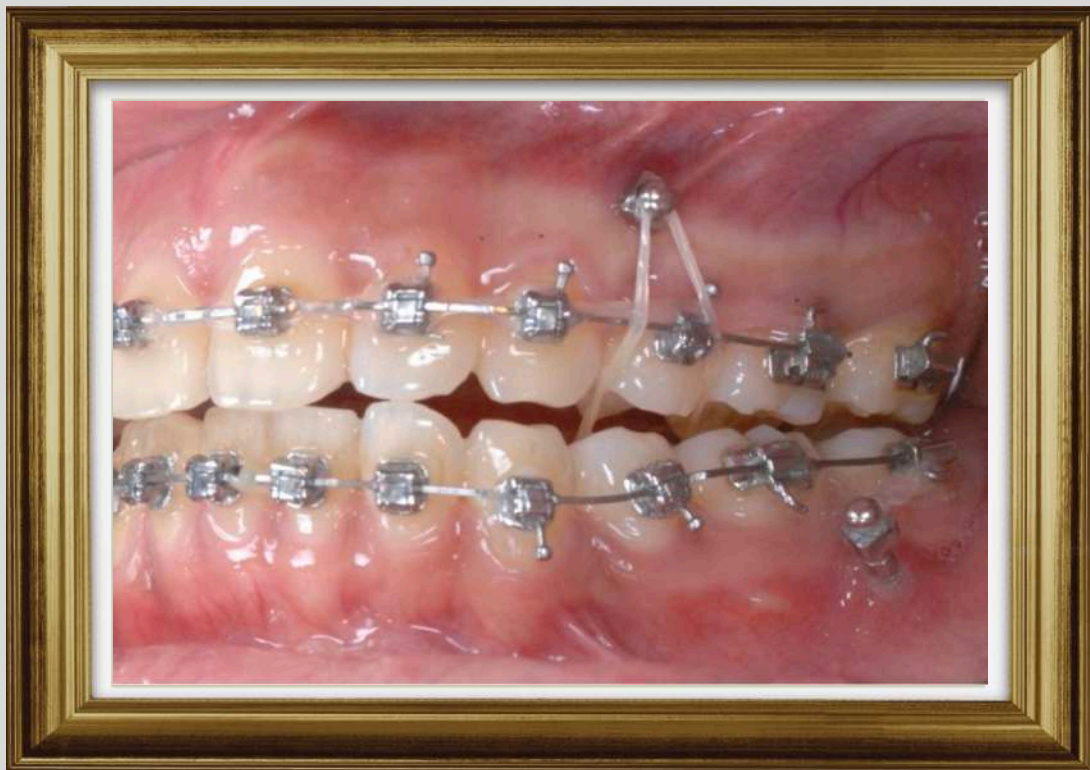Vicky Y. Huang, Bear C. Chen, Chris H. Chang & W. Eugene Roberts

Class II Malocclusion with Severe Crowding and a Protrusive Profile

Shih-Wei Lu, Chris H. Chang & W. Eugene Roberts

Maximizing Spaces and Resources - Building a Rooftop Putting Green

Annie Chen



The bone screw (OrthoBoneScrew®, iNewton Dental, Hsinchu City, Taiwan) on the left buccal site was inserted in a tilt-forward position in order to protract the left lower posteriors forward. Another bone screw was placed between upper left canine and second premolar to provide intrusion mechanics to correct the occlusal canting.



ISSN 2523-9406
977 2523940 002

This journal is available for free download at iJDO.pro.

2022 熱愛學矯正

全新的貝多芬高效 Damon 矯正大師系列課程是由國際知名講師張慧男醫師親自規劃及授課，課程特色強調由臨床病例帶動診斷、分析、治療計畫擬定與執行技巧。此外，透過數位影片反覆觀看，課堂助教協助操作，以及診間臨床見習，讓學員在短時間內快速上手，感染「熱愛矯正學，熱愛學矯正」的熱情。

張慧男 博士

新竹貝多芬齒顎矯正中心負責人
中華民國齒顎矯正專科醫師
美國齒顎矯正專科醫師學院院士 (ABO)
美國印地安那普渡大學齒顎矯正研究所博士
美國 Angle 學會會員



Damon Master

(Thu) 9:00-5:00 中文授課

The Beethoven Damon Master Program, created by Dr. Chris Chang, is a two-year clinical program. Its hands-on orientation features case study-based diagnosis, analysis, treatment planning and result evaluation. Combining in-class teaching assistants, after-class video review and chair-side observation, participants will learn to master the essential tips of the Damon System.

Excellent Finishing

(Tue) 9:00-12:00 中文授課

Critically reviewing classical literature and contemporary papers and applying lessons learned to clinical work; utilising ABO's DI and CRE standards to turning excellent finishing into attainable goals.

International Workshop

(Digital Orthodontics, OBS & VISTA)

English Class

The workshop provides a 3 day, advanced hands-on program to experienced Damon users. The program includes world-class lectures, model and surgical hands-on workshops and clinical observation on patient care and clinic management.

✉ course@newtonsa.com.tw

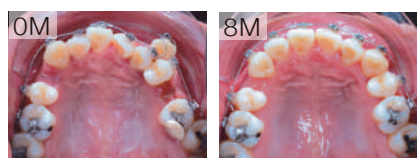
☎ +886-3-573-5676 #218 Annie

2022 A班 B班

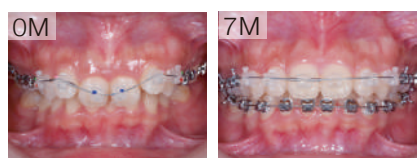Module 1 - 4/14 6/9	Module 7 - 8/18 9/22
Module 2 - 4/28 6/30	Module 8 - 9/15 10/20
Module 3 - 5/12 7/14	Module 9 - 9/29 11/3
Module 4 - 6/2 7/28	Module 10 - 10/13 12/1
Module 5 - 6/16 8/4	Module 11 - 11/10 12/15
Module 6 - 7/21 9/1	

Finishing XIV

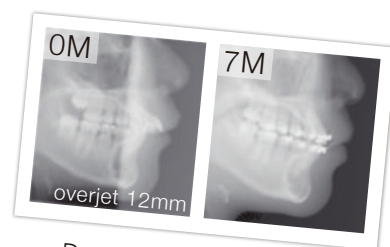
Module 1 - 5/10	Module 7 - 11/15
Module 2 - 6/7	Module 8 - 12/6
Module 3 - 7/12	Module 9 - 1/10/23'
Module 4 - 8/16	Module 10 - 2/7
Module 5 - 9/6	Module 11 - 3/7
Module 6 - 10/4	



Damon + .014 Cu NiTi



Damon Clear



Damon + Bite Turbo +
Early Light Short Elastic

每次上課請依最新一期 JDO 公告為主

(本文宣品僅供牙科診所及醫師參考，禁止張貼或擺置於公眾可瀏覽及取閱之處)

報名專線

湧傑 Yong Chieh

北區 楊文君

02-27788315 #122

中區 張馨云

04-23058915

南區 蔡淑玲

07-2260030

上課地點：新竹市建中一路25號2樓（金牛頓藝術科技）

2F, No. 25, Jianzhong 1st Rd., Hsinchu City, Taiwan (Newton's A)

In recent years, a few of our team's case reports have been published in the world-renowned journal, American Journal of Orthodontics and Dentofacial Orthopedics (AJO-DO). One even received the prestigious 2019 CDABO Case Report of the Year Award. These achievements are the fruits of our labor since 2006, when we started publishing case reports in our own humble JDO. I would like to share our secrets of writing pertinent case reports.

The journey to compose a standard case report takes only 5 weeks. In the first week, you need to immerse yourself in the case to firmly grasp as many details as possible. The initial step is to analyze the cep tracings to understand the change of profile and tooth positions between pre-treatment and posttreatment, followed by studying every treatment step as well as the Discrepancy Index (DI) and Cast-Radiograph Evaluation (CRE) measurements.

In the second week, systematically study and evaluate similar case reports to "copy and paste" useful phrases and expressions which can be utilized but not plagiarized. Pablo Picasso once said, "Good artists copy; great artists steal." You should learn from past masters by studying similar published case reports (as well as different cases) which will consequently allow you to complete your reports faster. During the third week, modify the contents of your manuscript accordingly, a process of creating a variation on the theme of the same topic. Ascertain the most appropriate sentences to compose your manuscript, focusing particularly on the required format standards of the journal to which you intend to submit your work.

In the fourth week, start to refine your manuscript. One of the most important and beneficial steps is orally presenting your case in front of other professionals. Speaking publicly is the best way to re-organize and re-evaluate your ideas and message, as well as receiving valuable feedback from audience members and mentors. After finishing the refinements, secure the services of a professional English editor to revise and proofread your manuscript. In the last week, scrutinize your content again before handing in the manuscript.

"We are what we repeatedly do. Excellence, then, is not an act but a habit," Aristotle once noted. You only need to spend 2 hours a day for 5 weeks, which is equal to 70 hours, to finish a case report. Make it a part of your routine, and subsequently, you can effortlessly achieve your goals.

An artist never reaches perfection in his own eyes, thus the necessity for the artist to always continue mastering his craft. The same could be said about case reports. However, the art of case report writing is not necessarily achieving a perfect result, but rather offering our experience, advice, support, and clinical facts to the orthodontic community, thereby enabling our profession to evolve and continue along its path to glory.

I sincerely hope all of us can help each other by writing as many case reports as we can.

Chris Chang PhD, ABO Certified, Publisher of JDO

- 3 Editorial
- CASE REPORT
- 4 Non-Extraction Aligner Treatment for Moderate Crowding and Flared Upper Incisors in a Female with a Flat Facial Profile and Prominent Chin
- 28 Non-Extraction Treatment for Excessive Overjet and Deep Bite with Aligner and IZC Screws
- 48 Class II Malocclusion with Sever Crowding and a Protrusive Profile
- TAIWANESE LIFESTYLE THROUGH THE EYES OF CC
- 80 Maximizing Spaces and Resources - Building a Rooftop Putting Green

JDO Editorial Board

Consultants



Dr. W. Eugene Roberts



Dr. Tucker Haltom



Dr. J. Michael Steffen



Dr. Larry White



Dr. Andrew Haas



Dr. Derek Mahony



Dr. Homa Zadeh



Dr. Fernando Rojas-Vizcaya



Dr. Baldwin W. Marchack



Dr. Kenji Ojima



Dr. Diego Peydro Herrero

Examiners



Dr. John J. J. Lin



Dr. Frank Chang



Dr. Hong Po Chang



Dr. Johnny Liaw

Associate editors



Dr. Bill Chuanwei Su



Dr. Yu Lin Hsu



Dr. Ming-Jen Chang



Dr. Yu-Hsin Huang



Dr. Chris Lin



Dr. W. Eugene Roberts



Dr. Chris Chang

Editors



Surgery
Dr. Shih-Yung Lin



Research
Dr. Eric Hsu



Case reports
Dr. Bear Chen



Case reports
Dr. Joy Cheng



Digital information
Dr. Lexie Y. Lin



Illustration
Dr. Rungs Thavarungkul



English editing
Paul Head



Proofreader
Tzu Han Huang



Desk editor
Chester Yu



Desk editor
Annie Chen



Dr. Chris Chang

Non-Extraction Aligner Treatment for Moderate Crowding and Flared Upper Incisors in a Female with a Flat Facial Profile and Prominent Chin

Abstract

Introduction: A 27-yr-1-mo-old female presented with chief complaints (CC) of flared and crowded incisors. She preferred aligner treatment to avoid oral hygiene problems.

Diagnosis: An assessment of the face revealed slightly concave profile (-2°), increased facial height (54.9%), decreased mandibular plane (FMA, 21°), protrusive maxilla (SNA, 82.0°), protrusive mandible (84.5°), and an intermaxillary discrepancy (-2.5°). Furthermore, there were severely flared incisors (129°) and retroclined lower incisors (77.5°). The dental midline was shifted 2mm to the left, and there was 6mm of crowding in the lower dentition. The Discrepancy Index (DI) was 17.

Etiology: The severe anterior crowding was due to the limited arch development in width.

Treatment: Clear Invisalign® aligners (Align Technology, Inc., San Jose, Calif) were used for the correction of the moderate crowding, flared upper incisors, and retroclined lower incisors. The crowding was mainly relieved by inter-proximal reduction (IPR) and arch expansion. Furthermore, smart-feature attachments were used to improve the rotated teeth. The buccal power ridges were designed for increasing the lingual root torque of the lower anterior teeth. Simultaneous dental movement was employed, and IPR was sequentially performed during the arch expansion and tooth rotation process. During the active treatment of 41 stages, off-tracking occurred on several anterior teeth in the 26th stage, so the remaining stages of aligner treatment were aborted and additional aligners for refinement were constructed. Four sets of additional aligners improved alignment and detailing.

Results: This crowded and canted dentition, with a Discrepancy Index (DI) of 17, was treated in 29 months with an excellent outcome, with a Cast-Radiograph Evaluation (CRE) score of 13 and a Pink and White dental esthetic score of 2. Both arches were well-aligned, and a Class I relationship was achieved. However, after concluding the treatment, slight bilateral posterior open bite still remained and the LL3, LR2 and LR3 still showed minor black triangles.

Conclusions: Crowded end-on Class III dentitions can be treated with IPR and arch expansion to relieve the crowding and allow tilted incisors to be up-righted without further extraction and miniscrew application. (J Digital Orthod 2022;66:4-22)

Key words:

Invisalign, aligner treatment, crowding, flared incisors, anterior crossbite, end-on Class III, arch expansion, inter-proximal reduction (IPR)

Introduction

The dental nomenclature used for this report is a modified Palmer notation. Upper (U) and lower (L) arches, as well as the right (R) and left (L) sides,

define four oral quadrants: UR, UL, LR, and LL. Teeth are numbered 1-8 from the midline in each quadrant, e.g., a lower right first molar is LR6.

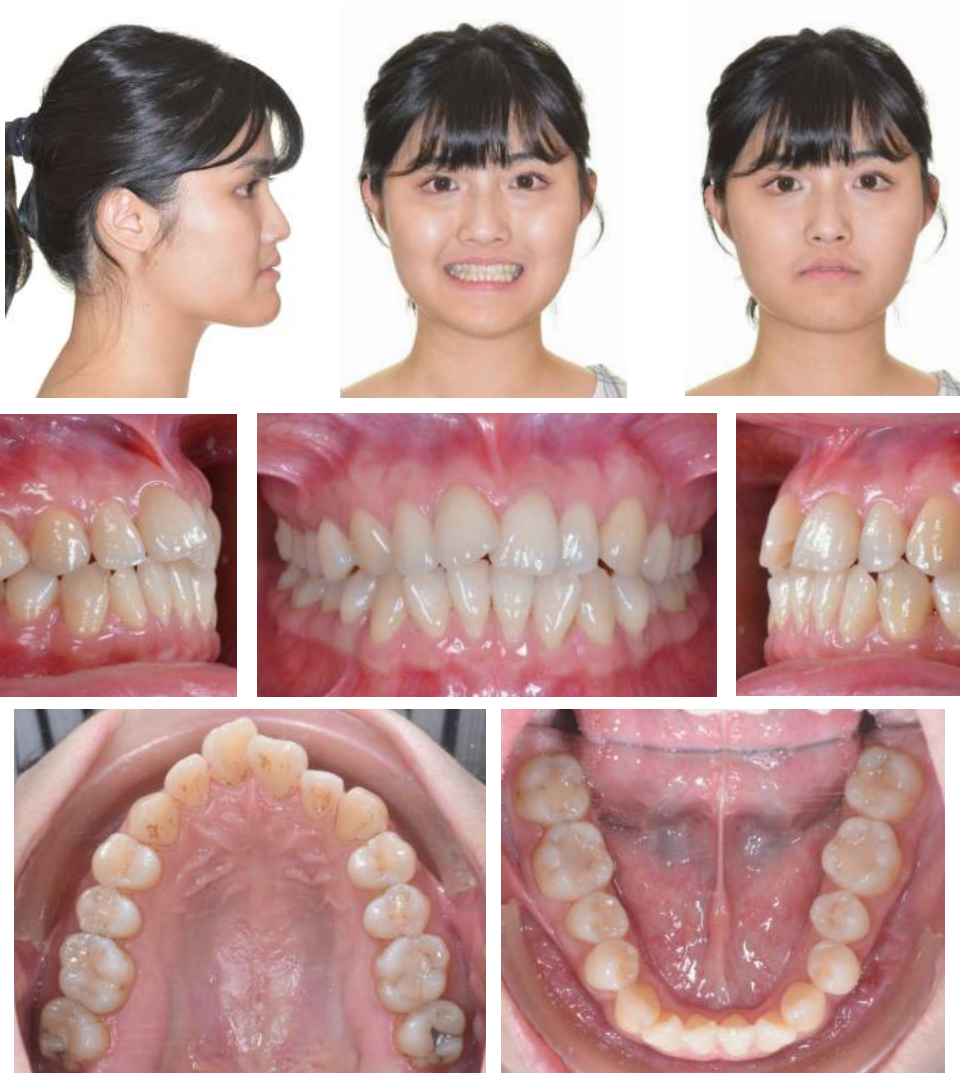Yu-Hsin Huang,*Diplomate, International Association of Orthodontists and Implantologists (Left)***Chris H. Chang,***Founder, Beethoven Orthodontic Center**Publisher, Journal of Digital Orthodontics (Center)***W. Eugene Roberts,***Editor-in-Chief, Journal of Digital Orthodontics (Right)*

History and Etiology

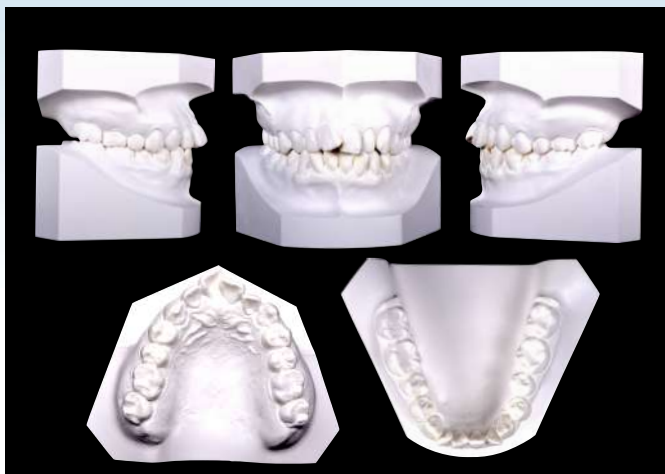A 27-year-1-month-old female presented with a relatively straight facial profile, occlusal cant, midline shifted 2mm to the left, crowding in both arches,

flared upper central incisors, and retroclined lower incisors (Figs. 1-5).

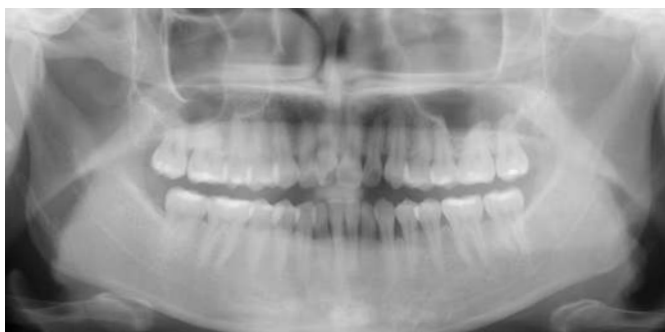There was no history of significant trauma, dental problems, or medical disorders. The etiology appeared to be either the narrow alveolar bone of



■ **Fig. 1:** Pre-treatment facial and intraoral photographs

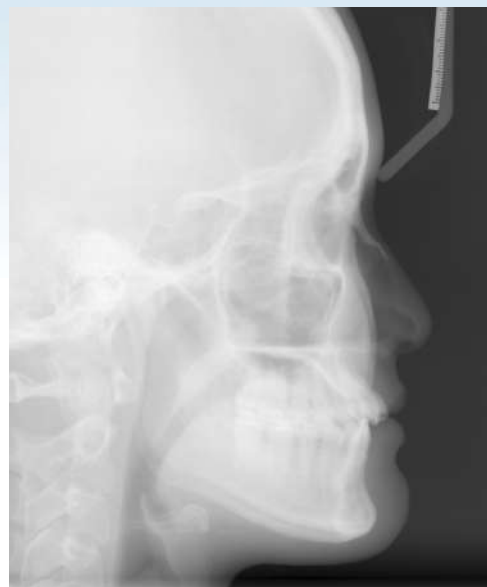

■ **Fig. 2:** Pre-treatment study models (casts)



■ **Fig. 3:** Pre-treatment panoramic radiograph

the arches that expanded insufficiently during growth, or the poor habit of thumb/pacifier sucking and tongue thrusting, which therefore limited the anterior teeth erupting normally in the early mixed dentition. The constricted arch lengths could not accommodate all the anterior teeth in the proper positions, resulting in the canting and crowding. After reaching adulthood, she searched for an ideal solution to correct the malocclusion for esthetic improvement (Fig. 1). The pre-treatment study models (casts), as well as panoramic and cephalometric radiographs, are shown in Figs. 2-4. The cephalometric analysis is presented in Table 1.



■ **Fig. 4:** Pre-treatment cephalometric radiograph. Note the straight profile and the flared incisors.

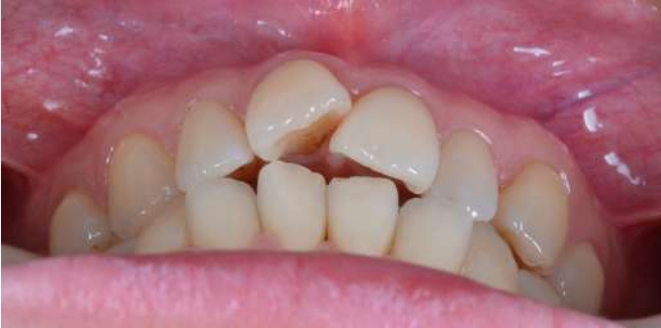

■ **Fig. 5:** Flared incisors within the concave mid-face

Diagnosis

Facial:

- Facial Height: *Increased (54.9%) with tapered facial form*
- Protrusion: *Relatively retrusive lips (upper: -5mm to the E-Line; lower: -4mm to the E-Line)*



■ **Fig. 6:** Flared central incisors, LL2 crossbite and retroclined canines

- Symmetry: Maxillary dental midline 2mm to the left of the occlusal plane cant (Fig. 1)
- Smile line: Upper lip curtain had a median elevation, but was consistent with the occlusal cant on the left side (1mm inferior on the patient's right side)

Skeletal:

- Intermaxillary Relationship: Protrusive maxilla (SNA, 82.0°) and mandible (SNB, 84.5°) and intermaxillary skeletal discrepancy (ANB, -2.5°)
- Mandibular Plane: Insufficient inclination (SN-MP, 31°; FMA, 23°) (Fig. 5; Table 1)
- Vertical Dimension of Occlusion (VDO): Excessive Na-ANS-Gn (54.9%)
- Symmetry: Within normal limits

Dental:

- Classification: End-on Class III on both sides
- Overbite: 1mm
- Overjet: 6mm

- Missing/Unerupted: None
- Symmetry: Upper midline deviated 2mm to the left, as well as occlusal cant (Fig. 1)

The ABO Discrepancy Index (DI) was 17 as documented in the subsequent worksheet.¹

Treatment Objectives

The treatment objectives were to: 1. correct the flared upper incisors, retroclined lower incisors, and asymmetric dental arches, 2. improve the canted and crowded dentition, and 3. coincide the upper dental midline to the facial midline.

CEPHALOMETRIC SUMMARY			
SKELETAL ANALYSIS			
	PRE-TX	POST-TX	DIFF.
SNA° (82°)	82.0°	83.0°	1°
SNB° (80°)	84.5°	84.5°	0°
ANB° (2°)	-2.5°	-1.5°	1°
SN-MP° (32°)	28°	28°	0°
FMA° (25°)	21°	21°	0°
DENTAL ANALYSIS			
U1 TO NA mm (4 mm)	8	3.5	4.5
U1 TO SN° (110°)	129°	102°	27°
L1 TO NB mm (4 mm)	1	1	0
L1 TO MP° (90°)	77.5°	75°	2.5°
FACIAL ANALYSIS			
E-LINE UL (-1mm)	-5	-5	0
E-LINE LL (0 mm)	-4	-3	1
%FH: Na-ANS-Gn (53%)	54.9%	55.3%	0.4%
Convexity: G-Sn-Pg' (13°)	-2°	-1°	1°

■ **Table 1:** Cephalometric Summary

Maxilla (all three planes):

- A-P: *Maintain.*
- Vertical: *Maintain.*
- Transverse: *Maintain.*

Mandible (all three planes):

- A-P: *Maintain.*
- Vertical: *Maintain.*
- Transverse: *Maintain.*

Maxillary Dentition:

- A-P: *Decrease.*
- Vertical: *Maintain.*
- Inter-Molar/Inter-Canine Width: *Maintain/expand.*

Mandibular Dentition:

- A-P: *Maintain.*
- Vertical: *Maintain.*
- Inter-Molar/Inter-Canine Width: *Maintain/expand.*

Facial Esthetics:

- *Maintain.*

Treatment Alternatives

In this moderately crowded dentition, sufficient space had to be created for proper alignment. Judging from the profile, SN-MP (FMA) angle, overbite, and incisor inclination are all important when considering alternative treatments. Possible treatment options are listed below (Fig. 7):

Option 1:

Relieve the crowding by extracting 4 premolars.

Option 2:

Relieve the crowding by expanding the arches.

Option 3:

Relieve the crowding with moderate inter-proximal reduction (IPR).

Rationale: An Invisalign provider is trained to create a customized tooth alignment orthodontic plan using the ClinCheck® software (Align Technology, Inc., San Jose, Calif) after receiving all the necessary data. Orthodontists can develop more detailed treatment plans when utilizing the simulation feature of this software. The information regarding the digital steps of the sequence of each tooth movement and the differences from the starting aligner to the final one allows the provider to decide which tooth or steps need further modification.

For the first treatment option, four first premolar extraction provides too much space, which could cause excessive retraction of anterior teeth, as well as a dished-in profile. In the design of aligner treatment progress, large extraction space increases the distance the teeth must move, consequently

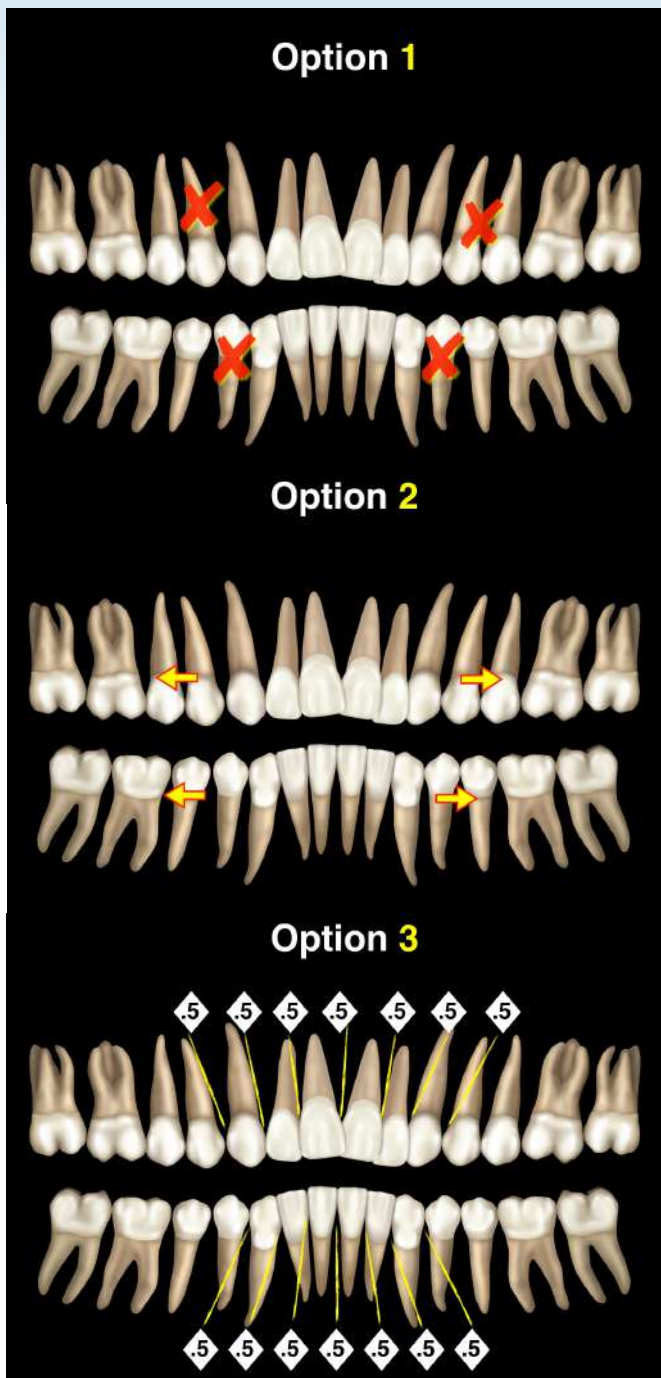


Fig. 7:
Diagram showing the configuration of different treatment plans of tooth extraction, arch expansion, and IPR.

increasing the difficulty of the treatment. Therefore, the number of aligners and refinement plans may have to be increased incrementally.

For the second option, by expanding the arch without extraction and IPR, treatment planning focuses on the preservation of integral teeth and facial profile. However, it is usually suitable for minor crowding or easy cases which need less tooth movement and space creation. Thus, a Class I occlusal relationship with correct midlines of both arches would be easier to manipulate. However, pure arch expansion faces other risks, namely more flared incisors, and possible failed de-crowding due to insufficient arch expansion. In order to reverse the severe side effect of flared out anteriors, bone screws may be necessary as definitive anchorage.

The third option of IPR procedures can be used to relieve excessive crowding. In aligner treatment, less tooth movement is desirable. From the digital analysis in virtual orthodontic progress, reasonable dental reduction can be evaluated for the resolution of dental crowding. Therefore, with less tooth movement and arch expansion, the treatment progress becomes simple and easy. In other words, without premolar extraction and excessive anterior flaring, which are commonly encountered in the first two options, the number of aligners can be markedly reduced, and the final result will be more predictable and stable.




Table 2:
The simultaneous movement of all teeth was planned in the initial alignment.

Treatment Progress

Simultaneous movement of the whole dentition was designed in the staging progress (Table 2), and the main tooth movements were as follows:

1. Extrude and rotate upper central incisors.
2. Expand upper and lower inter-canine distances.
3. Intrude lower anterior teeth.

In the first phase, the aligners was free of attachments, allowing the patient to get used to the wearing process with less restrictions. After 5 days, all the attachments were placed from the second stage of the first set, and each aligner was worn for 10 days (Figs. 8 and 9). One and a half months later, the aligners were well-fitted to all teeth. Therefore, aligners 6-11 were prescribed and were worn for 7 days each. After 1 month, 8 more aligner stages were given to the patient. After 5 months of active treatment, LL2 showed 1mm off-tracking. The wearing time of each aligner was increased to 10 days. By the 26th stage, the aligner

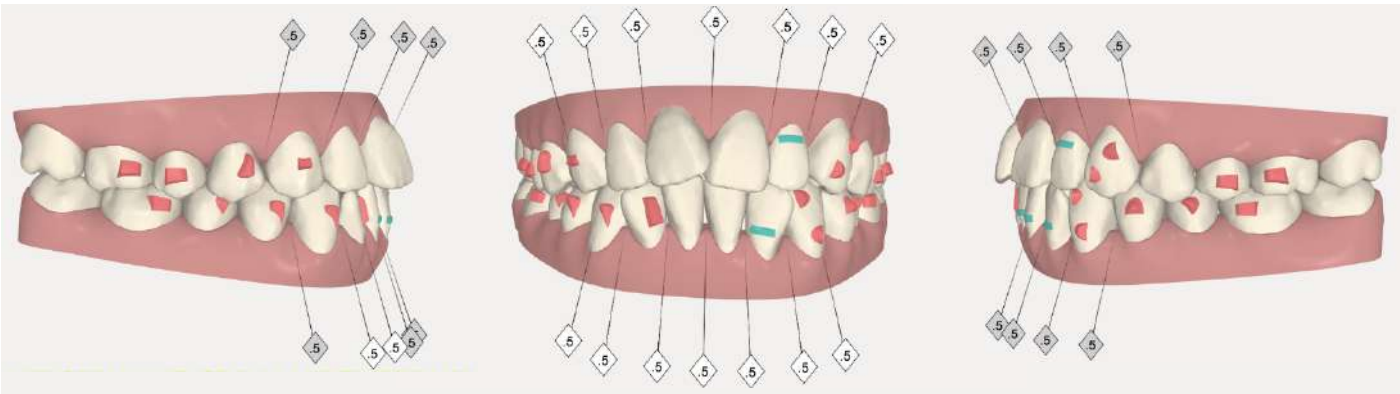


Fig. 8:
Initial setup of the attachments including rectangular and optimized features, IPR around the anterior teeth and upper first premolars, as well as power ridges placed in the late stages of first aligner set.

showed multiple off-track places, especially on UR2, UR1, UL2, LR2, and LL2 (Figs. 10 and 11). Therefore, the need for aligner refinement treatment was identified.

After 9 months of treatment, the second set of 33 aligners was delivered to correct the off-tracking. Further IPR was performed at the 27th stage. After

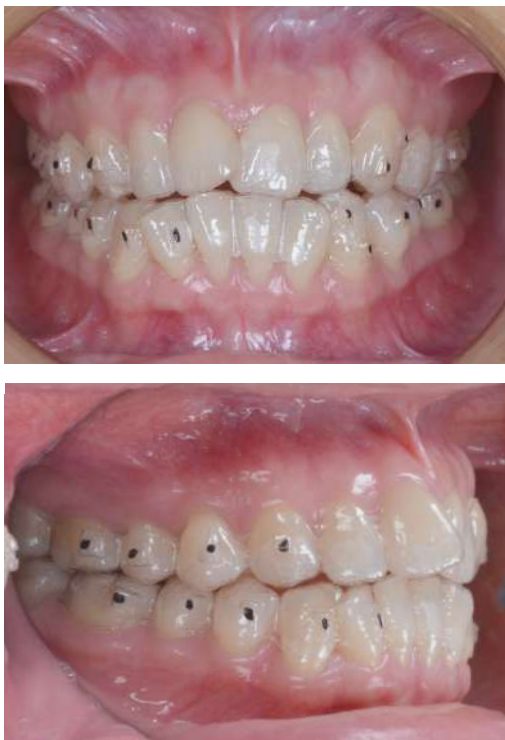

Fig. 9:
Dark markers can help the clinician to see where to place the attachments.

15 months of treatment, the major dental crowding was relieved. UR1, UL2, and LL2 showed slight rotation, and slight open bite was noted for the posterior teeth (Fig. 12); therefore, more refinement procedures were approved, which focused on pushing UR1 mesial-in, rotating UL2 and LL2 mesial-out, and eliminating the free occlusal contact on the left side for this section of the treatment program. All the aligners were worn with a 7 day protocol.

After 20 months of treatment, UL2 and LL2 did not rotate with enough angulation and needed more mesial-out action to even up the incisal edges. Besides, the lower anterior black triangles were more obvious (Fig. 13). Therefore, IPR was applied between LR2 and LL2 during the next set of aligners. New attachments were placed on UR4, UL7, LL7, and LR2, and old attachments were preserved for the other teeth when delivering new scanning data to the aligner company. 10 aligners were delivered in this part of refinement. In the next refinement of 9 aligners, detailing the occlusion included mesial-out actions of four lateral incisors. Finally, the last refinement of 18 aligners focused on closure of remaining spaces and occlusal contact cultivation. The total

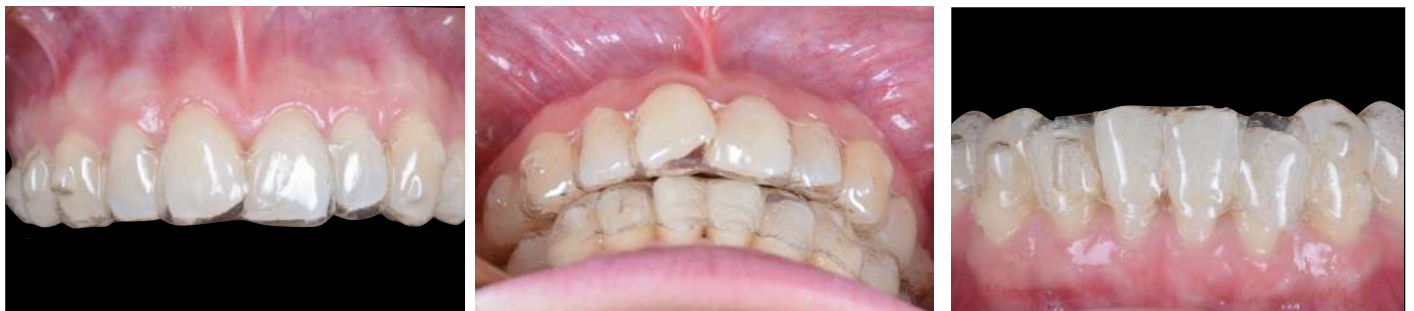

Fig. 10: The first set was halted due to off-tracking of UR2, UR1, UL2, LR2, and LL2 at the 26th stage.

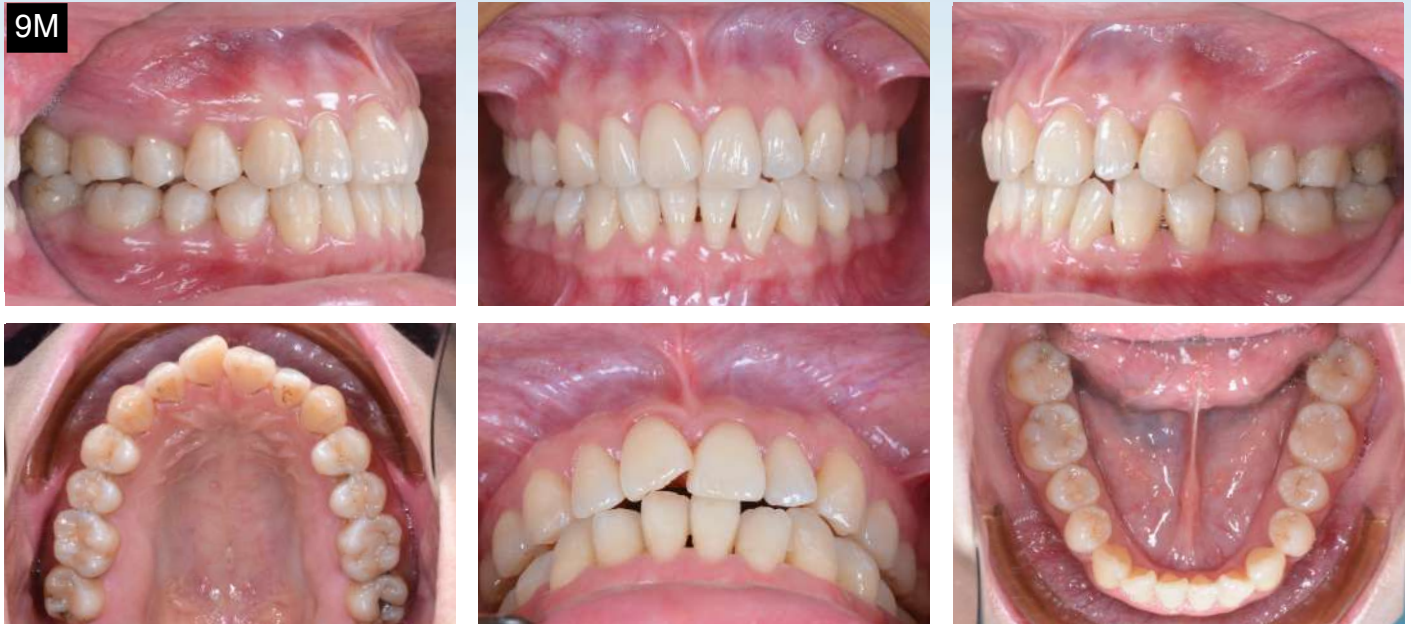

Fig. 11:

After the first set of treatment (9 months (9M)), the arch expansion was not ideal. Further arch expansion was prescribed, and further IPR was performed. A posterior open bite occurred and was corrected in the next set of aligners.

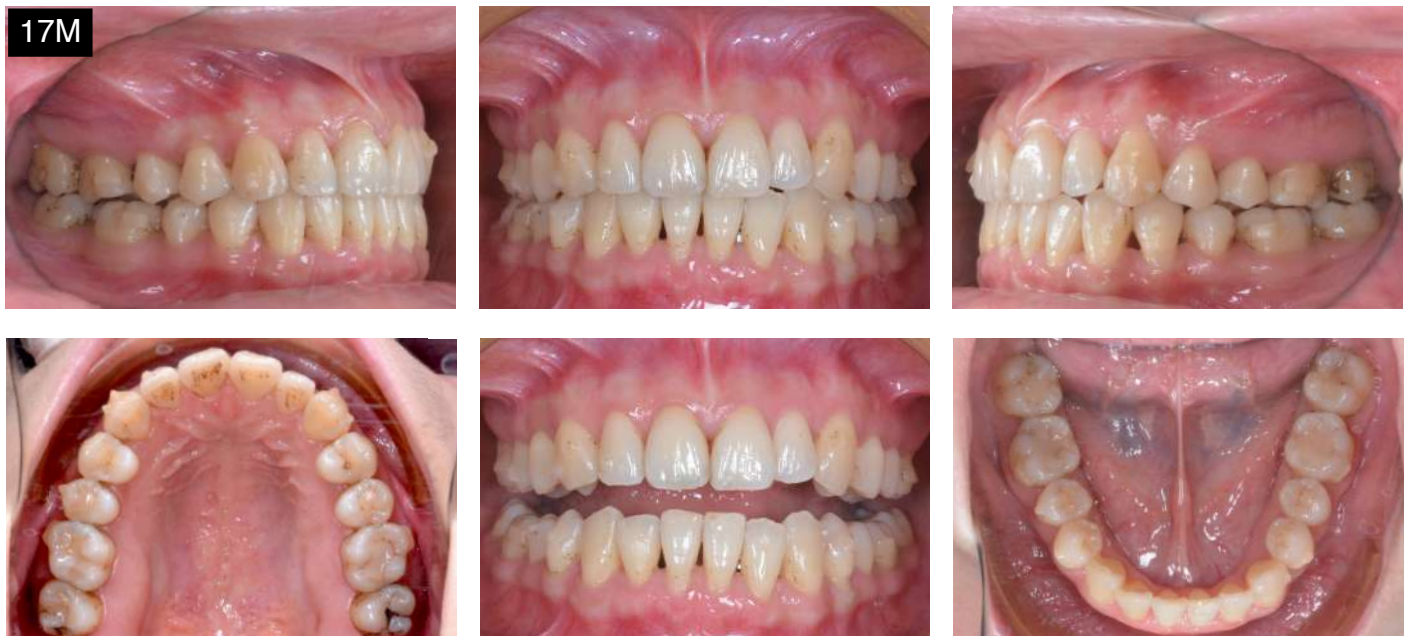
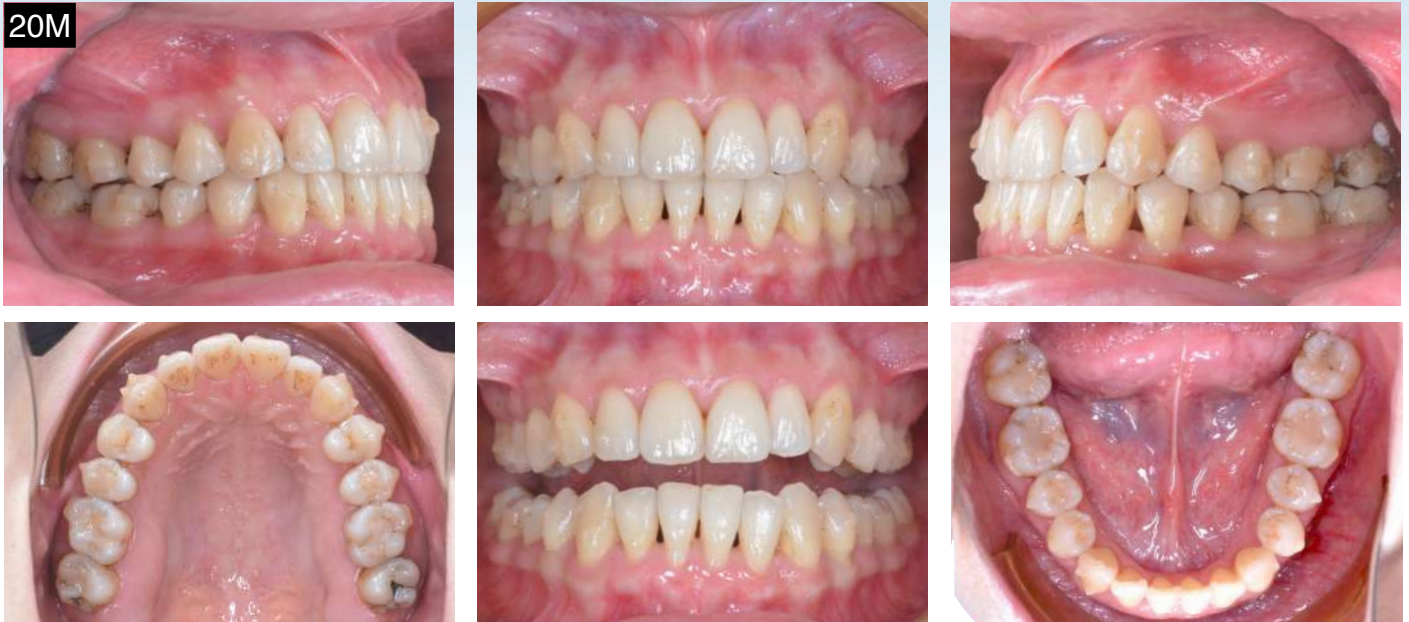
Fig. 12:

After the second set of treatment (17 months (17M)), the anterior crowding was almost solved. All four lateral incisors as well as LL6 and LR6 appeared to be intruded compared to the adjacent teeth. The anterior black triangles were to be decreased with IPR.



■ **Fig. 13:** After 20 months of treatment (20M), the UL2 and LR2 showed rotated positions. Further IPR is needed to create space.

treatment time was 29 months, and all the attachments and auxiliaries were removed (Figs. 14 and 15).

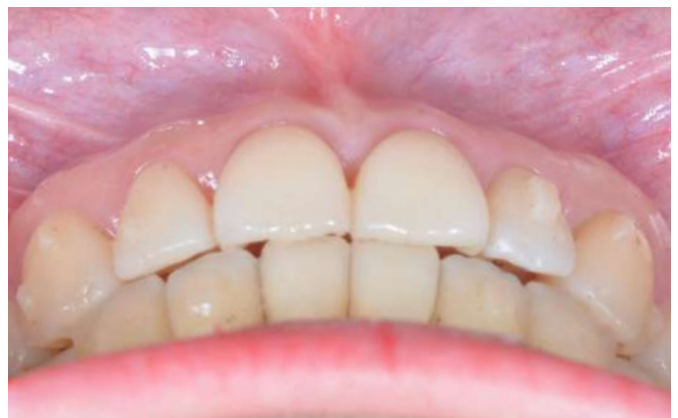Results achieved

The moderate crowding, flared UR1 and UL1, and UL2 in cross bite (DI=17) were corrected to a more symmetric result (CRE=13) with 29 months of aligner treatment as documented in Worksheet 2 at the end of this report. Despite only moderate IPR, the occlusion was finished in Class I (Figs. 16-19). LFH (VDO) increased 0.4% and FMA, SN-MP, and SNB angles remained unchanged. The profile only increased 1° (final convexity: G-Sn-Pg', -1°) (Figs. 18 and 19). Despite minimal change in the lip profile, the upper incisors were markedly up-righted by 27° (Table 1).

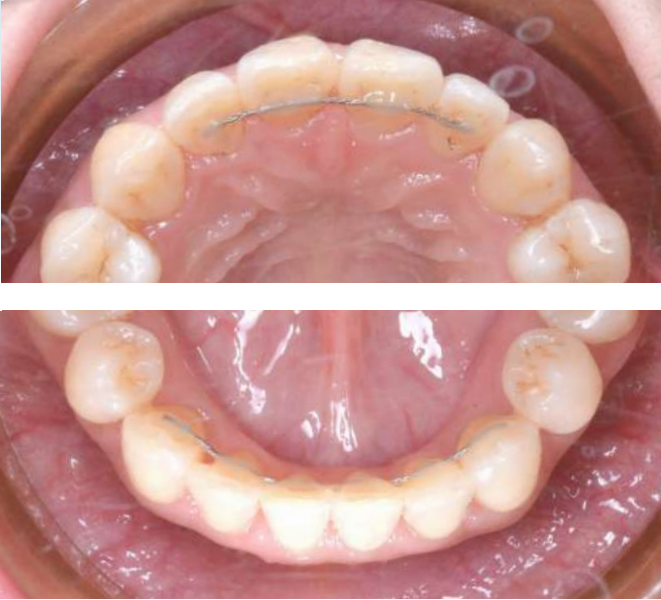
The specific treatment objectives are outlined below:

Maxilla (all three planes):

- A-P: *Maintained*
- Vertical: *Maintained*
- Transverse: *Maintained*



■ **Fig. 14:** Central incisor open bite was completely corrected.



■ **Fig. 15:** Fixed retainers were delivered after aligner treatment.

Mandible (all three planes):

- A-P: *Slightly advanced*
- Vertical: *Maintained*
- Transverse: *Maintained*

Maxillary Dentition:

- A-P: *Slightly retracted incisors*
- Vertical: *Slightly intruded molars*
- Inter-Molar/Inter-Canine Width: *Maintained/Increased*

Mandibular Dentition:

- A-P: *Incisors retracted*
- Vertical: *Molars up-righted*
- Inter-Molar/Inter-Canine Width: *Maintained*

Facial Esthetics:

- Lateral profile maintained (Fig. 16)

Retention

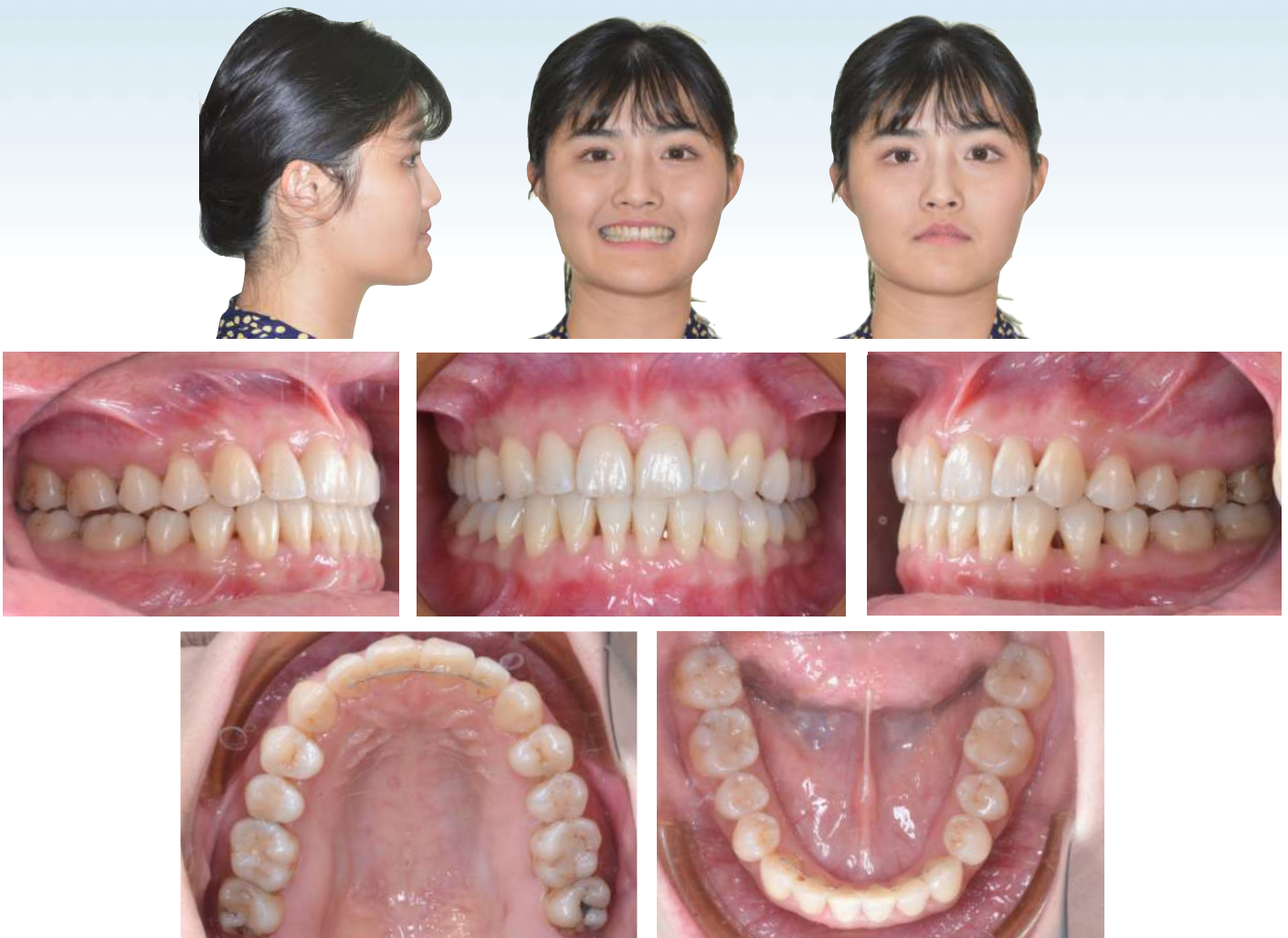Sectional twisted wires were bonded on UR2 to UL2 and LR3 to LL3 after the aligner treatment. Two ESSIX retainers were given to the patient to maintain the correct alignment and leveling of the dentition in both arches. The patient was instructed to use these retainers throughout the day during the first month and then only while sleeping (Fig. 15).

Final Evaluation

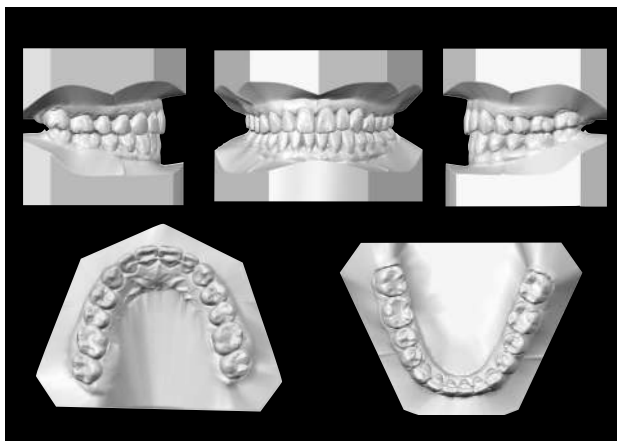
A Class I occlusion was achieved with proper overbite and overjet, and the lower midline was coincident with the upper midline. The ABO Cast-Radiograph Evaluation was 13 points. Rotation, marginal ridge, buccal lingual angulation, and overjet showed excellent results, but the occlusal contacts were compromised (10 points). The deficiencies of occlusal relationship were 4 points. The Pink and White (P&W) dental esthetic score was 2, with symmetry and harmony. The CRE and P&W scores are shown at the end of the case report as Worksheets 2 and 3, respectively.

Discussion

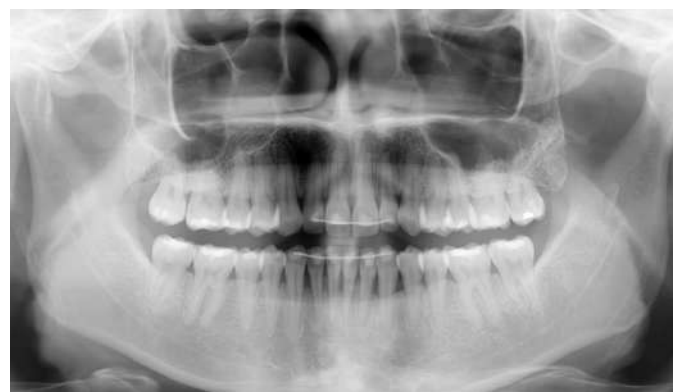In orthodontics, there are five main ways to create space: tooth extraction, anterior tooth flaring, posterior tooth retraction, arch expansion, and inter-proximal dental reduction. Generally, tooth extraction can create space over 7mm, which is



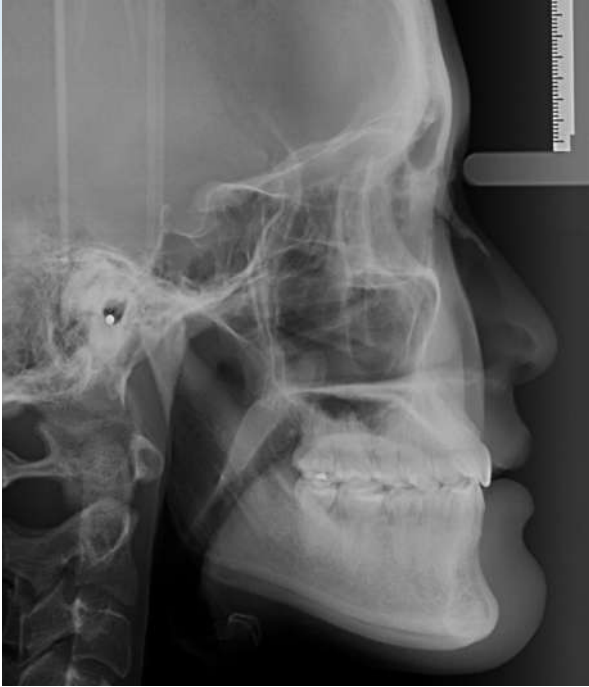■ Fig. 16: Posttreatment facial and intraoral photographs



■ Fig. 17: Posttreatment dental models (casts)



■ Fig. 18: Posttreatment panoramic radiograph



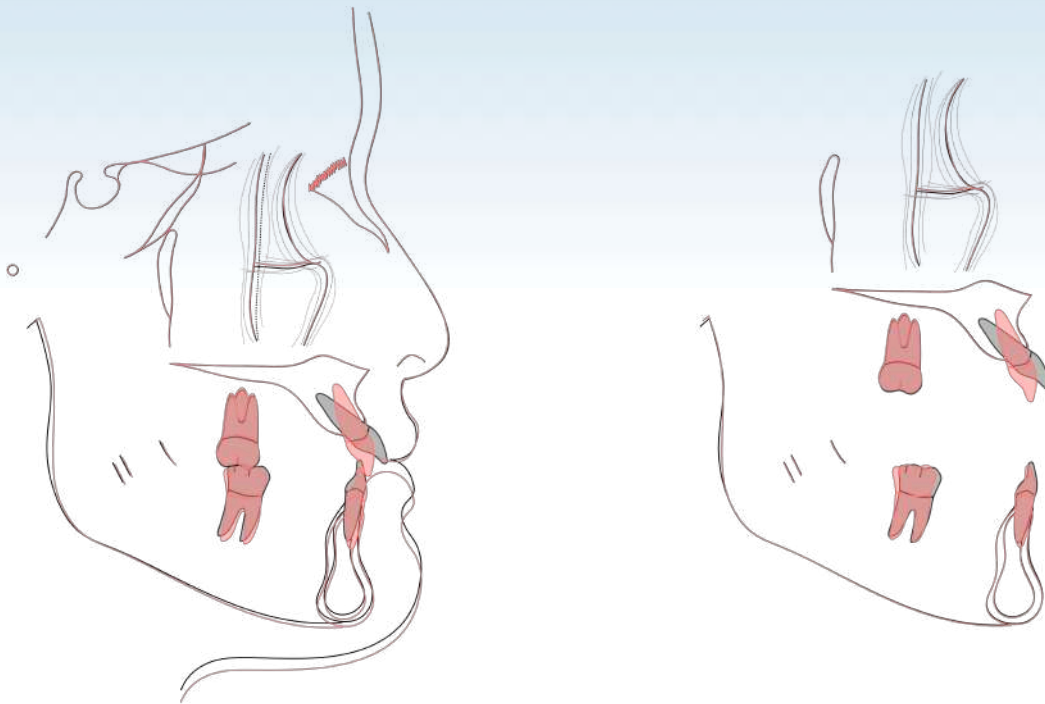
■ **Fig. 19:** Posttreatment cephalometric radiograph

useful not only for relieving moderate crowding, but also for anterior retraction. Therefore, for this case, the space created after removing 4 premolars was about 30mm for only 6mm of crowding relief. Closure of the excess space would make the straight profile more recessive.² Due to the patient's flared anterior teeth, other conventional space creation methods were unsuitable because the pre-treatment incisal angulation was 129°, which was 19° more than the standard value. Therefore, the teeth could not be flared any further. Conversely, the original incisal angulation was reduced by up-righting the teeth instead of flaring them.

Posterior tooth retraction is a good way for creating space whilst avoiding tooth extraction, but the amount of space created is related to the

stability of the designed anchorage. When treating with aligners, the sequential distalization of the posterior teeth can increase the anchorage by allowing movement of only one or two teeth in each aligner activation. Hence, the result after sequential distalization usually can not achieve the designed positions, as much stronger anchorage is required. Commonly, wearing Class II elastics or placing bone screws can achieve more predictable results for posterior tooth retraction. Bone screws provide outstanding anchorage, which can replace inter-arch elastics to avoid anchorage loss and the off-tracking side effect from the vertical force.³

In this case, upper and lower molar relationships were end-on Class III. When placing bone screws or wearing Class II elastics for retraction of the in the upper arch, an anterior crossbite might occur. However, placing bone screws for posterior teeth retraction was still included in this treatment planning as a de-crowding solution of the anterior teeth, as other ways did not work. Arch expansion is easy when faced with minor crowding.⁴ However, when crowding is moderate to severe, arch expansion is significantly related to the root anatomy and cortical plate thickness. Once arch expansion was underway in the treatment, the intended buccal tooth movement was constricted by the buccal bone. It is understood that the buccal bone is composed of cortical bone and therefore more resistant to resorption, so it may slow down the tooth movement or result in more root resorption.⁵ The thickness of buccal bone affects the speed of progress during the aligner treatment, which always needs continual refinement due to the dense bone. Sometimes, the



■ **Fig. 20:**

Superimposed pre-treatment (black) and posttreatment (red) cephalometric tracings show that the occlusion was finished at Class I, and the anterior teeth and lower molar were up-righted. Lower incisor was intruded. A clockwise rotation of the mandible was noticed.

posterior teeth become palatally tilted, which indicates that the coronal portion of tooth is in a more palatal position than the root. Therefore, when the tooth is pushed buccally in the arch expansion procedure, the tooth can move to the up-righted position with less difficult root translation and less resistance of the buccal bone. If a pushing action is employed as the main orthodontic force, arch expansion will be easier when the posterior teeth are tilted toward the palatal side.

IPR is an irreversible procedure which strips the inter-proximal enamel, but it can be an alternative to other space creation methods such as dental extraction.⁶ This procedure can resolve mild to moderate crowding up to 6mm and decrease the unesthetic presence of black triangles in the anterior

teeth. In this case, IPR was performed after the teeth were almost completely aligned, to better evaluate the amount required reducing. The results showed successful crowding relief and eradication of multiple black triangles. Regarding optimization of aligner treatments, tooth rotation, translation, and tipping processes are all digitally and statically staged in the relevant programs of the software. The extrusion and rotation rates are less accurate after aligner treatment.⁷⁸ If these tooth movements were to occur simultaneously, possible errors could increase during the progress. The risk of off-tracking increases, and the treatment could end with poor results. In order to reduce any unwanted mistakes, separating the actions and increasing the number of aligners can slow down and simplify the tooth movement from one stage into several stages.

Enlarging attachment size can improve the retention, especially when a tooth is short or round. The interferences of neighboring teeth before digital planning approval is considerable when relieving crowded dentitions.

Conclusions

The Invisalign aligner treatment can resolve moderate crowding using inter-proximal reduction and arch expansion, but the virtual steps of tooth movement should be optimized for the number of aligners by meticulously evaluating activations relative to the resistance of cortical bone. The patient was very pleased with her new smile, and the posttreatment result is stable (Figs. 21 and 22).

Acknowledgment

Thanks to Mr. Paul Head for proofreading this article.

References

1. Chang CH, Roberts WE. Orthodontics Vol. 1 [E-reader version]. Hsinchu: Newton's A; 2012.
2. Dai FE, Xu TM, Shu G. Comparison of achieved and predicted tooth movement of maxillary first molars and central incisors: First premolar extraction treatment with Invisalign. *Angle Orthod* 2019;89:679-687.
3. Hsu Y, Chang CH, Roberts WE. Extraction treatment for Class II open bite using the combination of aligners and IZC screws. *J Digital Orthod* 2021;63:4-16.



■ **Fig. 21:** Recall for dental stability evaluation



■ **Fig. 22:** A confident wedding smile was achieved.

4. Houle JP, L Piedade, Todescan R Jr, Pinheiro FH. The predictability of transverse changes with Invisalign. *Angle Orthd* 2017;87:19-24.
5. Roberts WE. Bone physiology, metabolism and biomechanics in orthodontic practice. In: *Orthodontics: Current Principles and Techniques*, Chapter 10, 5th ed. Graber LW, Vanarsdall RL Jr, Vig KWL (Eds). St. Louis: Elsevier Mosby; 2012. pp. 287- 343.
6. Huang YH, Chang CH, Roberts WE. Mandibular incisor extraction and interproximal reduction facilitates clear aligner treatment to correct UR2 crossbite with moderate crowding. *J Digital Orthod* 2019;55:4-22.
7. Rossini G, Parrini S, Castroflorio T, Deregibus, Devernardi C. Efficacy of clear aligners in controlling orthodontic tooth movement: A systematic Review. *Angle Orthod* 2015;85(5):881-889.
8. Grunheld T, Loh C, Larson B. How accurate is Invisalign in non extraction cases? Are predicted tooth positions achieved? *Angle Orthod* 2017;87(6) 809-815.



Discrepancy Index Worksheet

TOTAL D.I. SCORE

17

OVREJET

0 mm. (edge-to-edge)	=	
1 - 3 mm.	=	0 pts.
3.1 - 5 mm.	=	2 pts.
5.1 - 7 mm. 6mm	=	3 pts.
7.1 - 9 mm.	=	4 pts.
> 9 mm.	=	5 pts.

Negative OJ (x-bite) 1 pt. per mm. Per tooth = 2

Total = 5

OVERBITE

0 - 3 mm.	=	0 pts.
3.1 - 5 mm.	=	2 pts.
5.1 - 7 mm.	=	3 pts.
Impinging (100%)	=	5 pts.

Total = 0

ANTERIOR OPEN BITE

0 mm. (Edge-to-edge), 1 pt. per tooth
Then 1 pt. per additional full mm. Per tooth

Total = 2

LATERAL OPEN BITE

2 pts. per mm. Per tooth

Total = 0

CROWDING (only one arch)

1 - 3 mm.	=	1 pt.
3.1 - 5 mm.	=	2 pts.
5.1 - 7 mm. 6mm (lower)	=	4 pts.
> 7 mm.	=	7 pts.

Total = 4

OCCLUSION

Class I to end on	=	0 pts.
End on Class II or III	=	2 pts. per side 4 pts.
Full Class II or III	=	4 pts. per side _____ pts.
Beyond Class II or III	=	1 pt. per mm. _____ pts. additional

Total = 4

LINGUAL POSTERIOR X-BITE

1 pt. per tooth Total = 0

BUCCAL POSTERIOR X-BITE

2 pts. Per tooth Total = 0

CEPHALOMETRICS (See Instructions)

ANB $\geq 6^\circ$ or $\leq -2^\circ$ **0°** = 4 pts.Each degree $< -2^\circ$ _____ x 1 pt. = _____Each degree $> 6^\circ$ _____ x 1 pt. = _____

SN-MP **28°**
 $\geq 38^\circ$ = 2 pts.

Each degree $> 38^\circ$ _____ x 2 pts. = _____ $\leq 26^\circ$ = 1 pt.Each degree $< 26^\circ$ _____ x 1 pt. = _____1 to MP $\geq 99^\circ$ **77.5°** = 1 pt.Each degree $> 99^\circ$ _____ x 1 pt. = _____

Total = 0

OTHER (See Instructions)

Supernumerary teeth	_____ x 1 pt.	= _____
Ankylosis of perm. Teeth	_____ x 2 pts.	= _____
Anomalous morphology	_____ x 2 pts.	= _____
Impaction (except 3 rd molars)	_____ x 2 pts.	= _____
Midline discrepancy (≥ 3 mm)	@ 2 pts.	= _____
Missing teeth (except 3 rd molars)	_____ x 1 pt.	= _____
Missing teeth, congenital	_____ x 2 pts.	= _____
Spacing (4 or more, per arch)	_____ x 2 pts.	= _____
Spacing (Mx cent. diastema ≥ 2 mm)	@ 2 pts.	= _____
Tooth transposition	_____ x 2 pts.	= _____
Skeletal asymmetry (nonsurgical tx)	@ 3 pts.	= _____
Addl. treatment complexities 1	x 2 pts.	= 2

Identify: **Occlusal canting**

Total = 2

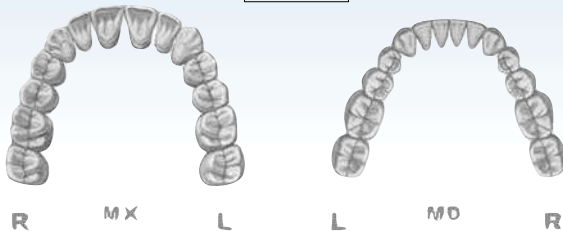
Cast-Radiograph Evaluation

Total Score:

13

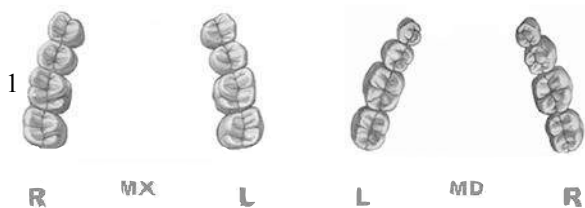
Alignment/Rotations

0



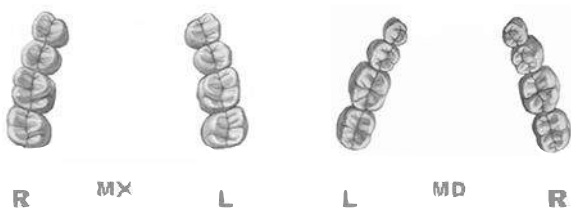
Marginal Ridges

1



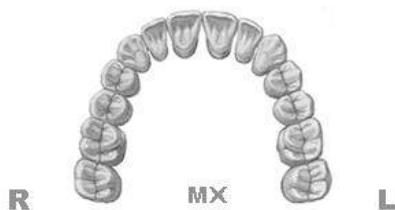Buccolingual Inclination

0



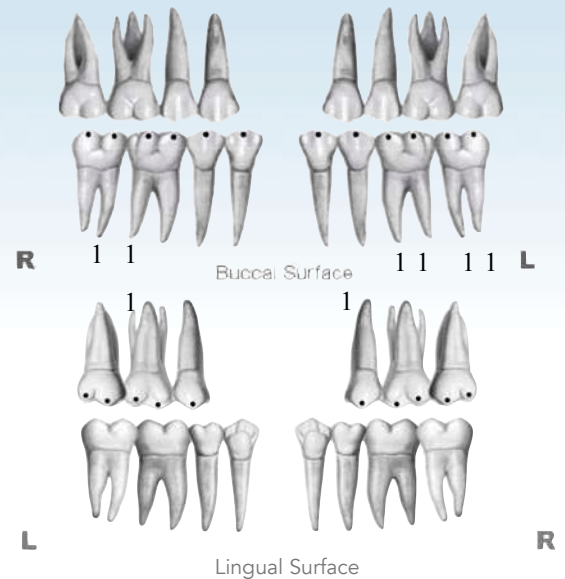
Overjet

0



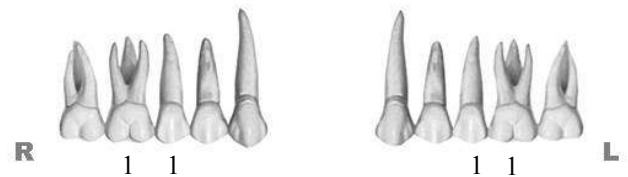Occlusal Contacts

8



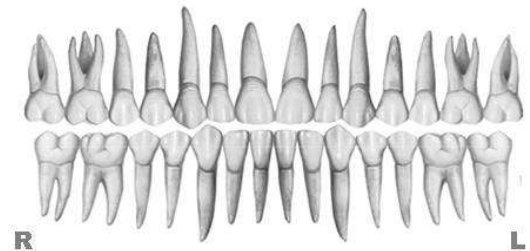
Occlusal Relationships

4



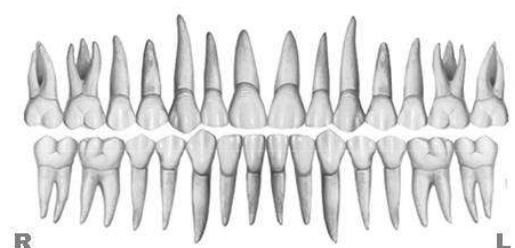
Interproximal Contacts

0



Root Angulation

0

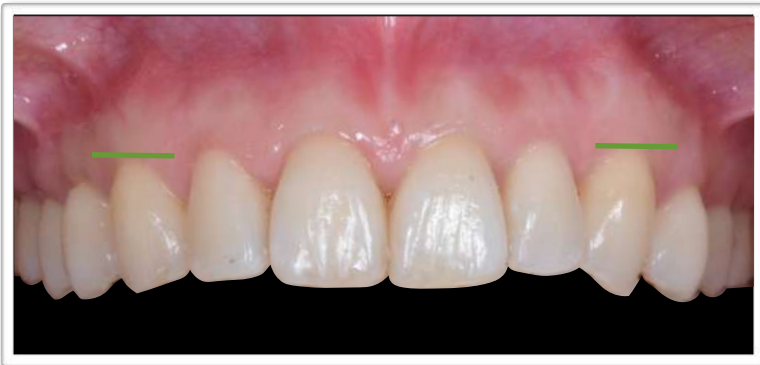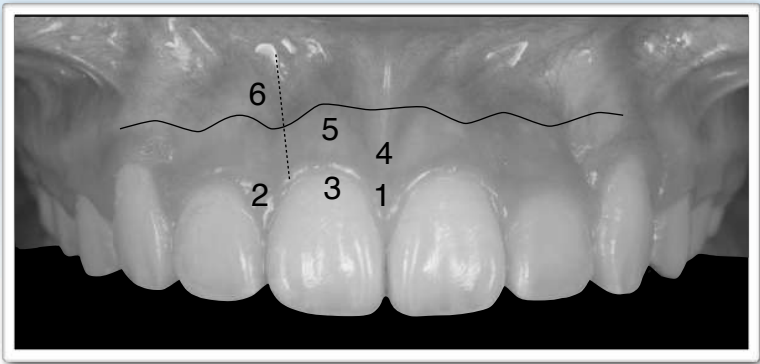


INSTRUCTIONS: Place score beside each deficient tooth and enter total score for each parameter in the white box. Mark extracted teeth with "X". Second molars should be in occlusion.

IBOI **Pink & White** Esthetic Score

Total Score = 2

1. **Pink** Esthetic Score

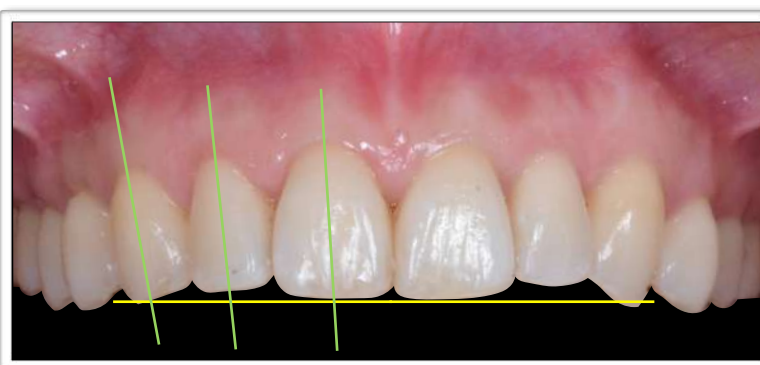
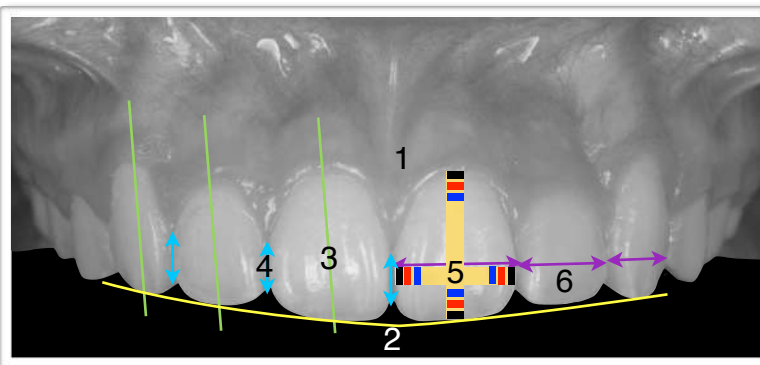


Total = 1

1. M & D Papillae	0	1	2
2. Keratinized Gingiva	0	1	2
3. Curvature of Gingival Margin	0	1	2
4. Level of Gingival Margin	0	1	2
5. Root Convexity (Torque)	0	1	2
6. Scar Formation	0	1	2

1. M & D Papillae	0	1	2
2. Keratinized Gingiva	0	1	2
3. Curvature of Gingival Margin	0	1	2
4. Level of Gingival Margin	0	1	2
5. Root Convexity (Torque)	0	1	2
6. Scar Formation	0	1	2

2. **White** Esthetic Score (for Micro-esthetic)



Total = 1

1. Midline	0	1	2
2. Incisor Curve	0	1	2
3. Axial Inclination (5° , 8° , 10°)	0	1	2
4. Contact Area (50% , 40% , 30%)	0	1	2
5. Tooth Proportion	0	1	2
6. Tooth to Tooth Proportion	0	1	2

1. Midline	0	1	2
2. Incisor Curve	0	1	2
3. Axial Inclination (5° , 8° , 10°)	0	1	2
4. Contact Area (50% , 40% , 30%)	0	1	2
5. Tooth Proportion	0	1	2
6. Tooth to Tooth Proportion	0	1	2

2022-2023 第十四年度 貝多芬 矯正精修班



時間：週二上午 09:00-12:00

地點：金牛頓教育中心（新竹市建中一路 25 號 2 樓）

上課日期：

2022 5/10、6/7、7/12、8/16、9/6、10/4、11/15、12/6

2023 1/10、2/7、3/7

- ▶ 09:00 ~ 10:00 精選文獻分析
- ▶ 10:00 ~ 10:30 精緻完工案例
- ▶ 10:50 ~ 12:00 臨床技巧及常犯錯誤分享

全新的第十四年度 2022-23 貝多芬精修班，是由國際知名講師張慧男醫師主持，並偕同貝多芬牙醫團隊住院醫師群共同主講。

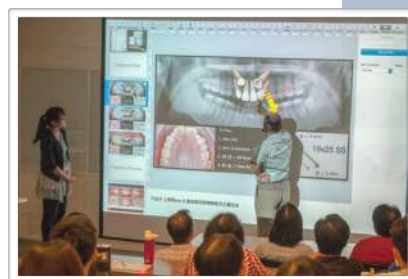每月一次的課程之中，包含了：

1. 精選矯正權威期刊 AJODO 的文章做文獻分析與評讀。
2. 精緻完工 ABO 案例報告，其中因應數位矯正的世界趨勢，Insignia 與 Invisalign 病例為課程探討的主要內容之一。
3. 分享臨床上常犯的錯誤以及解決方法。

2022-23 貝多芬精修班內容豐富精彩，讓您經由每個月一次的課程，在面對各式的臨床案例時，更能游刃有餘、得心應手。

學習目的：

研讀最新趨勢文章可以窺知世界文獻公認的治療方式，而藉由評論文章的優缺點不僅能夠訓練判斷與思考能力，更可以清楚比較作法上的不同，達到完整理解治療方向、內容與穩定性的目標。



報名專線：03-5735676 #218 陳小姐



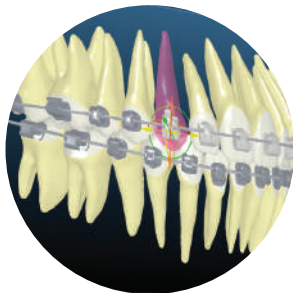
International Workshop

Digital Orthodontics, OBS, VISTA

Digital



@Taiwan 🇹🇼

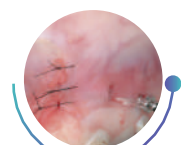
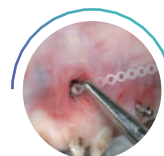
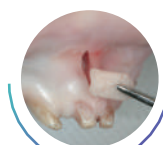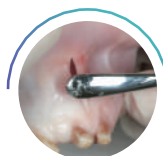INSIGNIA



OBS

Beethoven's International Workshop is designed for doctors who provide orthodontic treatment using the Damon and Insignia System. This workshop is consisted of lectures, hands-on workshops as well as chair-side observation sessions. Participants will have the opportunity to observe clinical treatment, didactic lectures, live demonstration and gain hands-on practice experiences involving TAD placement, indirect bonding, CBCT-enhanced digital treatment planning for Insignia.



VISTA Vertical Incision Subperiosteal Tunnel Access

Registration:

Day 123 USD 3,600 Early bird rate: \$100 off (advanced registration two months prior to the course date)

Day 4 USD 600 Early bird rate: \$100 off (advanced registration two months prior to the course date)

For more information and registration, visit

<http://iworkshop.beethoven.tw>

course@newtonsa.com.tw
+886-3-5735676 #218 Annie





Course Schedule

Day

1

Chair-side observation

Day

2

Insignia Lecture, Chair-side observation

Chris' Lecture:

Digital Orthodontics with TAD

Day

3

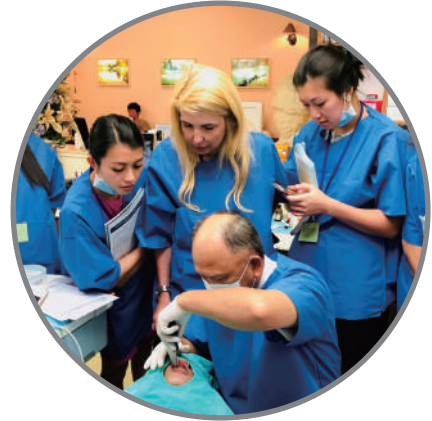VISTA Lecture & workshop

Chris' Lecture:

VISTA for Impacted Cuspids

* The topics for VISTA workshop:

1. VISTA with screw placement
2. VISTA with connective tissue graft
3. Suture technique



Prof. Dr. Paulo Fernandes Retto, Portugal

"Dr. Angle would be glad to know that contemporary orthodontics has a professional as Chris Chang!"

Digital Orthodontics, OBS & VISTA

Day

4

Keynote workshop (Optional)

by Newton's A team

1. Patient clinical records management
2. Patient communication presentation
3. Basic animations and visual aids



Dr. Rungsi Thavarungkul, Thailand



"If you think this is a computer course that will show you step-by-step how to use the application, please reconsider. If you want to improve communication in your practice, and with patients, this 8-hour course is definitely worth it."

KEYNOTE

THE LECTURER



Dr. Chris Chang

CEO, Beethoven Orthodontic and Implant Group. He received his PhD in bone physiology and Certificate in Orthodontics from Indiana University in 1996. As publisher of *Journal of Digital Orthodontics-A journal for Interdisciplinary dental treatment*, he has been actively involved in the design and application of orthodontic bone screws.

戴蒙系統鉅作 感恩回饋

國際大師推薦，愛用好評如潮 **Damon Q2** × **Damon Clear**

OrmcoTM
YOUR PRACTICE. OUR PRIORITY.



特惠組1

DAMON **DAMON**₂

(Q/Q2 共200顆)



+ $\frac{6}{6} \frac{6}{6}$ $\frac{7}{7} \frac{7}{7}$ **Bondable Tube*** x 10 人份

特價 **NT\$135,999** /組



DamonQ2 特色

- Under tie-wing空間加大，掛Power chain好操作
- Torque, rotation角度控制升級
- 滑蓋scribe line標誌，提升臨床效率

+ 配件加購

Drop-in Hook

DQ/DQ2 插入式掛鉤

特價 **NT\$1,800** /盒

*限與訂單同時加購，訂單成立後恕無法再行追加。



Drop-in hook 使用說明



1. 插入矯正器vertical slot
(位於矯正器undercut遠心側)



2. 黃色點朝唇側/頰側，
將尾端彎折至矯正器凹槽內

特惠組2

DAMON **DAMON**₂
CLEAR **CLEAR**₂

(Clear/Clear2 共200顆)



+ $\frac{6}{6} \frac{6}{6}$ $\frac{7}{7} \frac{7}{7}$ **Bondable Tube*** x 10 人份

特價 **NT\$175,999** /組



* 以上販售及贈品品項皆不含 SnapLink Tubes, Accent Mini Tubes, A⁺



回饋贈禮！

選購特惠組1或2，即贈送以下矯正線

- .014 Damon Copper Ni-Ti x 20 條
感溫性鎳鈦合金線 - Level and Align
- .014 x .025 Damon Copper Ni-Ti x 20 條
感溫性鎳鈦合金線 - Begin Torque Control
- .016 x .025 Damon SS x 20 條
不鏽鋼合金線 - Space Closure
- .017 x .025 Damon Low-Friction TMA Wire x 20 條
低摩擦力鈦鉬合金線 - Finishing and Detailing



熱門
線徑





好評推薦！

動物圏 x Power Chain

買 Zoo Pack Elastics x 4 盒
動物圈



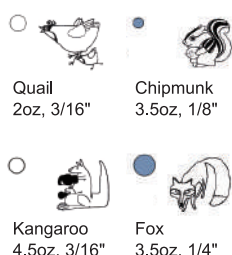
特價 **NT\$12,000** /組

贈 **Power Chain x 4 卷**
(任選open/close/wide)

矯正専用弾力鏈



矯正新手動物圈建議



Quail
2oz, 3/16"

Chipmunk
3.5oz, 1/8"

Kangaroo
4.5oz 3/1

Fox
3.5oz 1/4"



熱銷組！

小資新手矯正黏著套組

Bonding Sample Kit :

Enlight Syringe x 1 支

Ortho Solo x 1 瓶

光照含氟矯正專用黏著劑(4g) + 多功能光照基底劑(5ml)

⊕ Enlight Syringe x 2 支



特價 **NT\$5,000** /組

線定優惠組

買 **Copper Ni-Ti x 5 盒** (線徑任選)
感溫性鎳鈦合金線 - Level and Align

贈 *Low-Friction TMA* x 2 盒 (線徑任選)
低摩擦力鈦鋁合金線 - Finishing and Detailing



特價 NT\$14,500 /組

Non-Extraction Treatment for Excessive Overjet and Deep Bite with Aligners and IZC Screws

Abstract

Introduction: A 15-year-11-month-old female presented with chief complaints of protrusion and a severe deep bite.

Diagnosis: Cephalometric analysis revealed a skeletal Class I relationship (SNA, 87°; SNB, 84°; ANB, 3°), reduced facial convexity (-10°), as well as proclined upper and lower incisors. An intraoral assessment revealed canine Class II malocclusion with an 8mm overjet and an impinged deep bite. There were slight generalized spaces in the upper anterior dentition, and the Discrepancy Index (DI) was 35.

Treatment: The treatment plan was a non-extraction treatment using Invisalign® clear aligner therapy anchored with infrazygomatic crest (IZC) bone screws bilaterally. Class II elastics were used during the treatment to correct the relative position between the upper and lower arches. The active treatment time was 25 months with 3 refinements to effectuate the final result.

Results: Improved dentofacial esthetics and a better occlusal function were achieved after treatment. The Cast-Radiograph Evaluation (CRE) was 12, and Pink and White esthetics score was 4. No significant root resorption nor periodontal problems were noted. The patient was well satisfied with the final outcome.

Conclusions: With Chang's extraction decision table, a feasible treatment plan was completed with a pleasant result. In retrospect, the treatment time could have been decreased by adding virtual anterior bite ramps, which would reduce the bite-block effect. Overcorrection of intrusion for the lower anterior teeth was applied since, along with canine rotation, it is one of the most inaccurate movements in ClinCheck®. Rearranging the sequence of tooth movements by intruding the lower anterior teeth before retracting the upper arch may also improve this issue. (*J Digital Orthod* 2022;66:28-42)

Key words:

Excessive overjet, deep bite, clear aligner treatment, Invisalign®, IZC screws, anchorage

Introduction

The dental nomenclature for this case report is a modified Palmer notation with four quadrants: upper right (UR), upper left (UL), lower right (LR), and lower left (LL). Teeth are numbered 1-8 from the midline in each quadrant.

Patients who seek orthodontic treatment are often motivated by esthetic issues. Therefore, clear aligner is often an attractive option for patients not only for easier oral hygiene maintenance but also for its esthetics during treatment. Clear aligner treatment was initially introduced to treat mild orthodontic cases;¹ however,

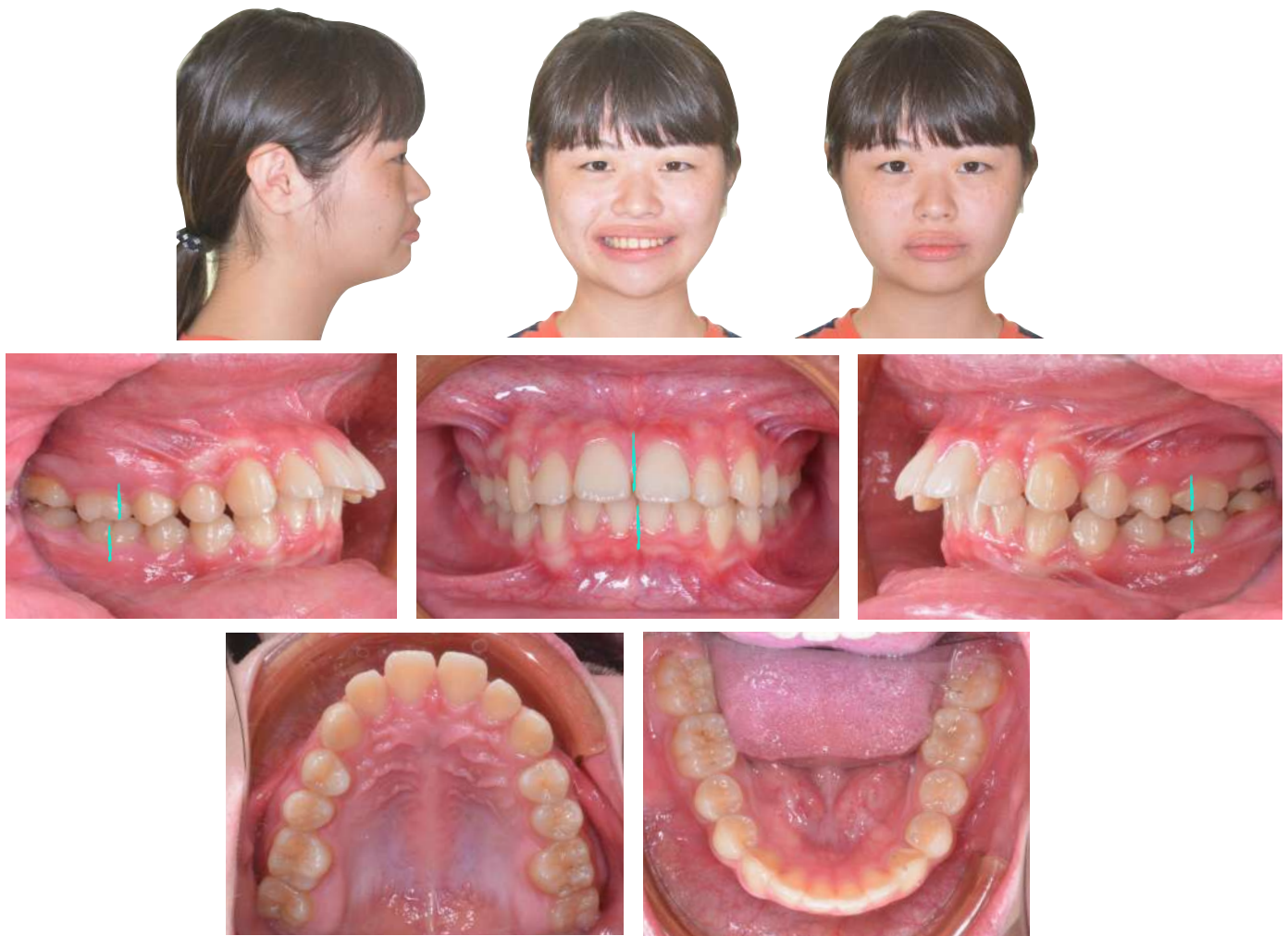several complex cases which were treated with Invisalign® appliances and achieved satisfactory results were recently reported.² One of the most common side effects when treating with aligners is the bite-block effect. The thickness of the aligners may cause intrusion of the posterior teeth and induce deepening of the overbite. As a consequence, deep bite cases treated with aligners are seldom reported,³ even less so if the case is complicated by excessive overjet. This special case report, which documents a patient with an 8mm overjet and deep bite treated with aligners and the aid of infrazygomatic crest (IZC) screws within 25 months, however, supports the feasibility and effectiveness of aligners in excessive overjet and deep bite cases.

Vicky T. Huang,*Resident, Beethoven Orthodontic Center (Left)***Bear C. Chen,***Associate Director, Beethoven Orthodontic Center (Center left)***Chris H. Chang,***Founder, Beethoven Orthodontic Center**Publisher, Journal of Digital Orthodontics (Center right)***W. Eugene Roberts,***Editor-in-Chief, Journal of Digital Orthodontics (Right)*

Diagnosis and Etiology

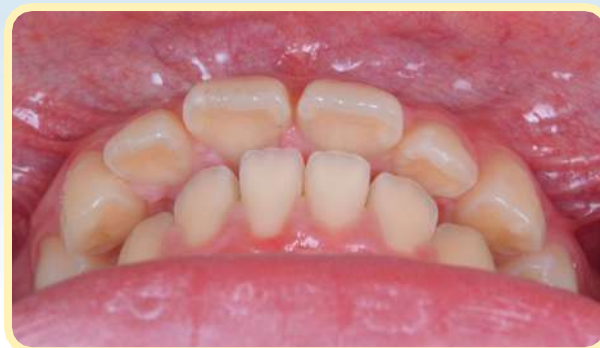A 15-year-11-month-old female presented with chief complaints of protrusive lips and a deep bite (Fig. 1). The patient had no significant medical or dental history, and oral hygiene was acceptable. A

radiographic examination was performed with a panoramic radiograph, lateral cephalometric film, and a temporomandibular joint (TMJ) series (Figs. 3-5). The panoramic radiograph showed three unerupted third molars with no pathological symptoms. The cephalometric analysis revealed

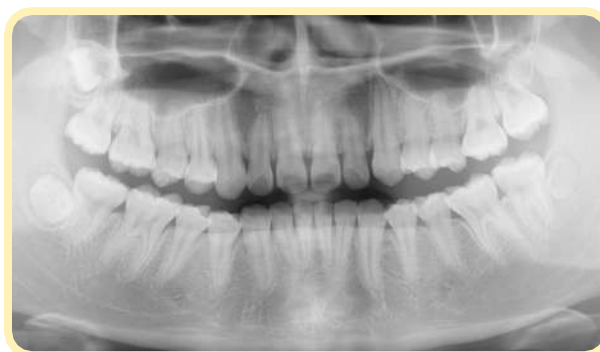


■ Fig. 1: Pre-treatment facial and intraoral photographs in C₀

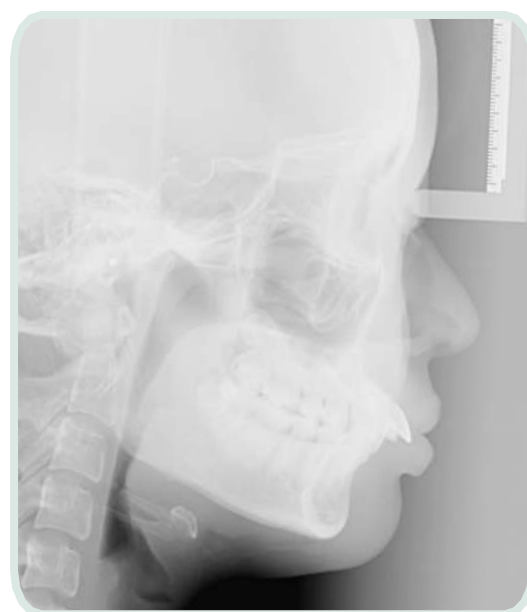proclined upper and lower incisors with a low mandibular angle, and a skeletal Class I with protruded maxilla and normal mandible (Table 1). After facial evaluation, a convex profile, as well as acceptable upper and lower lips to the E-line were noted. The intraoral examination showed an 8mm overjet and deep bite, along with dental canine Class II and molar end-on Class II relationships on the right, but Class I relationships on the left side. The maxillary dental midline was 1mm to the left of the facial midline, and the mandibular and maxillary dental midline were coincident. The TMJ radiographs (Fig. 5) showed symmetrical condylar morphology with no signs or symptoms of temporomandibular dysfunction (TMD). The American Board of Orthodontics (ABO) Discrepancy Index (DI) was 35 points,⁴ as shown in Worksheet 1 at the end of this report.



■ Fig. 2: Anterior crossbite at the anterior dentition



■ Fig. 3: Pre-treatment panoramic radiograph



■ Fig. 4: Pre-treatment cephalometric radiograph

Treatment Objectives

The treatment objectives were to:

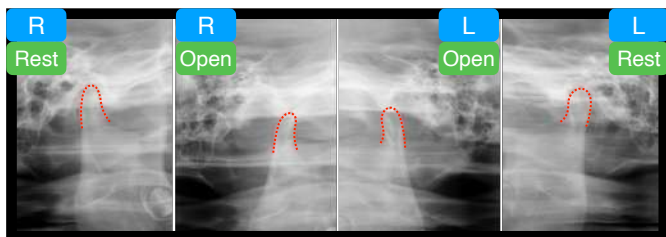
1. Correct an 8mm overjet and deepbite.
2. Achieve Class I canine and molar relationships.
3. Correct the midline discrepancy.

Treatment Plan

The main goal of this Invisalign® aligner treatment was correction of the lip protrusion and deep bite (Fig. 1). A non-extraction treatment approach was proposed: upper arch retraction of 2mm, interproximal reduction (IPR) to relieve the anterior protrusion, and Class II elastic mechanics.

CEPHALOMETRIC SUMMARY			
SKELETAL ANALYSIS			
	PRE-TX	POST-TX	DIFF.
SNA° (82°)	87°	86°	1°
SNB° (80°)	84°	83°	1°
ANB° (2°)	3°	3°	0
SN-MP° (32°)	24°	24°	0
FMA° (25°)	17°	17°	0
DENTAL ANALYSIS			
U1 TO NA mm (4mm)	11	6	5
U1 TO SN° (104°)	130°	108°	22°
L1 TO NB mm (4mm)	8	6	2
L1 TO MP° (90°)	112°	104°	8°
FACIAL ANALYSIS			
E-LINE UL (-1mm)	-1	-1	0
E-LINE LL (0mm)	2	0	2
%FH: Na-ANS-Gn (53%)	46%	52%	6%
Convexity:G-Sn-Pg' (13°)	10°	9°	1°

■ Table 1: Cephalometric summary



■ Fig. 5 :
Pre-treatment TMJ transcranial radiographs show the right (R) and left (L) sides in the rest and open positions. The mandibular condyles are outlined in red. Note the mandibular condyle heads are quite symmetrical.

OrthoBoneScrews® (OBSs) (iNewton dental, Inc., Hsinchu City, Taiwan) anchorage on the upper arch was also scheduled in order to enhance the force for upper arch retraction.

Treatment Alternatives

Lefort I orthognathic surgery with bilateral sagittal split osteotomy (BSSO) was the surgical treatment option for the patient since she had an 8mm overjet. Extraction of the upper first premolars would also be one of the treatment options to solve the overjet problem. However, space closure is sometimes challenging for Invisalign® and may cause side effects such as bowing effect. In this case, the retromolar space could be sufficient for retracting the maxillary arch to correct the overjet. The patient in the end declined both surgery and extractions, taking into consideration the higher risk of complications and psychological stress.

Treatment Progress

iTero Element® intraoral scans (Align Technology, Inc., San Jose, CA, USA) were performed to provide a 3D dataset. The ClinCheck® system (Align Technology, Inc., San Jose, CA, USA) was used to plan a reasonable biomechanical design and simulate the outcome. Oral hygiene and aligner fitness were evaluated at monthly intervals.

An initial set of 60 aligners was planned, and the aligner duration was set for 10 days each. The patient was instructed to wear the appliances at least 20 hours a day with the aid of chewing a Chewie.

The selected attachments required for optimal tooth movement were (Fig. 6):

- Optimized attachments: *UR2-UR5, UL2-UL5, LL3-LL5, as well as LR3-LR5*
- Horizontal rectangular attachments: *UR6, UR7, UL6, UL7, LL6, and LR7*

Attachments were installed during the first visit and aligners #1-4 were delivered to the patient with instructions to progress with the next aligner every 10 days. The objectives for the first set of aligners were to: 1. retract the maxillary arch, 2. achieve normal overbite, and 3. reach ideal occlusion.

In the 4th month of treatment (19th aligners), buttons were positioned on LR6, and LL6 and Class II elastics (Kangaroo, 3/16-in, 4.5-oz) were introduced bilaterally from the upper canines to the lower first molars (Fig. 7).

In the 6th month of treatment (26th aligners), IZC screws were placed (Fig. 7). During the same visit,

elastics (Chipmunk, 1/8-in, 3.5-oz) were hooked bilaterally from the upper canines to the IZC screws.

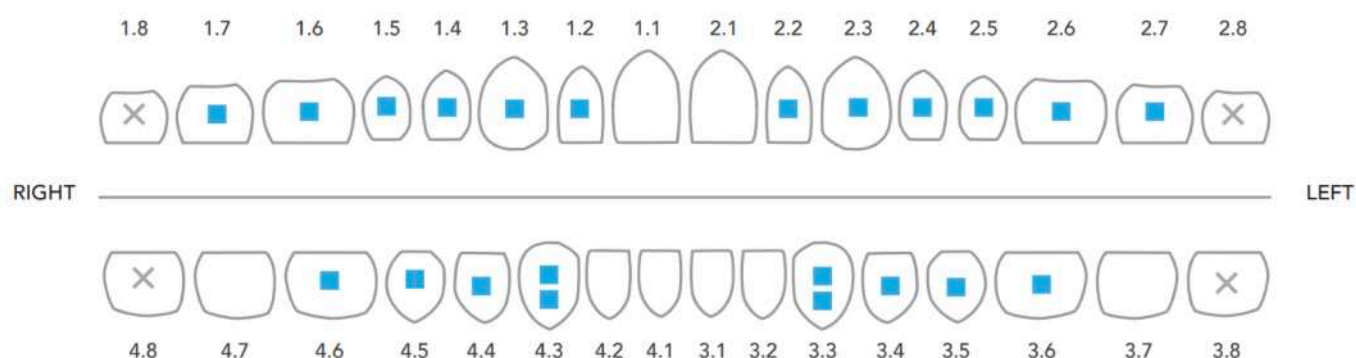
After the first set of aligners, the overjet was reduced from 8 to 6mm. Refinement was undertaken in order to continue decreasing the discrepancy between the maxilla and mandible (Fig. 8). The first refinement involving 20 additional aligners commenced with the additional attachments:

- Optimized attachments: *UL7 and LR7*

Three more refinements were processed aiming to achieve a normal overjet and overbite with ideal arch alignment (Table 2). IPR was performed between the upper incisors to provide spaces for anterior teeth retraction. Intrusion for lower anterior teeth was designed for overbite correction.

Results Achieved

The facial esthetics, gummy smile, and intermaxillary occlusion were significantly improved after 25 months of active treatment (Fig. 9). The upper and



■ Fig. 6: Initial treatment phase: Invisalign® treatment sheet; smartForce® features (optimized attachments) of the Invisalign

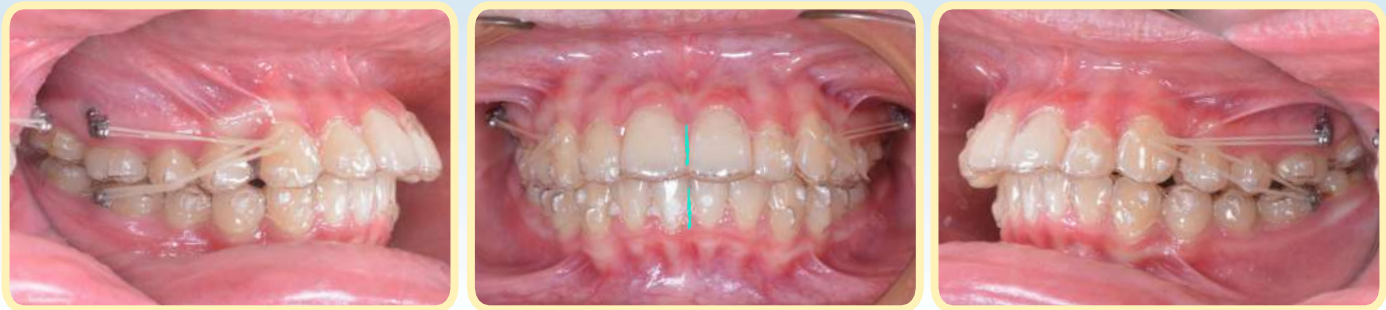

Fig. 7:
Intraoral photographs in the 9th month. In the 4th month, buttons were placed, and Class II elastics (Kangaroo, 3/16-in, 4.5-oz) were introduced bilaterally from the upper canines to the lower first molars. In the 6th month, IZC screws were placed and elastics (Chimpunk, 1/8-in, 3.5-oz) were hooked bilaterally from the upper canines to the IZC screws.

lower midlines were coincident with the facial midline. The canine relationships were corrected from Class II to Class I. The molar relationship was corrected from end-on Class II to Class I on the right side and remained Class I on the left side. The superimposed cephalometric tracings illustrated that the mandible rotated clockwise. The upper and lower lips were both retracted along with the anterior segments. The overbite and overjet were finished

within a normal range. The mandibular plane angle (SN-MP) was well-maintained (Table 1). The Cast-Radiograph Evaluation (CRE) score was 12 points, as shown in the supplementary Worksheet 2.⁵ The Pink and White dental esthetic score was 4 points (Worksheet 3).⁶ The patient was very pleased with the final result. Four sets of aligners over 25 months produced a final result that was close to the original 3D ClinCheck® projection.

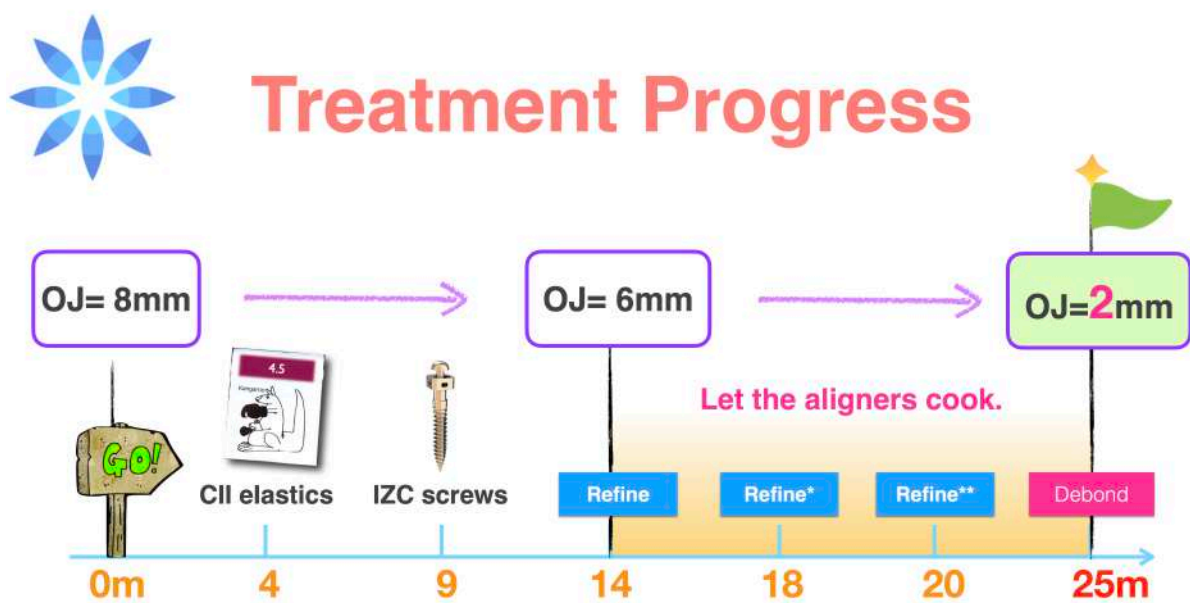
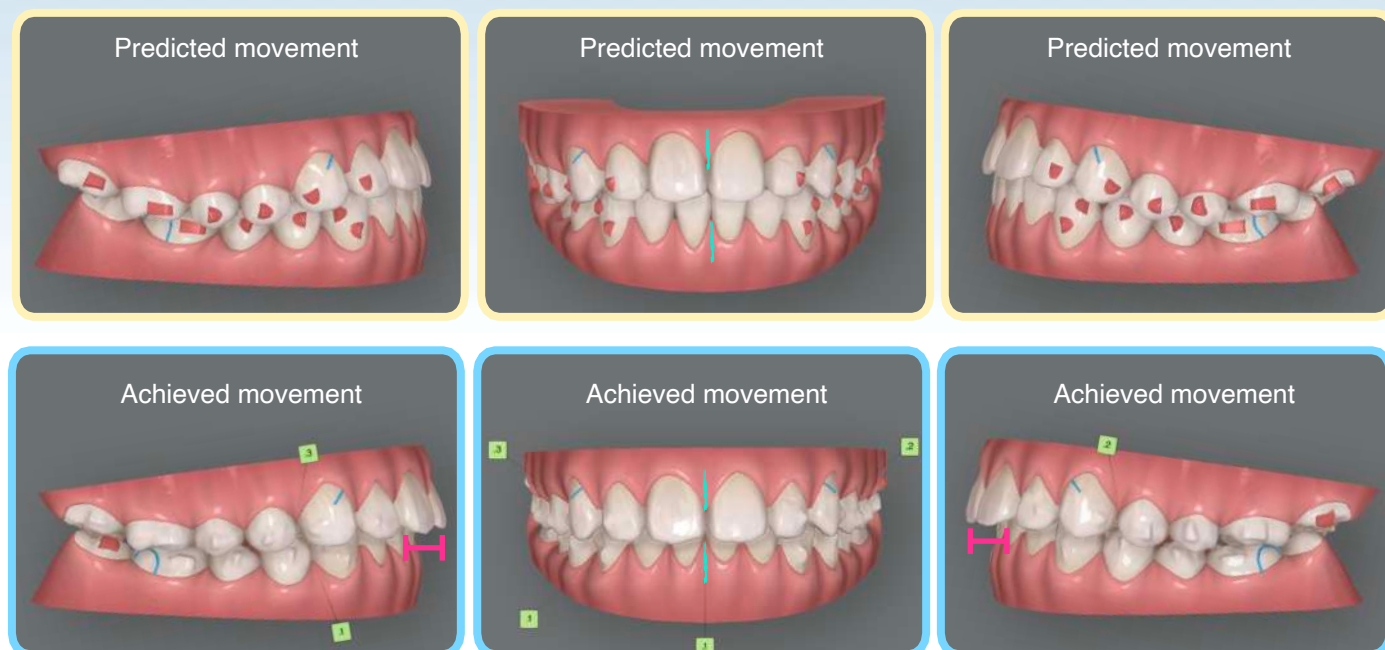

Table 2: Timeline for overjet changes, assisted appliances and refinements processed during treatment progress.



■ Fig. 8 :

Differences between predicted and achieved tooth movement (DPATM) after first set of aligners in the 14th month. It was discovered that the result did not meet the predicted movement. Overjet and overbite correction was inadequate. In the second refinement, IPR was scheduled to acquire more spaces for anterior teeth retraction.

Retention

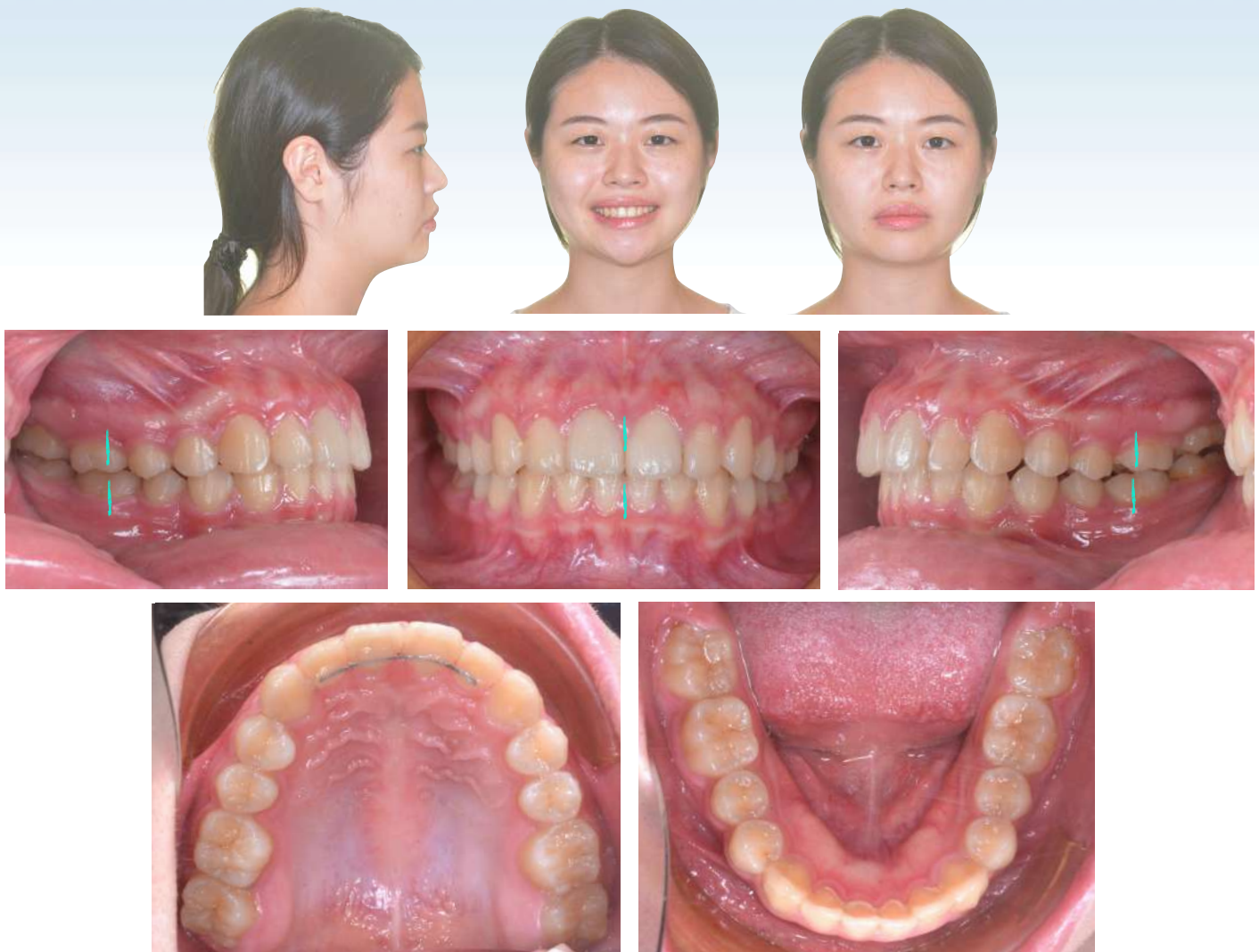After 25 months of treatment, all aligner attachments were removed. In order to prevent the relapse of anterior protrusion, a fixed retainer was placed from canine to canine on the upper arch (Fig. 9). Two ESSIX® (Dentsply Sirona, Harrisburg, PA) overlay retainers were provided to retain the leveling and alignment of the dentition. The patient was instructed to use the overlay retainers full time for the first month and only while sleeping thereafter.

Discussion

The etiology for large overjet may be the overuse of pacifiers or thumb sucking during childhood. Excessive overjets can enhance the risk of suffering traumatic

dental injuries.⁷ Furthermore, excessive overjets may entail unattractive appearances which may indirectly affect psychological development due to social pressure. Therefore, it is often recommended for patients to rectify this issue early to avoid possible dental damage or mental stress.

Extraction and orthognathic surgery were often introduced to patients with excessive overjets.⁸ However, a thorough evaluation should be considered instead of jumping into conclusions. In this case, although the patient had an 8mm overjet, her upper lip was not protruded normally. On the contrary, she had a low mandibular plane angle with a retrusive lower lip. Chang's extraction decision table (Table 3) was used to assess the necessity for extractions. For this case, three factors favoring a non-extraction treatment were the



■ Fig. 9: Posttreatment facial and intraoral photographs

low mandibular plane angle, deep bite, and the absence of crowding. In addition, the patient requested to avoid extractions and surgery, thus the feasible option was to apply extra-alveolar IZC bone screws to retract the whole maxillary arch.⁹

Aligners are suitable for retracting maxillary molars when a 2 to 3mm distalization is required to obtain a Class I relationship in selected end-to-end Class II adult patients.¹⁰ However, after the first set of aligners, there

were significant differences between predicted and achieved movements in this case (Fig. 8). The scheduled plan for upper molar distalization, which was to reduce the overjet to 1mm and correct the overbite, was not achieved. The overjet was decreased from 8 to 6mm, and the overbite was even deeper due to nearly no intrusion on the lower anterior teeth. There was only a slight inclination change on the upper incisors, which were more retroclined, and the lower incisors were more proclined instead. These

circumstances may be due to the bite-block effect, which is a common side effect in aligner treatment owing to the 0.38mm thickness that each aligner provides between posterior teeth during the whole treatment. Unanticipated intrusion of the molars would cause the incisors to appear extruded after superimposition (Fig. 10), causing difficulties especially for deep bite cases.¹¹ Lack of intrusion of the lower anterior teeth may limit the upper anterior retraction, as well as molar distalization since the bite was impinged.

Hence, with the intention of achieving an acceptable overjet and overbite, IZC screws were inserted to enhance the force of maxillary retraction.

	Ext	Non
1. Profile	Protrusive	Straight
2. Md. angle	High	Low
3. Bite	Open	Deep
4. Ant. inclination	Flaring	Flat
5. Crowding	> 7 mm	None
6. Decay/ missing	Present	?
7. P't perception	Ok	No
8. Etc...		

Table 3: Chang's Extraction Decision Table

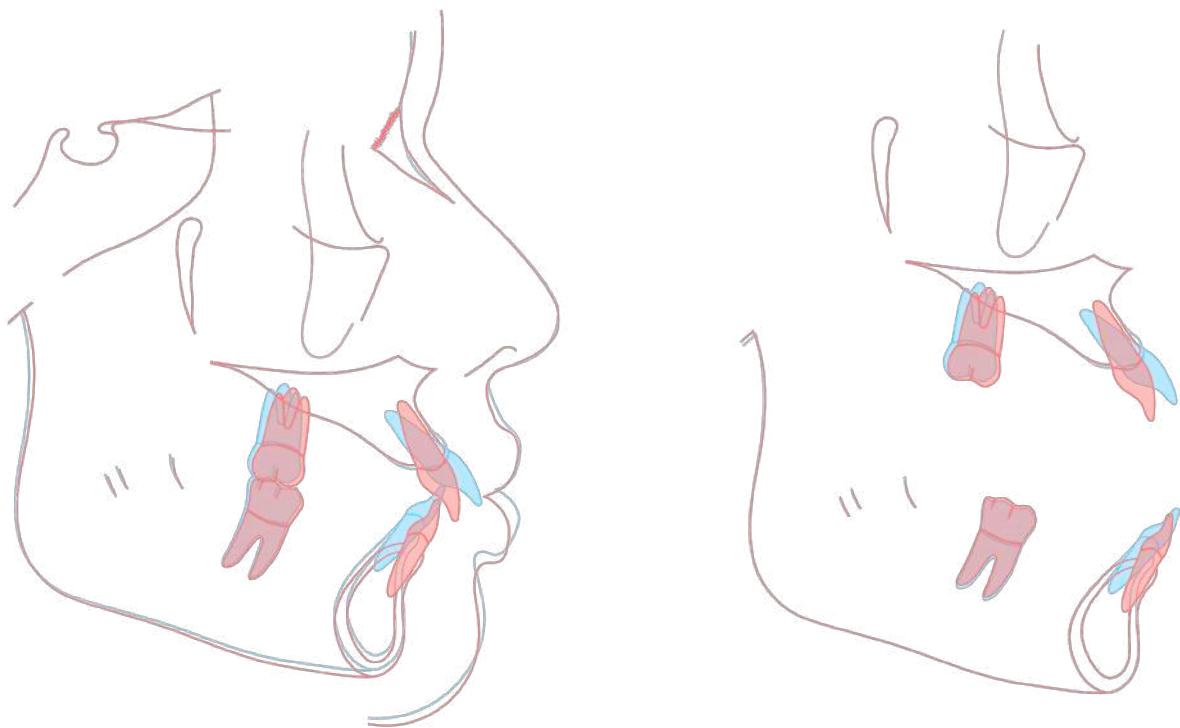


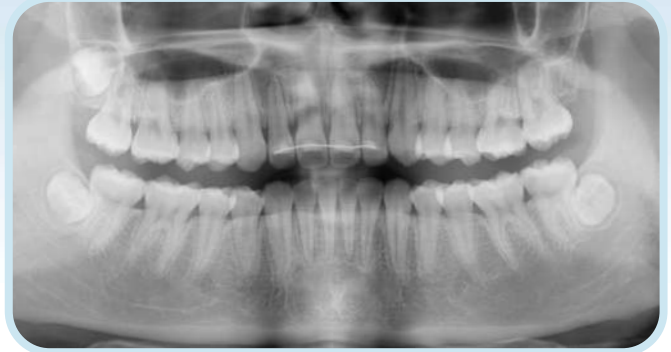
Fig.10: Superimposed cephalometric tracings (pre-treatment: blue; post-treatment: red) indicate that the molar relationship ended in Class I with mandible clockwise rotation. The superimpositions on the right document clockwise rotation of the occlusal plane associated with the retroclination of the upper incisors.

Furthermore, Class II elastics were also applied bilaterally, the buttons were placed on the lower first molars, providing an extrusion force to counteract the intrusion caused by the bite-block effect. Three refinements were also delivered to adjust the dental alignment, and eventually the patient reached a pleasant result with which she was fully satisfied.¹¹

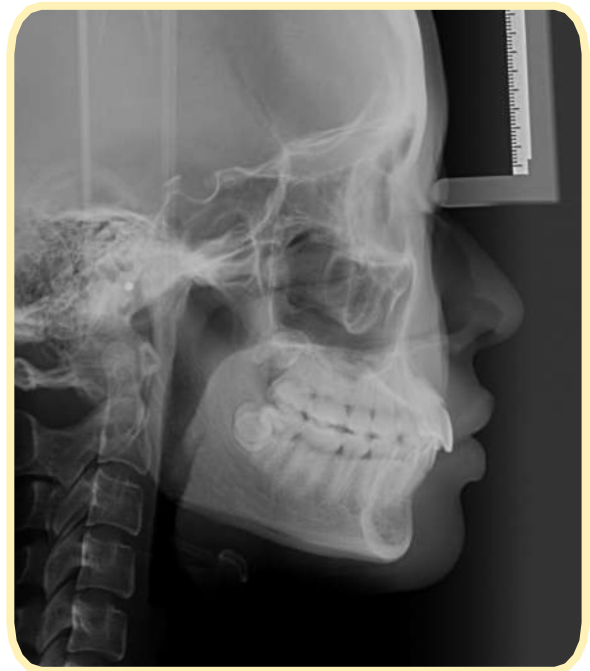In hindsight, anterior virtual bite ramps, which Align Technology recently developed, could be additionally applied to prevent deepening the overbite, which may help decrease the discrepancy between predicted and achieved results.³ In addition, overcorrection of the lower anterior teeth intrusion could be considered since the achieved amount was often inaccurate from the predicted movement.¹¹ The teeth movement sequence could also be rearranged by scheduling intrusion of the lower anterior teeth first before retracting the upper arch to avoid possible obstructions.

Conclusions

This excessive overjet and deep bite case was treated to a pleasant result in 25 months without orthognathic surgery nor extraction. With Chang's extraction decision table (Table 3), a feasible treatment plan was completed with a pleasant outcome. In retrospect, the treatment time could have been decreased by adding virtual anterior bite ramps, overcorrecting the lower anterior teeth intrusion, or rearranging the sequence of teeth movement by intruding the lower anterior teeth first and then retracting the maxillary arch. However, further research is required to minimize the treatment duration and optimize the aligner treatment design.



■ Fig. 11: Posttreatment panoramic radiograph



■ Fig. 12: Posttreatment cephalometric radiograph

References

1. Phan X, Ling PH. Clinical limitations of Invisalign. J Can Dent Assoc 2007;73:263-266.
2. Guarneri MP, Oliverio T, Silvestre I, Lombardo L, Siciliani G. Open bite treatment using clear aligners. Angle Orthod 2013;83:913-919.

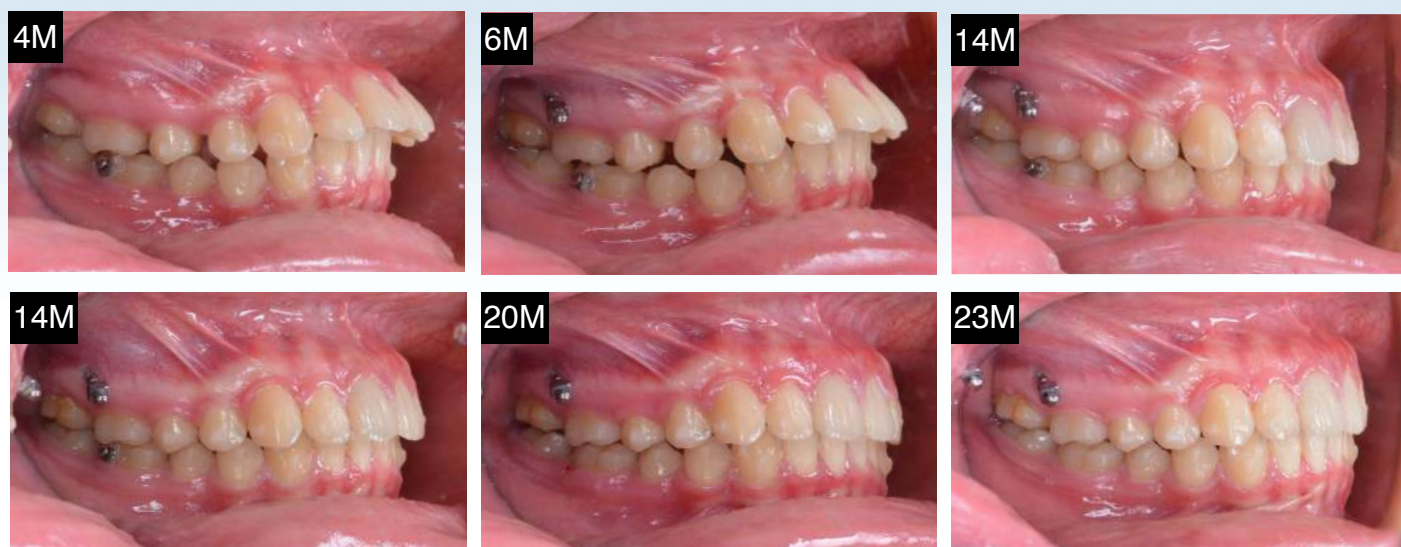

Fig. 13:
Treatment progression from the right buccal view for 23 months (M). In the 6th month (6M), IZC screws were placed with elastics (Chipmunk, 1/8-in, 3.5-oz) hooked bilaterally to retract the maxillary arch.

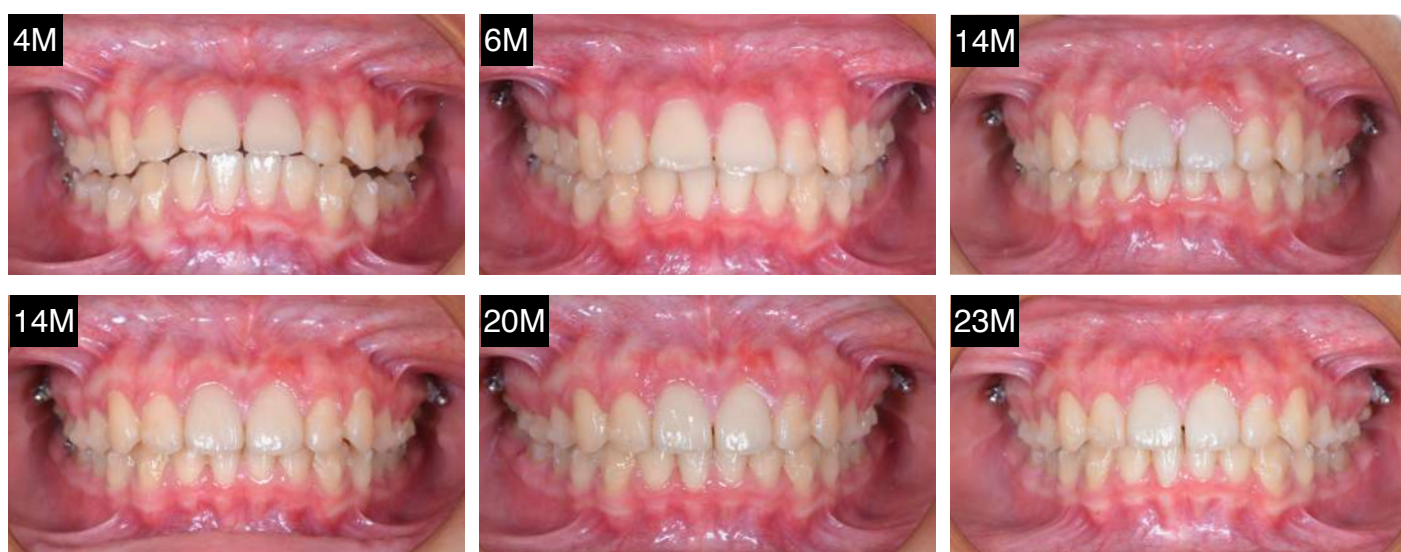
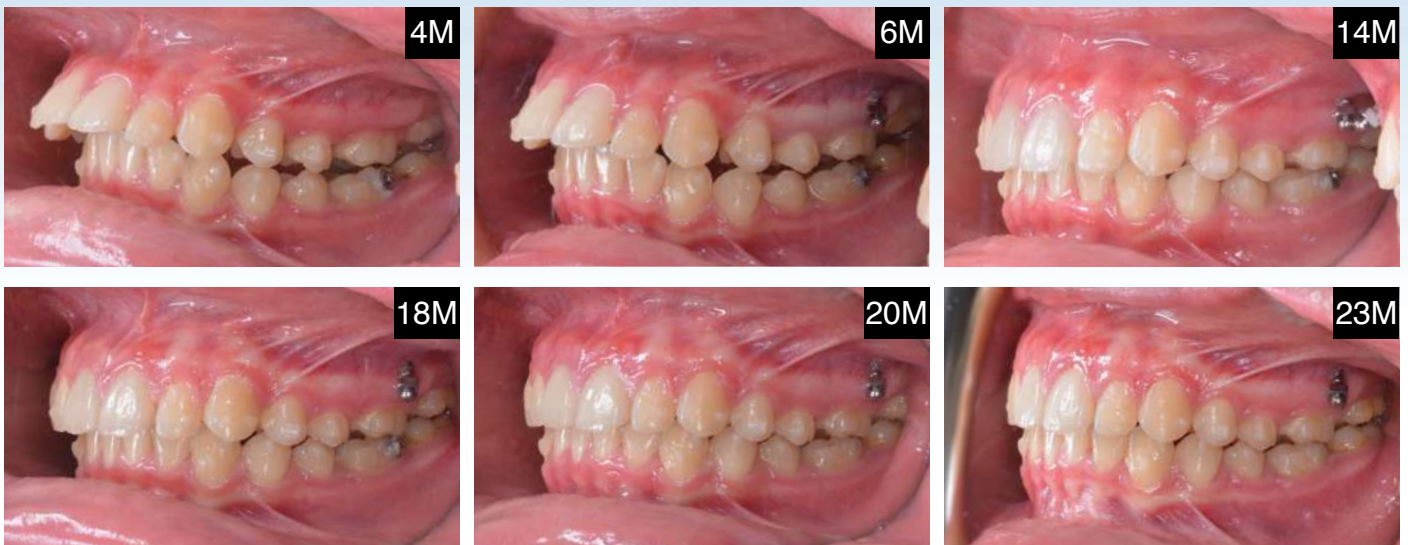

Fig. 14:
Treatment progression from the frontal view for 23 months (M). First set of aligners was finished in the 14th month (14M) but further overbite correction was required. Refinements in the following months gradually achieve ideal occlusion.



■ Fig. 15:

Treatment progression from the left buccal view for 23 months (M). The curve of Spee was progressively flattened during the treatment process.

3. Khosravi R, Cohan B, Hujoel P, Daher S, Neal M, Liu W et al. Management of overbite with the Invisalign appliance. *Am J Orthod Dentofacial Orthop* 2017;151:691-699.e692.
4. Cangialosi TJ, Riolo ML, Owens SE, Jr., Dykhouse VJ, Moffitt AH, Grubb JE et al. The ABO discrepancy index: a measure of case complexity. *Am J Orthod Dentofacial Orthop* 2004;125:270-278.
5. Casco JS, Vaden JL, Kokich VG, Damone J, James RD, Cangialosi TJ et al. Objective grading system for dental casts and panoramic radiographs. American Board of Orthodontics. *Am J Orthod Dentofacial Orthop* 1998;114:589-599.
6. Su B. IBOI Pink and White esthetic score. *Int J Orthod Implantol* 2013;28:80-85.
7. Arraj GP, Rossi-Fedele G, Doğramacı EJ. The association of overjet size and traumatic dental injuries—A systematic review and meta-analysis. *Dent Traumatol* 2019;35:217-232.
8. Proffit WR. *Contemporary Orthodontics*, 4th ed, 2007. p. 308-309.
9. Burstone CJ. Integumental contour and extension patterns. *Angle Orthod* 1959;29:93-104.
10. Ravera S, Castroflorio T, Garino E, Daher S, Cugliari G, Deregibus A. Maxillary molar distalization with aligners in adult patients: a multicenter retrospective study. *Prog Orthod* 2016;17(1):1-9.
11. Charalampakis O, Iliadi A, Ueno H, Oliver DR, Kim KB. Accuracy of clear aligners: A retrospective study of patients who needed refinement. *Am J Orthod Dentofacial Orthop* 2018;154:47-54.



Discrepancy Index Worksheet

TOTAL D.I. SCORE

35

OVREJET

0 mm. (edge-to-edge)	=	
1 - 3 mm.	=	0 pts.
3.1 - 5 mm.	=	2 pts.
5.1 - 7 mm.	=	3 pts.
7.1 - 9 mm.	=	4 pts.
> 9 mm.	=	5 pts.

Negative OJ (x-bite) 1 pt. per mm. Per tooth =

Total

=

4

OVERBITE

0 - 3 mm.	=	0 pts.
3.1 - 5 mm.	=	2 pts.
5.1 - 7 mm.	=	3 pts.
Impinging (100%)	=	5 pts.

Total

=

2

ANTERIOR OPEN BITE

0 mm. (Edge-to-edge), 1 pt. per tooth
Then 1 pt. per additional full mm. Per tooth

Total

=

0

LATERAL OPEN BITE

2 pts. per mm. Per tooth

Total

=

0

CROWDING (only one arch)

1 - 3 mm.	=	1 pt.
3.1 - 5 mm.	=	2 pts.
5.1 - 7 mm.	=	4 pts.
> 7 mm.	=	7 pts.

Total

=

0

OCCLUSION

Class I to end on	=	0 pts.
End on Class II or III	=	2 pts. per side _____ pts.
Full Class II or III	=	4 pts. per side _____ pts.
Beyond Class II or III	=	1 pt. per mm. _____ pts. additional

Total

=

2

LINGUAL POSTERIOR X-BITE

1 pt. per tooth

Total

=

0

BUCCAL POSTERIOR X-BITE

2 pts. Per tooth

Total

=

0

CEPHALOMETRICS

(See Instructions)

ANB $\geq 6^\circ$ or $\leq -2^\circ$ = 4 pts.Each degree $< -2^\circ$ _____ x 1 pt. = _____Each degree $> 6^\circ$ _____ x 1 pt. = _____

SN-MP

 $\geq 38^\circ$ = 2 pts.Each degree $> 38^\circ$ _____ x 2 pts. = _____ $\leq 26^\circ$ = 1 pt.Each degree $< 26^\circ$ 2 x 1 pt. = 21 to MP $\geq 99^\circ$

=

1 pt.

Each degree $> 99^\circ$ 21 x 1 pt. = 21

Total

=

25

OTHER

(See Instructions)

Supernumerary teeth _____ x 1 pt. = _____

Ankylosis of perm. Teeth _____ x 2 pts. = _____

Anomalous morphology _____ x 2 pts. = _____

Impaction (except 3rd molars) _____ x 2 pts. = _____Midline discrepancy (≥ 3 mm) @ 2 pts. = _____Missing teeth (except 3rd molars) _____ x 1 pt. = _____

Missing teeth, congenital _____ x 2 pts. = _____

Spacing (4 or more, per arch) _____ x 2 pts. = 2

Spacing (Mx cent. diastema ≥ 2 mm) @ 2 pts. = _____

Tooth transposition _____ x 2 pts. = _____

Skeletal asymmetry (nonsurgical tx) @ 3 pts. = _____

Addl. treatment complexities _____ x 2 pts. = _____

Identify:

Total

=

2

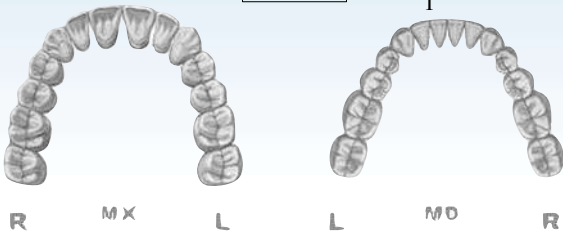
Cast-Radiograph Evaluation

Total Score:

12

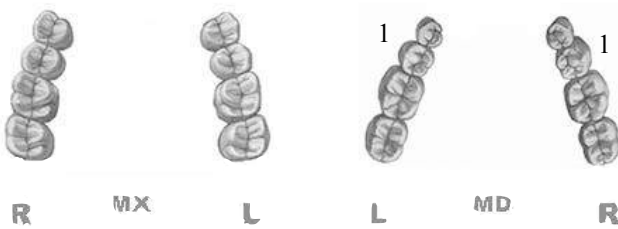
Alignment/Rotations

1



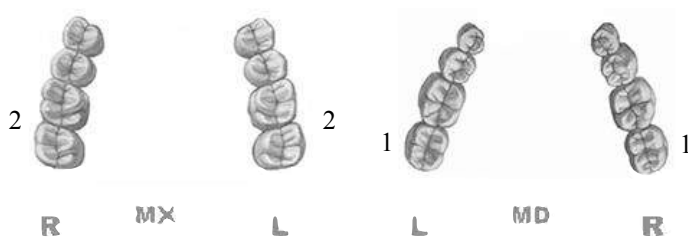
Marginal Ridges

2



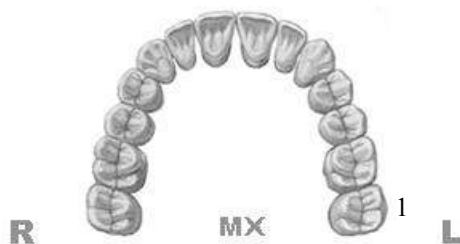Buccolingual Inclination

6



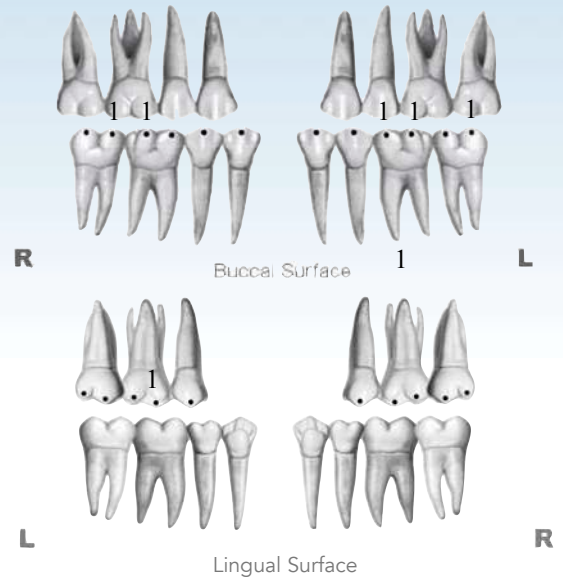
Overjet

0



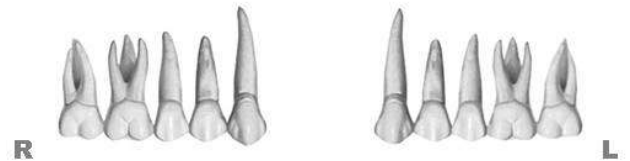Occlusal Contacts

1



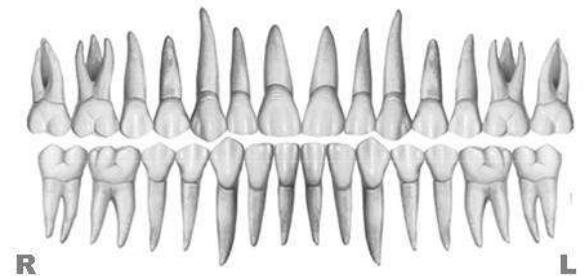
Occlusal Relationships

0



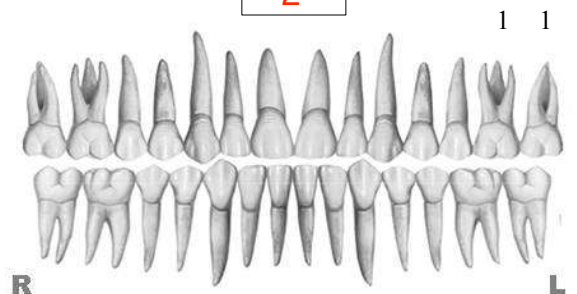
Interproximal Contacts

0



Root Angulation

2



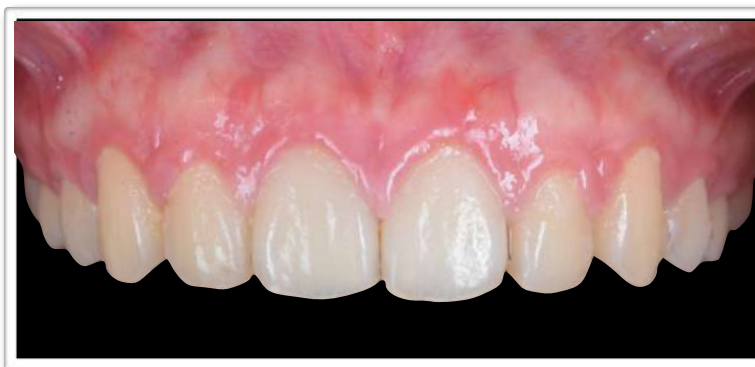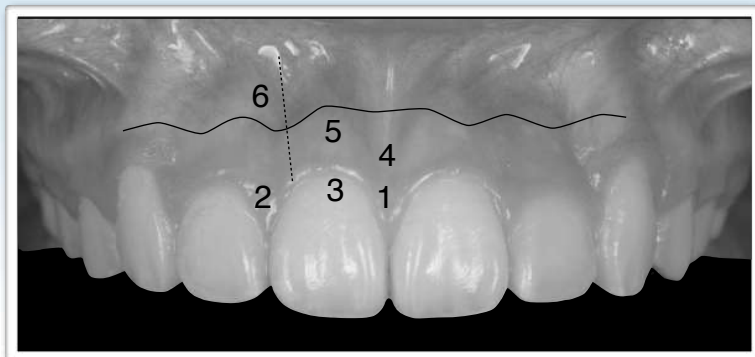
INSTRUCTIONS: Place score beside each deficient tooth and enter total score for each parameter in the white box. Mark extracted teeth with "X". Second molars should be in occlusion.

IBOI Pink & White Esthetic Score

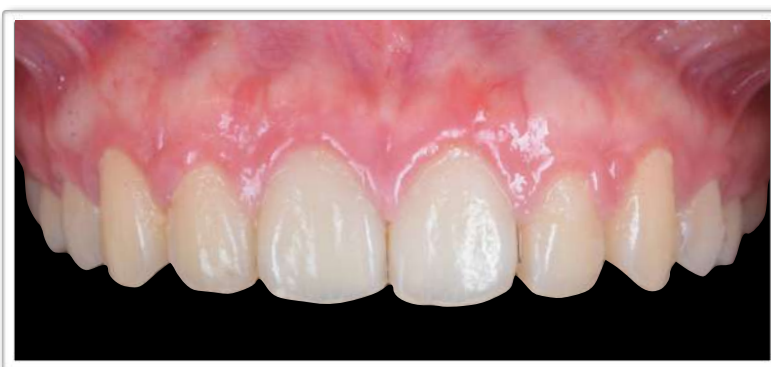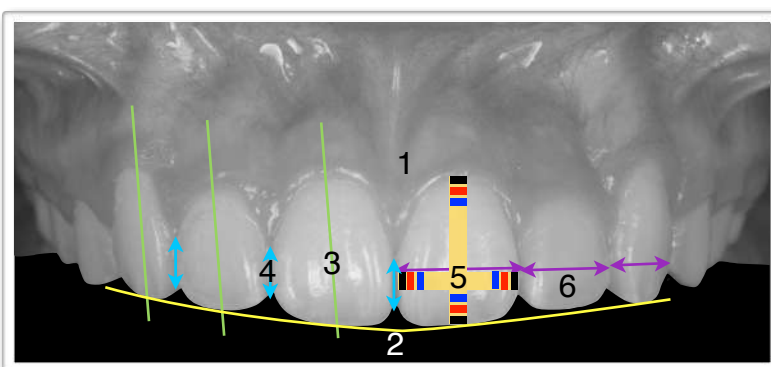
Total Score =

4

1. Pink Esthetic Score



2. White Esthetic Score (for Micro-esthetic)



Total =

1

1. M & D Papillae	0	1	2
2. Keratinized Gingiva	0	1	2
3. Curvature of Gingival Margin	0	1	2
4. Level of Gingival Margin	0	1	2
5. Root Convexity (Torque)	0	1	2
6. Scar Formation	0	1	2

1. M & D Papillae	0	1	2
2. Keratinized Gingiva	0	1	2
3. Curvature of Gingival Margin	0	1	2
4. Level of Gingival Margin	0	1	2
5. Root Convexity (Torque)	0	1	2
6. Scar Formation	0	1	2

Total =

3

1. Midline	0	1	2
2. Incisor Curve	0	1	2
3. Axial Inclination (5°, 8°, 10°)	0	1	2
4. Contact Area (50%, 40%, 30%)	0	1	2
5. Tooth Proportion	0	1	2
6. Tooth to Tooth Proportion	0	1	2

1. Midline	0	1	2
2. Incisor Curve	0	1	2
3. Axial Inclination (5°, 8°, 10°)	0	1	2
4. Contact Area (50%, 40%, 30%)	0	1	2
5. Tooth Proportion	0	1	2
6. Tooth to Tooth Proportion	0	1	2



OBS Super Set

Created by Dr. Chris Chang, OBS is made of medical grade, stainless steel and titanium, and is highly praised by doctors for its simplistic design, low failure rate and excellent quality. OBS is your must-have secret weapon for maximum, reliable anchorage.



Smooth Mushroom Head

For comfort & retention of elastic chain

4-way Rectangular Holes

For lever arm to solve impacted tooth

Double Neck Design

Easy hygiene control & extra attachment



Made in Taiwan

New **Titanium** Higher biocompatibility*

1.5 | 1.5X8mm

Stainless Steel**

2.0 | 2.0x12mm

2.7 | 2.0x14mm (with holes)

Buy a Super Set, get **OBS Clinical Guide** (eBook) for free.



* TADs made of Ti alloy have a lower failure rate compared to SS when placed in thin cortical bone. These results are consistent with a biocompatibility-related tendency for less bone resorption at the bone screw interface.
Reference: Failure Rates for SS and Ti-Alloy Incisal Anchorage Screws: Single-Center, Double Blind, Randomized Clinical Trial (J Digital Orthod 2018;52:70-79)

** The overall success rate of 93.7% indicates that both SS and TiA are clinically acceptable for IZC BSs.

Reference: Failure rates for stainless steel versus titanium alloy infrazygomatic crest bone screws: A single-center, randomized double-blind clinical trial (Angle Orthod 2019;89(1):40-46)



Join the **iAOI** the future of dentistry!

About our association-iAOI

International Association of Orthodontists and Implantologists (iAOI) is the world's first professional association dedicated specifically for orthodontists and implantologists. The Association aims to promote the collaboration between these two specialties and encourage the combined treatment of orthodontic and implant therapy in order to provide better care for our patients.

How to join iAOI?

Certified members of the Association are expected to complete the following three stages of requirements.

1. Member

Doctors can go to <http://iaoi.pro> to apply for membership to join iAOI. Registered members will have the right to purchase a workbook in preparation for the entry exam.

2. Board eligible

All registered members can take the entry exam. Members will have an exclusive right to purchase a copy of iAOI workbook containing preparation materials for the certification exam. The examinees are expected to answer 100 randomly selected questions out of the 400 ones from the iAOI workbook. Those who score 70 points or above can become board eligible.

3. Diplomate

Board eligible members are required to present three written case reports, one of which has to be deliberated verbally. Members successfully passing both written and verbal examination will then be certified as Diplomate of iAOI.

4. Ambassador

Diplomates will have the opportunity to be invited to present six ortho-implant combined cases in the iAOI annual meeting. Afterwards, they become Ambassador of iAOI and will be awarded with a special golden plaque as the highest level of recognition in appreciation for their special contribution.



For more information on benefits and requirements of iAOI members, please visit our official website: <http://iaoi.pro>.

iAOI Ambassador & Diplomat

國際矯正植牙大使與院士



Ambassadors

Dr. Kenji Ojima



Dr. 林詩詠
Joshua Lin



38 pts

Dr. Diego
Peydro Herrero



Dr. 張銘珍
Ming-Jen Chang



18 pts

Dr. 曾令怡
Linda Tseng



16 pts

New Dr. 陳俊宏
Chun-Hung Chen



19 pts

Ambassador (大使):

★ One who has published 9+ case reports in JDO.

◆ Keynote speakers for iAOI annual workshops

▲ Case report(s) published at least once in referral journals.

● Referral journals/Research paper - 3 points
ABO case report - 2 points
Clinical tip - 1 point

Diplomates

Dr. 徐玉玲
Lynn Hsu



29 pts

Dr. 李雙安
Angle Lee



26 pts

Dr. 蘇筌璋
Bill Su



24 pts

Dr. 葉信吟
Hsin-Yin Yeh



20 pts

Dr. 徐重興
Eric Hsu



20 pts

Dr. 黃育新
Yu-Hsin Huang



20 pts

Dr. 黃祈
Richie Huang



16 pts

Dr. 邱上珍
Grace Chiu



13 pts

Dr. 黃瓊嬋
Sabrina Huang



13 pts

Dr. 鄭惠文
Joy Cheng



13 pts

Dr. 曾淑萍
Shu-Ping Tseng



12 pts

Dr. 林曉鈴
Sheau-Ling Lin



10 pts

Dr. 張倩瑜
Charlene Chang



10 pts

Dr. 林佳宏
Alex Lin



10 pts

Dr. 林彥君
Lexie Lin



8 pts

Dr. 林森田
Chris Lin



7 pts

Dr. 黃登楷
Kevin Huang



6 pts

Dr. 張馨文
Sara Chang




6 pts

Dr. 李名振
Major Lee



6 pts

Dr. 陳惠華
Judy Chen



6 pts

Dr. 魏明偉
Ming-Wei Wei



6 pts

Dr. 黃荷薰
Ashley Huang



6 pts

Dr. 李彥峰
Yen-Feng Lee



6 pts

Dr. 張銘津
Ariel Chang



5 pts

Dr. 彭緯綸
Wei-Lun Peng



4 pts

Dr. 呂詩薇
Julie Lu



4 pts

一路暢通

的「ENDO」
治療組合

Kerr™
ENDODONTICS

優惠期限自 2022/04/01~2022/12/25 止

Endo Hand Instrument

K - Type

#06-#40 NT\$420/盒

#45-#80 NT\$470/盒

Triple-Flex

#08-#40 NT\$420/盒

#45-#80 NT\$470/盒



買 3 送 1

修型

FILLING

充填

M4 Safety Handpiece

NT\$36,000/支

限量20支

買 1 送 1



M4教學影片



廖婉瑩 醫師
愛用推薦

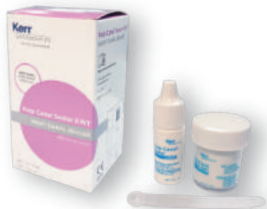- Available for E-style motors or TC Cordless Handpieces.
- Compatible with most hand files
- Mimics watch-winding motion
- Greatly reduces fatigue.



EWT Pulp Canal Sealer

Features a work time of greater than 6 hours on the pad

NT\$5,400/盒



馬來膠針

Autofit

NT\$830/盒

買 3 送 1

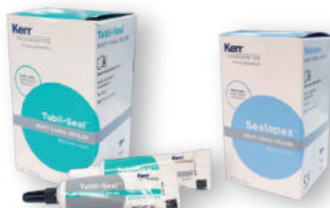

Tubli-Seal

NT\$2,200/盒

Sealapex

NT\$2,200/盒



買 3 送 1

馬來膠熱融機

Touch'n Heat

特價 NT\$28,700/台



Buchanan Hand Plugger

size #1、#2 任選

NT\$3,680/支



— 前衛醫器總經銷字號022553號 Manufactured by MVN0091000 META BIOMED VINH ONE MEMBER LIMITED LIABILITY COMPANY (add: LOT N-18, NO. 4 ROAD, EXTENDED LONG HAU INDUSTRIAL PARK, HAMLET 3, LONG HAU COMMUNE CAN GIUOC DISTRICT LONG AN, VIETNAM 8100) for MUS1030100 KERR CORPORATION (add: 1717 WEST COLLINS AVENUE ORANGE, CA 92667, USA) — 前衛醫器總經銷字號022558號 Manufactured by MM00021000 ORMEC S. DE R.L. DE C.V. (add: CALLE 21, NO. 1103, AMPLACION CIUDAD IND. YUCATAN UMAN, MEXICO 97390) for MUS1030100 KERR CORPORATION — 前衛醫器總經銷字號022592號 Manufactured by MUS5858000 AMERICAN EAGLE INSTRUMENTS, LLC (add: 6575 BUTLER CREEK ROAD, MISSOULA, MT 59808, USA) for MUS1030100 KERR CORPORATION — 前衛醫器總經銷字號032240-032241-032340號 Manufactured by MT00278100 Kerr Italia SRL (add: Via Passanti, 332, Scalfati, Salerno I-84018, Italy) for MU54540000 Kerr Corporation (add: 1717 W Collins Ave, ORANGE, CA 92667, USA) — 前衛醫器總經銷字號030982號 Manufactured by MM002040100 SDS de Mexico S. de R.L. de C.V. (add: CIRCUITO SUR NUM. 31, PARQUE IND. NELSON MEXICALI, B.C.P., MEXICO 21395)

YONG CHIEH 湧傑 客服專線：北區 (02)2778-8315 · 中區 (04)2305-8915 · 南區 (07)226-0030

*北市衛器販(松)字第MD6201015238號 *消費者使用前應詳閱醫療器材說明書 *本公司保留更改及終止活動辦法與條款之權利 *本優惠專案僅適用於牙醫診所

*本文宣品僅供牙科診所及醫師參考，禁止張貼或擺置於公眾可瀏覽及取閱之處 *本文宣品僅供牙科診所及醫師參考，未經本公司同意禁止轉載

湧傑官方社群



修型 SHAPING

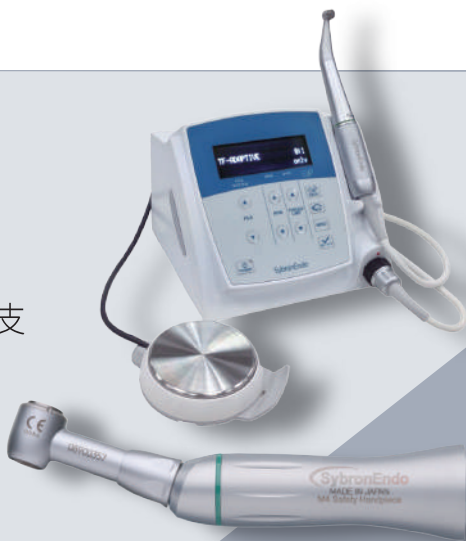TFA 課程機方案

Elements Motor (課程機) x1台

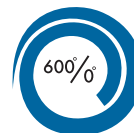M4 Safety Handpiece (課程機) x1支

特價 **NT\$59,900/組**

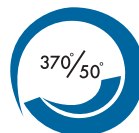
限量15組



ADAPTIVE MOTION TECHNOLOGY



Rotary: 600° clockwise and 0° counter-clockwise file motion when no load is applied.



Reciprocation: 370° clockwise and up to 50° counter-clockwise file motion when load is applied.

課程機保固期：自銷售日起六個月

充填 FILLING

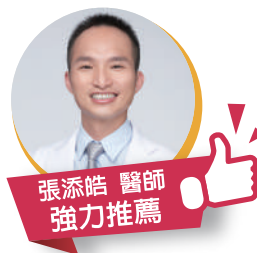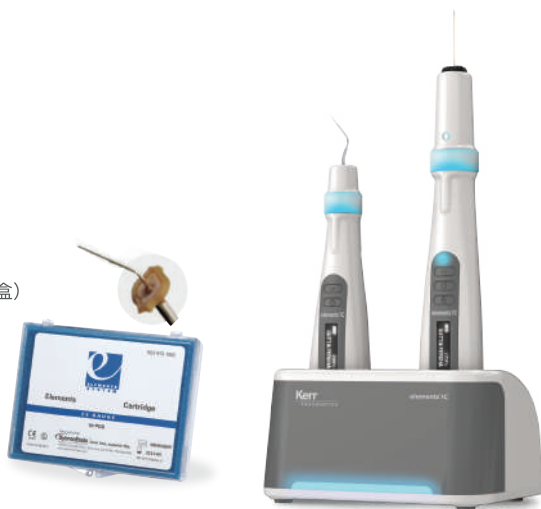Elements IC x1台

GP Cartridge x6盒 (10個/盒)

特價 **NT\$95,000/組**



專業教學影片



DENTAL ADVISOR

榮獲 2020 Dental Advisor
Continuous Wave Obturation

TOP AWARD WINNER

根管治療銼針

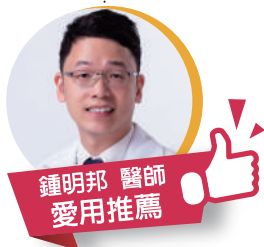TF Adaptive Small 23mm / 27mm
TF Adaptive Med / Lrg 23mm / 27mm
K3XF #15 - #40



TFA 或 K3XF 鎳鈦彈性旋轉器械 x20盒
TFA 綜合包 或 K3XF (號碼任選)

再贈 **HuFriedyGroup DG16 EXDG16 x1支**

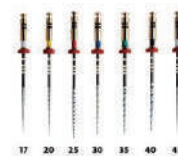特價 **NT\$26,000/組**



EDGEENDO®

EDGETAPER PLATINUM™

EDGEFILE®



Edge Endo 鎳鈦彈性旋轉器械
EdgeTaper PLATINUM 或 EdgeFile X7

特價 **NT\$11,000/10盒**

Class II Malocclusion with Severe Crowding and a Protrusive Profile

Abstract

A 25-year-old female presented with almost end-to-end Class II buccal segments, severe anterior crowding bilaterally in the right lateral incisor and canine areas, and a protrusive profile. The Discrepancy Index (DI) was 19. All four first premolars were extracted, canines were moved distally to resolve crowding, and the anterior segments were retracted to correct lip protrusion. After initial alignment and leveling, the residual space was closed with elastometric chains, and Class II elastics were applied to correct the sagittal discrepancy. At progress evaluation, it was noted that the crowding, protrusion, and flaring of upper and lower incisors were corrected, but the buccal segments were still Class II, the bite had deepened, and a 1-2mm midline deviation was evident. Extra-alveolar miniscrews were inserted to complete the correction. After a total of 36 months of active treatment, an optimal result was achieved. The final Cast-Radiograph Evaluation (CRE) score was 24, and the Pink and White dental esthetic score was 2. (*J Digital Orthod* 2022;66:48-75)

Key word:

Protrusive profile, four bicuspid extraction, miniscrew, Angle Class II malocclusion, asymmetric crowding

History and Etiology

A 25-year-old female presented for orthodontic consultation with a chief complaint that her front teeth were crooked (Figs. 1-3). There was no contributory medical or dental history. The patient had no known harmful habits which might contribute to the malocclusion. The relatively narrow arches and crowding pattern suggest a primarily environmental etiology associated with a history of inadequate masticatory loading. The patient was treated to a very good result (Figs. 4-6). The pre-treatment and posttreatment cephalometric and panoramic radiographs are shown in Figs. 7 and 8, respectively. Superimposed cephalometric tracings document the dentofacial changes (Fig. 9). The correction of the malocclusion was facilitated by assessing progress records at 11 and 24 months of treatment. Including an

interruption in treatment when the appliances were removed for wedding photographs, the total treatment time was 36 months.

Diagnosis

Skeletal:

- Class II with slightly retrusive mandible (SNA, 81°; SNB, 77.5°; ANB, 3.5°)
- Normal mandibular plane angle (SN-MP, 32°)

Dental:

- Angle Classification: *bilateral Class II molar relationship*
- Incisal relationships: *overjet 6mm, overbite ~5mm, increased axial inclination of all incisors (Fig. 10)*

Shih-Wei Lu

Lecturer, Beethoven Orthodontic Center (Left)

Chris H. Chang,

Founder, Beethoven Orthodontic Center

Publisher, Journal of Digital Orthodontics (Center)

W. Eugene Roberts,

Editor-in-Chief, Journal of Digital Orthodontics (Right)

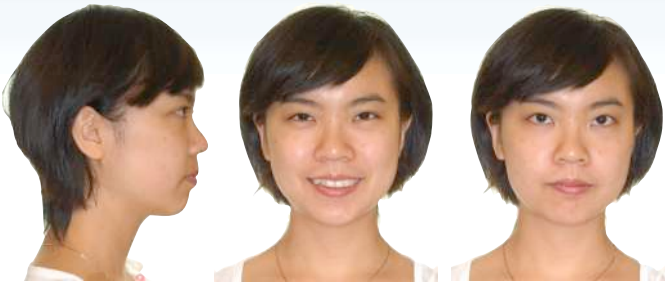

Fig. 1: Pre-treatment facial photographs



Fig. 4: Posttreatment facial photographs

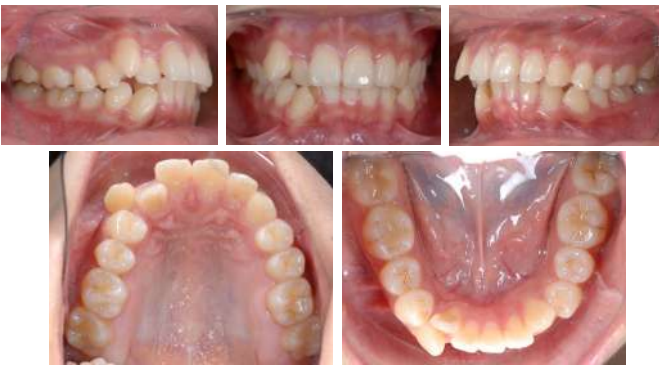

Fig. 2: Pre-treatment intra-oral photographs

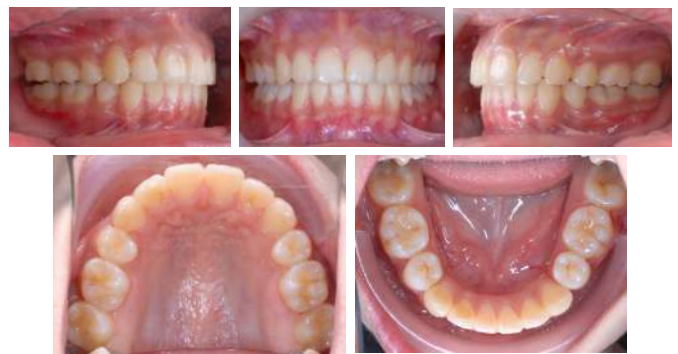

Fig. 5: Posttreatment intra-oral photographs

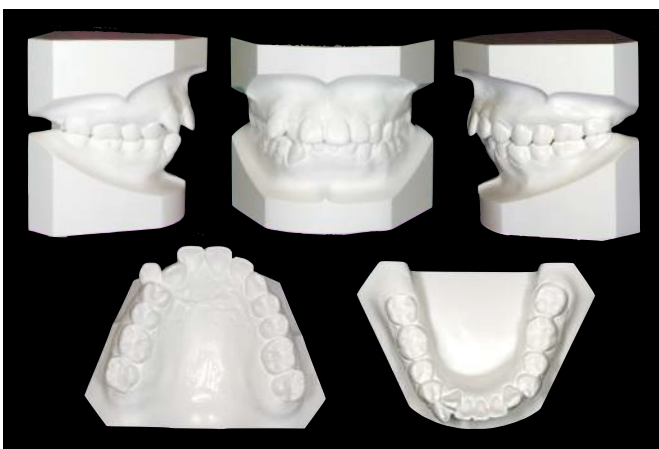

Fig. 3: Pre-treatment study models (casts)

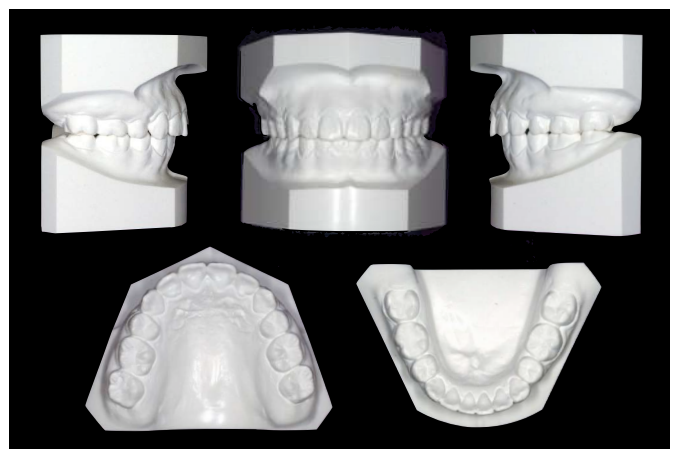

Fig. 6: Posttreatment study models (casts)

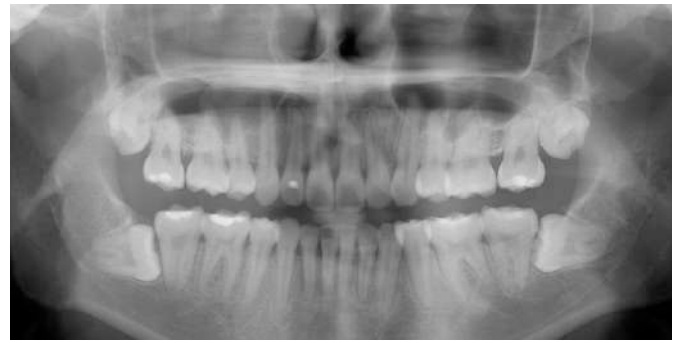
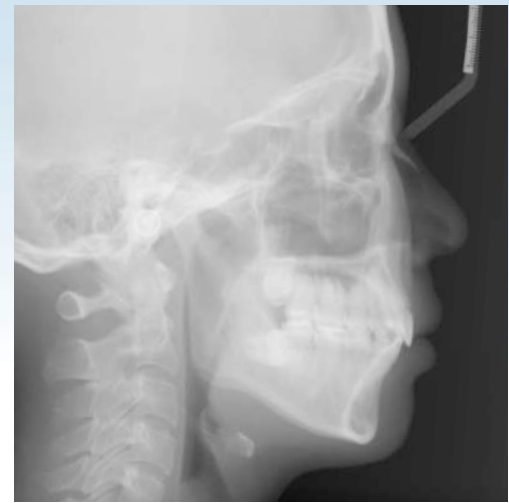
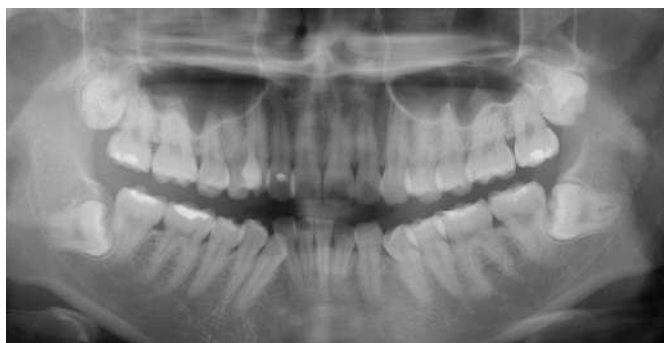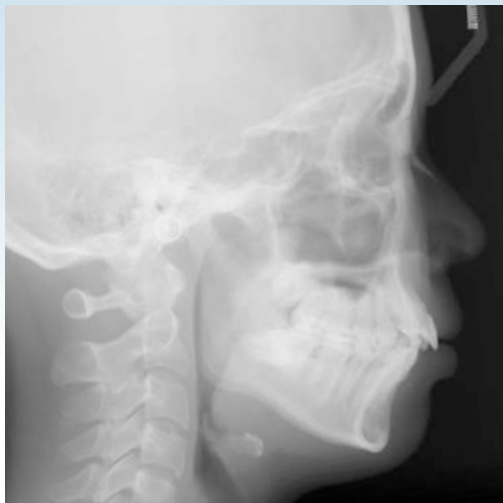Fig. 7:
Pre-treatment panoramic and lateral cephalometric radiographs

- Tooth Size Arch Length Discrepancy: *Maxillary arch 8mm, mandibular arch 10mm*
- UR and LR block-out canines
- LR central incisal edge fractured (Fig. 11)

Radiographic/Panoramic:

- Enlarged maxillary sinuses and low sinus floor (Fig. 7)

Facial:

- Protrusive profile
- Convex due to a retrusive chin

The ABO Discrepancy Index (DI) was 19 as shown in the subsequent worksheet.

Fig. 8:
Posttreatment panoramic and lateral cephalometric radiographs

Specific Treatment Objectives

Maxilla:

- A-P: *Maintain.*
- Vertical: *Maintain.*
- Transverse: *Maintain.*

Mandible:

- A-P: *Maintain.*
- Vertical: *Maintain.*
- Transverse: *Maintain.*

Maxillary Dentition:

- A-P: *Retract incisors.*

- Vertical: *Maintain*.
- Inter-Molar Width: *Maintain*.
- Inter-Canine Width: *Decrease*.
- Buccolingual Inclination: *Maintain*.

Mandibular Dentition:

- A-P: *Maintain*.
- Vertical: *Maintain*.
- Inter-Molar Width: *Maintain*.
- Inter-Canine Width: *Maintain*.
- Buccolingual Inclination: *Maintain*.

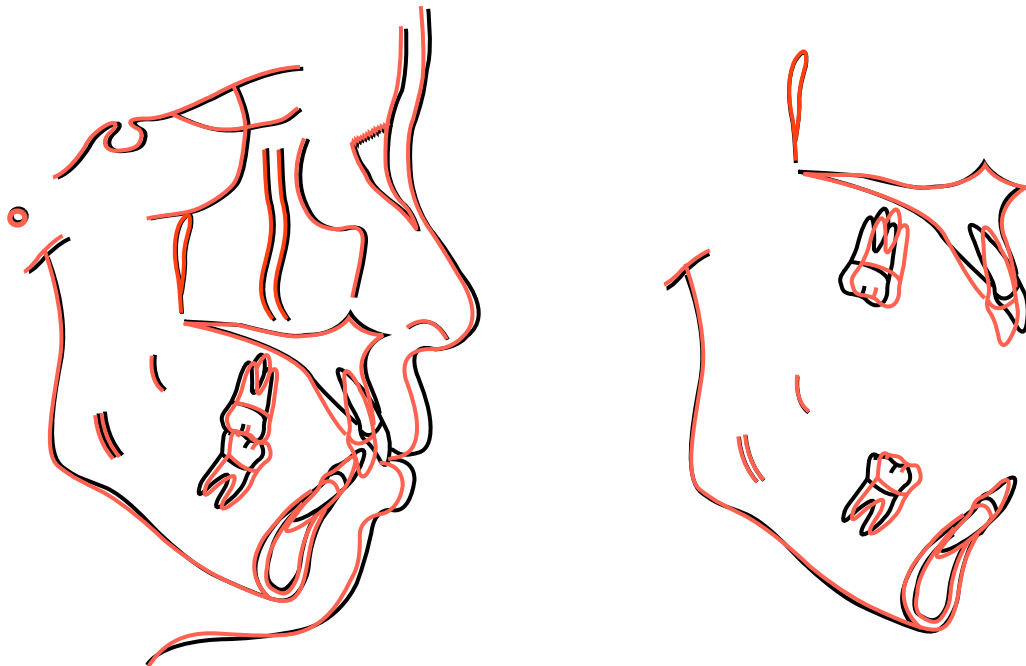
Facial Esthetics: *Correct protrusive lips.*

Treatment Plan

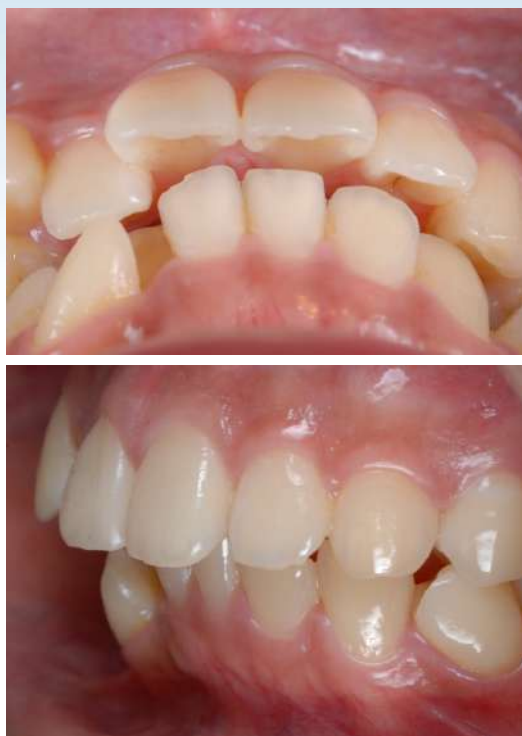Extract four first premolars, and utilize a full fixed orthodontic appliance to align, level, and close

CEPHALOMETRIC SUMMARY			
SKELETAL ANALYSIS			
	PRE-TX	POST-TX	DIFF.
SNA° (82°)	90°	90°	0°
SNB° (80°)	86°	86°	0°
ANB° (2°)	4°	4°	0°
SN-MP° (32°)	26°	26°	0°
FMA° (27°)	19°	19°	0°
DENTAL ANALYSIS			
U1 TO NA mm (4mm)	7	5	2
U1 TO SN° (104°)	120°	108°	12°
L1 TO NB mm (4mm)	8	6	2
L1 TO MP° (90°)	100°	95°	5°
FACIAL ANALYSIS			
E-LINE UL (-1mm)	2	1	1
E-LINE LL (0 mm)	3	2	1
%FH: Na-ANS-Gn (56%)	55%	56%	1%
Convexity: G-Sn-Pg (13°)	5°	4°	1°

■ **Table 1:** Cephalometric summary

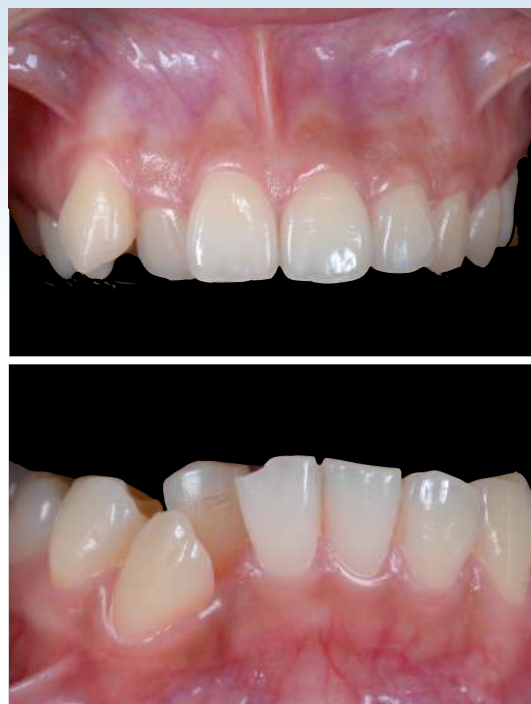

■ **Fig. 9:** Cephalometric tracings superimposed on stable skeletal landmarks in the anterior cranial base, maxilla, and mandible. (Pre-treatment: black; posttreatment: red)



■ **Fig. 10:**

Pre-treatment photographs document a 6mm overjet and ~5mm overbite, associated with proclined lower incisors (IMPA=104°).



■ **Fig. 11:**

UR and LR block-out canines; LR central incisor with a distal incisal edge fracture

spaces in both arches. Use anterior bite turbos to control the deep bite and early light short elastics (2oz) to correct the Class II buccal segments. Miniscrews (2x12-mm, OrthoBoneScrew®, iNewton dental, Inc., Hsinchu City, Taiwan) in the infrazygomatic crests (IZC) may be needed to retract upper dentition and improve the lip profile. The final occlusion is to be detailed with bracket repositioning, archwire adjustment, and intermaxillary elastics, as needed. When the fixed appliances are removed, the corrected dentition will be retained with upper and lower clear overlay retainers.

Appliances and Treatment Progress

Before the treatment, the patient was referred to a general dentist to extract the maxillary and

mandibular first premolars. A 0.022" slot Damon Q® bracket system (Ormco, Glendora, CA) was used, with high torque brackets on the upper incisors (Fig. 12). The initial upper archwire was 0.014" CuNiTi. After one month of initial alignment and leveling in the maxillary arch, the mandibular arch was bonded with standard torque brackets and fitted with a 0.014" CuNiTi archwire. An open coil spring was placed between mandibular right central incisor and canine to open the space for the lingually displaced right lateral incisor. An elastometric chain was used to retract the lower right canine (Fig. 13). The patient was instructed to wear Class II elastics (Parrot 5/16, 2oz) bilaterally full time, from the upper canine to the lower first molar to correct the sagittal discrepancy.

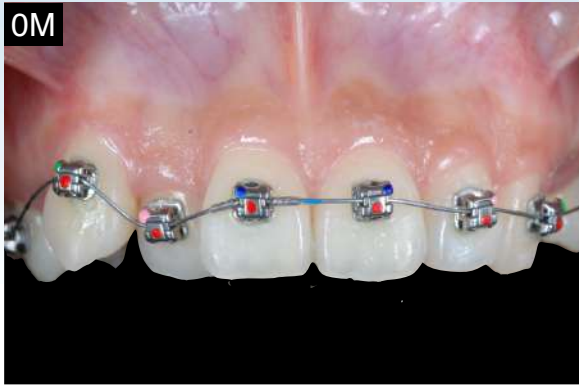

Fig. 12:
High torque brackets were bonded on the upper anterior segment.

In the 3rd month (3M), a 0.016" CuNiTi archwire was placed in the upper arch. One month later, the mandibular right lateral incisor bracket was bonded, and the archwire was engaged (Fig. 14). Five months into treatment, a rectangular 0.014x0.025" CuNiTi wire was placed in the upper arch. One month later, the upper archwire was replaced by 0.017x0.025" low friction TMA, and the anterior segment was ligated with a 0.012" stainless steel (SS) ligature in a figure-eight tie pattern. The lower archwire was fitted with 0.014x0.025" CuNiTi. Class II elastics (Fox 1/4, 3.5oz) were worn bilaterally from the upper canines to the lower first molars.

Eight months after the initiation of treatment (8M), a 0.019x0.025" SS archwire was used on the upper arch, and a 0.017x0.025" low friction TMA was placed in the lower arch. The UR and LR blocked-out canines were both corrected (Fig. 15). One month later (9M), the lower archwire was replaced with a 0.016x0.025" SS. Elastometric chains were attached from the canines to the first molars to close the residual extraction spaces in both arches. L-type elastics (Bear 1/4, 4.5oz.) were applied from the upper canines to lower molars bilaterally. After

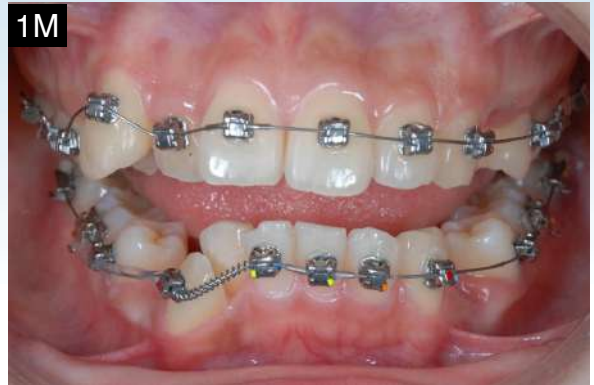

Fig. 13:
An open coil spring was placed between LR1 and LR3 to open the space for the lingually displaced LR2. An elastometric chain was attached from LR3 to LR6 to retract the canine.

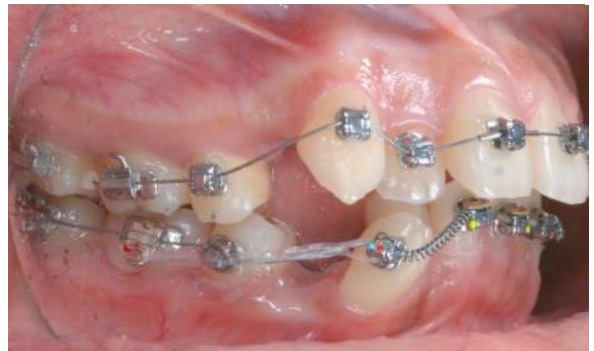
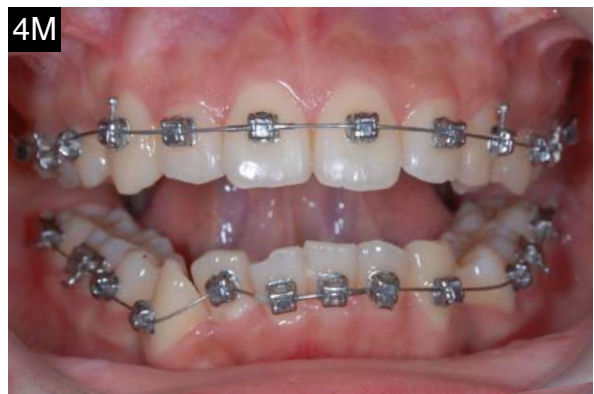
Fig. 14:
After space opening, a bracket was bonded on LR2 and the archwire was engaged.



11 months of active treatment, interim records were collected to evaluate the treatment progress and to plan the future treatment (Figs. 16-18).

Interim Treatment Progress-1

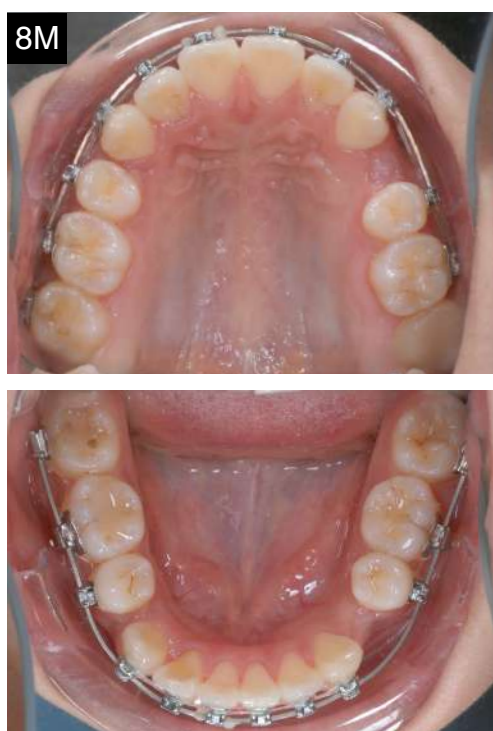Midcourse Corrections after 11 Months

Crowding, protrusion, and flaring of upper and lower incisors are improved. An interim American Board of Orthodontics (ABO) Cast-Radiograph Evaluation (CRE) score of 31 revealed good progress (figs. 19-24), but also identified further treatment needs:

1. Detailed bending to correct rotations (Fig. 19).
2. Bracket repositioning to improve marginal ridges (Fig. 20).
3. Bond lingual buttons on LL5 and LL6 and apply cross elastics to correct lingual tipping (Fig. 21).
4. Use vertical elastics on R7s.
5. Correct the overjet (Fig. 22) and close residual extraction spaces (Fig. 24).
6. Coordinate arches to improve occlusal relationships (Fig. 23).
7. Use miniscrews to correct the Class II buccal segments and midline discrepancy.

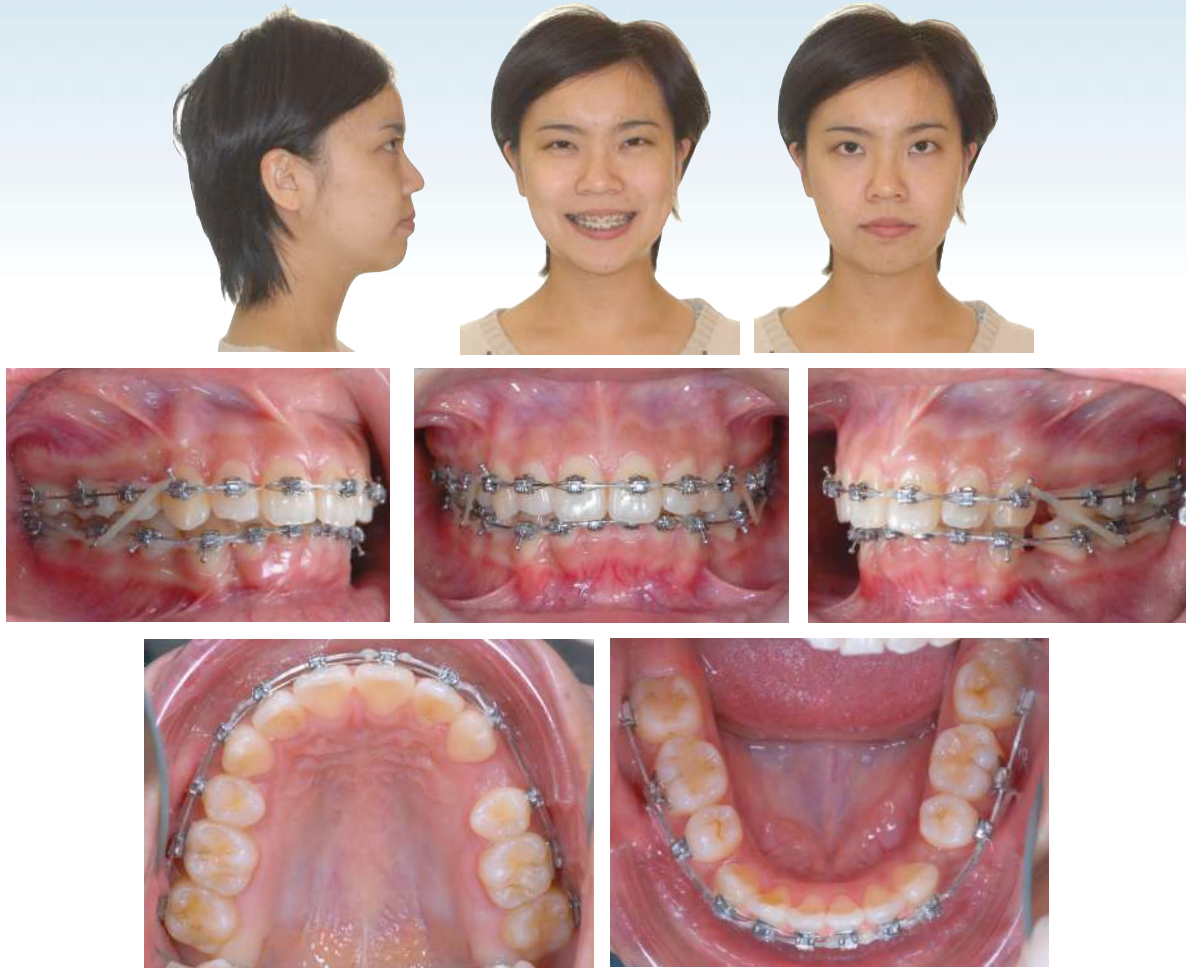In the 15th month of treatment, the anterior overbite was deeper due to space closing mechanics. Anterior bite turbo were used on the palatal side of upper central incisors (Fig. 25). Elastometric chains were attached from the canines to the first molars to close the residual extraction spaces in both arches (Fig. 26).

After 17 months of active treatment (17M), extra-alveolar miniscrews were inserted in the right IZC and buccal shelf (BS) of the left mandibular first molar to correct the midline deviation. Three months later (20M), all extraction spaces were closed (Fig. 27). In the 21st month of treatment (21M), a panoramic radiograph was taken to evaluate axial inclinations for all teeth. Bracket repositioning of LL3, LR5, and LR6 were performed as indicated (Fig. 28). LR1 was restored to normal dental morphology. Additionally, vertical elastics (Chipmunk 1/8, 3.5oz.) were used on the R7s to

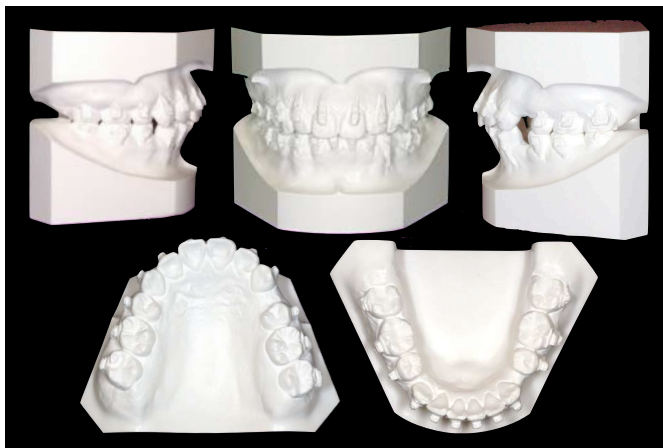

■ **Fig. 15:**

The upper archwire was 0.019x0.025" SS and the lower archwire was 0.017x0.025" low friction TMA.



■ **Fig. 16:** Interim treatment facial and intraoral photographs (11M)



■ **Fig. 17:** Interim treatment (11M) study models (casts)

improve buccolingual inclination. L-type elastics (Fox 1/4, 3.5oz.) were applied from the upper canines to lower molars on the left side to correct the deviated midline.

Two months later (23M), the lower archwire was expanded to improve arch coordination. Lingual buttons were bonded on lower right 2nd premolar, and cross elastics (Chipmunk 1/8, 3.5oz.) were used to correct lingual tipping (Fig. 29). In the 24th month of treatment (24M), interim-treatment records were collected to evaluate the treatment

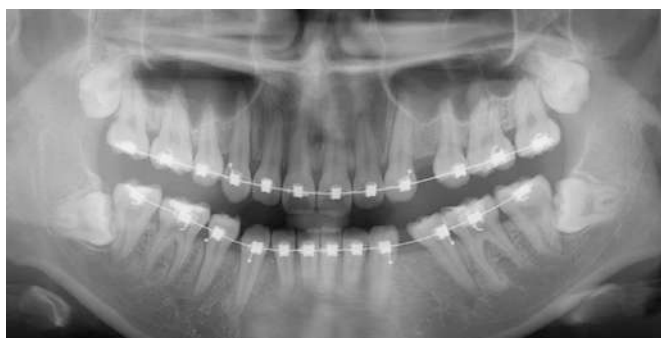
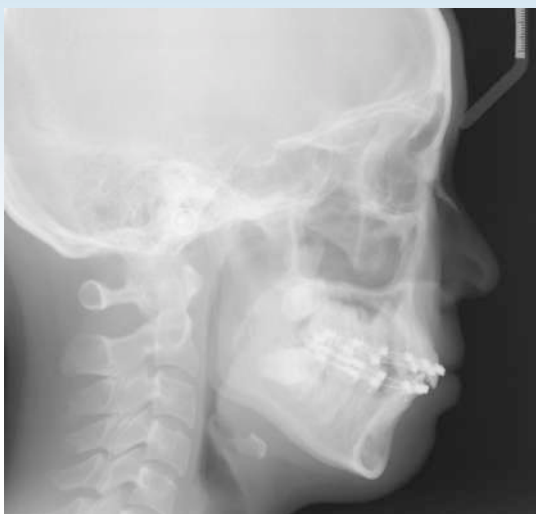
Fig. 18:
Interim treatment (11M) cephalometric and panoramic radiographs

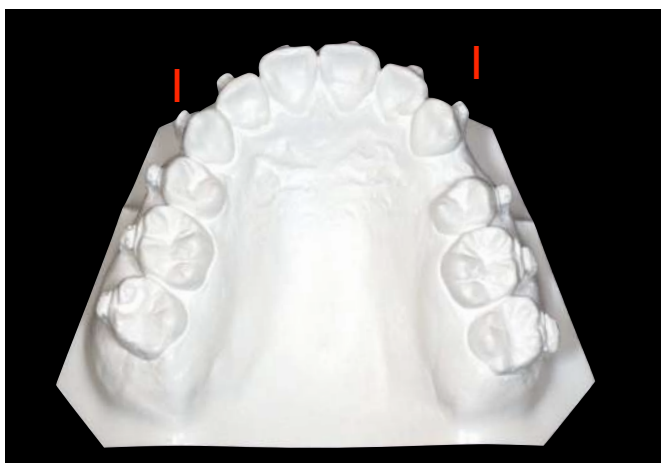

Fig. 19:
The interim treatment CRE (11M): Alignment/rotations had two discrepancies <1mm for a total of 2 points.

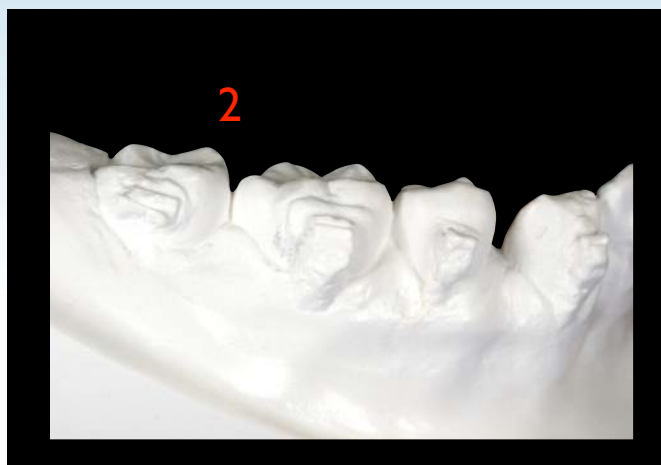

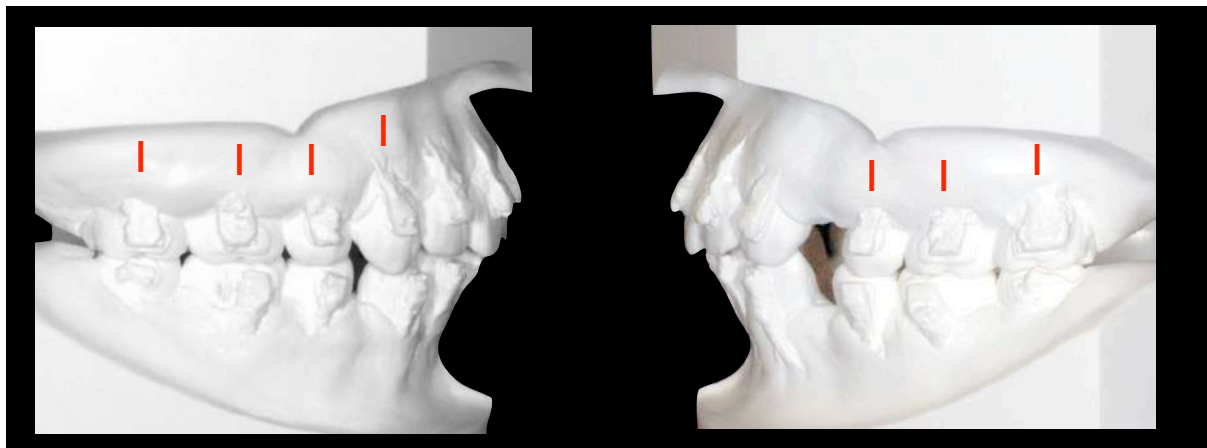
Fig. 20:
The interim treatment CRE (11M): A marginal ridge discrepancy >1mm was 2 points.

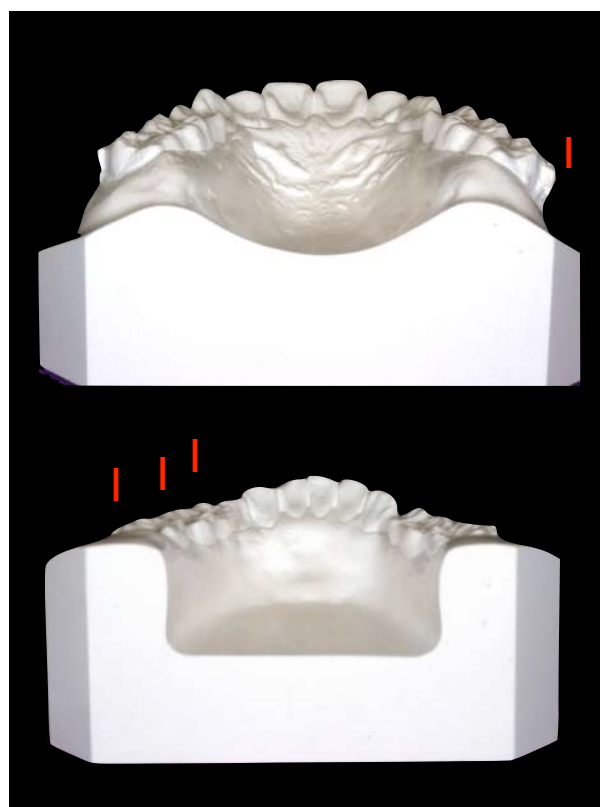
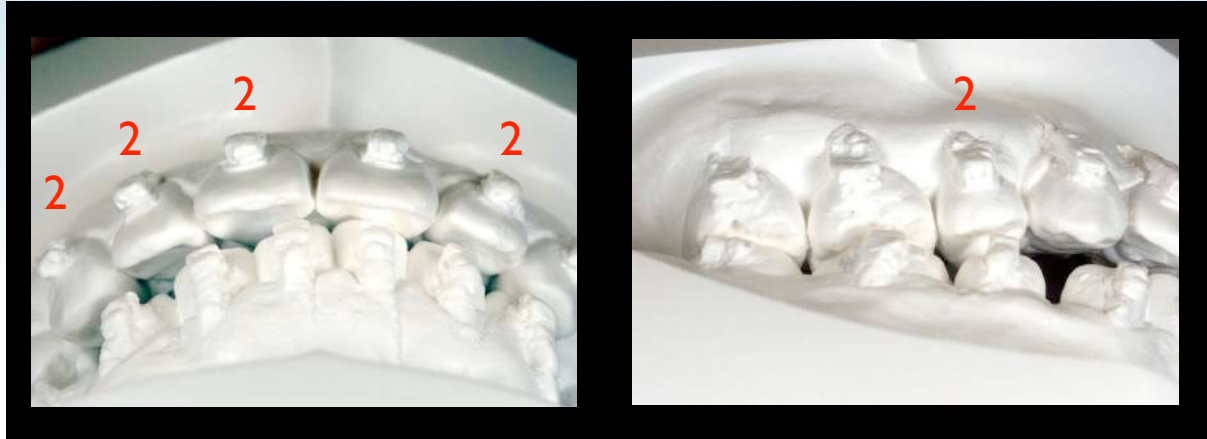
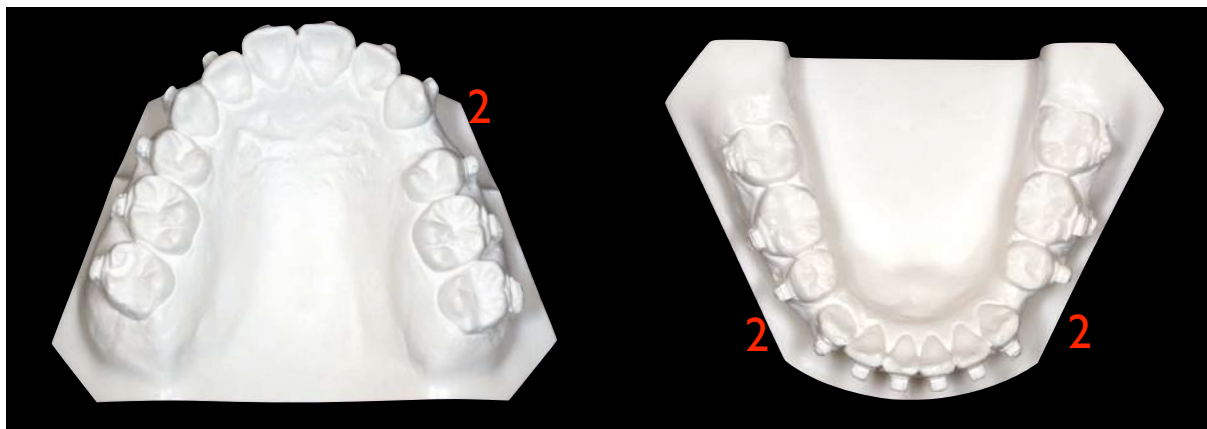
Fig. 21:
The interim treatment CRE (11M): Buccolingual Inclination discrepancies (red) were scored 4 points.



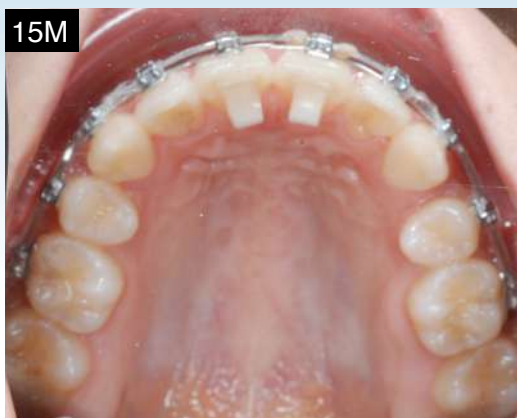■ **Fig. 22:** The interim treatment CRE (11M): Five overjet discrepancies >1mm resulted in a score of 10 points.



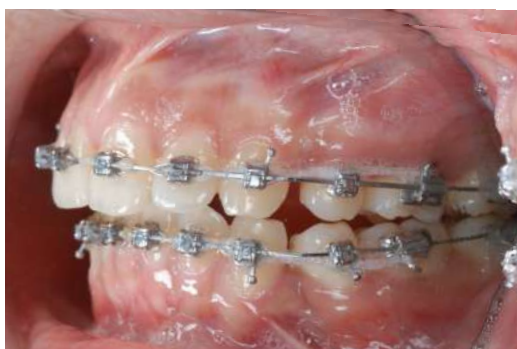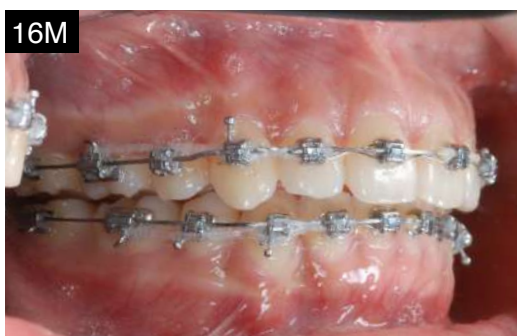■ **Fig. 23:** The interim treatment CRE (11M): Four occlusal relationships resulted in 7 points.



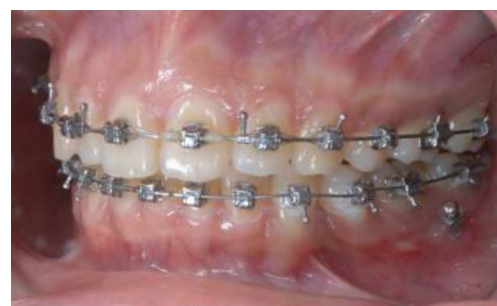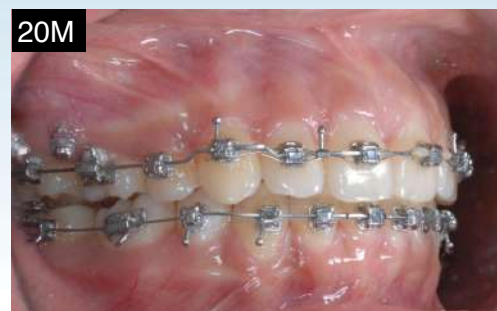■ **Fig. 24:** The interim treatment CRE (11M): Interproximal contact due to unclosed extraction spaces was scored at 6 points.



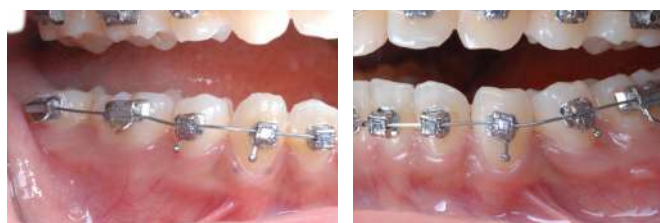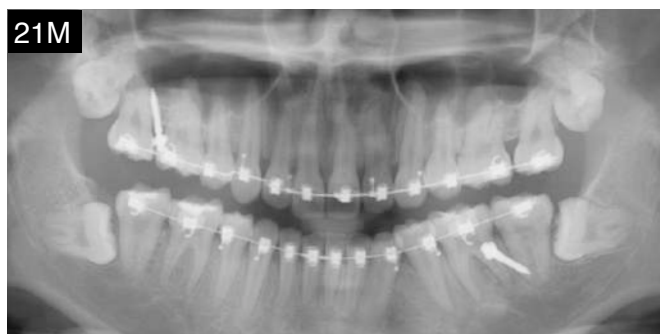■ **Fig. 25:**
Anterior bite turbos were bonded on upper central incisors to correct the deep bite.



■ **Fig. 26:**
Elastometric chains were attached from the canines to the first molars to close the residual extraction spaces in both arches.



■ **Fig. 27:**
Extra-alveolar miniscrews were inserted in the right IZC and the BS of left mandibular region near the first molar.



■ **Fig. 28:**
A panoramic radiograph was taken to evaluate bracket positions relative to the axial inclinations of the teeth, and brackets were repositioned accordingly. See text for details.

progress and to plan the future treatment (Figs. 30-33).

Interim Treatment Progress-2

Midcourse Corrections after 24 months

The progress Cast-Radiograph Evaluation (CRE) score was 31 points (Figs. 34-40). The upper anteriors were excessively retracted due to the extensive use of Class II elastics. The following objectives were generated based on the CRE score.

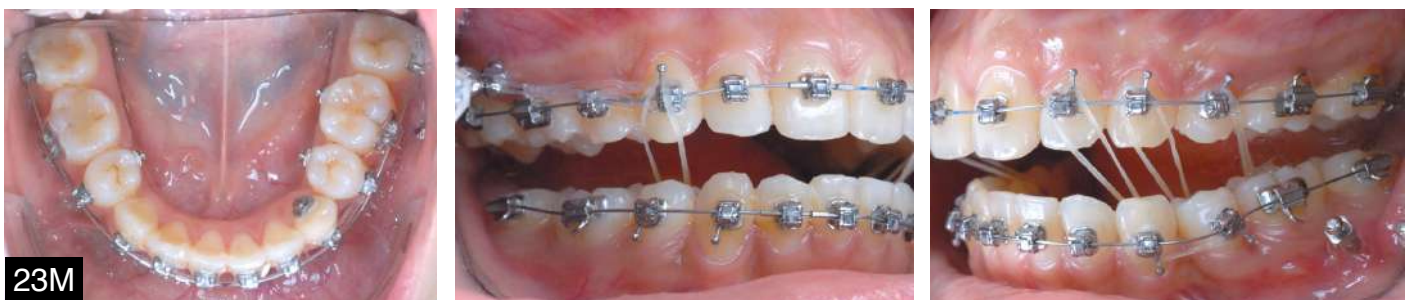1. Detailed bending to correct rotations (Fig. 34).
2. Arch coordination to improve occlusal relationship, contacts, and reduce the overjet (Figs. 37-39).
3. Improve occlusal contacts by using vertical elastics (Fig. 38).
4. Reposition brackets on LL3 and LL5 to improve root alignment (Fig. 40).
5. Increase lingual root torque on the upper anteriors by placing torque in the archwire.

6. Correct the midline deviation with BS miniscrews. On the left side, insert the miniscrew with a tilt-forward position in order to protract the left posterior segment.

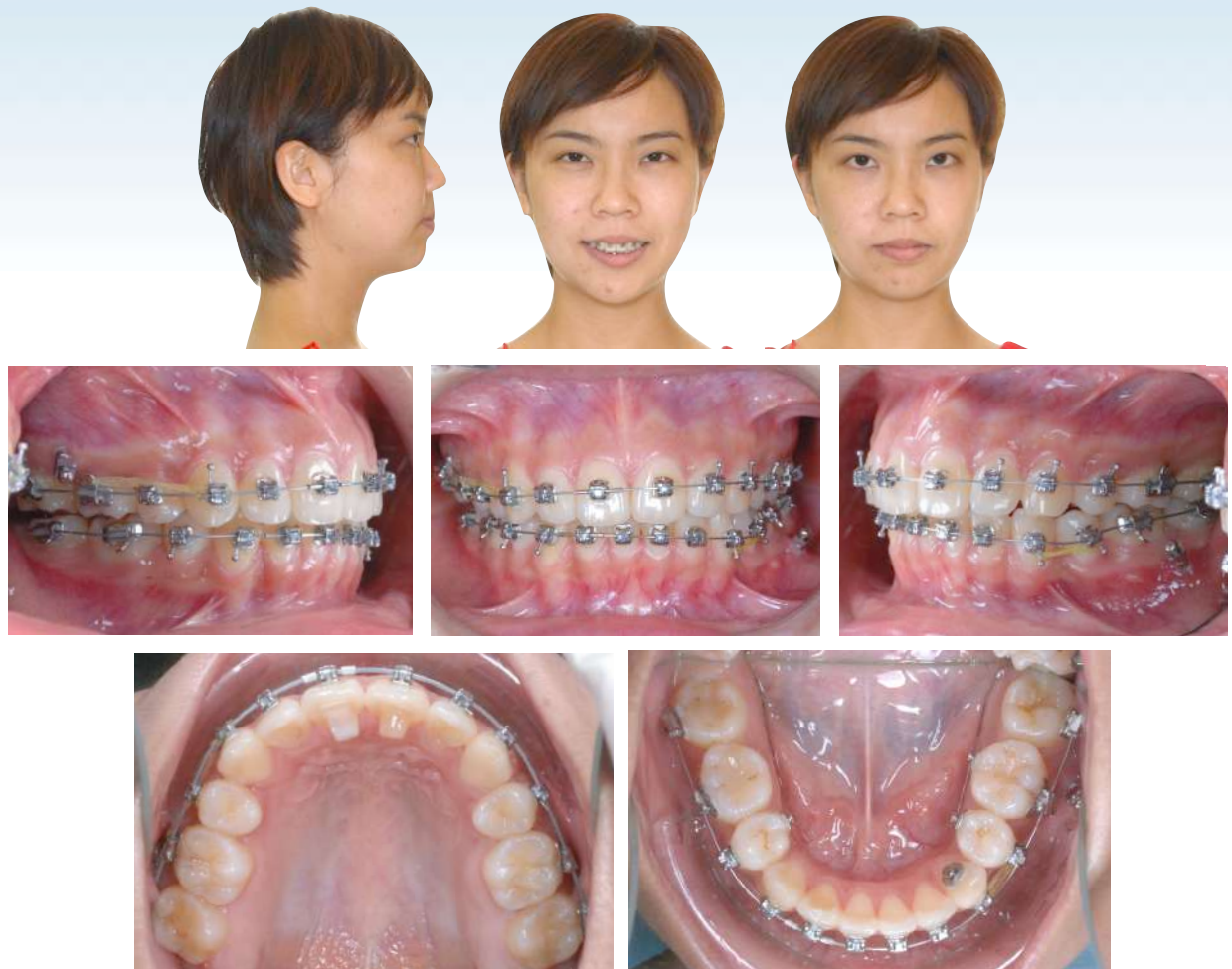To correct the midline deviation, BS miniscrews were used as prescribed. Three months later (27M), the patient complained about occlusal canting, so another miniscrew was placed between the UL3 and UL5 to anchor intrusion mechanics to correct the problem. Cross elastics (Kangaroo 3/16, 4.5oz.) were worn from the miniscrew to lower left second premolar and first molar (Fig. 41).

In the 31st month of treatment, continuous vertical elastics were applied to the posterior segments to improve occlusal contacts. One month later (32M), the upper and lower 5-5 brackets were removed for wedding photographs. They were replaced two weeks later. Upper and lower 0.016" NiTi archwires were fitted (Fig. 42). After one month, archwires were changed to 0.016" SS. Detailed bending and intermaxillary elastics were applied for the final correction.

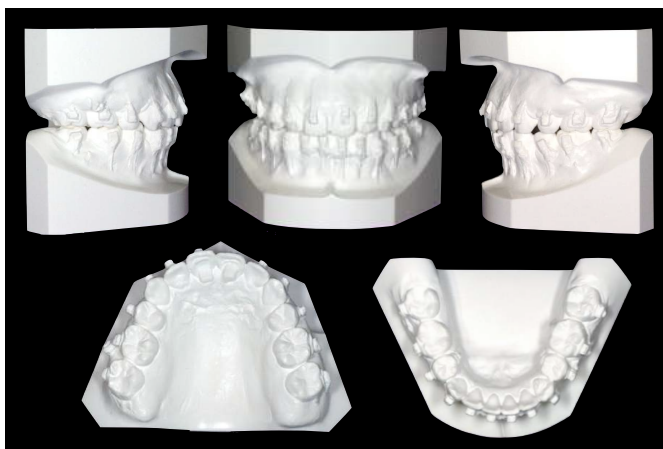After an optimal correction was achieved, all appliances were removed after 36 months of active treatment. Upper and lower clear overlay retainers were provided.



■ Fig. 29: Bond lingual buttons on LL3, LL5, LL6, and LR5 to apply cross elastics



■ **Fig. 30:** Interim treatment facial and intraoral photographs (24M)



■ **Fig. 31:** Interim treatment (24M) study models (casts)

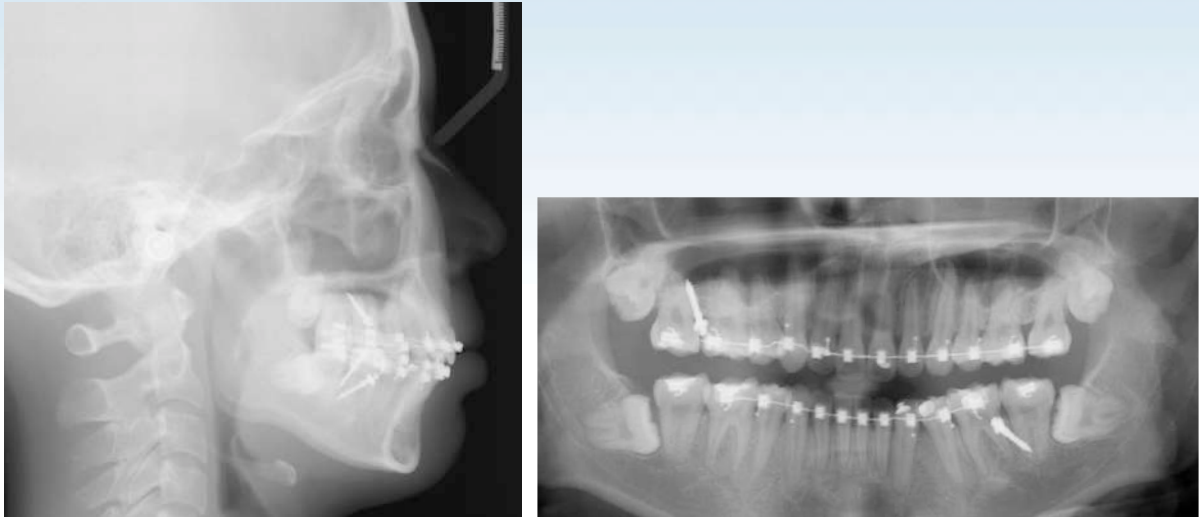Results Achieved

Maxilla:

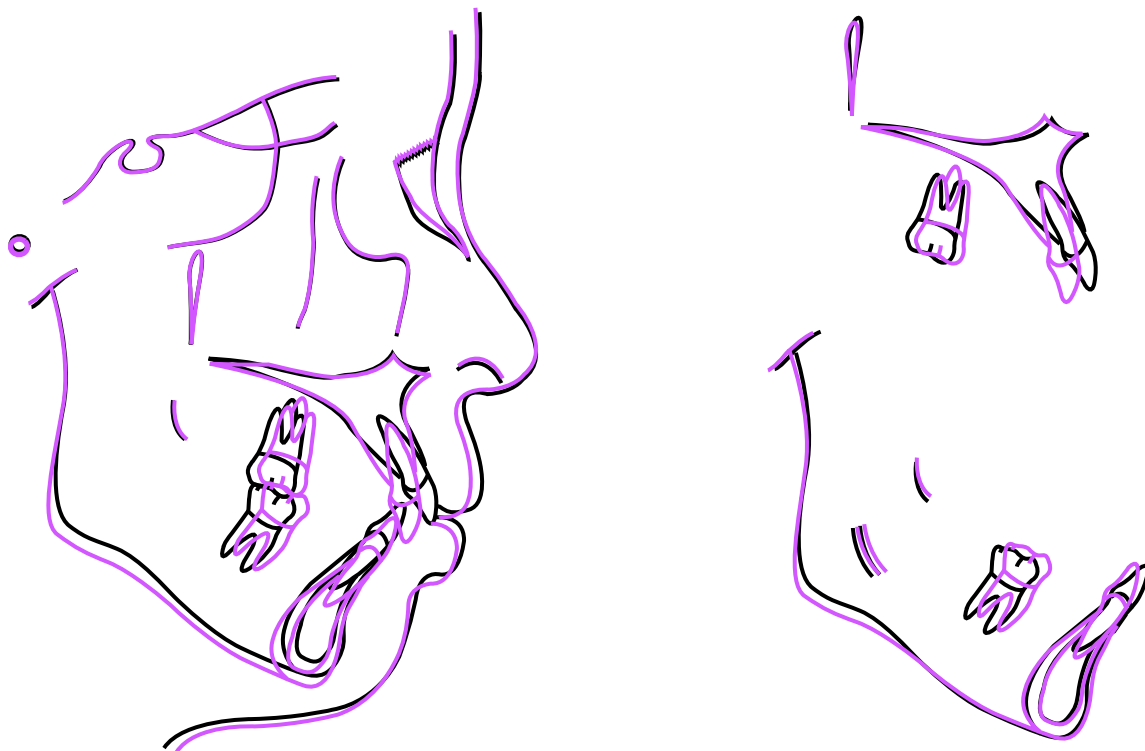
- A-P: *Maintained.*
- Vertical : *Maintained.*
- Transverse : *Maintained.*

Mandible:

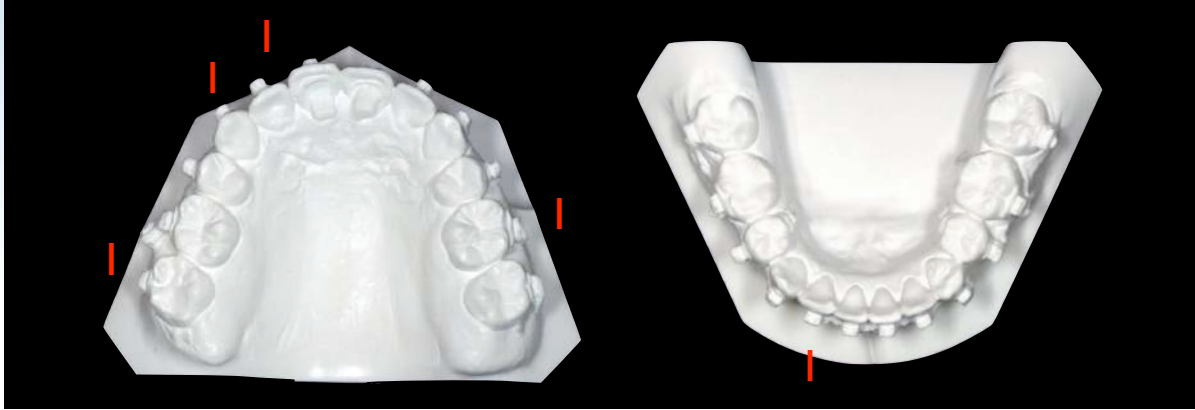
- A-P: *Maintained.*
- Vertical: *Maintained.*



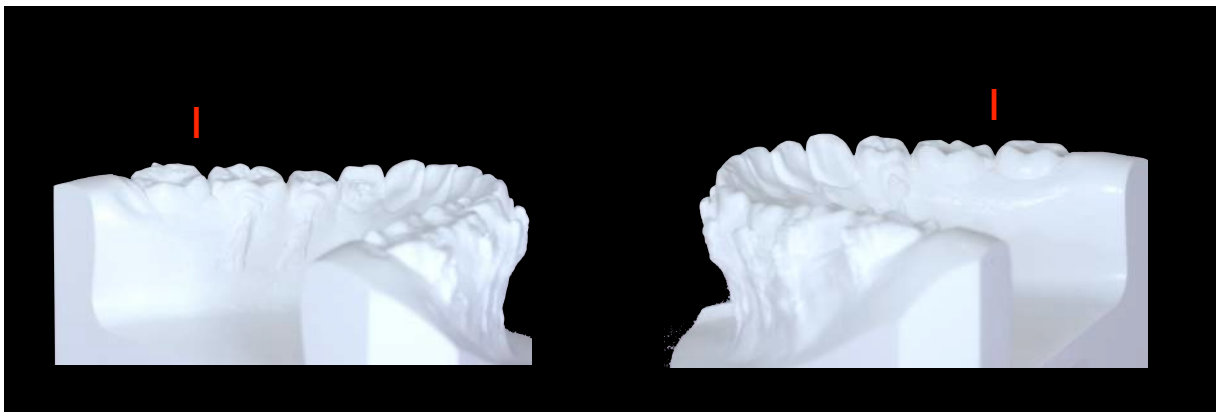■ **Fig. 32:** Interim treatment (24M) panoramic and cephalometric radiographs



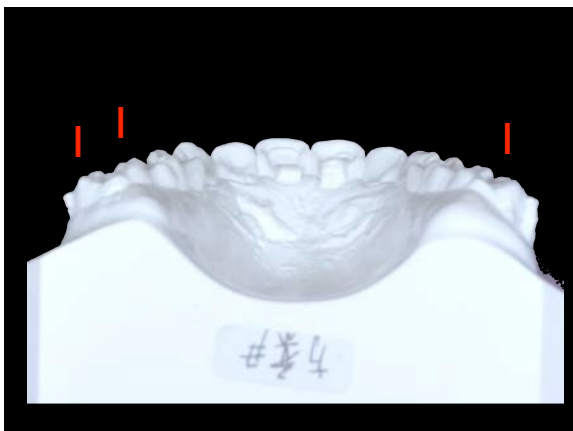
■ **Fig. 33:** Superimposed cephalometric tracings at 24 months of treatment revealed the maxillary incisors were excessively tipped to the lingual (pre-treatment: black; 24M: purple).



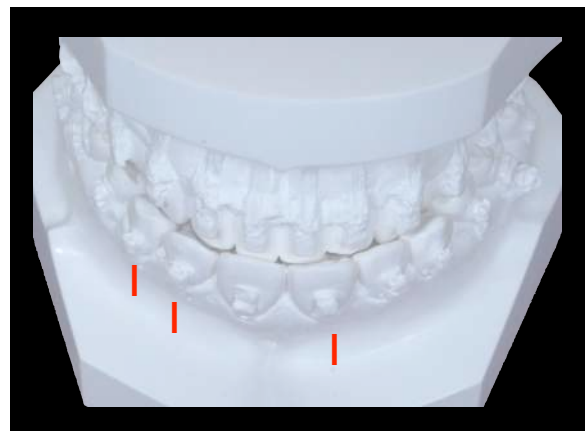■ **Fig. 34:** The interim treatment CRE (24M): Alignment/ Rotations lost 5 points.



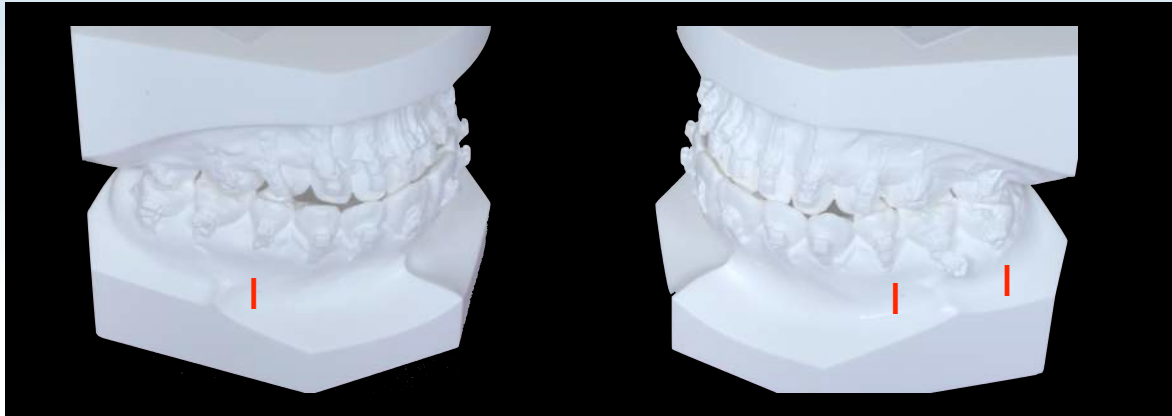
■ **Fig. 35:** The interim treatment CRE (24M): Marginal ridges lost 2 points.



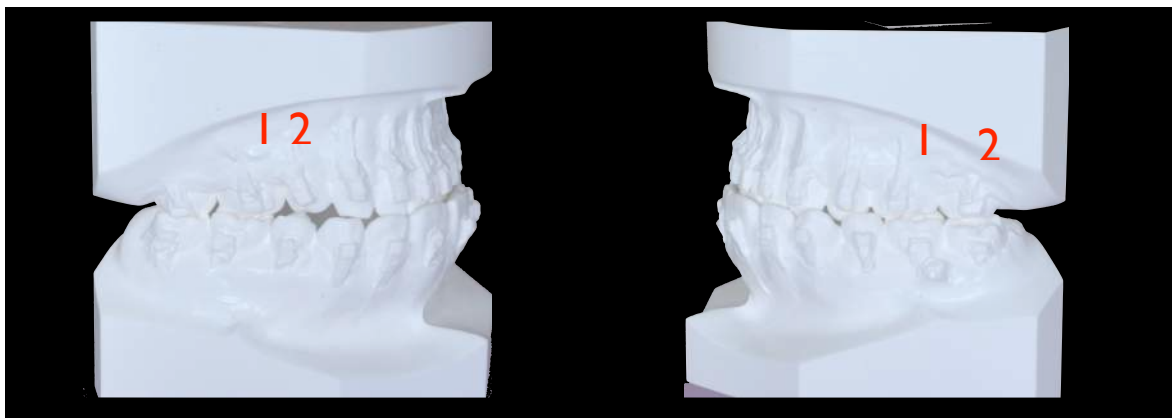
■ **Fig. 36:**
The interim treatment CRE (24M): Buccolingual inclination was scored 3 points.



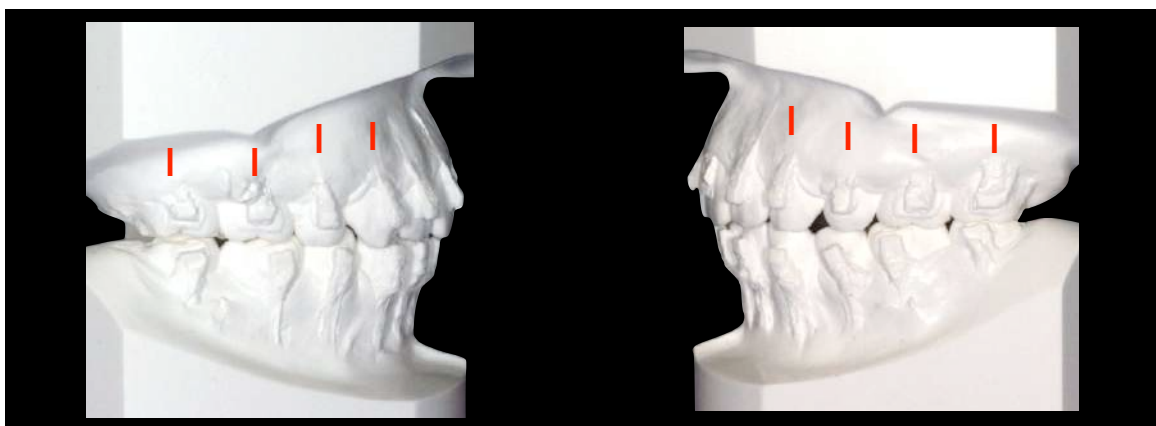
■ **Fig. 37a:**
The interim treatment CRE (24M): Overjet lost 3 points in this view.



■ **Fig. 37b:** The interim treatment CRE (24M): Overjet lost and additional 3 points (total 6 points)



■ **Fig. 38:** The interim treatment CRE (24M): Occlusal contact was scored 6 points.



■ **Fig. 39:** The interim treatment CRE (24M): Occlusal Relationships lost 8 points.

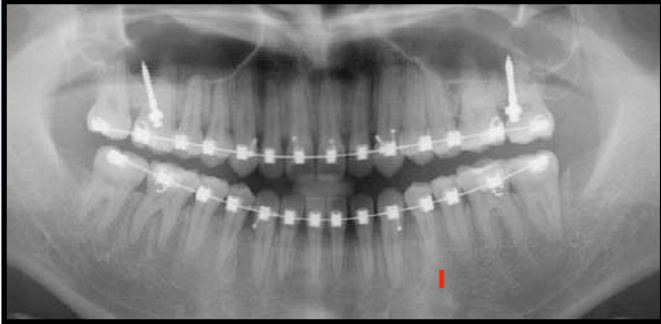


Fig. 40:
The interim treatment CRE (24M): Root angulation lost 1 point.

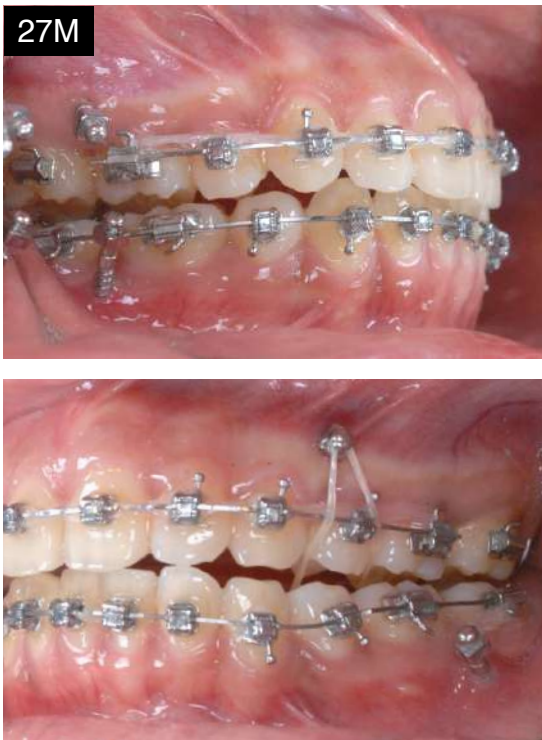

Fig. 41:
The miniscrew on the left side was inserted in a tilt-forward position in order to protract the left lower posteriors forward. Another miniscrew was placed between upper left canine and second premolar to provide intrusion mechanics to correct occlusal canting.

- Transverse: *Maintained.*

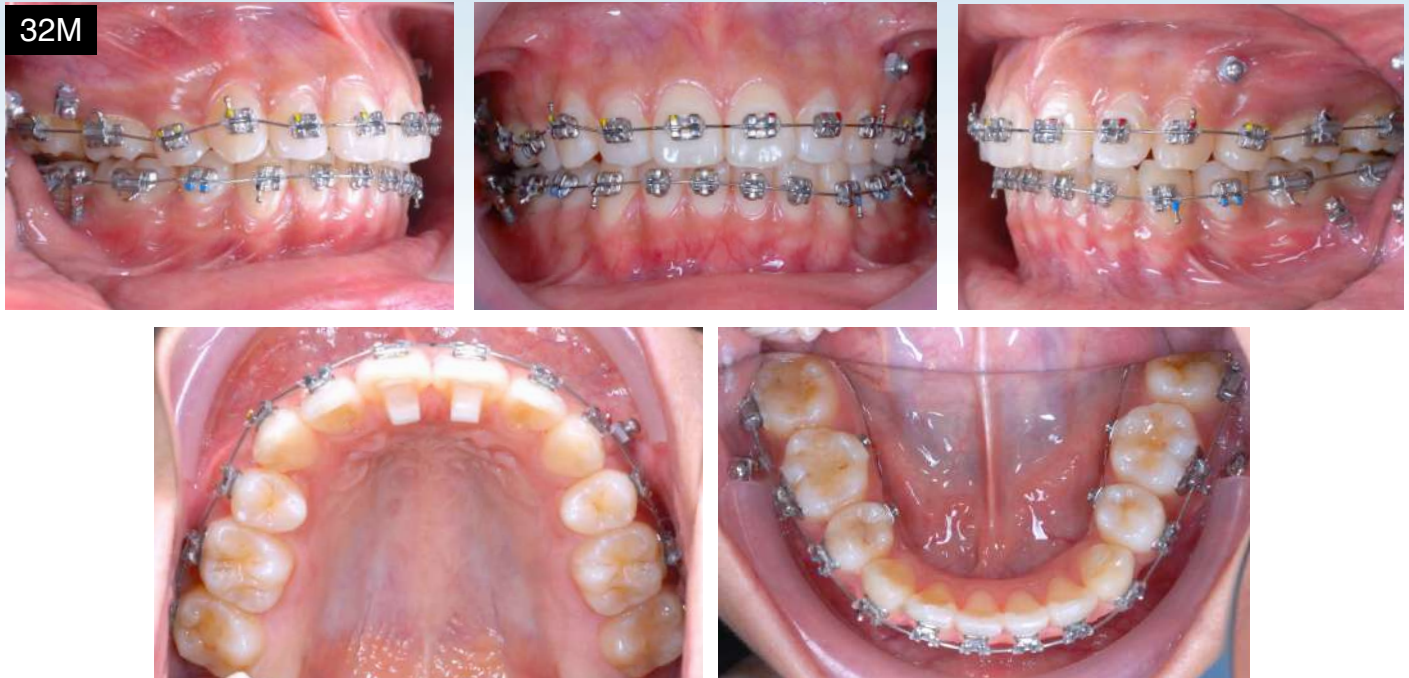
Maxillary Dentition:

- A-P: *Incisors were retracted and molars were protracted to close extraction space.*
- Vertical: *Incisors extruded and molars were maintained.*
- Inter-Molar Width: *Maintained.*
- Inter-Canine Width: *Increased.*
- Buccolingual Inclination: *Maintained.*
- Alignment: *Mesial-in rotation of UL3 was achieved.*

Mandibular Dentition:

- A-P: *Incisors were retracted and molars were protracted utilizing extraction space.*
- Vertical : *Incisors intruded and molars were extruded to flatten the plane of occlusion.*
- Inter-Molar Width: *Maintain.*
- Inter-Canine Width: *Increase.*
- Buccolingual Inclination: *Maintain.*
- Alignment: *Mesial-in rotation of LL3 was achieved.*

Facial Esthetics: *Decreased facial convexity and improved lip profile*



■ **Fig. 42:** Upper and lower 5-5 brackets were re-bonded, with 0.016 NiTi archwires fitted in each arch.

Retention

The patient was instructed to wear the upper and lower clear overlay retainers full time for the first 6 months and nights only thereafter. Home care and retainer maintenance instructions were provided. All four third molars were impacted so extractions were scheduled.

Final Evaluation of Treatment

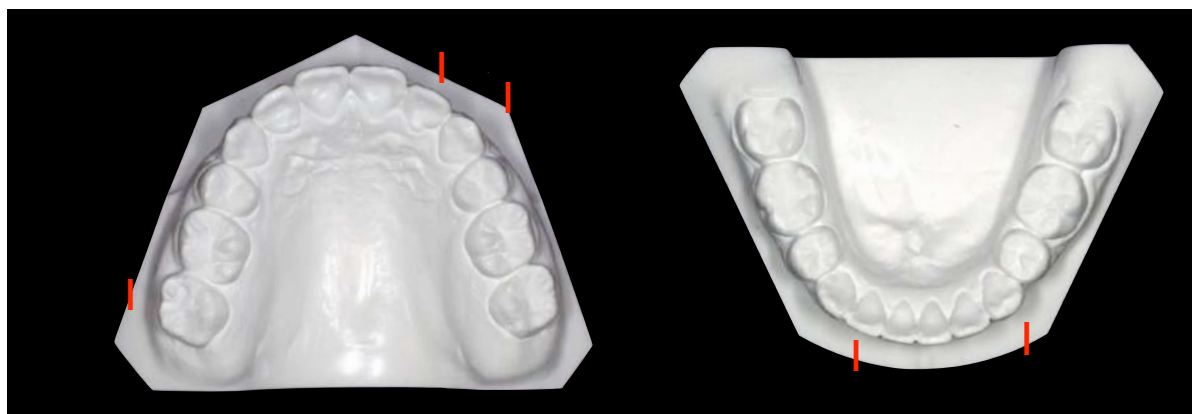
Cephalometric superimpositions (Fig. 9) reveal typical reciprocal tooth movement to close extraction sites. The upper molars were protracted more than the lower molars accentuating the Class II molar relationship. This problem could have been avoided with miniscrew anchorage and Class II elastics from the start of treatment. The upper

incisors tipped distally, preventing the complete correction of the Class II molar relationship. More lingual root torque was needed at an earlier stage of treatment. Intrusion of the lower incisors was primarily due to the use of anterior bite turbos, which also helped to maintain the proper overbite and overjet. Slight extrusion of the lower molars was noted due to the extensive use of Class II elastics. Overjet and overbite were ideal. The protrusive lips were reduced, improving lower face convexity (Fig. 9).

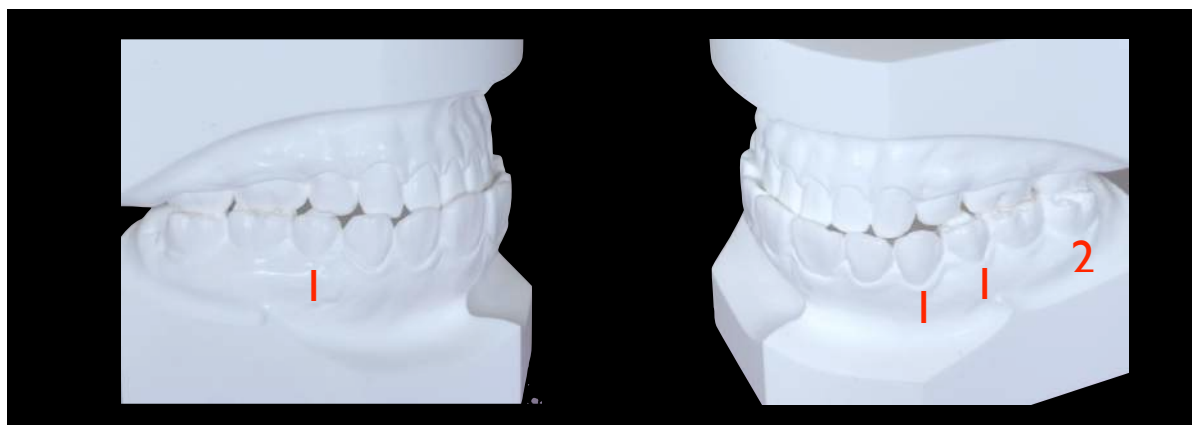The final ABO CRE score was 24 points. The major discrepancies are alignment/rotation (5 points), overjet (5 points), occlusal contacts (4 points), and occlusal relationships (6 points) (Figs. 43-46). Miniscrews were inserted in the IZC and BS areas bilaterally for Class II and midline correction.

Another miniscrew was inserted between the left canine and 2nd premolar to solve the occlusal canting. The mechanics were well designed to manage the malocclusion but the patient's personal commitment to an ideal result was compromised by her marriage plans. The appliances were removed and replaced twice for the wedding photographs. After that it was difficult to schedule finishing appointments, so it was necessary to accept an optimal rather than an ideal result.

In retrospect, the maxillary miniscrews were indicated early in the treatment to retract the upper molars to achieve a Class I molar relationship and correct the dental midline. The patient was satisfied with the treatment because the anterior crowding and lip protrusion were corrected. She had no interest in additional treatment to resolve the Class II buccal segments. Despite the incomplete sagittal correction, the prognosis for stability is good,



■ **Fig. 43:** The CRE: Alignment/ Rotations was scored 5 points.



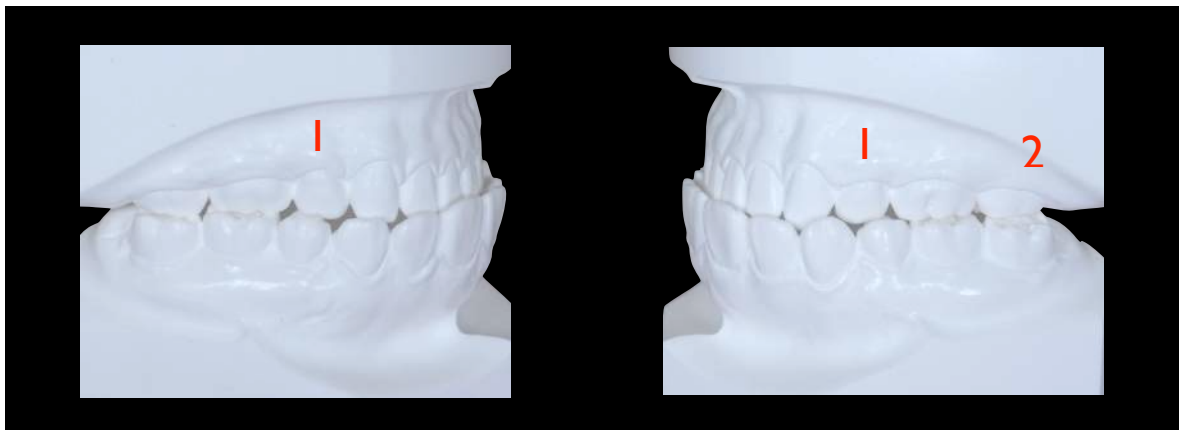■ **Fig. 44:** The CRE: Overjet lost 5 points as indicated.

presumably due to the patient's compliance with retainer wear.

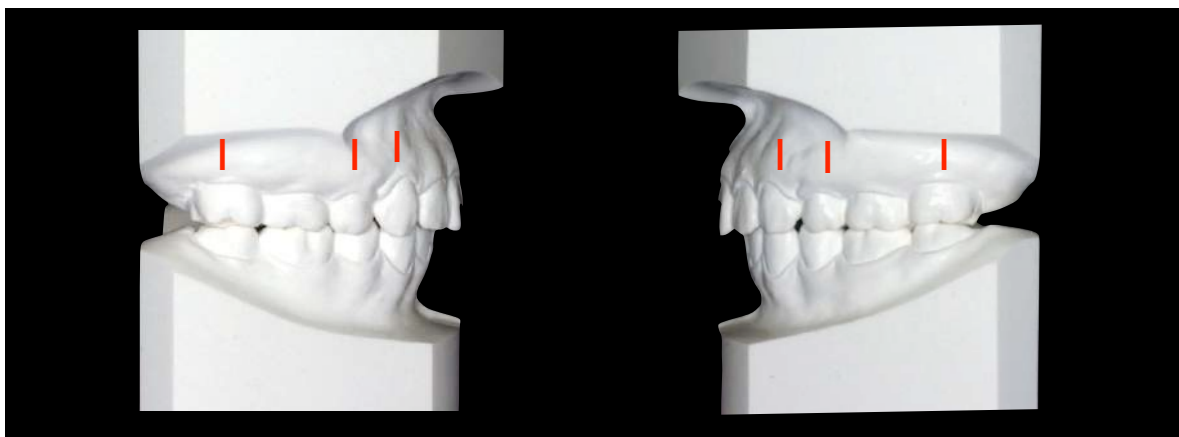
Discussion

To resolve a crowded anterior dentition with protrusive lips, extraction of four bicuspids is usually indicated. However, most orthodontic mechanics come with side effects. The vertical component of force for Class II elastics is usually considered to be

the biggest problem because it extrudes the maxillary incisors and mandibular molars, thereby leading to steepening of the occlusal plane as well as posterior rotation of the mandible. The horizontal vector of force may cause the mandibular first molars to rotate or tip mesially, increase the axial inclination of the incisors, and displace the entire lower dental arch anteriorly. In addition, the effect relative to extrusion and distal tipping of the maxillary incisors



■ **Fig. 45:** The CRE: Occlusal contacts was scored 4 points



■ **Fig. 46:** The CRE: Occlusal Relationships lost 6 points.

may adversely affect the smile line, leading to excessive gingival exposure and an increase in the axial inclination of the lower incisors.

It is important to define the use of Class II elastics, relative to diameter, strength, prescription, appropriate archwire, and periods of wear. Ultimately Class II elastics have similar effects to other methods for Class II treatment, such as fixed functional appliances.¹

Increased torque in upper incisor brackets and less torque in lower incisor brackets would have helped compensate for the side effects of Class II elastics. For the present case, high torque brackets were placed on upper incisors, and standard brackets on lower incisors. However, low torque brackets would have been superior for the mandibular incisors, and additional lingual root torque was needed for the maxillary incisors.

Retracting the dentition may result in an anterior deep bite and sometimes posterior open bite. To prevent over-closure, bite turbos were placed on the palatal side of the upper incisors and cross elastics were used in the posterior segments. Since a deep curve of Spee is usually associated with an increased overbite, a lower .0016x0.022" SS archwire with reversed curve of Spee was indicated for anterior intrusion and posterior extrusion in the mandibular arch.

The asymmetric crowding and decreased anchorage value of maxillary compared to mandibular molars contributed to the midline discrepancy that occurred during space closure. Use of differential anchorage in the buccal segments or

extra-alveolar temporary skeletal anchorage devices (E-A TSADs) is the best approach for managing anchorage as the spaces are closed. Midline coordination is an important landmark to guide orthodontists during space closure to achieve maximum intercuspation, optimal function, and anterior dental esthetics. However, small discrepancies of 1mm or so are often insignificant to the final occlusion. In fact, there are no points deducted for a midline discrepancy with the CRE outcome assessment. Midline discrepancies are only a problem if they are associated with a compromised intermaxillary posterior occlusion. Miniscrews are common supplemental anchorage for midline problems because they are simple to place and remove, they are relatively inexpensive, and there is minimal need for patient compliance.

One of the complications that can occur with the use of miniscrews is impingement on structures such as periodontal ligament, tooth roots, nerves, blood vessels, or the maxillary sinus. In case of impingement, the miniscrews should be removed and inserted in a different location. These placement problems rarely affect the treatment prognosis. As a general rule, it is advisable to leave a clearance of 2mm from the roots of teeth, nerves, and other vital structures,² especially when the miniscrews are inserted in interdental areas.³ That is why E-A TSADs are highly recommended to prevent damage to roots of teeth and contact with the periodontal ligament (PDL). Inflammation and infection of the tissues around miniscrews are often significant problems, best handled by meticulous oral hygiene, 0.2% chlorhexidine mouth rinses, and/or topical

application of the same solution with dental floss or interproximal brushes.

Although miniscrews have enjoyed routine use for orthodontic anchorage in recent years, there are still many problems particularly failure, defined as loosening and/or loss of the anchorage unit. A recent meta-analysis by Papageorgiou et al.⁴ reported that orthodontic miniscrews have a modest mean failure rate of only 13.5%, but much of the published data is reported by authors with a conflict of interest. Miniscrew failure may be due to inflammation of the surrounding bone, location of the miniscrew, thickness of cortical bone, skeletal characteristics, and age.

A higher failure rate is common for miniscrews placed in the mandible compared to the maxilla. By placing the miniscrew at a different angulation, the change in the amount of bone contact may affect the failure rate. The angle of the miniscrew to the long axis of the teeth was generally 43–47°, which resulted in the miniscrew being relatively far from the neighboring tooth roots.⁵ Watanabe et al.⁶ stated that root proximity is the factor that is most likely to precipitate miniscrew failure, especially when placed in the mandible. They failed to identify an association between miniscrew failure with the patients' age, bone density, or site of insertion. However, the jaw of insertion and root proximity are clearly related to miniscrew failure.⁷ Extra-alveolar insertion in the IZC, BS and palate, usually increases the cortical bone contact which enhances the stability of the screw. Furthermore, the more upright position of the screw reduces the possibility of root damage.⁸

During treatment progress, brackets were rebonded to achieve optimal alignment with a minimum of archwire adjustments. The common marginal ridge discrepancy between an adjacent premolar and first molar can be corrected by placing the brackets of first molar more occlusally, and positioning the premolar bracket more apically (Fig. 13). The mesio-distal (M-D) positions of lateral incisors, canines, and upper first premolars should be confirmed with an oral mirror from occlusal view to check the bracket positions relative to the axial inclinations of the teeth. In general, it is wise to bond brackets in a more mesial position on the lateral incisors and canines. For upper first premolars, a more distal position is often preferred.⁹

Conclusions

A challenging Class II malocclusion with severe crowding and lip protrusion (DI=19) was managed initially with premolar extractions, space closure, and Class II elastics. Side effects of these conservative mechanics required additional treatment with bite turbos and miniscrew anchorage. An active treatment time of 36 months produced an optimal result, documented by a CRE score of 24 and a Pink and White dental esthetic score of 2. Utilizing E-A miniscrew anchorage from the beginning of treatment would probably have improved the result and decreased treatment duration. Both the patient and the clinician were satisfied with the result.

References

1. Janson G, Sathler R, Fernandes TM, Branco NC, Freitas MR. Correction of Class II malocclusion with Class II

- elastics: A systematic review. *Am J Orthod Dentofacial Orthop* 2013;143:383-92.
2. Ohashi E, Pecho O, Moron M, Lagravere M. Implant vs screw loading protocols in orthodontics. *Angle Orthod* 2006;76:721-7.
 3. Wang YC, Liou EJW. Comparison of the loading behavior of self-drilling and predrilled miniscrews throughout orthodontic loading. *Am J Orthod Dentofacial Orthop* 2008;133:38-43.
 4. Papageorgiou SN, Zogakis IP, Papadopoulos MA. Failure rates and associated risk factors of orthodontic miniscrew implants: A meta-analysis. *Am J Orthod Dentofacial Orthop* 2012;142:577-95.
 5. Kim SH, Yoon HG, Choi YS, Hwang EH, Kook YA, Nelson G. Evaluation of interdental space of the maxillary posterior area for orthodontic mini-implants with cone-beam computed tomography. *Am J Orthod Dentofacial Orthop* 2009;135:635-41.
 6. Watanabe H, Deguchi T, Hasegawa M, Ito M, Kim S, Takano-Yamamoto T. Orthodontic miniscrew failure rate and root proximity, insertion angle, bone contact length, and bone density. *Orthod Craniofac Res* 2013; 16:44-55.
 7. Chang CH, Roberts WE. Stability of mini-screws on buccal shelves: A retrospective study of 1680 mini-screw insertions by the same orthodontist. *Int J Ortho Implantol* 2013; 30:76-78.
 8. Chang CH, Roberts WE. A retrospective study of the extra-alveolar screw placement on buccal shelves. *Int J Ortho Implantol* 2013; 32:80-89.
 9. Pitts TR. Begin with the end in minds: Bracket placement and early elastic protocols for smile arc protection. *Ormco clinical impressions* 2009;17:2-11.



Discrepancy Index Worksheet

TOTAL D.I. SCORE

19

OVREJET

0 mm. (edge-to-edge)	=	
1 - 3 mm.	=	0 pts.
3.1 - 5 mm.	=	2 pts.
5.1 - 7 mm.	=	3 pts.
7.1 - 9 mm.	=	4 pts.
> 9 mm.	=	5 pts.

Negative OJ (x-bite) 1 pt. per mm. Per tooth =

Total = 3

OVERBITE

0 - 3 mm.	=	0 pts.
3.1 - 5 mm.	=	2 pts.
5.1 - 7 mm.	=	3 pts.
Impinging (100%)	=	5 pts.

Total = 2

ANTERIOR OPEN BITE

0 mm. (Edge-to-edge), 1 pt. per tooth
Then 1 pt. per additional full mm. Per tooth

Total = 1

LATERAL OPEN BITE

2 pts. per mm. Per tooth

Total = 0

CROWDING (only one arch)

1 - 3 mm.	=	1 pt.
3.1 - 5 mm.	=	2 pts.
5.1 - 7 mm.	=	4 pts.
> 7 mm.	=	7 pts.

Total = 7

OCCLUSION

Class I to end on	=	0 pts.
End on Class II or III	=	2 pts. per side _____ pts.
Full Class II or III	=	4 pts. per side _____ pts.
Beyond Class II or III	=	1 pt. per mm. _____ pts. additional

Total = 0

LINGUAL POSTERIOR X-BITE

1 pt. per tooth Total = 0

BUCCAL POSTERIOR X-BITE

2 pts. Per tooth Total = 0

CEPHALOMETRICS (See Instructions)

ANB $\geq 6^\circ$ or $\leq -2^\circ$ = 4 pts.Each degree $< -2^\circ$ _____ x 1 pt. = _____Each degree $> 6^\circ$ _____ x 1 pt. = _____

SN-MP

 $\geq 38^\circ$ = 2 pts.Each degree $> 38^\circ$ _____ x 2 pts. = _____ $\leq 26^\circ$ = 1 pt.Each degree $< 26^\circ$ _____ x 1 pt. = _____1 to MP $\geq 99^\circ$ 104° = 1 pt.Each degree $> 99^\circ$ 5 x 1 pt. = _____

Total = 6

OTHER (See Instructions)

Supernumerary teeth _____ x 1 pt. = _____

Ankylosis of perm. Teeth _____ x 2 pts. = _____

Anomalous morphology _____ x 2 pts. = _____

Impaction (except 3rd molars) _____ x 2 pts. = _____Midline discrepancy (≥ 3 mm) @ 2 pts. = _____Missing teeth (except 3rd molars) _____ x 1 pt. = _____

Missing teeth, congenital _____ x 2 pts. = _____

Spacing (4 or more, per arch) _____ x 2 pts. = _____

Spacing (Mx cent. diastema ≥ 2 mm) @ 2 pts. = _____

Tooth transposition _____ x 2 pts. = _____

Skeletal asymmetry (nonsurgical tx) @ 3 pts. = _____

Addl. treatment complexities _____ x 2 pts. = _____

Identify:

Total = 0

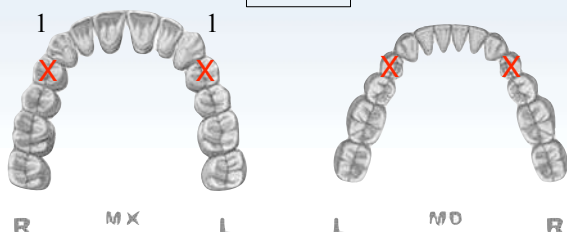
Cast-Radiograph Evaluation

Total Score:

31

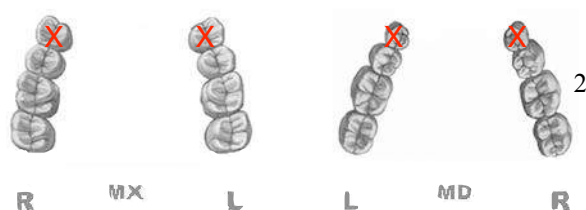
Alignment/Rotations

2



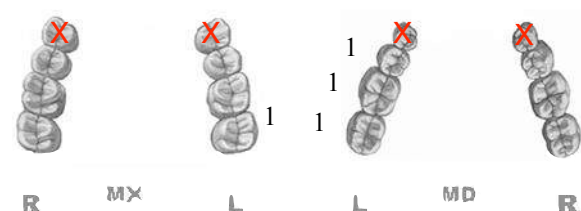
Marginal Ridges

2



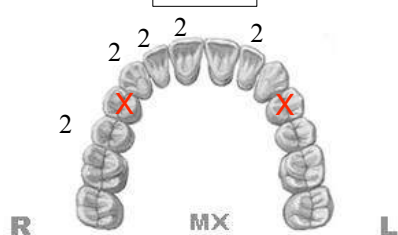
Buccolingual Inclination

4



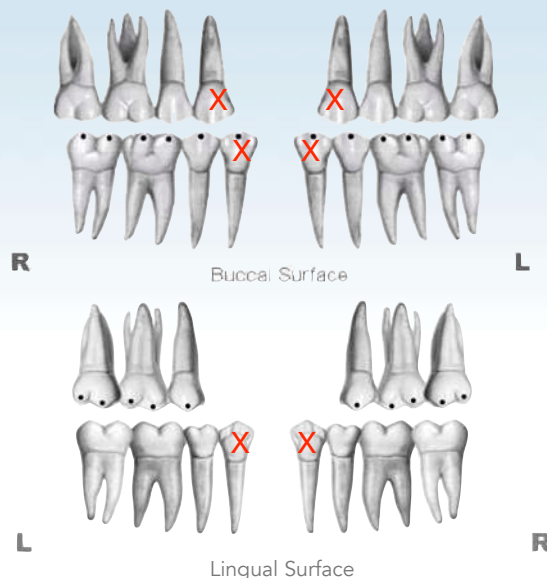
Overjet

10



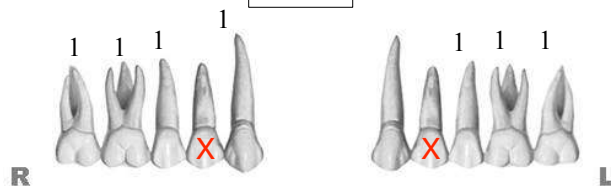
Occlusal Contacts

0



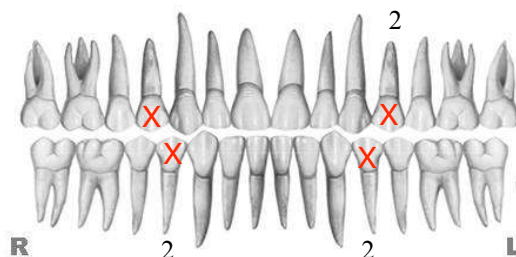
Occlusal Relationships

7



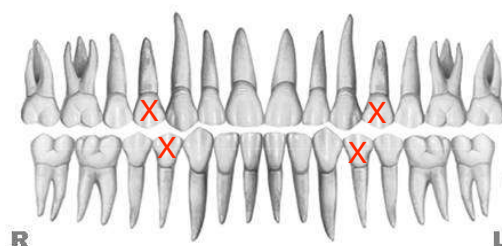
Interproximal Contacts

6



Root Angulation

0



INSTRUCTIONS: Place score beside each deficient tooth and enter total score for each parameter in the white box. Mark extracted teeth with "X". Second molars should be in occlusion.

Cast-Radiograph Evaluation

31


5



2




3



6



6



8



0



1



INSTRUCTIONS: Place score beside each deficient tooth and enter total score for each parameter in the white box. Mark extracted teeth with "X". Second molars should be in occlusion.

Final Evaluation

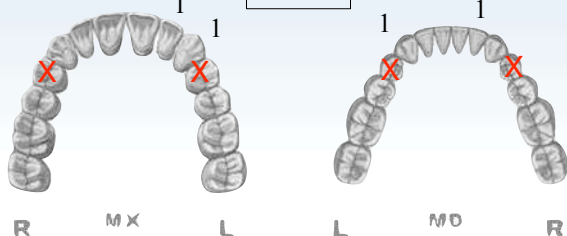
Cast-Radiograph Evaluation

Total Score:

24

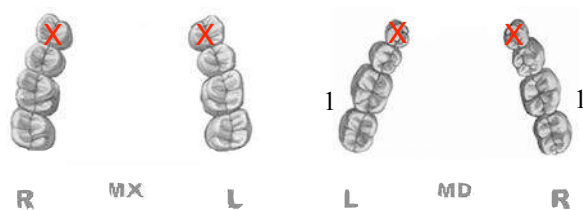
Alignment/Rotations

5



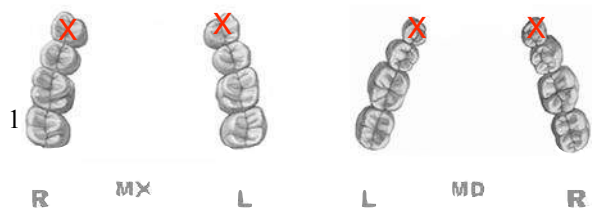
Marginal Ridges

2



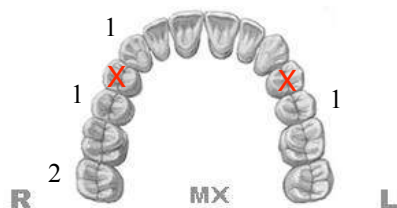
Buccolingual Inclination

0



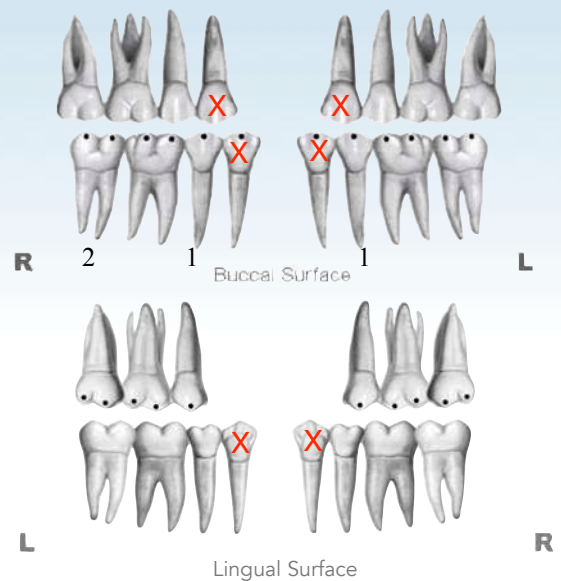
Overjet

5



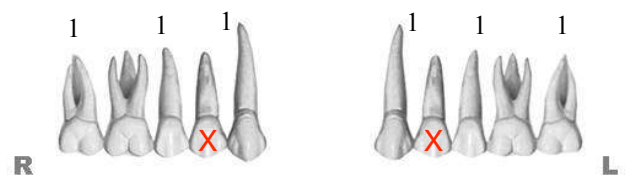
Occlusal Contacts

4



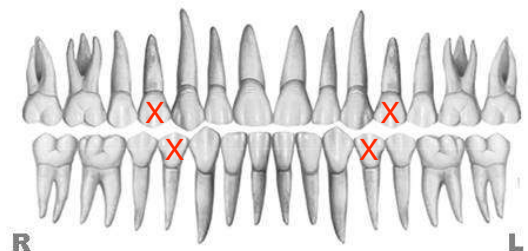
Occlusal Relationships

6



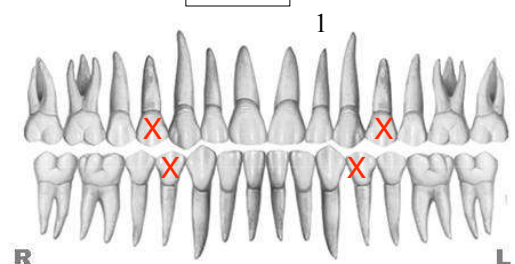
Interproximal Contacts

0



Root Angulation

1

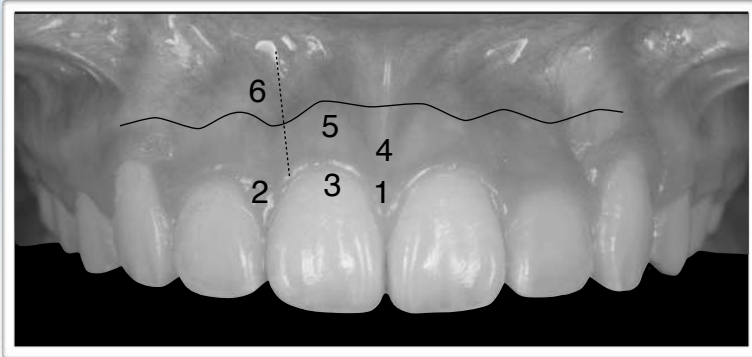


INSTRUCTIONS: Place score beside each deficient tooth and enter total score for each parameter in the white box. Mark extracted teeth with "X". Second molars should be in occlusion.

IBOI Pink & White Esthetic Score

Total Score = **2**

1. Pink Esthetic Score

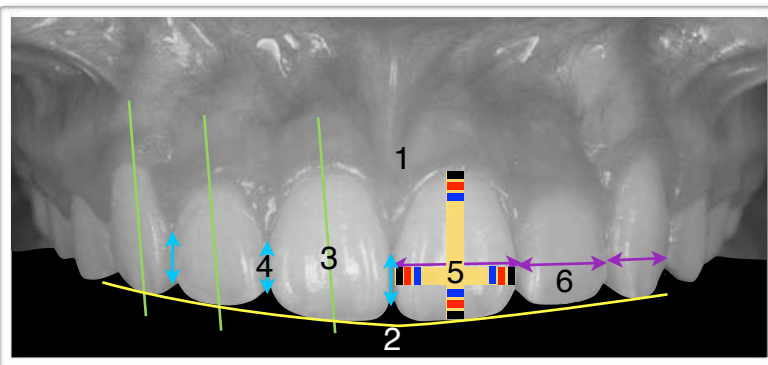


1. M & D Papillae	0	1	2
2. Keratinized Gingiva	0	1	2
3. Curvature of Gingival Margin	0	1	2
4. Level of Gingival Margin	0	1	2
5. Root Convexity (Torque)	0	1	2
6. Scar Formation	0	1	2

Total = **1**

1. M & D Papillae	0	1	2
2. Keratinized Gingiva	0	1	2
3. Curvature of Gingival Margin	0	1	2
4. Level of Gingival Margin	0	1	2
5. Root Convexity (Torque)	0	1	2
6. Scar Formation	0	1	2

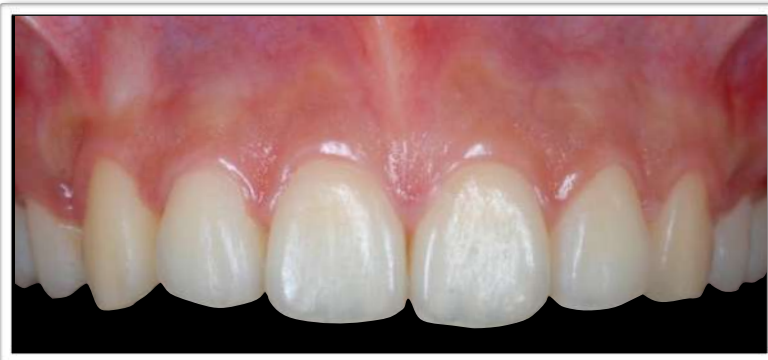2. White Esthetic Score (for Micro-esthetic)



1. Midline	0	1	2
2. Incisor Curve	0	1	2
3. Axial Inclination (5° , 8° , 10°)	0	1	2
4. Contact Area (50% , 40% , 30%)	0	1	2
5. Tooth Proportion	0	1	2
6. Tooth to Tooth Proportion	0	1	2

Total = **1**

1. Midline	0	1	2
2. Incisor Curve	0	1	2
3. Axial Inclination (5° , 8° , 10°)	0	1	2
4. Contact Area (50% , 40% , 30%)	0	1	2
5. Tooth Proportion	0	1	2
6. Tooth to Tooth Proportion	0	1	2

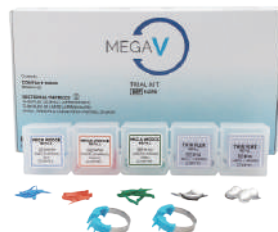

1. ISOLATION



Contact Matrix
NT\$4,500/盒

買 1 送 1



MEGA V
特價 NT\$5,390/盒



MEGA V Rings Refill
NT\$6,100/1盒2個

買 1 送 1

2. BONDING SYSTEM

黏著劑系列

Total etch

OptiBond FL

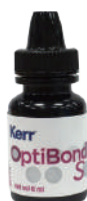4th



特價 NT\$5,500/組

OptiBond S

5th



特價 NT\$6,000/5瓶

Self etch

OptiBond Universal

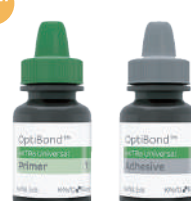8th



特價 NT\$7,500/5瓶

OptiBond eXTRa Universal

9th



NEW ARRIVAL

定價 買 3 送 1

3.COMPOSITE SERIES

4.LIGHT CURE

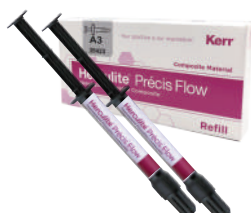Flowable

Dyad Flow



特價 NT\$5,000/4支

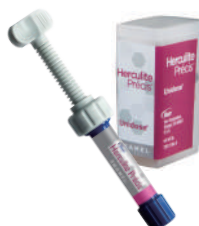Herculite Précis Flow



特價 NT\$10,000/10盒

Universal

Herculite Précis



特價 NT\$5,500/10支

Harmonize



特價 NT\$12,000/10支

美學專用



NEW ARRIVAL

無線型光聚機 Demi Plus

特價 NT\$28,000/台

優惠期限自 2022/04/01~2022/12/25 止

IMPRESSION

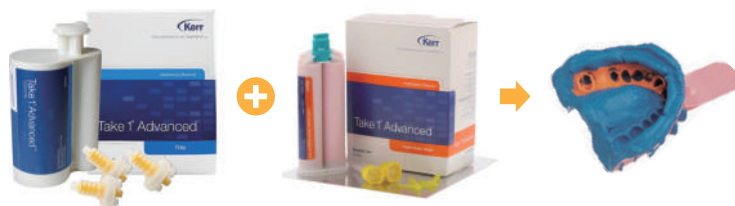Full denture / RPD / Implant

Take 1 Advanced
Med / Mono



Crown / Bridge / Inlay / Onlay / Implant

Take 1 Advanced
HB Tray + LB Wash



定價 買 3 送 1 或 買 10 送 6

CEMENTATION

處理劑

Silane Primer

特價 NT\$2,400/瓶



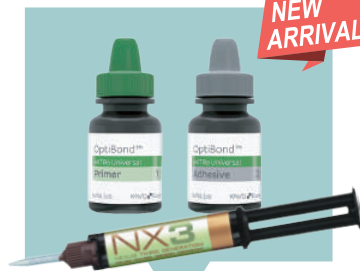In/Onlay / Crown



一支會變色的 RESIN CEMENT
UNIQUE COLOR INDICATOR
讓您精確掌握多餘Cement的移除時機！

Maxcem Elite™ Chroma
(5gx2支/盒)

特價 NT\$13,750/5盒

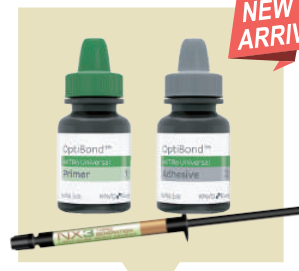

OptiBond eXTRA Universal x1組
(1組/2罐/各5ml)

NX3 Dual Cure x1支
(5g/支)

特價 NT\$5,500/套

Veneer



OptiBond eXTRA Universal x1組
(1組/2罐/各5ml)

NX3 Light Cure x1支
(1.8g/支)

特價 NT\$5,500/套





Products

Dental Products Essential Kit



Double Retractors 2.0 Autoclavable!

Double Retractors x2, Black Board x2

While keeping the same lip & cheek two-way design, the new Double Retractors 2.0 is upgraded to medical grade PPSU. This new material is more durable, resilient and most importantly, autoclavable. Its smooth edges and translucent quality make it the best aid to perfect intra-oral photography.



Stainless Steel Mirror

Strong, durable stainless steel, autoclave-proof, the specially designed size, shape and thickness ensure maximum intra-oral view without sacrificing patient comfort.

NEW



Bite Turbo 3.0 Autoclavable!

Handle x1, BT molds x6, BT extended molds x6, Button molds x6

A simple and powerful tool to correct severe deep bite and cross efficiently. The handle of Bite Turbo 3.0 is now autoclavable with non-slip design. The bite turbos and lingual button molds, made with silicon and filled with flowable resin, can be reused and adjusted depending on treatment progress. The longer one allows you to solve all kinds of deep bite and large horizontal overjet.

OrthoBoneScrew

2022 Damon Master Program

一年一度

預報享優惠價



+



全新改版的 2022 貝多芬高效 Damon 矯正大師系列課程，是由國際知名講師張慧男醫師親自規劃及授課，課程特色強調由臨床病例帶動診斷、分析、治療計畫擬定與執行技巧，本年度亦特別加入最新的數位矯正與隱形牙套的內容，並邀請了貝多芬牙科集團各院院長演講特別矯正專題。

此外，透過數位影片反覆觀看，結合矯正與電腦教學，課堂助教協助操作，以及診間臨床見習，讓學員在短時間能快速上手，感染「熱愛學，熱愛學矯正」的熱情。

名額有限，一年僅有一次機會在台完整體驗 Damon 矯正大師課程，錯過只能等明年囉！

Module 1 - 4/14 (A班) | 6/9 (B班)

1. Selecting your ideal first case
2. Bonding position
3. Bonding + BT + Ceph tracing
4. TADs + space closing + hook + spring
5. Finishing bending & fixed retainer

Practice: Clinical photography

Module 2 - 4/28 (A班) | 6/30 (B班)

1. Four stages of efficient orthodontic treatment
2. Simple and effective anchorage system
3. Extraction vs. Non-extraction analysis

Practice: Patient photo management

Module 3 - 5/12 (A班) | 7/14 (B班)

1. Soft & hard tissue diagnostic analysis
2. Big overjet correction
3. Damon diagnosis & fine-tuning

Practice: Ceph tracing

Module 4 - 6/2 (A班) | 7/28 (B班)

1. Excellent finishing
2. Retention & relapse

Practice: Ceph superimposition & measurement

Module 5 - 6/16 (A班) | 8/4 (B班)

1. Simplify your system
2. Extraction vs. non-extraction

Practice: Case report demo

▲ Computer training (Mac): 1:30-2:30 pm

Module 6 - 7/21 (A班) | 9/1 (B班)

1. Class III correction
2. Class II correction

Topic: Early orthodontic treatment (曾淑萍醫師)

Module 7 - 8/18 (A班) | 9/22 (B班)

1. Upper impaction
2. Lower impaction
3. Gummy smile correction

Topic: Modified VISTA (蘇奎璋醫師)

Module 8 - 9/15 (A班) | 10/20 (B班)

1. ABO DI, CRE workshop
2. Open bite

Topic: Modified 2X4 appliance in ortho treatment (徐玉玲醫師)

Module 9 - 9/29 (A班) | 11/3 (B班)

1. Implant-ortho combined treatment
2. Asymmetry

Topic: Interdisciplinary approach (邱上珍醫師)

Module 10 - 10/13 (A班) | 12/1 (B班)

1. Minor surgeries in orthodontics
2. Digital orthodontics

Topic: Ortho-viewed interdisciplinary treatment (徐重興醫師)

Module 11 - 11/10 (A班) | 12/15 (B班)

1. Aligner & TADs
2. Keys to aligner learning

Topic: Pre-aligner treatment (林詩詠醫師)

▲ Special lecture: 1:30-2:30 pm

時間：週四全天 (9 am - 5 pm)

地點：金牛頓藝術科技 (新竹市建中一路 25 號 2 樓)

費用含課程視訊、iPad、課程電子書與材料。

報名專線 湧傑 Yong Chieh

北區 邵美珍

02-27788315 #120

中區 張馨云

04-23058915

南區 蔡淑玲

07-2260030



LINE@
官方帳號

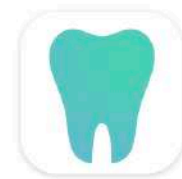

Facebook
官方帳號

e-Courses

A rich learning experience

Never have enough time to pursue continuing education? Want to review those amazing cases and practical tips of Dr. Chris Chang? You can now take the internationally renowned expert in Damon and TADs with you on the go and learn anywhere, anytime. The video course series feature excellently finished cases, live narration recordings, and stunning visuals are your best learning source in dentistry.



iOS / Android

+ Free App

Beethoven Dental Encyclopedia

Series Each video course are valid for 3 years



Damon Master



E-Lecture



OBS (TAD)



Finishing
(12 seasons)



Implant Forum
(9 seasons)




Assistant



E-Ortho



E-Implant



E-Pedo


Note:

1. Most video courses are available in both English and Chinese and are sold separately.
2. Damon Master and OBS (TAD) are renewed annually and each renewal is to be purchased separately with a 50% discount.

e-Books

Learn it your favorite way!

Best of all



+ BUY BOOK

This book requires iBooks 3.0 or later and iOS 5.0 or later.

The World's Best e-Textbook

Beethoven Dental Encyclopedia e-Books collection

Beethoven Orthodontic and Implant Group has been publishing the International Journal of Orthodontics and Implantology since 2007. This Journal features excellently finished case reports evaluated by objective grading systems.

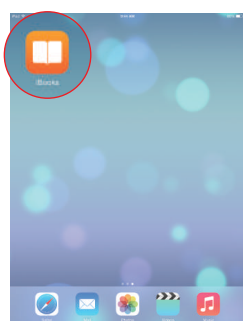
The Orthodontics and Implant Dentistry eBook series is a special selection of exciting cases with interactive functions and multimedia resource. Once opening this book, your understanding of dentistry will never be the same!

Now available in **iBooks Store** in **51** countries:

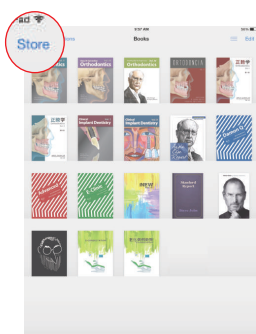
Argentina, Australia, Austria, Belgium, Bolivia, Brazil, Bulgaria, Canada, Chile, Colombia, Costa Rica, Cyprus, Czech Republic, Denmark, Dominican Republic, Ecuador, El Salvador, Estonia, Finland, France, Germany, Greece, Guatemala, Honduras, Hungary, Ireland, Italy, Japan, Latvia, Lithuania, Luxembourg, Malta, Mexico, Netherlands, New Zealand, Nicaragua, Norway, Panama, Paraguay, Peru, Poland, Portugal, Romania, Slovakia, Slovenia, Spain, Sweden, Switzerland, United Kingdom, United States, and Venezuela.



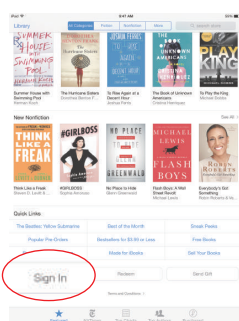
Step-by-step Instructions



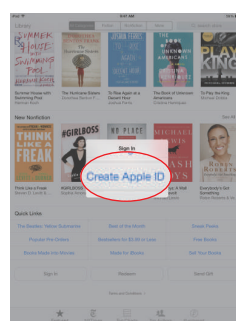
1. Launch "iBooks" app on your iPad.



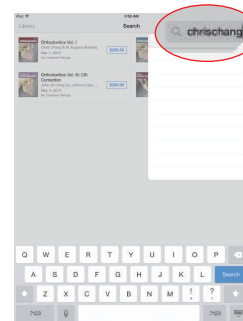
2. Click "Store."



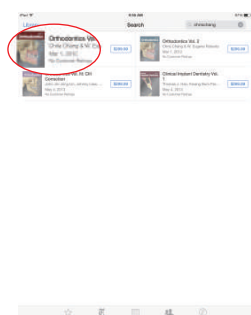
3. "Sign in" with your Apple ID.



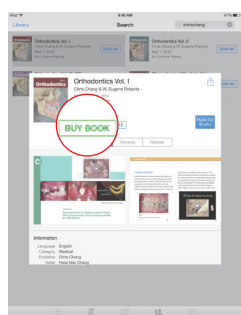
4. "Create Apple ID" if you don't have one.



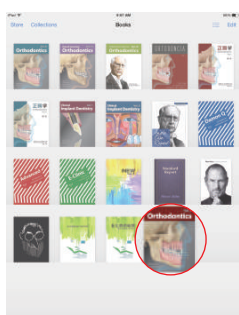
5. Search for "chrischang."



6. Click the book's icon.



7. Check the price and click "BUY BOOK."



8. Once downloaded, click the book's icon to launch the e-book and enjoy.

If you are interested in our paid video or medical products, contact inewton.dental@gmail.com for more information.

+886-3-573-5676

orthobonescrew.com

iNewton

Chapter 5. Maximizing Spaces and Resources

– Building a Rooftop Putting Green

“Golf is about how well you accept, respond to, and score with your misses much more than it is a game of your perfect shots.”

– Dr. Bob Rotella



Have you ever thought about what your dream house would look like? For Dr. Chris Chang, the answer lies in maximizing all available spaces and turning them into something that can be enjoyed. For example, most Taiwanese households have a rooftop deck; however, apart from hosting a water tank, very few people actually make use of them, let alone know how to have fun with them.

When it comes to making the best use of your rooftop space, the single most crucial key (and we cannot emphasize this more in this lifestyle series - see also Chapters 2 and 3 on building a rooftop garden and a rooftop aviary) is waterproofing and drainage. Dr. Chang always says “no over-retention of water means no leaking!” (不積水，就不漏水！) This is especially true when designing a golf green with artificial turf, as there are no plants to help absorb any excessive moisture in the base structure. Therefore, instead of the regular one layer, two layers of drainage trays (10cm thick in total) were used in addition to coats of waterproofing for extra draining ability and air circulation at the bottom.

Next, to create various terrains to accommodate 5 different putting holes, it was important that the base formation was not subject to any changes due to depletion from heavy rain or strong winds. The base mixture of gravel and sand had to be compressed as much as possible using a water compactor. As its name suggests, a water compactor relies on water to achieve the desired density and strength; however, once emptied the tool can still be carried and moved around with ease. It took the construction team one whole day just to make sure the base had been completely compacted! Then, it was time to plant some greens, or, to be more exact, artificial greens!

A special technique was used to keep the artificial turf in place. Once the turf patches had been paved over the base structure, fine sand was scattered all over the turf (Fig. 1). The whole area was brushed through with a bristle brush so the fine sand could spread more evenly, and another round of the compaction procedure was carried out to push the sand from the surface to the interface between the turf and the base mixture, securing the foundation of the turf and locking the two layers together. No adhesive was needed!

On the side of the putting green, a taller deck has been designed for chipping practice, as well as for occasional social events. This area connects two roofs, the current roof under discussion with a putting green and the roof with a wildlife garden (previously introduced in Chapter 2) hosting Dr. Chang's quails, as well as some newly arrived geese and Japanese bantam chickens. The turf here has been divided into two parts (Fig. 2). Around the edges, the turf patches



Fig. 1: Instead of any adhesive, fine sand was used to secure the turf patches in place. Fine sand is pushed to the interface between the artificial turf and the base structure to lock the two layers together.

have been glued to the bullet-proof glass underneath; at the center, two large turf patches have been simply laid on top of the glass as removable grassy 'curtains'. When closed, the turf curtains protect the glass during chipping practice, as well as providing comfort and a relaxed atmosphere when family and friends gather for a casual brunch or supper. When the grassy curtains are drawn back, natural sunlight is allowed to shine through the bullet-proof glass, under which is an enormous aviary that cleverly makes use of the space between the Changs' two houses (Fig. 3). The aviary not only further links the two houses together with built-in stairs and bridges, it also provides bird-lovers like Dr. Chang with a calming yet thought-provoking environment to either sit back and relax or sit tight to work.

What does your dream home look like? Perhaps now you have a different answer. Maximizing available spaces and resources demands that we stay inside the box while thinking outside of the box, which in




Fig. 2: On the side deck, artificial turf with longer grass was chosen, for one to provide a more realistic floor for chipping practice, and for another to create a relaxed atmosphere during social or family gatherings.



Fig. 3: Below the side deck is actually an enormous aviary which connects the Chang's two houses together. When the removable turfs are folded up, natural sunlight is allowed through the bullet-proof glass underneath.



Fig. 4: Apart from its functional purpose, the golf green is a perfect venue for casual gatherings where family and friends enjoy some golf practices while snacking on some light meals. The atmosphere is especially relaxing at dawn!

itself sounds very much like Orthodontics, does it not? With a certain set of tools and mechanics, doctors maximize the combined effect of each factor to treat various types of cases. Neither Orthodontics nor space-designing is a matter of reaching perfection, but something that requires us work with what we have and constantly respond to all changes, both predictable and unpredictable.

When re-reading the quote at the beginning this article, it could be construed that golf may also be a very similar type of game. Ever wondered why Dr. Chang has so many different interests? :)

Desk editor of JDO & a wildlife enthusiast*

Annie Chen

*Title bestowed by Dr. Chris Chang



Fig. 5: The Chang family are the biggest fans of their new rooftop golf green! Having breakfast up on the side deck is one of their favorite ways to start a day.



Fig. 6: Much like orthodontics and space-designing, golf is a game of responding to all changes, both predictable and unpredictable. Therefore, accumulation of experience is as crucial as, if not more important than, natural gift.



Fig. 7: From a bird's eye view, the structure linking the two roofs are clearly shown. At the top of the photograph is the wildlife garden rooftop, the bottom half is the newly built artificial putting green, and the section in-between is securely connected by a layer of bullet-proof glass, supported by solid metal pillars underneath.

Along with built-in bridges and stairs, the whole design allows easy access not only to the rooftops, but also throughout the indoor spaces in the Chang's two houses, whichever house one is in and wherever in the houses one is at.



Fig. 9: With living greens and vivid flowers thriving in the surroundings, the artificial turf seems very much brought to life.

Fig. 8: The rooftops are not merely for the human residents to enjoy. An abundant amount of space and designs are preserved for the Chang's feathered companions to have their own fun, too!





"From this book we can gain a detailed understanding of how to utilize this ABO system for case review and these challenging clinical cases from start to finish."

Dr. John JJ Lin, Taipei, Taiwan

"I'm very excited about it. I hope I can contribute to this e-book in someway."

Dr. Tom Pitts, Reno, Nevada, USA

"A great idea! The future of textbooks will go this way."

Dr. Javier Prieto, Segovia, Spain

"No other book has orthodontic information with the latest techniques in treatment that can be seen in 3D format using iBooks Author. It's by far the best ever."

Dr. Don Drake, South Dakota, USA

"Chris Chang's genius and inspiration challenges all of us in the profession to strive for excellence, as we see him routinely achieve the impossible."

Dr. Ron Bellohusen, New York, USA

"This method of learning is quantum leap forward. My students at Oklahoma University will benefit greatly from Chris Chang's genius."

Dr. Mike Steffen, Oklahoma, USA

"Dr. Chris Chang's innovation eBook is at the cutting edge of Orthodontic Technology... very exciting!"

Dr. Doraida Abramowitz, Florida, USA

"Dr. Chang's technique is absolutely amazing and cutting-edge. Anybody who wants to be a top-tiered orthodontist MUST incorporate Dr. Chris Chang's technique into his/her practice."

Dr. Robert S Chen, California, USA

"Dr. Chris Chang's first interactive digital textbook is ground breaking and truly brilliant!"

Dr. John Freeman, California, USA

"Tremendous educational innovation by a great orthodontist, teacher and friend."

Dr. Keyes Townsend Jr, Colorado, USA

"I am awed by your brilliance in simplifying a complex problem."

Dr. Jerry Watanabe, California, USA

"Just brilliant, amazing! Thank you for the contribution."

Dr. Errol Yim, Hawaii, USA

"Beyond incredible! A more effective way of learning."

Dr. James Morrish Jr, Florida, USA



In April, the Damon Master program started a new round, with 37 young dentists participating in the first of the two batches of class 2022. Dr. Chang's beloved pet, Bagel the monk parakeet, is now a frequent visitor of the classes.