



Dental Products

Must-Have Secret Weapons

Autoclavable

Double Retractors 2.0

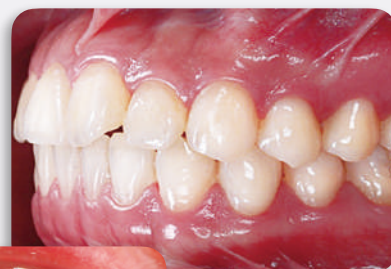Double Retractors x2, Black Board x2

While keeping the same lip & cheek two-way design, the new Double Retractors 2.0 is upgraded to medical grade PPSU.

NEW

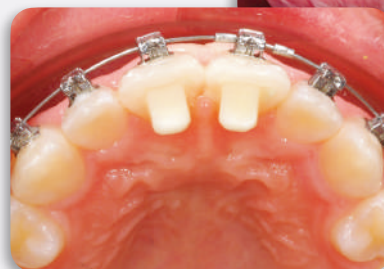Stainless Steel Mirror 2.0

Strong, durable stainless steel, autoclave-proof, the specially designed size, improved shape and thickness ensure maximum intra-oral view without sacrificing patient comfort.

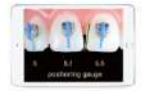

Bite Turbo 3.0

Handle x1, BT molds x6, BT extended molds x6, Button molds x6
Designed by Dr. Chris Chang, the new Bite Turbo 3.0 allows you to solve all kinds of deep bite and large horizontal overjet. A simple and powerful tool you should add to your kit!



2023 一年一度 預報享優惠價 Damon Master Program



全新改版的 2023 年貝多芬高效 Damon 矯正大師系列課程，是由國際知名講師張慧男醫師親自規劃及授課，課程特色強調由臨床病例帶動診斷、分析、治療計畫擬定與執行技巧，本年度亦特別加入最新的數位矯正與隱形牙套的內容，並邀請了貝多芬牙科集團各院院長演講特別矯正專題。

此外，透過數位影片反覆觀看，結合矯正與電腦教學，課堂助教協助操作，讓學員在短時間能快速上手，感染「熱愛矯正學，熱愛學矯正」的熱情。

名額有限，一年僅有一次機會在台完整體驗 Damon 矯正大師課程，錯過只能等明年囉！

Module 1 - 4/13

1. Selecting your ideal first case
2. Bonding position
3. Bonding + BT + cephal tracing
4. TADs + space closing + hook + spring
5. Finishing bending & fixed retainer

Practice: Clinical photography (黃亭雅, 陳韻如醫師)

Module 2 - 5/11

1. Four stages of efficient orthodontic treatment
2. Simple and effective anchorage system
3. Extraction vs. non-extraction analysis

Practice: Patient photo management (金牛頓工程師)

Module 3 - 6/8

1. Soft & hard tissue diagnostic analysis
2. Big overjet correction
3. Damon diagnosis & fine-tuning

Practice: Ceph tracing (金牛頓工程師)

Module 4 - 6/29

1. Excellent finishing
2. Retention & relapse

Practice: Ceph superimposition & measurement (金牛頓工程師)

Module 5 - 7/13

1. Simplify your system
2. Extraction vs. non-extraction

Practice: Case report demo (陳俊宏醫師)

▲ Computer training (Mac): 1:30-3:00 pm

時間：週四全天 (9 am - 5 pm)

地點：金牛頓藝術科技 (新竹市建中一路 25 號 2 樓)

費用含課程視訊*、iPad、課程電子書與材料。

*贈送之課程視訊提供兩年時間串流觀看。

報名專線 湧傑 Yong Chieh

北區 邵美珍

02-27788315 #120

中區 張馨云

04-23058915

南區 蔡淑玲

07-2260030

Module 6 - 7/27

1. Class III correction
2. Class II correction

Topic: Early orthodontic treatment (曾淑萍醫師)

Module 7 - 8/10

1. Upper impaction
2. Lower impaction
3. Gummy smile correction

Topic: Modified VISTA (蘇荃璋醫師)

Module 8 - 8/24

1. ABO DI, CRE workshop (林彥君醫師)
2. Open bite

Topic: Modified 2X4 appliance in ortho treatment (徐玉玲醫師)

Module 9 - 9/7

1. Implant-ortho combined treatment
2. Asymmetry

Topic: Impacted cuspid treatment (張譚文, 張瑜珍, 黃亭雅, 陳韻如醫師)

Module 10 - 9/21

1. Minor surgeries in orthodontics
2. Digital orthodontics

Topic: Ortho-viewed interdisciplinary treatment (徐重興醫師)

Module 11 - 9/28

1. Aligner & TADs
2. Keys to aligner learning

Topic: Pre-aligner treatment (林詩詠醫師)

▲ Special lecture: 1:30-2:30 pm



LINE@
官方帳號



Facebook
官方帳號

Premolar Substitution of Missing Canine with Crowding and Midline Deviation

Abstract

History: A 29-year-old female presented with chief complaints of crooked teeth and crowding.

Diagnosis: Lower facial height, convexity, and lip protrusion were within normal limits. Bimaxillary retrusion (SNA, 76°; SNB, 73°; ANB, 2.5°) and a high mandibular angle (SN-MP, 42.7°) were noted. Both upper and lower incisors were within normal limits (U1 to SN, 102°; U1 to NA, 5.5mm; L1 to MP, 95.1°; L1 to NB, 4mm). In the right buccal segment, the molars were Class I, but the upper right canine and the upper left first molar were missing. There was >10mm of crowding in the lower arch, and the upper dental midline was shifted 4mm to the right. The Discrepancy Index was 23.

Treatment: Following extraction of two mandibular first premolars, all teeth were bonded with a Damon Q® passive self-ligating bracket system. An infrazygomatic crest bone screw was inserted buccal to the upper left second molar. A power chain applied to the upper arch corrected the midline deviation and closed the upper left first molar extraction space. In addition, premolar substitution for the missing upper right canine was performed. Both arches were detailed and finished.

Outcome: After 29 months of active treatment, all teeth were aligned, and all extraction spaces were closed. The upper right first premolar was substituted for the missing upper right canine. The midline discrepancy was corrected to 1mm after the active treatment. The final alignment and dental esthetics were satisfactory as evidenced by an ABO Cast-Radiograph Evaluation score of 12, and the IBOI Pink & White Esthetic Score of 4. Both the patient and the clinician were satisfied with the final outcome.

Conclusions: Missing canines usually have a history of ectopic eruption, impaction, or trauma. Premolar substitution is an attractive treatment option, but may result in substantial midline deviation. Orthodontic bone screws play an important role in correcting midline deviation with asymmetric mechanics. (*J Digital Orthod* 2023;69:30-45)

Key words:

Midline deviation, premolar substitution, IZC bone screw, asymmetric mechanics, temporary skeletal anchorage devices (TSADs), passive self-ligating brackets

Introduction

The dental nomenclature for this report is a modified Palmer notation with four oral quadrants: upper right (UR), upper left (UL), lower right (LR), and lower left (LL). From the midline, permanent teeth are numbered 1-8.

The management of midline deviation resulting from unilaterally missing teeth is challenging. In the treatment of midline correction, bone screws play an essential role for asymmetric mechanics. This case

report demonstrates the combined use of passive self-ligating (PSL) brackets, bone screws (BSs), premolar substitution, and extractions for a desirable treatment outcome.

History and Etiology

A 29-year-old female sought orthodontic consultation due to unesthetic maxillary anterior dentition and crooked teeth (Fig. 1). No contributing medical or dental histories were reported. Clinical examination revealed a straight

Maurice Huang,

Training Resident, Beethoven Orthodontic Center (Left)

Joshua S. Lin,

Associate Director, Beethoven Orthodontic Center (Center left)

Chris Chang,

Founder, Beethoven Orthodontic Center

Publisher, Journal of Digital Orthodontics (Center right)

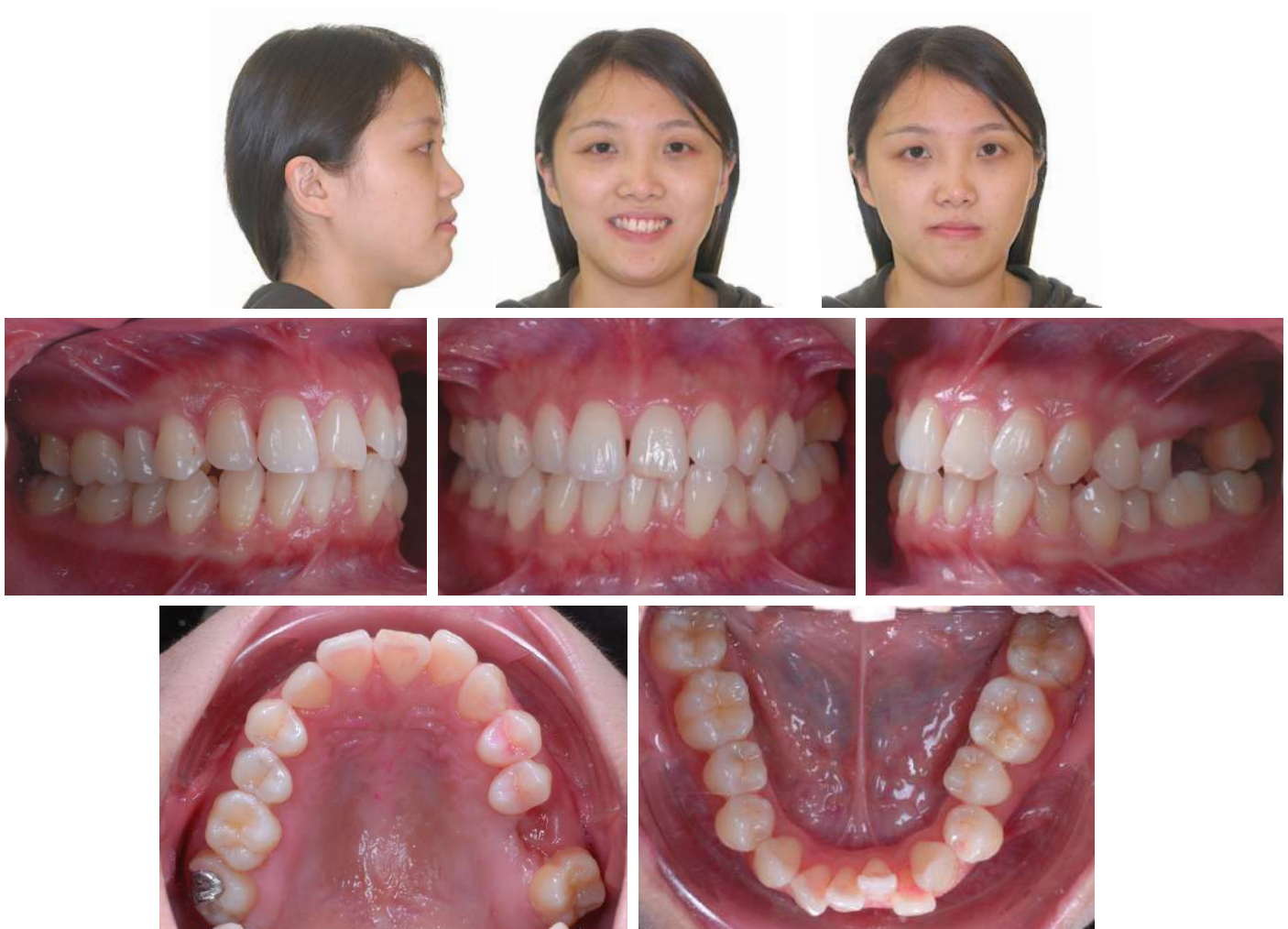W. Eugene Roberts,

Editor-in-chief, Journal of Digital Orthodontics (Right)



facial profile. Overbite and overjet of the central incisors were within normal limits (WNL), and the right buccal segment was Class I. The upper midline was shifted 4mm to the right (Fig. 2). The UR3 was missing, and the space was closed by drift of adjacent teeth; the UL6 was also missing (Fig. 3).

There was >10mm of crowding in the lower arch. The panoramic and lateral cephalometric radiographs revealed impaction of lower third molars (Figs. 4 and 5).



■ Fig. 1: Pre-treatment facial and intraoral photographs

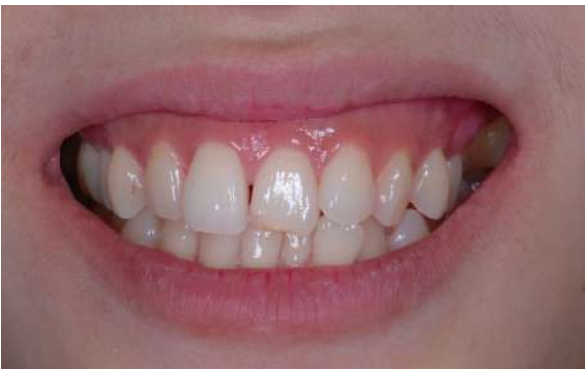Diagnosis

Facial:

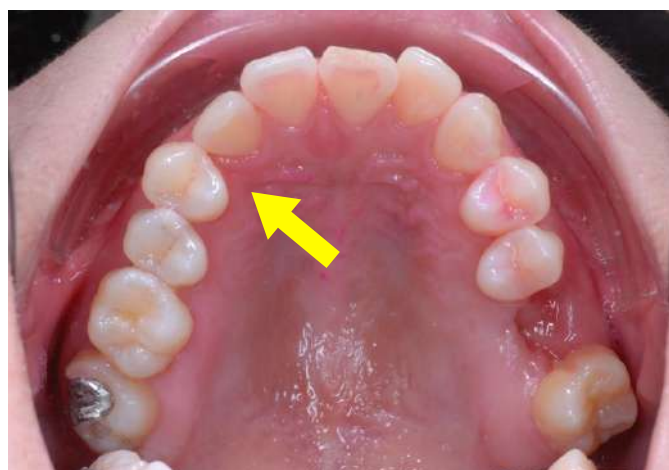- Convexity: WNL (12°)
- Lip Protrusion: WNL (-1.5mm/0mm to the E-line)

Skeletal:

- Sagittal Relationship: Class I relationship (SNA, 76° ; SNB, 73.5° ; ANB, 2.5°)



■ Fig. 2: Pre-treatment upper midline was shifted 4mm to the right.



■ Fig. 3: Pre-treatment upper occlusal shot shows the missing UR3 space (yellow arrow) was completely closed by the adjacent teeth. UL6 extraction space was also noted.

- Mandibular Plane Angle: Increased (SN-MP, 42.5° ; FMA, 28.5°)

Dental:

- Occlusion: Class I molar in the right segment
- Overjet: 1mm
- Upper incisor: WNL (U1-NA, 5.5mm; U1-SN, 102°)
- Lower incisor: WNL (L1-NB, 4mm; L1-MP, 95°)

The American Board of Orthodontics (ABO) Discrepancy Index (DI) was 23, as documented in the supplementary Worksheet 1.

Treatment Objectives

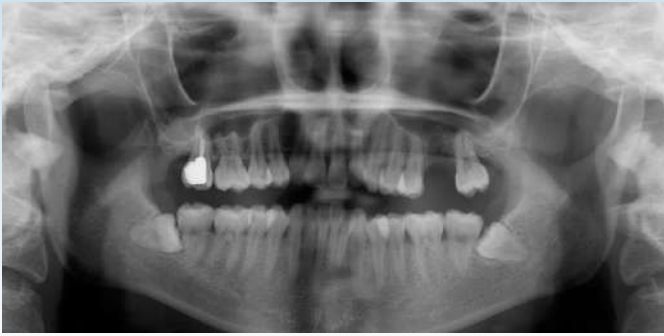1. Correct the midline discrepancy.
2. Close missing UR3 and UL6 extraction spaces.
3. Relieve crowding.

Treatment Alternatives

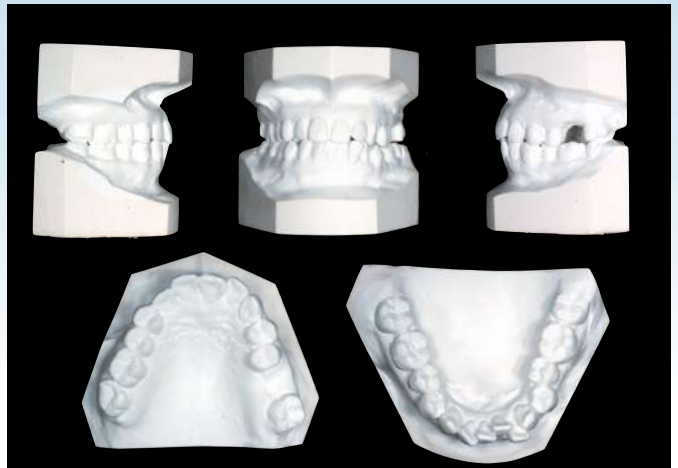
The objectives for full-fixed appliance treatment were to resolve the missing UR3, close the UL6 space, align the dentition, and correct the midline. Two options were considered:

Option 1 (Fig. 7): Extract two lower 1st premolars. Insert an infrazygomatic (IZC) bone screw on the left buccal side to provide definite anchorage to solve the midline deviation. Substitute the upper right premolar for the missing UR3.

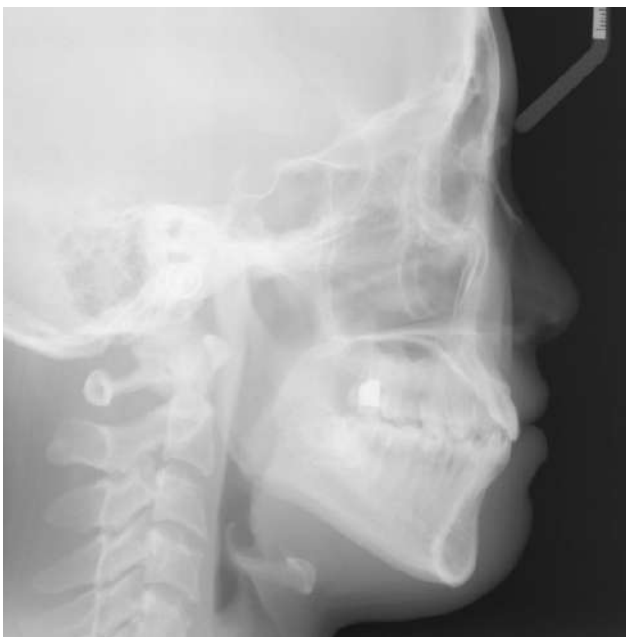Extraction of lower first premolars corrects crowding relief and facilitates upper midline correction. An IZC



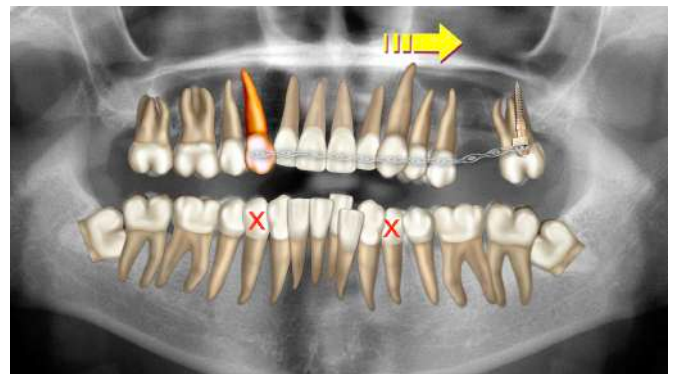
■ Fig. 4: Pre-treatment panoramic radiograph



■ Fig. 6: Pre-treatment dental models (casts)



■ Fig. 5: Pre-treatment lateral cephalometric radiograph



■ Fig. 7:
Treatment option 1. Note the substitution of UR4 (orange) for the missing UR3. See text for details.

bone screw is placed in the UL segment to correct the midline deviation.

Option 2 (Fig. 8): Extract two lower 1st premolars. Open the space between UR2 and UR4, and restore UR3 and UL6 with dental implants.

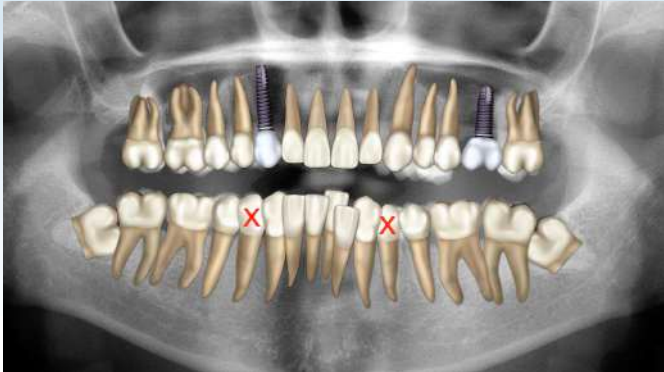
To deal with the missing teeth, place an open coil spring to create UR3 space, and maintain the UL6 extraction space for dental implants. Extract lower first

premolars to relieve crowding. Compromised dental esthetics and function are to be expected.

The patient refused implant-supported prostheses because of higher risk of complications and cost. After a thorough discussion of the two options, the patient preferred the first approach.

Treatment Progress

A 0.022-in slot Damon Q® fixed appliance (Ormco, Glendora, California) with PSL brackets was selected along with all specified archwires and orthodontic auxiliaries.



■ Fig. 8: Treatment option 2. See text for details.

The patient was referred to extract the LR4 and LL4 prior to active treatment. Damon Q® 0.022-in PSL brackets (Ormco, Glendora, CA) were bonded on the upper teeth with a 0.014-in CuNiTi archwire engaged. 1 month later, the lower dentition was also bonded with PSL brackets.

After 6 months, alignment of both arches was completed. Both archwires were changed to 0.016x0.025-in SS for space closure.

In the 12th month, an OrthoBoneScrew® (OBS, iNewton Dental Inc., Hsinchu City, Taiwan) was inserted in the left IZC. As a definite anchorage device, the IZC bone screw facilitated space closure of UL6 extraction site and midline correction (Fig. 9).

In the 16th month, the UL6 extraction space was closed and the midline deviation was significantly improved (Fig. 10).

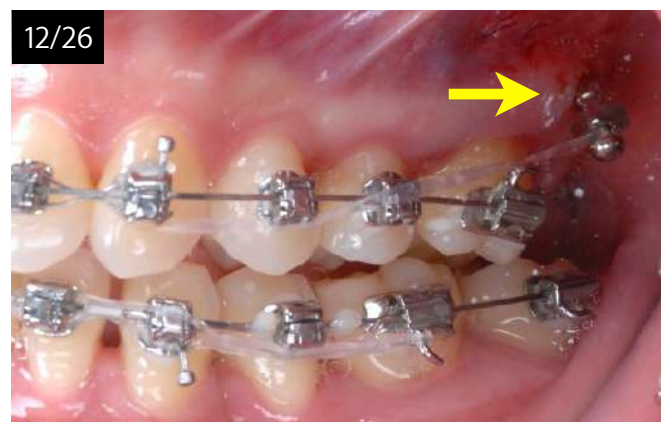
In the 19th month, the lower extraction spaces were almost closed. A residual midline deviation remained but was WNL.

All fixed appliances were removed after 26 months of active treatment. All extraction spaces were closed. Retention was accomplished with upper and lower clear overlay retainers. Also, a lingual fixed retainer was constructed on the mandibular anterior segment (LR3-LL3).

Results Achieved

Facial esthetics and dental alignment were significantly improved after 26 months of treatment (Figs. 11 and 12). The midline deviation was corrected to an acceptable result. The missing canine (UR3) was replaced by the first premolar (Fig. 11). The UL6 extraction space was closed with a molar Class III relationship on the left and Class I on the right. The posttreatment panoramic radiograph documented acceptable root parallelism, except for LR5, UL5, and UL7 (Fig. 13).

The superimposed cephalometric tracings illustrated that both lower 1st molars were protracted due to closing of the extraction space



■ Fig. 9: An OBS (yellow arrow) was inserted in the IZC, and a power chain was attached from the OBS to the UL4 to correct midline deviation.

with elastic force (Fig. 15). The axial inclination of the upper incisors (U1-SN) decreased 11° (105° to 94°), but the lower incisors (L1-MP) were inevitably tipped lingually (95° to 84°). The upper and lower lips were both retruded following retraction of the anterior segments. The mandibular plane angle (SN-MP) was well-maintained (Table 1).

The Cast-Radiograph Evaluation (CRE) score was 12 points, as shown in the supplementary Worksheet 2. The Pink and White dental esthetic score was 4 points (Worksheet 3). The patient was pleased with the final result.

Retention

After the fixed appliances were removed, two ESSIX® (Dentsply Sirona, Harrisburg, PA) overlay retainers were provided to retain the leveling and alignment of the dentition. A fixed retainer was placed from canine to canine on the lower arch to prevent relapse of crowding. The patient was instructed to use the overlay retainers full time for the first month and only while sleeping thereafter.

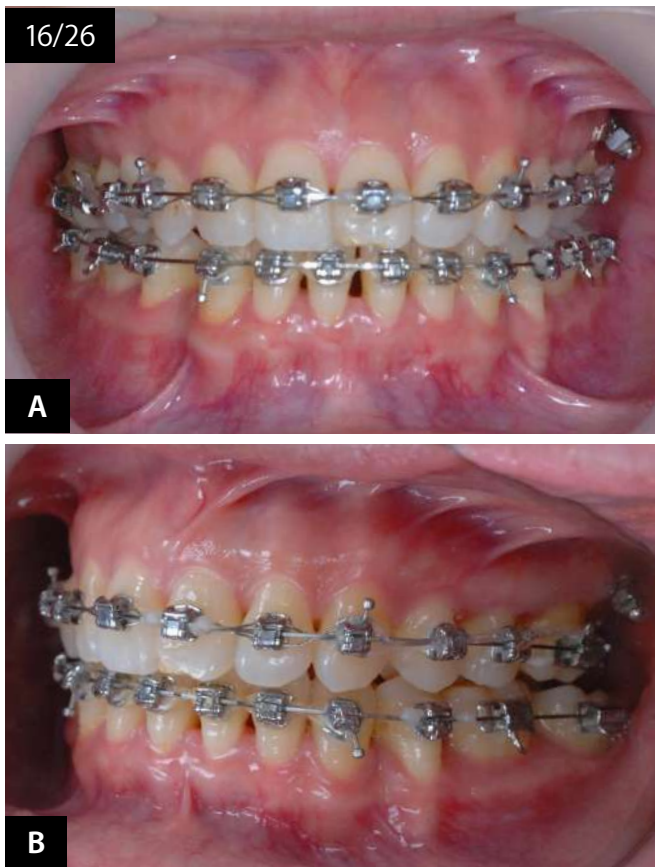


Fig. 10:
A. By the 16th month, midline deviation was improved.
B. UL6 extraction space was closed.

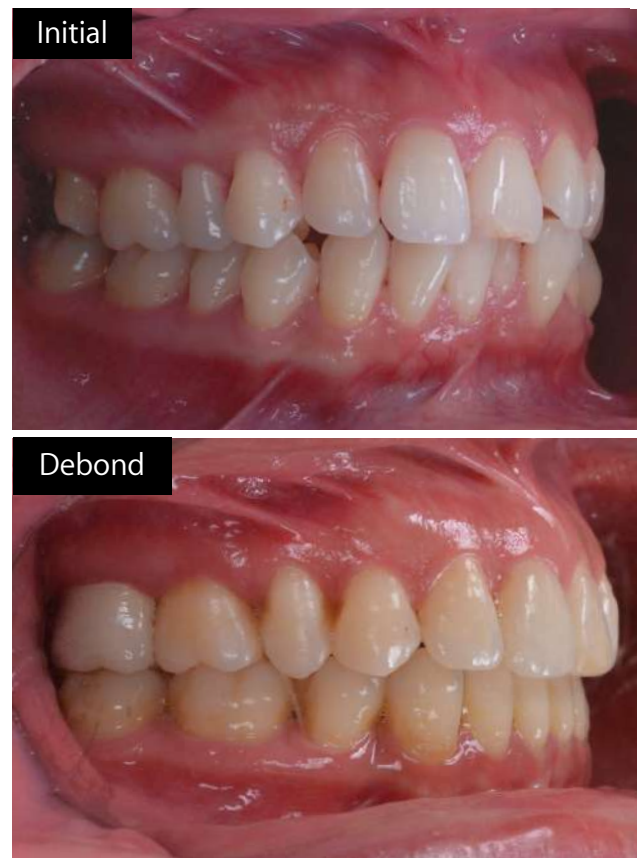
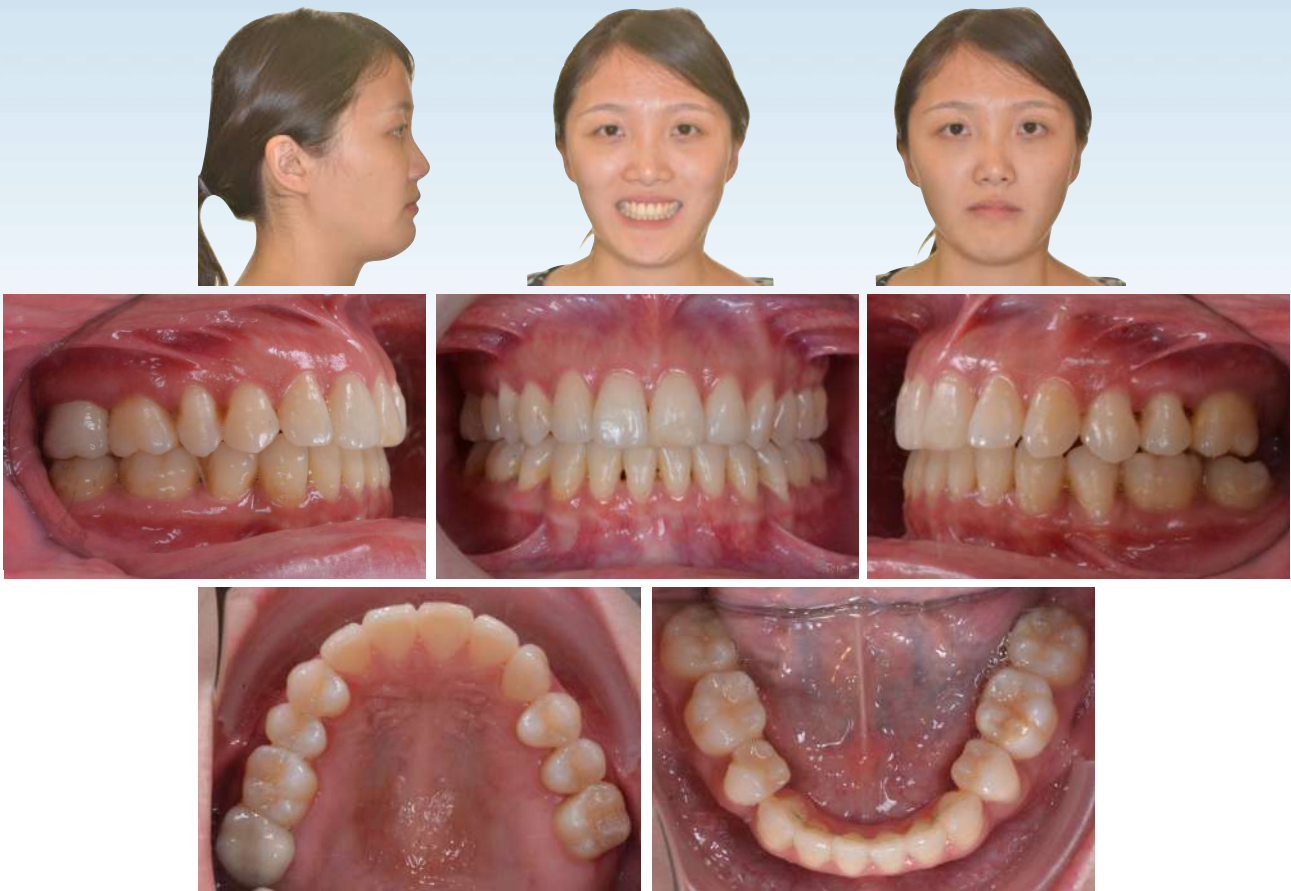
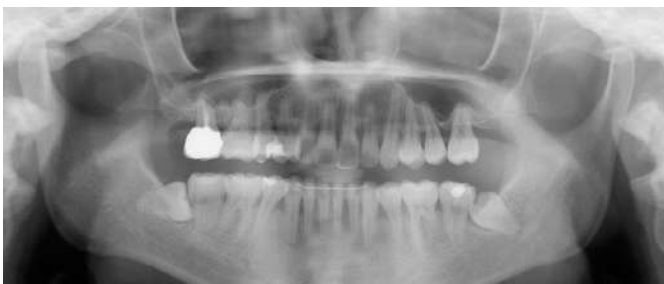Fig. 11:
 Premolar substitution resulted in a good outcome and acceptable occlusion on the right segment.



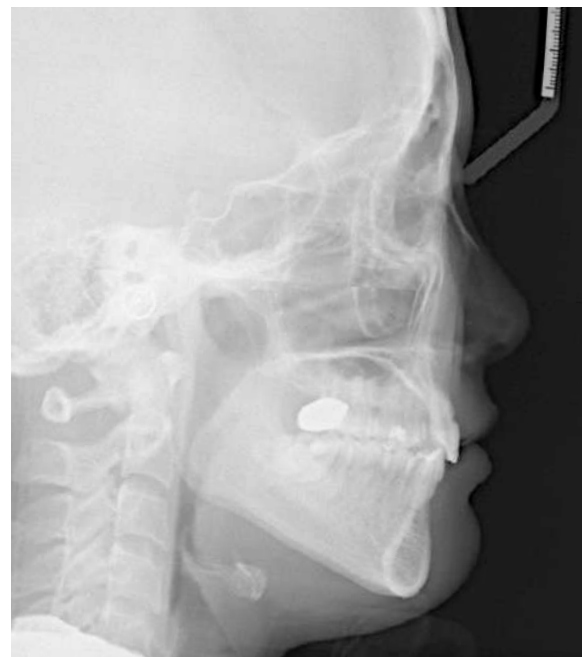■ Fig. 12: Posttreatment facial and intraoral photographs

Discussion

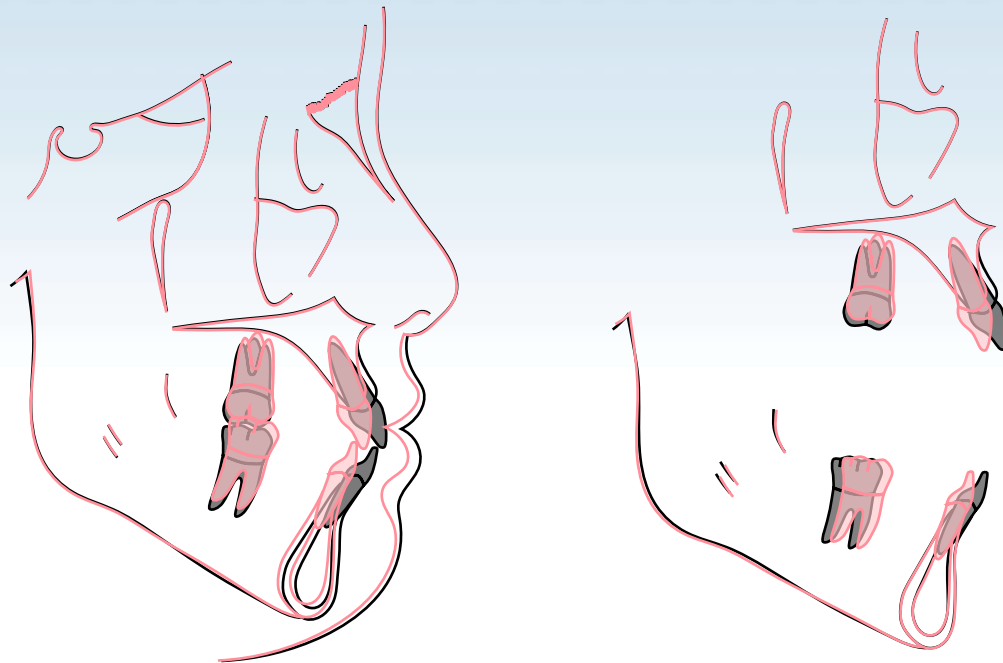
To correct midline deviation, asymmetrical mechanics with IZC bone screw anchorage is an excellent solution. In this case, the missing UR3 space was closed by substitution of the UR4, resulting in the midline shifting 4mm to the right.



■ Fig. 13: Posttreatment panoramic radiograph



■ Fig. 14: Posttreatment lateral cephalometric radiograph



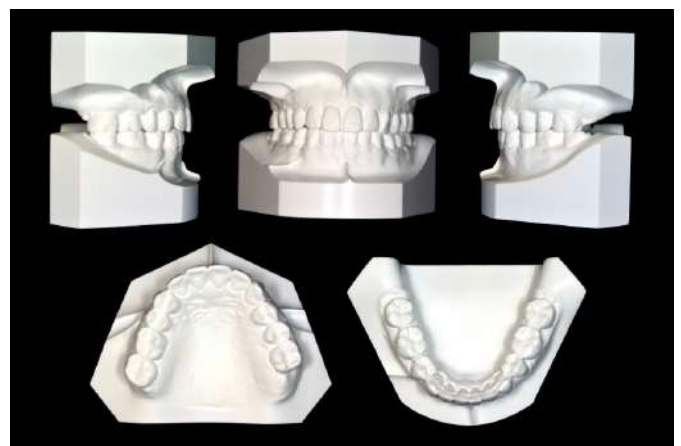
■ Fig. 15:

Initial (black) and final (red) cephalometric tracings are superimposed on the anterior cranial base (left), the skeletal structures of the maxilla (upper right) and the mandible (lower right).

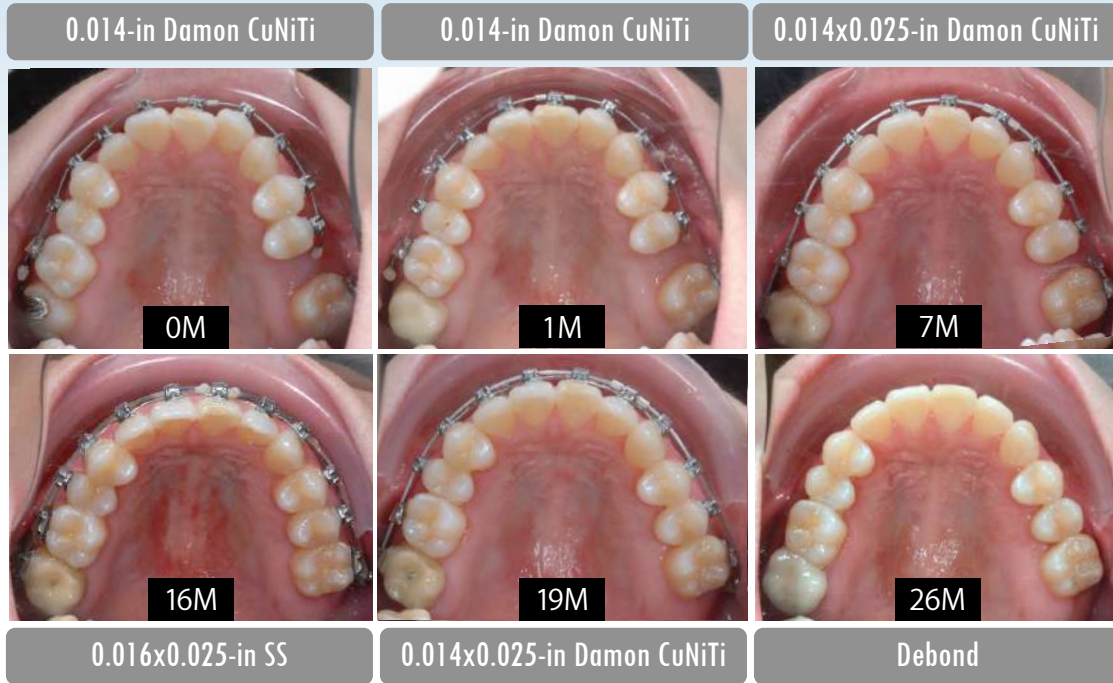
CEPHALOMETRIC SUMMARY			
SKELETAL ANALYSIS			
	PRE-TX	POST-TX	DIFF.
SNA° (82°)	78°	78°	0°
SNB° (80°)	76°	76°	0°
ANB° (2°)	2°	2°	0°
SN-MP° (32°)	41°	39°	2°
FMA° (25°)	37°	36°	1°
DENTAL ANALYSIS			
U1 TO NA mm (4 mm)	6	2	4
U1 TO SN° (104°)	105°	94°	11°
L1 TO NB mm (4 mm)	7	3	4
L1 TO MP° (90°)	95°	84°	11°
FACIAL ANALYSIS			
E-LINE UL (-1 mm)	-2	-3	1
E-LINE LL (0 mm)	0	-2	2
%FH: Na-ANS-Gn (53%)	56%	56%	0%
Convexity:G-Sn-Pg' (13°)	6°	6°	0°

■ Table 1: Cephalometric summary

Since the UL6 was extracted and there remained an extraction space, an IZC bone screw was placed buccal to UL7 to correct the maxillary dentition shift and simultaneously close the UL6 extraction space. However, another issue was lower dentition crowding; therefore, LR4 and LL4 were extracted to relieve the anterior crowding. By the end of the

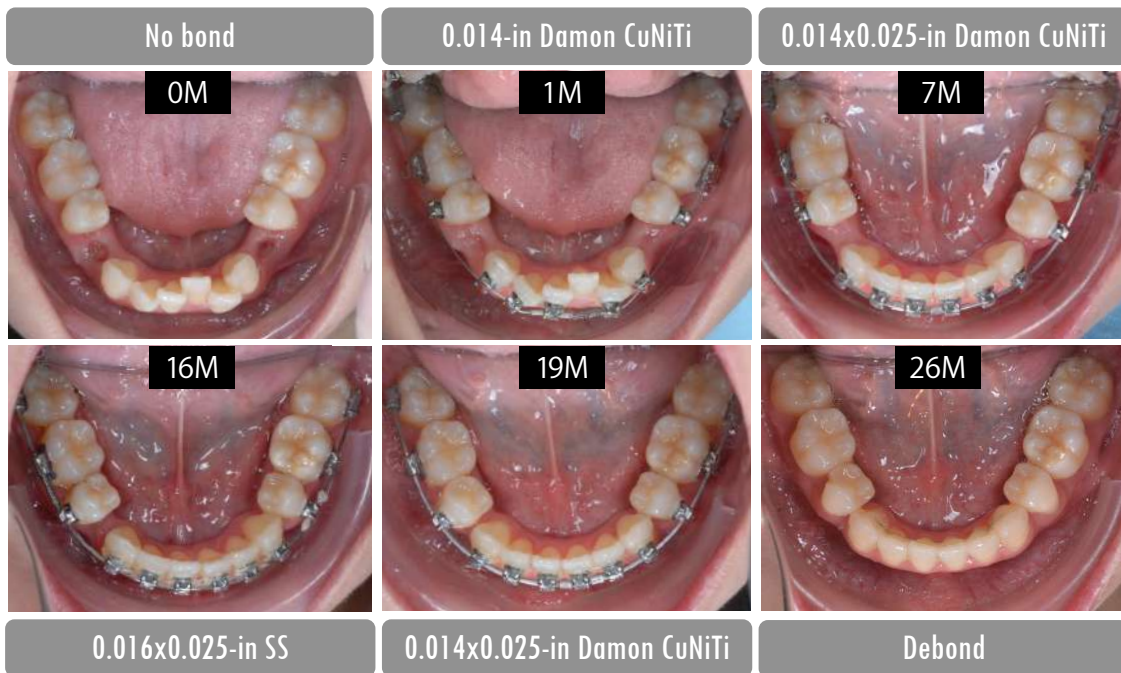


■ Fig. 16: Posttreatment dental models (casts)



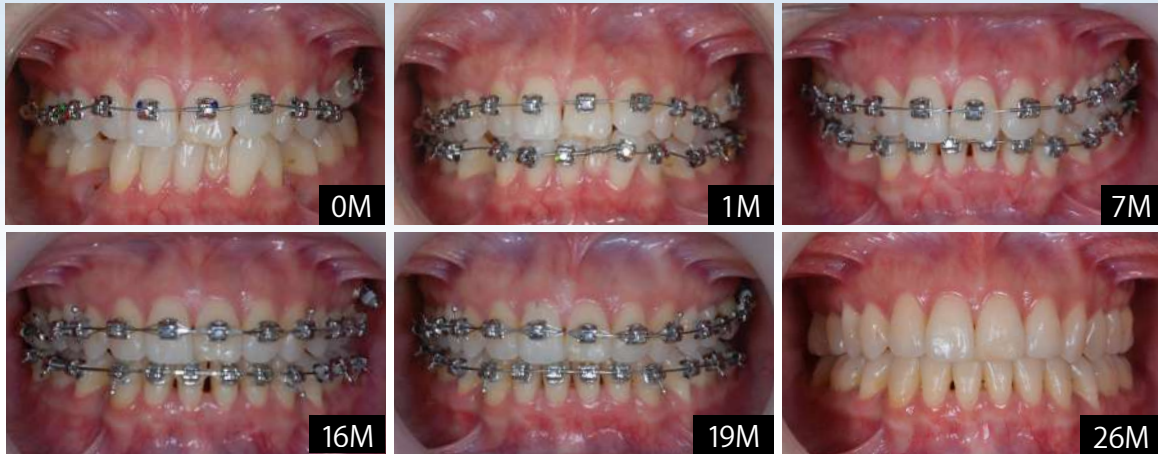
■ Fig. 17:

Treatment progress for the upper arch from the maxillary occlusal view is shown in months (M), and the archwire progression is specified from the start of treatment (0M) to twenty-six months (26M).

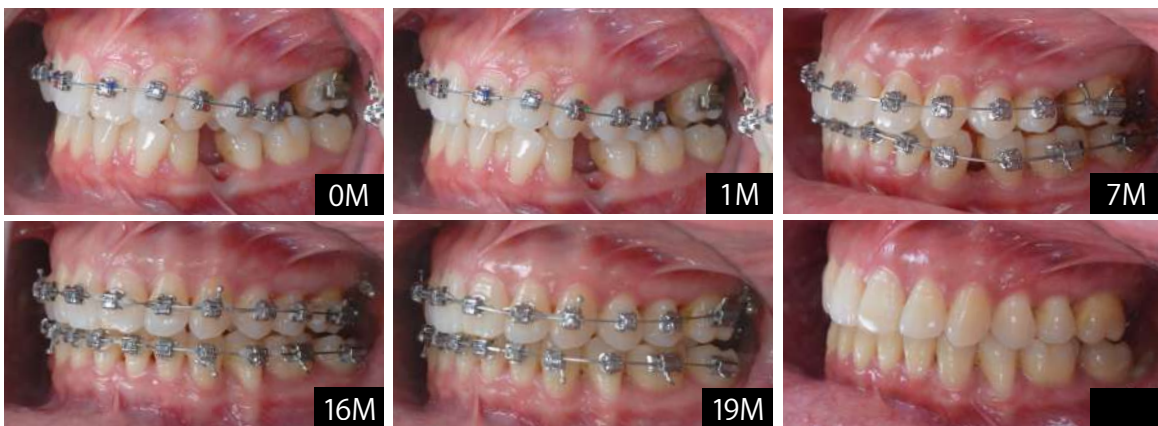


■ Fig. 18:

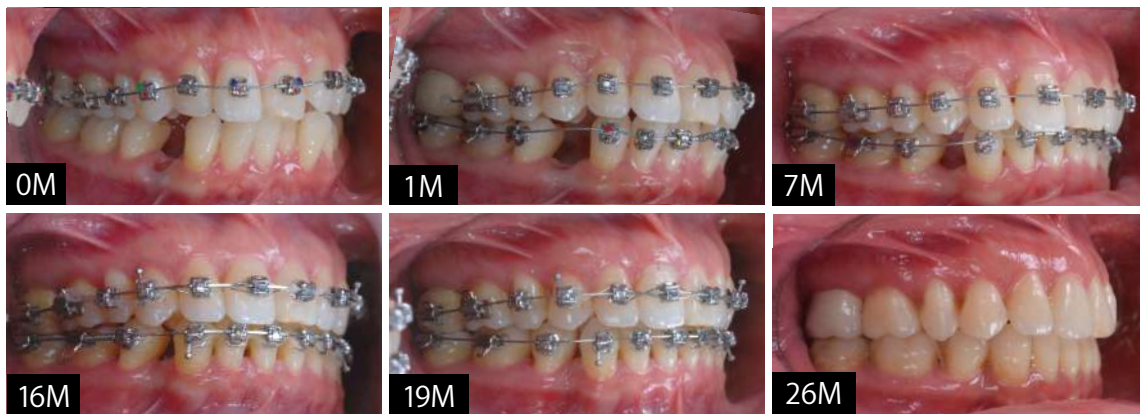
Treatment progress for the lower arch from the mandibular occlusal view is shown in months (M), and the archwire progression is specified from the start of treatment (0M) to twenty-six months (26M). Note that the lower first premolars were extracted prior to active treatment.



■ Fig. 19: Treatment progress from the frontal view. Midline discrepancy was corrected to an acceptable result.



■ Fig. 20: Treatment progress from the left buccal view. An IZC bone screw was placed at the buccal side of UR7 to correct midline and close UL6 extraction space. Class III molar relationship was achieved for the left segment.



■ Fig. 21: Treatment progress from the right buccal view. Premolar substitution was performed. Good occlusal relationship was achieved after 26 months of treatment.

treatment, the 4mm midline deviation was improved to 1mm (Fig. 19).

IZC bone screws

IZC bone screws are placed buccal to the roots of the maxillary molars, which provides extra-radicular anchorage for retraction of individual teeth or the entire arch. This is a very effective anchorage for correcting midline deviations.^{1,2}

For the present patient, a single IZC bone screw provided firm anchorage for space closure and midline correction. The IZC screw was loaded and reactivated every month with pre-stretched power chains.³ The power chains were tied to the maxillary anterior teeth in order to rectify the midline deviation and close the UL6 space. However, when closing molar extraction space there are several concerns regarding the maxillary sinus floor.

Moving teeth through the floor of maxillary sinus

Moving teeth through the floor of the sinus is a viable clinical option based on physiological principles⁴ and is further supported by experimental studies.^{5,6} Park et al.⁵ reported that teeth can be moved through anatomic limitations, such as thin cortical bone or the maxillary sinus.

The maxillary sinus floor is a hard, high-density bone similar to the cortical bone.⁷ Furthermore, it takes more time to achieve bone remodeling at the maxillary sinus floor, compared with the cancellous bone. The above factors explain orthodontic tooth movements and treatment outcomes.

With dental root penetration into maxillary sinus, several features can be observed during orthodontic tooth movement, such as moderate apical root resorption,⁸ considerable tipping,⁵ abnormal pulp vitality, and perforation of the sinus membrane.⁹ While facing the clinical cases with sinus penetration, the orthodontists should carefully modify the orthodontic force system to reduce these side effects⁷ and recognize that even a light constant force moves teeth through the sinus floor.

Bodily movement is generally expected but is difficult to achieve in such cases. In the article of Wehrbein et al.,⁵ the authors stated that bodily or tipping movement through the maxillary sinus depends on the morphology of the antrum. Furthermore, they demonstrated that in the orthodontic movements of the maxillary teeth, greater tipping could be accomplished if there is a more vertical extension of the basal maxillary sinus in front of the tooth to be moved than with teeth moved through a more horizontal maxillary sinus base.

For our patient, the UL6 extraction space was closed in 26 months. However, the panoramic radiographs demonstrated that UL5 was tipped due to the vertical extension of the maxillary sinus, which is consistent with previous studies.^{10,11}

Premolar substitution

Regarding the two main scenarios: firstly missing lateral incisors and secondly impacted canines, premolar substitution is a good solution. Missing maxillary lateral incisors affect 2~5% of the population.¹² Space closure is the preferred esthetic

option. The canine substitutes for the lateral incisor, and the first premolar fills the position of the canine.

The prevalence of impacted canines is reported to be from 0.27-2.4%,^{13,14} second only to third molars.¹⁵ In most patients, the impacted canines are ectopically positioned.¹⁶⁻¹⁸ In fact, there are many cases with missing canine due to ectopic impactions or previous anomalies. While treating this kind of situation, premolar substitution is a feasible solution if conditions allowed.

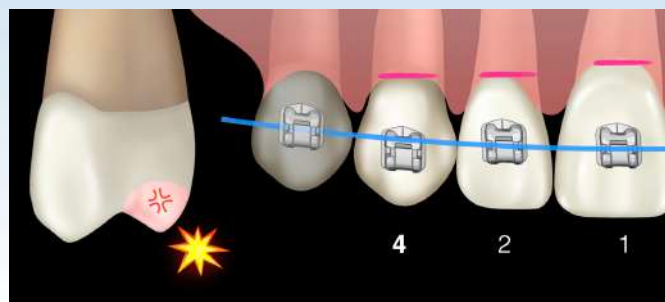
For this patient, the UR3 was missing, and the space was closed by the adjacent UR2 and UR4. Therefore, premolar substitution was an effective method to treat this problem. There are 2 important tips to note for premolar substitution:

1. Bonding position

For maxillary canine substitution, it is particularly important to restore the natural contours of the gingival margins. A high-low-high gingival margin from incisor to canine is the principle to be achieved with coordinated orthodontics. To improve the gingival emersion profile, the premolar can be intruded by a more incisal bracket position (Figs. 22 and 23). In addition, intruding the premolar can eliminate the palatal cusp interference.

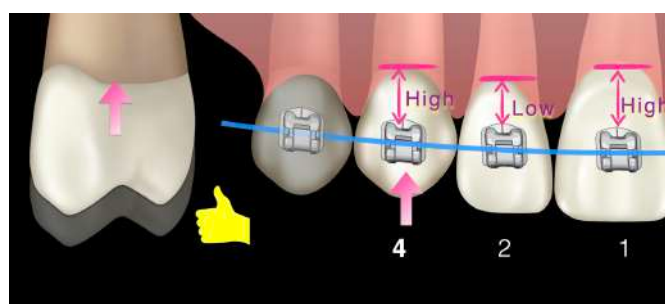
2. Size and shape

In comparison to the canine, the adjacent premolar has a similar buccal surface and dimensions at the cemento-enamel junction (CEJ) for both mesio-distal and bucco-lingual width. To simulate a maxillary canine, the outline form of the crown should be



■ Fig. 22:

In premolar substitution, gingival margin and palatal cusp interference are usually the problems. Premolar intrusion using incisal bracket position is recommended.



■ Fig. 23:

Intrude the premolar to achieve ideal gingival margins (high-low-high gingival line) and to avoid palatal cusp interference.

restored by composite resin at the buccal cusp tip to make it look like a natural canine from both frontal and buccal views.

Conclusions

Missing canines are often encountered due to ectopic impactions or previous anomalies. Premolar substitution is an attractive option.

Furthermore, midline deviation is a common orthodontic problem. Orthodontic bone screws play an important role in correcting midline deviations

with asymmetric mechanics. As bone screws enhance the treatment efficiency, they are becoming increasingly essential in modern orthodontics.

References

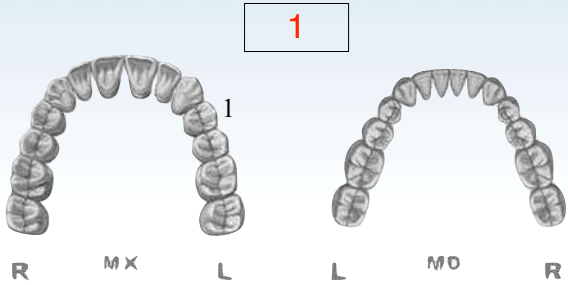
1. Chang CH, Huang C, Lee WH, Roberts WE. Failure rates for SS and Ti-alloy incisal anchorage screws: Single-center, double blind, randomized clinical trial. *J Digital Orthod* 2018;52:70-79.
2. Tseng LYL, Chang CH, Roberts WE. Diagnosis and conservative treatment of skeletal Class III malocclusion with anterior crossbite and asymmetric maxillary crowding. *Am J Orthod Dentofacial Orthop* 2016;149:555-66.
3. Kin KH, Chung CH, Choy K, Lee JS, Vanarsdall RL. Effects of prestretching on force degradation of synthetic elastomeric chains. *Am J Orthod Dentofacial Orthop* 2005;128:477-482.
4. Roberts WE, Graber LW, Vanarsdall RL Jr, Vig KWL. Bone physiology, metabolism and biomechanics in orthodontic practice. In: *Orthodontics: Current principles and techniques*, Chapt 10. 5th ed. St. Louis: Elsevier Mosby; 2012. p. 287-343.
5. Park JH, Tai K, Kanao A, Takagi M. Space closure in the maxillary posterior area through the maxillary sinus. *Am J Orthod Dentofac Orthop* 2014;145(1):95-102.
6. Kuroda S, Wazen R, Moffatt P, Tanaka E, Nanci A. Mechanical stress induces bone formation in the maxillary sinus in a short-term mouse model. *Clin Oral Investig* 2013;17(1):131-137.
7. Chaiyasang S, Deesamer S, Kaen K. Orthodontic tooth movement through maxillary sinus. *Srinagarind Med J* 2010;25(2):156-161.
8. Wehrbein H, Fuhrmann RAW, Diedrich PR. Human histologic tissue response after long-term orthodontic tooth movement. *Am J Orthod Dentofacial Orthop* 1995;107:360-371.
9. Daimaruya T, Takahashi I, Nagasaka H, Umemori M, Sugawara J, Mitani H. Effects of maxillary molar intrusion on the nasal floor and tooth root using the skeletal anchorage system in dogs. *Angle Orthod* 2003;73:158-166.
10. Wehrbein H, Bauer W, Wessing G, Diedrich P. The effect of the maxillary sinus floor on orthodontic tooth movement. *Fortschr Kieferorthop* 1990;51(6):345-351.
11. Kuroda S, Wazen R, Moffatt P, Tanaka E, Nanci A. Mechanical stress induces bone formation in the maxillary sinus in a short-term mouse model. *Clin Oral Investig* 2013;17(1):131-137.
12. Silverman NE, Ackerman JL. Oligodontia: a study of its prevalence and variation in 4032 children. *ASDC J Dent Child* 1979;46:470-477.
13. Takahama Y, Aiyama Y. Maxillary canine impaction as a possible microform of cleft lip and palate. *Eur J Orthod* 1982;4:275-7.
14. Sacerdoti R, Baccetti T. Dentoskeletal features associated with unilateral or bilateral palatal displacement of maxillary canines. *Angle Orthod* 2004;74:725-32.
15. Bass T. Observation on the misplaced upper canine tooth. *Dent Pract Dent Rec* 1967;18:25-33.
16. Johnston WD. Treatment of palatally impacted canine teeth. *Am J Orthod* 1969;56:589-96.
17. Sajjani AK, King NM. Prevalence and characteristics of impacted maxillary canines in southern Chinese children and adolescents. *J Investig Clin Dent* 2014;5(1):38-44.
18. Zhong YL, Zeng XL, Jia QL, Zhang WL, Chen L. Clinical investigation of impacted maxillary canine. *Chinese J Stomatology* 2006;41(8):483-5.



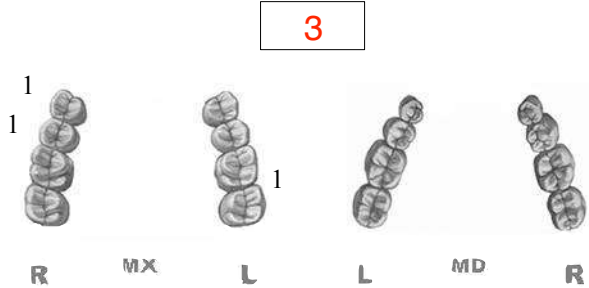
Cast-Radiograph Evaluation

Total Score: 12

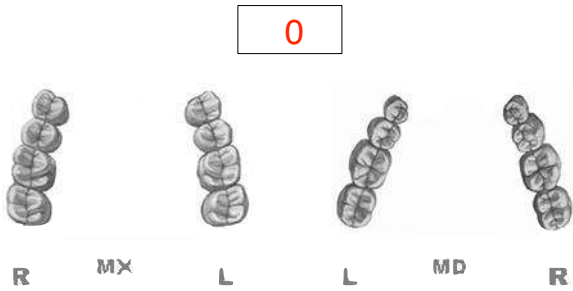
Alignment/Rotations



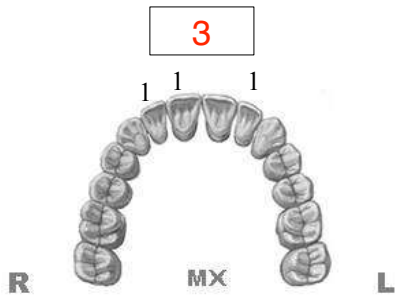
Marginal Ridges



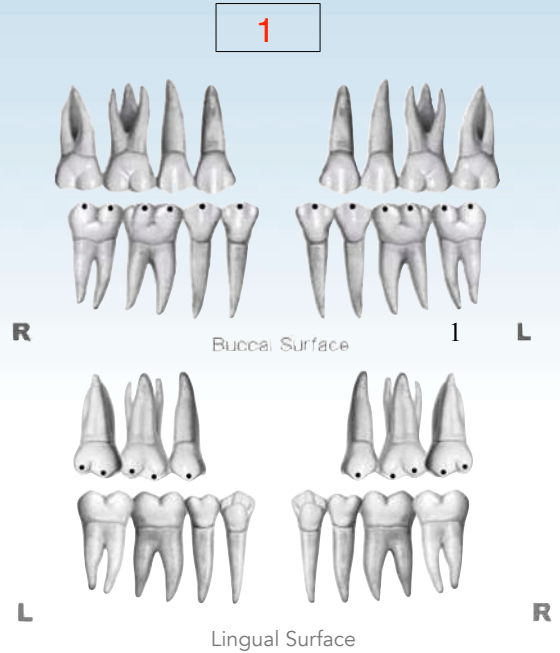
Buccolingual Inclination



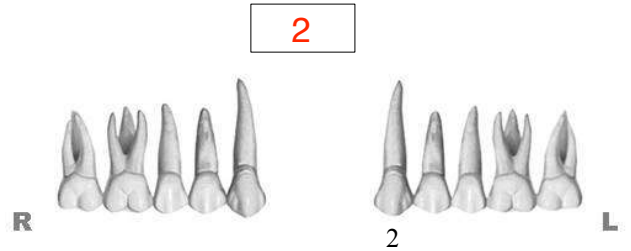
Overjet



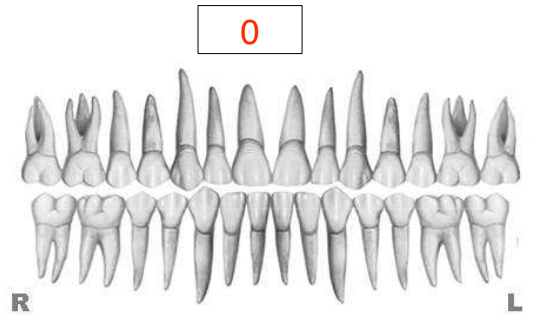
Occlusal Contacts



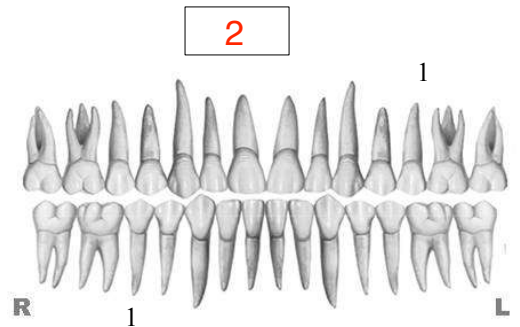
Occlusal Relationships



Interproximal Contacts



Root Angulation

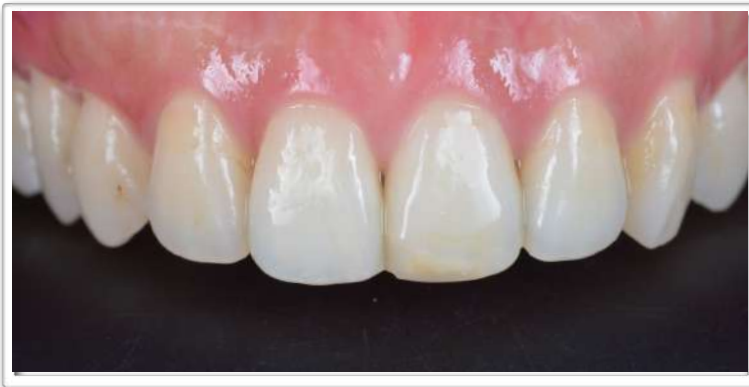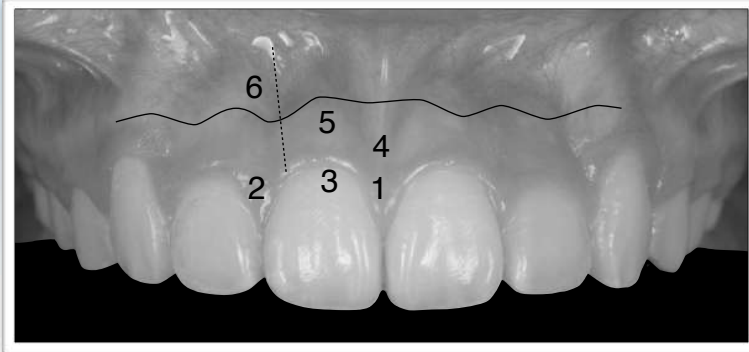


INSTRUCTIONS: Place score beside each deficient tooth and enter total score for each parameter in the white box. Mark extracted teeth with "X". Second molars should be in occlusion.

IBOI Pink & White Esthetic Score

Total Score = 4

1. Pink Esthetic Score

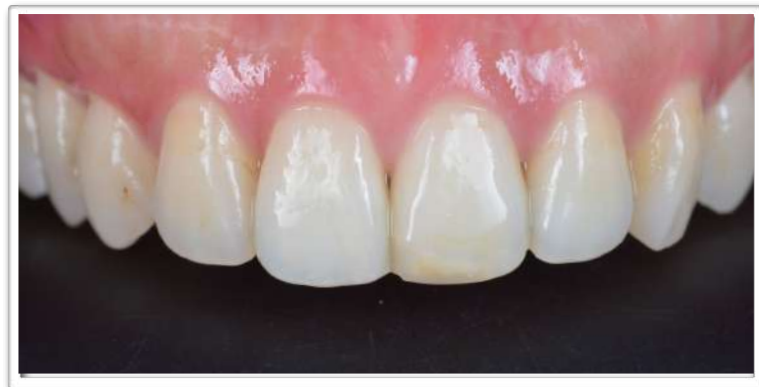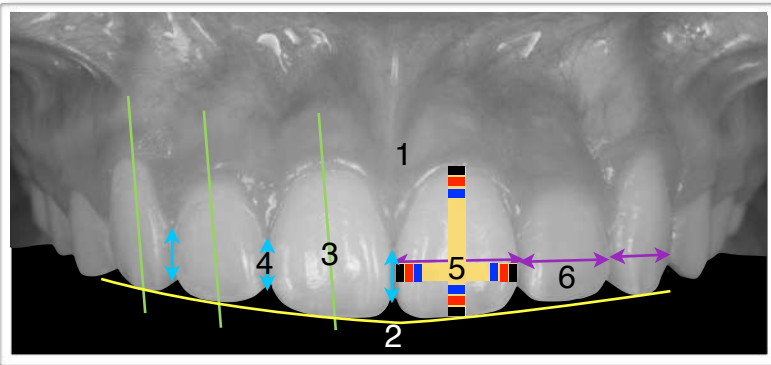


1. M & D Papillae	0	1	2
2. Keratinized Gingiva	0	1	2
3. Curvature of Gingival Margin	0	1	2
4. Level of Gingival Margin	0	1	2
5. Root Convexity (Torque)	0	1	2
6. Scar Formation	0	1	2

Total = 1

1. M & D Papillae	0	1	2
2. Keratinized Gingiva	0	1	2
3. Curvature of Gingival Margin	0	1	2
4. Level of Gingival Margin	0	1	2
5. Root Convexity (Torque)	0	1	2
6. Scar Formation	0	1	2

2. White Esthetic Score (for Micro-esthetic)



1. Midline	0	1	2
2. Incisor Curve	0	1	2
3. Axial Inclination (5°, 8°, 10°)	0	1	2
4. Contact Area (50%, 40%, 30%)	0	1	2
5. Tooth Proportion	0	1	2
6. Tooth to Tooth Proportion	0	1	2

Total = 3

1. Midline	0	1	2
2. Incisor Curve	0	1	2
3. Axial Inclination (5°, 8°, 10°)	0	1	2
4. Contact Area (50%, 40%, 30%)	0	1	2
5. Tooth Proportion	0	1	2
6. Tooth to Tooth Proportion	0	1	2



International Association for **O**rdhodontists & Implantologists

Join the **iAOI** the future of dentistry!

About our association-iAOI

International Association of Orthodontists and Implantologists (iAOI) is the world's first professional association dedicated specifically for orthodontists and implantologists. The Association aims to promote the collaboration between these two specialties and encourage the combined treatment of orthodontic and implant therapy in order to provide better care for our patients.

How to join iAOI?

Certified members of the Association are expected to complete the following three stages of requirements.

1. Member

Doctors can go to <http://iaoi.pro> to apply for membership to join iAOI. Registered members will have the right to purchase a workbook in preparation for the entry exam.

2. Board eligible

All registered members can take the entry exam. Members will have an exclusive right to purchase a copy of iAOI workbook containing preparation materials for the certification exam. The examinees are expected to answer 100 randomly selected questions out of the 400 ones from the iAOI workbook. Those who score 70 points or above can become board eligible.

3. Diplomate

Board eligible members are required to present three written case reports, one of which has to be deliberated verbally. Members successfully passing both written and verbal examination will then be certified as Diplomate of iAOI.

4. Ambassador

Diplomates will have the opportunity to be invited to present six ortho-implant combined cases in the iAOI annual meeting. Afterwards, they become Ambassador of iAOI and will be awarded with a special golden plaque as the highest level of recognition in appreciation for their special contribution.



For more information on benefits and requirements of iAOI members, please visit our official website: <http://iaoi.pro>.

iAOI Ambassador & Diplomat

國際矯正植牙大使與院士



Ambassadors

Dr. Kenji Ojima



Dr. 林詩詠
Joshua Lin



42 pts

Dr. Diego
Peydro Herrero



Dr. 陳俊宏
Chun-Hung Chen



20 pts

Dr. 張銘珍
Ming-Jen Chang



18 pts

Dr. 曾令怡
Linda Tseng



16 pts

Ambassador (大使):

* One who has published 9+ case reports in JDO.

◆ Keynote speakers for iAOI annual workshops

▲ Case report(s) published at least once in referral journals.

● Referral journals/Research paper - 3 points
ABO case report - 2 points
Clinical tip - 1 point

Diplomates

Dr. 徐玉玲
Lynn Hsu



29 pts

Dr. 李雙安
Angle Lee



26 pts

Dr. 蘇荃璋
Bill Su



24 pts

Dr. 葉信吟
Hsin-Yin Yeh



20 pts

Dr. 徐重興
Eric Hsu



20 pts

Dr. 黃育新
Yu-Hsin Huang



18 pts

Dr. 黃祈
Richie Huang



16 pts

Dr. 邱上珍
Grace Chiu



13 pts

Dr. 黃瓊嬋
Sabrina Huang



13 pts

Dr. 鄭惠文
Joy Cheng



13 pts

Dr. 曾淑萍
Shu-Ping Tseng



12 pts

Dr. 林曉鈴
Sheau-Ling Lin



10 pts

Dr. 張倩瑜
Charlene Chang



10 pts

Dr. 林佳宏
Alex Lin



10 pts

Dr. 林彥君
Lexie Lin



9 pts

Dr. 林森田
Chris Lin



7 pts

Dr. 黃登楷
Kevin Huang



6 pts

Dr. 張馨文
Sara Chang



6 pts

Dr. 李名振
Major Lee



6 pts

Dr. 陳惠華
Judy Chen



6 pts

Dr. 魏明偉
Ming-Wei Wei



6 pts

Dr. 黃荷薰
Ashley Huang



6 pts

Dr. 李彥峰
Yen-Feng Lee



6 pts

Dr. 張銘津
Ariel Chang



5 pts

Dr. 彭緯綸
Wei-Lun Peng



4 pts

Dr. 呂詩薇
Julie Lu



4 pts

德國國立杜易斯堡-埃森大學

Master Degree in Specialized Orthodontics

黃金陣容師資團隊



Scientific Director
德國國立杜易斯堡-埃森大學 IMC 口腔醫學院院長

Univ. Prof. Dr. Dr. Dr. h. c. mult. Ulrich Jaos, FRCS, FDSRCS

德國國立杜易斯堡-埃森大學 IMC 口腔醫學院院長
德國明斯特大學口腔顎面外科醫院及門診部榮譽教授
英國皇家外科學會榮譽院士 (FRCS, FDSRCS)
德國外科基金會 OCS 創辦人
德國杜易斯堡 MVZ 醫療中心創辦人
歐洲顎面外科協會 EACMFPS 主席

1972年至1979年為其學術養成重要階段，先後完成牙醫、醫學學士，隨後於德國為口腔顎面外科醫師。1980年於德累斯登大學任教期間 (D3-Professor)，取得德國特許任教資格，後擔任歐洲及歐盟各國口腔顎面外科相關學會的領導者，曾獲頒發外科協會榮譽會員及匈牙利學術榮譽博士 (1980-1984)，法國口腔顎面外科協會副主席 (1985)，1989至2002年再度擔任歐洲顎面外科協會主席，德國杜易斯堡-埃森大學 IMC 口腔醫學碩士學位委員會主席 (2003)，同年獲頒西牙牙口顎面外科協會榮譽會員，海德拉巴德 (口顎顎裂) 協會國際副院長委員會榮譽會員 (2005)，匈牙利塞格德大學醫學博士及教授 (2012)，英國皇家外科學會榮譽院士 (2016)，30年職涯內培育超過300名口腔顎面外科醫師。



Dr. med. dent.
Thomas Zieburg

- 德國明斯特大學教學醫院齒顎矯正醫師
- 德國特許特許執業正私人診所院長



Prof. Dr. med. dent.
Thomas Stamm

- 德國杜易斯堡 MVZ 醫療中心齒顎矯正科主任
- 德國明斯特大學教授
- 德國齒醫學會正牙科醫師



Prof. Dr. med. dent.
Jörg Lisson

- IMC 齒顎矯正學科碩士學位課程主任
- 德國萊茵蘭大學齒顎矯正系主任
- 德國牙科委員會主席
- 德國口腔顎面外科大學教授協會主席
- 德國齒醫學會理事



Univ. Pro. Dr.
Ulrike Ehmer

- 德國明斯特大學齒顎矯正系主任
- 德國齒醫學會及德國齒醫學會理事
- 齒醫學會及會員大使



Prof. Dr. med. Dr. med. dent.
Alexander Hemprich

- 德國萊茵蘭大學牙科診所院長
- 德國口腔顎面外科學會主席



Prof. Dr. med. Dr. med. dent.
József Piffkó

- 德國齒醫學會外科學會主席
- 匈牙利口腔顎面外科學會主席
- 匈牙利塞格德大學醫學教授及主任
- 口腔顎面外科主任



Dr.
Karl-Ludwig Mischke

- 德國明斯特大學教學醫院齒顎矯正醫師



PD Dr. med. Dr. med. dent.
Thomas Filles

- 德國萊茵蘭大學海軍醫院口腔顎面外科主任
- 德國萊茵蘭大學海軍醫院齒顎矯正中心主任



Univ.-Prof. Dr. med. dent.
Ariane Hohoff

- 德國明斯特大學教學醫院齒顎矯正部主任
- 德國齒醫學會正牙科醫師



Dr. med. dent.
Werner Schupp

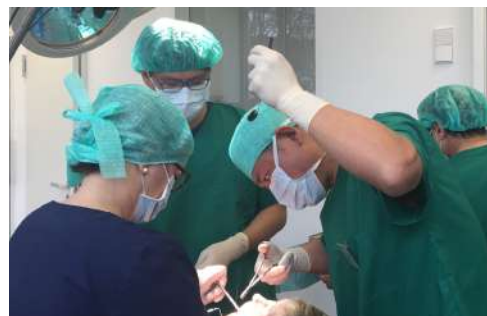- 德國口腔顎面外科學會理事
- 德國齒醫學會正牙科醫師
- 奧地利法蘭克大學教授

全球獨家歐盟臨時行醫權


歐洲唯一提供國際醫師

在當地進行實作的臨床碩士學位

課程重視臨床運用及實作技巧學程期間學員須親赴歐洲于指導教授監督下，親自執行臨床診療，學習最先進的臨床技術，應用於自身牙科診療工作。



線上遠距教學 + 德國實習 · 工作學業兼顧



- 1 線上互動式教學
即時發問立即回饋
- 2 完整案例分析及最新技術分享
即時應用於每日臨床工作
- 3 兩年碩士課程包含德國實習兩次
實際參與現場課程與執行診療

Beethoven International Orthodontic Specialty Course

德國國立杜易斯堡-埃森大學
IMC 齒顎矯正專科碩士學位先修課程

UNIVERSITÄT
DUISBURG
ESSEN



Dr. Chris Chang

DDS, PhD. ABO certified, Angle Midwest
Beethoven Orthodontic Center, Taiwan



Dr. Bill Su

VISTA surgical
techniques

Dr. Yulin Hsu

Early orthodontic
treatment

Dr. Shu Ping Tseng

Early orthodontic
treatment

Dr. Joshua Lin

Treatment for
impacted teeth

Dr. Eric Hsu

Research design

Dr. Bear Chen

ABO DI & CRE

Dr. Lexie Lin

ABO case report

Annie Chen

Academic writing

Beethoven International Orthodontic Specialty Course, 是德國國立杜易斯堡-埃森大學 IMC 齒顎矯正專科碩士學位所特別增設的先修課程, 由國際知名講師張慧男醫師親自規劃及授課, 課程特色強調由臨床病例帶動診斷、分析、治療計劃擬定與執行技巧, 亦加入最新的數位矯正與隱形牙套的內容, 並邀請了貝多芬牙科集團各院院長演講特別矯正專題。

除包含原貝多芬矯正大師班的課程內容外, 另外加入了骨釘與 VISTA 術式的操作課程, 並新增了學術文章寫作與演講的訓練, 讓醫師在進入德國碩士班之前, 做好更充分的準備。

想要取得歐洲正式矯正碩士學位資格又苦惱時間不足的醫師, 本先修課程是追求您目標的最佳途徑!



課程修畢即取得德國碩士班入學資格

全球目前只有三個機構擁有此先修課程資格, 想要取得歐洲齒顎矯正碩士的台灣醫師, 此課程為最有效率的選擇。



全新規劃的術式實作

本課程全新規劃的術式實作特別採用了由國際知名的西班牙臨床大師 Dr. Fernando Rojas-Vizcaya 所設計含阻生牙的新式牙齒模型, 與歐洲課程接軌, 臨床操作更易上手。



學術文章寫作訓練

本課程除了課堂演講與模型操作課程外, 亦加入了學術文章寫作訓練。醫師可以學習如何有技巧並且有效率的撰寫學術文章, 讓之後的碩士論文與文章發表更游刃有餘。



☎ 03-5735676#217 Chester Yu

✉ yuebucy@newtonsa.com.tw