



好評推薦!

動物圈 x Power Chain

買 Zoo Pack Elastics x 4 盒
動物圈

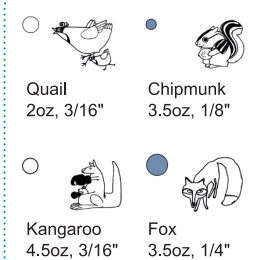


贈 Power Chain x 4 卷
(任選open/close/wide)

矯正專用彈力鏈



矯正新手動物圈建議



特價 **NT\$12,000** /組



熱銷組!

小資新手矯正黏著套組

Bonding Sample Kit :

Enlight Syringe x 1 支

Ortho Solo x 1 瓶

光照含氟矯正專用黏著劑(4g) + 多功能光照基底劑(5ml)

+ Enlight Syringe x 2 支

特價 **NT\$5,000** /組



線定優惠組

買 Copper Ni-Ti x 5 盒 (線徑任選)
感溫性鎳鈦合金線 - Level and Align

贈 Low-Friction TMA x 2 盒 (線徑任選)
低摩擦力鈦鉬合金線 - Finishing and Detailing

特價 **NT\$14,500** /組



戴蒙系統鉅作 感恩回饋

國際大師推薦，愛用好評如潮 **Damon Q2 × Damon Clear**

OrmcoTM
YOUR PRACTICE. OUR PRIORITY.



特惠組1

DAMON[®] DAMON[®] 2

(Q/Q2 共200顆)



$\frac{6}{6} \frac{6}{6} \frac{7}{7} \frac{7}{7}$

Bondable Tube* x 10 人份

特價 **NT\$135,999** /組



DamonQ2 特色

- Under tie-wing空間加大，掛Power chain好操作
- Torque, rotation角度控制升級
- 滑蓋scribe line標誌，提升臨床效率

+ 配件加購

Drop-in Hook

DQ/DQ2 插入式掛鉤

特價 **NT\$1,800** /盒

*限與訂單同時加購，訂單成立後恕無法再行追加。



Drop-in hook 使用說明



1. 插入矯正器vertical slot
(位於矯正器undercut遠心側)



2. 黃色點朝唇側/頰側，
將尾端彎折至矯正器凹槽內

特惠組2

DAMON[®] DAMON[®] CLEAR[™] CLEAR[™] 2

(Clear/Clear2 共200顆)



$\frac{6}{6} \frac{6}{6} \frac{7}{7} \frac{7}{7}$

Bondable Tube* x 10 人份

特價 **NT\$175,999** /組



* 以上販售及贈品品項皆不含 SnapLink Tubes, Accent Mini Tubes, A⁺



回饋贈禮！

選購特惠組1或2，即贈送以下矯正線

- .014 Damon Copper Ni-Ti x 20 條
感溫性鎳鈦合金線 - Level and Align
- .014 x .025 Damon Copper Ni-Ti x 20 條
感溫性鎳鈦合金線 - Begin Torque Control
- .016 x .025 Damon SS x 20 條
不鏽鋼合金線 - Space Closure
- .017 x .025 Damon Low-Friction TMA Wire x 20 條
低摩擦力鈦鋁合金線 - Finishing and Detailing



熱門
線徑

Non-Extraction Treatment for Excessive Overjet and Deep Bite with Aligners and IZC Screws

Abstract

Introduction: A 15-year-11-month-old female presented with chief complaints of protrusion and a severe deep bite.

Diagnosis: Cephalometric analysis revealed a skeletal Class I relationship (SNA, 87°; SNB, 84°; ANB, 3°), reduced facial convexity (-10°), as well as proclined upper and lower incisors. An intraoral assessment revealed canine Class II malocclusion with an 8mm overjet and an impinged deep bite. There were slight generalized spaces in the upper anterior dentition, and the Discrepancy Index (DI) was 35.

Treatment: The treatment plan was a non-extraction treatment using Invisalign® clear aligner therapy anchored with infrazygomatic crest (IZC) bone screws bilaterally. Class II elastics were used during the treatment to correct the relative position between the upper and lower arches. The active treatment time was 25 months with 3 refinements to effectuate the final result.

Results: Improved dentofacial esthetics and a better occlusal function were achieved after treatment. The Cast-Radiograph Evaluation (CRE) was 12, and Pink and White esthetics score was 4. No significant root resorption nor periodontal problems were noted. The patient was well satisfied with the final outcome.

Conclusions: With Chang's extraction decision table, a feasible treatment plan was completed with a pleasant result. In retrospect, the treatment time could have been decreased by adding virtual anterior bite ramps, which would reduce the bite-block effect. Overcorrection of intrusion for the lower anterior teeth was applied since, along with canine rotation, it is one of the most inaccurate movements in ClinCheck®. Rearranging the sequence of tooth movements by intruding the lower anterior teeth before retracting the upper arch may also improve this issue. (J Digital Orthod 2022;66:28-42)

Key words:

Excessive overjet, deep bite, clear aligner treatment, Invisalign®, IZC screws, anchorage

Introduction

The dental nomenclature for this case report is a modified Palmer notation with four quadrants: upper right (UR), upper left (UL), lower right (LR), and lower left (LL). Teeth are numbered 1-8 from the midline in each quadrant.

Patients who seek orthodontic treatment are often motivated by esthetic issues. Therefore, clear aligner is often an attractive option for patients not only for easier oral hygiene maintenance but also for its esthetics during treatment. Clear aligner treatment was initially introduced to treat mild orthodontic cases;¹ however,

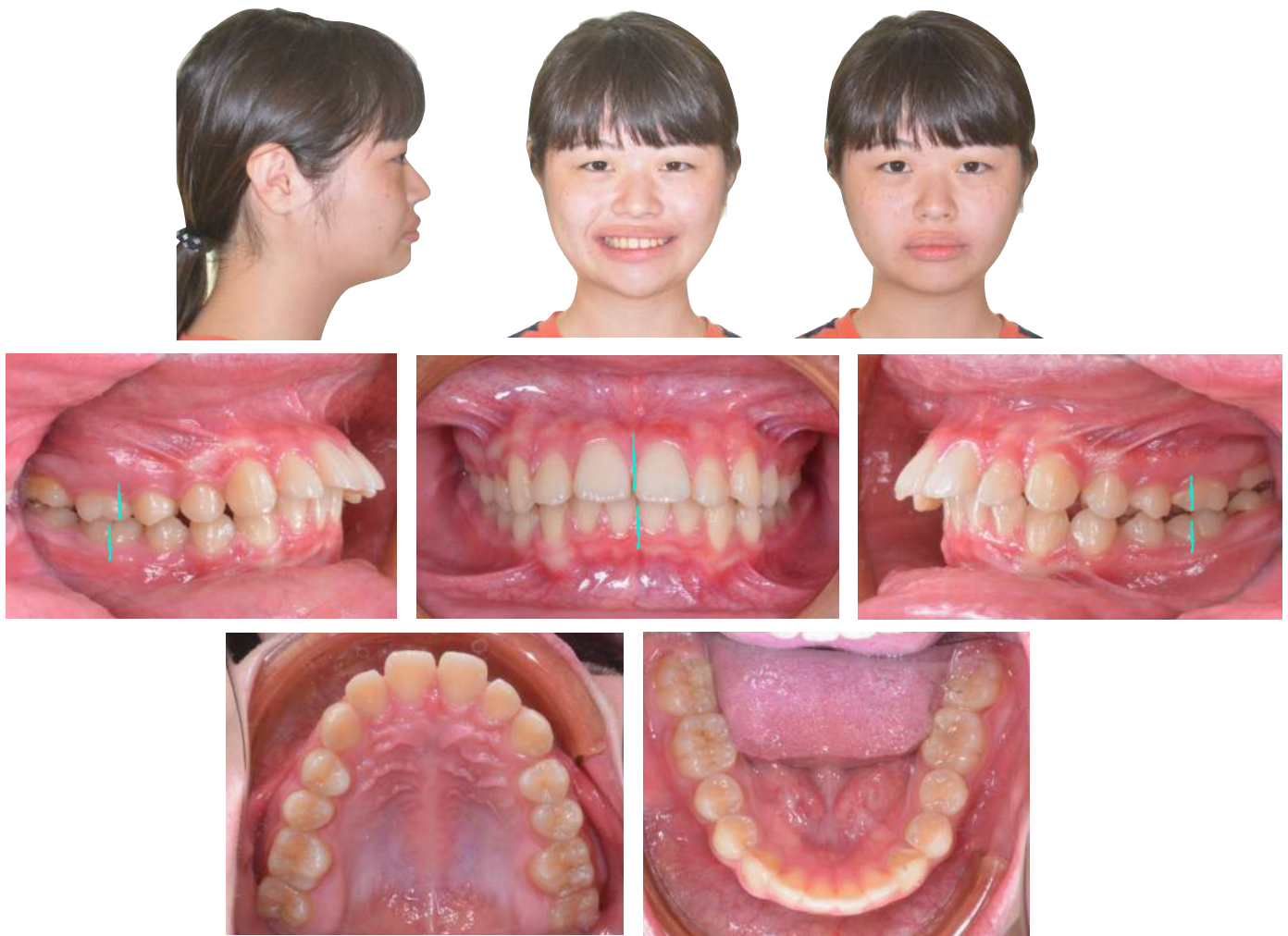several complex cases which were treated with Invisalign® appliances and achieved satisfactory results were recently reported.² One of the most common side effects when treating with aligners is the bite-block effect. The thickness of the aligners may cause intrusion of the posterior teeth and induce deepening of the overbite. As a consequence, deep bite cases treated with aligners are seldom reported,³ even less so if the case is complicated by excessive overjet. This special case report, which documents a patient with an 8mm overjet and deep bite treated with aligners and the aid of infrazygomatic crest (IZC) screws within 25 months, however, supports the feasibility and effectiveness of aligners in excessive overjet and deep bite cases.

Vicky T. Huang,*Resident, Beethoven Orthodontic Center (Left)***Bear C. Chen,***Associate Director, Beethoven Orthodontic Center (Center left)***Chris H. Chang,***Founder, Beethoven Orthodontic Center**Publisher, Journal of Digital Orthodontics (Center right)***W. Eugene Roberts,***Editor-in-Chief, Journal of Digital Orthodontics (Right)*

Diagnosis and Etiology

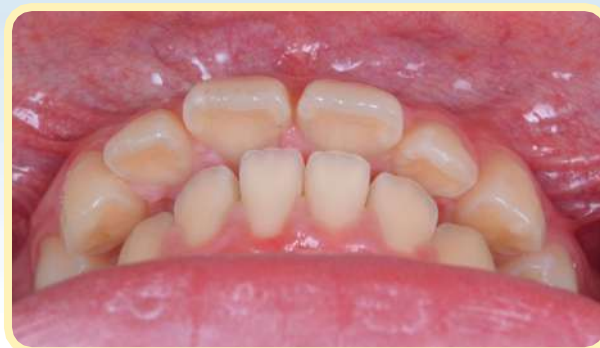A 15-year-11-month-old female presented with chief complaints of protrusive lips and a deep bite (Fig. 1). The patient had no significant medical or dental history, and oral hygiene was acceptable. A

radiographic examination was performed with a panoramic radiograph, lateral cephalometric film, and a temporomandibular joint (TMJ) series (Figs. 3-5). The panoramic radiograph showed three unerupted third molars with no pathological symptoms. The cephalometric analysis revealed

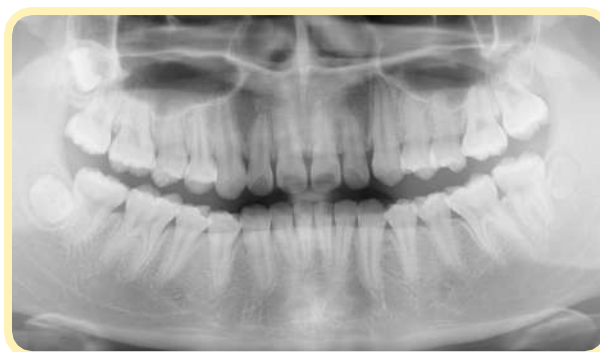


■ Fig. 1: Pre-treatment facial and intraoral photographs in C₀

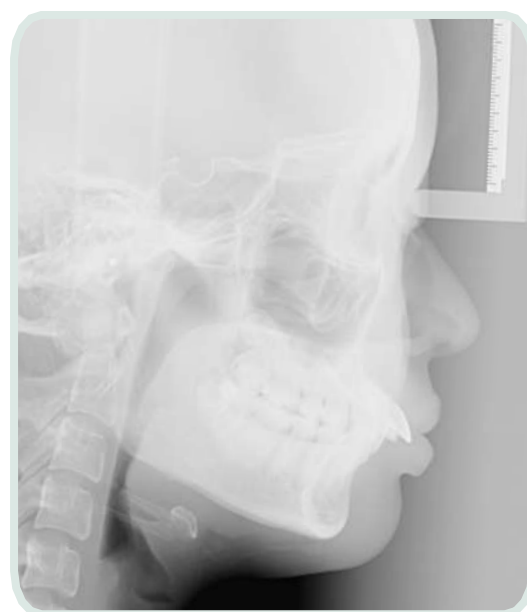proclined upper and lower incisors with a low mandibular angle, and a skeletal Class I with protruded maxilla and normal mandible (Table 1). After facial evaluation, a convex profile, as well as acceptable upper and lower lips to the E-line were noted. The intraoral examination showed an 8mm overjet and deep bite, along with dental canine Class II and molar end-on Class II relationships on the right, but Class I relationships on the left side. The maxillary dental midline was 1mm to the left of the facial midline, and the mandibular and maxillary dental midline were coincident. The TMJ radiographs (Fig. 5) showed symmetrical condylar morphology with no signs or symptoms of temporomandibular dysfunction (TMD). The American Board of Orthodontics (ABO) Discrepancy Index (DI) was 35 points,⁴ as shown in Worksheet 1 at the end of this report.



■ Fig. 2: Anterior crossbite at the anterior dentition



■ Fig. 3: Pre-treatment panoramic radiograph



■ Fig. 4: Pre-treatment cephalometric radiograph

Treatment Objectives

The treatment objectives were to:

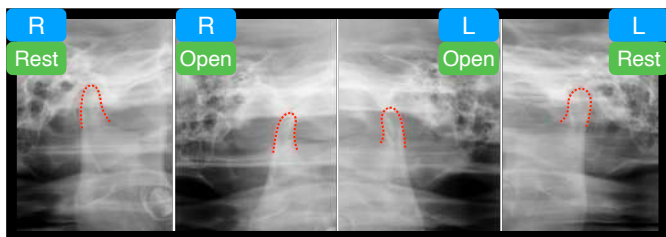
1. Correct an 8mm overjet and deepbite.
2. Achieve Class I canine and molar relationships.
3. Correct the midline discrepancy.

Treatment Plan

The main goal of this Invisalign® aligner treatment was correction of the lip protrusion and deep bite (Fig. 1). A non-extraction treatment approach was proposed: upper arch retraction of 2mm, interproximal reduction (IPR) to relieve the anterior protrusion, and Class II elastic mechanics.

CEPHALOMETRIC SUMMARY			
SKELETAL ANALYSIS			
	PRE-TX	POST-TX	DIFF.
SNA° (82°)	87°	86°	1°
SNB° (80°)	84°	83°	1°
ANB° (2°)	3°	3°	0
SN-MP° (32°)	24°	24°	0
FMA° (25°)	17°	17°	0
DENTAL ANALYSIS			
U1 TO NA mm (4mm)	11	6	5
U1 TO SN° (104°)	130°	108°	22°
L1 TO NB mm (4mm)	8	6	2
L1 TO MP° (90°)	112°	104°	8°
FACIAL ANALYSIS			
E-LINE UL (-1mm)	-1	-1	0
E-LINE LL (0mm)	2	0	2
%FH: Na-ANS-Gn (53%)	46%	52%	6%
Convexity:G-Sn-Pg' (13°)	10°	9°	1°

■ Table 1: Cephalometric summary



■ Fig. 5 :
Pre-treatment TMJ transcranial radiographs show the right (R) and left (L) sides in the rest and open positions. The mandibular condyles are outlined in red. Note the mandibular condyle heads are quite symmetrical.

OrthoBoneScrews® (OBSs) (iNewton dental, Inc., Hsinchu City, Taiwan) anchorage on the upper arch was also scheduled in order to enhance the force for upper arch retraction.

Treatment Alternatives

Lefort I orthognathic surgery with bilateral sagittal split osteotomy (BSSO) was the surgical treatment option for the patient since she had an 8mm overjet. Extraction of the upper first premolars would also be one of the treatment options to solve the overjet problem. However, space closure is sometimes challenging for Invisalign® and may cause side effects such as bowing effect. In this case, the retromolar space could be sufficient for retracting the maxillary arch to correct the overjet. The patient in the end declined both surgery and extractions, taking into consideration the higher risk of complications and psychological stress.

Treatment Progress

iTero Element® intraoral scans (Align Technology, Inc., San Jose, CA, USA) were performed to provide a 3D dataset. The ClinCheck® system (Align Technology, Inc., San Jose, CA, USA) was used to plan a reasonable biomechanical design and simulate the outcome. Oral hygiene and aligner fitness were evaluated at monthly intervals.

An initial set of 60 aligners was planned, and the aligner duration was set for 10 days each. The patient was instructed to wear the appliances at least 20 hours a day with the aid of chewing a Chewie.

The selected attachments required for optimal tooth movement were (Fig. 6):

- Optimized attachments: *UR2-UR5, UL2-UL5, LL3-LL5, as well as LR3-LR5*
- Horizontal rectangular attachments: *UR6, UR7, UL6, UL7, LL6, and LR7*

Attachments were installed during the first visit and aligners #1-4 were delivered to the patient with instructions to progress with the next aligner every 10 days. The objectives for the first set of aligners were to: 1. retract the maxillary arch, 2. achieve normal overbite, and 3. reach ideal occlusion.

In the 4th month of treatment (19th aligners), buttons were positioned on LR6, and LL6 and Class II elastics (Kangaroo, 3/16-in, 4.5-oz) were introduced bilaterally from the upper canines to the lower first molars (Fig. 7).

In the 6th month of treatment (26th aligners), IZC screws were placed (Fig. 7). During the same visit,

elastics (Chipmunk, 1/8-in, 3.5-oz) were hooked bilaterally from the upper canines to the IZC screws.

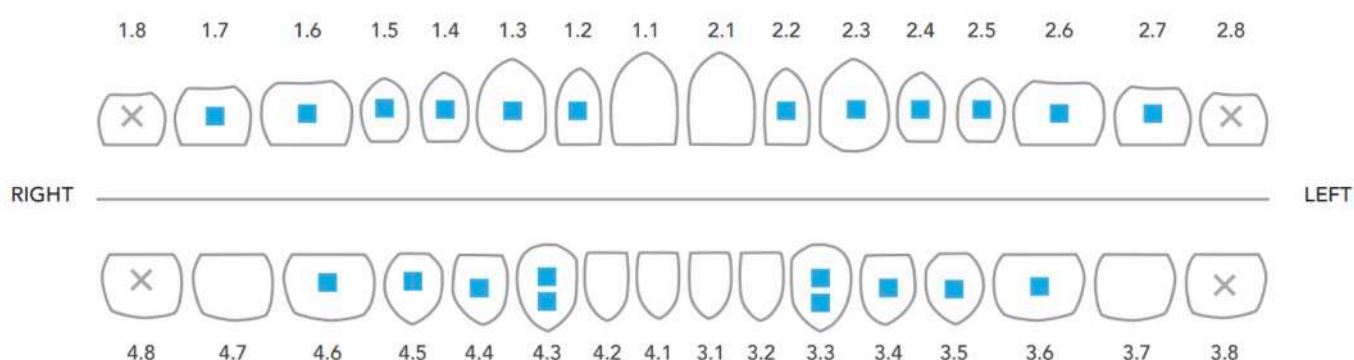
After the first set of aligners, the overjet was reduced from 8 to 6mm. Refinement was undertaken in order to continue decreasing the discrepancy between the maxilla and mandible (Fig. 8). The first refinement involving 20 additional aligners commenced with the additional attachments:

- Optimized attachments: *UL7 and LR7*

Three more refinements were processed aiming to achieve a normal overjet and overbite with ideal arch alignment (Table 2). IPR was performed between the upper incisors to provide spaces for anterior teeth retraction. Intrusion for lower anterior teeth was designed for overbite correction.

Results Achieved

The facial esthetics, gummy smile, and intermaxillary occlusion were significantly improved after 25 months of active treatment (Fig. 9). The upper and



■ Fig. 6: Initial treatment phase: Invisalign® treatment sheet; smartForce® features (optimized attachments) of the Invisalign

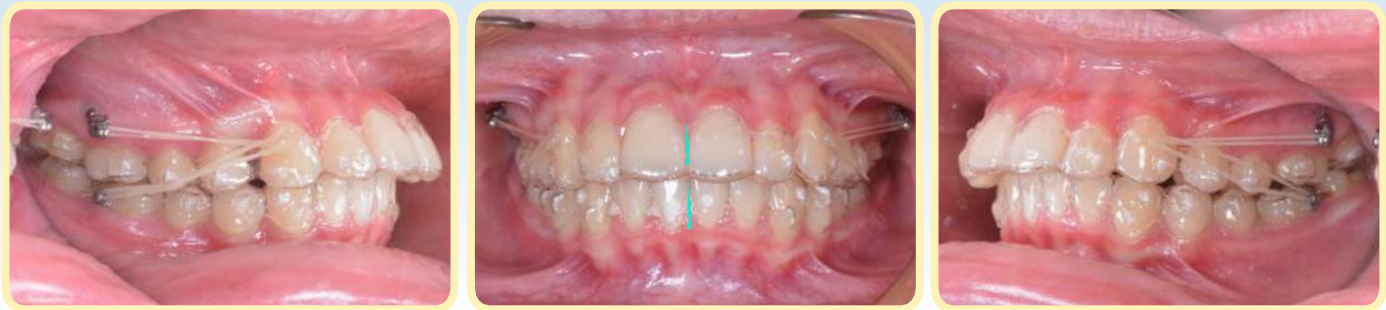

Fig. 7:
Intraoral photographs in the 9th month. In the 4th month, buttons were placed, and Class II elastics (Kangaroo, 3/16-in, 4.5-oz) were introduced bilaterally from the upper canines to the lower first molars. In the 6th month, IZC screws were placed and elastics (Chipmunk, 1/8-in, 3.5-oz) were hooked bilaterally from the upper canines to the IZC screws.

lower midlines were coincident with the facial midline. The canine relationships were corrected from Class II to Class I. The molar relationship was corrected from end-on Class II to Class I on the right side and remained Class I on the left side. The superimposed cephalometric tracings illustrated that the mandible rotated clockwise. The upper and lower lips were both retracted along with the anterior segments. The overbite and overjet were finished

within a normal range. The mandibular plane angle (SN-MP) was well-maintained (Table 1). The Cast-Radiograph Evaluation (CRE) score was 12 points, as shown in the supplementary Worksheet 2.⁵ The Pink and White dental esthetic score was 4 points (Worksheet 3).⁶ The patient was very pleased with the final result. Four sets of aligners over 25 months produced a final result that was close to the original 3D ClinCheck® projection.

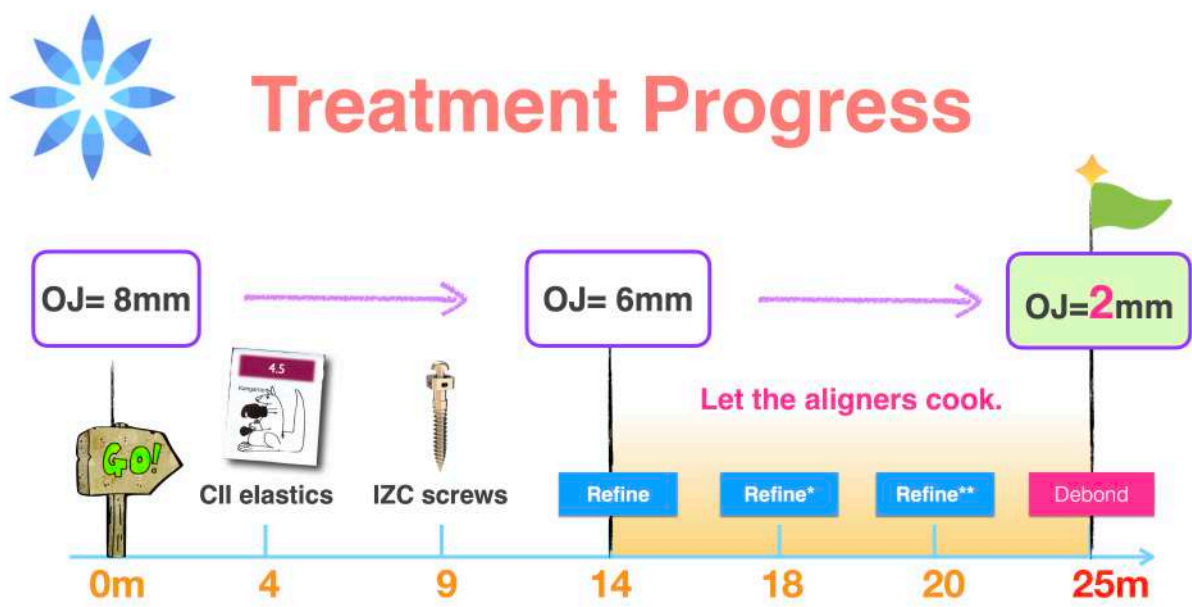
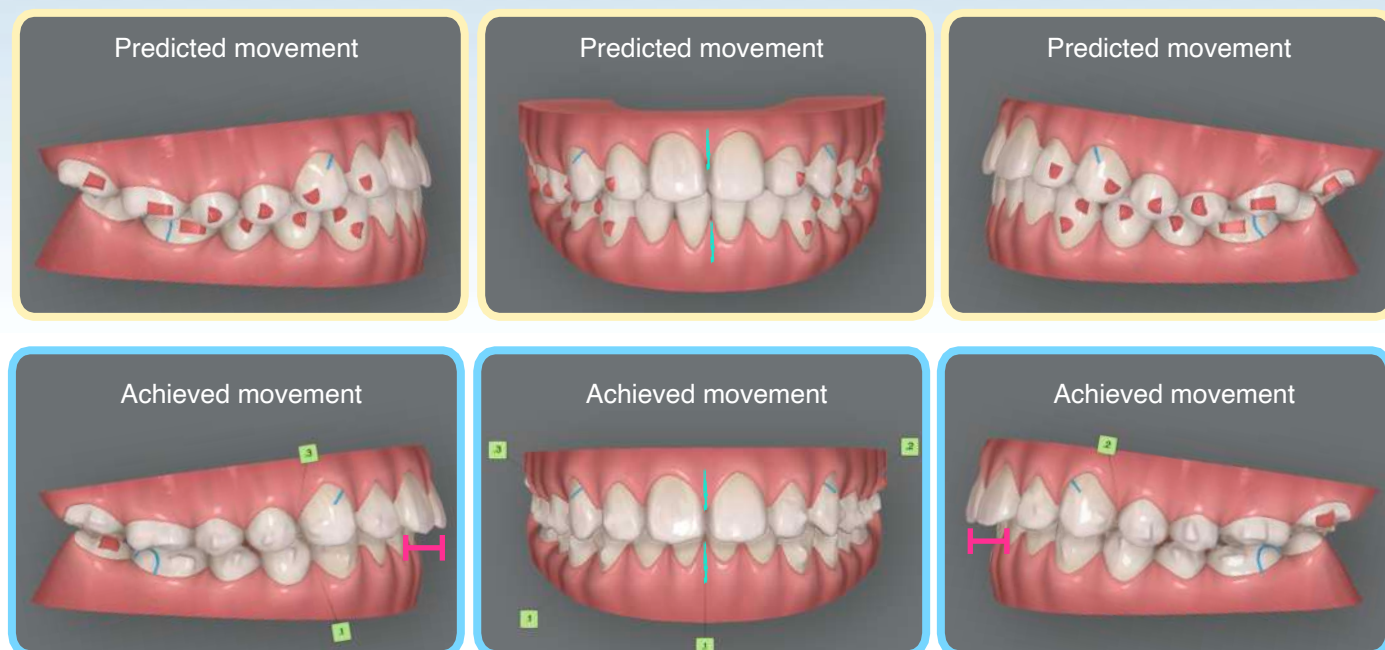

Table 2: Timeline for overjet changes, assisted appliances and refinements processed during treatment progress.



■ Fig. 8 :

Differences between predicted and achieved tooth movement (DPATM) after first set of aligners in the 14th month. It was discovered that the result did not meet the predicted movement. Overjet and overbite correction was inadequate. In the second refinement, IPR was scheduled to acquire more spaces for anterior teeth retraction.

Retention

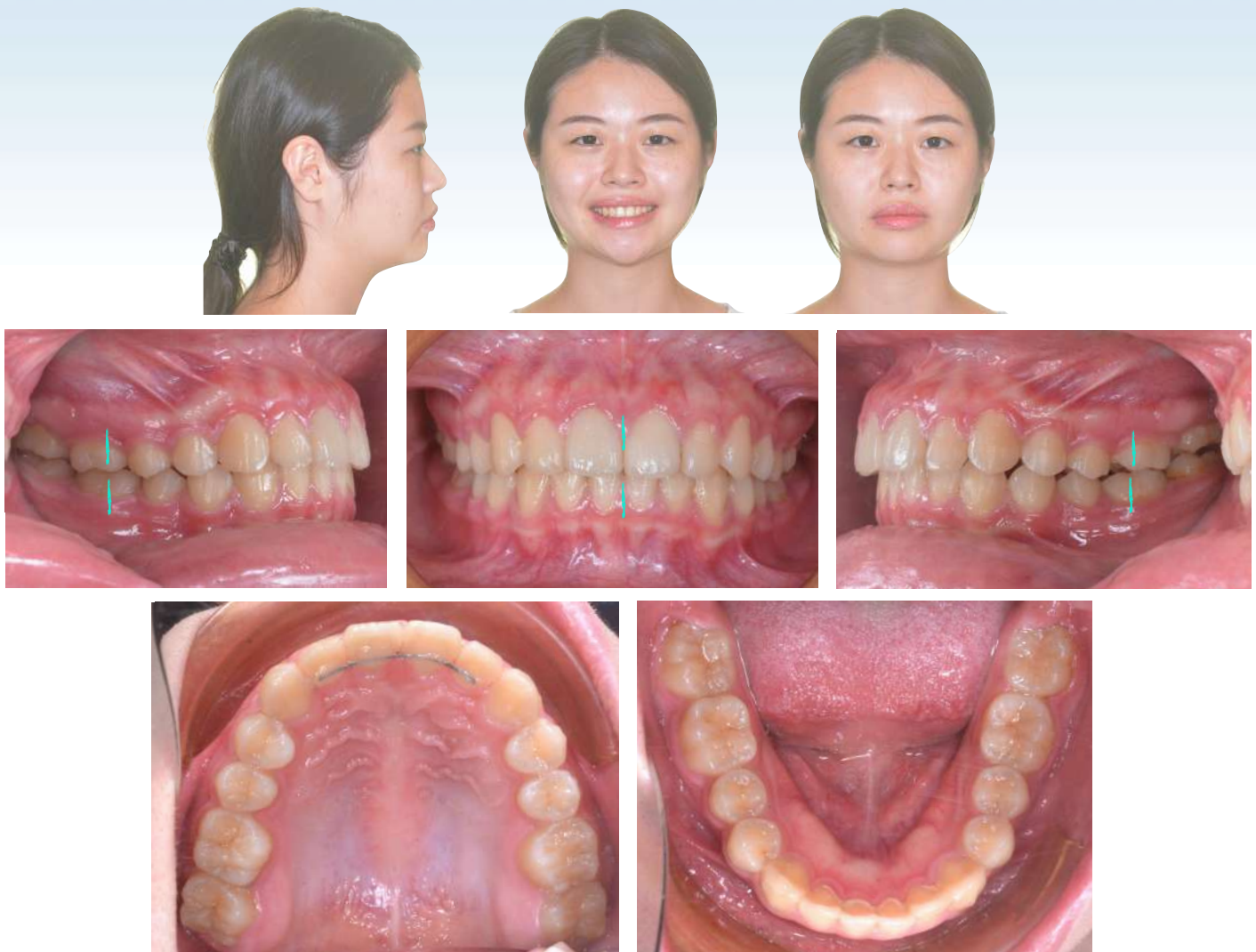After 25 months of treatment, all aligner attachments were removed. In order to prevent the relapse of anterior protrusion, a fixed retainer was placed from canine to canine on the upper arch (Fig. 9). Two ESSIX® (Dentsply Sirona, Harrisburg, PA) overlay retainers were provided to retain the leveling and alignment of the dentition. The patient was instructed to use the overlay retainers full time for the first month and only while sleeping thereafter.

Discussion

The etiology for large overjet may be the overuse of pacifiers or thumb sucking during childhood. Excessive overjets can enhance the risk of suffering traumatic

dental injuries.⁷ Furthermore, excessive overjets may entail unattractive appearances which may indirectly affect psychological development due to social pressure. Therefore, it is often recommended for patients to rectify this issue early to avoid possible dental damage or mental stress.

Extraction and orthognathic surgery were often introduced to patients with excessive overjets.⁸ However, a thorough evaluation should be considered instead of jumping into conclusions. In this case, although the patient had an 8mm overjet, her upper lip was not protruded normally. On the contrary, she had a low mandibular plane angle with a retrusive lower lip. Chang's extraction decision table (Table 3) was used to assess the necessity for extractions. For this case, three factors favoring a non-extraction treatment were the



■ Fig. 9: Posttreatment facial and intraoral photographs

low mandibular plane angle, deep bite, and the absence of crowding. In addition, the patient requested to avoid extractions and surgery, thus the feasible option was to apply extra-alveolar IZC bone screws to retract the whole maxillary arch.⁹

Aligners are suitable for retracting maxillary molars when a 2 to 3mm distalization is required to obtain a Class I relationship in selected end-to-end Class II adult patients.¹⁰ However, after the first set of aligners, there

were significant differences between predicted and achieved movements in this case (Fig. 8). The scheduled plan for upper molar distalization, which was to reduce the overjet to 1mm and correct the overbite, was not achieved. The overjet was decreased from 8 to 6mm, and the overbite was even deeper due to nearly no intrusion on the lower anterior teeth. There was only a slight inclination change on the upper incisors, which were more retroclined, and the lower incisors were more proclined instead. These

circumstances may be due to the bite-block effect, which is a common side effect in aligner treatment owing to the 0.38mm thickness that each aligner provides between posterior teeth during the whole treatment. Unanticipated intrusion of the molars would cause the incisors to appear extruded after superimposition (Fig. 10), causing difficulties especially for deep bite cases.¹¹ Lack of intrusion of the lower anterior teeth may limit the upper anterior retraction, as well as molar distalization since the bite was impinged.

Hence, with the intention of achieving an acceptable overjet and overbite, IZC screws were inserted to enhance the force of maxillary retraction.

	Ext	Non
1. Profile	Protrusive	Straight
2. Md. angle	High	Low
3. Bite	Open	Deep
4. Ant. inclination	Flaring	Flat
5. Crowding	> 7 mm	None
6. Decay/ missing	Present	?
7. P't perception	Ok	No
8. Etc...		

Table 3: Chang's Extraction Decision Table

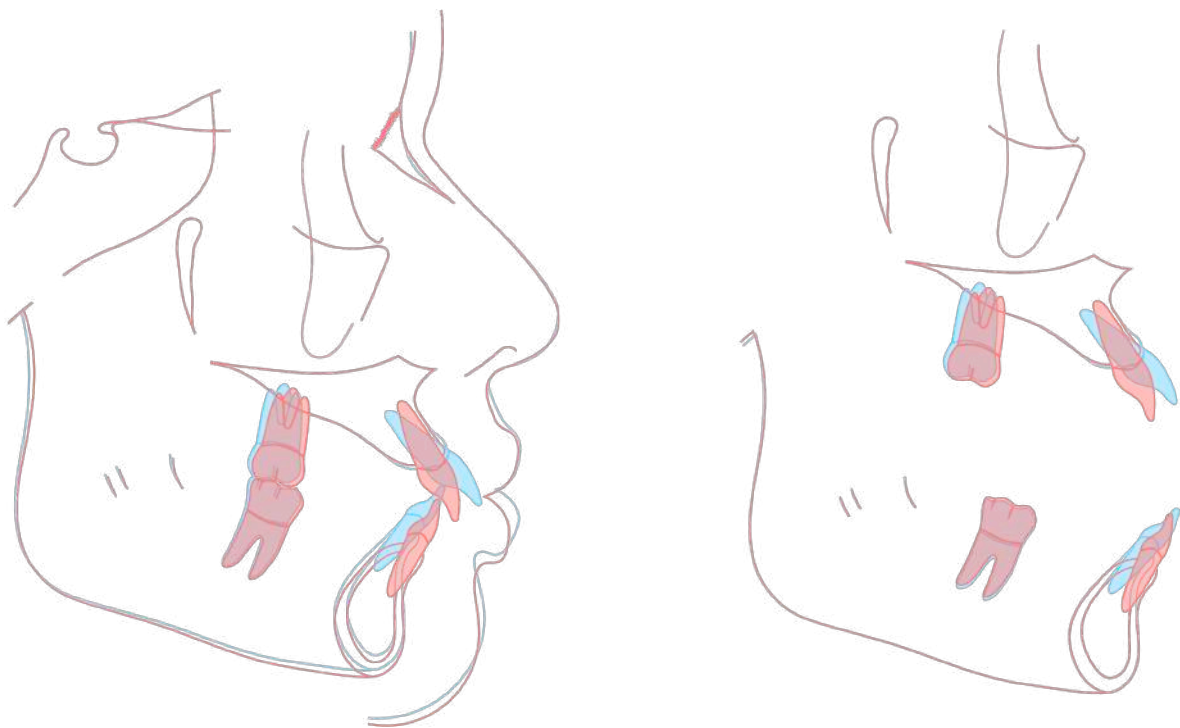


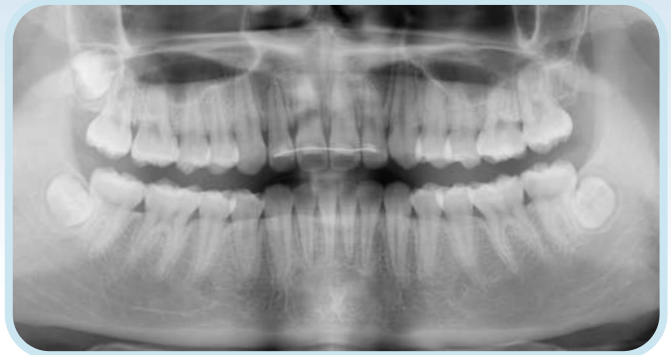
Fig.10: Superimposed cephalometric tracings (pre-treatment: blue; posttreatment: red) indicate that the molar relationship ended in Class I with mandible clockwise rotation. The superimpositions on the right document clockwise rotation of the occlusal plane associated with the retroclination of the upper incisors.

Furthermore, Class II elastics were also applied bilaterally, the buttons were placed on the lower first molars, providing an extrusion force to counteract the intrusion caused by the bite-block effect. Three refinements were also delivered to adjust the dental alignment, and eventually the patient reached a pleasant result with which she was fully satisfied.¹¹

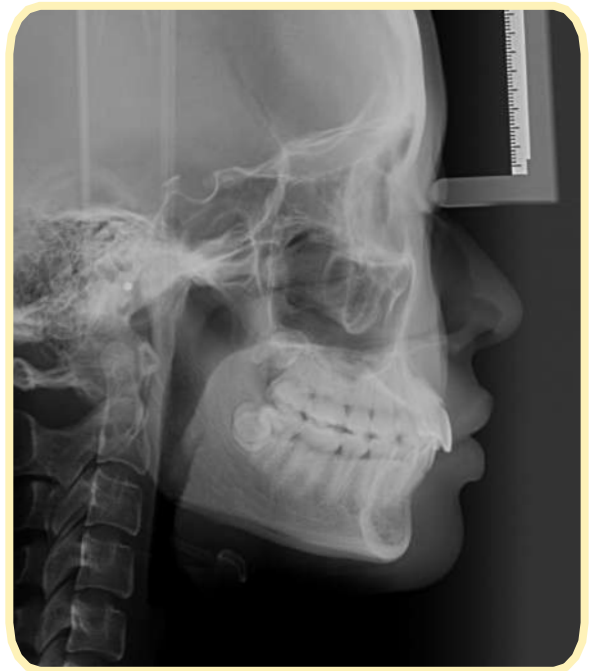In hindsight, anterior virtual bite ramps, which Align Technology recently developed, could be additionally applied to prevent deepening the overbite, which may help decrease the discrepancy between predicted and achieved results.³ In addition, overcorrection of the lower anterior teeth intrusion could be considered since the achieved amount was often inaccurate from the predicted movement.¹¹ The teeth movement sequence could also be rearranged by scheduling intrusion of the lower anterior teeth first before retracting the upper arch to avoid possible obstructions.

Conclusions

This excessive overjet and deep bite case was treated to a pleasant result in 25 months without orthognathic surgery nor extraction. With Chang's extraction decision table (Table 3), a feasible treatment plan was completed with a pleasant outcome. In retrospect, the treatment time could have been decreased by adding virtual anterior bite ramps, overcorrecting the lower anterior teeth intrusion, or rearranging the sequence of teeth movement by intruding the lower anterior teeth first and then retracting the maxillary arch. However, further research is required to minimize the treatment duration and optimize the aligner treatment design.



■ Fig. 11: Posttreatment panoramic radiograph



■ Fig. 12: Posttreatment cephalometric radiograph

References

1. Phan X, Ling PH. Clinical limitations of Invisalign. J Can Dent Assoc 2007;73:263-266.
2. Guarneri MP, Oliverio T, Silvestre I, Lombardo L, Siciliani G. Open bite treatment using clear aligners. Angle Orthod 2013;83:913-919.

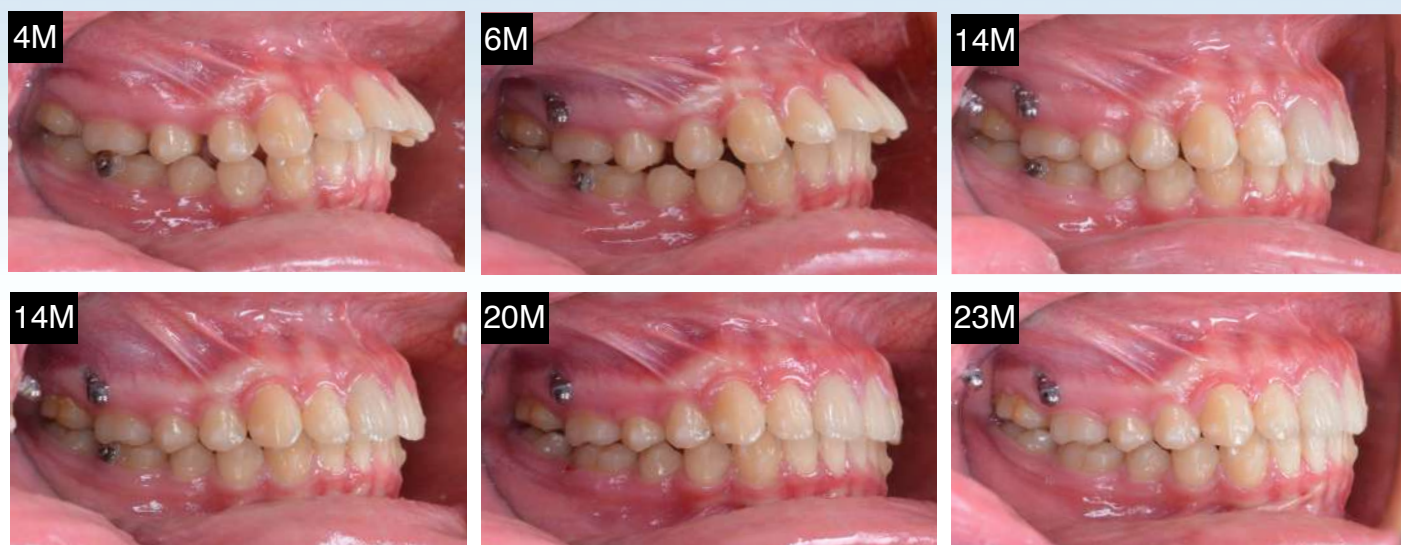

Fig. 13:
Treatment progression from the right buccal view for 23 months (M). In the 6th month (6M), IZC screws were placed with elastics (Chipmunk, 1/8-in, 3.5-oz) hooked bilaterally to retract the maxillary arch.

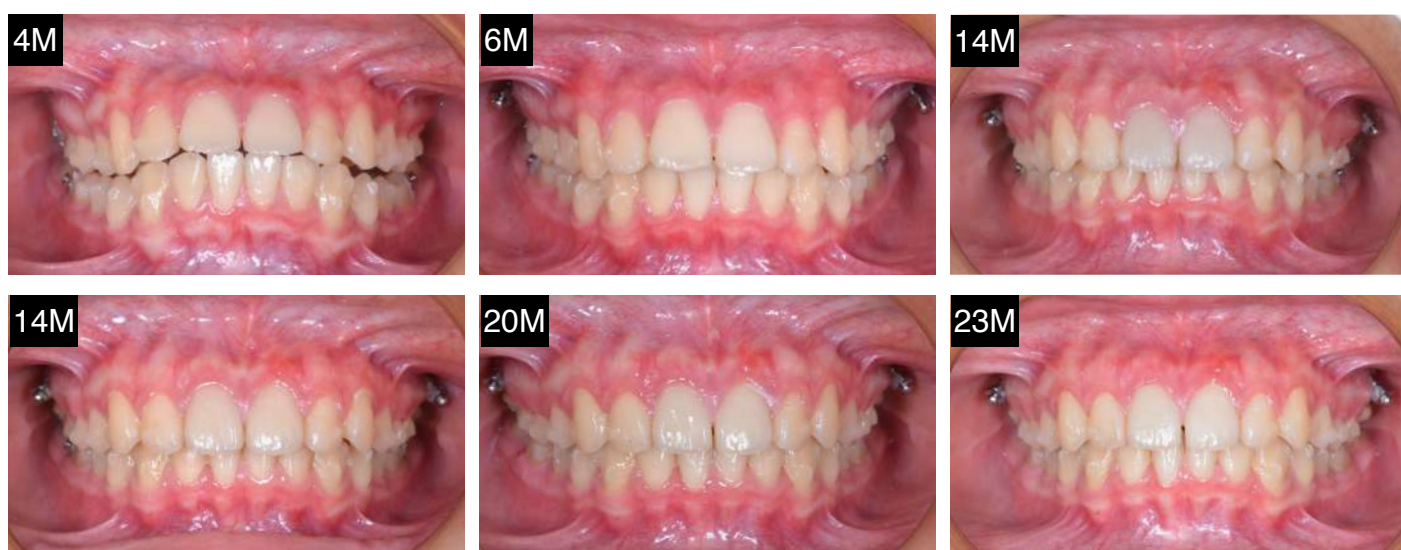
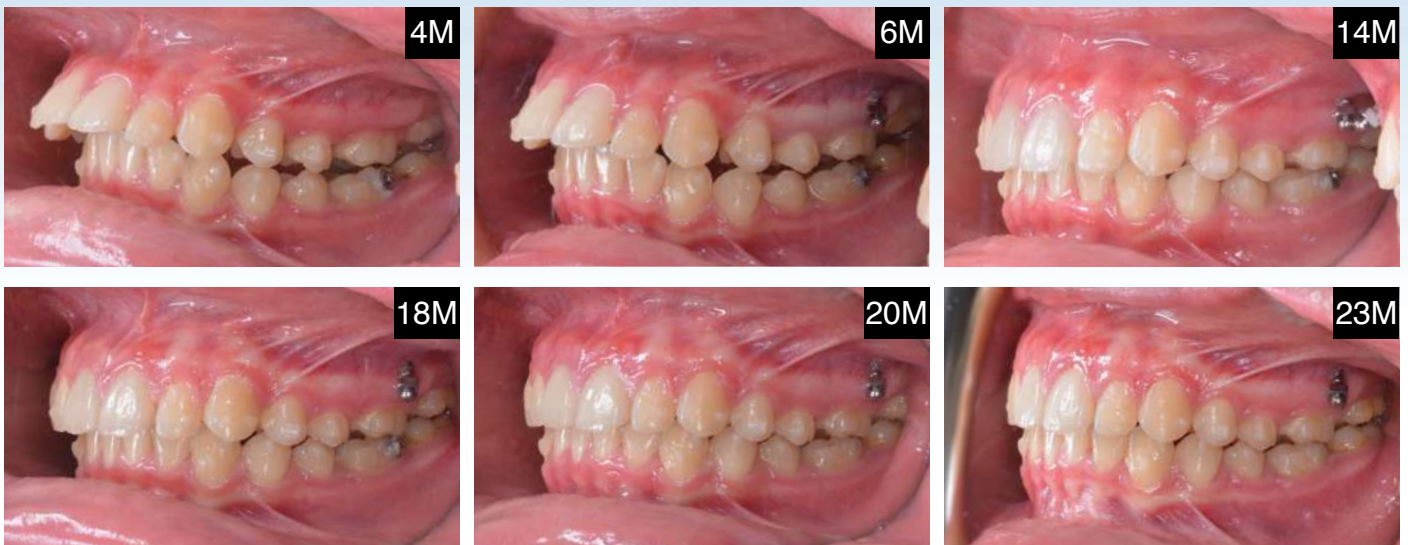

Fig. 14:
Treatment progression from the frontal view for 23 months (M). First set of aligners was finished in the 14th month (14M) but further overbite correction was required. Refinements in the following months gradually achieve ideal occlusion.



■ Fig. 15:

Treatment progression from the left buccal view for 23 months (M). The curve of Spee was progressively flattened during the treatment process.

3. Khosravi R, Cohan B, Hujoel P, Daher S, Neal M, Liu W et al. Management of overbite with the Invisalign appliance. *Am J Orthod Dentofacial Orthop* 2017;151:691-699.e692.
4. Cangialosi TJ, Riolo ML, Owens SE, Jr., Dykhouse VJ, Moffitt AH, Grubb JE et al. The ABO discrepancy index: a measure of case complexity. *Am J Orthod Dentofacial Orthop* 2004;125:270-278.
5. Casco JS, Vaden JL, Kokich VG, Damone J, James RD, Cangialosi TJ et al. Objective grading system for dental casts and panoramic radiographs. American Board of Orthodontics. *Am J Orthod Dentofacial Orthop* 1998;114:589-599.
6. Su B. IBOI Pink and White esthetic score. *Int J Orthod Implantol* 2013;28:80-85.
7. Arraj GP, Rossi-Fedele G, Doğramacı EJ. The association of overjet size and traumatic dental injuries—A systematic review and meta-analysis. *Dent Traumatol* 2019;35:217-232.
8. Proffit WR. *Contemporary Orthodontics*, 4th ed, 2007. p. 308-309.
9. Burstone CJ. Integumental contour and extension patterns. *Angle Orthod* 1959;29:93-104.
10. Ravera S, Castroflorio T, Garino E, Daher S, Cugliari G, Deregibus A. Maxillary molar distalization with aligners in adult patients: a multicenter retrospective study. *Prog Orthod* 2016;17(1):1-9.
11. Charalampakis O, Iliadi A, Ueno H, Oliver DR, Kim KB. Accuracy of clear aligners: A retrospective study of patients who needed refinement. *Am J Orthod Dentofacial Orthop* 2018;154:47-54.



Discrepancy Index Worksheet

TOTAL D.I. SCORE **35**

OVREJET

0 mm. (edge-to-edge) =
 1 - 3 mm. = 0 pts.
 3.1 - 5 mm. = 2 pts.
 5.1 - 7 mm. = 3 pts.
 7.1 - 9 mm. = 4 pts.
 > 9 mm. = 5 pts.

Negative OJ (x-bite) 1 pt. per mm. Per tooth =

Total = **4**

OVERBITE

0 - 3 mm. = 0 pts.
 3.1 - 5 mm. = 2 pts.
 5.1 - 7 mm. = 3 pts.
 Impinging (100%) = 5 pts.

Total = **2**

ANTERIOR OPEN BITE

0 mm. (Edge-to-edge), 1 pt. per tooth
 Then 1 pt. per additional full mm. Per tooth

Total = **0**

LATERAL OPEN BITE

2 pts. per mm. Per tooth

Total = **0**

CROWDING (only one arch)

1 - 3 mm. = 1 pt.
 3.1 - 5 mm. = 2 pts.
 5.1 - 7 mm. = 4 pts.
 > 7 mm. = 7 pts.

Total = **0**

OCCLUSION

Class I to end on = 0 pts.
 End on Class II or III = 2 pts. per side _____ pts.
 Full Class II or III = 4 pts. per side _____ pts.
 Beyond Class II or III = 1 pt. per mm. _____ pts.
 additional

Total = **2**

LINGUAL POSTERIOR X-BITE

1 pt. per tooth Total = **0**

BUCCAL POSTERIOR X-BITE

2 pts. Per tooth Total = **0**

CEPHALOMETRICS (See Instructions)

ANB $\geq 6^\circ$ or $\leq -2^\circ$ = 4 pts.

Each degree $< -2^\circ$ _____ x 1 pt. = _____

Each degree $> 6^\circ$ _____ x 1 pt. = _____

SN-MP

$\geq 38^\circ$ = 2 pts.

Each degree $> 38^\circ$ _____ x 2 pts. = _____

$\leq 26^\circ$ = **1 pt.**

Each degree $< 26^\circ$ **2** x 1 pt. = **2**

1 to MP $\geq 99^\circ$ = **1 pt.**

Each degree $> 99^\circ$ **21** x 1 pt. = **21**

Total = **25**

OTHER (See Instructions)

Supernumerary teeth _____ x 1 pt. = _____

Ankylosis of perm. Teeth _____ x 2 pts. = _____

Anomalous morphology _____ x 2 pts. = _____

Impaction (except 3rd molars) _____ x 2 pts. = _____

Midline discrepancy (≥ 3 mm) @ 2 pts. = _____

Missing teeth (except 3rd molars) _____ x 1 pt. = _____

Missing teeth, congenital _____ x 2 pts. = _____

Spacing (4 or more, per arch) _____ x 2 pts. = **2**

Spacing (Mx cent. diastema ≥ 2 mm) @ 2 pts. = _____

Tooth transposition _____ x 2 pts. = _____

Skeletal asymmetry (nonsurgical tx) @ 3 pts. = _____

Addl. treatment complexities _____ x 2 pts. = _____

Identify:

Total = **2**

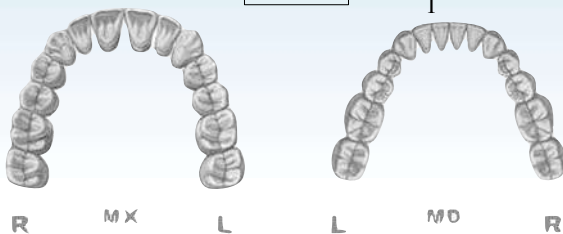
Cast-Radiograph Evaluation

Total Score:

12

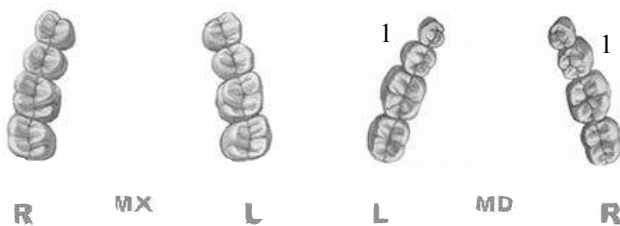
Alignment/Rotations

1



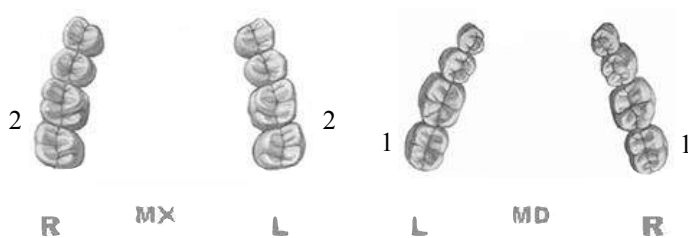
Marginal Ridges

2



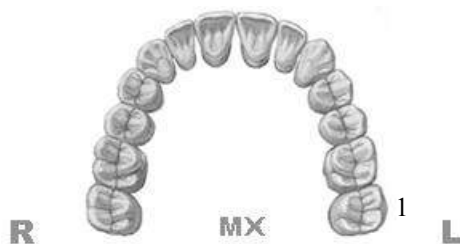Buccolingual Inclination

6



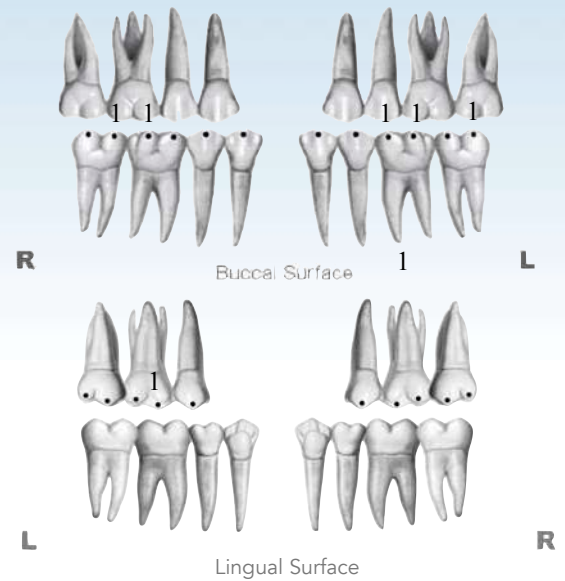
Overjet

0



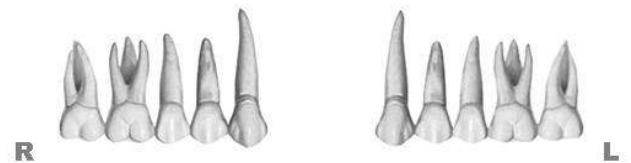Occlusal Contacts

1



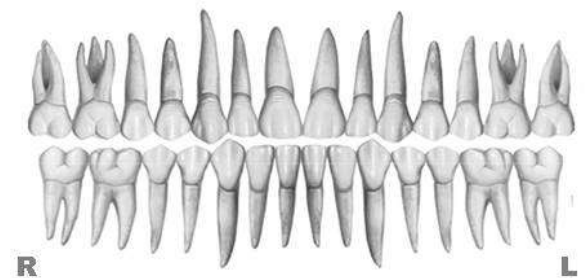
Occlusal Relationships

0



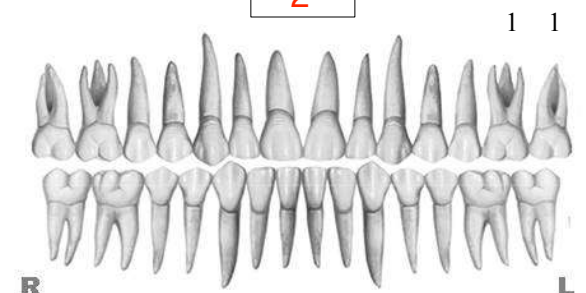
Interproximal Contacts

0



Root Angulation

2



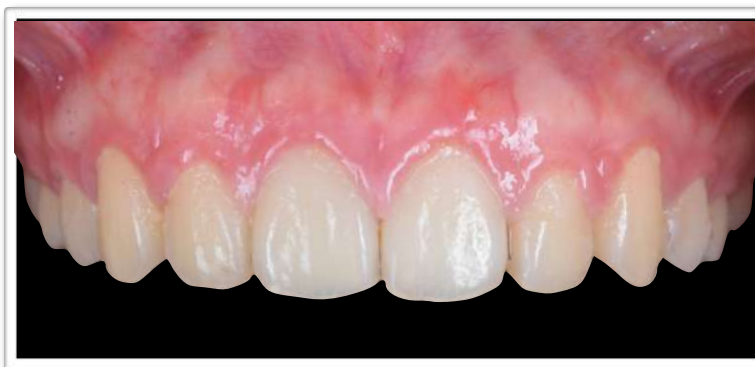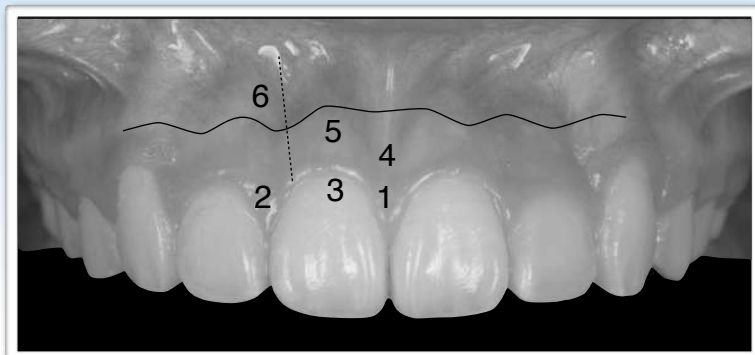
INSTRUCTIONS: Place score beside each deficient tooth and enter total score for each parameter in the white box. Mark extracted teeth with "X". Second molars should be in occlusion.

IBOI Pink & White Esthetic Score

Total Score =

4

1. Pink Esthetic Score



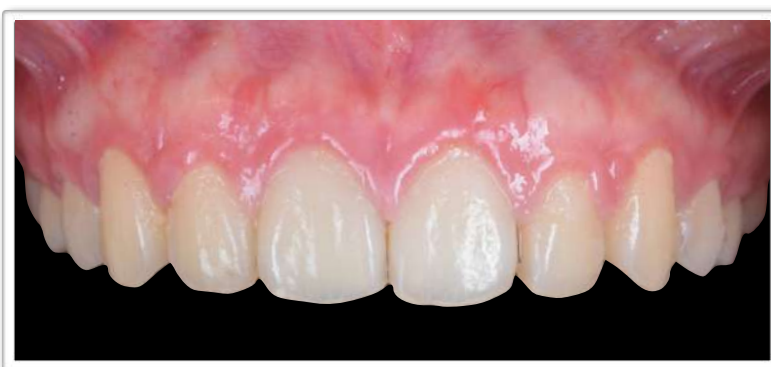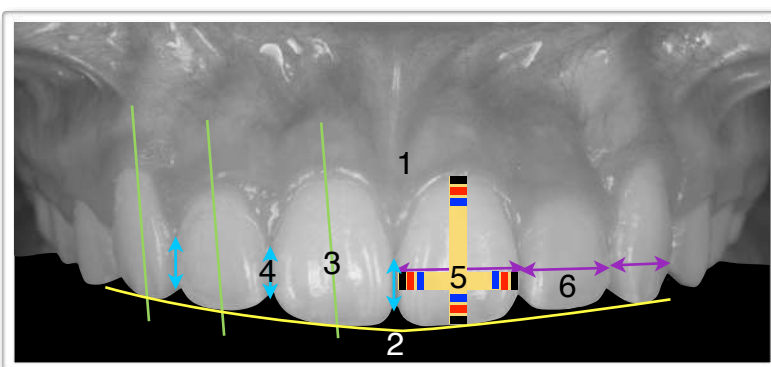
1. M & D Papillae	0	1	2
2. Keratinized Gingiva	0	1	2
3. Curvature of Gingival Margin	0	1	2
4. Level of Gingival Margin	0	1	2
5. Root Convexity (Torque)	0	1	2
6. Scar Formation	0	1	2

Total =

1

1. M & D Papillae	0	1	2
2. Keratinized Gingiva	0	1	2
3. Curvature of Gingival Margin	0	1	2
4. Level of Gingival Margin	0	1	2
5. Root Convexity (Torque)	0	1	2
6. Scar Formation	0	1	2

2. White Esthetic Score (for Micro-esthetic)



1. Midline	0	1	2
2. Incisor Curve	0	1	2
3. Axial Inclination (5°, 8°, 10°)	0	1	2
4. Contact Area (50%, 40%, 30%)	0	1	2
5. Tooth Proportion	0	1	2
6. Tooth to Tooth Proportion	0	1	2

Total =

3

1. Midline	0	1	2
2. Incisor Curve	0	1	2
3. Axial Inclination (5°, 8°, 10°)	0	1	2
4. Contact Area (50%, 40%, 30%)	0	1	2
5. Tooth Proportion	0	1	2
6. Tooth to Tooth Proportion	0	1	2



OBS Super Set

Created by Dr. Chris Chang, OBS is made of medical grade, stainless steel and titanium, and is highly praised by doctors for its simplistic design, low failure rate and excellent quality. OBS is your must-have secret weapon for maximum, reliable anchorage.



Smooth Mushroom Head

For comfort & retention of elastic chain

4-way Rectangular Holes

For lever arm to solve impacted tooth

Double Neck Design

Easy hygiene control & extra attachment



Made in Taiwan

New **Titanium** Higher biocompatibility*

1.5 | 1.5X8mm

Stainless Steel**

2.0 | 2.0x12mm

2.7 | 2.0x14mm (with holes)

Buy a Super Set, get **OBS Clinical Guide** (eBook) for free.



* TADs made of Ti alloy have a lower failure rate compared to SS when placed in thin cortical bone. These results are consistent with a biocompatibility-related tendency for less bone resorption at the bone screw interface. Reference: Failure Rates for SS and Ti-Alloy Incisal Anchorage Screws: Single-Center, Double Blind, Randomized Clinical Trial (J Digital Orthod 2018;52:70-79)

** The overall success rate of 93.7% indicates that both SS and TiA are clinically acceptable for IZC BSs.

Reference: Failure rates for stainless steel versus titanium alloy infrazygomatic crest bone screws: A single-center, randomized double-blind clinical trial (Angle Orthod 2019;89(1):40-46)