

Efficient Correction of Crowded Anterior Crossbite: Passive Self-Ligating Brackets and Anterior Bite Turbos

Abstract

Etiology: A 16-year-5-month-old female presented with chief complaints of anterior crossbite and crowding. Past medical history was non-contributory, but dental history revealed that the upper left second premolar was extracted because of a blocked-in position.

Diagnosis: Extra-oral examination revealed a symmetric, but long tapered face in the frontal view, with a SN-MP angle of 39°. The facial profile was convex with competent lips, and the lower lip was protrusive. There was an asymmetric Class III (right) and Class II (left) molar relationship, anterior crossbite, intermaxillary crowding, and a missing upper left (UL) second premolar. The Discrepancy Index (DI) was 27.

Treatment: This challenging malocclusion was efficiently corrected with a passive self-ligating fixed appliance, anterior bite turbos, progressive archwires, and intermaxillary elastics. After only 16 months of active treatment, the patient was satisfied with the result, and requested appliance removal prior to the planned completion of treatment.

Results: Lip profile was improved, and there was no lip strain when the patient smiled naturally. After 16 months of active treatment, the dental outcomes were acceptable, with a Cast Radiograph Evaluation (CRE) score of 24 and a Pink & White dental esthetic score of 7, but the result could have been improved with more detailed finishing. (J Digital Orthod 2021;62:74-90)

Key words:

Anterior cross bite, extraction, asymmetric Class II and III, passive self-ligating appliance, crowding

Introduction

Class III malocclusion among Taiwanese, Japanese, Chinese, and Korean is relatively common, with a prevalence rate of 15-23%,¹ compared to a 2-6% rate among European caucasians.^{2,3} Etiology of Class III malocclusion may reflect deficient maxillary growth, and/or overgrowth of the mandible. Maxillary deficiency may be due to deficient sutural growth or stenosis, but overgrowth of the mandible has less physiologic basis as a primary mechanism.⁴ Mandibular prognathism may have a secondary etiology such as anterior posturing

of the mandible due to a functional problem like maintaining airway patency.⁴ Efficient conservative treatment for Class III malocclusion depends on a valid differential diagnosis. Despite a large negative overjet and sagittal discrepancy, Class III patients, with an orthognathic profile in the centric relation (C_R) position of the mandible, can usually be treated with a non-surgical approach. The 3-ring diagnosis proposed by John Lin⁵ is a useful diagnostic method for identifying patients with a good prognosis for conservative treatment.

Chia-Wei Liu,
Orthodontist, Ming-Hao Dental Clinic (Left)

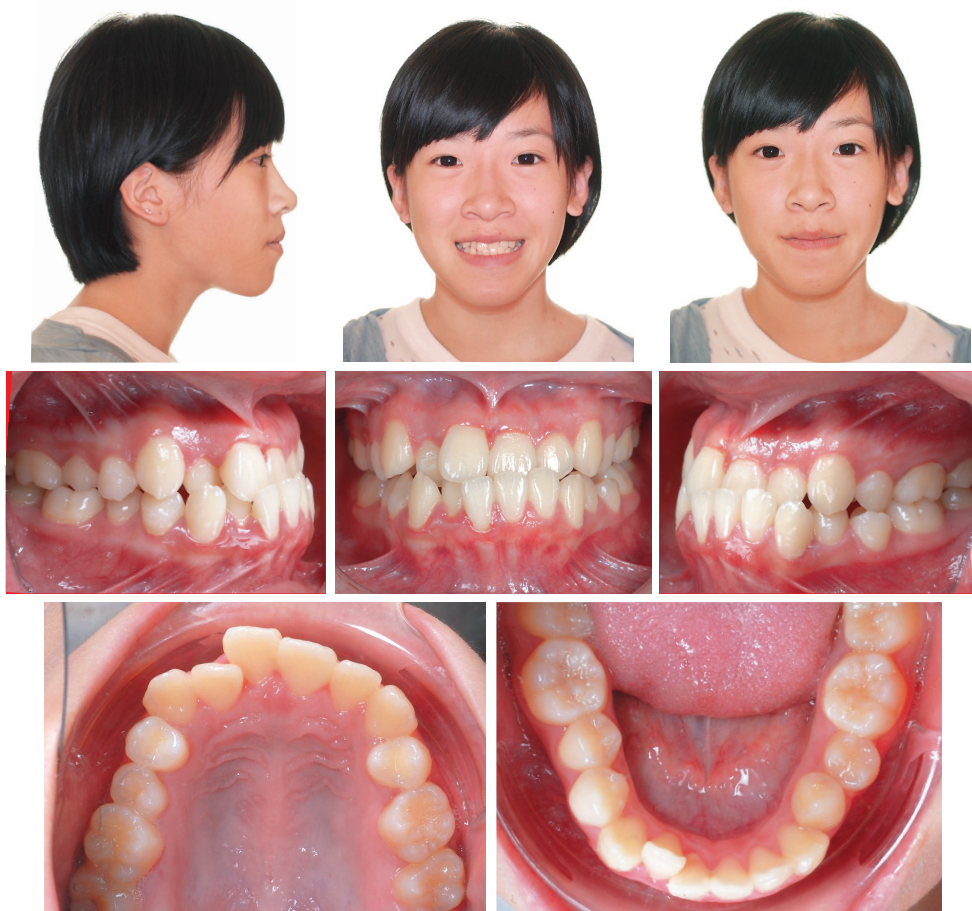Chris H. Chang,
Founder, Beethoven Orthodontic Center
Publisher, Journal of Digital Orthodontics (Center)

W. Eugene Roberts,
Editor-in-Chief, Journal of Digital Orthodontics (Right)



Anterior crossbite is a common dental trait in Asian patients with a prevalence of 18.6% in Japanese adolescents (age 12-15 years).⁶ An unpublished study by the authors had a similar result (17.9%) for Taiwanese adolescents (age 15-16 years). Anterior crossbite is an easily perceived, negative trait that is frequently the chief complaint which leads parents to seek early orthodontic correction for young patients.⁷ Orthodontic literature advocates early treatment of anterior crossbite to avoid restriction

of maxillary growth,^{8,9} but Sugawara et al.¹⁰ failed to show an advantage for early treatment with a chin-cup started at age 7 years because the patients demonstrated catch-up growth. Excessive mandibular growth in adolescents is a well-known problem for skeletal Class III patients.⁹ Clinicians considering early treatment are advised to use the Lin's⁵ 3-ring method for a reliable differential diagnosis to identify patients with a good prognosis.



■ Fig. 1: Pre-treatment facial and intraoral photographs

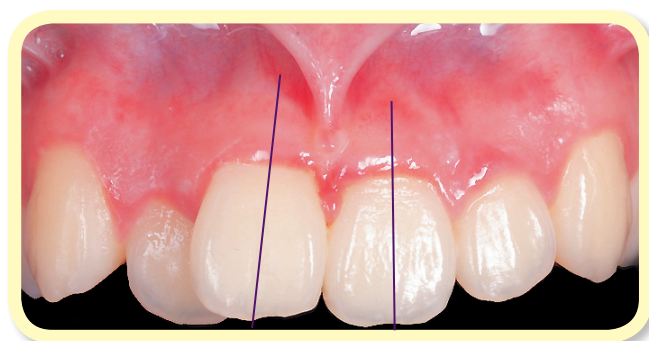
There are multiple approaches to treating asymmetric anterior crossbite with crowding. Huang, Chang, and Roberts¹¹ proposed 6 methods for the correction of anterior crossbite, depending on dental factors and skeletal diagnosis. Removable bite-plates with lingual springs and tongue-blade exercises are advocated by some clinicians,¹² but the current authors prefer a more efficient correction with a Damon passive self-ligating (PSL) fixed appliance (Ormco, Glendora, CA), and anterior bite turbos.

Diagnosis and Etiology

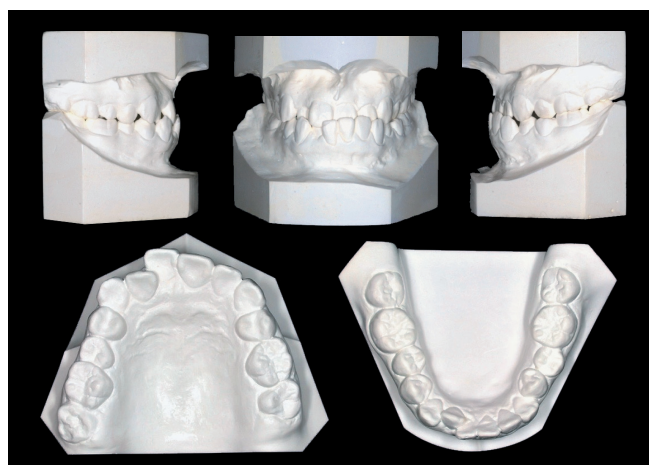A 16yr-5mo-old female presented for orthodontic evaluation with chief complaints of anterior crossbite and crowding (Fig. 1). Past medical history was non-contributory, but the upper left second premolar was extracted because of a blocked-in position. Extra-oral examination revealed a symmetrical, long tapered face in the frontal view. The facial profile was convex but within normal limits (WNL). The patient resisted smiling with her teeth exposure due to crowding and inclination of incisors in the maxillary arch (Figs. 1-3).

There were no signs or symptoms of temporomandibular disorder (TMD), and no mandibular deviation on opening was noted. Intraoral examination revealed an anterior crossbite of -2mm, and an asymmetric molar relationship: 7mm Class III on the right and end-on Class II on the left (Figs. 1 and 2). The maxillary dental midline was oblique because the central incisors were tipped to the right (Fig. 2), and the mandibular midline was 2mm to the left. The upper left first premolar and lower

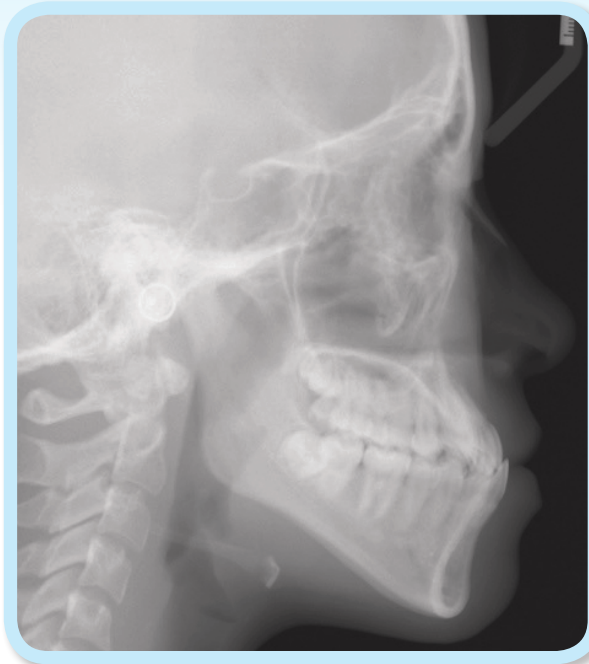left second premolar were in lingual crossbite, and the upper left second premolar was missing (Fig. 1). Crowding was 5mm in the upper arch and 7mm in the lower arch. The pre-treatment cephalometric analysis (Fig. 4; Table 1) showed a 1° ANB and a 39° SN-MP angle. There were no dental or pathological abnormalities noted in the pre-treatment panoramic radiograph (Fig. 5). Four developing third molars were present, and both lower third molars were impacted. The American Board of Orthodontic (ABO) Discrepancy Index (DI) was 27 points, as shown in the supplementary Worksheet 1.¹³



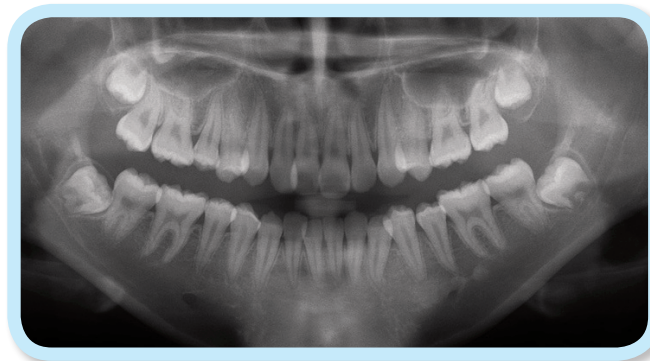■ Fig. 2:
The maxillary midline is oblique due to the abnormal inclination of the incisors.



■ Fig. 3: Pre-treatment study models (casts)



■ Fig. 4: Pre-treatment lateral cephalometric radiograph



■ Fig. 5: Pre-treatment panoramic radiograph

Treatment Objectives

The following treatment objectives were specified for the preferred approach, **Option 1**:

1. Maintain the skeletal pattern in all three skeletal planes for both jaws.

CEPHALOMETRIC SUMMARY			
SKELETAL ANALYSIS			
	PRE-Tx	POST-Tx	DIFF.
SNA° (82°)	82.5°	82.5°	0°
SNB° (80°)	81°	81°	0°
ANB° (2°)	1°	1°	0°
SN-MP° (32°)	39°	40°	1°
FMA° (25°)	32°	33°	1°
DENTAL ANALYSIS			
U1 To NAm (4mm)	5	5	0
U1 To SN° (110°)	105.5°	102°	3.5°
L1 To NBmm (4mm)	8.5	4	4.5
L1 To MP° (90°)	85°	75.5°	9.5°
FACIAL ANALYSIS			
E-LINE UL (-1mm)	-2	-1.5	0.5
E-LINE LL (0mm)	2	-1.5	3.5
%FH: Na-ANS-Gn (53±3%)	56.5%	56%	0.5%
Convexity: G-Sn-Pg' (13°)	19°	21°	2°

■ Table 1: Cephalometric summary

2. Extract the upper right second premolar and both lower first premolars to: a. relieve crowding, b. help correct the molar relationship, and c. facilitate anterior crossbite correction.
3. Use a full fixed PSL appliance to level and align both arches.
4. Use anterior bite turbos to unlock the maxillary anterior teeth; correct the anterior crossbite with archwire configuration and Class III intermaxillary elastics.
5. Correct posterior crossbites with archwire alignment, supplemented with cross-elastics as needed.

6. Midline correction with intermaxillary elastics.
7. Optimize occlusion with finishing bends and up-and-down elastics.

Treatment Alternatives

Option 2: Impacted lower third molars may cause problems in the future, but extraction prior to treatment requires flap surgery, and there could be periodontal problems distal to the second molars. Extraction of both lower second molars instead of first premolars might be a wise choice because the third molars in the radiographs appear to be good substitutes for the second molars. However, that approach would result in Class II buccal segments, and possibly a longer treatment time. In the maxillary arch, extraction of the upper right second premolar remains the best option for relieving crowding and correcting the midline.

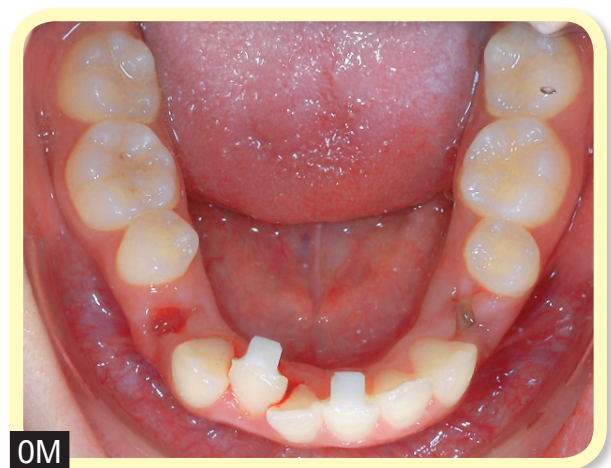Option 3: Extraction of only the maxillary second premolar is a viable approach if there was no interference with the correction of the anterior crossbite. With this option, brackets are bonded to the upper arch first, and an inclined plane or inclined anterior bite turbos are bonded to the lower anterior teeth. The anterior crossbite should be corrected prior to the extraction. If the crowding in the lower arch is still present after alignment, interproximal reduction (IPR) of the lower anterior teeth and intermaxillary elastics are indicated. The disadvantage of this option is a more convex face with a protrusive upper lip after treatment.

The patient considered all the options, but was

concerned about lip protrusion and an extended treatment time. She opted for option 1, and agreed to extraction of the three premolars.

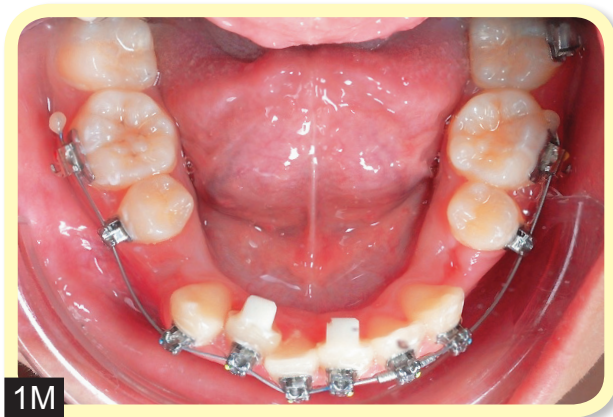
Treatment Progress

The maxillary right second premolar and the lower first premolars were extracted prior to active treatment. The Damon D3MX 0.022-in PSL bracket system (*Ormco, Glendora, CA*) was used for both arches. All elastics, archwires, and auxiliaries were provided by the same manufacturer. PSL brackets were bonded on the maxillary arch with low-torque brackets on the upper anterior teeth. At the same appointment, the anterior bite turbos were bonded to the lingual surface of the lower right lateral incisor, and the lower left central incisor to open the bite for anterior crossbite correction (*Fig. 6*). The patient was also instructed to use a tongue blade as often as possible to manually correct the anterior crossbite. One month later (1M), brackets were bonded to the lower dentition, and standard-torque brackets were used for the lower anterior teeth. The

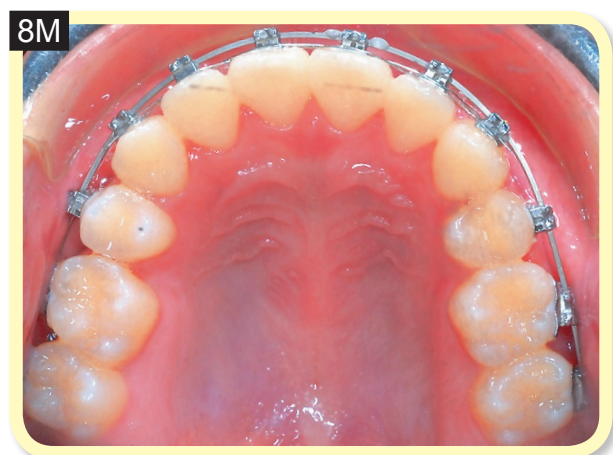

■ *Fig. 6: Lower anterior bite turbos were used to open the bite.*

lower second molars were not bonded to avoid mucosal irritation at the distal end of the archwire (Fig. 7). Within 8 months (8M), the anterior crossbite was corrected, and the bite turbos were removed (Fig. 8). The extraction space on the upper right closed spontaneously due to correction of crowding and mesial drift of the adjacent molar (Fig. 8). In the 9th

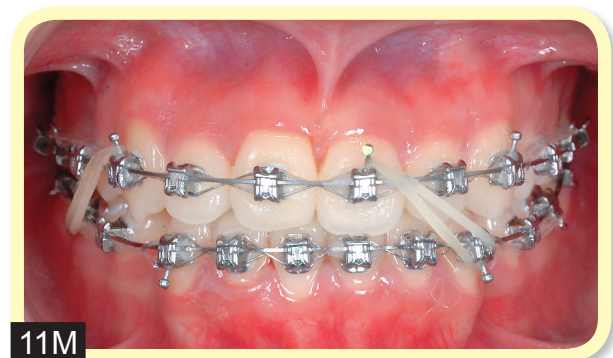

■ **Fig. 7:**
Extension of the 0.014x0.025-in CuNiTi archwire through the 2nd molars is not essential if it is expected that the subsequent archwire can engage the molar tubes of the 2nd molars easily. This approach helps to avoid discomfort to the patient.



■ **Fig. 8:**
The upper right extraction space closed spontaneously during initial alignment.

month, 0.016x0.025-in stainless steel (SS) archwires were placed, and elastomeric chains were used to retain space closure. Bilateral Class II elastics (*Bear*, 4.5-oz, *Ormco*, *Glendora, California*) were stretched between the upper canine and lower first molar to facilitate space closure and achieve a better molar relationship.¹⁴ In the 11th month (11M), a hook was installed on the bracket of upper left central incisor, and an intermaxillary elastic was applied from the upper left central incisor to the lower left canine to correct the 2mm midline discrepancy (Fig. 9). In the 12th month, the midline problem was not resolved, so a frenectomy of the hypertrophic upper labial frenum was suggested, which was rejected by the patient. In the 14th month, bilateral N-shape up-and-down elastics (*Ostrich*, 2-oz) were applied between the posterior teeth bilaterally to enhance maximum intercuspation. In the 16th month, the patient was satisfied with the progress and preferred to end treatment. All the fixed appliance were removed, and fixed retainers were bonded on the lingual surfaces of all incisors in the maxillary arch, as well as from canine to canine in the lower arch. Upper and lower clear overlay retainers were delivered.



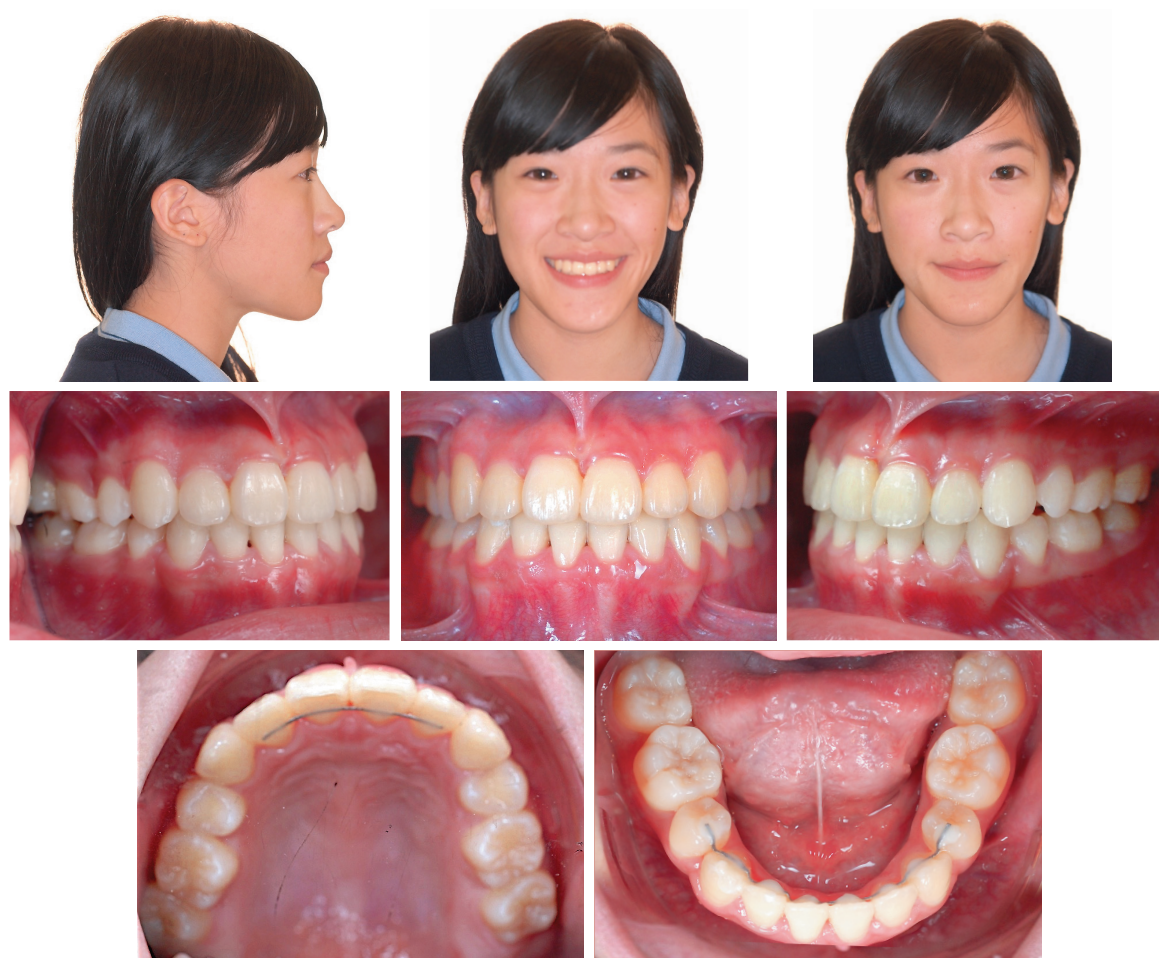■ **Fig. 9:**
An intermaxillary elastic from the upper left central incisor to the lower left canine was used to correct the midline.

The patient was instructed to wear them full-time for 6 months and nights only thereafter. Instructions were provided for home dental care, as well as for maintenance of the retainers.

Treatment Results

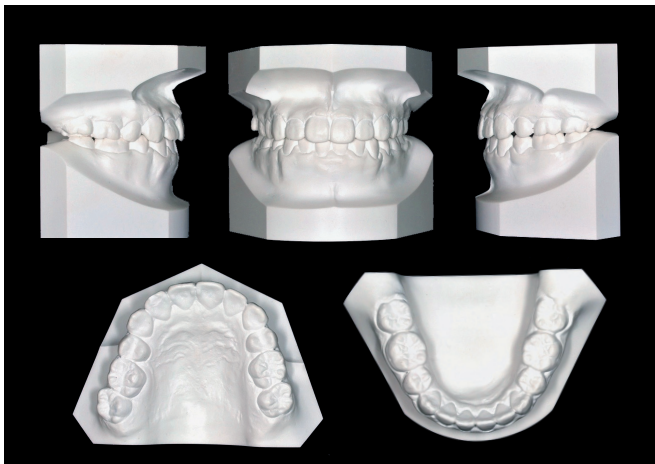Lip profile was improved, there was no lip strain, and the patient was able to smile naturally (Fig. 10). The teeth were well aligned, with Class I buccal segments on the right side, but there was a Class

II buccal relationship on the left side (Fig. 11). The patient was satisfied with the progress at this stage and requested that the brackets be removed prior to completion of treatment. The ABO Cast-Radiograph Evaluation (CRE)¹⁵ score is 24 as shown in Worksheet 2. This is an adequate finish for a patient with a DI score of 27, particularly since treatment was terminated with only 16 months of active treatment. However, two additional months of treatment would probably decrease the CRE considerably. The major unresolved alignment problems were mild rotations

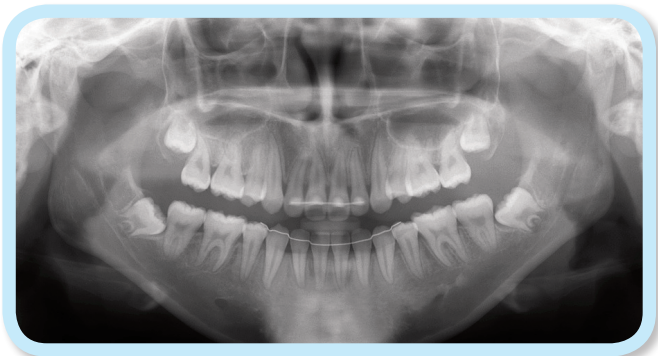

■ Fig. 10: Post-treatment facial and intraoral photographs

(6 points), marginal ridge discrepancies (8 points), and occlusal relationships (4 Points). Many of these deficiencies could have been corrected by detailing bends in an 0.018-in SS wire. The post-treatment panoramic radiograph (Fig. 12) reveals that the root of upper left second premolar and first molar converge apically; therefore, 1 point was deducted. The post-treatment cephalometric radiograph and the superimposition of cephalometric tracings document the dentofacial changes achieved during treatment (Figs. 13 and 14).



■ Fig. 11: Post-treatment study models (casts)

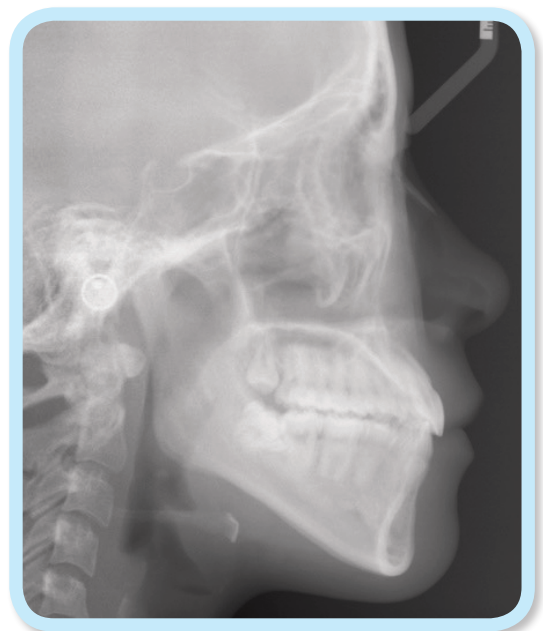

■ Fig. 12: Post-treatment panoramic radiograph

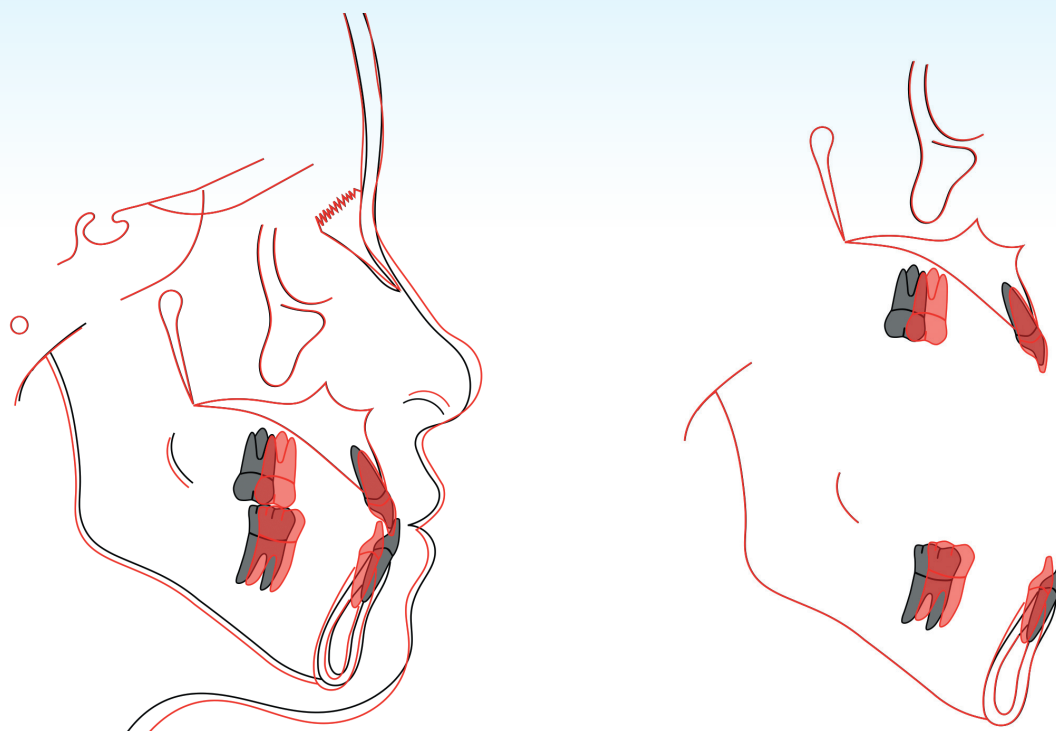
Discussion

Treatment for Anterior Crossbite

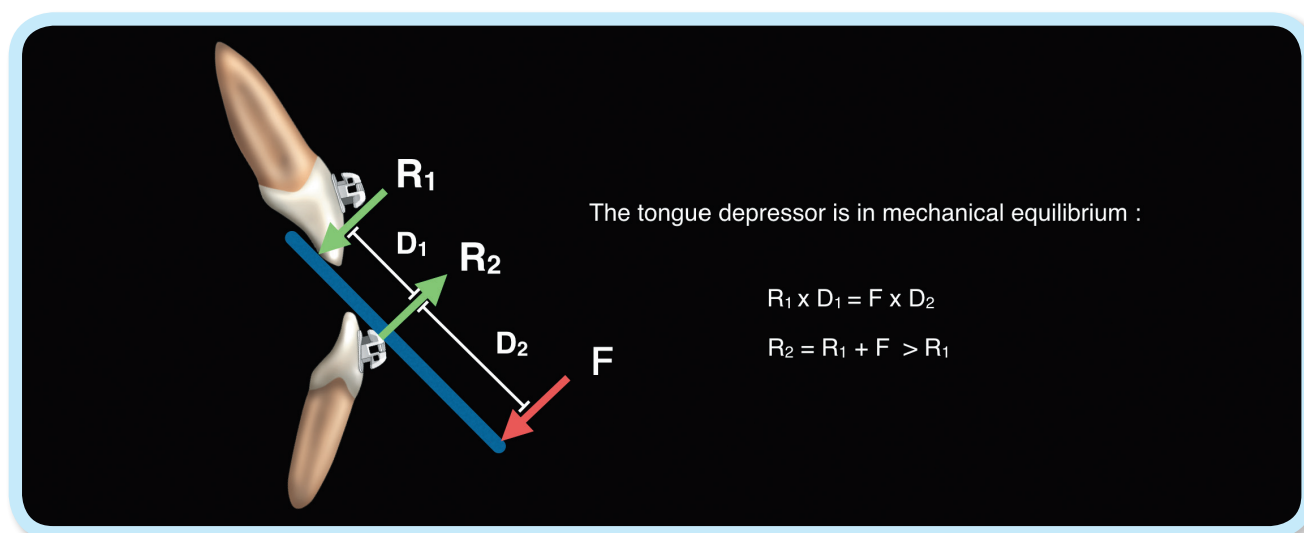
There are several methods for treating anterior crossbite with either fixed or removable appliances.⁷⁻¹² A tongue blade is an easy and inexpensive device for correcting anterior crossbite of one or two teeth. The patient was instructed to use the device during leisure time. The tongue blade is placed between the anterior teeth in crossbite and deflected inferiorly so that the lower dentition serves as a fulcrum. The mechanics exerts labial force against the lingually-inclined maxillary anterior teeth and lingual force against the lower teeth (Fig. 15). This simple appliance corrects anterior crossbite ver effectively if the patient is compliant. Unlike other removable appliances, a tongue blade



■ Fig. 13: Post-treatment cephalometric radiograph



■ Fig. 14: Superimposed pre-treatment (black) and post-treatment (red) cephalometric tracings document the dental and facial changes.



■ Fig. 15:

For anterior crossbite correction, a tongue blade (blue line) is placed between the upper and lower anterior teeth to exert labial force (the reactive force of R_1) to the upper incisor and lingual force (the reactive force of R_2) to the lower incisor when force (F) is applied by pressing a finger down at the end of the tongue blade. This device is a Class I lever with the lower teeth serving as the fulcrum. Note that the force exerted to the lower teeth is greater than that exerted to the upper teeth.

requires manual activation by the patient. The same result can be accomplished with tongue pressure, but that approach is less likely to achieve adequate compliance, compared to a more obvious device such as a tongue blade used at a planned frequency and duration.

Fixed appliances are usually more predictable, and are particularly effective if tipping of the maxillary dentition is the primary problem. However, archwire activation produces occlusal trauma unless the bite is opened with a removable orthotic or bite turbos. Anterior bite turbos have two important effects: 1. removing the occlusal interference, and 2. rotating the mandible posteriorly, which decreases the negative overjet. For severe negative overjet, early light short Class III elastics are an effective adjunct to the crossbite mechanics.

Torque Selection

A finishing archwire (0.016x0.025-in SS) has about $\pm 20^\circ$ play between the bracket lumen and the archwire.¹⁶ Bracket torque selection is important to control dental axial inclinations during treatment. The axial inclination of the incisors is a particular concern when they are moved in the sagittal plane. Low-torque brackets are used for the upper arch because of the Class III intermaxillary elastics tend to flare the incisors. The expression of low torque offsets this flaring effect.^{8,11} However, the current patient required supplemental mechanics because she had an asymmetric Class II/III malocclusion with minimal negative overjet. The anterior crossbite was corrected before placing the first rectangular

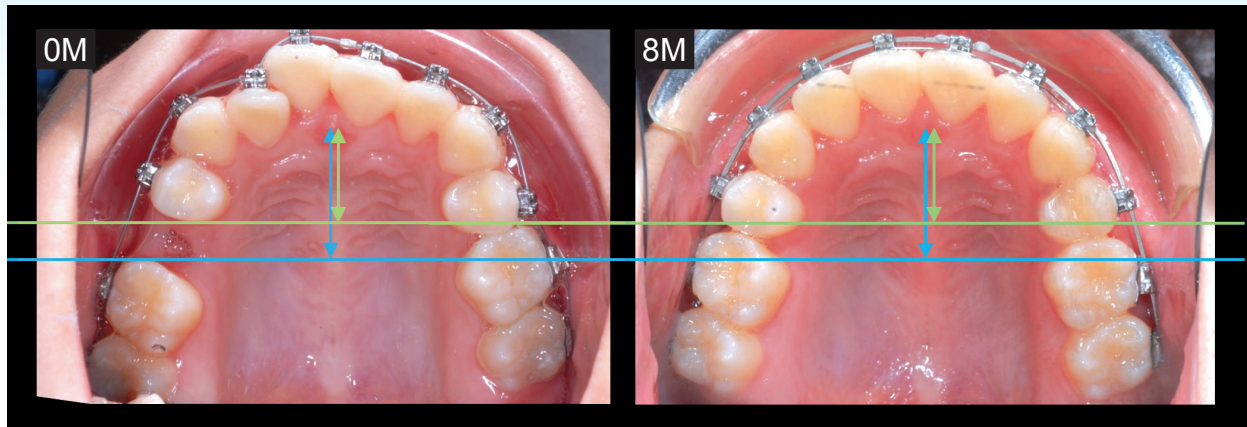
archwire: 0.017x0.025-inch TMA. Furthermore, Class II elastics were used during mandibular posterior space closure to protract the molars, and prevent lingual tipping of the lower incisors. In retrospect, standard-torque brackets were indicated for the maxillary incisors to increase the U1 to SN angle (105.5° pretreatment, see Table 1), and high-torque brackets were a better choice for the lower arch to increase the L1 to MP angle (85° compared to norm 90°).¹⁷

Space Closure Without Elastics

The extraction site for the upper right second premolar closed spontaneously during the initial alignment phase. More than half of the space closure appeared to be due to mesial movement of the upper right first molar (Fig. 16). Low bone density and the tripod configuration of the roots are conducive factors for mesial drift of maxillary molars into edentulous spaces.¹⁸⁻¹⁹ The actual forces exerted on the maxillary right first molar to produce mesial migration are unknown, but it is well established that first molars move mesially into edentulous spaces as the second and third molars erupt.^{16,18,19}

Frenum and Tooth Position

Soft tissue posture is an important etiologic factor in malocclusion and longterm stability,²⁰ because light continuous forces are effective for eliciting tooth movement.²¹ Resting posture of the lips, tongue and cheeks exert constant light forces on the dentition.^{20,21} Net forces on the buccal and lingual surfaces result in an equilibrium zone where



■ Fig. 16:

The position of the upper right first molar is compared in standardized intraoral photographs immediately after bracket bonding (0M) and eight months (8M) later, respectively. Utilizing the incisive papilla as landmark, the mesial drift of the upper right 1st molar is shown by a blue and green lines that define the length of the extraction site at the start of treatment. Although there was some distal drift of the first premolar, the extraction site was closed in 8 months primarily by mesial drift of the molar.

tooth position is stable. Orthodontic therapy moving teeth outside the boundaries of the equilibrium zone is subject to relapse unless there is permanent retention.^{22,23} The etiology of some malocclusions are attributed to the constant force of tongue posture, but not to short duration tongue thrusting.^{16,20,21} Evaluating all functional forces is important for establishing the etiology of a malocclusion, and effectively correcting it. For instance, open bites are typically tongue posture problems, and the abnormal posture must be corrected to achieve a stable result.^{16,20}

A hypertrophic maxillary frenum may be the etiologic factor in some midline diastemas.^{24,25} Sometimes the diastema closes spontaneously after frenectomy,²⁶ but it is more predictable to combine frenectomy with concomitant orthodontic treatment to close the space.²⁴ Proffit¹⁶ recommends

frenectomy after the orthodontic treatment, and only if there's a tendency for the diastema to reopen, due to excessive soft tissue mass in the midline area. The asymmetric midline problem for the current patient (Figs. 2 and 3) is associated with tipping of the maxillary central incisors. If crossbite correction does not solve the problem, unilateral intermaxillary elastics are indicated.

Distal Tipping of Mandibular Second Molar During Retention Period

At the four-year recall after active treatment, the mandibular second molar roots were displaced mesially, apparently due to pressure associated with development of the adjacent third molars (Figs. 17 and 18). There is no clear consensus that developing third molars have any influence on crowding of lower incisors,²⁷ but a direct effect on

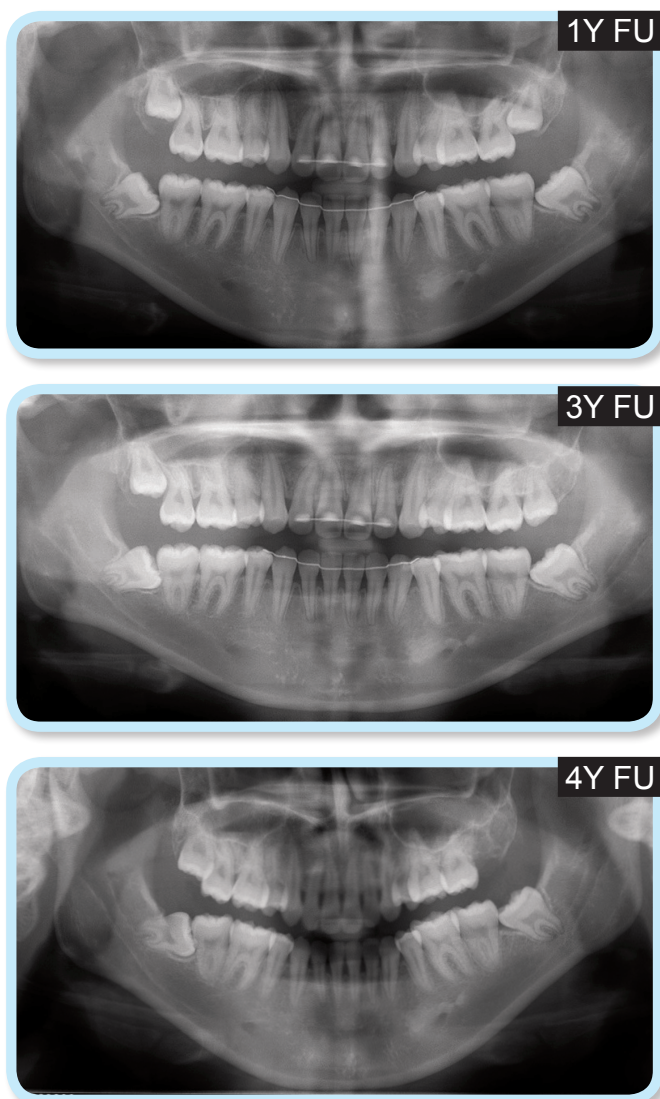
the axial inclination of the adjacent second molar is highly probable (Fig. 17). It is not justified to extract lower third molars for prevention of lower incisor crowding, but when the impactions are mesially

inclined, orthodontic alignment or extraction is indicated to prevent localized problems (Figs. 17 and 18). Extraction of both mandibular third molars was suggested to avoid further alignment problems, as well as to control the risk of periodontal disease and caries.

Relationship Between Relapse and Treatment Time

Over a century ago, Angle²⁸ suggested that relapse was related to how rapidly a malocclusion was corrected. Theoretically, slow tooth movement allows for more physiologic reorganization of the supporting tissues as the malocclusion is corrected.²³ Since the present severe malocclusion ($DI=27$) was corrected in only 16 months, it was wise to plan a rigorous retention phase to provide adequate time for remodeling of supporting bone¹⁸ and soft tissue reorganization.²³ It is unclear if prolonged wear of retainers increases longterm stability, so continuing the night-time wear of the clear overlay retainers was recommended indefinitely. The patient should be educated that it is wise to retain acquired desirable traits to avoid the necessity for retreatment.

For Class III patients, late mandibular growth is a significant concern,^{5,8} which cannot be controlled with intraoral retainers. It is important to follow up Class III treatment until the adult years. The occlusal and facial results were well-maintained during four years of follow-up until the patient reached about 22 years of age. Significant late mandibular growth was not observed.

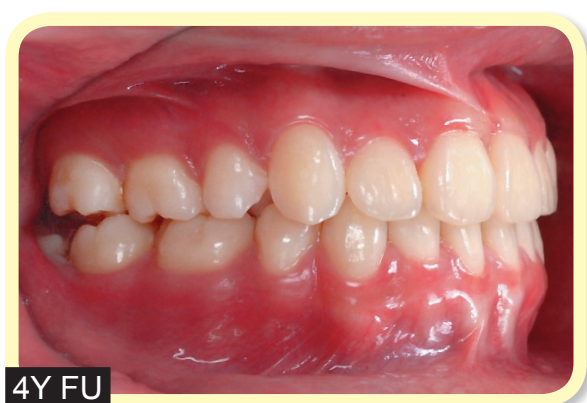

■ Fig. 17:

Panoramic radiographs at one-year (1Y FU), three-year (3Y FU), and four-year (4Y FU) follow-up show mesial movement of the lower second molar roots, apparently due to pressure from the impacted lower third molars. Note that root movement was greatest on the side with the most horizontal orientation of the impaction.

Conclusions

1. Uncomplicated anterior crossbite with moderate crowding can be effectively treated with posterior bite turbos and light archwires in PSL brackets. For more severe sagittal discrepancies, the addition of early light short Class III elastics may be indicated.
2. Bracket torque selection depends on a careful assessment of the original malocclusion relative to the treatment plan. Low torque brackets in the maxillary anterior are indicated if substantial use of Class III elastics is anticipated.
3. Post-treatment retention is an integral part of comprehensive treatment.
4. Soft tissue posture and unerupted third molars are important factors in the etiology of malocclusion.



■ Fig. 18:

In the right buccal photograph taken at four-year follow-up (4Y FU), the second molar is tipped distally, consistent with the radiographic image shown in Fig. 17.

References

1. Chang HP, Tseng YC, Chang HF. Treatment of mandibular prognathism. *J Formosan Med Assoc* 2006;105(1):781-90
2. Burgersdijk R, Truin GJ, Frakenmolen E, Kalsbeek H, van't Hof M, Mulder J. Malocclusion and orthodontic treatment need of 15-74-year-old Dutch adults. *Community Dentistry and Oral Epidemiology* 1991;19:64-67.
3. Willems G, De Bruyne I, Verdonck A, Fieuws S, Carels C. Prevalence of dentofacial characteristics in a Belgian orthodontic population. *Clin Oral Investig* 2001;5:220-226.
4. Chang MJ, Lin JJ, Roberts WE. Probable airway etiology for a severe Class III openbite malocclusion: conservative treatment with extra-alveolar bone screws and intermaxillary elastics. *Int J Orthod Implantol* 2017;45:4-20.
5. Lin JJ. *Creative Orthodontics Blending the Damon System & TADs to Manage Difficult Malocclusions*. 2nd ed. Taipei: Yong Chieh; 2010. p.263-271.
6. Komazaki Y, Fujiwara T, Ogawa T, Sato M, Suzuki K, Yamagata Z, Moriyama K. Prevalence and gender comparison of malocclusion among Japanese adolescents: a population-based study. *J World Fed Orthod* 2012;1(2):67-72.
7. Shih YH, Lin JJ, Roberts WE. Treatment of a Class III Malocclusion with anterior crossbite and deepbite, utilizing infrazygomatic crest (IZC) bone screw as anchorage. *Int J Orthod Implantol* 2015;40:2-14.
8. Tseng SP, Chang CH, Roberts WE. Early treatment of anterior crossbite complicated by maxillary posterior crowding. *Int J Orthod Implantol* 2013;30:62-72.
9. Lin JJ. Mandibular growth and Class III treatment. *Int J Orthod Implantol* 2013;32:4-13.
10. Sugawara J, Asano T, Endo N, Mitani H. Long-term effects of chin-up therapy on skeletal profile in mandibular prognathism. *Am J Orthod Dentofacial Orthop* 1990;98(2):127-33.
11. Huang YH, Chang CH, Roberts WE. Correction of anterior crossbite complicated with two supernumerary teeth. *Int J Orthod Implantol* 2013;31:44-60.
12. Ulusoy AT, Bodrumlu EH. Management of anterior dental crossbite with removable appliances. *Contemp Clin Dent* 2013;4(2):223-226.
13. Cangialosi TJ, Riolo ML, Owens SE, Dykhouse VJ, Moffitt AH, Grubb JE, Greco PM, JD English, RD James. The ABO discrepancy index: a measure of case complexity. *Am J Orthod Dentofacial Orthop* 2004;125(3):270-278.
14. Steffen JM, Haltom FT. The five-cent tooth positioner. *J Clin Orthod* 1987;21:528-529.

15. Casco JS, Vaden JL, Kokich VG, Joseph Damone, James RD, Cangialosi TJ, Riolo ML, Owens SE, Bills ED. Objective grading system for dental casts and panoramic radiographs. American Board of Orthodontics. Am J Orthod Dentofacial Orthop 1998;114(5):589-599.
16. Proffit WR, Fields HW, Sarver DM. Contemporary Orthodontics. 4th ed. St. Louis: Mosby; 2007.
17. Kozlowski J. Honing Damon system mechanics for the ultimate in efficiency and excellence. Clinical Impression 2008;16:23-28.
18. Roberts WE. Bone physiology, metabolism and biomechanics in orthodontic practice. In: Orthodontics: Current Principles and Techniques, Chapter 10, 5th ed. Graber LW, Vanarsdall RL Jr, Vig KWL (Eds). St. Louis: Elsevier Mosby; 2012. pp. 287-343.
19. Roberts WE, Nelson CL, Goodacre CJ. Rigid implant anchorage to close a mandibular first molar extraction site. J Clin Orthod 1994;28(12):693-704.
20. Proffit RW. Equilibrium theory revisited: Factors influencing position of the teeth. Angle Orthod 1978;48:175-186.
21. Weinstein S, Haack DC, Morris LY, Snyder BB, Attaway HE. On an equilibrium theory of tooth position. Angle Orthod 1963;33(1):1-26.
22. Ackerman JL, Proffit RW. Soft Tissue Limitations in Orthodontics: Treatment planning guidelines. Angle Orthod 1997;67(5):327-336
23. Graber LW, Vanarsdall RL, Vig KW. Orthodontics: Current principles and techniques. 5th ed. Philadelphia: Mosby; 2012. p. 991-1022.
24. Suter VGA, Heinzmann AE, Grossen J, Sculean A, Bernstein MM. Does the maxillary midline diastema close after frenectomy? Quintessence Int 2014;45(1):57-66.
25. Delli K, Livas C, Sculean A, Katsaros C, Bornstein MM. Facts and myths regarding the maxillary midline frenum and its treatment: a systematic review of the literature. Quintessence Int 2013;44(2):177-87.
26. Koora K, Muthu MS, Rathna PV. Spontaneous closure of midline diastema following frenectomy. J Indian Soc Pedod Prev Dent 2007;25(1):23-6.
27. Zawawi KH, Melis M. The role of mandibular third molars on lower anterior teeth crowding and relapse after orthodontic treatment: A systematic review. Scientific World Journal 2014;2014:615429.
28. Angle EH. Malocclusion of the teeth, 7th ed. Philadelphia: SS white Dental Manufacturing; 1907.

Cast-Radiograph Evaluation

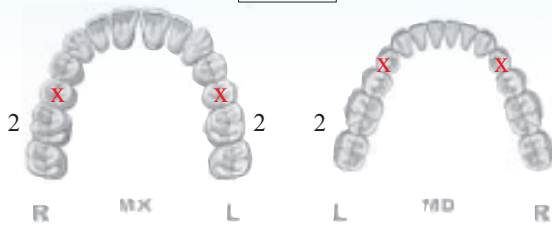
Case #

Patient

Total Score: **24**

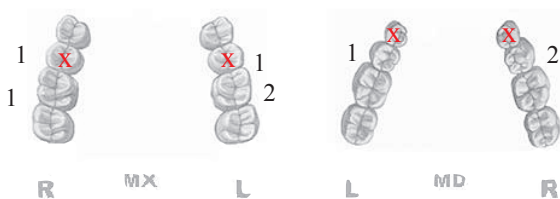
Alignment/Rotations

6



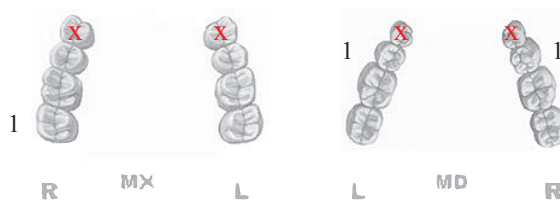
Marginal Ridges

8



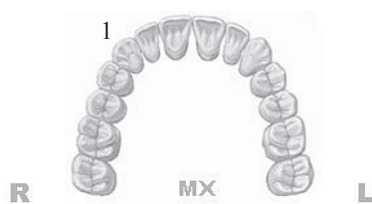Buccolingual Inclination

3



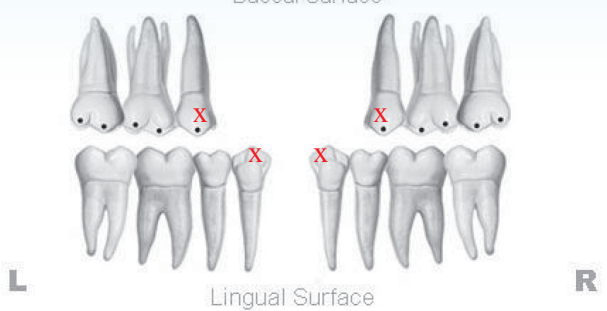
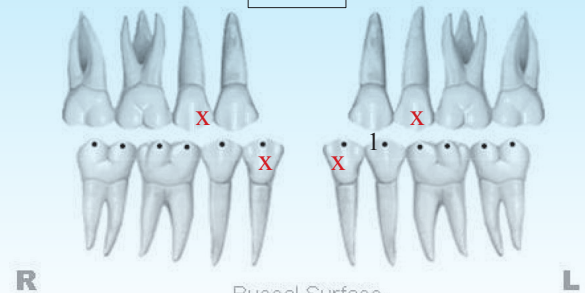
Overjet

1



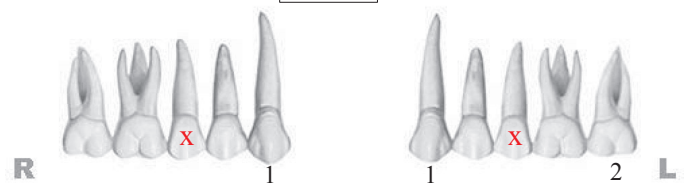
Occlusal Contacts

1



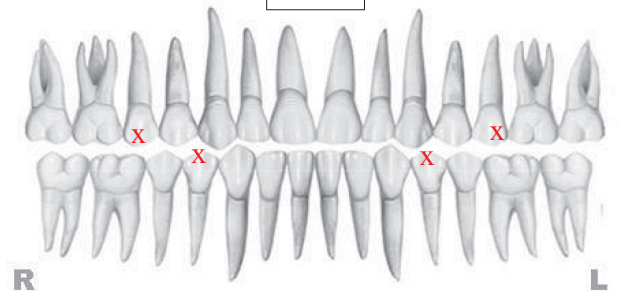
Occlusal Relationships

4



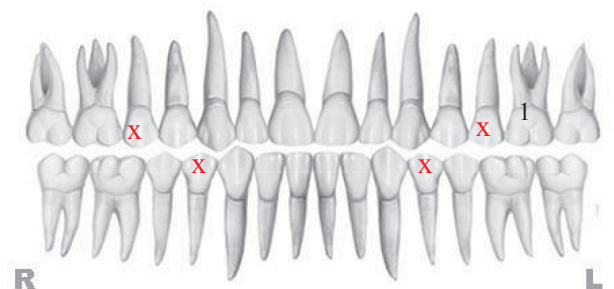
Interproximal Contacts

0



Root Angulation

1

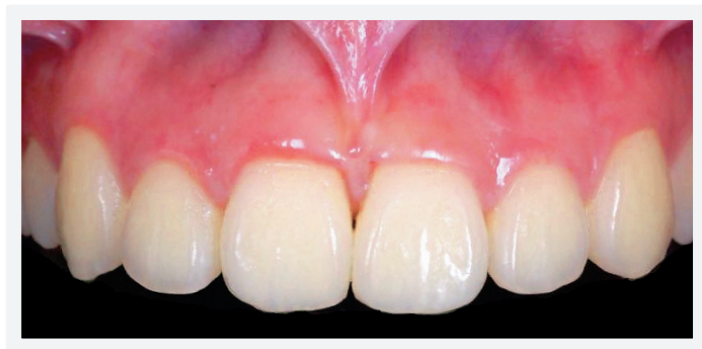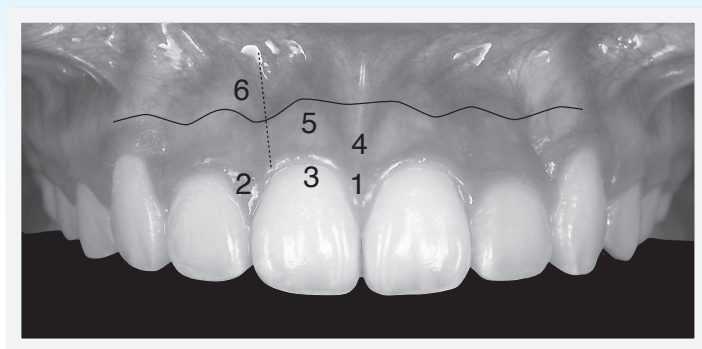


INSTRUCTIONS: Place score beside each deficient tooth and enter total score for each parameter in the white box. Mark extracted teeth with "X". Second molars should be in occlusion.

IBOI Pink & White Esthetic Score

Total Score: = **7**

1. Pink Esthetic Score

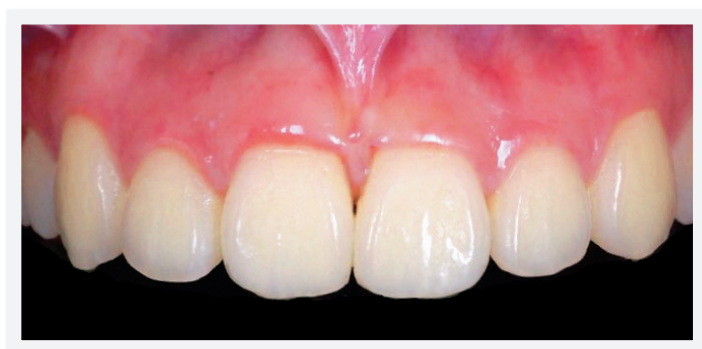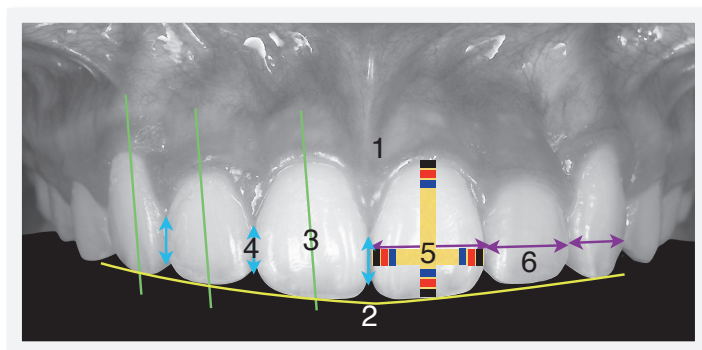


1. M & D Papillae	0	1	2
2. Keratinized Gingiva	0	1	2
3. Curvature of Gingival Margin	0	1	2
4. Level of Gingival Margin	0	1	2
5. Root Convexity (Torque)	0	1	2
6. Scar Formation	0	1	2

Total = **3**

1. M & D Papilla	0	1	2
2. Keratinized Gingiva	0	1	2
3. Curvature of Gingival Margin	0	1	2
4. Level of Gingival Margin	0	1	2
5. Root Convexity (Torque)	0	1	2
6. Scar Formation	0	1	2

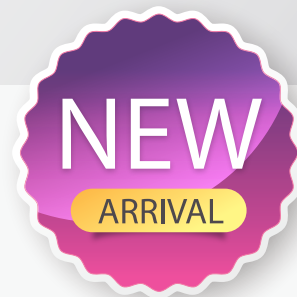2. White Esthetic Score (for Micro-esthetics)



1. Midline	0	1	2
2. Incisor Curve	0	1	2
3. Axial Inclination (5°, 8°, 10°)	0	1	2
4. Contact Area (50%, 40%, 30%)	0	1	2
5. Tooth Proportion (1:0.8)	0	1	2
6. Tooth to Tooth Proportion	0	1	2

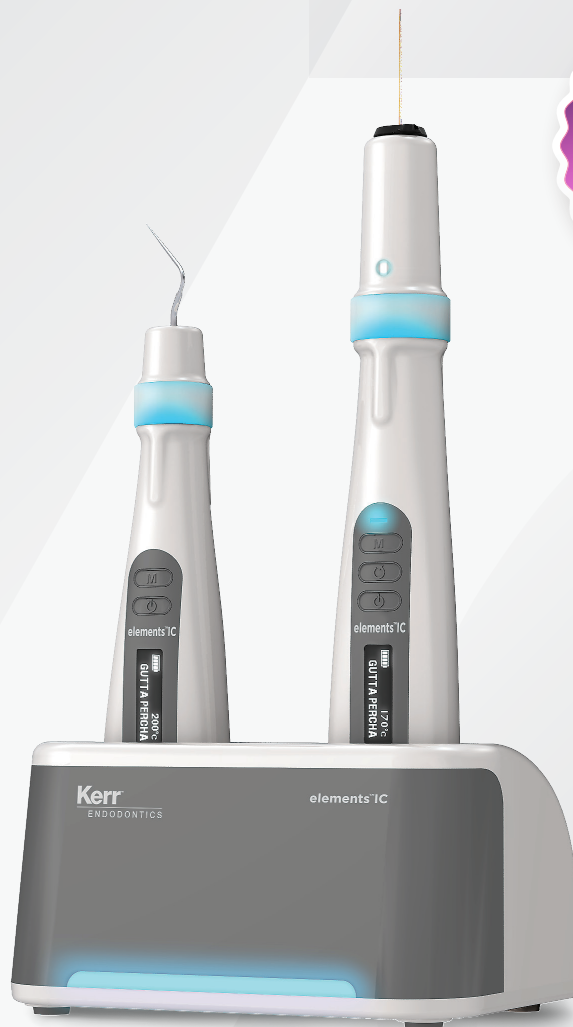Total = **4**

1. Midline	0	1	2
2. Incisor Curve	0	1	2
3. Axial Inclination (5°, 8°, 10°)	0	1	2
4. Contact Area (50%, 40%, 30%)	0	1	2
5. Tooth Proportion (1:0.8)	0	1	2
6. Tooth to Tooth Proportion	0	1	2

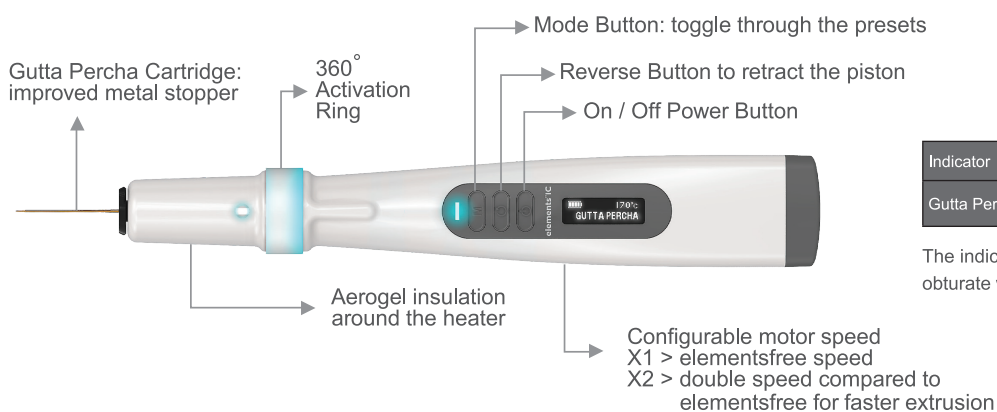
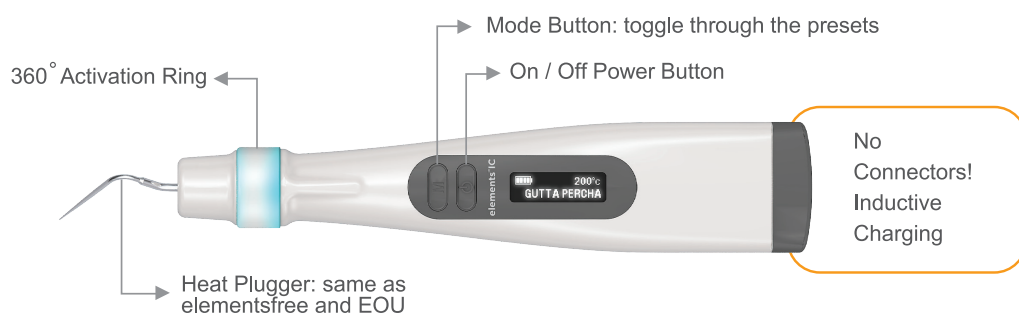


榮獲 2020 Dental Advisor
Continuous Wave Obturation

TOP AWARD WINNER



elements™ IC

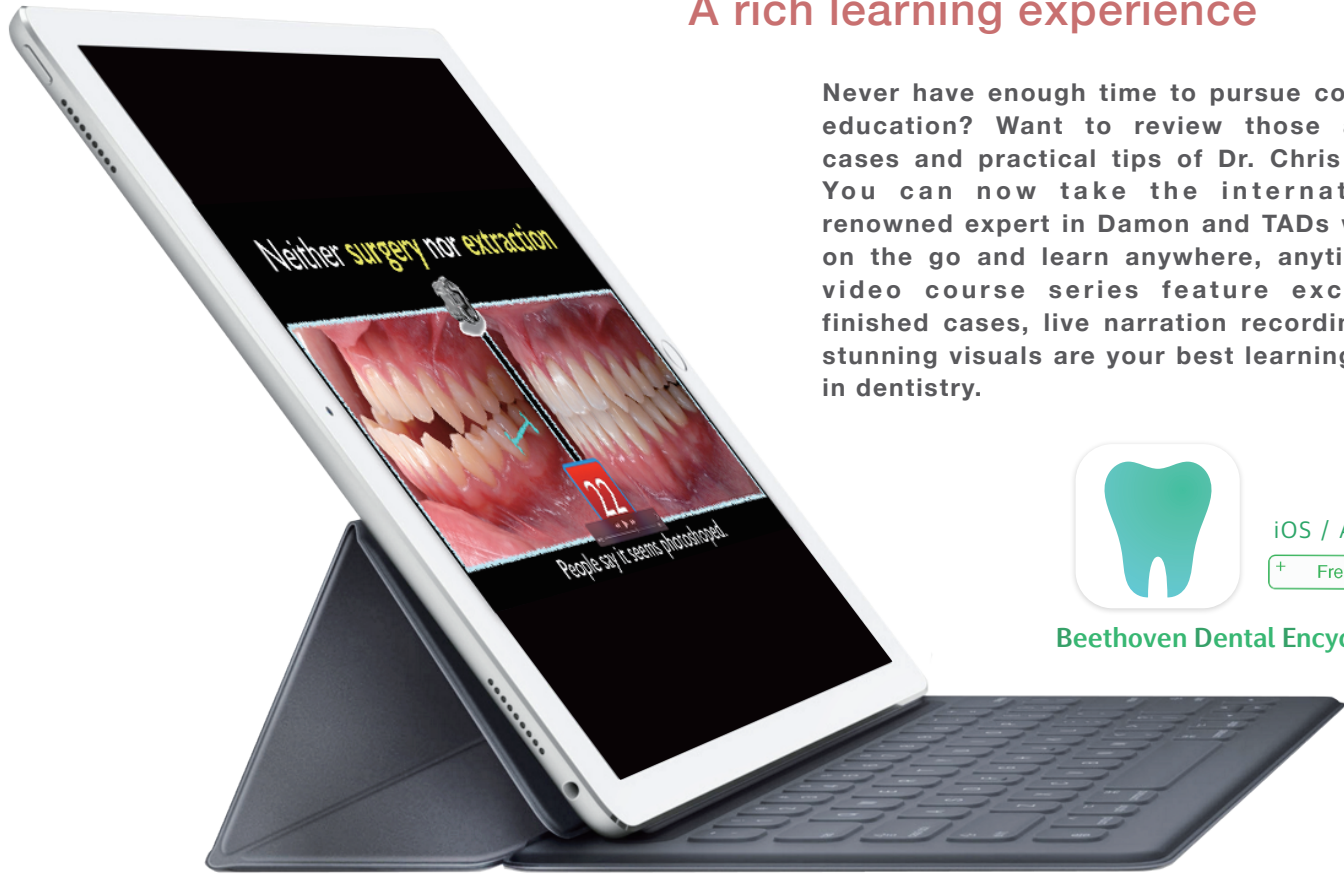


Indicator	4	3	2	1	0
Gutta Percha Level	Full	75%	50%	25%	Empty

The indicator estimates how many canals you can obturate with the material left in the GP cartridge.

e-Courses

A rich learning experience



Never have enough time to pursue continuing education? Want to review those amazing cases and practical tips of Dr. Chris Chang? You can now take the internationally renowned expert in Damon and TADs with you on the go and learn anywhere, anytime. The video course series feature excellently finished cases, live narration recordings, and stunning visuals are your best learning source in dentistry.



iOS / Android


+ Free App

Beethoven Dental Encyclopedia

Series



Damon Master



E-Lecture



OBS (TAD)



Finishing
(12 seasons)



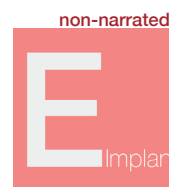
Implant Forum
(9 seasons)



Assistant



E-Ortho



E-Implant



E-Pedo


Note:

1. Most video courses are available in both English and Chinese and are sold separately.
2. Damon Master and OBS (TAD) are renewed annually and each renewal is to be purchased separately with a 50% discount.

e-Book

Learn it your favorite way!

Best of all



+ BUY BOOK

This book requires iBooks 3.0 or later and iOS 5.0 or later.

The World's Best e-Textbook

Beethoven Dental Encyclopedia e-Books collection

Beethoven Orthodontic and Implant Group has been publishing the International Journal of Orthodontics and Implantology since 2007. This Journal features excellently finished case reports evaluated by objective grading systems.

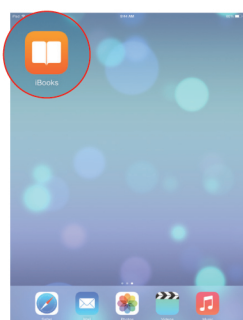
The Orthodontics and Implant Dentistry eBook series is a special selection of exciting cases with interactive functions and multimedia resource. Once opening this book, your understanding of dentistry will never be the same!

Now available in **iBooks Store** in **51** countries:

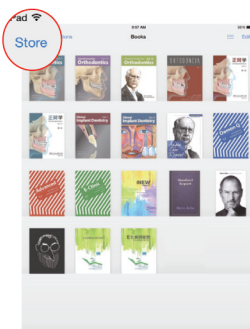
Argentina, Australia, Austria, Belgium, Bolivia, Brazil, Bulgaria, Canada, Chile, Colombia, Costa Rica, Cyprus, Czech Republic, Denmark, Dominican Republic, Ecuador, El Salvador, Estonia, Finland, France, Germany, Greece, Guatemala, Honduras, Hungary, Ireland, Italy, Japan, Latvia, Lithuania, Luxembourg, Malta, Mexico, Netherlands, New Zealand, Nicaragua, Norway, Panama, Paraguay, Peru, Poland, Portugal, Romania, Slovakia, Slovenia, Spain, Sweden, Switzerland, United Kingdom, United States, and Venezuela.



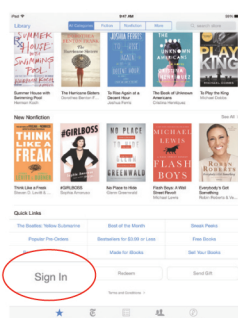
Step-by-step Instructions



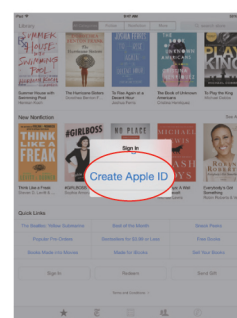
1. Launch "iBooks" app on your iPad.



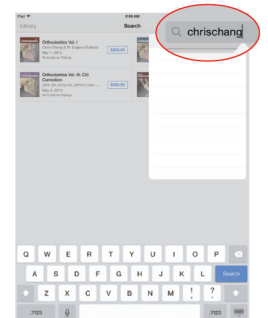
2. Click "Store."



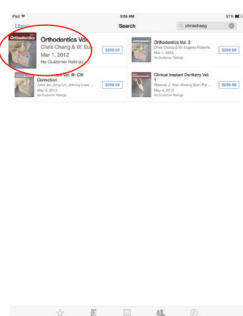
3. "Sign in" with your Apple ID.



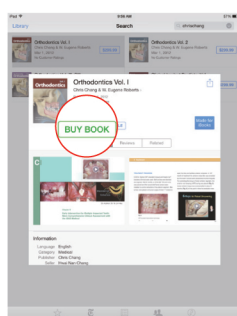
4. "Create Apple ID" if you don't have one.




5. Search for "chrischang."



6. Click the book's icon.



7. Check the price and click "BUY BOOK."



8. Once downloaded, click the book's icon to launch the e-book and enjoy.

If you are interested in our paid video or medical products, contact inewton.dental@gmail.com for more information.

+886-3-573-5676

orthobonescrew.com

iNewton