

Class II Malocclusion with Blocked-Out Maxillary Canines and a Steep Mandibular Plane: Non-Extraction Treatment with 5-Year Follow-Up

Abstract

History: A 10-year-old female was referred because of bilateral unerupted maxillary canines.

Etiology: Insufficient arch perimeter resulted in the premature loss of the upper deciduous canine (Uc) space due to ectopic eruption of adjacent maxillary lateral incisors.

Diagnosis: Increases in lower facial height (56%), mandibular plane angle (SN-MP 40.5°), intermaxillary relationship (ANB 4°), and lip protrusion (1mm/2mm to the E-Line) were associated with full cusp Class II molar relationships, bilaterally. Both upper canine spaces were lost due to tipping of adjacent teeth into the exfoliated Uc spaces, and the upper left first premolar (UL4) was rotated mesial-in. The upper right canine (UR3) was well positioned, but its path of eruption was blocked. The UL3 was high in the alveolar process and at risk for impaction. The maxillary arch perimeter was deficient (-8mm) due to premature loss of upper deciduous canines, but no significant root resorption was apparent. The American Board of Orthodontic (ABO) Discrepancy Index (DI) was 25.

Treatment: A full fixed passive self-ligating (PSL) appliance was bonded on all permanent teeth. Compressed coil springs were inserted to open space and the maxillary canines erupted spontaneously. Intermaxillary growth helped correct the Class II molar relationship as the canines erupted, and the occlusion was finished with vertical elastics. Retention was with clear aligners.

Outcomes: After 27 months of active treatment, the blocked-out maxillary canines were well aligned. The supporting gingiva was healthy, periodontal form was near ideal, and no root resorption was noted. Final alignment and dental esthetics were excellent as evidenced by an ABO Cast-Radiograph Evaluation (CRE) score of 18, and an International Board of Orthodontics and Implantology (IBOI) Pink & White Esthetic Score of 3. Follow-up records 5 years later documented the stability of the correction.

Conclusions: The etiology of a blocked-out canine indicates the most efficient timing for orthodontic intervention. Space maintenance is indicated if an Uc is lost due to ectopic eruption of the lateral incisors. Otherwise adjacent teeth may drift into the canine space preventing normal eruption of the permanent cuspid(s). Phase I treatment is required to prevent ectopic buccal eruption or impaction. (*J Digital Orthod* 2020;58:24-39)

Key words:

Impacted maxillary canine, eruption, etiology, ectopic eruption, spontaneous correction, Class II malocclusion

Introduction

With the exception of third molars, a maxillary canine (U3) is the tooth most susceptible to impaction. The etiology may involve ectopic loss of a deciduous canine (Uc) followed by mesial drift of the buccal segment to create a Class II intermaxillary discrepancy. This type of malocclusion affects about 2% of the general population and 4% of patients referred to orthodontists.^{1,2} In ethnic Chinese adolescents, U3 impaction occurs labially or within the alveolus 49.9-67.7% of the time.^{3,4} Only about one-third of U3 impactions are labial in North American.⁵ Arch length deficiency is associated with labial impactions. Jacoby⁶ found that

Dr. Lexie Y. Lin,

Resident, Beethoven Orthodontic Center (Left)

Dds. Jennifer Chang,

Clerk, Beethoven Orthodontic Center (Center left)

Dds. Kristine Chang,

Clerk, Beethoven Orthodontic Center (Center right)

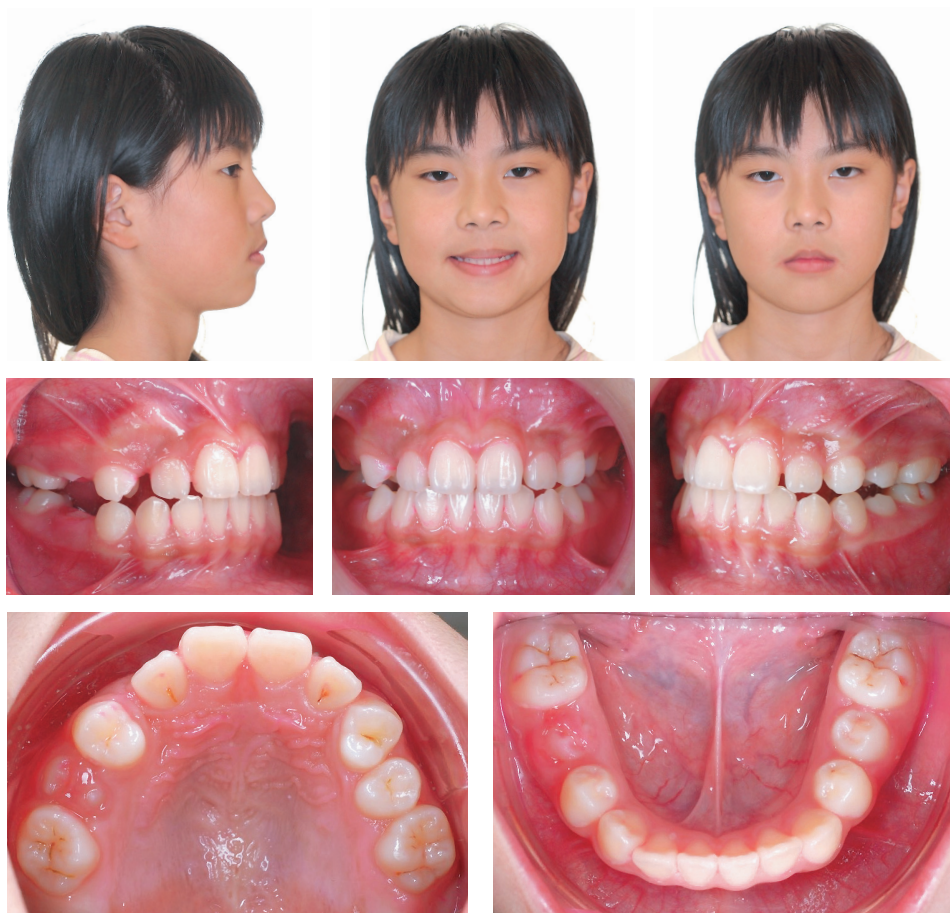Dr. W. Eugene Roberts,

Editor-in-chief, Journal of Digital Orthodontics (Right)



only 17% of labially impacted canines had sufficient space to erupt. Normal eruption can be achieved with orthodontic mechanics that create space, selective removal of deciduous canines, and/or extraction of an adjacent premolar.^{7,8} However, if the canine does not erupt spontaneously, surgical intervention is indicated.⁹

Spontaneous eruption is preferred because surgical intervention may result in a deficient band of attached gingiva especially for labial impactions. Periodontal health depends on the amount of attached gingiva apical to the tooth crown after eruption.¹⁰ Furthermore, gingival re-intrusion of a recovered impaction and gingival scarring are common complications.¹¹ Anomalous development of adjacent teeth is linked to canine impaction.¹²

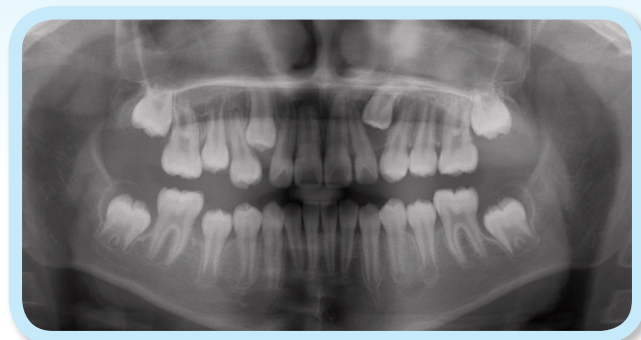


■ Fig. 1: Pre-treatment facial and intraoral photographs

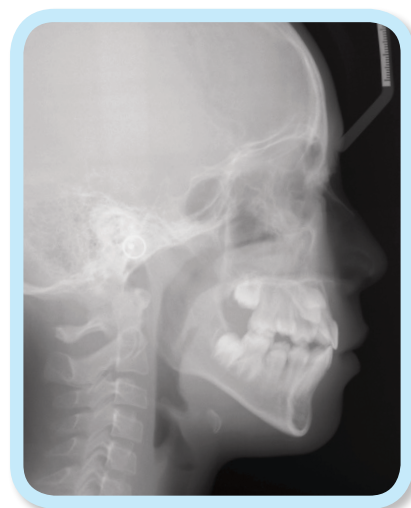The dental nomenclature for this report is a modified Palmer notation. Upper (U) and lower (L) arches, as well as the right (R) and left (L) sides, define four oral quadrants: UR, UL, LR and LL. Teeth are numbered 1-8 from the midline in each quadrant, e.g. a lower right first molar is LR6.

History and Etiology

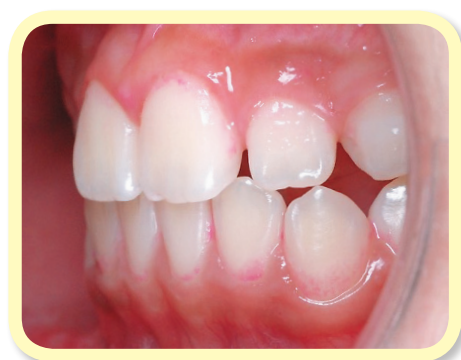A 10-year-old female was referred by her pedodontist for orthodontic evaluation because both unerupted maxillary canines were blocked-out (Figs. 1-3). The UL3 was high in the alveolar process and at risk of impaction. No contributing medical problems were reported. Oral hygiene was acceptable, and there was no history of dental trauma, oral habits, or temporomandibular dysfunction. Clinical examination revealed a straight profile, facial symmetry, and slightly protrusive lips to the E-line (Fig. 4, Table 1). Overbite and overjet were within normal limits, but the buccal segments were full cusp Class II (Fig. 5). Upper primary canines



■ Fig. 3: Pre-treatment panoramic radiograph

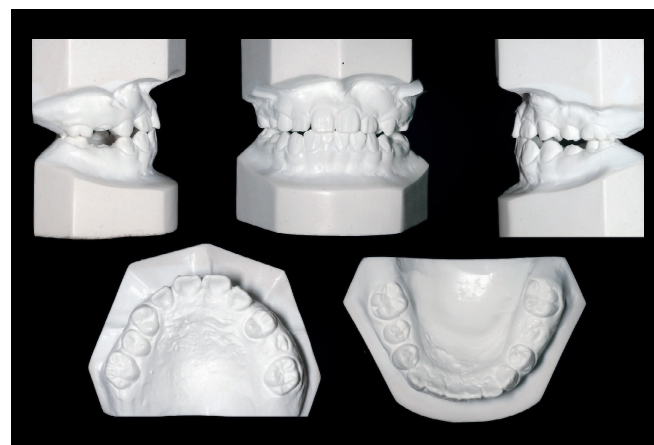

■ Fig. 4: Pre-treatment lateral cephalometric radiograph



■ Fig. 2:

An anterior left intraoral photograph shows the UL2 and UL4 are tipped into the UL3 space pretreatment. See text for details.



■ Fig. 5: Pre-treatment dental models (casts)

CEPHALOMETRIC SUMMARY			
SKELETAL ANALYSIS			
	PRE-Tx	POST-Tx	DIFF.
SNA° (82°)	81°	83.5°	2.5°
SNB° (80°)	77°	79°	2°
ANB° (2°)	4°	4.5°	0.5°
SN-MP° (32°)	40.5°	41°	0.5°
FMA° (25°)	33.5°	34°	0.5°
DENTAL ANALYSIS			
U1 To NA mm (4 mm)	2.5	3.5	1
U1 To SN° (104°)	98°	107°	9°
L1 To NB mm (4 mm)	6	6.5	0.5
L1 To MP° (90°)	86°	86°	0°
FACIAL ANALYSIS			
E-LINE UL (-1 mm)	1	-1	2
E-LINE LL (0 mm)	2	1	1
%FH: Na-ANS-Gn (53%)	56%	57%	1%
Convexity: G-Sn-Pg' (13°)	12.5°	14°	2.5°

■ Table 1: Cephalometric summary

were missing and second molars were un-erupted. A tendency for an edge-to-edge relationship was noted between the upper and lower lateral incisors (Fig. 2). Mesial-in rotation was associated with premature loss of the adjacent deciduous canine. Crowding was 8-9mm in the upper arch. The panoramic radiograph revealed that lateral incisors and first premolars were tipped into the sites of the missing deciduous canines, bilaterally. The unerupted maxillary canines appeared well positioned to erupt when adequate space was provided, so CBCT imaging was not indicated.

Diagnosis

Facial:

- Height: *Excessive lower facial height (56%)*
- Convexity: *WNL (12°)*
- Lip Protrusion: *Slightly protrusive (1mm/2mm to the E-line)*

Skeletal:

- Sagittal Relationship: *Mandibular retrusion (SNA 81°, SNB 77°, ANB 4°)*
- Mandibular Plane Angle: *Increased (SN-MP 40.5°, FMA 33.5°)*

Dental:

- Occlusion: *Class II molar*
- Overjet & Overbite: *WNL*
- Upper incisor: *Retrusive (U1-NA 2.5mm), decreased axial inclination (L1-MP 98°)*
- Lower incisor: *Protrusive (L1-NB 6mm), decreased axial inclination (L1-MP 86°)*
- Canines: *UR3 was normally positioned, but blocked-out. The UL3 was high in the alveolar process and at risk of impaction.*

American Board of Orthodontics (ABO) Discrepancy Index (DI): 25 as shown in the subsequent worksheet.

Treatment Objectives

Maxilla and Mandible

- Allow normal growth expression in sagittal and transverse planes.

Maxillary Dentition

- A-P: *Anterior movement of incisors*
- Vertical: *Allow extrusion consistent with normal growth.*
- Inter-Canine Width: *Increase*
- Inter-Molar Width: *Increase as molars are retracted to create space for canines*

Mandibular Dentition

- A-P: *Retract incisors*
- Vertical: *Maintain*
- Inter-Canine Width: *Maintain*
- Inter-Molar Width: *Maintain*

Facial Esthetics:

- Lips: *Slightly retract the lips to the E-Line consistent with ethnic preference.*

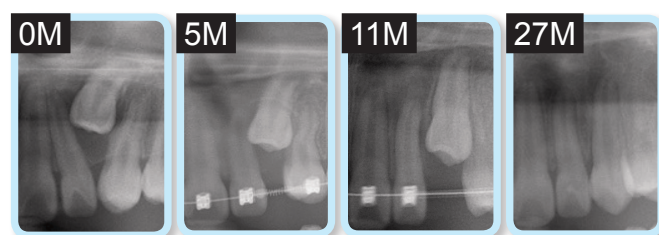
Treatment Plan

Despite an 8mm upper arch deficiency, non-extraction treatment was indicated because the facial profile and growth potential were favorable. A positive indicator for conservative treatment was the optimal intra-alveolar orientation of the blocked-out U3s (Fig. 3). Opening adequate space was likely to result in normal eruption. Since the premolars were (*or soon will be*) erupted, a full fixed PSL appliance was indicated. Open coil springs were inserted between the first premolars and lateral incisors bilaterally to provide sufficient space for the maxillary canines. If the canines failed to erupt spontaneously, surgical intervention was indicated to expose the crowns and bond attachments for traction. Bilateral infrazygomatic crest (IZC) bone screws (BSs) were also a viable option if needed. However, the mandible was retruded (SNB 77°)

with a steep mandibular plane (FMA 33.5°), so Class II elastics were risky. However, they were the mechanics of choice if the Class II molar discrepancy does not spontaneously correct when space is opened for the unerupted U3s. Clear retainers were planned to retain both arches.

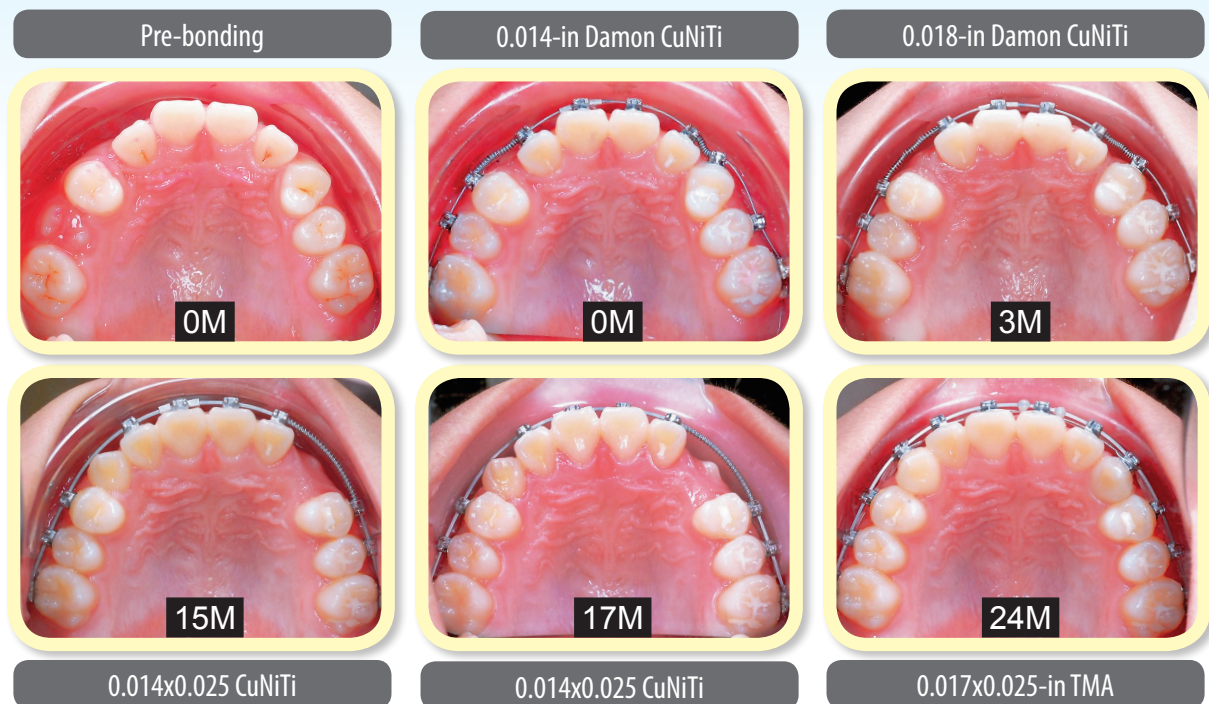Treatment Progress

A 0.022" slot Damon Q® passive self-ligating (PSL) brackets (Ormco Corporation, Brea, CA) were bonded on all upper teeth. A 0.014" CuNiTi archwire was inserted, and compressed coil springs were placed to create space for the maxillary canines. Low-torque brackets were chosen for the four upper incisors to compensate for the expected increase in axial inclination that was associated with space opening. The light labial force of the coil springs was resisted with lip competence to prevent excessive flaring of the incisors. The unerupted U3s had no root interference with adjacent teeth (Fig. 6), so there was no need to avoid bonding the upper lateral incisors. Increasing the arch perimeter of the upper arch was the principal objective. During the first 17 months of active treatment, the UL4 was aligned (Fig. 7) and the Class II molar relationships were spontaneously corrected to Class I. It was not necessary to use Class II elastics.

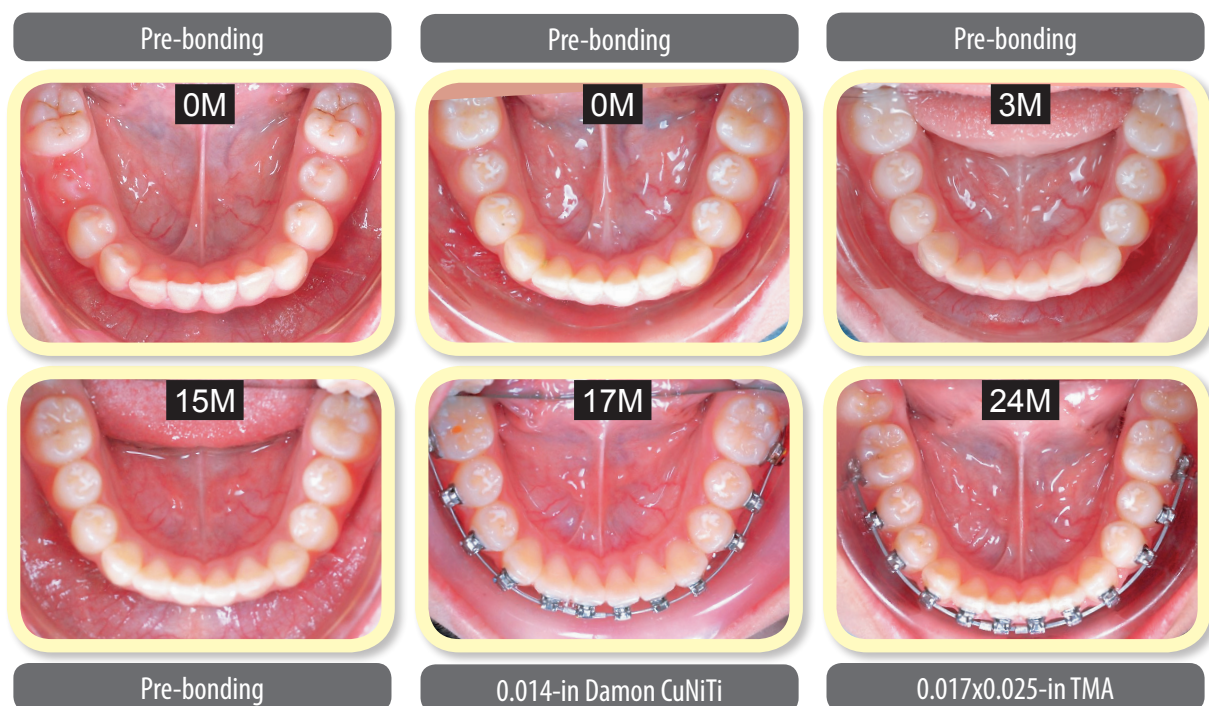


■ Fig. 6:

A panel of four radiographs shows the recovery of the impacted UL3 from 0-27 months (M). See text for details.



■ Fig. 7: Treatment progress for the upper arch is shown from 0-24 months (M). See text for details.



■ Fig. 8: Treatment progress for the lower arch is shown from 0-24 months (M).

Prior to bonding the lower arch (17 months into treatment), space was provided for the maxillary canines to erupt normally (Fig. 6). Both canines erupted into keratinized gingiva, coronal to the mucogingival junction, but were tipped buccally, so they were bonded with high-torque brackets. Both arches were leveled and aligned with light, continuous archwires: 0.014" CuNiTi followed by 0.014x0.025" NiTi. Low friction 0.017x0.025" TMA wires were used to refine the final alignment in both arches (Figs. 7 and 8).

Over the entire course of treatment, the axial inclinations of incisors, lip competence and labial prominence were carefully monitored. Vertical elastics were used to improve interdigitation and posterior contacts (Fig. 9). No bone screws or other temporary anchorage devices were needed to retract either arch. The archwire was sectioned distal to the upper right canine in the last month of treatment, and intermaxillary vertical (zig-zag) elastics were used for final finishing of the buccal segments (Fig. 9). The fixed appliances were removed in the 27th month of treatment, and clear overlay retainers were delivered.

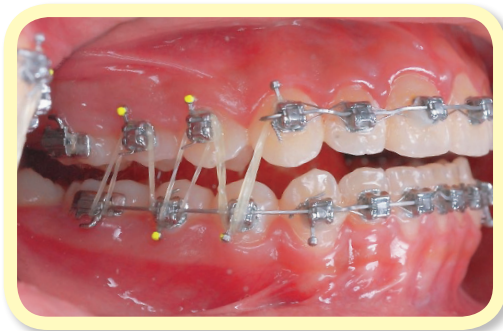


Fig. 9:
Finishing the occlusal contacts in the buccal segments is accomplished with continuous (zig-zag) vertical elastics.

Results Achieved

Maxilla (all three planes):

- A-P: Increased
- Vertical: Increased
- Transverse: Increased

Mandible (all three planes):

- A-P: Increased
- Vertical: Increased
- Transverse: Maintained

Maxillary Dentition:

- A-P: Incisors and molars were protracted.
- Vertical: Extruded, consistent with normal growth
- Inter-Molar Width: Increased

Mandibular Dentition:

- A-P: Molars protracted
- Vertical: Incisors extruded
- Inter-molar/Inter-canine Width: Maintained

Facial Esthetics:

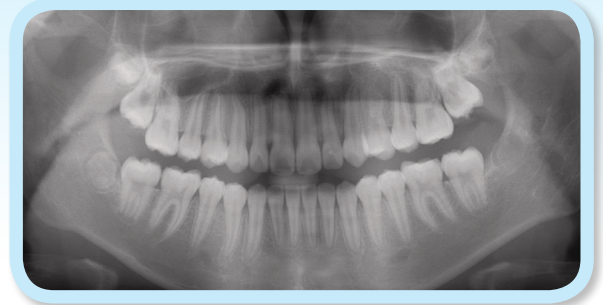
- Convexity: Increased with anterior growth of the maxilla during treatment, but decreased 5 years later due to continuing anterior growth of the mandible
- Lips: Both upper and lower lips were slightly retracted to the E-line.

Final Evaluation of Treatment

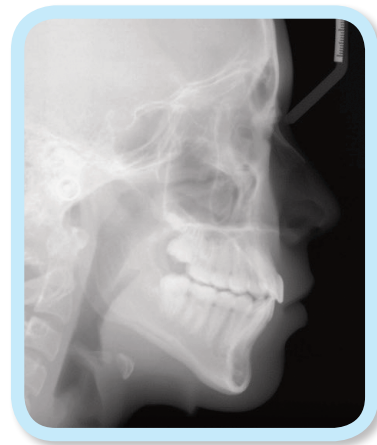This board case report describes the correction of a severe malocclusion with a DI of 25, which was

treated to an acceptable CRE of 18 points. The major residual discrepancy was Class II occlusal relationships in the canine and premolar areas (7 points). The post-treatment panoramic (Fig. 10) and cephalometric (Fig. 11) radiographs reveal near ideal root parallelism for all teeth including the untreated lower second molars. Comparison of the initial (Fig. 5) and final casts (Fig. 12) documents correction of a full cusp Class II molar relationship. Upper arch perimeter was increased by 8mm and arch width was expanded by 3mm, but there was little dimensional change in the lower arch.

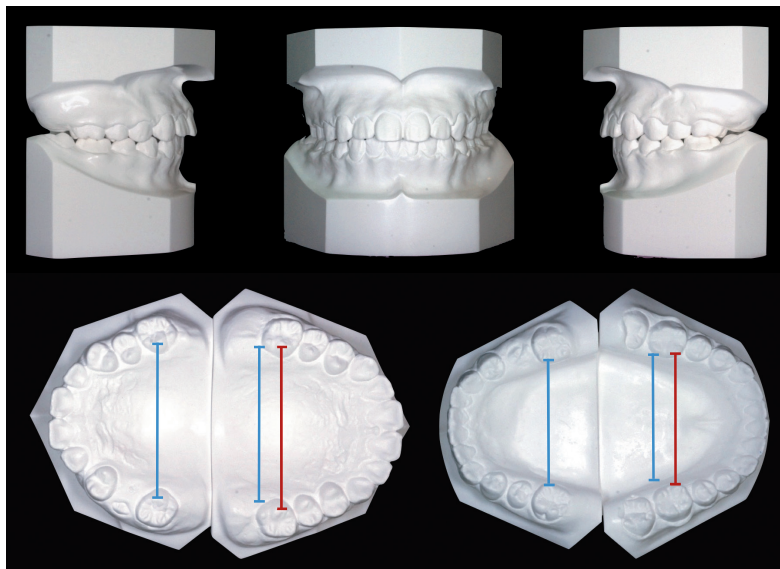
Post-treatment facial and intraoral photographs (Fig. 13) show good facial esthetics, and an acceptable smile arc, but growth in the length of the upper lip restricted ideal correction of the upper incisor display. Overall, dentofacial esthetics were improved



■ Fig.10: Post-treatment panoramic radiograph

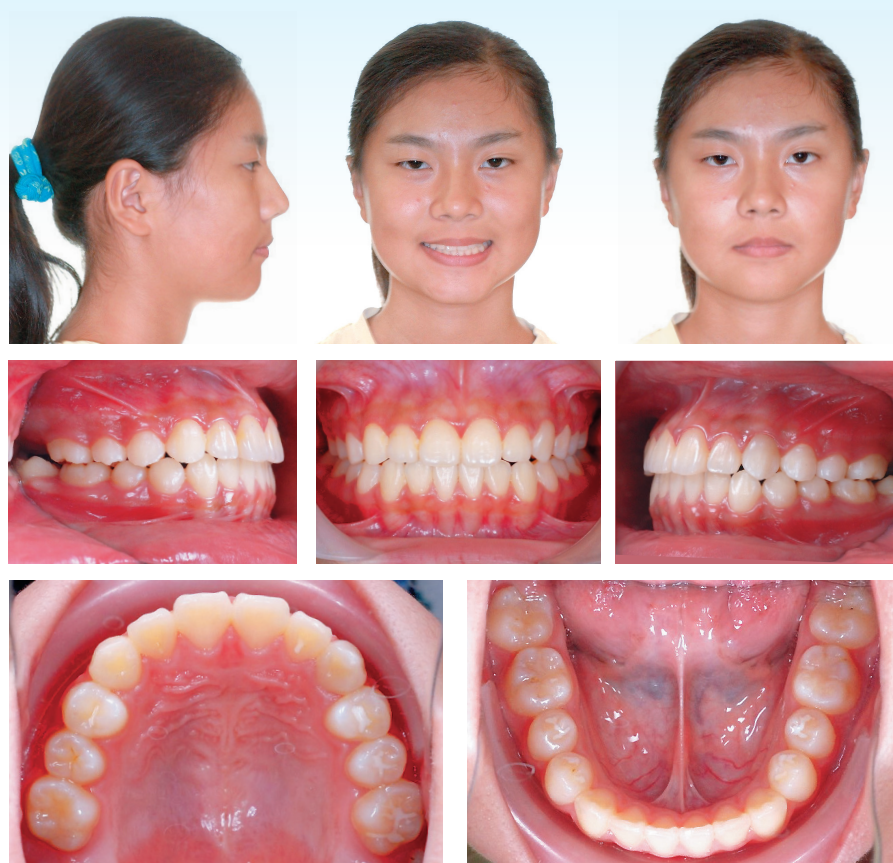

■ Fig.11: Post-treatment lateral cephalometric radiograph

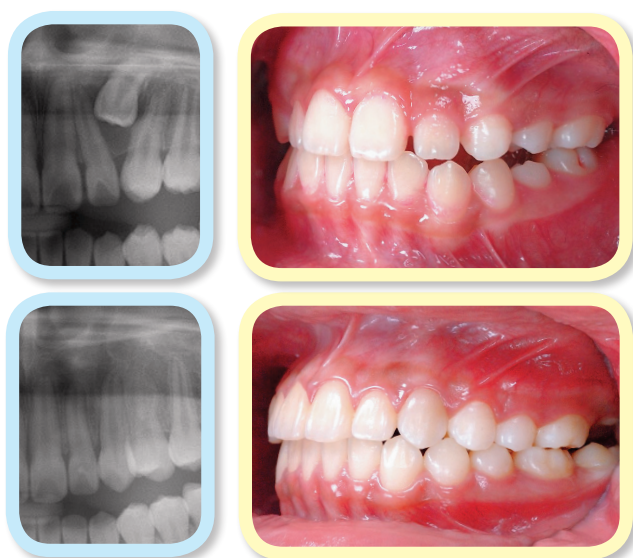

■ Fig. 12:

The upper three images show buccal and frontal views of the post-treatment dental models (casts). The lower occlusal views are direct comparisons of width at the mesiobuccal cusps for the initial (blue line) to the finish (red line) casts. Expansion was 3mm and 1.5mm for the upper (left) and lower (right) casts.



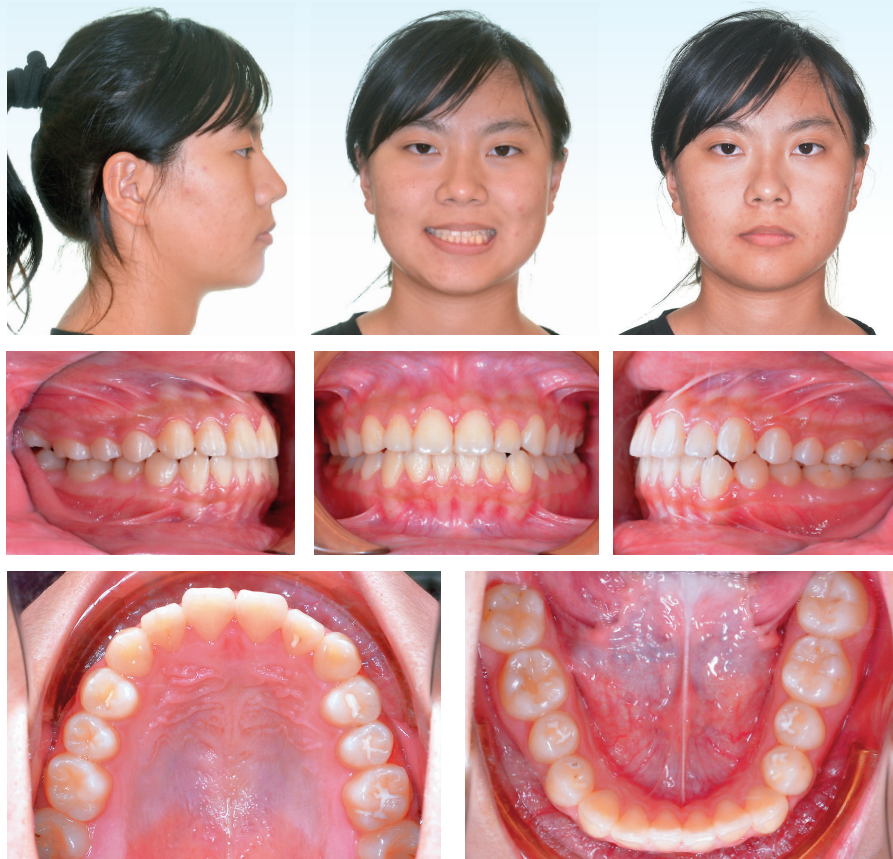■ Fig. 13: Post-treatment facial and intraoral photographs



■ Fig. 14:
Matched radiographs and intraoral photographs show the initial (upper) and final left buccal occlusion (lower).

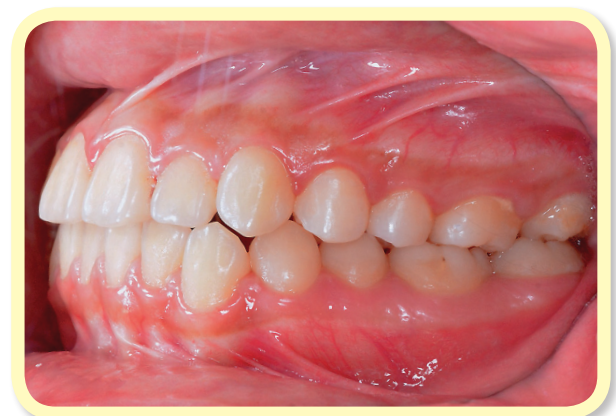compared to the start of treatment, and the midline was maintained (Fig. 1). Anterior labial gingiva of the maxillary arch was healthy and well keratinized (Fig.14).

At the 5-year follow-up evaluation, anterior maxillary gingival display was improved (Fig.15). The upper second molars erupted into a slightly more buccal orientation, particularly on the right side. Overall alignment of the dentition was maintained, but the lower left canine was slightly rotated distal-out. The recovered UL3 was surrounded with keratinized stable gingiva (Fig.16), and there were no signs of re-intrusion, root resorption or gingival inflammation.



■ **Fig. 15:** Facial and intraoral photographs five years after treatment

The patient was no longer wearing retainers, so the final result was deemed stable. Fig. 17 shows the superimposed cephalometric tracings pre-treatment, post-treatment, and at 5-year follow-up. Overall, the patient had a favorable downward and forward growth pattern, but an unusual increase in anterior growth of the midface resulted in increased facial convexity at the end of the treatment (15.5°). Five years later, increased mandibular compared to maxillary growth resulted in correction of facial convexity to 10° . Lip protrusion decreased 1-2mm during treatment, and the lower lip decreased another 1mm at follow-up (Table 2).



■ **Fig. 16:**

At 5-year follow-up, a left buccal intraoral photograph shows that the attached gingiva surrounding the UL3 compared to adjacent teeth. The periodontium was healthy and sufficient. In particular, note the high-low-high gingival margin relationships of the central incisor, lateral incisor and canine. See text for details.

CEPHALOMETRIC SUMMARY			
SKELETAL ANALYSIS			
	PRE-Tx	POST-Tx	f/u
SNA° (82°)	81°	83.5°	86°
SNB° (80°)	77°	79°	81°
ANB° (2°)	4°	4.5°	5°
SN-MP° (32°)	40.5°	41°	38°
FMA° (25°)	33.5°	34°	31°
DENTAL ANALYSIS			
U1 To NA mm (4 mm)	2.5	3.5	4
U1 To SN° (104°)	98°	107°	108°
L1 To NB mm (4 mm)	6	6.5	7
L1 To MP° (90°)	86°	86°	90°
FACIAL ANALYSIS			
E-LINE UL (-1 mm)	1	-1	-1
E-LINE LL (0 mm)	2	1	0
%FH: Na-ANS-Gn (53%)	56%	57%	57%
Convexity: G-Sn-Pg' (13°)	12.5°	14°	10°

Table 2: Cephalometric summary with 5-year follow-up (f/u) measurements

Discussion

The treatment for the present patient may appear simple and intuitive, but the clinical success required a series of timely and precise decisions. First, an assessment of the etiology indicated a non-extraction approach. Second, early treatment reversed the etiology to achieve normal eruption. Third, gentle labial force within the limits of lip competence increased arch perimeter and helped correct the Class II molar discrepancy. These important principles were based on a fundamental understanding of maxillary canine development and eruption. In effect, the cause of the malocclusion was reversed in a timely manner, thereby preventing high label eruption and/or impaction of the U3s. Reversing the etiology of a malocclusion is fundamental to achieving a natural result that is stable. A very attractive smile was accomplished with minimal mechanical intervention.

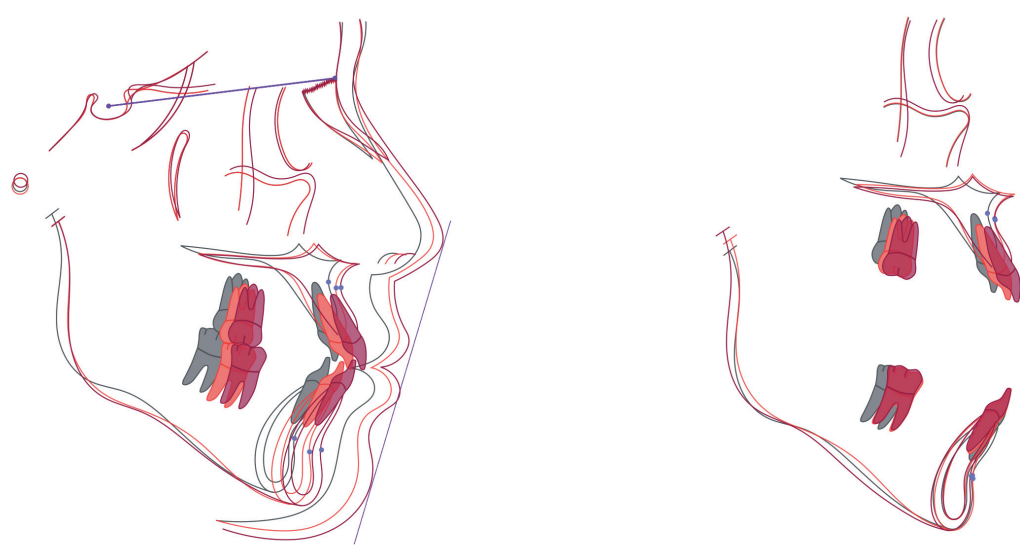


Fig. 17: Cephalometric tracings before treatment (black), at the finish (red), and 5-years later (purple) are superimposed on the anterior cranial base (left), maxilla (upper right) and mandible (lower right). Note the unusually large component of anterior growth for the mid-face (maxilla) compared to the mandible. See text for details.

Etiology of Maxillary Canine Impaction

In 1993, Kokich and Mathews¹³ suggested that the etiology of impacted maxillary canines was unknown. Subsequently (2015), Becker and Chaushu¹² classified the etiology into 4 distinct groups: 1) local hard tissue obstruction, 2) local pathology, 3) disturbance of normal incisor development, and 4) hereditary or genetic factors. For the present patient, the most probable etiology was ectopic eruption of the maxillary lateral incisors into the canine space, which resulted in the premature loss of the deciduous canines.^{14,15} The buccal segments drifted mesially resulting in full cusp Class II malocclusion. To achieve an optimal result, it was necessary to recover the canine spaces with compressed coil springs to facilitate U3 eruption.¹⁶ Fortunately, as the upper canine spaces were opened, the patient maintained lip competence, so this physiologic force system retracted the upper molars. In addition, strong lower face growth assisted the spontaneous correction of the Class II buccal segments.

Critique: the occlusal result could be improved by flattening the lower curve of Spee, performing interproximal enamel reduction of the lower incisors, and using Class II elastics to complete correction of cuspid and premolar occlusal relationships (Fig. 13).

Timing of Non-Extraction Treatment

Chang's Extraction Decision Table¹⁷ was used to assess the necessity for extractions. Two factors favoring extraction were a high mandibular plane angle (FMA 33.5°) and >7mm of crowding in the maxillary arch. However, the patient had a normal profile with decreased axial inclination of the maxillary incisors (98°). Furthermore, extraction(s) to

correct impacted canines is best limited to patients with ankylosis, uncontrollable infection, internal or external root resorption, severe root dilaceration, and/or pathology that may compromise the adjacent teeth.^{18,19} The patient was only 10 years old at the start of treatment, had competent lips, and considerable anterior growth was expected. Therefore, a non-extraction treatment plan was indicated.

Broadbent²⁰ described the mechanism of anterior maxillary eruption as the "ugly duckling" stage. The concept implied was that the eruptive movement of the canines was guided along the distal aspect of the roots of the lateral incisors.¹² The pre-treatment panoramic radiograph (Fig. 3) showed that the U3 roots were not fully developed, so there appeared to be strong eruption potential. The problem was inadequate arch length. Since arch development was required, compressed coil springs were indicated to provide space for U3 eruption.

Open Coil Springs

A classic approach for impacted maxillary canines is space opening, surgical exposure, and light traction force.²¹ For the present patient, open coil springs increased the space between the lateral incisors and first premolars to create an unobstructed path of eruption for the canines. The reciprocal force generated by the open coil springs uprighted the mesially tipped buccal segments, rotated the UL4, and flared the upper incisors. To prevent excessive tipping of the incisors, low-torque brackets were chosen.²² Bonding standard-torque brackets upside-down and applying root torque springs were additional options, if needed.²³ Maintenance of lip competence as incisors flare is the responsibility

of patients and should be emphasized to his or her family.²⁴

Conclusions

Careful management of impacted maxillary canines is important both esthetically and functionally. Investigating the cause of the problem is the first step for establishing an optimal treatment plan. Reversing the etiology is usually the best choice for correcting acquired malocclusions. Well planned orthodontic therapy (*with or without surgery*) provides optimal results for both the patient and the clinician. A careful assessment of the etiology is critical for differentiating between potential treatment plans. It is wise to use the least invasive approach that has a reasonable probability of success.

References

1. Kurol J. Early treatment of tooth-eruption disturbances. *Am J Orthod Dentofacial Orthop* 2002;121:588-91.
2. McDonald E, Yap WL. The surgical exposure and application of direct traction of unerupted teeth. *Am J Orthod* 1986;89:331-40.
3. Sajnani AK, King NM. Prevalence and characteristics of impacted maxillary canines in southern Chinese children and adolescents. *J Investig Clin Dent* 2014;5(1):38-44.
4. Zhong YL, Zeng XL, Jia QL, Zhang WL, Chen L. Clinical investigation of impacted maxillary canine. *Chinese J Stomatology* 2006;41(8):483-5.
5. Ericson S, Kurol J. Early treatment of palatally erupting maxillary canines by extraction of the primary canines. *Eur J Orthod* 1988;10(4):283-95.
6. Jacoby H. The etiology of maxillary canine impactions. *Am J Orthod* 1983;84:125-32.
7. Leite HR, Oliveira GS, Brito HH. Labially displaced ectopically erupting maxillary permanent canine: interceptive treatment and long-term results. *Am J Orthod Dentofacial Orthop* 2005;128:241-51.
8. Williams B. Diagnosis and prevention of maxillary cuspid impaction. *Angle Orthod* 1981;51:30-40.
9. Kokich VG. Surgical and orthodontic management of impacted maxillary canines. *Am J Orthod Dentofacial Orthop* 2004;126:278-83.
10. Vanarsdall R, Corn H. Soft tissue management of labially positioned unerupted teeth. *Am J Orthod* 1977;72:53-64.
11. Vermette M, Kokich V, Kennedy D. Uncovering labially impacted teeth: closed eruption and apically positioned flap techniques. *Angle Orthod* 1995;65:23-32.
12. Becker A, Chaushu S. Etiology of maxillary canine impaction: A review. *Am J Orthod Dentofacial Orthop* 2015;148:557-67.
13. Kokich VG, Mathews DP. Surgical and orthodontic management of impacted teeth. *Dent Clin North Am* 1993;37:181-204.
14. Lindauer SJ, Rubenstein LK, Hang WM, Andersen WC, Isaacson RJ. Canine impaction identified early with panoramic radiographs. *J Am Dent Assoc* 1992;123:91-92, 95-97.
15. Power SM, Short MB. An investigation into the response of palatally displaced canines to the removal of deciduous canines and an assessment of factors contributing to favorable eruption. *Br J Orthod* 1993;20:215-23.
16. Fearn J, Lee RT. Favourable spontaneous eruption of severely displaced maxillary canines with associated follicular disturbance. *Br J Orthod* 1988;15:93-8.
17. Chang C. Advanced damon course no.7: crowding: extraction vs. non-extraction. Taiwan: Newton's A Ltd, 2019.
18. Niagara K et al. Impacted maxillary central incisor, canine, and second molar with 2 supernumerary teeth and an odontoma. *Am J Orthod Dentofacial Orthop* 2009;135:390-9.
19. Halazonetis DJ. Horizontally impacted maxillary premolar and bilateral canine transposition. *Am J Orthod Dentofacial Orthop* 2009;135:380-9.
20. Broadbent BH. Ontogenic development of occlusion. *Angle Orthod* 1941;11:223-41.
21. Chang C, Roberts WE. Beethoven Podcast Encyclopedia in Orthodontics 2012. Taiwan: Newton's A Ltd, 2012.
22. Thomas B. Variable torque for optimal inclination. *Clinical Impression* 2009;1:1-9.
23. Tseng L, Chang C, Roberts WE. Diagnosis and conservative treatment of skeletal Class III malocclusion with anterior crossbite and asymmetric maxillary crowding. *Am J Orthod Dentofacial Orthop* 2016;149:555-66.
24. Oliver BM. The influence of lip thickness and strain on upper lip response to incisors reaction. *Am J Orthod* 1982;82:141-49.

Discrepancy Index Worksheet

TOTAL D.I. SCORE	25
-------------------------	-----------

OVERJET

0 mm. (edge-to-edge)	=	
1 – 3 mm.	=	0 pts.
3.1 – 5 mm.	=	2 pts.
5.1 – 7 mm.	=	3 pts.
7.1 – 9 mm.	=	4 pts.
> 9 mm.	=	5 pts.

Negative OJ (x-bite) 1 pt. per mm. per tooth =

Total	=	0
-------	---	---

OVERBITE

0 – 3 mm.	=	0 pts.
3.1 – 5 mm.	=	2 pts.
5.1 – 7 mm.	=	3 pts.
Impinging (100%)	=	5 pts.

Total	=	0
-------	---	---

ANTERIOR OPEN BITE

0 mm. (edge-to-edge), 1 pt. per tooth
then 1 pt. per additional full mm. per tooth

Total = 1

LATERAL OPEN BITE

2 pts. per mm. per tooth

Total	=	0
-------	---	---

CROWDING (only one arch)

1 – 3 mm.	=	1 pt.
3.1 – 5 mm.	=	2 pts.
5.1 – 7 mm.	=	4 pts.
> 7 mm.	=	7 pts.

Total = 7

OCCLUSION

Class I to end on	=	0 pts.	
End on Class II or III	=	2 pts. per side	<u> </u> pts.
Full Class II or III	=	4 pts. per side	<u>8</u> pts.
Beyond Class II or III	=	1 pt. per mm.	<u> </u> pts.
		additional	

Total = 8

LINGUAL POSTERIOR X-BITE

1 pt. per tooth	Total	=	0
-----------------	-------	---	---

BUCCAL POSTERIOR X-BITE

2 pts. per tooth	Total	=	0
------------------	-------	---	---

CEPHALOMETRICS (See Instructions)

$$\text{ANB} \geq 6^\circ \text{ or } \leq -2^\circ = 4 \text{ pts.}$$

Each degree $< -2^\circ$ _____ x 1 pt. = _____

Each degree $> 6^\circ$ _____ x 1 pt. = _____

SN-MP
 $\geq 38^\circ$ = 2 pts.

Each degree $> 38^\circ$ 2.5 x 2 pts. = 5

$$\leq 26^\circ = 1 \text{ pt.}$$

Each degree $< 26^\circ$ _____ x 1 pt. = _____

1 to MP $\geq 99^\circ$ = 1 pt.

Each degree $> 99^\circ$ _____ x 1 pt. = _____

Total = 7

OTHER (See Instructions)

Supernumerary teeth	_____	x 1 pt. = _____
Ankylosis of perm. teeth	_____	x 2 pts. = _____
Anomalous morphology	_____	x 2 pts. = _____
Impaction (except 3 rd molars)	<u>1</u>	x 2 pts. = <u>2</u>
Midline discrepancy ($\geq 3\text{mm}$)	_____	@ 2 pts. = _____
Missing teeth (except 3 rd molars)	_____	x 1 pts. = _____
Missing teeth, congenital	_____	x 2 pts. = _____
Spacing (4 or more, per arch)	_____	x 2 pts. = _____
Spacing (Mx cent. diastema $\geq 2\text{mm}$)	_____	@ 2 pts. = _____
Tooth transposition	_____	x 2 pts. = _____
Skeletal asymmetry (nonsurgical tx)	_____	@ 3 pts. = _____
Addl. treatment complexities	_____	x 2 pts. = _____

Identify:

Total = 2

Cast-Radiograph Evaluation

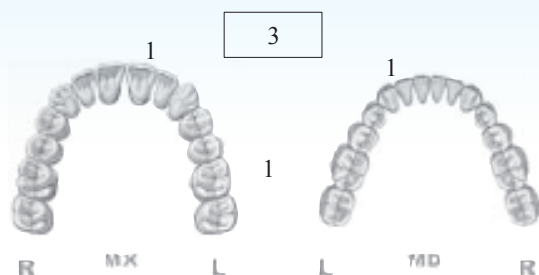
Case #

Patient

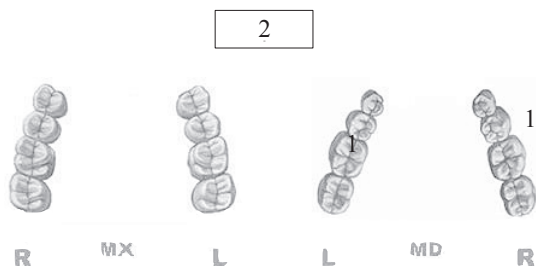
Total Score:

18

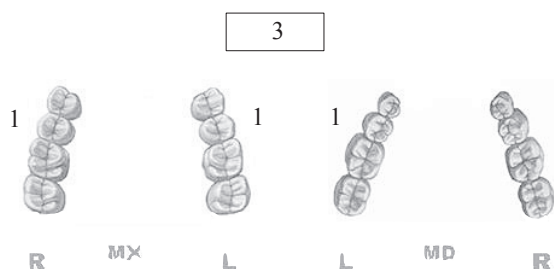
Alignment/Rotations



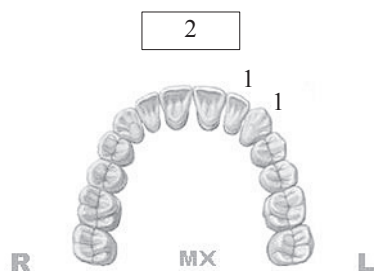Marginal Ridges



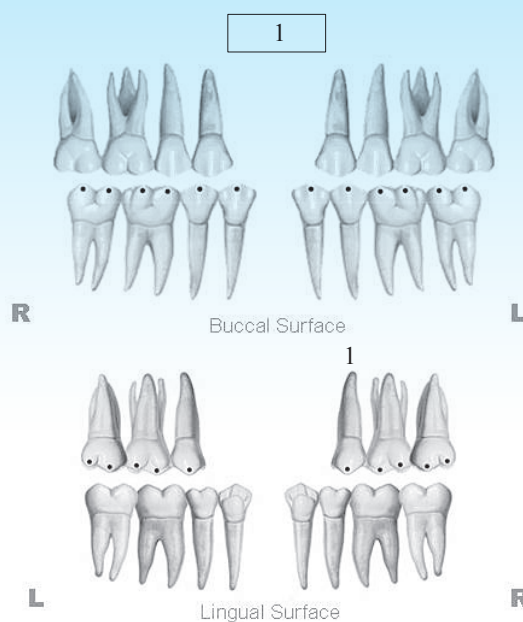
Buccolingual Inclination



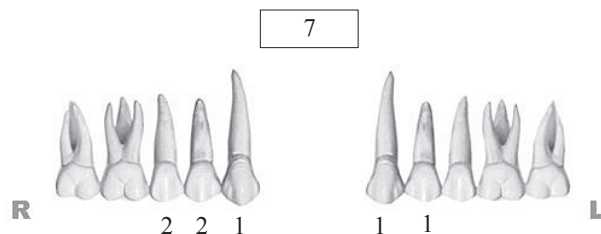
Overjet



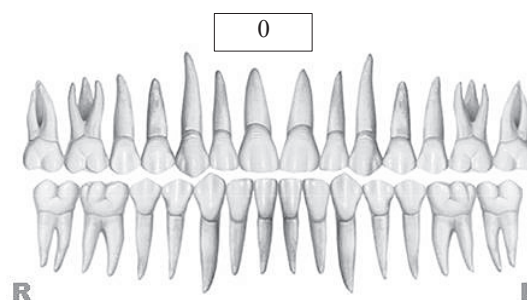
Occlusal Contacts



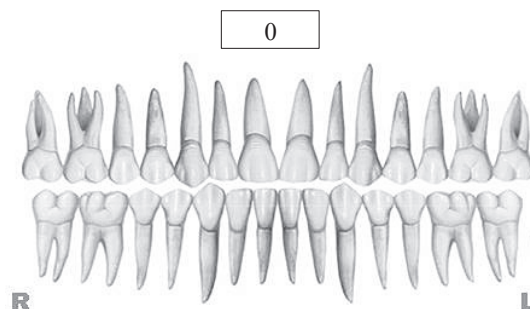
Occlusal Relationships



Interproximal Contacts



Root Angulation

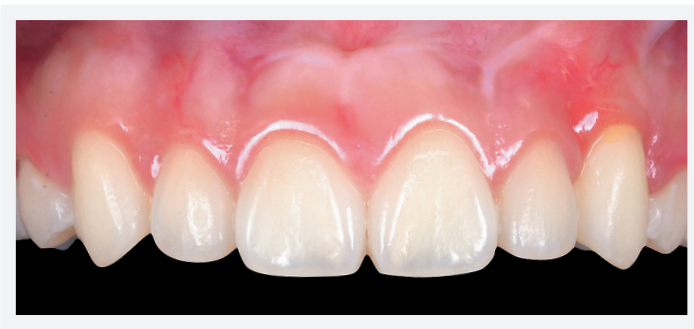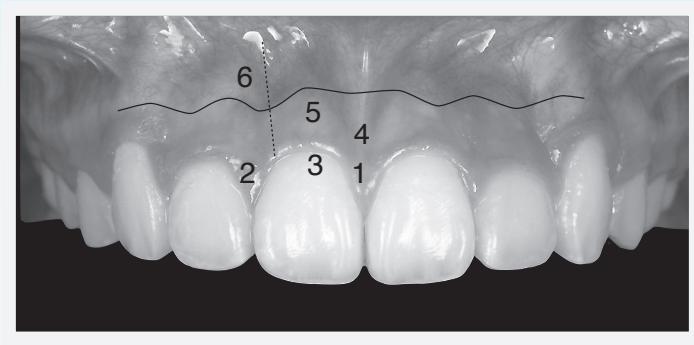


INSTRUCTIONS: Place score beside each deficient tooth and enter total score for each parameter in the white box. Mark extracted teeth with "X". Second molars should be in occlusion.

IBOI Pink & White Esthetic Score

Total Score: = **3**

1. Pink Esthetic Score

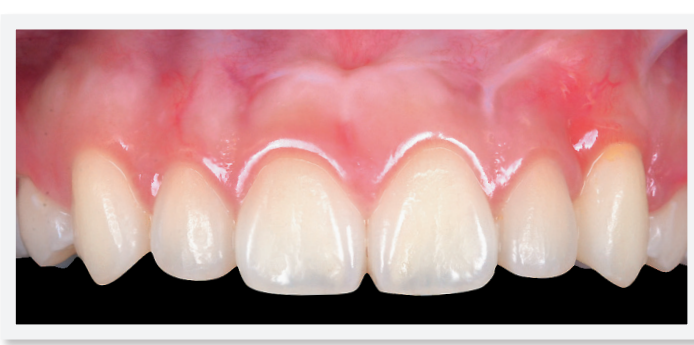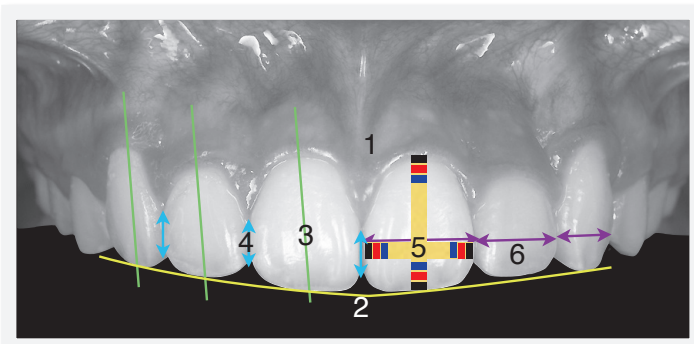


1. M & D Papillae	0	1	2
2. Keratinized Gingiva	0	1	2
3. Curvature of Gingival Margin	0	1	2
4. Level of Gingival Margin	0	1	2
5. Root Convexity (Torque)	0	1	2
6. Scar Formation	0	1	2

1. M & D Papilla	0	1	2
2. Keratinized Gingiva	0	1	2
3. Curvature of Gingival Margin	0	1	2
4. Level of Gingival Margin	0	1	2
5. Root Convexity (Torque)	0	1	2
6. Scar Formation	0	1	2

Total = **2**

2. White Esthetic Score (for Micro-esthetics)



1. Midline	0	1	2
2. Incisor Curve	0	1	2
3. Axial Inclination (5°, 8°, 10°)	0	1	2
4. Contact Area (50%, 40%, 30%)	0	1	2
5. Tooth Proportion (1:0.8)	0	1	2
6. Tooth to Tooth Proportion	0	1	2

1. Midline	0	1	2
2. Incisor Curve	0	1	2
3. Axial Inclination (5°, 8°, 10°)	0	1	2
4. Contact Area (50%, 40%, 30%)	0	1	2
5. Tooth Proportion (1:0.8)	0	1	2
6. Tooth to Tooth Proportion	0	1	2

Total = **1**