

# Correction of Anomalous Tooth Form Prior to Bonding Preadjusted Orthodontic Brackets

## Abstract

*Orthodontics is an art as well as a science. All preadjusted (straight-wire) appliances require precision bracket placement to efficiently achieve the desired functional and esthetic result. The geometric center of a bracket base is ideally positioned over the facial axis (FA) point, which is in the middle of the labial surface of a clinical crown, and in line with the long axis of the tooth. Prospective (pretreatment) tooth contouring may be necessary to optimally position brackets for facilitating the function and esthetics of the final alignment. A step-by-step procedure is described for reshaping anomalous tooth form to reliably bond a bracket at the desired FA point to help achieve an optimal result. (Int J Orthod Implantol 2016;44:64-71)*

## Introduction

Aesthetics and esthetics are synonymous terms that are associated with desired orthodontic outcomes. Although ideal occlusion is an important outcome for orthodontists, the public usually focuses on facial appearance, particularly the smile. The critical consideration is the maxillary anterior segment: The Esthetic Zone. Shape and alignment of the incisors and canines are premier objectives for patients and their families.

Pitts<sup>1</sup> emphasizes recontouring of teeth before bonding to enhance dental esthetics, improve the fit of the brackets, and to achieve an attractive smile arc. Macroenamel recontouring (*enameloplasty*) is carefully planned with a careful clinical examination and a detailed study of stone casts.

## Objectives

The aim of enameloplasty is to enhance the interarch alignment and appearance of individual teeth to achieve optimal function and an attractive smile. The goal of this article is to highlight the usefulness of small anatomical corrections and cosmetic contouring for enhancing orthodontic outcomes.

## Armamentarium

A high speed handpiece with fine diamond burs (*elliptical and end-cutting*), as well as rotary instrumentation with a sandpaper disc was used to trim teeth and smooth rough edges. Adjusted areas were polished with a white stone bur or a sandpaper finishing strip, and fluoride was applied to the finished surface. With modest anatomical corrections, there is little risk of complications.

**Dr. Linda Tseng,**  
Lecturer, Beethoven Orthodontic Course (Left)

**Dr. Chris Chang,**  
Founder, Beethoven Orthodontic Center  
Publisher, International Journal of Orthodontics & Implantology (Center)

**Dr. W. Eugene Roberts,**  
Editor-in-chief, International Journal of Orthodontics & Implantology (Right)

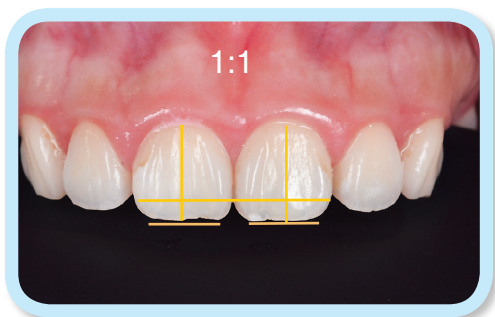

However, if teeth do become sensitive, it is usually due to excessive enamel removal and/or a prominent pulp. A thin layer of restorative composite or laser desensitization is usually effective for managing sensitivity.

### Case 1

A young female beginning her orthodontic treatment had central incisors with numerous esthetic deficiencies:

1. Square shape: height to width ratios of about 1:1 (Fig. 1)
2. Greater width in the contact area than at the incisal edge (*inverted taper*)

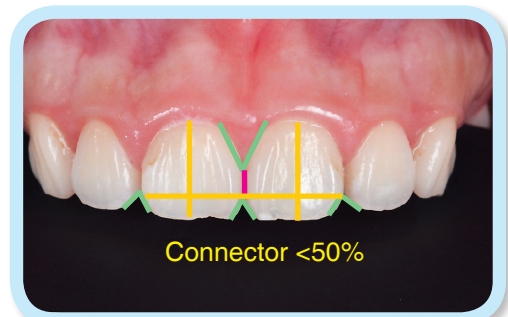


■ **Fig. 1:** Large, square-shaped maxillary central incisors are unattractive because: 1. height/width ratio of 1:1, 2. interproximal contact area is gingivally positioned, and 3. width of the tooth is greater in the middle aspect of the crown than at the incisal edge.

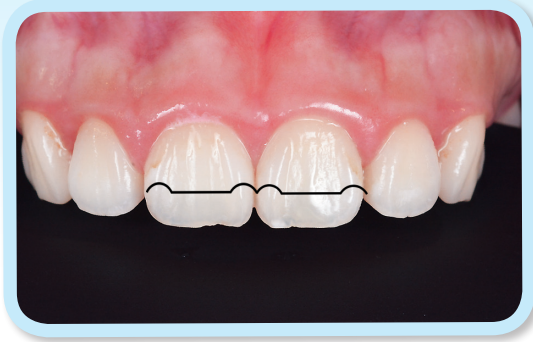3. Excessive incisal embrasures result in apically positioned, relatively narrow contact areas: connector <50% (Fig. 2).
4. Prominent mesial and distal marginal ridges on the labial surface (*double shoveling*) (Fig. 3).
5. Irregular incisal edges (Fig. 4).

### Enameloplasty Step By Step

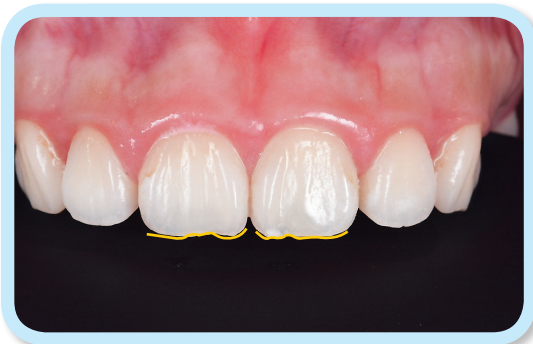**Step 1:** Periapical radiograph(s) reveal the long axis of the tooth (*teeth*) to be trimmed. Only well aligned teeth are good candidates for enameloplasty. Reshaping malposed teeth is not recommended because it is difficult to visualize the appropriate tooth shape that will result in a desired final



■ **Fig. 2:** Additional unattractive features of the central incisors are excessive incisal embrasures (green inverted Vs), short connector (<50%) as shown by the pink line, and a hyperplastic midline papilla (green V).



■ **Fig. 3:**  
Prominent mesial and distal marginal ridges, delineated by a back contour line on the labial surface of the central incisors, was diagnosed as the double shoveling trait.

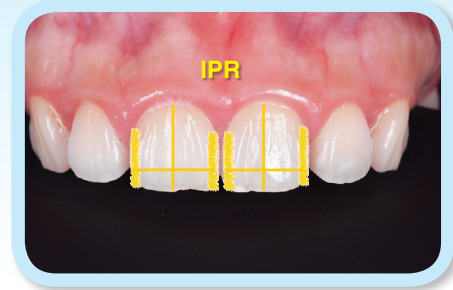


■ **Fig. 4:**  
Incisor edges of the central incisors were irregular (yellow lines).

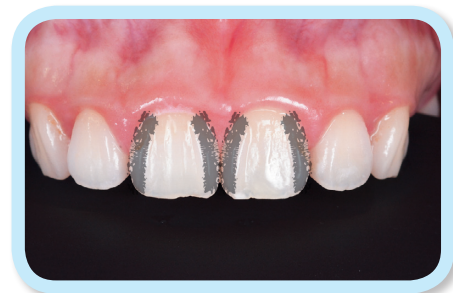alignment. Adjusting enamel contours, out of context with adjacent teeth, can result in irreparable damage.<sup>3-7</sup>

**Step 2:** IPR (*interproximal reduction*) of enamel is performed to reduce the width of the two central incisors (Fig. 5). The procedure begins by reshaping the connector between the central incisors using a fine diamond fissure bur. The enamel reduction should be no more than 0.5mm (0.25mm each side) per tooth.

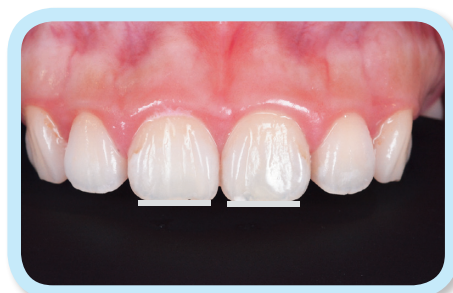**Step 3:** Prominent marginal ridges (*double shoveling*) were smoothed with a flat-end high speed diamond



■ **Fig. 5:**  
Interproximal reduction (IPR) of the enamel (bold yellow lines) was performed to reduce the width of the incisors. The thin yellow lines are references for the axial inclination and width of each labial surface as defined in Fig. 1.



■ **Fig. 6:**  
The prominent marginal ridges were smoothed with a flat-end diamond bur and polished with a white stone as illustrated with the textured gray lines.



■ **Fig. 7:**  
The incisor edges were smoothed and leveled with a fine sandpaper disc.

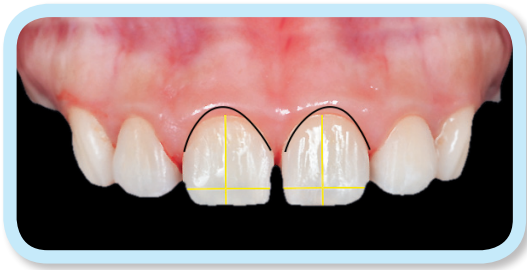
bur, and then the adjusted surface was polished with a white stone (Fig. 6).

**Step 4:** The incisor edges were smoothed with a sandpaper disk (Fig. 7).

**Step 5:** All line angles were rounded and smoothed with sandpaper strips.

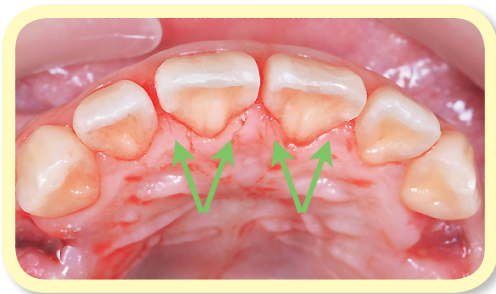
### Result Achieved

The width to height ratio was about 0.8, and the connector length between central incisors was increased to the ideal of ~50%. A soft tissue laser was used to improve crown height as well as to reshape gingival contours and relocate the gingival zenith relative to the interdental papillae (Fig. 8). From the occlusal view (Fig. 9), the labial surface of the central incisors was smooth after marginal ridge recontouring, but the palatal contours required



■ Fig. 8:

After enameloplasty relative to the yellow reference lines, the width to height ratio was ~0.8, and the length of the interproximal connector was ~50% of crown height. The curved black line at the free gingival margin shows that gingival recontouring is required to increase the clinical crown height, and to relocate the gingival zenith.



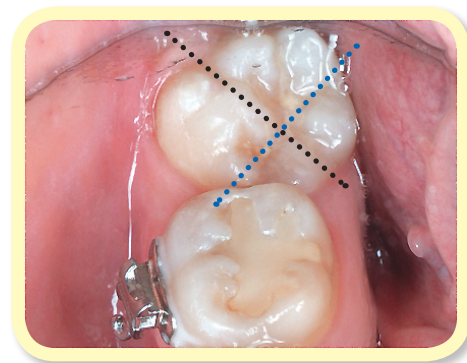
■ Fig. 9:

After IPR to reduce crown width, the prominent marginal ridges (green arrows) require recontouring to create optimal palatal embrasures, and to prevent occlusal interferences with the antagonist incisors.

more reduction to avoid interfering with the overbite, overjet and interproximal alignment. All the reshaped contours were thoroughly inspected from multiple perspectives and polished with a white finishing stone.

### Case 2

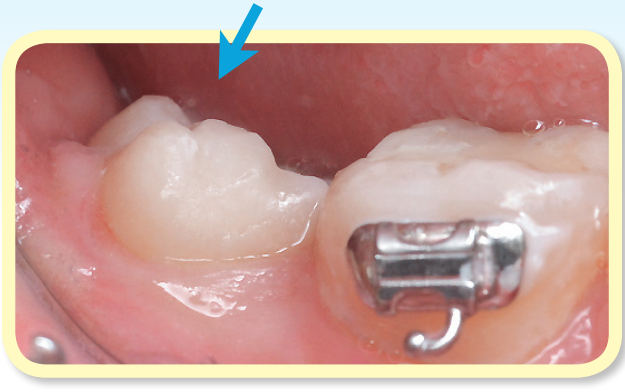
An extra cusp (*protostylid*) in the middle of the buccal surface of the lower second molar impeded bracket placement (Figs. 10 and 11). Protostylids are relatively common anomalies (*deviations from what is standard, normal, or expected*) in Asian populations, as well as their descendants, the natives of the Americas.<sup>2</sup> The most common protostylid is a supernumerary cusp protruding from the buccal surface of upper and/or lower permanent molars. In the usual (*normal*) configuration, the buccal groove is on or near the the facial axis (FA) point on lower molars. During development, a protostylid can separate the mesial



■ Fig. 10:

The buccal groove is typically the FA point of the lower molars, but a protostylid has grossly distorted normal morphology. The blue dotted line, with a perpendicular black dotted line, demonstrates the distortion of the buccolingual and mesiodistal dimensions, respectively. Reduction of protostylid is indicated. However, care must be exercised to not penetrate the enamel.





■ **Fig. 11:**  
*The protostylid impeded the placement of the bracket. Recontouring the labial surface of the affected molar was indicated to obtain an enamel profile that was compatible with the base of the bracket.*

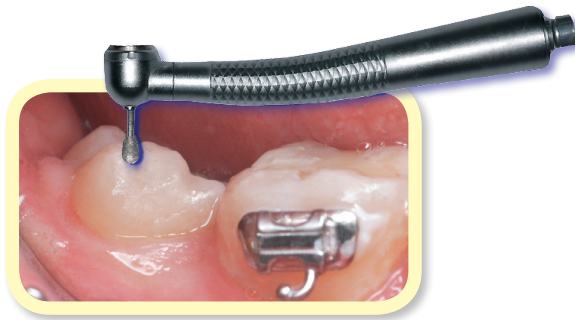
and distal cusps, resulting in three cusps on the facial surface (Fig. 10). Obliteration of the buccal groove and FA point precluded precise bonding of a preadjusted bracket (Figs. 10 and 11).

A high speed handpiece with a diamond bur was used to remove the bulging supernumerary cusp. Then the adjusted area was polished with a white

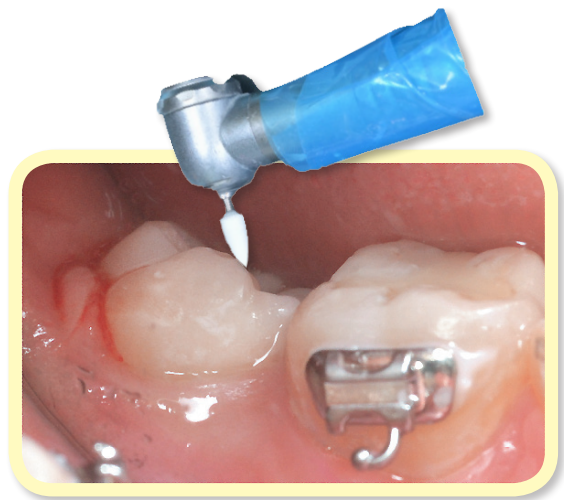stone bur (Figs. 12, 13). In this instance, an acceptable labial surface was achieved, so the bracket was bonded in the optimal position (Fig. 14).

### Discussion

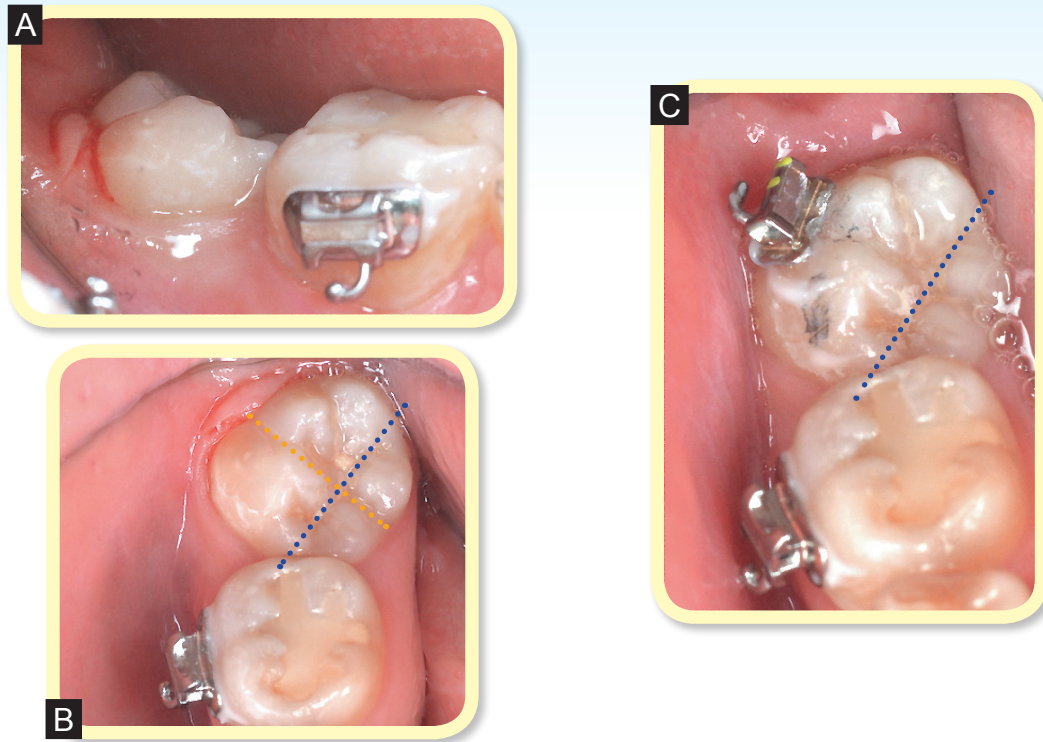
The criteria for dental esthetics include (1) tooth proportionality, (2) contacts, connectors and embrasures, and (3) gingival characteristics.<sup>3-7</sup> As shown in Fig. 15, the ideal maxillary central incisor width to height proportion is ~0.8. The most occlusal aspect of the contact area between the central incisors (*connector*) is progressively positioned higher (*more apical*), compared to the incisal edges or marginal ridges, for central incisors lateral incisors and canines, respectively (Fig. 16). Connector length between the maxillary anterior teeth progressively decreases from ~50 to 40 to 30% of crown height, from the central incisors to the



■ **Fig. 12:**  
*A high speed handpiece with an elliptical diamond bur was used to adjust the bulging cusp.*

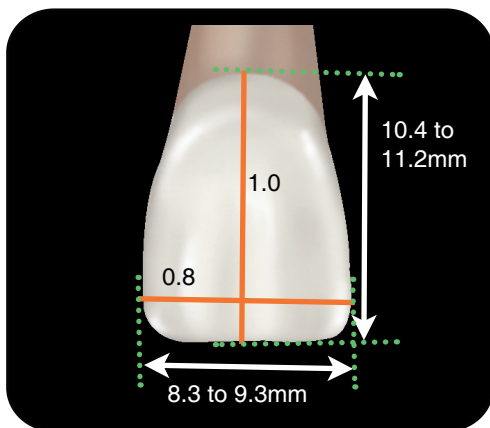


■ **Fig. 13:**  
*The adjusted area was polished with a white stone bur.*



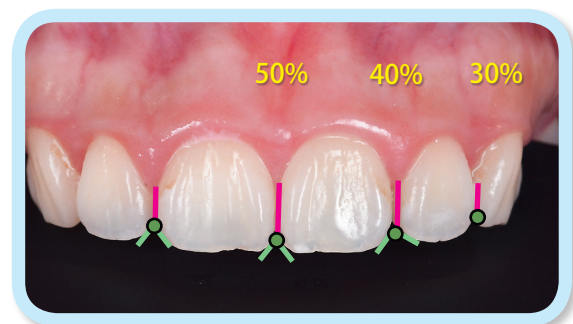
■ Fig 14:

A suitable curvature was achieved (A) for bonding the tube along the FA, as defined by the orange dotted line (B), which is perpendicular to the central groove, as defined by the blue dotted line (C).



■ Fig. 15:

As shown, the normal variation (between the green dotted lines) for the height and width of a central incisor crown varies considerably, but the most esthetic ratio is a constant: ~0.8.

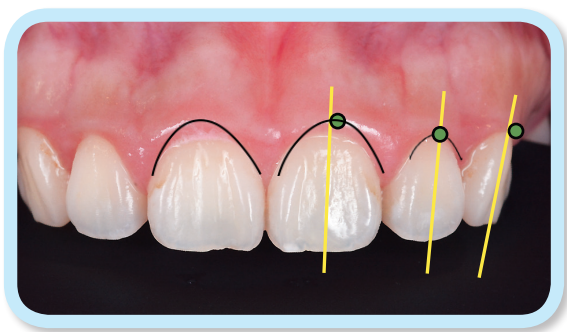


■ Fig. 16:

As shown, there is a descending order for the connector height from maxillary central incisor to the canines, bilaterally. The ideal connector, compared to crown height, on the mesial surface in the maxillary anterior segment is 50, 40 and 30% for centrals, laterals and canines, respectively. The most superior margin of the connectors (green dots) are the base of the embrasures (green lines).

canines. Embrasure depth, coronal to the connector, shows an ascending pattern from the midline to the canines (Fig. 16). Gingival esthetics depends on both shape and contour of the attached mucosa. Shape is typically defined as the curvature of the free gingival margin. Maxillary central incisors and canines are most esthetic with an elliptical profile of the free gingival margin, but the lateral incisors benefit from a compressed half-oval shape, that is symmetrical. Gingival contour is determined by the soft tissue zenith, i.e. the most apical curvature of the free gingival margin. It is located distal to the long axis of the central incisors and canines, but is coincident with the long axis of the lateral incisors (Fig. 17).

If the palatal marginal ridges on maxillary central incisors are particularly prominent and enclose a deep fossa, the shape of the palatal surface of the incisor resembles a shovel or a scoop. When shovel-shaped incisors also feature prominent marginal ridges on the mesial and distal aspects of the labial surface, the anatomical variation is deemed double



■ **Fig. 17:** Esthetic soft tissue contours in the maxillary anterior segment are defined by a smooth margin (black lines) of the free gingiva, associated with a properly positioned zenith (green dot). The gingival zenith is slightly distal to the tooth long axis (yellow lines) for central incisors and canines, but it is on the long axis for lateral incisors.

shoveling.<sup>2,3</sup> These features are Asian characteristics that are also expressed in native Americans,<sup>2</sup> but are rare or absent in African and European populations.<sup>3</sup> Hyperplasia of the upper incisors, resulting in an excessive mesiodistal dimension, that is directly related to the shovel-shape morphology. Although males usually have larger teeth than females, the anomalous large, shovel and double shovel teeth are more common in females.<sup>2,3</sup> These anomalies are unesthetic and may interfere with occlusion, overjet, and overbite, as well as soft tissue contours (Fig. 9).<sup>4-7</sup>

Pitts<sup>1</sup> routinely corrects dental contours as needed before bonding a fixed appliance to optimize the fit of the bracket bases. This pretreatment preparation is designed to enhance esthetics, improve interproximal contacts, and optimize occlusion. The relationship of the bracket base to the tooth surface is particularly important for expressing proper torque.<sup>1,3</sup> Cusp and fossa adjustments are helpful for minimizing occlusal interferences.<sup>5,6</sup> Dental esthetics are improved by smoothing incisal edges and facial enamel. Optimizing the canine cusp position is important for protecting the smile arc, and facilitating the correction of Class II and III malocclusions with intermaxillary elastics.<sup>1</sup>

With respect to preadjusted brackets for a straight wire appliance (SWA), the design of the bracket base must be properly contoured to aid the orthodontist achieving optimal bracket placement. It follows that the most important factor in achieving an efficient, high quality outcome is bracket position. Brackets are designed to be placed according to the FA point, which is the middle of the clinical crown for all teeth

throughout the arch. Anomalies that interfere with the normal curvature of the labial surface should be adjusted prior to bonding. The objective of the enameloplasty is to restore normal anatomy, if at all possible.

Protostylids are highly variable anomalies that commonly affect the labial surface of lower molars. The defect may range from a pit or pearl in the buccal groove, to a furrow or a prominent cusp that substantially distorts the normal labial contour. Some form of the protostylid anomaly is present in up to 40% of susceptible populations.<sup>2,3</sup> The example shown in *Case 2* was a bulging cusp (*protostylid*) that displaced the buccal groove to the distal and obliterated the normal FA point (*Fig. 14*). The defect preempted normal bracket placement, so it was adjusted to permit reliable bonding of the bracket designed for the tooth. Although enameloplasty permits routine treatment of an anomalous molar, it is almost always necessary to correct the final alignment with detailing bends.

## Conclusion

Fixed appliance systems are designed to fit the average (*most common*) dental morphology, but normal tooth form is commonly altered by genetic and environmental anomalies. If abnormal enamel contours impede precise bracket placement, tooth reshaping is necessary to achieve optimal occlusion and an esthetic smile line. Contemporary orthodontic diagnosis and treatment planning requires careful assessment of tooth shape and form, as part of the comprehensive evaluation.

Enameloplasty is an important aspect of patient preparation for routinely achieving desirable outcomes.

## Acknowledgement

Thanks to Mr. Hughes for proofreading this article.

## References

1. Pitts T. Begin with the end in mind: bracket placement and early elastics protocols for smile arc protection. *Clin Impressions* 2009;17:4-13.
2. Dahlberg A. Analysis of the American Indian Dentition. In: Brothwell DR, editor. *Dental Anthropology*. Oxford: Pergamon; 1950. pp. 149-77.
3. Sarver DM. Principles of cosmetic dentistry in orthodontics: Part 1. Shape and proportionality of anterior teeth. *Am J Ortho Dentofacial Orthop* 2004;126:749-53.
4. Sarver DM. Principles of cosmetic dentistry in orthodontics: Part 2. Soft tissue laser technology and cosmetic gingival contouring. *Am J Ortho Dentofacial Orthop* 2005;127:85-90.
5. Sarver DM. Enameloplasty and esthetic finishing in orthodontics-Identification and treatment of microesthetic features in orthodontics Part 1 *Journal of Esthetic and Restorative Dentistry* 2011;23:296-302.
6. Sarver DM. Enameloplasty and esthetic finishing in orthodontics-The importance of appropriate visualization and records Part 2 *Journal of Esthetic and Restorative Dentistry* 2011;23:303-313.
7. Paliwal M, Thoma A, Balani R, Ekka S. Application of cosmetic contouring in orthodontic esthetic dentistry-A case report. *Int J of Advanced Dental Science and Technology* 2013;1:10-13.

