

Acquired Malocclusion Due to Early Loss of Permanent First Molars: OBS-Anchored Orthodontics and Implant-Supported Prostheses

Abstract

A 27-year-old female presented with a complex malocclusion: 1. mandibular midline and occlusal plane deviated to the left, 2. excessive gingival display when smiling, 3. multiple missing teeth, 4. atrophic edentulous space in the upper left first premolar area, 5. deepbite, and 6. lingual crossbite from the maxillary right lateral incisor to the second premolar. All four first molars plus the upper left first premolar were missing, and the upper right first premolar was compromised. Etiology of the severe acquired malocclusion, Discrepancy Index (DI) 33, was attributed to an occlusal collapse when the deciduous second molars exfoliated. Treatment was rendered with a full fixed orthodontic appliance, utilizing passive self-ligating brackets and extra-alveolar (E-A) OrthoBoneScrew (OBS) anchorage. Orthodontic site development, followed by implant-supported prostheses restored the maxillary second premolar areas. A diode laser was used for a maxillary midline frenectomy, and selective gingivectomy to improve soft tissue contours. The interdisciplinary treatment for this severe malocclusion required 71 months. Outcome assessments were a Cast-Radiograph Evaluation (CRE) score of 25, Pink & White dental esthetic score of 5, and implant esthetic score of 0. (*Int J Orthod Implantol* 2016;42:20-41)

Key words:

Self-ligating fixed appliance, lingual crossbite, bite turbos, extra-alveolar (E-A) OrthoBoneScrews (OBSs), gummy smile, gingivectomy, diode laser, occlusal canting, midline discrepancy, 2B-3D rule, Implant site development.

History and Etiology

A 27-year-old female presented for an evaluation of multiple edentulous spaces, dental extrusion, crossbite, gummy smile and facial asymmetry (Figs. 1-3). There were no contributory medical problems; however, the early loss of permanent first molars appeared to be a major contributing factor to the acquired malocclusion. The complex acquired malocclusion had five missing permanent teeth, all four first molars and the upper left first premolar, and the left second premolar was compromised by severe attrition and endodontic treatment. The alignment of the dentition was irregular due to occlusal compensations. From the occlusal view, severe atrophy of the buccal surface was noted in the upper left first premolar area, and there was a lingual crossbite from the right lateral incisor to the second premolar. Excessive gingival exposure was apparent when smiling. The mandibular midline and occlusal plane were canted to the left (Fig. 2). The patient was treated to an good dentofacial relationship (Figs. 4-9). Cephalometric and panoramic radiographs document the pre-treatment condition (Fig. 7) and the post-treatment results (Fig. 8). Superimposed cephalometric tracings before and after treatment are shown in Fig. 9. The diagnosis, interdisciplinary treatment and outcomes for this challenging malocclusion are discussed in detail.

Dr. Ming-Jen Chang,


Associate editor, International Journal of Orthodontics & Implantology (Left)

Dr. Chris Chang,

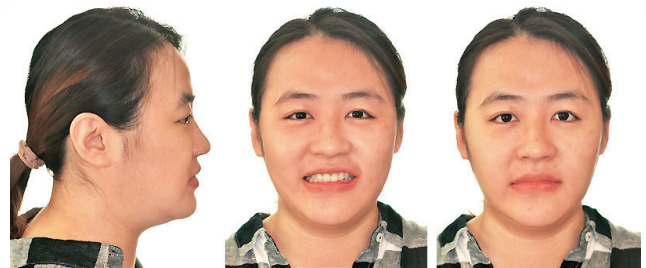*Founder, Beethoven Orthodontic Center
Publisher, International Journal of Orthodontics & Implantology (Center)*

Dr. W. Eugene Roberts,

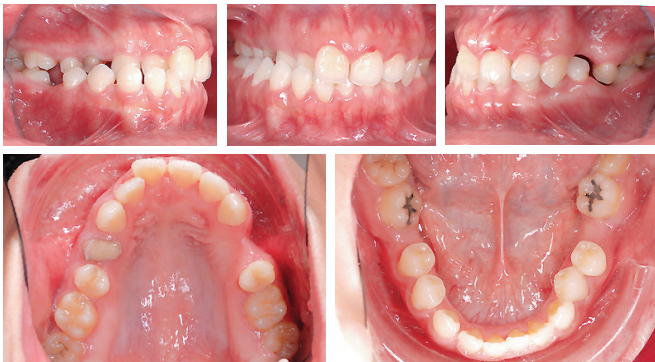Editor-in-chief, International Journal of Orthodontics & Implantology (Right)



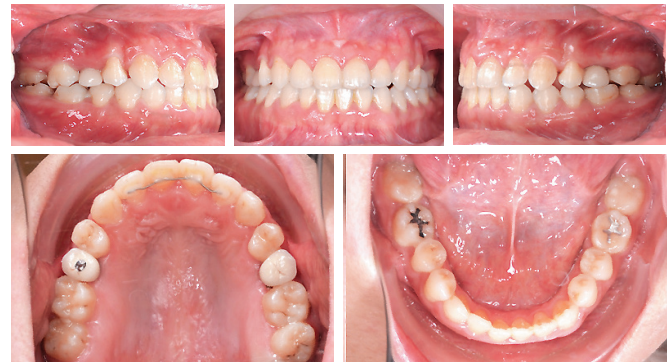■ Fig. 1: Pre-treatment facial photographs



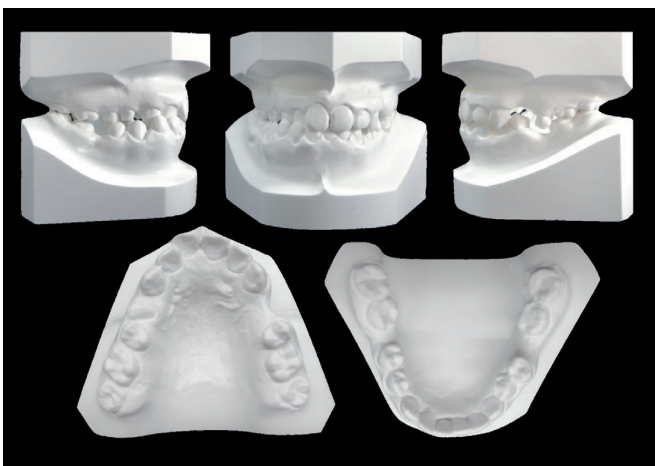■ Fig. 4: Post-treatment facial photographs



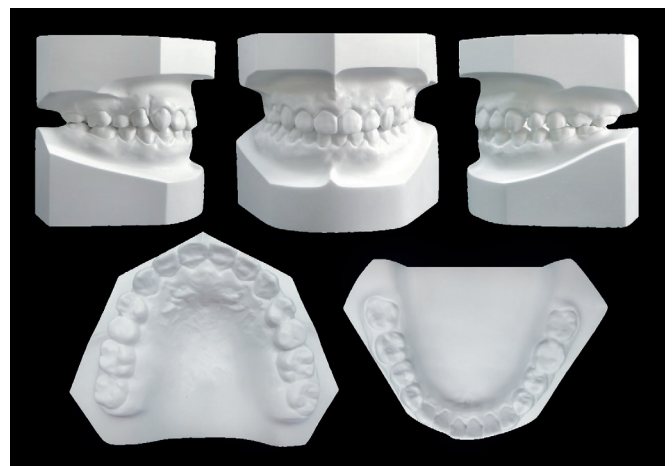■ Fig. 2: Pre-treatment intraoral photographs



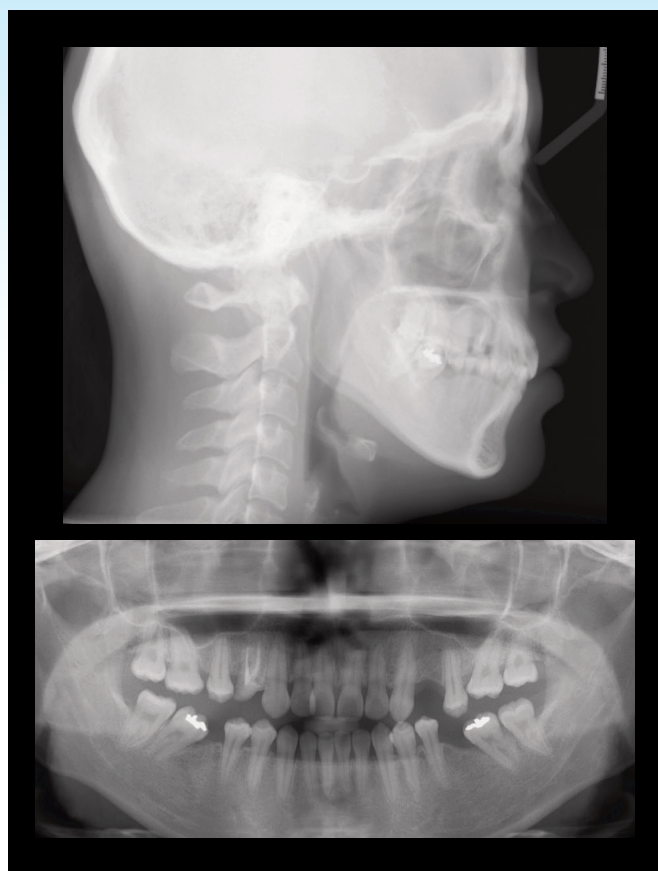
■ Fig. 5: Post-treatment intraoral photographs



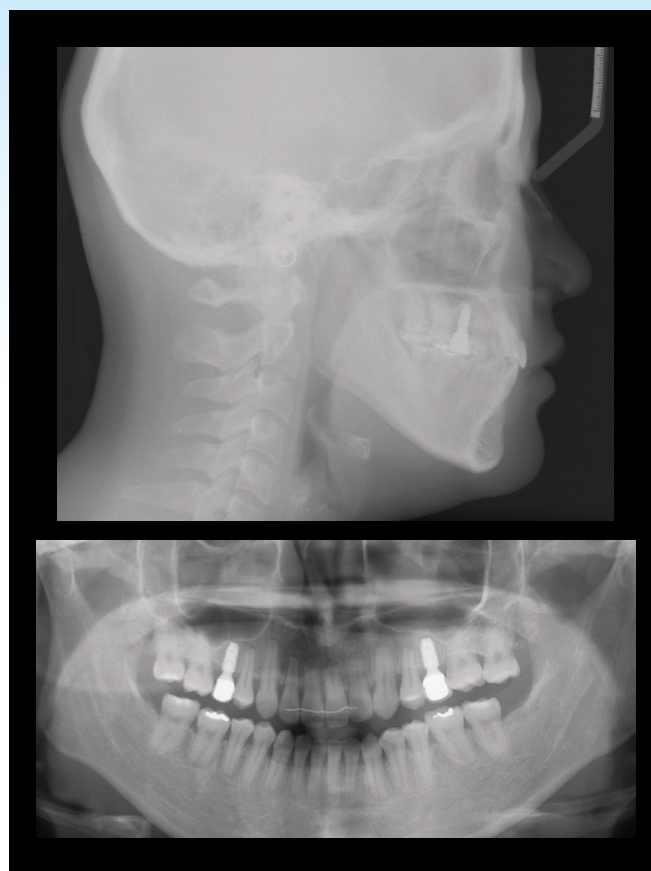
■ Fig. 3: Pre-treatment study models (casts)



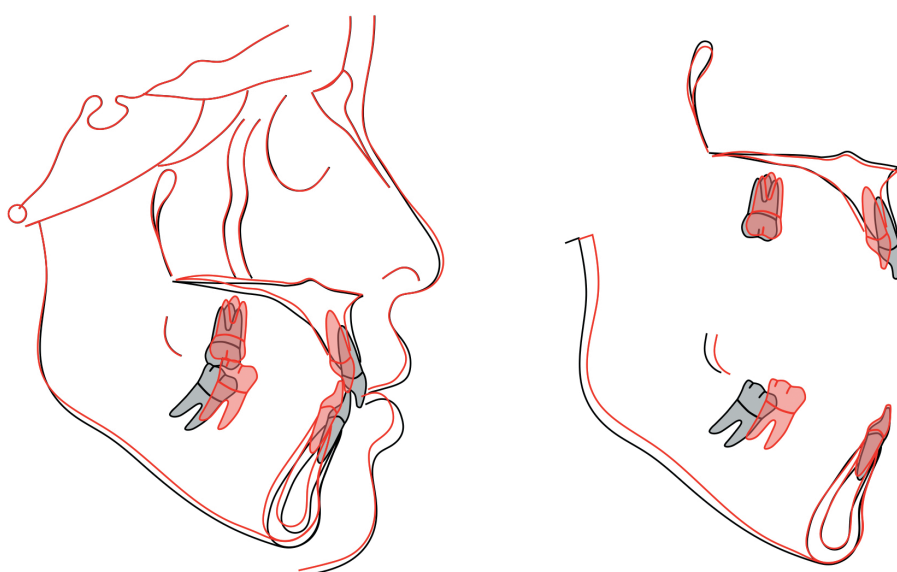
■ Fig. 6: Post-treatment study models (casts)



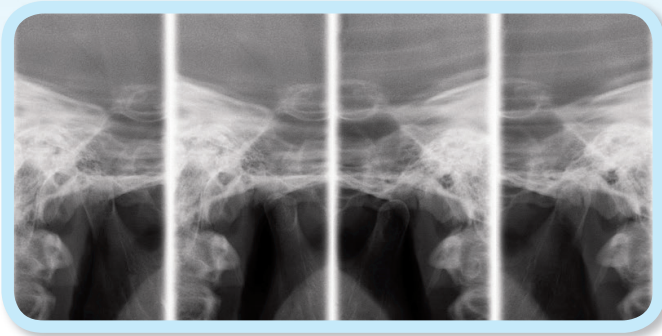
■ **Fig. 7:**
Pre-treatment cephalometric and panoramic radiographs



■ **Fig. 8:**
Post-treatment cephalometric and panoramic radiographs



■ **Fig. 9:**
Superimposed tracings of the pre-treatment (black) and post-treatment (red) cephalometric radiographs show the dental and skeletal changes during treatment. See text for details.



■ Fig. 10:

The morphology of the mandibular condyle heads was asymmetrical.

Diagnosis

Skeletal:

- Sagittal Relationship: $SNA\ 81^\circ$, $SNB\ 76^\circ$, $ANB\ 5^\circ$
- High mandibular plane angle: $SN-MP\ 44^\circ$, $FMA\ 37^\circ$
- Condylar heads: *asymmetric in length (Fig. 10)*

Dental:

- Bilateral Class I molar relationships
- Missing teeth: #3, 12, 14, 19, & 30
- Compromised teeth: *severe attrition and root canal treatment of #5*
- Lingual crossbite: *from the maxillary right lateral incisor to the second premolar*
- Occlusal Compensation: *multiple teeth extruded and/or tipped into edentulous spaces*
- Alveolar process atrophy: *buccal aspect of the edentulous #12 space*
- Midlines: *mandible was shifted 3mm to the right of the maxillary dental midline*
- Esthetics: *gummy smile and occlusal canting*

Facial:

- Profile: *facial convexity and lip protrusion is within normal limits (WNL)*
- Facial symmetry: *deviated to the right*

The ABO Discrepancy Index (DI) was 33, as documented in the subsequent worksheet.

Specific Objectives of Treatment

1. Align and level the dentition
2. Prepare implant sites and correct interocclusal spaces
3. Correct the lingual crossbite
4. Correct the gummy smile, dental midline deviation and occlusal canting
5. Achieve an ideal overjet and overbite relationship

Maxilla (all three planes):

- A - P: *Maintain*
- Vertical: *Maintain*
- Transverse: *Expand to correct the lingual crossbite*

Mandible (all three planes):

- A - P: *Maintain*
- Vertical: *Maintain*
- Transverse: *Maintain*

Maxillary Dentition:

- A - P: *Retract incisors and move molars anteriorly*

- Vertical: *Maintain*
- Inter-molar / Inter-canine Width: *Expand as needed to correct anterior crowding*

Mandibular Dentition:

- A - P: *Mesial movement and up-righting of molars, slight retraction of incisors*
- Vertical: *Slightly extrude molars as they are up-righted*
- Inter-molar / Inter-canine Width: *Expand as needed to relieve anterior crowding*

Facial Esthetics:

- Maintain the profile, correct gummy smile

Treatment Plan

Minimizing the numbers of implants was an important objective. The first priority was to extract the residual portions of the upper right first premolar (#5). High torque brackets were prescribed for the upper incisors and standard torque brackets for the lower incisors. A bite turbo was planned to facilitate development of the arch form and the correction of the lingual crossbite.

Place OrthoBoneScrews® (OBSs) (Newton's A Ltd, Hsinchu, Taiwan) bilaterally in the mandibular buccal shelves, as well as between the maxillary central and lateral incisors bilaterally, to intrude the maxillary anterior segment. Intermaxillary elastics were prescribed for midline and occlusal plane correction as needed.

Implant site development: translate both upper second premolars anteriorly to prepare an adequate

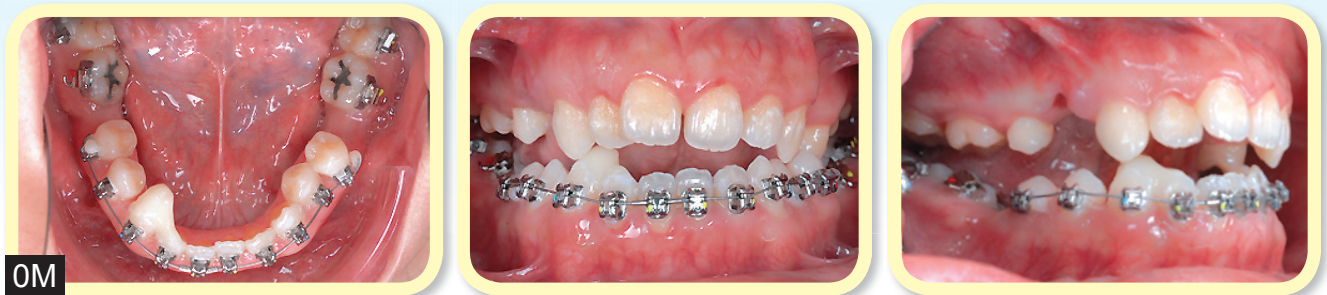CEPHALOMETRIC			
SKELETAL ANALYSIS			
	PRE-Tx	POST-Tx	DIFF.
SNA°	81°	80°	1°
SNB°	76°	75.5°	0.5°
ANB°	5°	4.5°	0.5°
SN-MP°	44°	43°	1°
FMA°	37°	36°	1°
DENTAL ANALYSIS			
U1 TO NA mm	1 mm	1 mm	0 mm
U1 TO SN°	94°	92.5°	1.5°
L1 TO NB mm	6 mm	5 mm	1 mm
L1 TO MP°	83.5°	80.5°	3°
FACIAL ANALYSIS			
E-LINE UL	-1 mm	-3 mm	2 mm
E-LINE LL	0.5 mm	-2 mm	2.5 mm

■ Table 1: Cephalometric summary

ridge proximal to the maxillary molars. Retain the corrected dentition with a lingual fixed retainer for the mandibular anterior segment, and clear overlay retainers for both arches.

Appliances and Treatment Progress

Following extraction of the upper right first premolar, an .022" slot D3MX® fixed appliance (Ormco Corporation, Glendora, CA) was bonded on the lower arch, utilizing standard torque brackets on the incisors. Following placement of the initial archwire (.014" CuNiTi), an anterior bite turbo was bonded on the occlusal surface of the lower left canine (#27) to open the bite for lingual crossbite correction (Fig. 11). To balance the occlusion an additional bite turbo

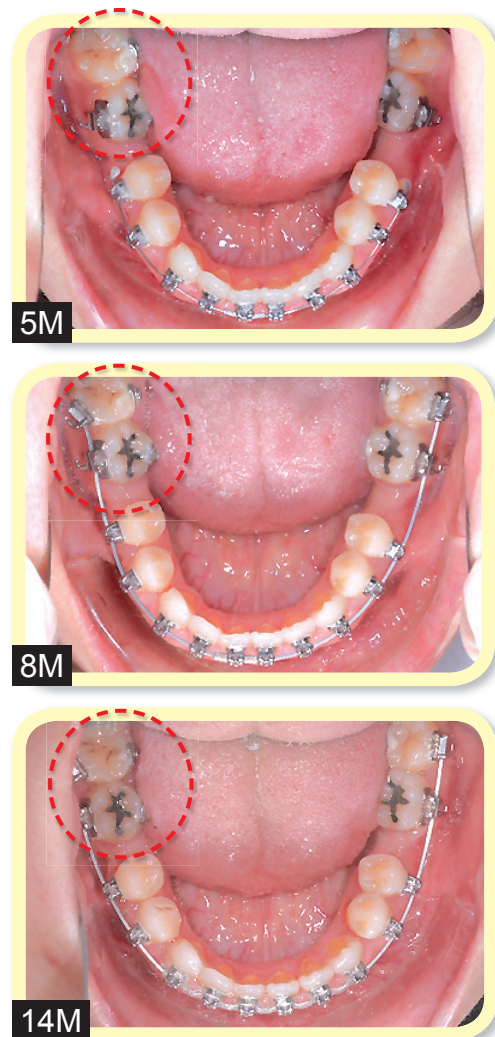


■ Fig. 11: To assist in correcting the right buccal crossbite, a bite turbo was bonded on the lower right canine (#27).

can be placed on the lower left terminal molar if needed. High torque brackets were bonded on the maxillary anterior teeth three weeks later. After two months of initial alignment and leveling, the lingual crossbite was corrected and the bite turbo(s) were removed. Lingual buttons were bonded on all four mandibular molars and cross elastics (*Chipmunk 1/8"*, 3.5oz) were applied to all molars (Fig. 12).

The upper arch was bonded and aligned with the following arch wire sequence: .014" CuNiTi, .016" CuNiTi, .014x.025" NiTi, .017x.025" TMA, .019x.025" SS and .019x.025" pretorqued 20°. The lower arch was aligned with the following arch sequence: .014" CuNiTi, .018" CuNiTi, .014x.025" NiTi, .017x.025" TMA and .016x.025" SS. During the course of the treatment, flexible sleeves were placed on the upper archwire in the first premolar edentulous areas to prevent irritation of the buccal mucosa (Fig. 13).

Implant Site Preparation: The atrophy of the buccal plate required bilateral bone augmentation procedures, prior to placing implants in the maxillary first premolar edentulous spaces. The



■ Fig. 12:

Once the upper right teeth lingual crossbite was corrected, the bite turbo was removed (5M). After the crossbite was corrected, the lower posterior segments were rapidly aligned (8M and 14M). aligned, particularly on the patient's right side (red dotted circles), (8M and 14M).

patient had financial constraints and concerns about additional surgery, so an alternate approach was selected: translate second premolars anteriorly to prepare implant sites proximal to the upper molars, bilaterally. At 26 months into treatment (Fig.

14) lingual buttons were bonded on the maxillary canines and premolars to facilitate mesial translation of the premolars. Power chains were used on the buccal and lingual surfaces to move the premolars anteriorly (Fig. 14).

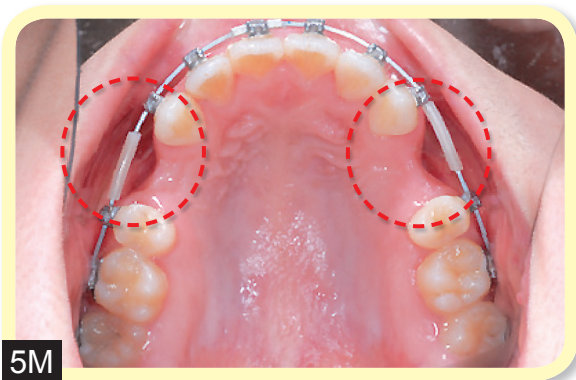


Fig. 13:
Two flexible sleeves were inserted on the archwire in the maxillary edentulous areas (red dotted circles) to control irritation of buccal mucosa.

Anterior bite turbos were placed on the palatal surfaces of the two upper central incisors (#8 and 9) to facilitate correction of the anterior overbite (Fig. 14). The patient was instructed to wear Class II light, short elastics (Fox 1/4, 3.5oz) bilaterally from the upper canines to the lower 2nd molars to retract the upper anterior teeth and reduce the overjet.

In the 33rd month of treatment (33M), a progress panoramic radiography was taken to evaluate axial inclinations. Brackets were repositioned on

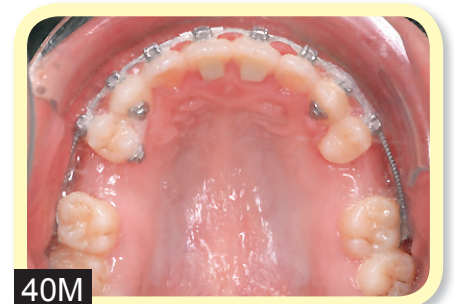
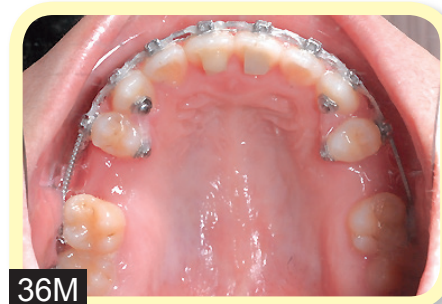
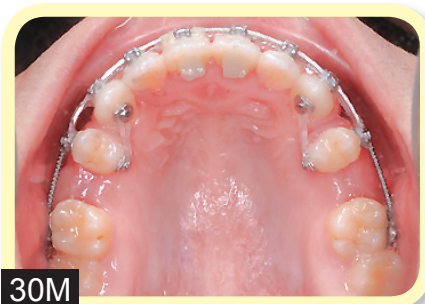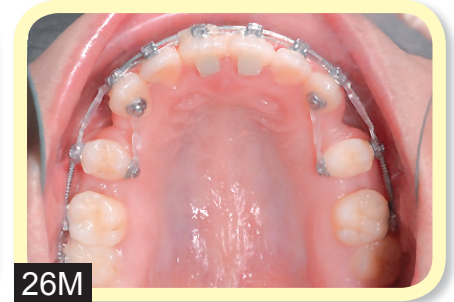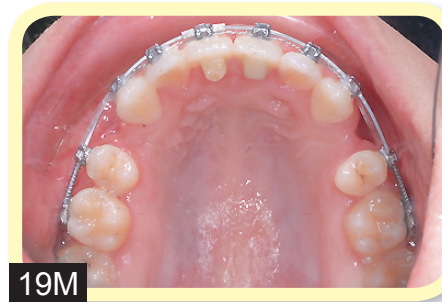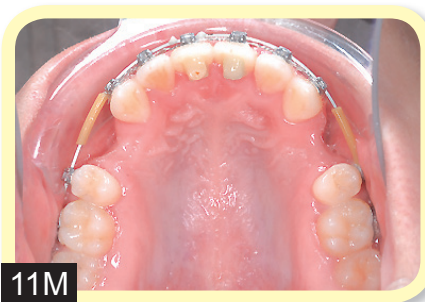Fig. 14:
Instead of bone augmentation to correct the severe bony defects in the maxillary arch (11M), the second premolars were moved into the first premolar sites (19-36M) to prepare implants sites between the premolars and the molars bilaterally (40M).

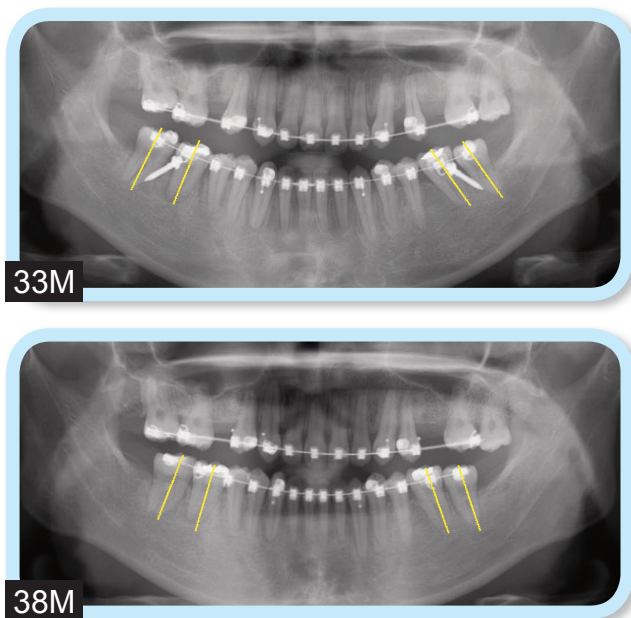
inadequately aligned teeth; mandibular molar corrections are highlighted with yellow lines in Fig. 15. Extra-alveolar (E-A) OBSs (2x12mm, Newton's A Ltd, Hsinchu, Taiwan) were implanted bilaterally in the lower buccal shelves. Power chains were stretched bilaterally, from the lower 2nd premolars to the bone screws, to retract the lower arch and correct the mesial tipping of the lower molars, bilaterally. Five months later, the aligned dentition was corrected and the bone screws were removed.

Precise bracket repositioning was performed repeatedly throughout the treatment. In the 40th month of treatment, the occlusal cant was corrected, but the midline deviation persisted. The upper

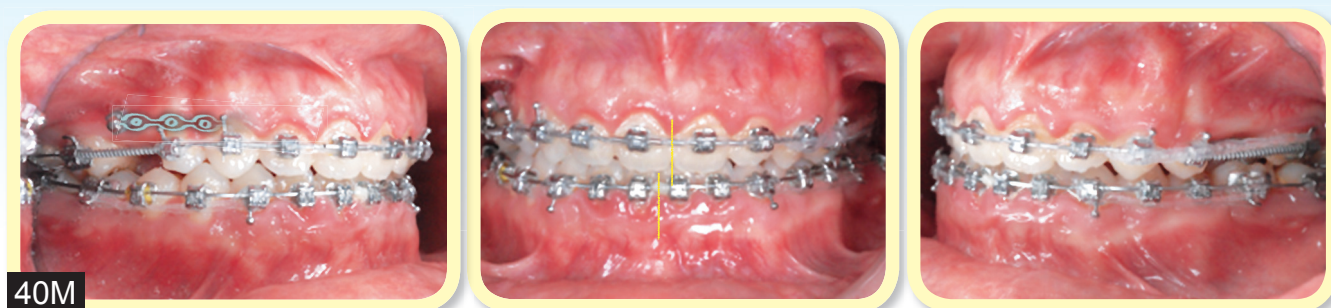midline was 2mm left of the facial midline, and lower dental midline was deviated ~3mm to the right of the upper dental midline. The best compromise was to shift the maxillary dental midline to the right until the right buccal intercuspation was corrected. Thus, a right infrazygomatic crest (IZC) OBS was installed to provide anchorage for a power chain to correct the right buccal segment (Fig. 16).

After 45 months of treatment (45M), all of the chief complaints were corrected except the excessive gingival display ("gummy smile") problem. Two OBSs (1.5x8mm) were placed between the maxillary central and lateral incisors bilaterally to serve as anchorage to intrude the maxillary anterior segment (Fig. 17). After 4 months of power chain traction, the right screw loosened and was reinserted between the lateral incisor and canine. The distance between the left bone screw and the main archwire decreased from 12 to 8mm after 6 months of traction (51M) (Fig. 17). As the incisors intruded, the overjet increased to ~4mm, so another bone screw was placed in the maxillary left IZC, to provide bilateral anchorage to retract the anterior segment (Fig. 18). Class II light elastics (Fox 1/4, 3.5oz) were used bilaterally from the upper canines to the lower molars to retract the upper anterior segment to reduce the overjet to 2mm.

After 58 months of orthodontic treatment, the dentition was well aligned (Fig. 18), but when all the fixed appliances were removed at 62 months, there was a prominent labial frenum and bulbous, inferiorly positioned gingival margins in the maxillary

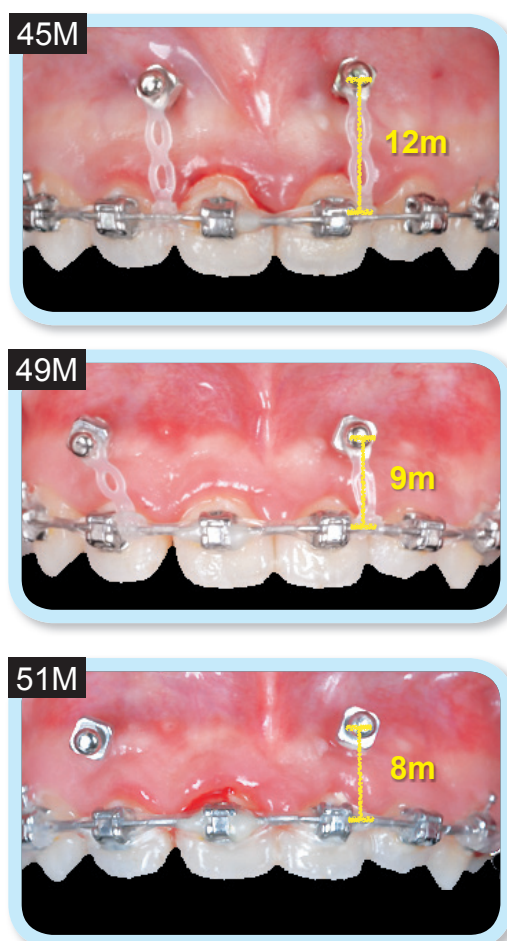


■ **Fig. 15:**
Bone screws were placed in the mandibular buccal shelves (33M) to align the mandibular molars (38M). The yellow lines demonstrate the correction of axial inclination as the molars are moved mesially.



■ Fig. 16:

The lower dental midline was deviated about 3mm to the right (center). An IZC OBS was placed on the right side to rotate the maxillary midline distally (left). Protraction of the second premolar continued on the left side of the arch (right). See text for details.



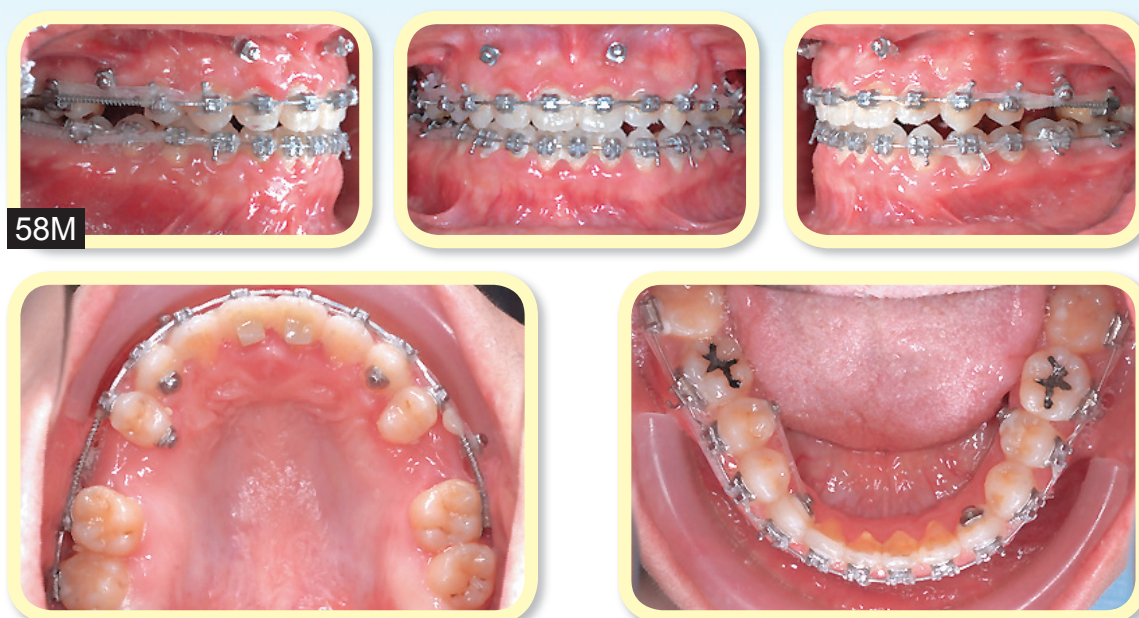■ Fig. 17:

Intrusion of the maxillary anterior segment is shown at 45, 49 and 51 months (45-51M). The distance from the bone screw on the left side and the archwire decreased 4mm from 45M to 51M.

anterior segment (Fig. 19). Excessive gingival sulcus depth was noted on the labial surfaces, so a gingivectomy was performed with a diode laser to improve the exposed tooth proportions for all teeth in the maxillary anterior segment. During the same procedure, the labial frenum was removed to help prevent a diastema from opening between the central incisors (Fig. 19). A fixed retainer was bonded from 2-2 (*lateral incisor to lateral incisor*) in the maxillary arch and clear overlay retainers were delivered for both arches.

Implant Placement

The bone volume for the maxillary implant sites was assessed with a CBCT scan (Fig. 20). The width of the spaces was 7.5mm on the right side and 8mm on the left. The depth of the implant sites, from the alveolar crest to the floor of the maxillary sinus, were also measured as 7.5mm bilaterally (Fig. 20). Referring to the Sinus Lift Decision Tree (Fig. 21)¹, a short fixture (4x8mm OsseoSpeedTX, Dentsply, Harrisburg, PA) was chosen. A crestal incision was performed at the palatal line angle of the edentulous space with



■ Fig. 18:

After 58 months (58M) of orthodontics treatment, all spaces were closed, except for the two implant sites mesial to the maxillary molars.

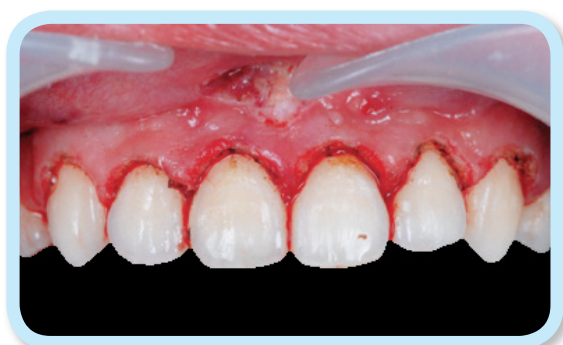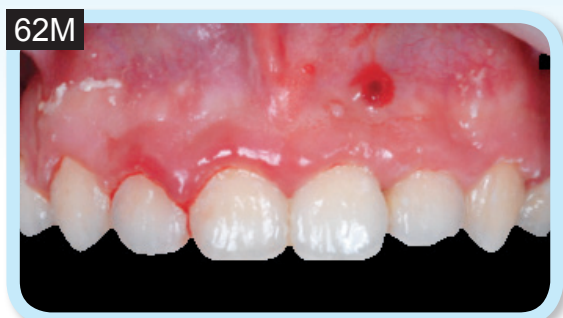a No. 15c scalpel. Sulcular incisions were made on the buccal and palatal sides of the adjacent teeth for flap reflection. A first lancer drill was used for the initial osteotomy. A periapical film was taken, with a surgical guide pin placed, to check the long axis of the osteotomy and its proximity to adjacent teeth. Following the manufacturer's recommended drilling and expansion procedure, the implant sites were surgically developed, step by step. According to the 2B-3D rule,¹ the two implant fixtures were installed bilaterally in the edentulous spaces mesial to the upper molars. Flared healing abutments (Ø4.5-H4) were used to help form the peri-implant mucosal contour and to conform to the cervical contour of the restoration. The flap was repositioned and closed with interrupted 5-0 Gore-Tex® (Flagstaff, AZ) sutures. Post-operative periapical radiographs and intraoral

photographs were taken to check the position and angulation of the implants (Figs. 22 and 23).

At the time of implantation, two small spaces between the upper canines and first premolars were noticed, bilaterally. The pre-treatment and post-treatment occlusal photographs (Fig. 24) demonstrated substantial arch expansion during alignment, that probably contributed to the spaces, but the patient was satisfied with the result, and had no interest in further orthodontic treatment.

Implant Prosthesis Fabrication

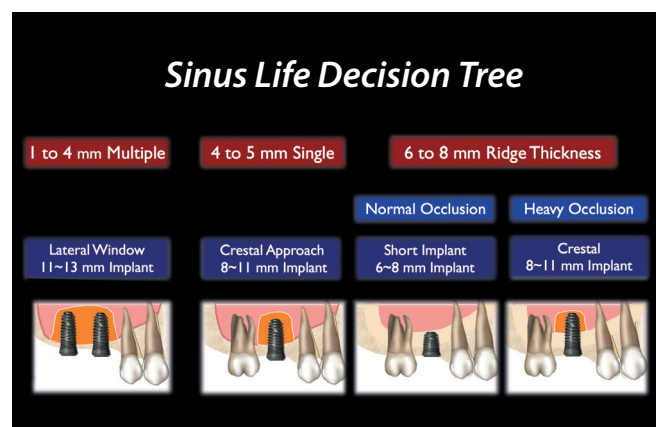
Five months after the implants were placed, the healing abutments were removed, and the implant position was assessed with the 2B-3D rule: >2mm of



■ Fig. 19

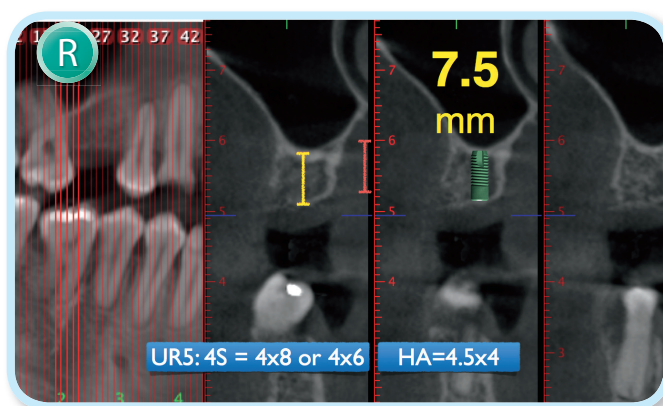
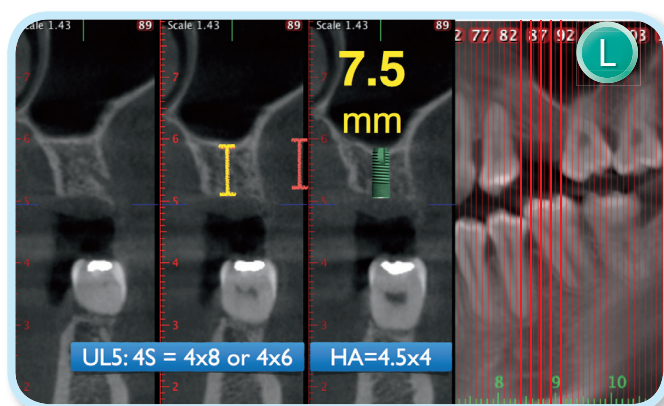
After the fixed appliances were removed, a prominent labial frenum and inadequate enamel exposure of the incisal labial surfaces were noted at 62 months (62M). A gingivectomy and labial frenectomy were performed with a diode laser. See text for details.

buccal bone and the implant is 3mm apical to the crown margin, to provide a 3mm biological width of soft tissue.¹ Direct abutments ($\varnothing 5 \times 2.5 \text{ mm}$, 3.5/4.0) were selected for each implant in preparation for prosthesis fabrication.



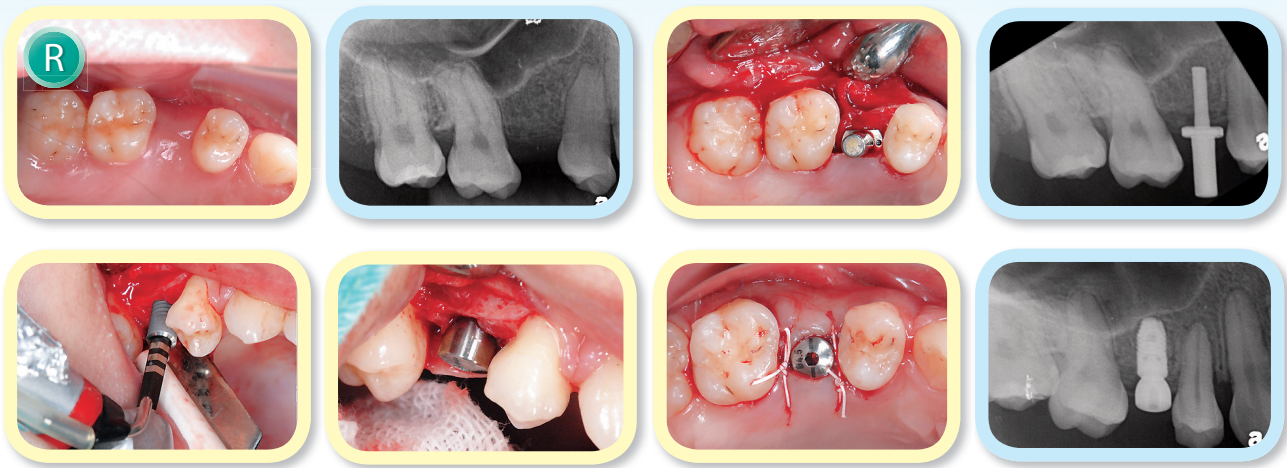
■ Fig. 21

Chang's sinus lift decision tree is a helpful guide for selecting an implant with appropriate height and width. See Chang et al. 2012 (reference #1) for details.



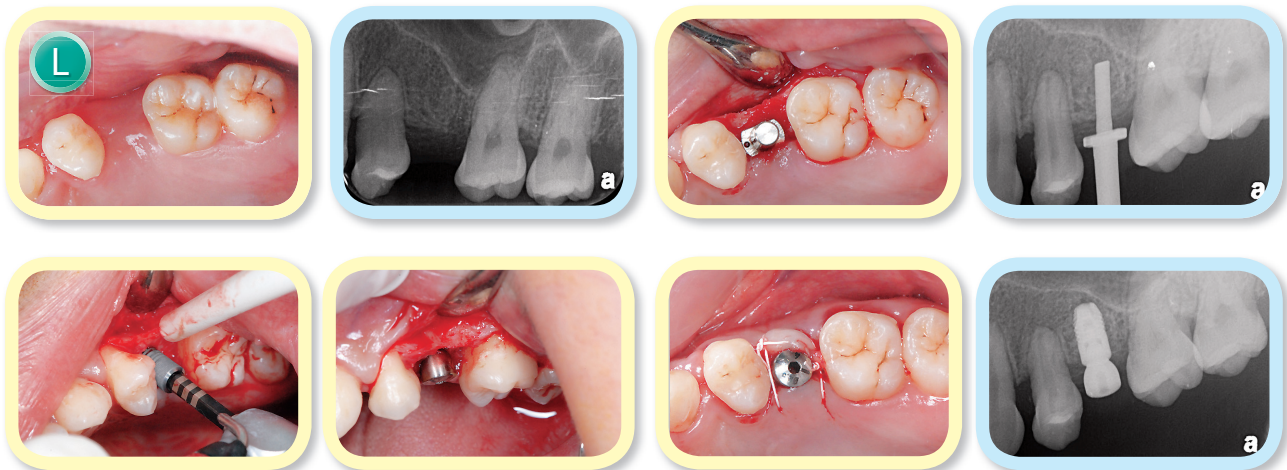
■ Fig. 20:

Following orthodontic preparation of the implant sites, a CBCT scan was used to evaluate the alveolar bone volume available for implants on the right (R) and left (L) sides. Note that the depth of the alveolar process beneath the maxillary sinus was 7.5mm on each side.



■ Fig. 22:

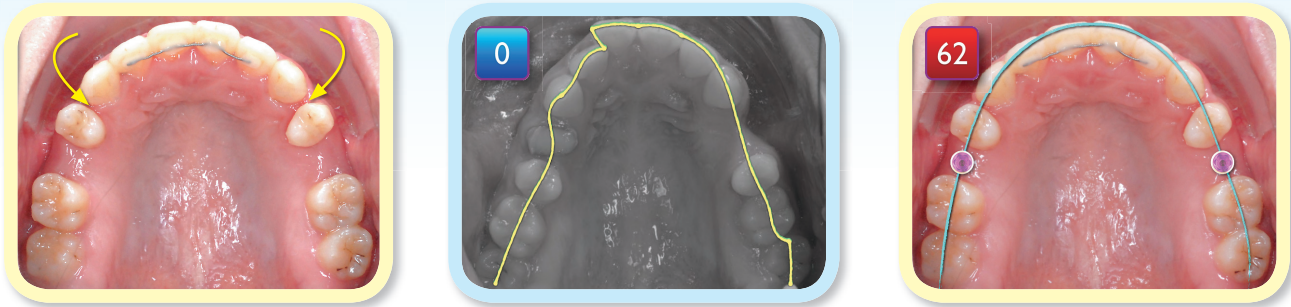The implantation procedure for the maxillary right side (R) is documented with photographs and periapical radiographs.



■ Fig. 23:

The implantation procedure for the maxillary left side (L) is documented with photographs and periapical radiographs.

Before taking the impression, the abutments were torqued twice to 25~30 N-cm with a torque wrench. The screw access hole for the abutment was then sealed with a small cotton pledget and temporary cement. For the abutment-level impression, the surface of the abutment was aligned with the raised knob on the Impression Pick-up and then seated on the Pick-up, by firmly snapping it into place. A closed-tray impression technique was used. Polyvinyl siloxane impression material was injected to make the impression. The impression was checked for the correct and stable retention of the Impression Pick-up. The abutments were



■ Fig. 24:

Following orthodontics treatment, two small spaces (yellow arrows) were noted between the upper canines and first premolars bilaterally (left). Comparison of pre-treatment (0) and post-treatment (62) arch forms shows the substantial expansion accomplished during active treatment.

then cemented with the Tony caps to prevent soft tissue overgrowth. The height of the abutments must not infringe on the 2mm of occlusal clearance required for the fabrication of a porcelain fused to metal crown. However, insufficient inter-occlusal space was noticed. Dura-lay resin was used as a guide for trimming the abutments. The height of the abutment post was adjusted intraorally with a diamond bur, mounted in a high speed hand piece, to provide inter-occlusal clearance for fabrication of the porcelain fused to metal crown, and then the crowns were fabricated by a commercial laboratory.

Unfortunately, the first prostheses did not fit probably because of an incomplete impression. The double core packing technique was used to retract the gingiva. A direct impression was made with polyvinyl siloxane, and poured with type IV dental stone. One month later, the second prostheses failed again because of an alignment error. After making three new impressions,

the casts were subsequently articulated with check-bite records. The subsequent crowns fit properly. Gingival marginal integrity was verified with a dental explorer, and the appropriate tightness of the contact area was confirmed with dental floss. After the final fit of the prostheses was checked with periapical radiographs, the permanent crowns were luted to place with permanent cement (Fig. 25).

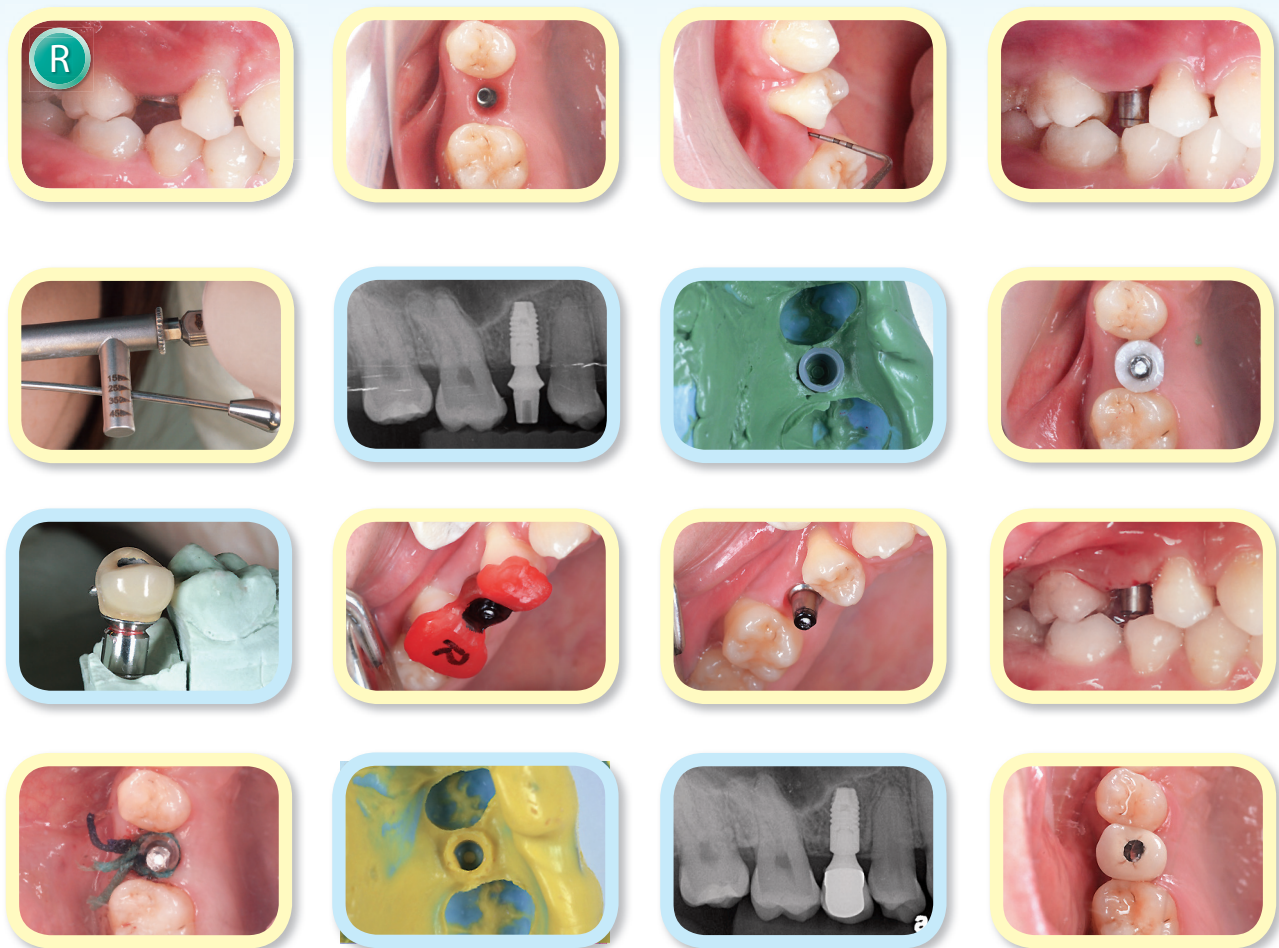
Results Achieved

Maxilla (all three planes):

- A - P: Retracted
- Vertical: Maintained
- Transverse: Maintained

Mandible (all three planes):

- A - P: Retracted
- Vertical: Decreased
- Transverse: Maintained



■ Fig. 25:

The implant prosthesis fabrication procedure is illustrated for the upper right side with a series of photographs and periapical radiographs. The same procedure was utilized on the left side.

Maxillary Dentition

- A - P: Incisors retracted
- Vertical: Intruded
- Inter-molar / Inter-canine Width: Expanded to correct crossbite
- Vertical: Incisors and molars extruded
- Inter-molar / Inter-canine Width: Expanded to conform to the upper arch

Mandibular Dentition

- A - P: Anterior incisors retracted and molars protracted

Facial Esthetics: The profile was maintained and the lips were retracted and remained competent. The gummy smile and occlusal canting were improved.

Retention

Fixed lingual retainers were bonded on the mandibular incisors and clear overlay retainers were delivered for both arches. The patient was instructed to wear the removable retainers full time for the first 6 months and nights only thereafter. Instructions were provided for home hygiene as well as for the maintenance of the retainers.

Final Evaluation of the Treatment

Cephalometric analysis (Table 1) and superimposition of the tracings (Fig. 9), show that the incisors in both arches were retracted. The upper molars were intruded and moved forward slightly. The lower molars were moved forward and extruded. The mandible rotated counter-clockwise, resulting in a 1° decrease in the mandibular plane angle, and a 1° reduction in the SNA angle. The upper incisor to SN angle was decreased from 94° to 92.5°. The lower incisor to the mandibular plane angle decreased from 83.5° to 80.5°. There were significant changes in arch forms and inter-occlusal space related to correction of the crossbite and occlusal irregularities (Figs. 5 and 6). Other dentofacial problems were markedly improved, such as the maxillary gingival display, occlusal cant and midline deviation (Fig. 4).

The ABO Cast-Radiograph Evaluation score was 25 points.² The major discrepancies were occlusal relationships (6 points), marginal ridges (8 points), alignment/rotation (5 points) and root angulation (3 points). The patient chose to retain the small spaces between the bilateral upper canines and 1st

premolars. Overall, the dentition was well aligned, midlines were improved, and the patient was satisfied the final result.

Discussion

The common goals in dentistry for restoring missing teeth are to achieve normal function, comfort, esthetics, speech, and health. In Taiwan, an increasing fraction of the population is partially edentulous, because a smaller fraction of the population is losing all their teeth (*totally edentulous*). The early loss of permanent first molars are associated with a variety of acquired malocclusions^{3,4} that occur after the deciduous second molars are exfoliated. Although teeth may be lost to caries at any age, a common problem is incisor-molar hypomineralization, a worldwide problem with a prevalence of 10-22%.^{5,6} The latter is a developmental problem associated with the illness of a child <3 years of age. Fever is thought to disrupt enamel formation of permanent first molars, rendering them susceptible to caries when they erupt. The problem is often not realized by the patients until the child has a tooth ache, and then the first molars are extracted prior to the loss of the second deciduous molars. In the absence of posterior centric stops in the late transitional stage of occlusal development, may result in severe acquired malocclusions.^{3,4}

Alveolar ridge atrophy is common for edentulous spaces, particularly during the first 6 months after extraction. Continued modeling and remodeling over 6 months results in a 40% decrease in alveolar

height and 60% decrease in alveolar width.⁷ The loss of individual teeth obviously compromises esthetics and function, but it may also contribute to an acquired, debilitating malocclusion. Contributing factors may be alveolar defects, tooth size to arch length discrepancies, crossbites, gummy smile, occlusal canting and midline discrepancies.

Acquired malocclusions^{3,4} often require interdisciplinary care: orthodontics, implants, periodontics and prosthodontics. Stepovich⁸ as well as Hom and Turley⁹ have shown that atrophic alveolar spaces can be closed and alternate implant sites opened, in the presence of a healthy periodontium. Horizontal and/or vertical defects in an edentulous ridge are challenging problems that usually require bone and soft tissue augmentation to serve as an appropriate implant site (Figs. 2 and 3). A viable alternative is orthodontic tooth movement to create an appropriate implant site that does not require tissue augmentation (Figs. 22 and 23). As a result of this treatment, lost function and occlusion is rehabilitated by the natural teeth and the long-term functionality of implant-supported prosthesis is satisfactory for the patient.¹⁰

Occlusal irregularity in the partially edentulous dentition is associated with tipping and extrusion (*supra-eruption*) of teeth into extraction spaces.¹¹ The treatment options available for extruded (*supra-erupted*) teeth are: 1. extraction, 2. reduction of crown height, which may require endodontics, or 3. orthodontic intrusion.¹²

For a missing tooth, the usual options are an implant, conventional fixed prosthesis, or

orthodontic space closure.^{13,14} A dental implant may provide the anchorage to close a missing first molar space(s) to restore an intact arch.¹³⁻¹⁵ Eliminating longterm prosthetic devices is the best option.¹⁴ If a prosthetic device is necessary, an implant provides several advantages over other restorative options. It looks and functions more like a natural tooth and does not require the preparation of adjacent teeth. Furthermore, a dental implant replaces the tooth root which helps preserve the periodontium. Based on the biologic evidence, the 2B-3D rule is an ideal implant placement guide.^{1,16} What is the 2B-3D rule? 2mm of buccal bone thickness should be preserved and the implant should be placed 3mm below the future prosthesis cervical margin. The 2B-3D rule is a practical guide, for both single implants and full mouth rehabilitation, to achieve ideal implant positions.¹⁶

Gummy smile also known as “*gingival smile*” or “*excessive gingival display*” refers to a condition in which there is a display of over 4mm of the labial gingiva superior to the maxillary incisors when smiling. The etiology of gummy smile may involve one or more of the following conditions: 1. short upper lip, 2. hypermobile lip, 3. vertical maxillary excess, 4. anterior over-eruption, 5. wear and compensatory eruption, 6. altered active eruption, and 7. altered passive eruption.¹⁷⁻¹⁹

There are three traditional methods for correcting a gummy smile: 1. orthodontic intrusion of teeth to superiorly reposition the periodontium,¹⁷ 2. periodontal surgery to lengthen the visible crown of a tooth (*typically performed on short teeth*),¹⁸ and 3.

orthognathic surgery to intrude the maxilla.¹⁹ These traditional methods are not necessarily appropriate for a hypermobile lip. The latter has popularized additional approaches: 1. Botox® (*Allergan, Irvine, CA*) injected into the muscles of the upper lip is an effective method, but it must be repeated every 3-6 months to maintain an optimal effect, and 2. lip repositioning surgery which severs the muscles that elevate the lip so that a broad smile in the vertical dimension is inhibited. This is an irreversible solution. Diagnosis is the key to a successful outcome for gummy smile.²⁰

Diode lasers are capable of precision cuts in gingiva and other soft tissues; they also eliminate bleeding at the site and reduce the healing time for the patient.²¹ This procedure also can be used for a variety of other soft tissue surgeries, such as periodontal therapy²² and implant procedures,²³ as well as endodontics and tooth whitening. The gingival level on each individual tooth is important for a harmonious smile. Assuming there is adequate periodontal pocket depth, a modest and symmetric gingivectomy with a diode laser can produce dramatic results (*Fig. 19*).²³

The etiology of facial asymmetry includes: 1. genetic or congenital malformations, e.g. hemifacial microsomia and unilateral clefts of the lip and palate, 2. environmental factors, e.g. habits and trauma, 3. functional deviations, e.g. mandibular shifts as a result of tooth interferences.²⁴ The condyle plays an important role as a secondary growth site in the mandible and serves as a pivot point during jaw opening. Facial asymmetry and a lateral deviation in the midline of the mandible may be related to

condylar hyperplasia. Figure 10 shows asymmetric lengths for the mandibular condyles, which may be related to the facial deviation (*Fig. 1*). Since there is no enlargement of the condylar head on the affected side, it does not appear to be a pathologic condition, such as condylar hyperplasia. However, the asymmetric condylar length may reflect a compensation to an environmental factor such as sleep posture or scoliosis.²⁵ Dental asymmetries and functional deviations can be treated orthodontically, but skeletal asymmetries are not usually amenable to orthodontic treatment. When approaching the orthodontic correction of a facial asymmetry, it is important to begin with the end in mind.²⁶

Conclusion

Partially edentulous malocclusions are particularly challenging if there is an underlying developmental component. A thorough facial, dental and functional evaluation is necessary to establish the likely etiology of the problem. Reversing the etiology of the problem(s) is the most direct strategy for resolving a malocclusion in a stable manner. Orthodontic alignment may involve preparation of symmetric sites for implant-supported prostheses to improve a patient's dental alignment, occlusal relationships and facial esthetics. Despite minor mechanical problems, the correction of the current severe malocclusion continued to improve after treatment, resulting in an optimal dental and facial esthetics.

Acknowledgment

Thanks to Mr. Paul Head for proofreading this article.

References

1. Chang MJ, Chang CH, Roberts WE. Combined Implant-Orthodontic Treatment for an Acquired Partially-Edentulous Malocclusion with Bimaxillary Protrusion. *Int J Orthod Implantol* 2012;28:38-64.
2. The American Board of Orthodontics. Grading System for Dental Casts and Panoramic Radiographs. 7th ed. St. Louis (MO): The American Board of Orthodontics; 2012.
3. Lu SW, Chang CH, Roberts WE. Asymmetric crowded Class II with missing first molars: space closure or implants? *Int J Orthod Implantol* 2015;40:18-37.
4. Yeh HY, Chang CH, Roberts WE. Conservative treatment of a skeletal Class III malocclusion complicated with atrophic extraction sites and periodontal compromise. *Int J Orthod Implantol* 2016;42:44-59.
5. Pitiphat W, Savisit R, Chansamak N, Subarnbhesaj A. Molar incisor hypomineralization and dental caries in 6-7 year old children. *Pediatric Dentistry* 2014;36(7):478-82.
6. Wuollet E, Lai S, Salmela E, Ess A, Alaluusua S. Background factors of molar-incisor hypomineralization in a group of Finnish children. *Acts Odontol Scand* 2014;72(8):963-9.
7. Bartee BK. Extraction site reconstruction for alveolar ridge preservation. Part 1: Rationale and materials selection. *J Oral Implantol* 2001;27:187-93.
8. Stepovich ML. A clinical study on closing edentulous spaces in the mandible. *Angle Orthod* 1979;49:227-233.
9. Hom BM, Turley PK. The effects of space closure of the mandibular first molar area in adults. *Am J Orthod* 1984;85:457-469.
10. Arslan SG, Tacir IH, Kama JD. Orthodontic and prosthetic rehabilitation of unilateral free-end edentulous space. *Au Dent J* 2006;51(4):338-341.
11. Davies S, Gray RMJ. What is occlusion? *Br Dent J* 2001;191:235-245.
12. Ricketts DNS, Smith BGN. Minor axial tooth movement. *Eur J Prosthodont Dent* 1993;1:145-149.
13. Roberts WE, Marshall KJ, Mozsary PG. Rigid endosseous implant utilized as anchorage to protract molars and close an atrophic extraction site. *Angle Orthod* 1990;60(2):135-152.
14. Roberts WE, Nelson CL, Goodacre CJ. Rigid implant anchorage to close a mandibular first molar extraction site. *J Clin Orthod* 1994;28(12):693-704.
15. Roberts WE, Arbuckle GR, Analoui M. Rate of mesial translation of mandibular molars using implant-anchored mechanics. *Angle Orthod* 1996;66(5):331-8.
16. Chang CH. The 2B-3D rule for implant planning, placement and restoration. *Int J Orthod Implantol* 2012;27:79-101.
17. Peck S, Peck L, Kataja M. The gingival smile line. *Angle Orthod* 1992;62:91-100.
18. Wu H, Lin J, Zhou L, Bai D. Classification and craniofacial features of gummy smile in adolescents. *J Craniofac Surg* 2010;21(5):1474-1479.
19. Rossi R, Benedetti R, Santos-Morales RI. Treatment of altered passive eruption: periodontal plastic surgery of the dentogingival junction. *Eur J Esthet Dent* 2008;3(3):212-223.
20. Otto Z. Plastic-esthetic periodontal and implant surgery: a microsurgical approach. Quintessence Publishing Co, Ltd. 2012.
21. Goharkhay K, Moritz A, Wilder-Smith P, Schoop U, Kluger W, Jakolitsch S, Sperr W. Effects on oral soft tissue produced by a diode laser in vitro. *Lasers Surg Med* 1999;25(5):401-406.
22. Moritz A, Schoop U, Goharkhay K, Schauer P, Doertbudak O, Wernisch J, Sperr W. Treatment of periodontal pockets with a diode laser. *Lasers Surg Med* 1998;22(5):302-311.
23. Maiorana C, Salina S, Santoro E. Treatment of Periimplantitis with Diode Laser: A Clinical Report. *J Oral Laser Applications* 2002;2:121-127.
24. Samir E. B, Paul S. B, John G. K. Dental and facial asymmetries: a review. *Angle Orthod* 1994;64(2): 89-98.
25. Zhou S, Yan J, Da H, Yang Y, Wang Na, Wang W, Ding Y, Sun S. A correlational study of scoliosis and trunk balance in adult patients with mandibular deviation. *PLoS One* 2013;8(3):e59929.
26. Pitts T. Begin with the end in mind: Bracket placement and early elastics protocols for smile arc protection. *Clinical impressions* 2009;17(1):4-13.



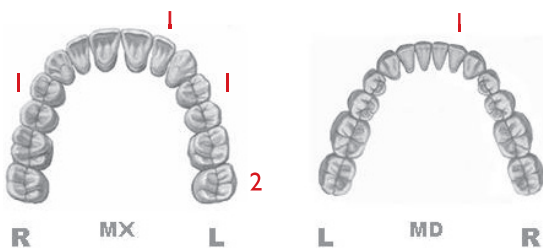
Cast-Radiograph Evaluation

Total CRE Score

25

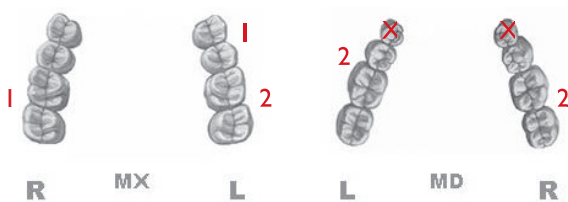
Alignment/Rotations

5



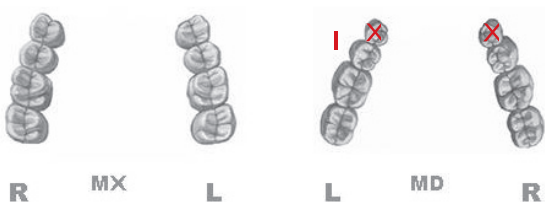
Marginal Ridges

8



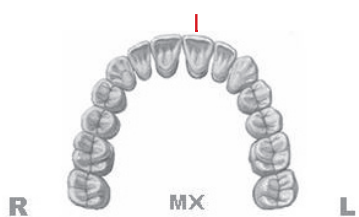Buccolingual Inclination

2



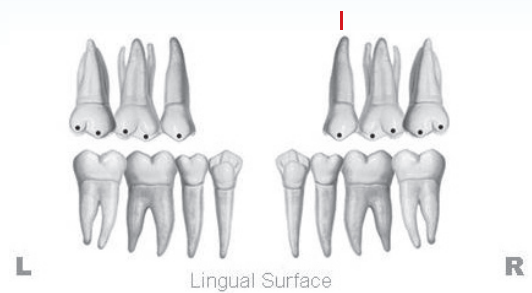
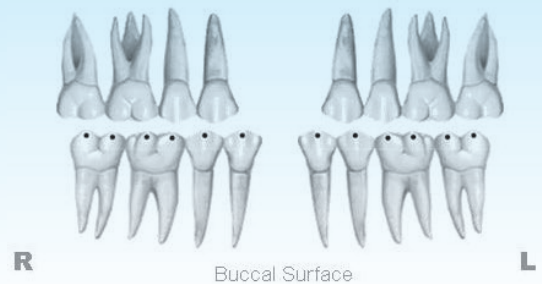
Overjet

1



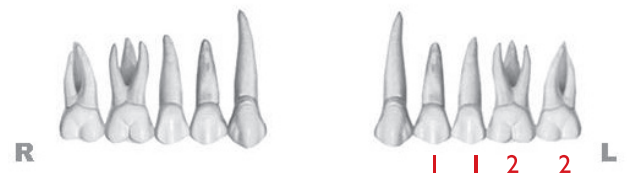Occlusal Contacts

1



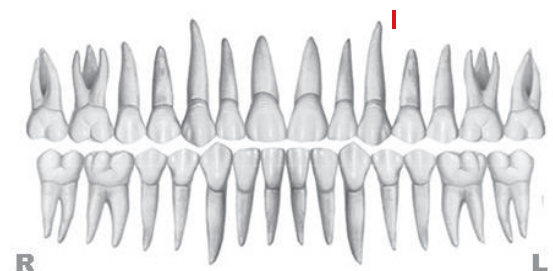
Occlusal Relationships

6



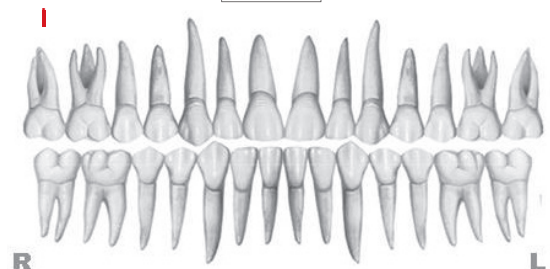
Interproximal Contacts

1



Root Angulation

1

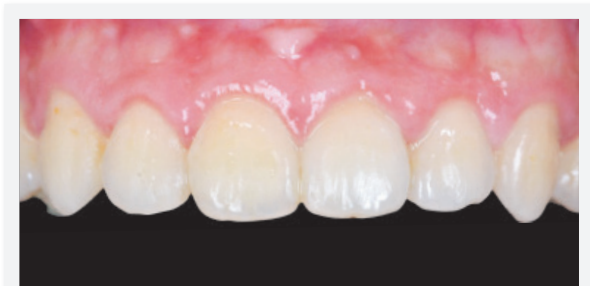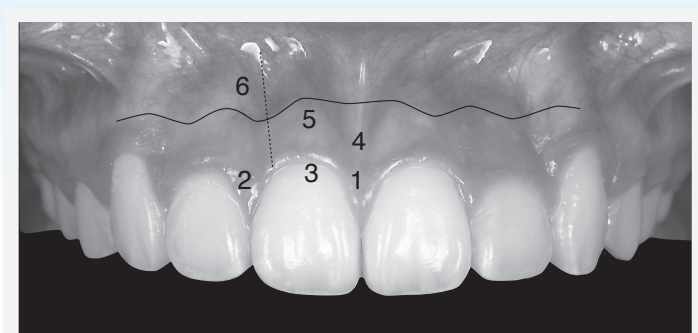


INSTRUCTIONS: Place score beside each deficient tooth and enter total score for each parameter in the white box. Mark extracted teeth with "X". Second molars should be in occlusion.

IBOI Pink & White Esthetic Score (Before Surgical Crown Lengthening)

Total Score: = **5**

1. Pink Esthetic Score

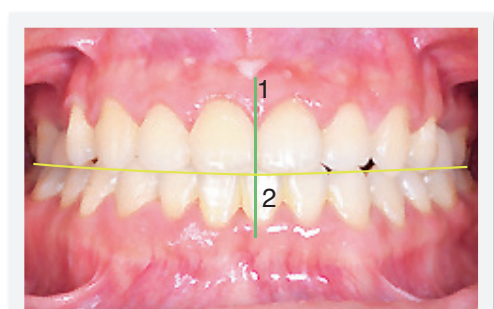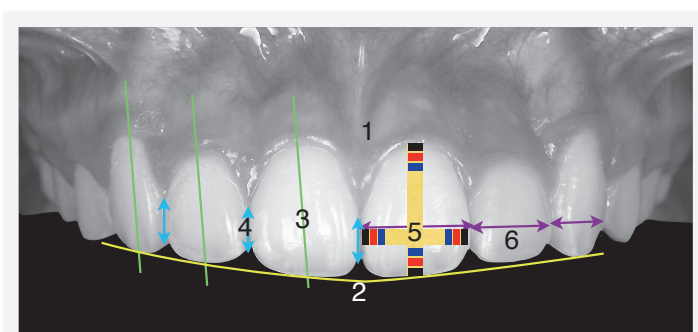


1. Mesial Papilla	0	1	2
2. Distal Papilla	0	1	2
3. Curvature of Gingival Margin	0	1	2
4. Level of Gingival Margin	0	1	2
5. Root Convexity (Torque)	0	1	2
6. Scar Formation	0	1	2

Total = **2**

1. M & D Papilla	0	1	2
2. Keratinized Gingiva	0	1	2
3. Curvature of Gingival Margin	0	1	2
4. Level of Gingival Margin	0	1	2
5. Root Convexity (Torque)	0	1	2
6. Scar Formation	0	1	2

2. White Esthetic Score (for Micro-esthetics)



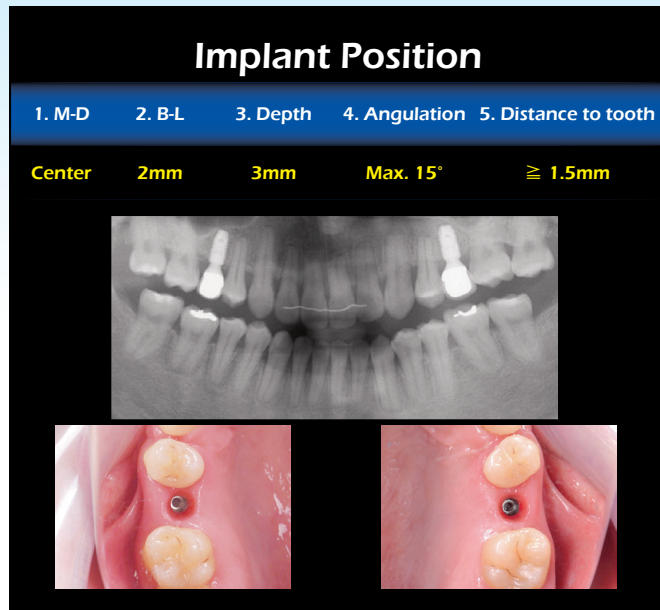
1. Midline	0	1	2
2. Incisor Curve	0	1	2
3. Axial Inclination (5°, 8°, 10°)	0	1	2
4. Contact Area (50%, 40%, 30%)	0	1	2
5. Tooth Proportion (1:0.8)	0	1	2
6. Tooth to Tooth Proportion	0	1	2

Total = **3**

1. Midline	0	1	2
2. Incisor Curve	0	1	2
3. Axial Inclination (5°, 8°, 10°)	0	1	2
4. Contact Area (50%, 40%, 30%)	0	1	2
5. Tooth Proportion (1:0.8)	0	1	2
6. Tooth to Tooth Proportion	0	1	2

Implant-Abutment Transition & Position Analysis

3. Implant Position

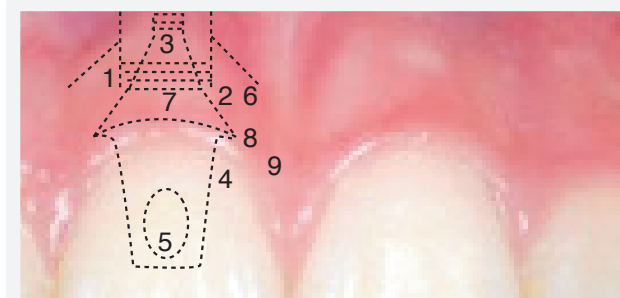


Total = 0

1. M & D (Center)	0	1	2
2. B & L (Buccal 2 mm)	0	1	2
3. Depth (3 mm)	0	1	2
4. Angulation (Max. 15°)	0	1	2
5. Distance to Adjacent Anatomy	0	1	2

1. M & D (Center)	0	1	2
2. B & L (Buccal 2 mm)	0	1	2
3. Depth (3 mm)	0	1	2
4. Angulation (Max. 15°)	0	1	2
5. Distance to Adjacent Anatomy	0	1	2

4. Abutment transition Contour



E : external connection,
I : internal connection,
S : screw type,
C : cement type,
P : palatal/central,
B : buccal

Total = 1

1. Fixture Cervical Design	N	Y		
2. Platform Switch	N	Y		
3. I-A Connection Type	E	I		
4. Abutment Selection	S	C		
5. Screw Hole Position	P	B		
6. Marginal Bone Loss			0	1 2
7. Modified Gingival Contour			0	1 2
8. Gingival Height			0	1 2
9. Crown margin fitness			0	1 2

1. Fixture Cervical Design	N	Y	bone level
2. Platform Switch	N	Y	platform
3. I-A Connection Type	E	I	11° morse taper
4. Abutment Selection	S	C	cement-retained
5. Screw Hole Position	P	B	incisor
6. Marginal Bone Loss	0	1	2
7. Modified Gingival Contour	0	1	2
8. Gingival Height	0	1	2
9. Crown margin fitness	0	1	2

