

# Missing Maxillary Central Incisor Treated with Mesial Substitution of the Lateral Incisor, Canine and First Premolar

## Abstract

A 24 yr female presented with convex profile, everted lower lip, severe lip protrusion, bimaxillary skeletal protrusion, flared maxillary incisors and two missing teeth: maxillary left central incisor and mandibular right first molar. The missing upper central incisor was corrected with progressive mesial substitution of the lateral incisor, canine, and first premolar. On the contralateral side, the left maxillary first premolar was extracted, and the space was closed to achieve a balanced retraction of the maxillary anterior segment to correct the dental and soft tissue protrusion. The mandibular right molar space was closed, the patient's facial profile was significantly improved, and dental esthetics in the esthetic zone were detailed with restorative procedures. This very difficult malocclusion, with a Discrepancy Index (DI) of 38, was treated to a satisfactory Cast Radiograph Evaluation (CRE) of 27, and a Pink and White (P&W) dental esthetics score of 6. The total interdisciplinary treatment time was 35 months. (Int J Othod Implantol 2015;38:78-93)

### Key words:

Bimaxillary protrusion, missing maxillary central incisor, missing mandibular first molar, dental substitution, asymmetry, restorative compensation

## History and Etiology

A 24 year-old woman presented two chief complaints: flared maxillary anterior teeth and protrusive lips (Figs. 1-3). The patient's medical history was noncontributory, but there was evidence of maxillary anterior dental trauma: missing left maxillary incisor (#9) and multiple endodontically treated teeth (#7, 8, 10 and 11). The maxillary anterior segment from #7-11 was restored with a porcelain-fused-to-metal (PFM) fixed partial denture. No history of adverse habits nor temporomandibular dysfunction was reported.

Clinical examination revealed a bilateral Class II molar relationship, 8 mm overjet, 5 mm over-bite, full buccal cross-bite of tooth #15, and maxillary incisal impingement, that resulted in pronounced protrusion and eversion of the lower lip. In addition, tooth #30 were missing.

The patient was treated to an acceptable result as documented in Figs. 4-6. The cephalometric and panoramic radiographs documented the pre-treatment condition (Fig. 7) and the post-treatment result (Fig. 8). The cephalometric tracings (*pre-and post-treatment*) are superimposed on the anterior cranial base, maxilla and mandible in Fig. 9.

**Dr. Teng-Kai Huang,**  
Instructor, Beethoven Orthodontic Course (Left)

**Dr. Chris Chang,**  
Founder, Beethoven Orthodontic Center  
Publisher, International Journal of Orthodontics & Implantology (middle)

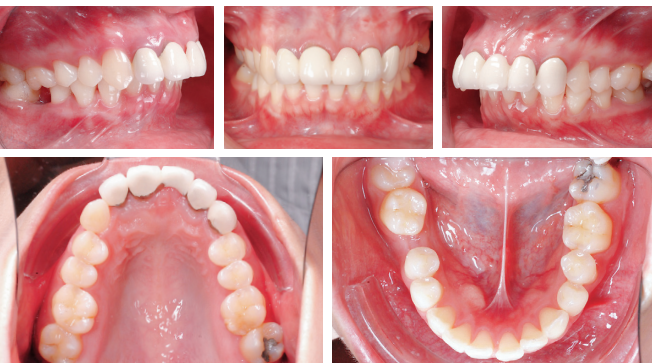**W. Eugene Roberts,**  
Chief editor, International Journal of Orthodontics & Implantology (right)



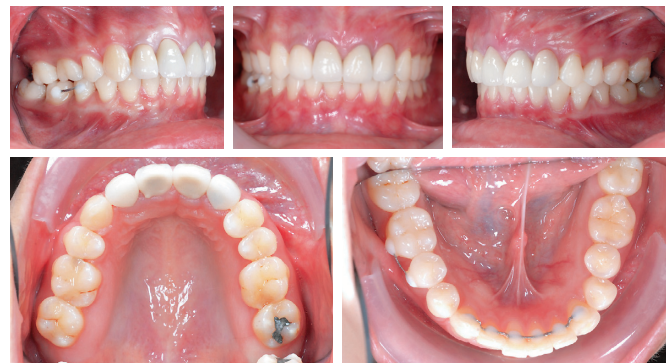■ Fig. 1: Pre-treatment facial photographs



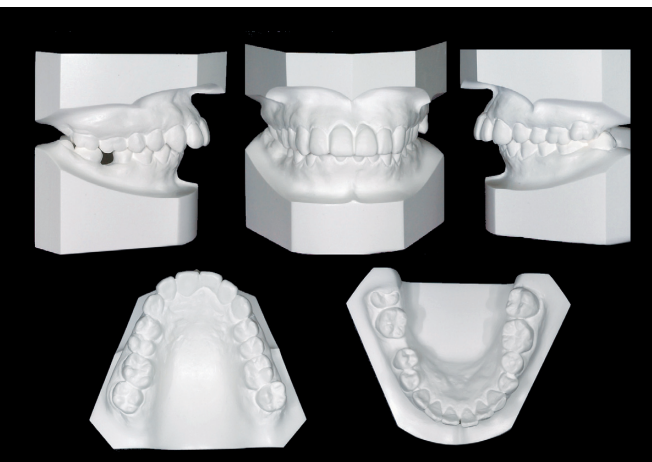■ Fig. 4:  
The post-treatment facial photographs show dramatic facial correction.



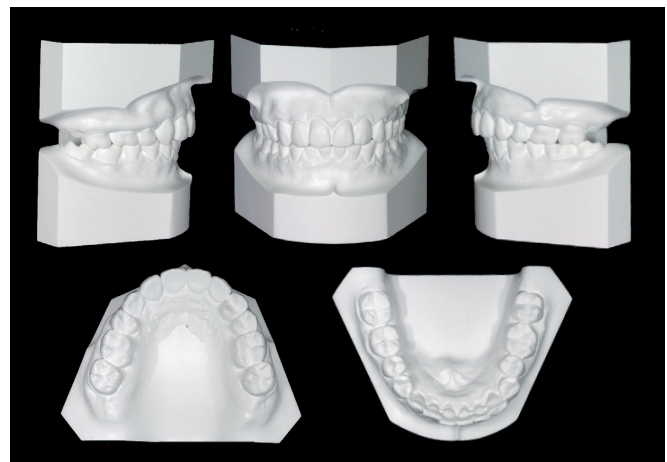
■ Fig. 2: Pre-treatment intraoral photographs



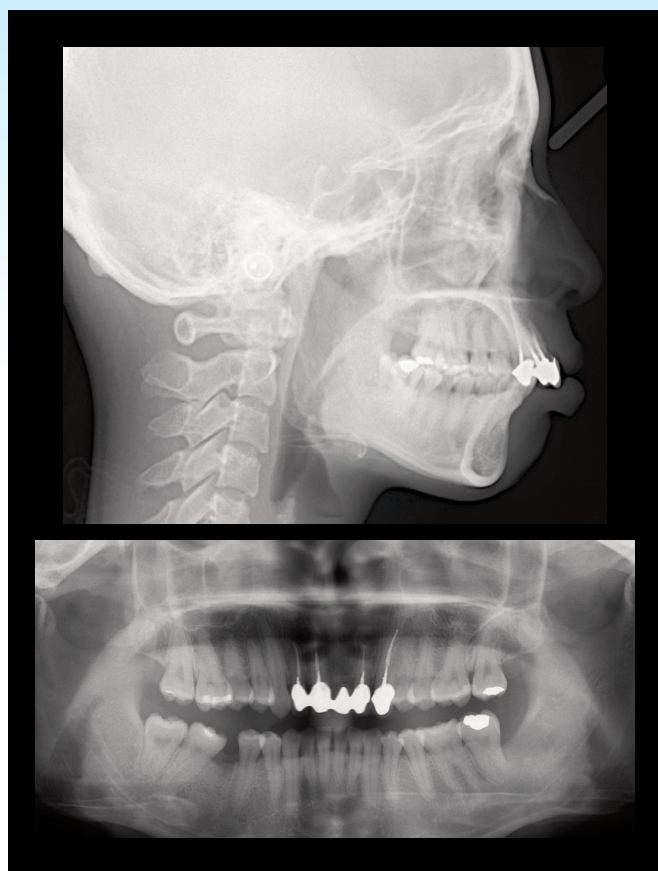
■ Fig. 5: Post-treatment intraoral photographs



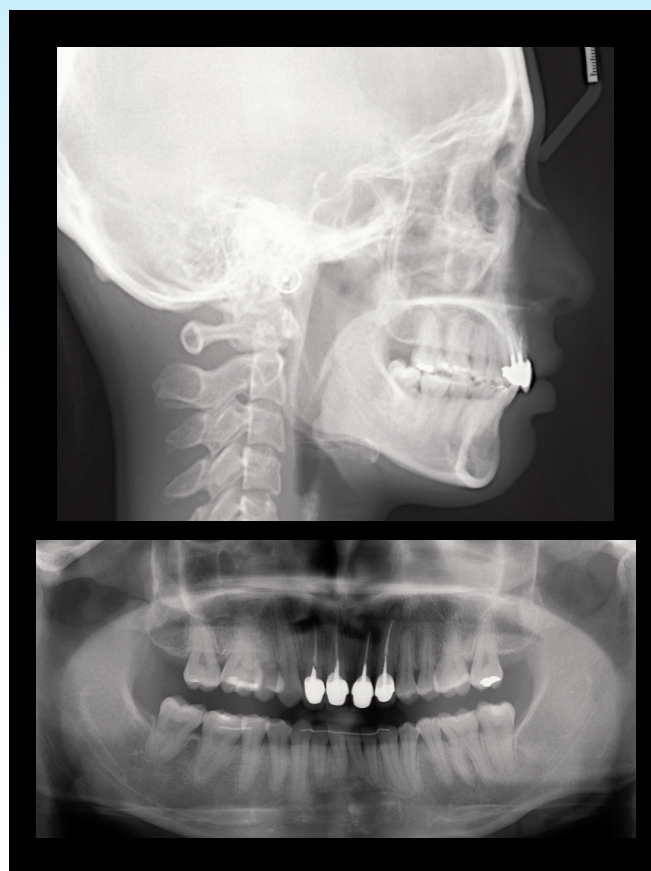
■ Fig. 3: Pre-treatment study models (casts)



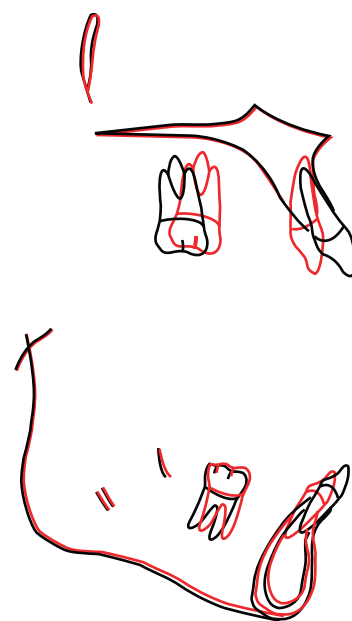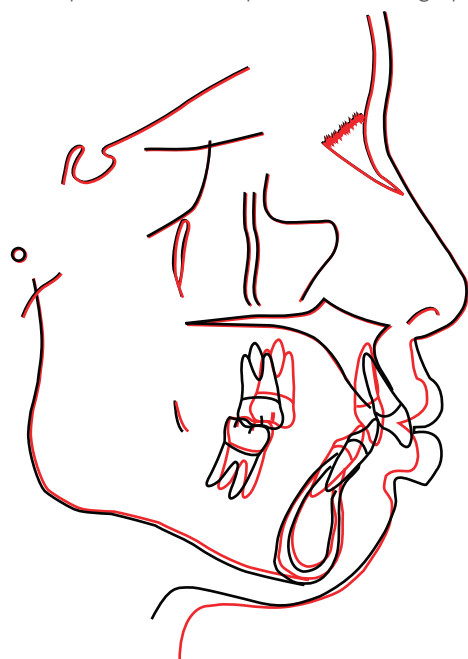■ Fig. 6: Post-treatment study models (casts)



■ **Fig. 7:**  
Pre-treatment cephalometric and panoramic radiographs



■ **Fig. 8:**  
Post-treatment cephalometric and panoramic radiographs



■ **Fig. 9:**  
Pre-treatment (black) and post-treatment (red) cephalometric tracings superimposed on the anterior cranial base (left) show an improved facial profile. Maxillary superimposition (upper right) documents the retraction of the incisors and protraction of the molars. Mandibular superimposition (lower right) documents flattening of the curve of Spee.



## Diagnosis

### Skeletal:

- Skeletal Class II ( $SNA\ 82^\circ$ ,  $SNB\ 76^\circ$ ,  $ANB\ 6^\circ$ )
- Mandibular plane angle ( $SN-MP\ 28.5^\circ$ )

### Dental:

- Class II molar relationship
- Fixed partial denture: #7-10
- Single crown: #11
- Missing Teeth: #9 and 30
- Endodontically treated teeth: #7, 8, 10, and 11
- Buccal posterior cross-bite: #15 (Fig. 10)

### Facial:

- Convex profile
- Bimaxillary protrusion
- Lip incompetence and everted lower lip (*lip curl*)

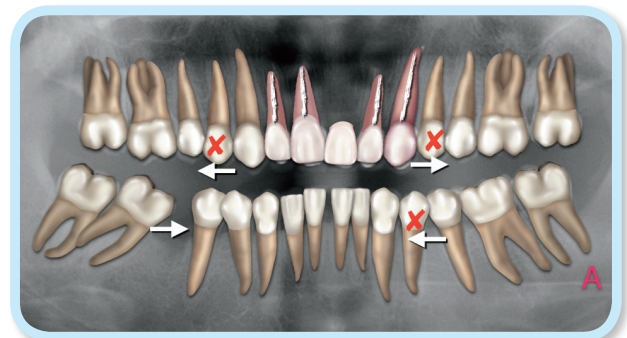The ABO Discrepancy Index ( $DI$ ) was 38 as shown in the subsequent worksheet.<sup>1</sup>

## Treatment Objectives

The principal objectives of this treatment were to retract the maxillary dentition and achieve an ideal overjet and overbite as well as to solve the lip incompetence and lip eversion. The treatment options were:

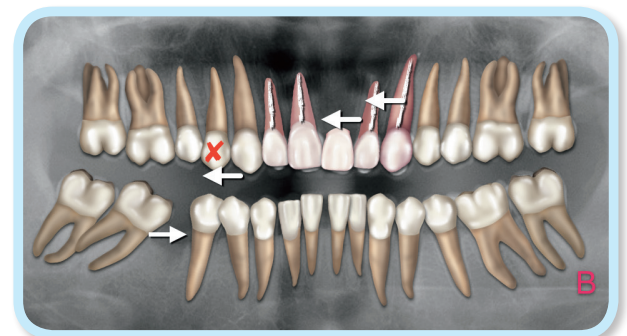
### Option A

- Extract teeth #5 and 12, and close the extraction spaces to reduce the overjet.
- Extract tooth #21 and close both lower spaces by protraction of the mandibular molars.



### Option B

- Extract tooth #5.
- Close the extraction spaces (teeth #5 and 9) to reduce the overjet.
- Close the space of tooth #30 by protraction of the mandibular right molars.



CEPHALOMETRIC			
SKELETAL ANALYSIS			
	PRE-Tx	POST-Tx	DIFF.
$SNA^\circ$	$82^\circ$	$81.5^\circ$	$0.5^\circ$
$SNB^\circ$	$76^\circ$	$76^\circ$	$0^\circ$
$ANB^\circ$	$6^\circ$	$5.5^\circ$	$0.5^\circ$
$SN-MP^\circ$	$28.5^\circ$	$28^\circ$	$0.5^\circ$
$FMA^\circ$	$21.5^\circ$	$21^\circ$	$0.5^\circ$
DENTAL ANALYSIS			
U1 TO NA mm	6 mm	-0.5 mm	6.5 mm
U1 TO $SN^\circ$	$103.5^\circ$	$85^\circ$	$18.5^\circ$
L1 TO NB mm	8 mm	4 mm	4 mm
L1 TO $MP^\circ$	$110^\circ$	$110^\circ$	$0^\circ$
FACIAL ANALYSIS			
E-LINE UL	3 mm	-1 mm	4 mm
E-LINE LL	7 mm	1 mm	6 mm

Table 1: Cephalometric summary



Option B is an unusual orthodontic treatment approach because closing the missing incisor space presents multiple esthetic problems related to tooth substitution and specialized restorative treatment. After a thorough discussion of the pros and cons for both options, the patient elected option B.

### Treatment Progress and Appliances

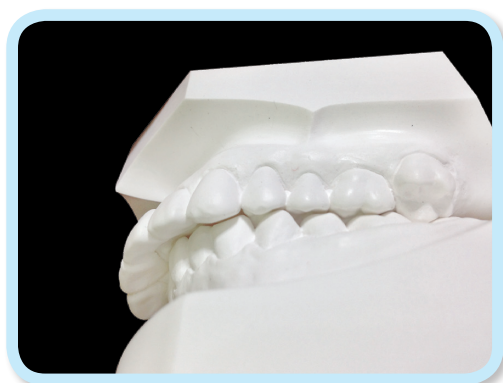After the maxillary right first premolar was extracted, the three-unit fixed prostheses was removed. A temporary fixed cantilever partial denture was constructed, with tooth #8 serving as an abutment for a #9 pontic. Temporary single crowns were placed on teeth #7, 10, and 11 (Fig. 11).

The brackets selected were 0.022" Damon D3MX® (Ormco, Glendora, CA) with high torque in the maxillary incisors and standard torque in the mandibular anterior segments. All of the archwires and elastics were produced by the same supplier (Ormco). The initial archwires were 0.014" CuNiTi.

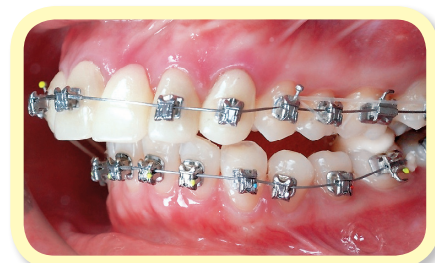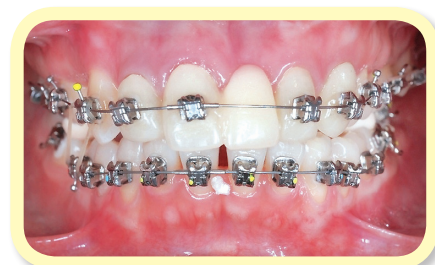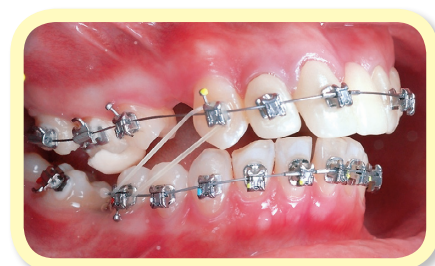Bite turbos were bonded on the occlusal surfaces of the the right maxillary and left mandibular

first molars. To simultaneously correct the Class II relationship, and the full buccal posterior cross-bite of tooth #15 (Fig. 10), a lingual button was bonded on the mandibular second molar. The patient was instructed to wear Class II elastics (Quail® 3/16", 2oz.) and cross-bite elastics full time.

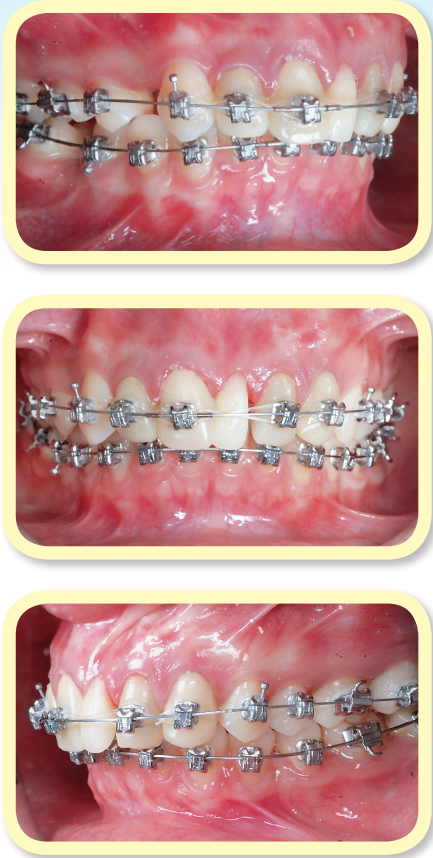After 10 months of treatment, the buccal posterior cross-bite was corrected, and the posterior bite turbos were removed. The wires were upgraded to .014"x.025" NiTi. The pontic width of tooth #9 was reduced and anterior segment of the maxillary arch was consolidated with an elastic power tube (Fig. 12).



■ **Fig. 10:**  
The upper left second molar (#15) was in full buccal cross bite.



■ **Fig. 11:**  
The fixed prostheses were removed and replaced with a temporary fixed partial denture and single crowns. The brackets bonded and posterior bite turbos were installed. The patient was instructed to wear Class II elastics.



■ Fig. 12:

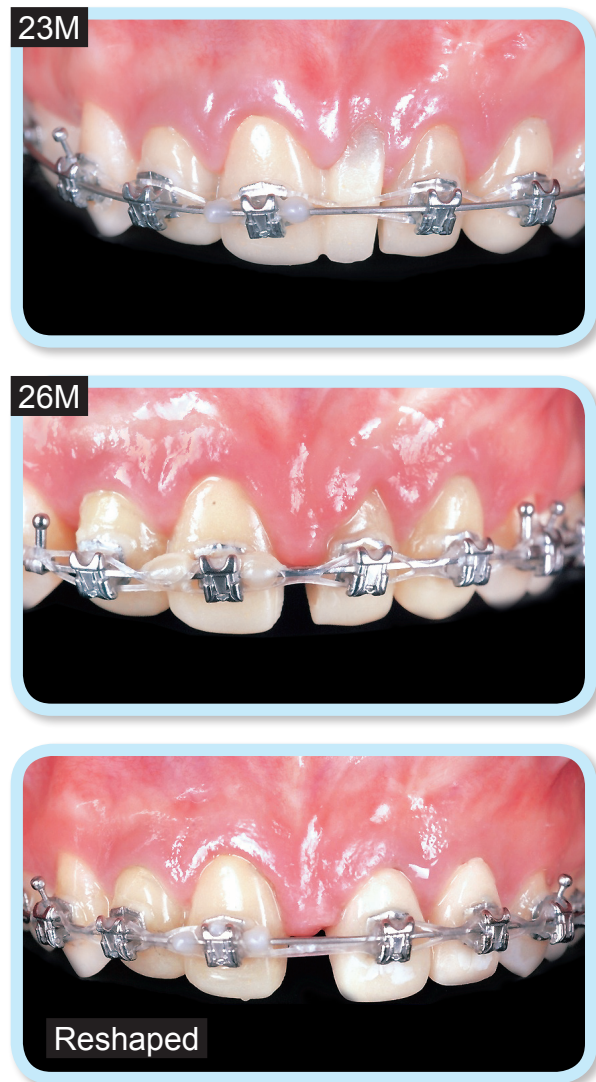After 10 months of treatment, the buccal posterior cross-bite was corrected, and the bite turbos were removed. The pontic width of #9 was reduced and the anterior segment of the maxillary arch was consolidated with an elastic power tube.

In the 13<sup>th</sup> month of treatment, a 0.017x0.025" TMA wire was inserted in the maxillary arch and the pontic width of #9 was reduced ~50%. An 0.016 x 0.022" SS wire was inserted in the mandibular arch and #31 was protracted with a power chain.

In the 14<sup>th</sup> month, the maxillary arch wire was upgraded to 0.019x0.025" SS wire. The tooth #9 space was progressively closed with power chain tension. In the 23<sup>rd</sup> month, the #9 pontic was removed to complete space closure. In the 26<sup>th</sup> month, the profile of the temporary crowns of #10 and 11

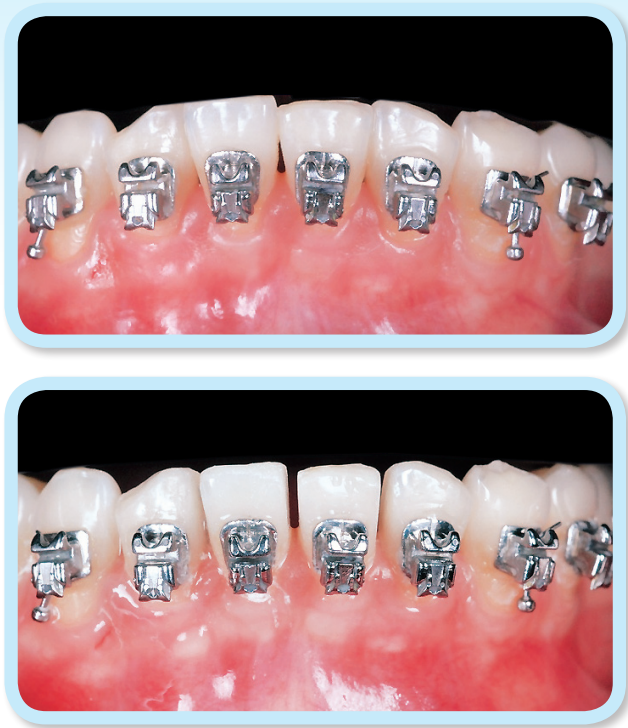were reshaped into central and lateral incisors. The maxillary anterior segment was consolidated as space was closed (Fig. 13).

The brackets of the mandibular central incisors were rebonded to correct axial angulations (Fig. 14). Inter-proximal enamel thickness of the mandibular incisors was reduced and spaces were closed with power chains to correct the black triangles. All fixed



■ Fig. 13:

In the 26<sup>th</sup> month, the profile of the temporary crowns (#10 and #11) were reshaped to simulate central and lateral incisors.



■ Fig. 14:

*Inter-proximal reduction was applied to the mandibular incisors to provide space for reducing the black triangles. The brackets of the mandibular central incisors were rebonded in the correct angulation.*

appliances were removed after 35 months of active interdisciplinary treatment.

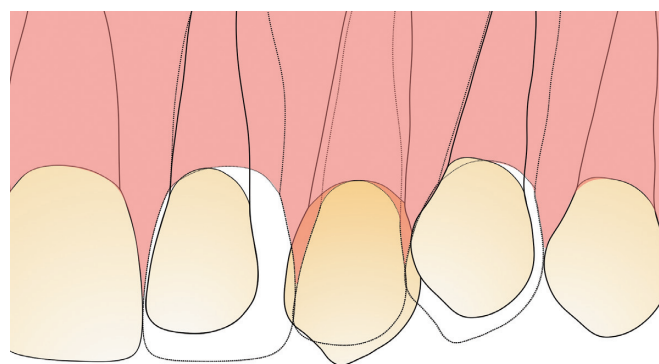
## Retention

Upper and lower clear overlay retainers were delivered. The patient was instructed to wear them full time for the first 6 months and nights only thereafter. Instructions for home care and maintenance of the retainers were provided.

## Prostheses Fabrication

One month after the completion of orthodontic treatment, temporary restorations were removed and a direct polyvinyl siloxane impression was made for

teeth #7, 8, 10, and 11. The impression was poured in die stone, and the four full ceramic maxillary anterior crowns were constructed with as natural morphology as possible. The major objective was achieving acceptable esthetic form and shade for the three mesially substituted teeth (#10-12) (Fig. 15). One week later, the four crowns were luted in place with resin cement and tooth #12 was restored in the form of a canine with restorative resin. A new upper clear overlay retainer was fabricated to fit the upper dentition.



■ Fig. 15:

*The mesially substituted teeth were altered restoratively to simulate upper left incisors and canine. Note that the primary consideration is aligning the gingiva and papillae. Once their axial inclinations were corrected, restorative procedures were performed.*

## Final Evaluation of Treatment

Cephalometric analysis (Table 1) and superimpositions (Fig. 9) showed no skeletal change in the maxilla or the mandible. The upper incisor to SN angle decreased from 103.5 to 85°. Because of the conservative treatment plan, the lower incisor to Md plane angle remained at 110°. The protrusive lips and lower lip eversion was improved, due to more ideal incisal relationships. All spaces were closed and the upper dental midline was corrected relative to



the facial and mandibular midline. The ABO Cast-Radiograph Evaluation (CRE) score was 27 points,<sup>1</sup> as documented later in this report.

There were multiple minor alignment discrepancies in the ABO CRE (27) that were primarily attributable to positional errors in bonding the brackets, but the overall result was pleasing. The protrusive lips were corrected and facial harmony was improved. The patient was particularly pleased with the improvement in her facial profile.

Although it is an esthetically challenging approach, multiple substitutions in the maxillary anterior esthetic zone are a viable conservative option for a missing central incisor.

## Discussion

Missing permanent maxillary anterior teeth (*esthetic zone*) is a substantial challenge in dentistry. From an orthodontic perspective, there are usually two treatment options:

1. Maintain the space and restore the missing teeth, prosthetically.
2. Close the space orthodontically and restoratively modify the teeth that are substituted.

There is no consensus as to which approach has the strongest evidence base, particularly with respect to long-term follow-up. A good immediate solution may be a long-term liability. The most common objections to orthodontic space closure are an “unnatural” esthetic outcome that is difficult to

retain and may compromise functional occlusion. However, patients often prefer the space closure option because they deem it a more conservative and desirable treatment plan compared to implants and prostheses.<sup>2,3</sup> An additional appeal is the belief that conservation of gingival tissue and papillae will provide a more predictable esthetic result.

The specific criteria for canine substitution are well discussed by Kokich and Kinser<sup>4</sup>. In addition to periodontal health, there are a number of important considerations when considering dental substitution: facial profile, type of malocclusion, space conditions, morphology and shades of the crowns, length of roots, and gingival contours.<sup>5,6,7</sup>

For the present patient (*Figs. 1-3*), the convex profile, Angle Class II malocclusion, and large overjet favor dental substitution. Another advantage was that most of the maxillary anterior teeth were already prepared for full coverage. This expands the conservative prosthetic options for restoring adjacent teeth with appropriate morphology, shades and functional contacts, in the maxillary anterior esthetic zone.

## Gingival Margin

When aligning natural teeth and abutments, the gingival margins should be the guide for optimal correction. Maxillary central incisors and the canines should be symmetric and in a more apical position compared to those of the lateral incisors (*high-low-high principle*). In addition, the esthetics should be reasonable symmetric between sides.

Orthodontic intrusion or extrusion is often the best option for raising or lowering gingival margins if teeth have a healthy periodontal attachment. However, adjustments of the gingival margins usually requires adjustment in crown morphology to provide optimal esthetics and function. Crown lengthening procedures may be required in addition to orthodontics, but this can considerably complicate treatment due to a loss of periodontal attachment (*mobility*), exposure of the cemento-enamel junction, and denuded root surfaces (*sensitivity*).

It is usually necessary to intrude mesially substituted lateral incisors and first premolars<sup>8,9,10,11</sup> to align the gingiva and provide prosthetic space for optimizing crown morphology and shade. On the other hand, a substituted canine may require extrusion and crown reduction to achieve a gingival margin characteristic of a lateral incisor.

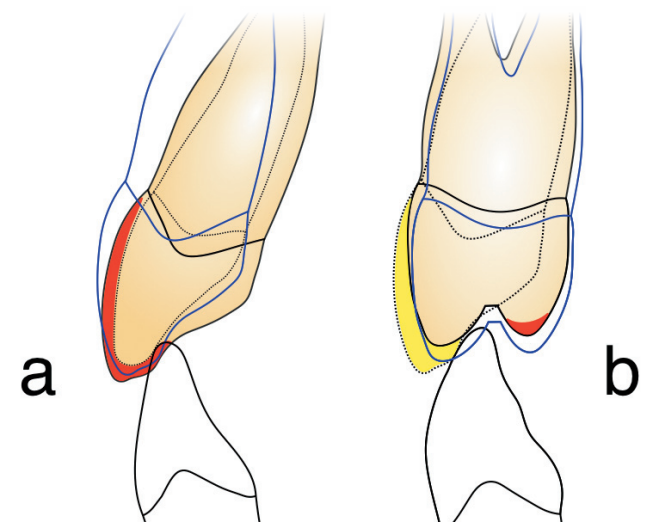
Canine Shape / Shade

The mesiodistal dimension of the canine (*Table 2*) is wider than a lateral incisor, so a significant amount of crown reduction, reshaping and tinting is required for a mesially substituted canine (*Fig. 15*), to achieve the appropriate esthetics and function of a lateral incisor. Moreover, the canine is thicker than the lateral incisor and it has less lingual curvature (*Fig. 16a*), so extensive crown or prosthetic adjustment is

required. The shade of the canine is usually darker than the adjacent lateral incisor. Optimal correction may require crowns or porcelain veneers.

Inclination and Root Eminence

When a maxillary canine is extruded with a labial fixed appliance, the crown usually tips lingually, resulting in a prominent, unesthetic canine eminence. Correcting this problem requires a great deal of lingual root torque<sup>12</sup> which may accentuate the crown morphology problems (*Fig. 16a*). It is usually best to correct the root torque before adjusting crown morphology.



■ Fig. 16:  
a. Lingual root torque reduces the canine prominence, but it requires reshaping of the tooth to look like lateral incisor. Compare with the superimposed positions: beginning canine prominence (blue), large canine root compared to normal lateral incisor root, and crown reduction required (red).  
b. Buccal root torque is needed to increase the first premolar root prominence. A resin buildup or a veneer (yellow) is needed along with reduction of the lingual cusp (red) to simulate canine form. The usual premolar position (blue) is shown prior to the orthodontic and restorative measures to simulate a canine.

Maxillary	Central Incisor	Lateral Incisor	Canine	1st Premolar	2nd Premolar	1st Molar	2nd Molar
Angulation (mesiodistal)	2°	7°	17°	9°	5°	10°	8°
Inclination (faciolingual)	28°	26°	16°	5°	6°	8°	10°
Crown Size (Mesiodistal)	8.5	6.5	7.5	7.0	7.0	10	9

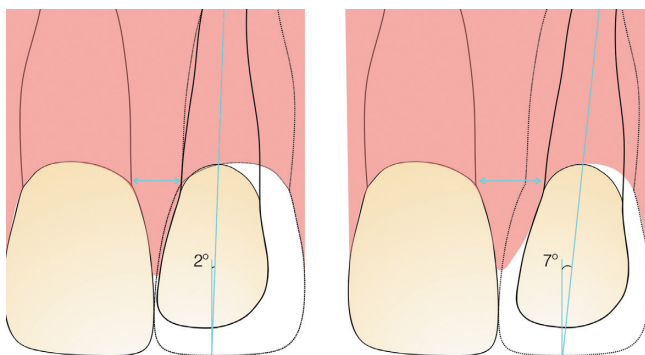
Adapted from Andrews and Wheeler

■ Table 2: Angulation/ Inclination/ Crown Size

In contrast, a substituted first premolar usually requires intrusion, followed by restoration with composite resin or a porcelain veneer to achieve optimal esthetics and occlusal function. As illustrated in Fig. 16b, intrusion of a maxillary premolar usually results in inadequate root eminence and an unesthetic exposure of the lingual cusp when smiling. Again, it is best to correct the axial inclination of the root prior to undertaking crown morphology modifications.

### Angulation and Mesiodistal Position

The emergence profile of a maxillary central incisor is generally flat on the mesial surface, but the adjacent lateral incisor is more angulated (*Table 2*). When substituting a lateral for a central incisor, it is necessary to move it close to the midline to provide a more natural midline papillae<sup>13,14</sup> (*Fig. 17*). Because of the size difference between the incisors (*Table 2*), the lateral incisor must be extensively recontoured on the distal surface (*Fig. 15*) which may or may not be consistent with periodontal health. Again the recontouring procedures must be carefully planned



■ **Fig. 17:**  
Compared to normal tooth form (right), angulation (2°) and mesiodistal positioning of the substituted lateral incisor is essential for simulating the midline papilla and central incisor crown form (left).

for the entire maxillary esthetic zone. It may be advisable to reduce the width of contralateral teeth and then redistribute the space to achieve the most esthetic and healthy gingival solution.

### Labio-Palatal Position and Rotation

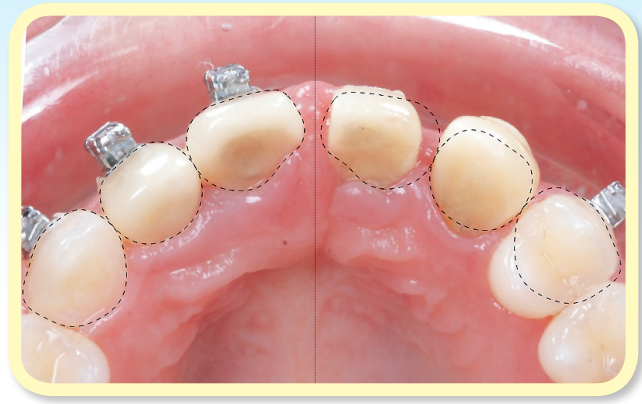
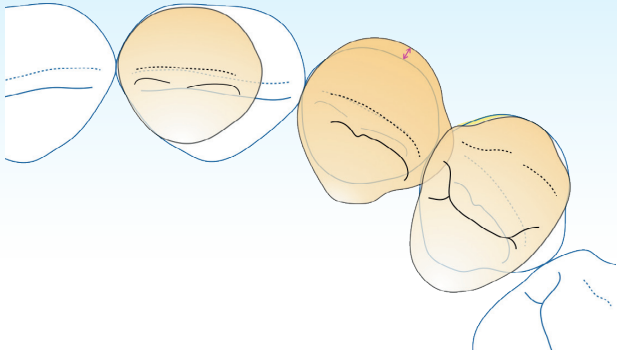
The lateral incisor should be placed somewhat labially in an atraumatic overjet relationship to reduce the functional load and to avoid traumatic occlusion (*jiggling*).<sup>14</sup> Since the canine is thicker labiopallatally than a lateral incisor, an outset in the main archwire may be necessary to obtain a proper alignment and occlusal contact points, between substituted maxillary incisors and their antagonists.

The mesial line angle of the first premolar is more prominent than for the canine. To present a more canine-like appearance, the first premolar is rotated slightly to the mesial, by distally positioning the bracket (*Fig. 18*).

### Bracket Selection

A central incisor bracket should be placed on a mesially substituted lateral incisor to achieve an appropriate angulation for the labial surface of the incisor, as well as to better control its rotation, and correct the second order axial inclination. This concept is supported by a 10 year follow-up study investigating outcomes for substituted canines to close spaces due to congenital absence of maxillary lateral incisors. The most common esthetic deficit was inadequate crown torque of the mesially relocated canine, so it was recommended that the bracket be specific to the final location of the tooth. Therefore, an incisor bracket should be used on the





■ Fig. 18:

*The substituted lateral incisor should be placed near the midline and slightly labial to reduce the functional loading during protrusion. A main archwire outset corrects the position the substituted canine (red arrows) to obtain a proper contact point. The substituted first premolar should be mesially rotated slightly to simulate the appearance of a canine.*

flattened facial surface of the substitutive canine.<sup>15</sup>

For both esthetic and functional reasons, the buccal crown torque for a mesially substituted first premolar should be relatively perpendicular. As previously mentioned, intrusion of the premolar increases the buccal crown torque, so the first premolar bracket is still used because it has more negative torque ( $-7^\circ$ ) than the canine bracket ( $0^\circ$ ). In effect, the usual torque in the premolar brackets compensates for the positive torque that is a side effect of intrusion.

These maxillary anterior torque problems are best managed by a combination of bracket selection and differential archwire torque. The important consideration is to carefully monitor the third order effects though out the segment, then adjust the brackets and archwires accordingly.

## Occlusion

The root length of the lateral incisor is less than for the central incisor, so it should be protected during

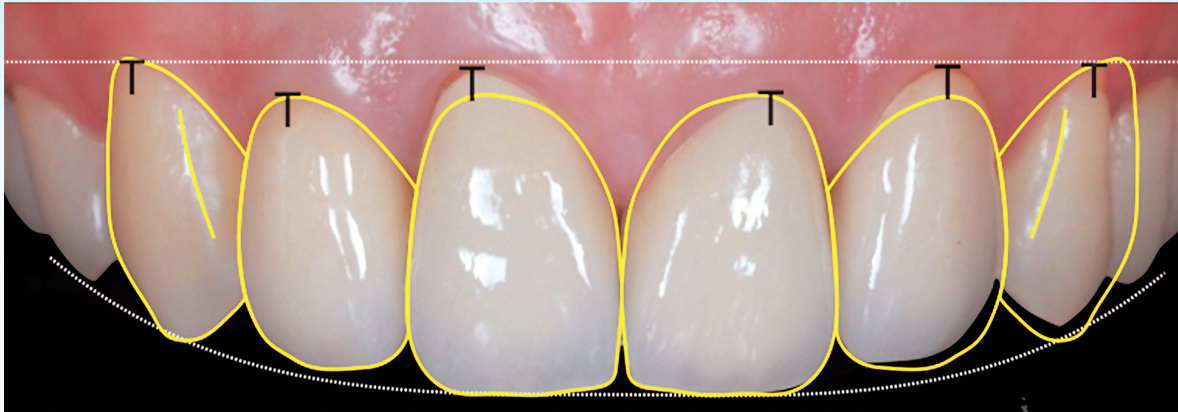
the incisive guidance of protrusion. The mesially substituted canine is best able to tolerate incisal guidance, but it may no longer be in an adequate position to provide canine guidance. It is important to carefully consider the optimal position of a tooth and its root structure in planning a mutually protected occlusion. Compromises may be required.

Also because of inadequate root structure, the medially substituted first premolar is usually a poor candidate for providing canine protected occlusion. Group function is the appropriate functional occlusion to avoid excessive stress on an intruded mesially substituted first premolar.

## Esthetic Evaluation of Treatment Results

Figs. 1, 2, 4, 5 and 20 document a pleasing improvement in both dental and facial esthetics, but careful analysis shows there is still room for improvement.

First, the left lateral incisor could have been moved



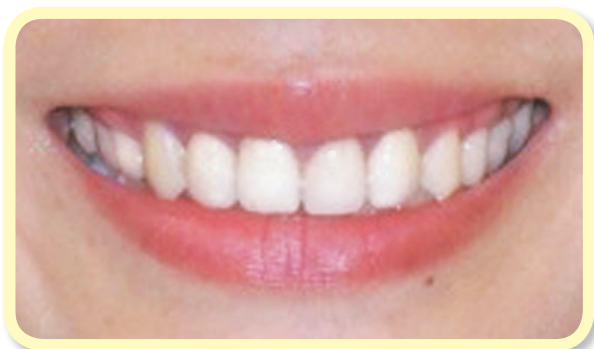■ Fig. 19:

The yellow lines indicates the ideal esthetic outline of the maxillary anterior crowns. Corrections required are:

- a. the gingival margin of the right central incisor and the left substitutive canine should be positioned more apically
- b. the gingival margin of the left substituted first premolar should be intruded
- c. the left substituted lateral incisor should be positioned closer to the midline
- d. the buccal surface and the cusp tip of the substituted left first premolar should be built-up restoratively.

closer to the midline to narrow the base of the midline papillae (Fig. 17).

Second, the left canine could have been extruded to lower the gingival margin and provide more gingival display, which would provide a more youthful appearance.<sup>16</sup> Also the translucence of the crown is a bit opaque, suggesting that a little more reduction on the facial surface of the abutment preparation was needed.



■ Fig. 20:

The treatment was very successful, but retrospective analysis suggests there is room for improvement.

Third, the left first premolar should have been intruded more to raise the gingival margin and then the restorative build-up could lengthen the cusp tip and thicken the facial surface, creating a more canine-like appearance.

## Conclusion

The initial consideration in managing missing maxillary teeth in the esthetic zone is the overall direction of treatment plan, which should be based on the facial profile, skeletal classification, dental occlusion, and patient preferences. It is important for the patient to understand the pros and cons of each approach, then agree to the cooperation necessary to achieve an optimal result. In monitoring treatment progress, it is essential to navigate the teeth into the arrangement that best meets the esthetic and functional requirements. Finally, the patient should be committed to the final restorative and prosthetic procedures to achieve an optimal long-term result with respect to both esthetics and function.

## Reference

1. Chang CH. Advanced Damon Course No.4,5: DI & CRE Workshop (1)(2). Beethoven Podcast Encyclopedia in Orthodontics [podcast]. Hsinchu: Newton's A Ltd; 2011.
2. Armbruster PC, Gardiner DM, Whitley Jr JB, Flerra J. The congenitally missing upper lateral incisor. Part 1: esthetic judgment of treatment options. *World J Orthod* 2005;6:369–75.
3. Armbruster PC, Gardiner DM, Whitley Jr JB, Flerra J. The congenitally missing upper lateral incisor. Part 2: assessing dentists' preferences for treatment. *World J Orthod* 2005;6:376–81.
4. Zachrisson BU. Improving orthodontic results in cases with maxillary incisors missing. *Am J Orthod Dentofacial Orthop* 1978;73:274–89.
5. Kokich VO Jr, Kinzer GA. Managing congenitally missing lateral incisors. Part I: canine substitution. *J Esthet Restor Dent* 2005;17:5–10.
6. Zachrisson BU. Improving orthodontic results in cases with maxillary incisors missing. *Am J Orthod Dentofacial Orthop* 1978;73:274–89.
7. McNeill RW, Joondeph DR. Congenitally absent maxillary lateral incisors: treatment planning considerations. *Angle Orthod* 1973;43:24–9.
8. Kokich V, Nappen D, Shapiro P. Gingival contour and clinical crown length: their effects on the esthetic appearance of maxillary anterior teeth. *Am J Orthod Dentofacial Orthop* 1984;86:89–94.
9. Kokich V, Nappen D, Shapiro P. Gingival contour and clinical crown length: their effects on the esthetic appearance of maxillary anterior teeth. *Am J Orthod Dentofacial Orthop* 1984;86:89–94.
10. Kokich V. Anterior dental esthetics: an orthodontic perspective I Crown length. *J Esthet Dent* 1993;5:19–23.
11. Kokich VG, Spear F. Guidelines for managing the orthodontic-restorative patient. *Semin Orthod* 1997;3:3–20.
12. Kokich VG. Esthetics and vertical tooth position: the orthodontic possibilities. *Compendium Cont Ed Dent* 1997;18:1225–31.
13. Kokich VG, Crabill KE. Managing the patient with missing or malformed maxillary central incisors. *Am J Orthod Dentofacial Orthop* 2006;129(4):S55–63.
14. Schwaninger B, Shaye R. Management of cases with upper incisor missing. *Am J Orthod Dentofacial Orthop* 1977;71:396–405.
15. Schwaninger B, Shaye R. Management of cases with upper incisor missing. *Am J Orthod Dentofacial Orthop* 1977;71:396–405.
16. Thordarson A, Zachrisson BU and Mjör, IA. Remodeling of canines to the shape of lateral incisors by grinding: A long term clinical and radiographic evaluation, *Am J Orthod Dentofacial Orthop* 1991;100:123–132.
17. Vig RG, Brundo GC. The kinetics of anterior tooth display. *J Prosthet Dent* 1975;39:502–4.





## Discrepancy Index Worksheet

TOTAL D.I. SCORE **38**

### OVERJET

0 mm. (edge-to-edge) =  
1 – 3 mm. = 0 pts.  
3.1 – 5 mm. = 2 pts.  
5.1 – 7 mm. = 3 pts.  
7.1 – 9 mm. = 4 pts.  
> 9 mm. = 5 pts.

Negative OJ (x-bite) 1 pt. per mm. per tooth =

Total = **4**

### OVERBITE

0 – 3 mm. = 0 pts.  
3.1 – 5 mm. = 2 pts.  
5.1 – 7 mm. = 3 pts.  
Impinging (100%) = 5 pts.

Total = **3**

### ANTERIOR OPEN BITE

0 mm. (edge-to-edge), 1 pt. per tooth  
then 1 pt. per additional full mm. per tooth

Total = **0**

### LATERAL OPEN BITE

2 pts. per mm. per tooth

Total = **0**

### CROWDING (only one arch)

1 – 3 mm. = 1 pt.  
3.1 – 5 mm. = 2 pts.  
5.1 – 7 mm. = 4 pts.  
> 7 mm. = 7 pts.

Total = **1**

### OCCLUSION

Class I to end on = 0 pts.  
End on Class II or III = 2 pts. per side **8** pts.  
Full Class II or III = 4 pts. per side **8** pts.  
Beyond Class II or III = 1 pt. per mm. **3** pts.  
additional

Total = **11**

### LINGUAL POSTERIOR X-BITE

1 pt. per tooth Total = **0**

### BUCCAL POSTERIOR X-BITE

2 pts. per tooth Total = **2**

### CEPHALOMETRICS (See Instructions)

ANB  $\geq 6^\circ$  or  $\leq -2^\circ$  = **4** pts.

Each degree  $< -2^\circ$  x 1 pt. =

Each degree  $> 6^\circ$  x 1 pt. =

### SN-MP

$\geq 38^\circ$  = 2 pts.

Each degree  $> 38^\circ$  x 2 pts. =

$\leq 26^\circ$  = 1 pt.

Each degree  $< 26^\circ$  x 1 pt. =

1 to MP  $\geq 99^\circ$  = 1 pt.

Each degree  $> 99^\circ$  **11** x 1 pt. = **11**

Total = **15**

### OTHER (See Instructions)

Supernumerary teeth x 1 pt. =  
Ankylosis of perm. teeth x 2 pts. =  
Anomalous morphology x 2 pts. =  
Impaction (except 3<sup>rd</sup> molars) x 2 pts. =  
Midline discrepancy ( $\geq 3$ mm) @ 2 pts. =  
Missing teeth (except 3<sup>rd</sup> molars) **2** x 1 pts. = **2**  
Missing teeth, congenital x 2 pts. =  
Spacing (4 or more, per arch) x 2 pts. =  
Spacing (Mx cent. diastema  $\geq 2$ mm) @ 2 pts. =  
Tooth transposition x 2 pts. =  
Skeletal asymmetry (nonsurgical tx) @ 3 pts. =  
Addl. treatment complexities x 2 pts. =

Identify:

Total = **2**

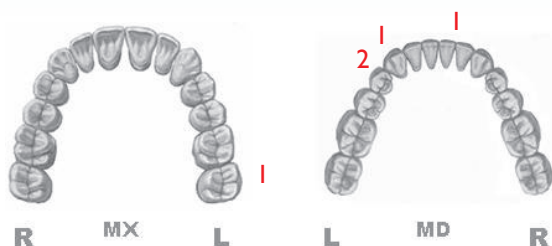
## Cast-Radiograph Evaluation

Total CRE Score

27

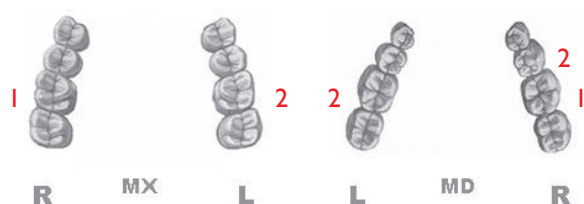
### Alignment/Rotations

5



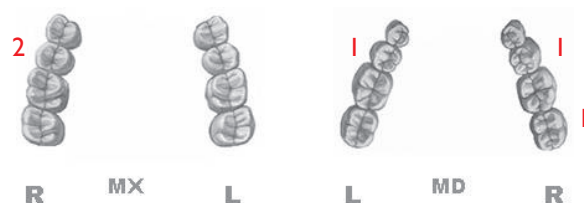
### Marginal Ridges

8



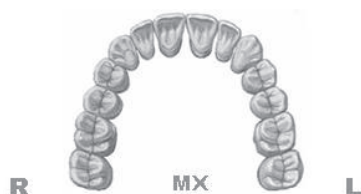### Buccolingual Inclination

5



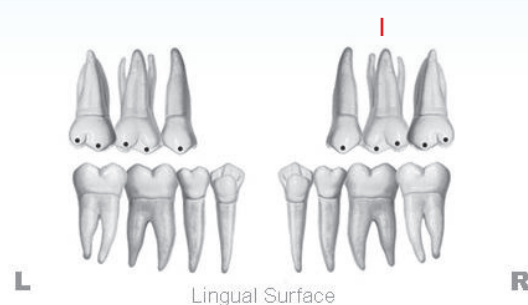
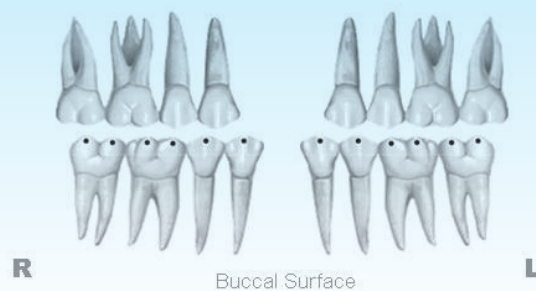
### Overjet

0



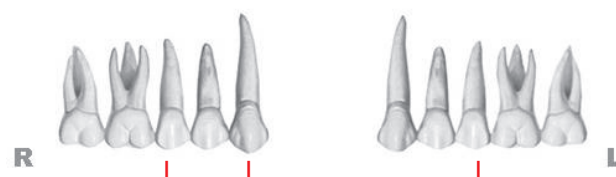### Occlusal Contacts

1



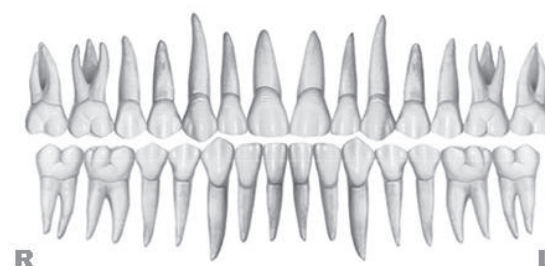
### Occlusal Relationships

3



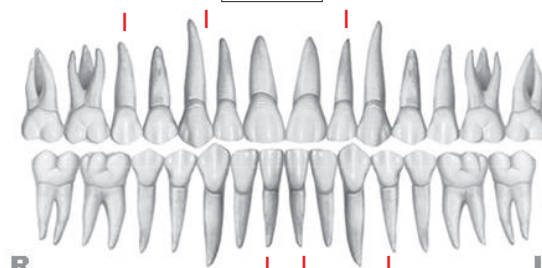
### Interproximal Contacts

0



### Root Angulation

5

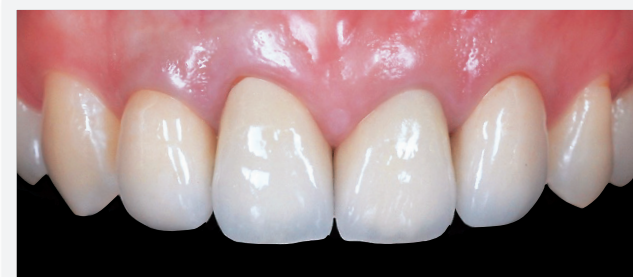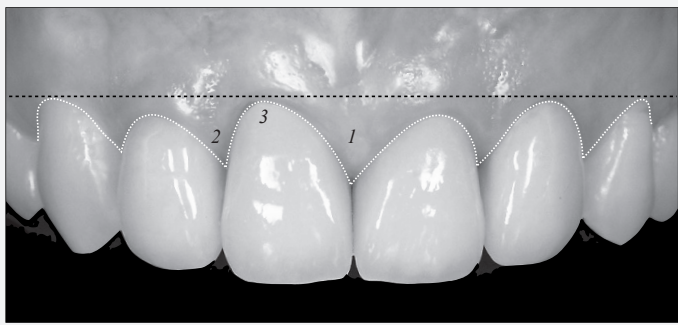


**INSTRUCTIONS:** Place score beside each deficient tooth and enter total score for each parameter in the white box. Mark extracted teeth with "X". Second molars should be in occlusion.

## IBOI **Pink & White** Esthetic Score (Before Surgical Crown Lengthening)

Total Score: = **6**

### 1. **Pink** Esthetic Score

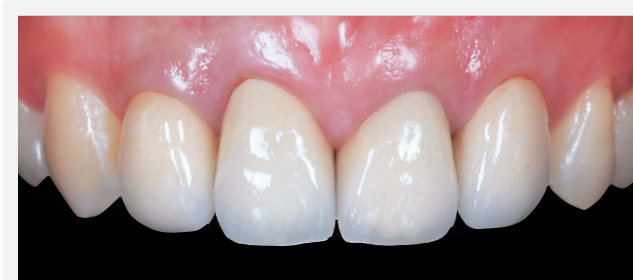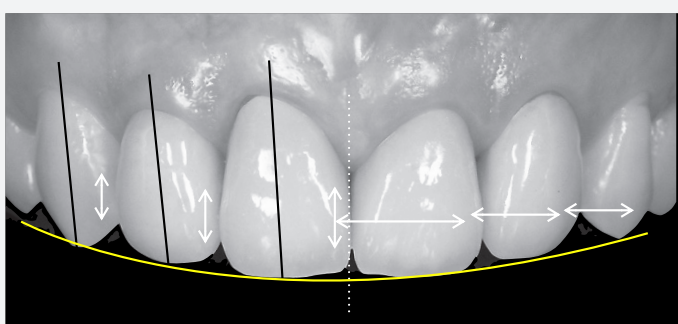


1. M-D Papillae	0	1	2
2. Keratinized Gingiva	0	1	2
3. Curvature of Gingival Margin	0	1	2
4. Level of Gingival Margin	0	1	2
5. Root Convexity ( Torque )	0	1	2
6. Scar Formation	0	1	2

Total = **2**

1. M & D Papillae	0	1	2
2. Keratinized Gingiva	0	1	2
3. Curvature of Gingival Margin	0	1	2
4. Level of Gingival Margin	0	1	2
5. Root Convexity ( Torque )	0	1	2
6. Scar Formation	0	1	2

### 2. **White** Esthetic Score ( for Micro-esthetics )



1. Midline	0	1	2
2. Incisor Curve	0	1	2
3. Axial Inclination ( 5°, 8°, 10° )	0	1	2
4. Contact Area ( 50%, 40%, 30% )	0	1	2
5. Tooth Proportion ( 1:0.8 )	0	1	2
6. Tooth to Tooth Proportion	0	1	2

Total = **4**

1. Midline	0	1	2
2. Incisor Curve	0	1	2
3. Axial Inclination ( 5°, 8°, 10° )	0	1	2
4. Contact Area ( 50%, 40%, 30% )	0	1	2
5. Tooth Proportion ( 1:0.8 )	0	1	2
6. Tooth to Tooth Proportion	0	1	2