

Case Report: Surgery-First Approach Combining with CDG® for Class II Patients

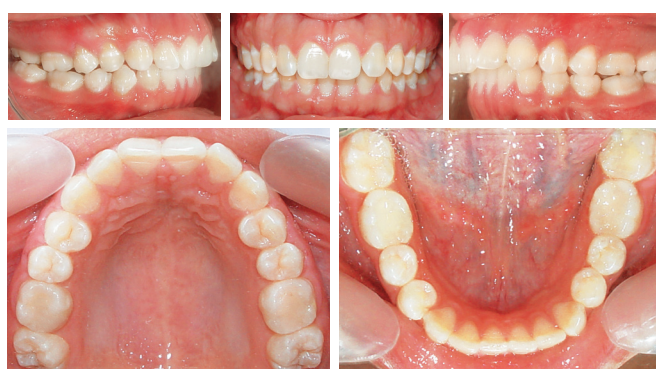Abstract

This article presents an interdisciplinary treatment approach for a 20-year-old female patient presenting with: (1) a convex profile, (2) and skeletal Class II malocclusion due to inferior mandibular retrognathism, (3) Retrogenia and (4) Amelogenesis imperfecta. Surgery was applied before orthodontics. A new device, Castellanos Direct Guides (CDG®), was used to ensure correct occlusal fixation during the surgery. The treatment time was significantly reduced to 8 months and the outcome was satisfactory according to the treatment plan. (Int J Ortho Implantol 2013;32:100-106)

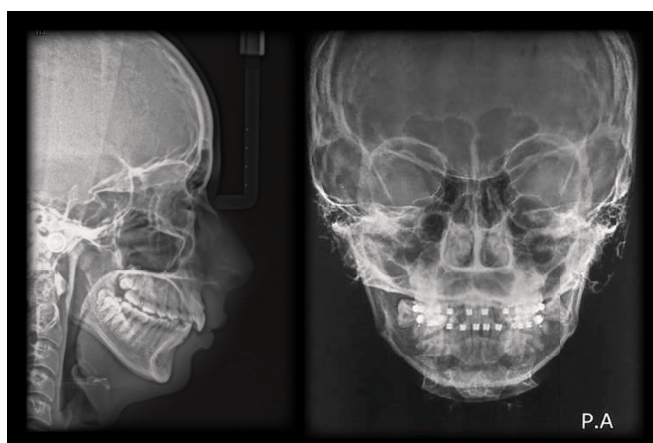
Introduction

Orthognathic surgery is considered for cases with different position and size of maxillary bones, when ideal esthetic and functional results are expected. Orthognathic surgery is planned to achieve the best esthetic (*macro, mini and micro esthetically*)¹ and functional results (*occlusion with condyles relocated in centric position and passive fixation of posterior segments*).

The conventional orthognathic surgery protocols require a relatively long period of treatment time, usually between 15 to 17 months^{2,3} and sometimes up to 24 months.⁴ These protocols are proceeded by a preliminary orthodontic dental alignment and leveling, using rigid stainless steel arches,

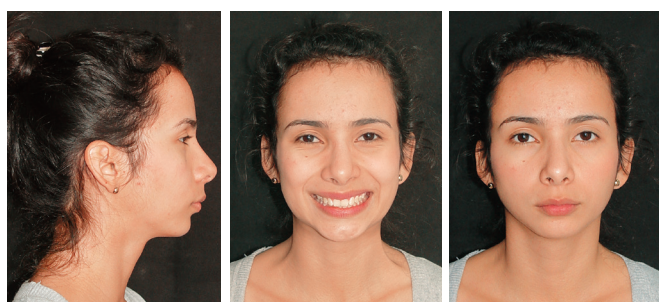

■ Lateral and postero-anterior x-ray



■ Fig. 1

Initial - December 20, 2011: Facial and intraoral pre-surgical pictures. Notice the convex profile, reduced inferior facial third, class II molar and canine bilateral dental relationship.





Dr. Tomás Castellanos Arteaga.
DDS Orthodontist
CIEO - Universidad Militar Nueva
Granada Graduate Teacher - UAN and
UNICOC Bogotá - Colombia



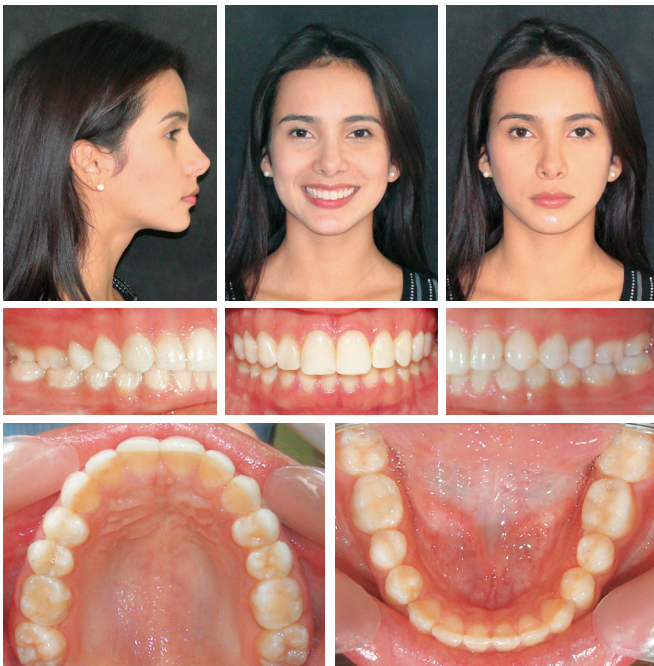Dra. Alejandra Rojas Ponte.
DDS Maxillofacial Surgeon
Universidad Militar Nueva Granada
Graduate Teacher
Bogotá - Colombia



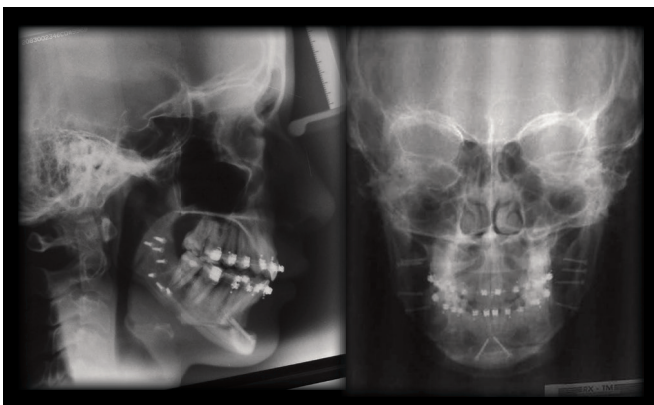
Dr. John Pobanz
DDS Orthodontist
University of Nebraska
Graduate Teacher - Pacific
University
UTAH - USA



Dra. Patricia Vergara Villarreal.
DDS Orthodontist
CIEO - Universidad Militar Nueva
Granada
Graduate Teacher
U. Cartagena - Colombia



■ Lateral and postero-anterior x-ray



■ Fig. 2

End of treatment: August 18th 2012 (total time of treatment: 8 months) Facial and intraoral post-surgical photos showing evidence of optimum esthetic and dental changes, providing symmetry, balance and shape of facial thirds, adequate mandibular and chin projection. The better projection of the nasal tip is partly due to the secondary rhinoplasty. Canine and molar relationships are class I bilateral and the dental inferior midline is corrected.

preferentially with welded surgical pins to assist in the fixation and intraoperative stability. Such orthodontic treatment is slow, offers limited results and often makes the malocclusion more pronounced which is part of the reason for rejection.

The conventional orthodontic method is also challenged as the result of patients' tendency to easily dislodge the inferior brackets. In addition, lifting the curve of Spee is more complex and slow due to the compressive force of masseter and internal pterygoid muscles' resistance. This can be avoided in mild cases by placing bite-turbos or biting blocks. However, in more complex cases it is necessary to initiate the orthodontic treatment only in one dental arch, and to place a bite lifting plate in the antagonist one, which further increases the time required for decompensation .

"Surgery first", an alternative described by Brachvogel in 1991⁵ and later by Nagasaka in 2009,⁶ is considered to eliminate the long decompensation stage and avoid some of the previously mentioned disadvantages. However, the risk of orthognatic surgery without prior orthodontics is the unexpected positional changes of jaws and teeth as a consequence of incorrect model surgery.

To provide stability some protocols are recommended for bonding brackets and placing passive arches .

Some protocols emphasize the problems derived from the Curve of Spee that contraindicate this approach due to the lack of intra and post-operative occlusal stability, related to development of bilateral posterior open bite, directly proportional to the Curve of Spee, that creates anterior edge to edge bites which tends to limit and compromise the final outcome.⁷ Other protocols as that cited by Liou in 2011 consider two options for class II patients: First, to perform a segmented mandibular anterior osteotomy to level the Curve of Spee and second, post-surgical dental intrusion of the anterior-inferior section to close posterior open bite, which will facilitate mandibular self-rotation and achieve a better profile of the patient.⁸

This surgery first approach can reduce treatment length in two aspects: First, the elimination of pre-surgical orthodontic phase of decompensation; second, the regional acceleration phenomena (RAP) that increases the rate of dental orthodontic movement.⁹ RAP is described as an increased metabolic activity linked to bone turnover, used in early post-surgical orthodontic phase, to facilitate a faster dental movement and reduce treatment time.

This case reported a new approach based on the surgery-first approach to treat class II dentofacial anomalies, using an innovative device, Castellanos Direct Guide (CDG®). It is easy to obtain, fast, reliable and warrants surgical stability, and provides great patient comfort. This device opens a broad set of diversified approaches to facial surgery. The design of this orthodontic aid serves two main purposes: to assist the orthognathic surgeon to place the bone segments in the desired occlusal position and to obtain better stability while reducing treatment time. It is made possible because of the regional acceleratory window developed by bone osteoinduction generated by the surgery.^{8,9}

This case report aims to explain the fabrication, function and advantages of this new device and its application. This article presents a case, representative of a group of patients that have been successfully treated by this interdisciplinary approach.

Patient: N. F.

Age: 20.

Gender: Female

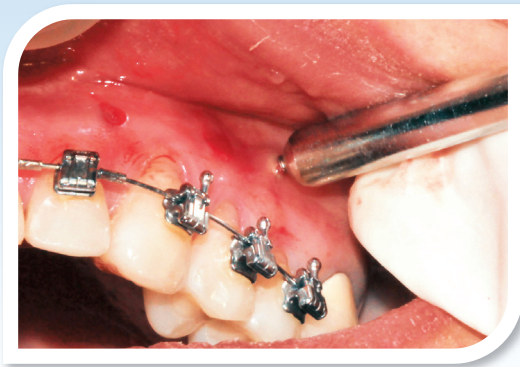Chief complaint: small mandible and protrusive upper central incisors.

Summary of Diagnostic Findings:

1. Convex Profile
2. Skeletal Class II associated to inferior mandibular retrognathism
3. Overjet: increased
4. Reduced inferior facial third
5. Short Distance menton-throat
6. Deep mento-labial groove
7. Retrogenia
8. Deep Curve of Spee
9. Multiple rotations and versions
10. Inferior midline deviation to the left 3 mm, associated to levognathism (*Condylar hyperplasia was discarded by bone gammagraphy*)
11. Left canine and molar Class II, 7 mm
12. Right canine and molar Class II, 3 mm
13. Enamel Hypoplasia (*Generalized Amelogenesis imperfecta*)
14. Third molar teeth extraction indicated for lack of space.

Interdisciplinary Team Participants:

- Maxillofacial surgeon



■ Fig. 3:

Taking into consideration that RAP occurs only in the lower jaw due to the surgical procedure, microperforations can be performed in the upper arch in order to match dental movement. It is important to point out that propel should not be done on the posterior upper teeth for the closing of the residual open bite should occur by the extrusion of lower molars and premolars, thus leveling the Curve of Spee.

- Orthodontist
- Plastic surgeon
- Esthetic dentist

Interdisciplinary Treatment Objectives:

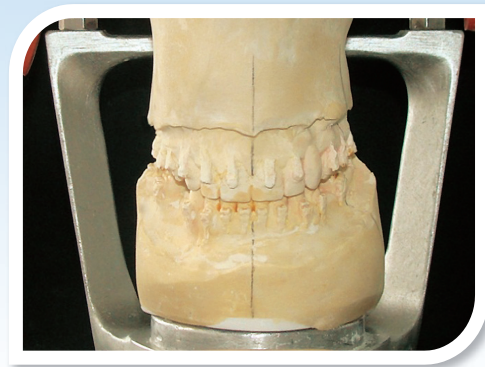- To obtain facial proportion harmony
- Straight Profile
- Skeletal class I
- Anterior teeth coupling
- Occlusion in centric relation
- Recover vertical dimension of the facial inferior third
- Reduce the curve of Spee
- Bilateral canine and molar Class I
- Dental Alignment and leveling
- Improve dental shape and color

Brackets:

- Passive self-ligation Brackets, Slot 0.022"

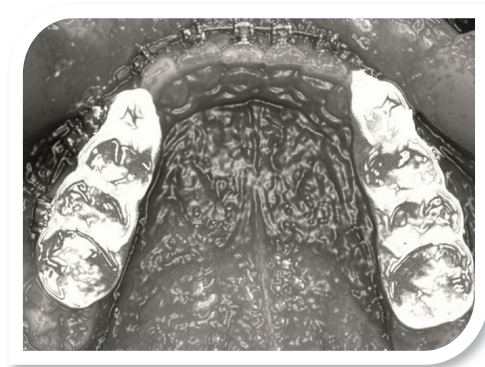Sequence of Treatment:

Once the ortho-surgical aims were established,



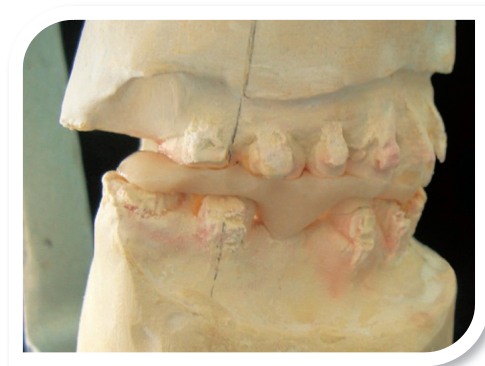■ Fig. 4:

Models mounted in the articulator (adjustable or semi-adjustable), based on the STO.



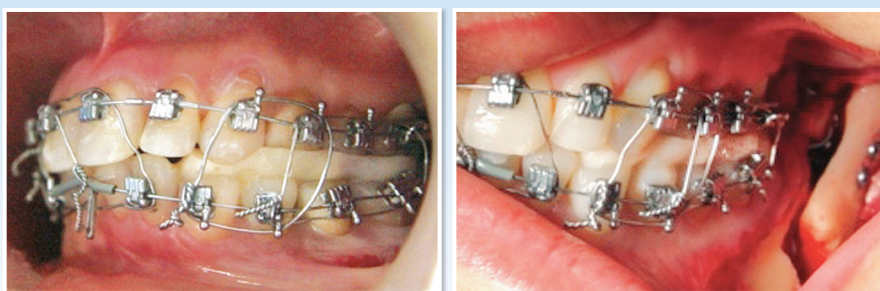
■ Fig. 5:

The CDG®s are independent (right and left) is recommended ideally covering the occlusal area since at least the third mesial occlusal surface of the second molar to the distal aspect of the canine. It is important that the morphology copied in detail in this area.



■ Fig. 6:

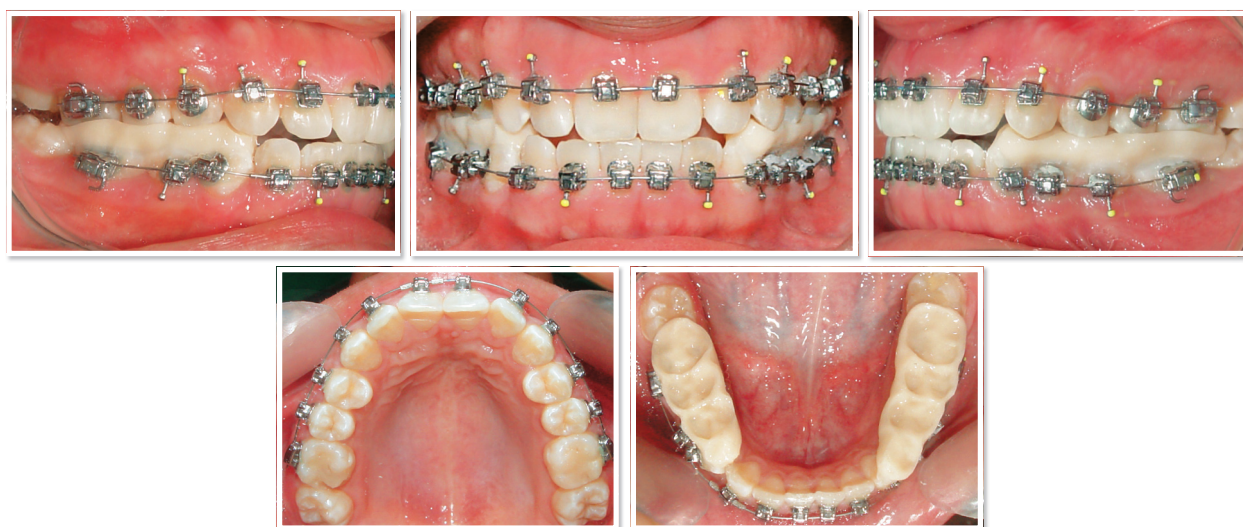The direct guide should provide the highest possible stability, (in the case shown in this figure the acrylic contacts saliva even in the space of an absent tooth)



■ Fig. 7

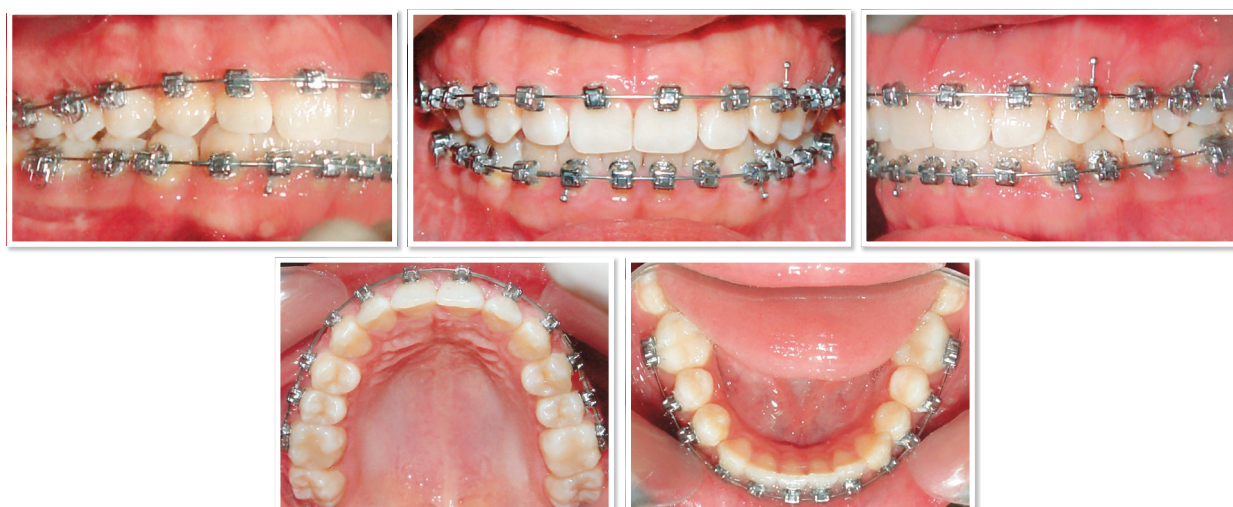a: Transoperative picture. Notice CDG® in position with FIM and wires in the expected position previously planned in the model surgery. Indentation is perfect.

b: It shows the mandibular advancement outcome and occlusion as planned.



■ Fig. 8:

Postsurgery: January 2012 (2 weeks after surgery) Shows the patient two weeks following the procedure CDG®'s preserved stability. the occlusion shows the same position as was predicted in the model surgery "The patient feels comfortable, because her bite remains stable reference tracks"



■ Fig. 9:

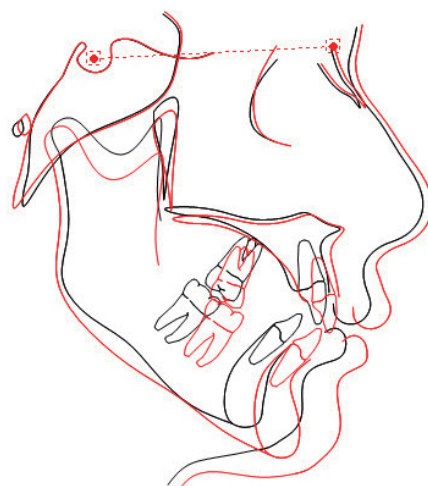
Intraoral photos of the post-surgical orthodontic process showing evidence of arch coordination six months after surgery.

treatment based on post operative occlusion and guidelines of surgical treatment objectives (STO) began. Special attention was given to the axial inclination of lower incisors and Curve of Spee, both of which would be corrected during the orthodontic phase when the adjacent soft tissue would be altered.

1. Articulator mounting in centric relation .
2. Surgical model sectioning and mandibular advance 7 mm to the right and 3 mm to the left, asymmetricly, according to the treatment plan and STO.
3. Preparation of CDG® guide. The customized CDG® are fabricated as follows:
 - a) Isolation of posterior occlusal surfaces in both models with separating solution.
 - b) Apply self-curing acrylic in its plastic phase, independently on the occlusal inferior right and left surfaces.
 - c) Occlude in the mounting position made as indicated in the STO.
4. Carefully remove the CDG®s.
5. Bonding of superior and inferior brackets with versatile Smile Arc Protection (SAP) to protect the arch and smile curve.¹¹
6. Initial arch: .014" NiTi archwire
7. Bonding CDG® guides to the inferior occlusal face, using glass ionomer.
8. Surgical sequences: Chin osteotomy, bilateral sagittal splint osteotomy with simultaneous extraction of inferior third molars, intermaxillary fixation with 0.5 wires using CDG®'s, rigid internal fixation with bicortical screws for osteotomy of mandibular ramus, remotion of intermaxillary fixation, checking occlusion and adequate condylar position and excursions, rigid internal chin fixation, extraction of superior third molars.
9. The patient kept the CDG® in place for 4 to 5

weeks. During this period, regular checkups were conducted to ensure the occlusion was stable and elastics were delivered.

10. After 4 to 5 weeks, X-ray films were taken and the CDG® was removed, using rotatory high speed instruments to debilitate the bonded interface.
11. After this stage, the orthodontic procedure is managed as a class I skeletal case, with the normal protocols and archwire sequences. Additionally, elastics (2 oz) were used, based on Pitts' protocols, to close the open bite at the premolar level caused by the deep Curve of Spee.
12. After completing the orthodontic treatment, the brackets were removed and superior impressions from second to second premolar were taken to apply Luminieres, which improved morphology and solve texture and color problems associated to the condition of amelogenesis imperfecta.
13. Occlusal adjustment by selective stripping.
14. Removable retention with Pitts' MT Splints, for dentomaxillary stabilization, to be used at night.



■ Fig. 10:

Superimpositions: Initial - December 20, 2011 (Black line) and final: August 18th 2012. Notice the convex profile, reduced inferior facial third, class II molar and canine bilateral dental relationship. (total time of treatment: 8 months)

Treatment Outcomes:

1. Straight Profile - Class I canine and molar bilateral
2. SAP Smile Arc Protection.
3. Anterior teeth coupling
4. Occlusion in centric relation
5. Recovery of vertical dimension of the facial inferior third
6. Flat Curve of Spee
7. Dental alignment and leveling
8. Improved dental shape and color.

Conclusions:

The Surgery-first protocol eliminates the decompensation orthodontic stage. The modified protocols applied in this case was performed by an interdisciplinary team. The combined use of a customized simple device-CDG® provided the surgeon precise guidance in the expected occlusal relation during the placement of bone segments and improved stability. One of the advantages of these protocols is the significant reduction of time, associated with the surgically induced, regional acceleratory phenomenon (RAP), the use of active NiTi archwires and early light elastics (2 Oz.) from the beginning of treatment, all of which allowed the initiation of dental movement during the time window. Other advantages are increased patient acceptance and comfort, better esthetic outcome and greater stability of the treatment. The CDG®s can provide an exact guide to the final occlusal relation and eliminate the post-surgery compensation stage. The CDG®s can be made and function even in absence of some teeth and give reliable stability during the intra and post-surgical procedures.

Acknowledgement

Acknowledgements to Drs. Luis Rogelio Hernández and Daniela Storino for their invaluable collaboration.

References:

1. Sarver D, Jacobson R. The aesthetic Dentofacial Analysis. *Clin Plastic Surg* 2007;34:369-394.
2. Luther F, Morris DO, Hart C. Orthodontic preparation for orthognathic surgery: How long does it take and why? A retrospective study. *Br J Oral Maxillofac Surg* 2003;41:401-406.
3. Dowling PA, Espeland L, Krogstad O, et al. Duration of orthodontic treatment involving orthognathic surgery. *Int J Adult Orthodon Orthognath Surg* 1999;14:146-152.
4. Diaz PM, Garcia RG, Gias LN, et al. Time used for orthodontic surgical treatment of dentofacial deformities in white patients. *J Oral Maxillofac Surg* 2010;68:88-92.
5. Brachvogel P, Berten JL, Hausamen JE. Surgery before orthodontic treatment: a concept for timing the combined therapy of skeletal dysgnathias. *Deutsche Zahn-,Mund-, und Kieferheilkunde mit Zentralblatt*, 1991;79(7): 557-563.
6. Nagasaka H, Sugawara J, Kawamura H, et al. "Surgery first" skeletal class III correction using the skeletal anchorage system. *J Clin Orthod* 2009;43:97-105.
7. Jeong HK, Mahdavi NN, and Evans CA. Guidelines for "Surgery First"Orthodontic Treatment, *Orthodontics In: Farid Bourzgui, editor. Orthodontics: Basic Aspects and Clinical Considerations. Rijeka: InTech; 2012. p. 265-300.*
8. Liou EJ, Chen PH, Wang YC, et al. Surgery-First Accelerated Orthognathic Surgery: Orthodontic Guidelines and Setup For Model Surgery. *J Oral Maxillofac Surg* 2011;69(3): 771-780.
9. Liou EJ, Chen PH, Wang YC, et al. Surgery-First Accelerated Orthognathic Surgery: Postoperative Rapid Orthodontic Tooth Movement. *J Oral Maxillofac Surg* 2011;69(3):781-785.
10. Pobanz JM, Nicocizis J, Storino D. Orthodontic Acceleration: Propel alveolar micro-osteoperforation. *Orthotown* 2013;5:22-25.
11. Pitts T. Begin with the end in mind. *Clinical impressions* 2009;17(1):4-12.

