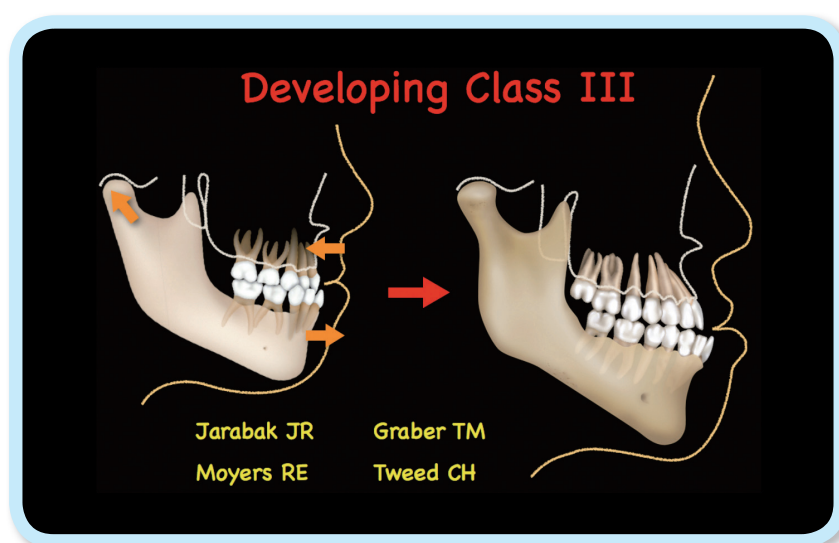


Mandibular Growth and Class III Treatment

Questionable Concepts of the Developing Class III

Most orthodontics literature advocates early treatment for anterior crossbite,¹⁻⁴ largely based on the hypothesis that a persistent anterior crossbite favors excessive growth of the mandible, and inadequate growth of the maxilla. This concept is predicated on the belief that a proper vertical overlap of the maxillary incisors is necessary to restrict mandibular and enhance maxillary growth. The traditional argument is that patients may have had an orthognathic profile and Pseudo Class III malocclusion when they are young, but they inevitably become a severe skeletal Class III malocclusions, in the absence of early orthodontics treatment to correct the crossbite (Fig. 1).



■ Fig. 1:

Developing Class III: if an anterior crossbite is not treated early, the functional restriction will result in decreased maxillary and excessive mandibular growth, resulting in a severe Class III skeletal malocclusion. (Courtesy Dr. Rungsi Thavarungkul)

Fig. 2A demonstrates the Class III growth process for a patient with a Pseudo Class III, anterior crossbite and orthognathic profile. Abnormal growth expression due to the crossbite results in a severe prognathic malocclusion with a True (Skeletal) Class III occlusal relationship. However, Fig. 2A is actually a computer morphing based on the initial facial profile photograph of a 8y9m boy with a Pseudo Class III malocclusion (Fig. 3). The boy was not treated, but did return for recall when was 13y9m. Note, that he is still a Pseudo Class III case and did not develop into a severe True Class III case, as was simulated in the photo sequence (Fig. 2A). In fact, the right side photograph in the simulation is the profile of the 11y11m lateral profile of the boy shown as **Case 2** in Fig. 4. The latter boy has been a severe prognathic True Class III malocclusion since the age of 6y8m.

Dr. John Jin-Jong Lin
 MS, Marquette University
 Chief Consultant of IJOI
 President of TAO (2000~2002)
 Author of *Creative Orthodontics*



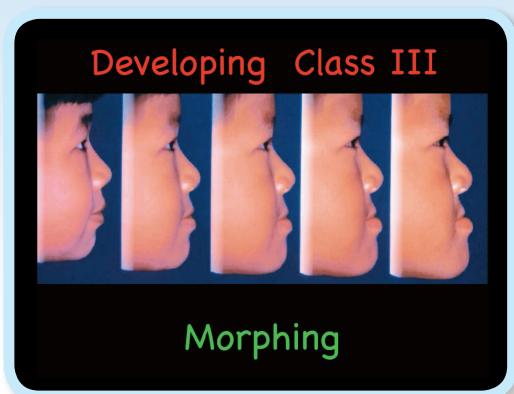Thus, the morphing in Fig. 2A is important for demonstrating the traditional concept of Class III development. All orthodontists have seen patients at each end of the Class III spectrum, so the natural assumption is that there is a progressive sequence for all of them. However, clinical experience has shown that severe, skeletal Class III malocclusions are manifest early. As explained in Section 1 of this chapter, differential diagnosis is critical for distinguishing patients, who are likely to benefit from early correction, from those who are probably destined for orthognathic surgery.

Many orthodontists ascribe to the concept that all Class III patients have an abnormal growth pattern, that will eventually lead to severe problems. Thus, they perform interceptive Class III treatment as early as possible, to correct the crossbite and establish a more normal growth pattern. For patients with a mild to moderate Pseudo Class III, with an orthognathic profile in CR, it is not necessary to perform interceptive treatment, but these patients usually have a good prognosis if early treatment is performed, as the definitive measure. On the contrary, if a patient shows a severe skeletal malocclusion early (*Class III molar and prognathic profile in CR*) early treatment is not an effective interceptive approach, because they will probably relapse, due to the late mandibular growth. This evolving concept will be discussed further after a review of literature later in this section.

Late Mandibular Growth

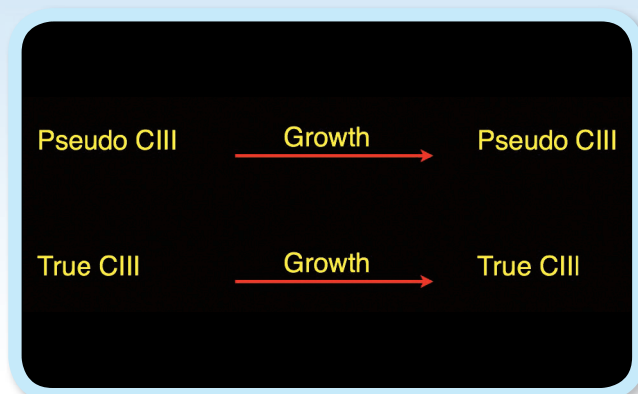
The long-term growth studies of Bjork⁵ and Thailander⁶ demonstrate that maxillary growth is essentially complete by the age of 10, but the mandible continues to grow until about age 20. The latter is referred to as late mandibular growth (Fig. 5). In this regard, the success of Class III interceptive treatment cannot be assessed until growth is completed.

A good clinical example of late mandibular growth is shown in Fig. 6. After orthodontic treatment was completed at age 19y9m, the patient's mandible continued to grow and deviate to the left side. The harsh reality when treating Class III malocclusions is that the patients may continue to grow forward, and they often deviate to one side or the other. Even after the age of 18-20yrs, some mandibular growth may still occur. Compensating for this potential problem requires overcorrection of the malocclusion, or waiting until later than 20yrs of age to start the orthodontic treatment.



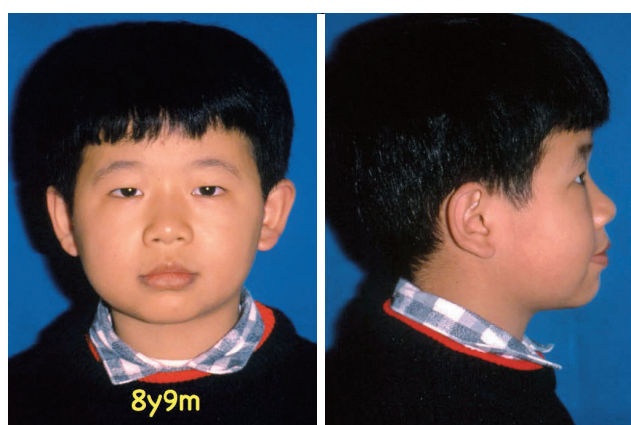■ Fig. 2A:

Developing Class III means a growing patient with an anterior crossbite (left) progressively becomes more Class III and prognathic (right). Early treatment of the anterior crossbite intercepts the Class III growth pattern.



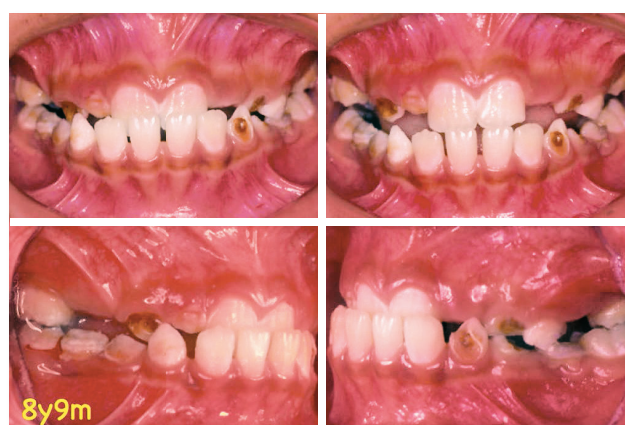■ Fig. 2B:

A long-term follow-up study shows that untreated Pseudo or True Class III malocclusions are maintained with growth.



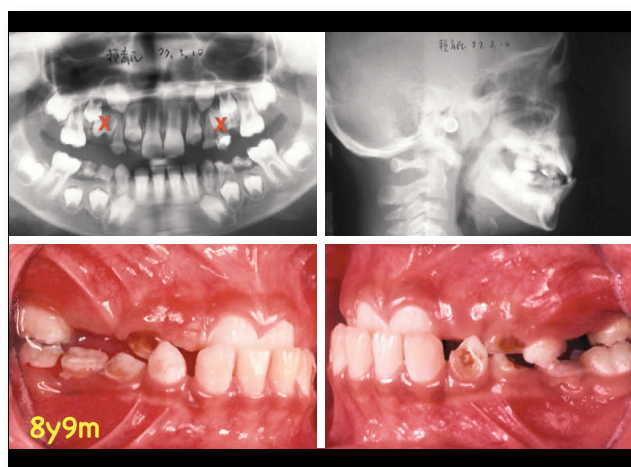■ Fig. 3A:

8y9m male with Pseudo Class III malocclusion with an orthognathic profile in CR.



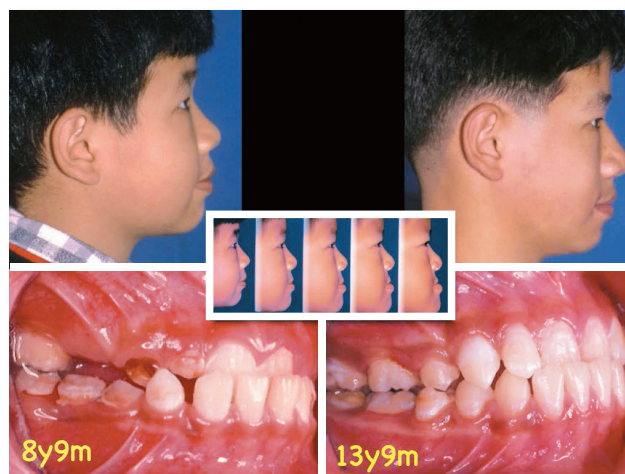
■ Fig. 3B:

The functional shift and pseudo Class III relationship.



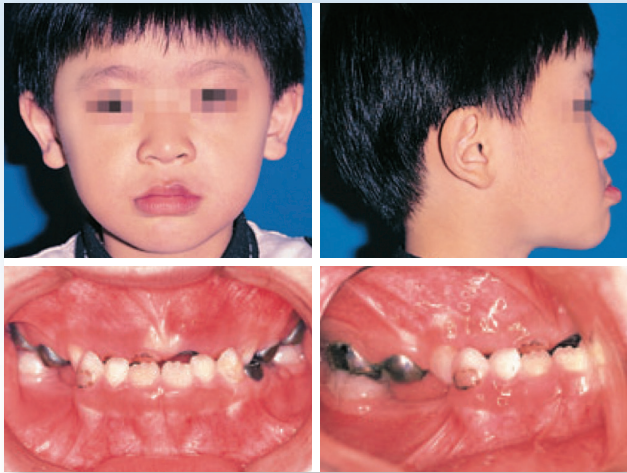■ Fig. 3C:

A severe mutilated dentition is due to rampant caries. The treatment plan was to remove four premolars, but after two upper first premolars were removed, the patient disappeared.



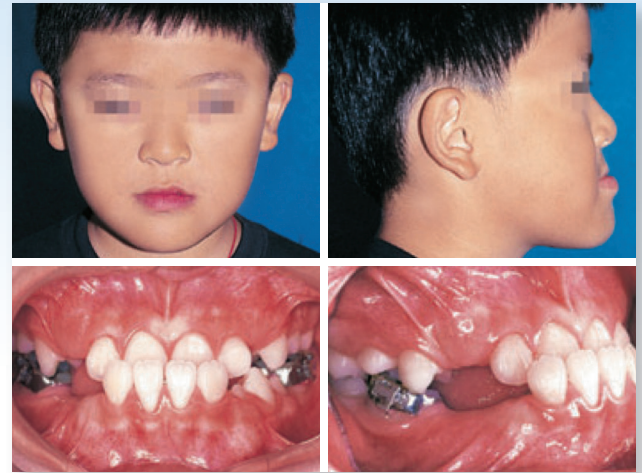
■ Fig. 3D:

About five years later, the patient returned with a better occlusion and a good profile, but he still had an anterior crossbite. This malocclusion is easily managed with fixed appliances.



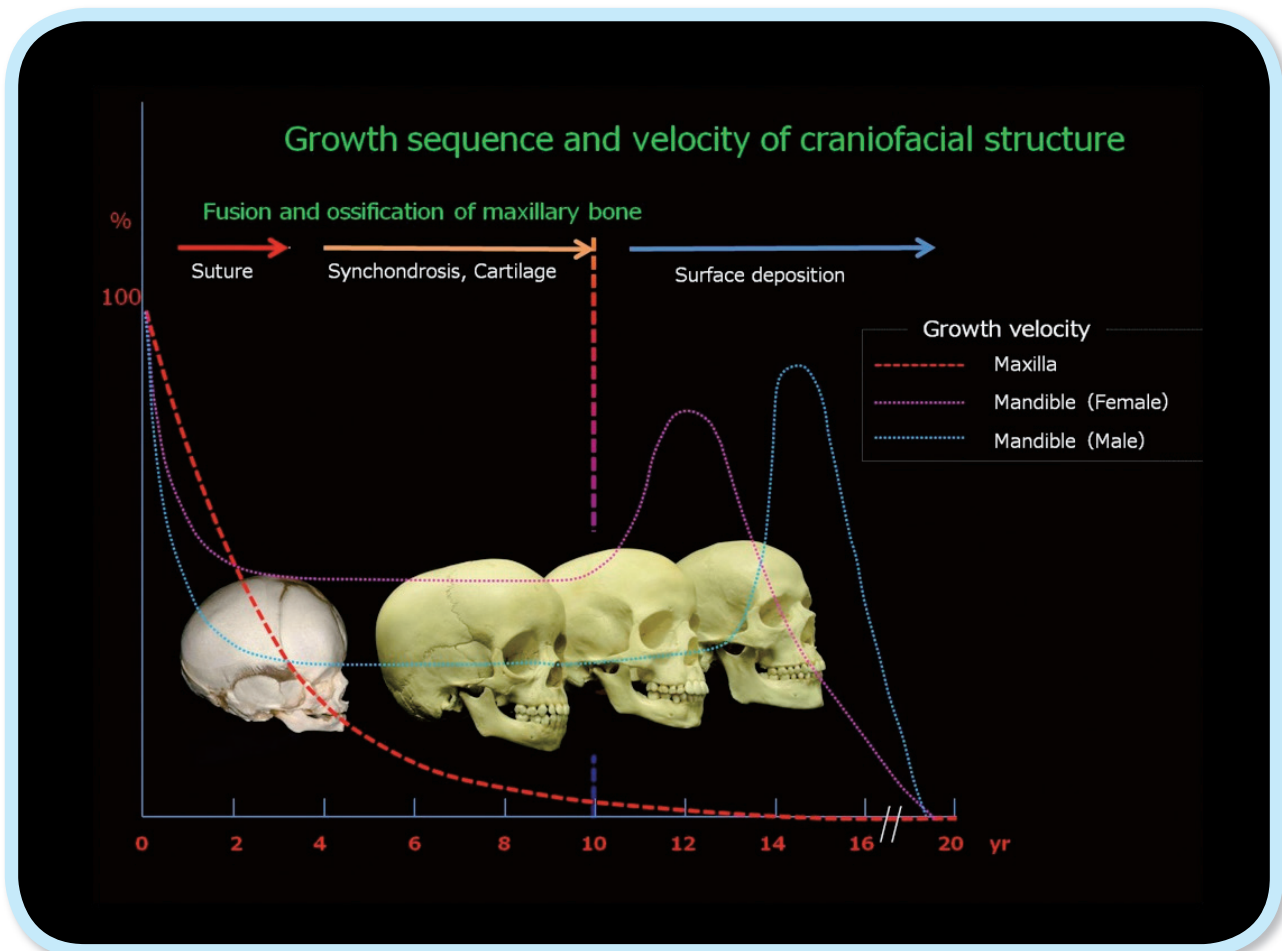
■ Fig. 4A: 6y8m

A true CIII malocclusion with a prognathic profile



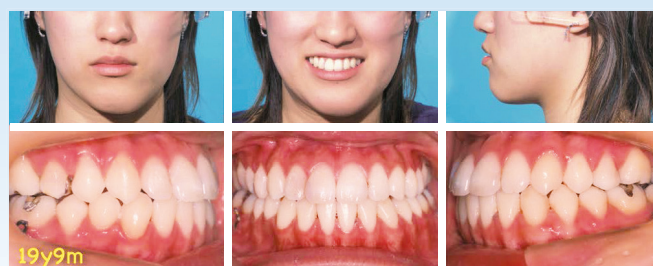
■ Fig. 4B (case 2): 11y11m

After 5 years 3 months of additional growth, this is still a severe true CIII case with a prognathic profile



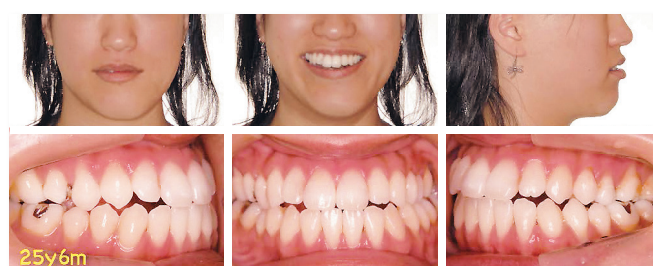■ Fig. 5:

Late mandibular growth: most of the maxillary growth is over by age 10, but there is still a lot of mandibular growth left until about age 20. Female lower jaw (F) growth usually finishes earlier than the male lower jaw (M) growth. (Courtesy Dr. Kazuto Kuroe)



■ Fig. 6A: 19y9m

A severe Class III, asymmetric open bite patient was successfully treated with the SAS (Skeletal Anchorage System) mini-plate system to a Class I occlusion. (Courtesy Dr. Junji Sugawara)



■ Fig. 6B: 25y6m

Although the patient was finished in Class I occlusion at age 19y9m, very late mandibular growth has produced a relapse of the Class III malocclusion with a mandibular deviation to the left.

Orthodontics or Orthopedics in Class II Treatment

As an introduction to Class III orthopedic treatment, it is important to review the extensive clinical experience with Class II treatment. Although some orthodontists still prefer removable functional appliances, the trend in recent years is clearly toward fixed functional appliances, because they require less patient cooperation. However, all orthodontic devices require a thorough understanding of its pros and cons to maximize the treatment outcome. According to Cohen⁷ and Mill et al.,⁸ the success rate with removable functional appliances is only ~30%. Inappropriate growth may be a factor, but Sahm, et al.⁹ report that the patient's lack of cooperation is the major reason for failure.

Herbst appliances require minimal patient cooperation. Pancherz et al.^{10,11} have published two longitudinal studies on the treatment outcomes with Herbst devices. They demonstrate that functional appliance is an appropriate treatment option for dentoalveolar correction (*"fitting teeth together"*), but there is little skeletal alteration, i.e. true orthopedic effect (Figs. 7-8).

An illustration from Proffit's text¹² demonstrates the curve for temporary acceleration of facial growth associated with functional appliance therapy (Fig. 9). The appliances are most effective during the early treatment period in the mixed dentition. However, this is only a temporary effect because the total amount of mandibular growth is unchanged. Functional appliances are incapable of stimulating additional mandibular growth, but they can cause it to be expressed earlier.

In dentofacial orthopedics of Class II malocclusions using the Herbst appliance it seems as if the inherent morphogenetic pattern dominates over the treatment procedure. This could also be true for other dentofacial orthopedic approaches as well (e.g. Activator, Frankel, Bionator)

Pancherz H & Fackel U
EJO 12:209-218, 1990

On a long term basis, Herbst treatment improved the sagittal jaw base relationship, but did not normalize it. The sagittal dental arch relationship, on the other hand, was almost normalized.

Hansen K & Pancherz H
EJO 14:285-295, 1992

■ Fig. 7:

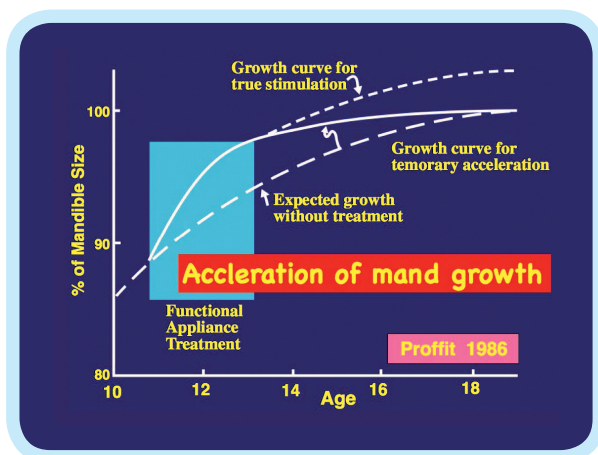
Functional appliances can hardly change the inherited mandibular morphogenetic pattern.

■ Fig. 8:

Functional appliance: Herbst appliance can only normalize the dentition relationship. However, it cannot normalize the intermaxillary relationship.

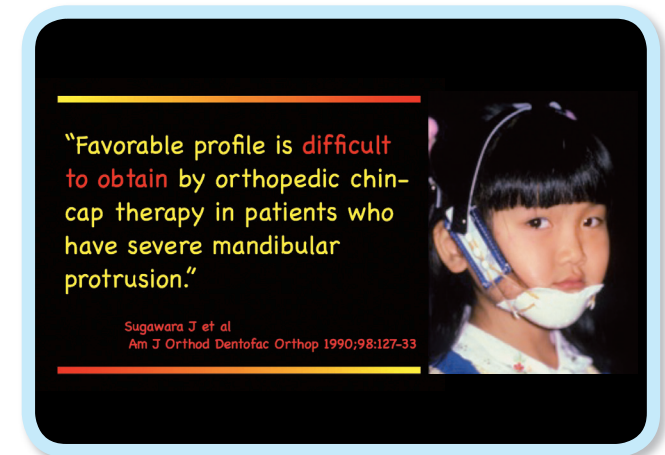Orthopedic Correction: Chin Cap for Class III Treatment?

In a short term, a chin cap can change the direction of the mandibular growth, but the favorable changes are not usually maintained at the end of the growth phase¹³ (Fig. 10). This scenario is similar to fixed functional appliances. Pancherz¹⁰ reported that in short term the Herbst treated group had a lot more mandibular growth, compared with control group, but in the long term the overall mandibular growth was about the same as the control group. The data show that there is little growth left after Herbst treatment. On the contrary, the control group continued to grow during the post-treatment retention phase. Overall, the mandibular growth was about the same in the treated and control group. Thus, orthopedic appliances for Class II or III correction do not change growth potential.



■ Fig. 9:

Functional appliances induce only temporarily mandibular growth to achieve Class II correction; the induced mandibular growth cannot exceed its inherited growth potential.



■ Fig. 10

Orthopedic Effect of Early Face Mask Treatment

Sugawara¹⁴ reported an interesting study on the effect of early treatment of identical twins (Figs. 11A & B). One twin was treated early with a face mask and her identical sister was not treated. The treated twin demonstrated more anterior growth of the maxilla than her sister (Figs. 11C & D). In the adolescent period,

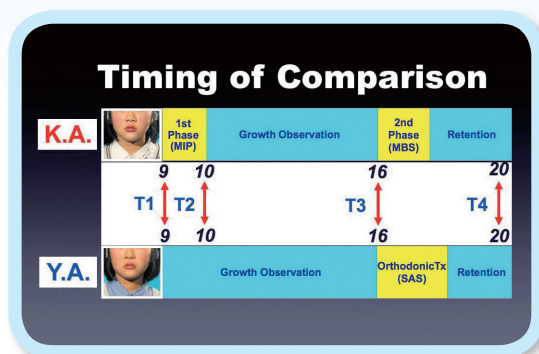


Fig. 11A:

Twin KA has two stage treatment. Twin YA only one stage treatment. (Courtesy Dr. Junji Sugawara)

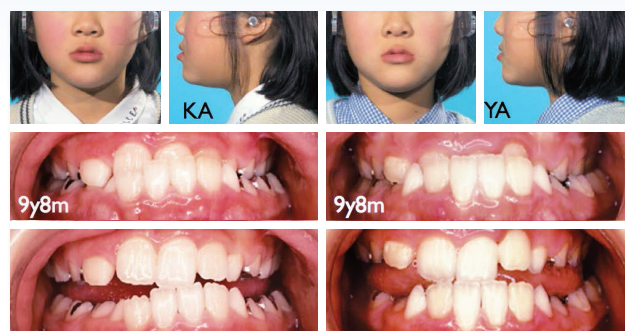


Fig. 11B:

At stage 9 years old, before treatment, both has severe Class III deep bite.

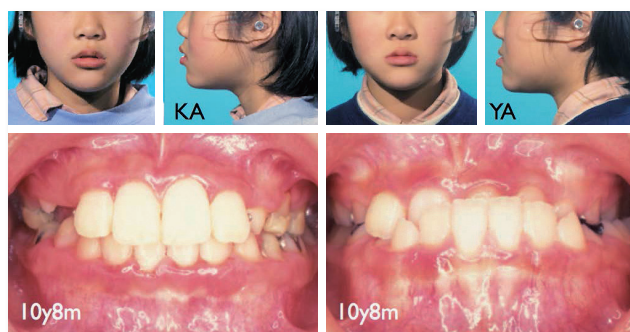


Fig. 11C:

At age 10 years old, KA already had her crossbite corrected, YA received no treatment.

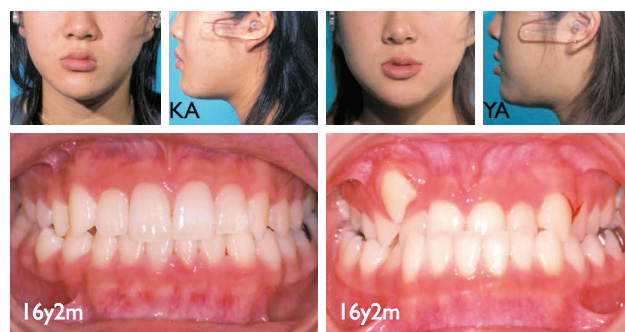


Fig. 11D:

At age 16, KA good overbite and overjet. YA still has anterior crossbite and deep bite overbite.

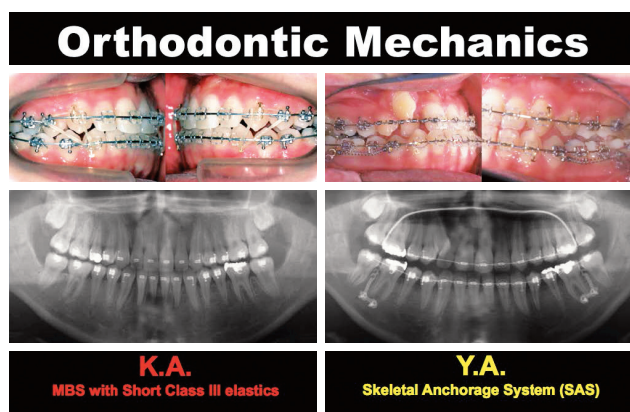


Fig. 11E:

Orthodontic treatment for KA was simply using Class III elastics. YA was finished using the more complicated SAS mini-plate system.

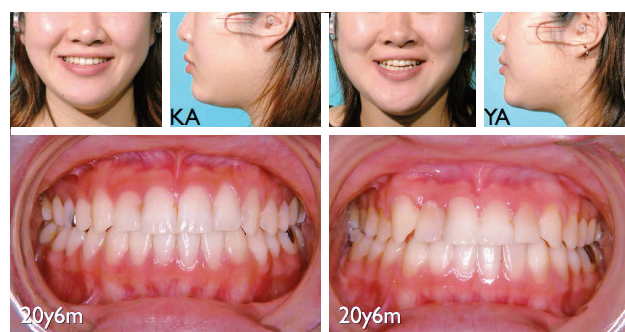
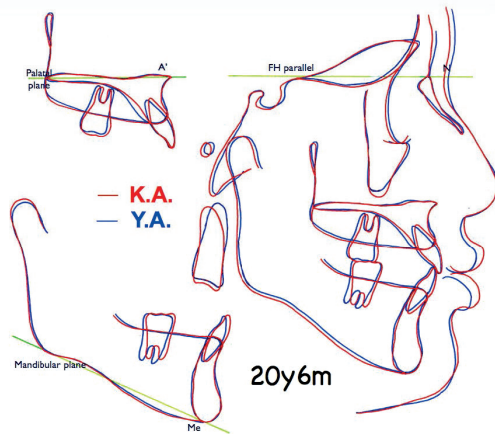


Fig. 11F:

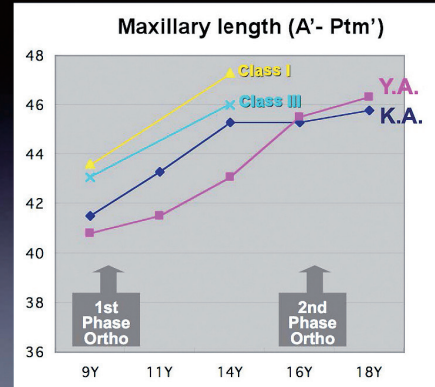
At 20 years old.



■ Fig. 11G:

At 20 years old, the cephalometric superimpositions of the twins, show little difference in the skeletal or dental patterns.

Maxillary Growth Changes



■ Fig. 11H:

After the first phase treatment, KA has much more maxillary growth, but after follow up at 16 years YA has caught up. By 18 years, there is no net difference in the expression of growth.

both twins were treated with fixed appliances (Fig. 11E) to a nearly identical result (Fig. 11F). In the late growth period, the control twin demonstrated catch up growth of the maxilla, and at the end of the active growth period, there was no difference between the twin sisters (Fig. 11G). A plot of maxillary growth changes in the sagittal plane shows there was no net difference in the total maxillary growth achieved, but the twin who received early treatment did express her growth sooner (Fig. 11H).

Interception Harmonize >> Normalize

Young patients who are diagnosed early with this problem can be treated orthopedically with a chin cap or protraction facemask to **normalize** the underlying skeletal discrepancy.

Burns NR, Musich DR, Martin C, Razmus T, Gunel E, Ngan P. Class III camouflage treatment: what are the limits? Am J Orthod Dentofacial Orthop. 2010 Jan;137(1):9.e1-9.e13; discussion 9-11.

■ Fig. 12:

Burns et al. thought early diagnosis of a Class III patient could lead to orthopedic treatment to normalize the skeletal discrepancy. In fact we cannot intercept Class III growth or normalize the developmental pattern. What we can do is harmonize the interdental relationship for mild malocclusions.

What We Can Learn From This Twin Study:

- (1) Although the anterior crossbite was not corrected early for YA, the original profile was maintained, and there was no deterioration into a severe, skeletal Class III malocclusion, that required surgical correction. These observations do not support the concept that early Class III treatment “*intercepts the developing Class III growth pattern.*” It appears that early treatment to correct the anterior crossbite is an option, that does not change the overall growth pattern (Fig. 12).
- (2) The original CO profile was somewhat prognathic, due to large functional shift, so the original CR profile is expected to be more orthognathic. Unfortunately no CR facial profile photographs were reported, underlining the importance of these diagnostic records at the first visit. Early correction was not necessary for YA’s malocclusion. As for her twin sister KA, early correction of the crossbite was an option, but it is unrealistic to expect a change in the overall growth expression. YA was readily treated with one phase of treatment when she was an adolescent. These data conflict with the traditional “*developing Class III*” concept that suggests that early crossbite correction will “*normalize growth.*”
- (3) Fig. 11H demonstrates enhanced maxillary growth, associated with early treatment, but the advantage is lost, compared to one phase of fixed appliance treatment, during the late phase of growth. Thus, from a skeletal perspective, there is no net advantage for early treatment (Figs. 11F & G).
- (4) Despite the lack of a net skeletal advantage, early treatment of the crossbite has clear esthetic and functional benefits (Fig. 11C). This may be the desired option of the patient and her family, but it offers no clear advantage for the final result (Fig. 11D).

Normalizing Jaw Growth Is Not Realistic

Burns et al.¹⁵ promote early treatment of the Class III malocclusion, with a chin cap or protraction face mask, to normalize the underlying skeletal growth discrepancy. However, the Pancherz Herbst Class II study¹¹ and the Sugawara¹⁴ face mask Class III report, both show that one phase treatment during the adolescent growth spurt is just as effective as two phases of treatment. Furthermore, Pancherz’s^{10,11} long term follow up of Class II patients, treated with a Herbst appliance, concluded that the fixed functional appliance improved the sagittal apical base relationship, but the treatment did not normalize the sagittal jaw base relationship.

Sugawara’s¹³ long term effects of chin cap therapy on Class III patients showed a favorable short term change, that was often not maintained at the end of growth. Long term follow up of rapid maxillary expansion combined with face mask protraction therapy in the mixed dentition revealed that about 25-33% of the growth enhancement relapses.¹⁶⁻¹⁹ This means that the overall expression of growth cannot be changed. These data suggest that normalization of growth, due to an early phase of treatment, is unlikely.

References

1. Tweed CH. Clinical Orthodontics. St. Louis: CV Mosby; 1966. p. 716.
2. Moyers RE. Handbook of Orthodontics. 4th ed. Chicago: Year Book Medical Publishers Inc; 1988. p. 413-14.
3. Graber TM. Current Orthodontic Concepts and Techniques. Philadelphia: W. B. Saunders; 1969. p. 928- 29.
4. Jarabak JR, Fizzel JA. Techniques and Treatment with Lightwire Edgewise Appliance. 2nd ed. St Louis: CV Mosby; 1972. p. 214.
5. Björk A. Timing of interceptive orthodontic measures based on stages of maturation. Transactions of the European Orthodontic Society 1972;64-74.
6. Thilander B, et al. Roentgen-cephalometric standards for a Swedish population. A longitudinal study between the ages of 5 and 31 years. Eur J Orthod 2005;27(4):370-89.
7. Cohen AM. A study of class II division 1 malocclusions treated by the Andresen appliance. Br J Orthod 1981;8(3):159-63.
8. Mills JRE. Clinical control of craniofacial growth: a skeptic's viewpoint. In McNamara JA, Ribbons KA, Howe RP, editors. Clinical alterations of the growing face. z Monograph 14, Craniofacial Growth Series. Michigan: Center for Human Growth and Development, University of Michigan; 1983. p 17-31.
9. Sahm G, Bartsch A, Witt E. Micro-electronic monitoring of functional appliance wear. Eur J Orthod 1990;12(3):297-301.
10. Pancherz H, Fackel U. The skeletofacial growth pattern pre- and post-dentofacial orthopaedics. A long-term study of Class II malocclusions treated with the Herbst appliance. Eur J Orthod 1990;12(2):209-18.
11. Hansen K, Pancherz H. Long-term effects of Herbst treatment in relation to normal growth development: a cephalometric study. Eur J Orthod 1992;14(4):285-95.
12. Proffit WR. Contemporary Orthodontics. 2nd ed. St Louis: CV. Mosby; 1993. p. 233.
13. Sugawara J, Asano T, Endo N, Mitani H. Long-term effects of chincap therapy on skeletal profile in mandibular prognathism. Am J Orthod Dentofacial Orthop 1990;98(2):127-33.
14. Sugawara J, et al. Long-term effects of chincap therapy on skeletal profile in mandibular prognathism. Am J Orthod Dentofacial Orthop 1990;98(2):127-33.
15. Burns NR, Musich DR, Martin C, Razmus T, Gunel E, Ngan P. Class III camouflage treatment: what are the limits? Am J Orthod Dentofac Orthop 2010;1379(1):9e1-9; discussion 9-11.
16. Hägg U, et al. Long-term follow-up of early treatment with reverse headgear. Eur J Orthod 2003;25(1):95-102.
17. Westwood PV, et al. Long-term effects of Class III treatment with rapid maxillary expansion and facemask therapy followed by fixed appliances. Am J Orthod Dentofacial Orthop 2003;123(3):306-20.
18. Wells AP, et al. Long-term efficacy of reverse pull headgear therapy. Angle Orthod 2006;76(6):915-22.
19. Masucci C, et al. Stability of rapid maxillary expansion and facemask therapy: a long-term controlled study. Am J Orthod Dentofacial Orthop 2011;140(4):493-500.

