

# A treatment of a bimaxillary protrusion case with canine substitution and impacted third molar uprighting

## History And Etiology

This female adult, aged 34 years 5 months, came for orthodontic evaluation. Her chief concern was dissatisfaction with her smile (Fig. 1). There was no contributory medical or dental history. Clinical exam revealed an upper left lateral incisor missing and anomalous morphology of the upper right lateral incisor. Her lower first molar had deep caries with defective crown (Figs. 2-3). After 44 months of orthodontic treatment, the patient was treated to an acceptable result as documented in Figs. 4-9. The details for diagnosis and treatment will be discussed below.

## Diagnosis

### Skeletal:

1. Skeletal Class II (SNA 82°, SNB 78°, ANB 4°)
2. Mandibular plane angle (SN-MP 42°, FMA 36°)

### Dental:

1. Class II molar malocclusion (*left*)
2. The overbite and overjet were both 5mm. (*from upper right central incisor to lower right central incisor*)
3. Severe crowding in both arches
4. Anomalous morphology of maxillary right lateral incisor.
5. Maxillary left lateral incisor missing.
6. Deep caries over mandibular left first molar.

### Facial:

Convex profile with protrusive lip position.



Fig. 1: Pretreatment facial photographs

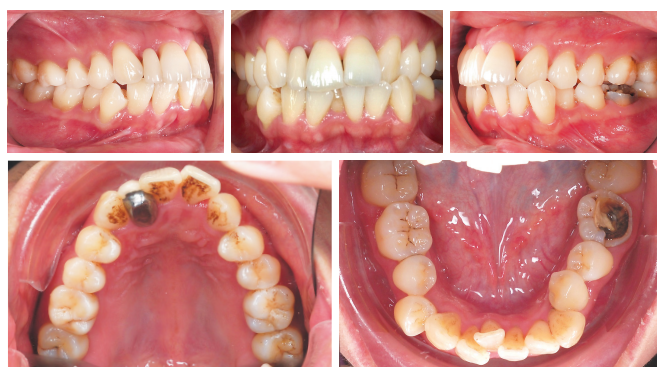

Fig. 2: Pretreatment intraoral photographs

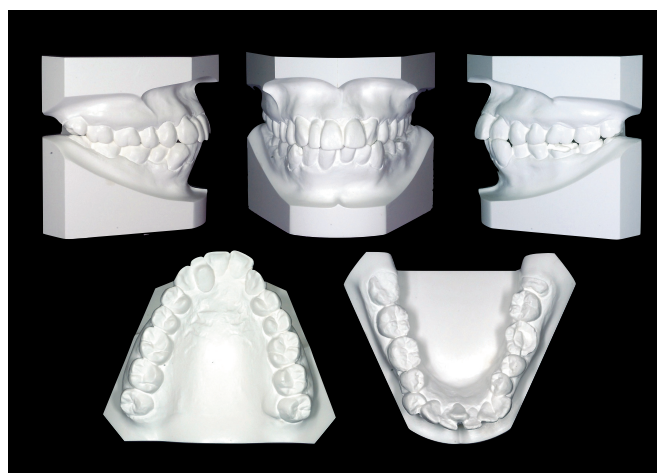
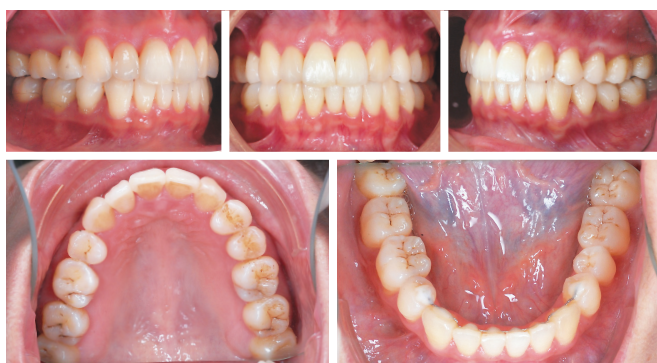
Fig. 3: Pretreatment study models

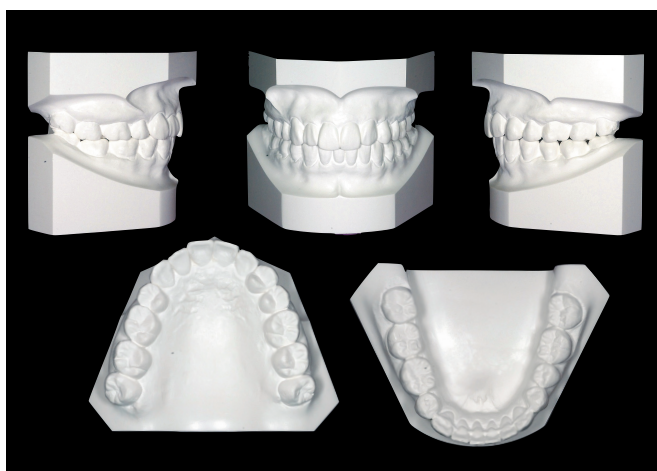Dr. HsinYinYeh, Lecturer, *Beethoven Orthodontic Course* (left)  
 Dr. Chris Chang, Director, *Beethoven Orthodontic Center* (middle)  
 Dr. Eugene W. Roberts, Consultant,  
*International Journal of Orthodontics & Implantology* (right)



■ Fig. 4: Posttreatment facial photographs



■ Fig. 5: Posttreatment intraoral photographs



■ Fig. 6: Posttreatment study models

The ABO Discrepancy Index (DI) was 35, as shown in the subsequent worksheet.

## Specific Objectives Of Treatment

Maxilla (*all three planes*):

- A - P: Maintain
- Vertical: Maintain
- Transverse: Maintain

Mandible (*all three planes*):

- A - P: Maintain
- Vertical: Maintain
- Transverse: Maintain

Maxillary Dentition

- A - P: Retract the maxillary incisors
- Vertical: Maintain
- Inter-molar Width: Maintain

Mandibular Dentition

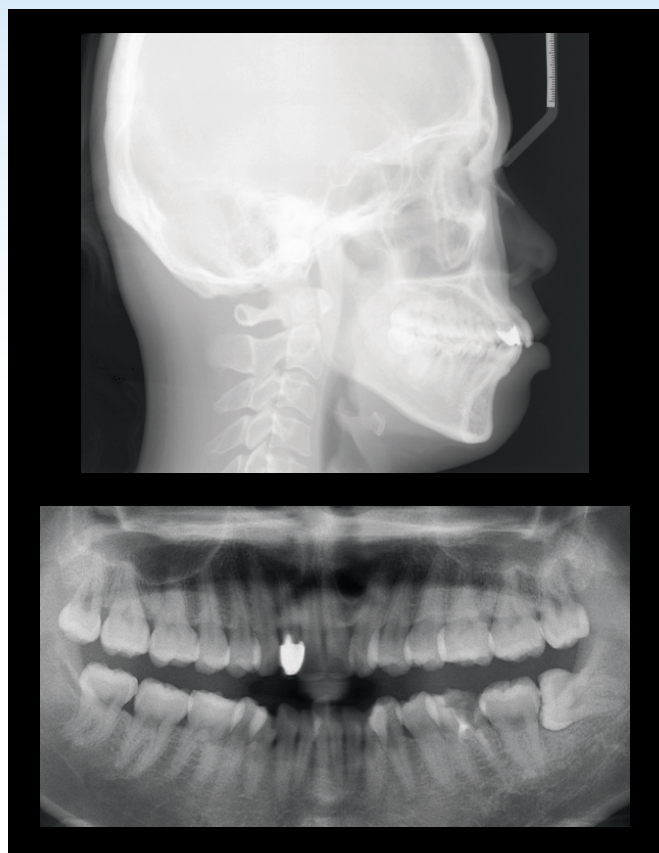
- A - P: Retract the mandibular incisors
- Vertical: Maintain
- Inter-molar / Inter-canine Width: Maintain

Facial Esthetics: Retract protrusive lips

## Treatment Plan

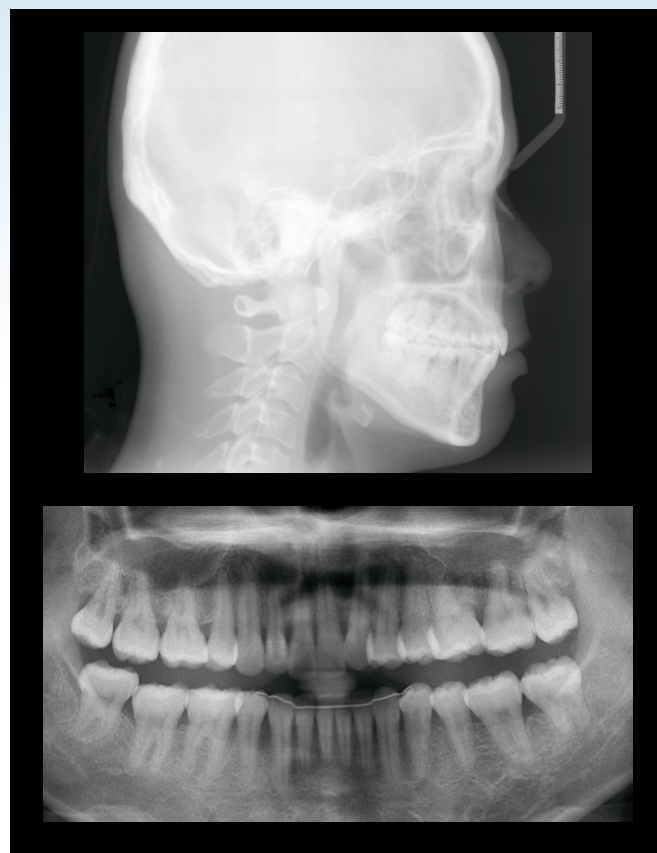
Full fixed orthodontic appliance was indicated to align and level the dentition. Extract maxillary and mandibular right first premolar for crowding release. The maxillary left canine was substituted for the missing maxillary left lateral incisor and the left first premolar replaced the canine. Because the long-term prognosis of the left mandibular first molar





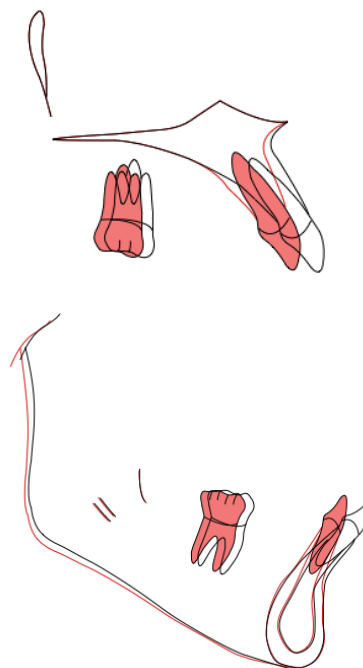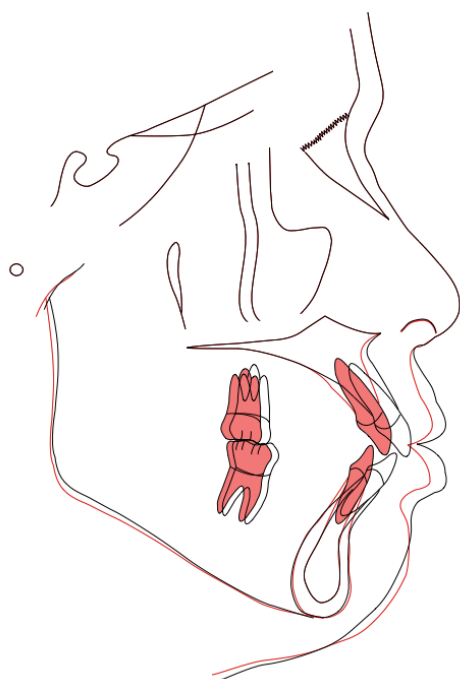■ Fig. 7:

Pretreatment pano and ceph radiographs. The pano film showed a deep caries over the mandibular left first molar and the mandibular left third molar was impacted.

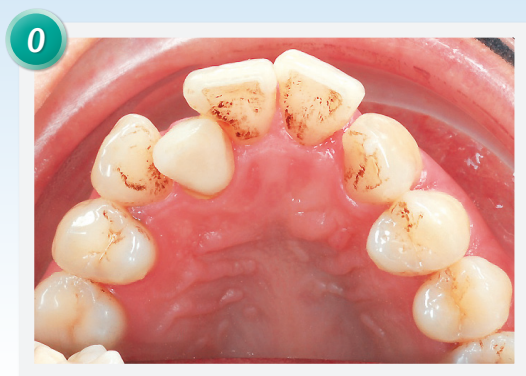

■ Fig. 8:

Posttreatment pano and ceph radiographs. The pano film showed that the impacted mandibular left third molar was upright and well aligned.



■ Fig. 9: Superimposed tracings indicate that both upper and lower central incisors were retracted and the protrusive profile was corrected.



■ Fig. 10:

*A temporary crown was fabricated for the palatally impacted maxillary right lateral incisor.*

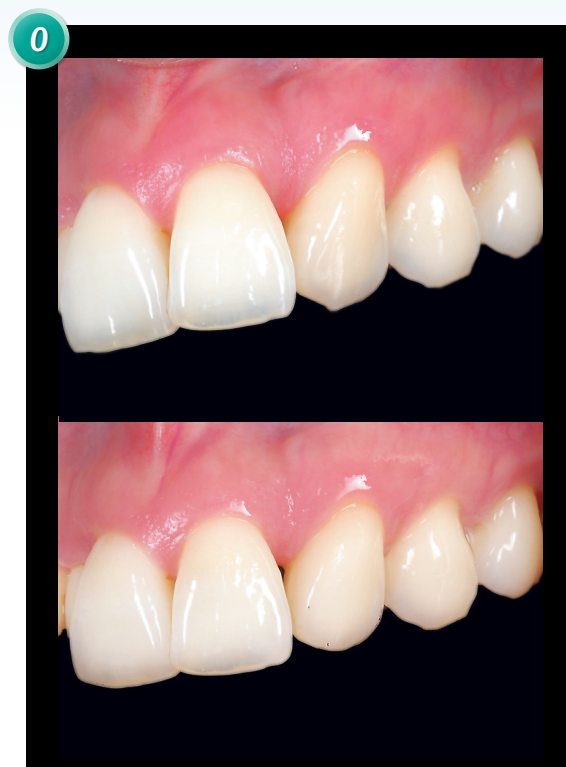was questionable, extract the first molar rather than the first premolar. To close the extraction space of mandibular left first molar, protract the second molar and upright the impacted third molar.

An open coil spring was used to create the space for maxillary right lateral incisor and post-treatment restoration with a porcelain crown would be applied on this anomalous morphology tooth. To correct the convex profile, four extra-alveolar miniscrews (2x12mm, OrthoBoneScrew, Newton's A, Inc.) were inserted in both sides of infrazygomatic crests and buccal shelves of mandibular first molar as anchorage for retracting the dentitions. Detailing bends produced the final occlusion. The fixed appliances were removed and the corrected dentition was retained with fixed anterior retainers in lower anterior teeth and clear overlay retainer on upper arch.

## Appliances And Treatment Progress

At the start of the treatment, the patient was referred to a general dentist to extract the maxillary and mandibular right first premolar. After that, the crown of the maxillary right lateral incisor was removed

and restored with a temporary crown made with normal size of maxillary lateral incisor (Fig. 10). Before applying fixed appliances, re-contour the prominent labial ridge and cusp tip of maxillary left canine to imitate lateral incisor (Fig. 11).

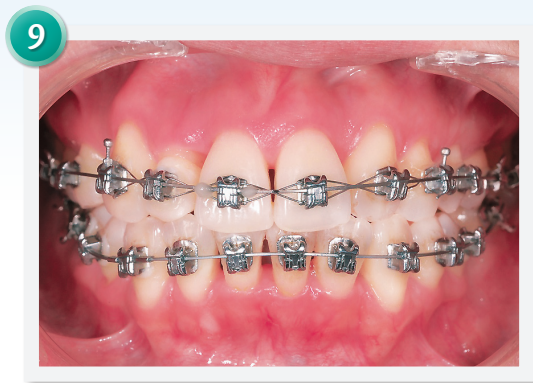

■ Fig. 11:

*Reshape the cusp tip and labial ridge of the maxillary left canine before bonding.*

.022" Damon D3MX brackets (Ormco corporation) were bonded on both arch (low torque on anterior teeth but high torque on the maxillary left canine). The wire sequence was: .014 NiTi, .018 NiTi, .014x.025 NiTi, .017x.025 TMA, .016x.025 SS. Open coil springs were used for space opening. One was placed between maxillary right central incisor and canine to open the space for palatally displaced lateral incisor and another was placed between mandibular left central incisor and right lateral incisor for lingually displaced right central incisor. Two months later, these displaced teeth were bonded with brackets.

After alignment, interproximal enamel reduction was performed in upper and lower incisors to lessen the black triangle area (Fig. 12).

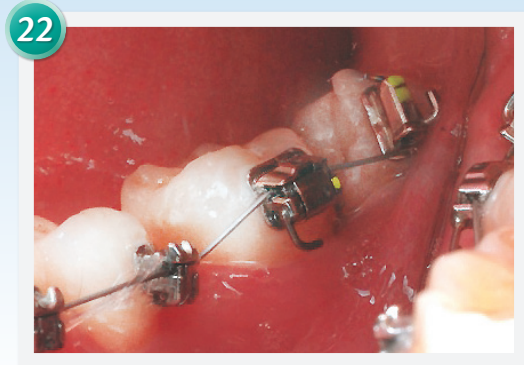

■ Fig. 12:

After alignment, black triangle areas between incisors were found. Interproximal enamel reduction can reduce the spaces for esthetics.

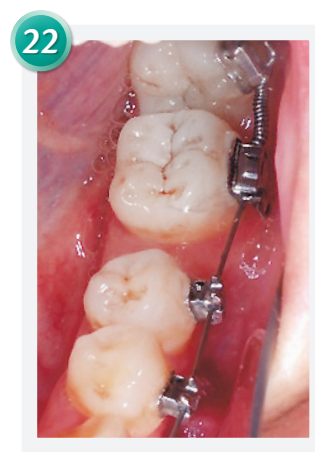22 months after the active treatment, the impacted mandibular left third molar erupted. A buccal tube was bonded on this third molar and the second molar was rebonded with a cover-lifting buccal tube (Fig. 13). This cover-lifting buccal tube made an open coil spring to be easily inserted between the second and third molar (Fig. 14). Eight months later, the third molar was uprighted. Two buttons were separately bonded on the mandibular second premolar and third molar, and a power chain was hung on these buttons to close the extraction space (Fig. 15). After all the spaces were closed, extra-alveolar miniscrews were inserted in both sides of infrazygomatic crests and buccal shelf of mandibular first molars to retract upper and lower dentition. A torquing spring was applied to correct the labial crown torque of right lateral incisor (Fig. 16).

After 44 months of active treatment, all appliances were removed. A upper clear overlay and lower fixed anterior retainer were delivered for lower arch.



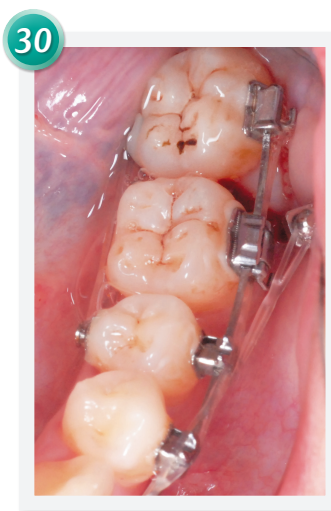
■ Fig. 13:

A cover-lifting buccal tube was bonded on mandibular left second molar and a buccal tube was bonded on third molar. A .018 NiTi archwire was used.



■ Fig. 14:

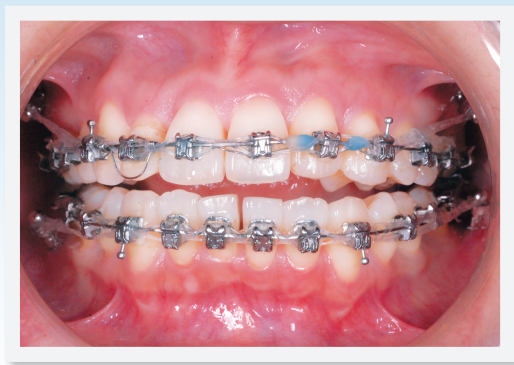An open coil spring was inserted between the second and third molar to upright the impacted third molar and push the second molar forward at the same time.



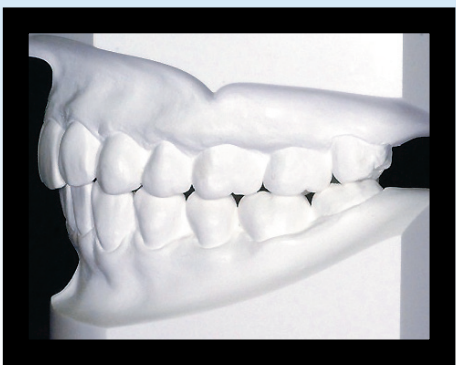■ Fig. 15:

Buttons were bonded on the third molar and second premolar with a power chain connecting them. This lingual force could facilitate space closing and prevent the third molar from lingual rotation and mesial tilting.





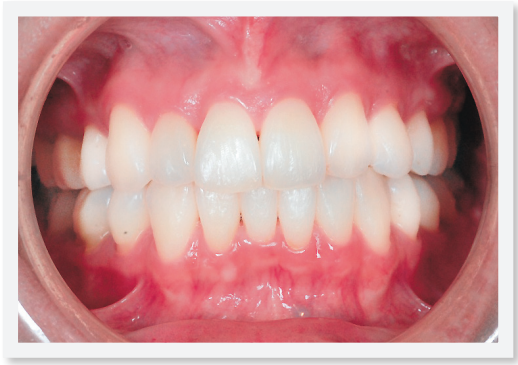**Fig. 16:**  
*Four extra-alveolar miniscrews were used as anchorage to retract dentitions. A torquing spring which produces a lingual crown torque corrected the labial crown torque of maxillary right lateral incisor.*



**Fig. 17:**  
*The occlusal relationship of the left side was not optimum because of asymmetric extraction.*

**Retention**

The fixed retainer was bonded from second premolar to second premolar in the mandibular arch. An upper clear overlay was delivered. The patient was instructed to wear it full time for the first 6 months and nights only thereafter. The patient was instructed in the home care and maintenance of the retainers.



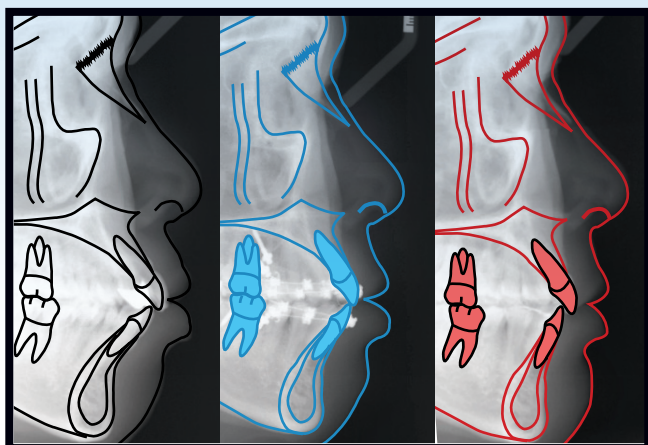
**Fig. 18:**  
*The midline of lower arch was 2mm to the left. The maxillary right lateral incisor was restored with porcelain crown and the maxillary left lateral incisor was replaced by canine.*

**Final Evaluation Of Treatment**

The ABO Cast-Radiograph Evaluation score was 26 points. The major discrepancies were in occlusal relationships and marginal ridges. Because of asymmetric extraction, the occlusal relationship of left side was not in ideal position and the midline of lower arch was 2mm to left (Figs. 17-18). The extraction space of left mandibular first molar area was closed and the impacted third molar was well aligned. The palatally displaced maxillary lateral incisor was restored with porcelain crown. The maxillary left canine substitution looked natural but the level of gingival margin was higher than the central incisor (Fig. 18).

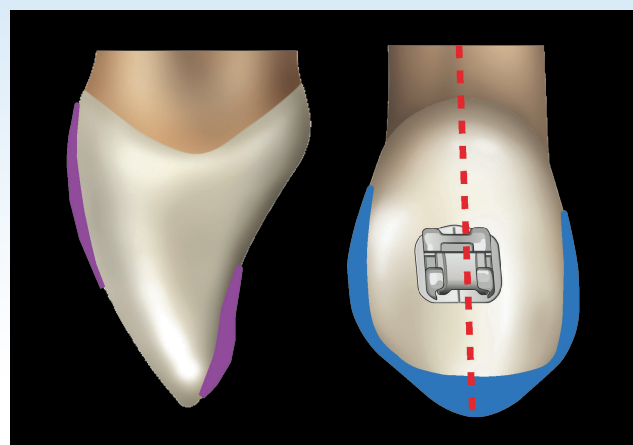
CEPHALOMETRIC			
SKELETAL ANALYSIS			
	PRE-Tx	POST-Tx	DIFF.
SNA°	82°	81°	1°
SNB°	78°	78°	0°
ANB°	4°	3°	1°
SN-MP°	42°	40°	2°
FMA°	36°	35°	1°
DENTAL ANALYSIS			
U1 TO NA mm	7 mm	2 mm	5 mm
U1 TO SN°	111°	109°	2°
L1 TO NB mm	10 mm	3 mm	7 mm
L1 TO MP°	102°	85°	17°
FACIAL ANALYSIS			
E-LINE UL	2 mm	-1 mm	3 mm
E-LINE LL	5 mm	1 mm	4 mm

■ Table. Cephalometric summary



■ Fig. 19:

Tracings of pre-treatment, the appointment of extra-alveolar miniscrews inserted, post-treatment. The protrusive profile was corrected.



■ Fig. 20:

Recontour the labial ridge, palatal surface, and cusp tip of canines before bonding a bracket. Bond the bracket distally to imitate lateral incisor crown torque. Reduce the interproximal area if the M-D dimension of canine is much wider than lateral incisor.

The protrusive upper and lower incisors were resolved and the convex profile was subsequently corrected (Fig. 19). Overall, the patient was satisfied with this treatment.

## Discussion

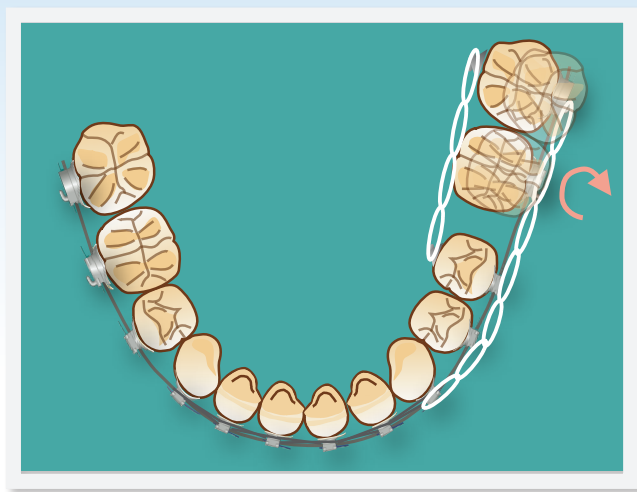Patients with missing teeth will make the orthodontic treatment more complicated. Maxillary lateral incisors are often anomalous or congenitally missing. Because mandibular first molars erupt at the age of 6, they are prone to have dental caries. It is common to see the mandibular first molars extracted or endodontic treatment in adults. There are many treatment options for replacement of missing teeth, including space closing with substitution of adjacent tooth, single tooth implants, and tooth-supported restorations. In this case, we had the treatment plan with the least restoration after finishing orthodontic treatment.

Conventional space closure with canine substitution for missing maxillary lateral incisor is a safe

procedure that provides satisfactory esthetic and functional long-term results. Single tooth implant-supported restorations, the thickness of alveolar ridge over the lateral incisor area must be adequate.<sup>1</sup> According to studies,<sup>2-3</sup> if a permanent canine is orthodontically moved distally, an increased dimension of buccolingual alveolar width is stable. To this patient, based on her convex profile, and severe crowding of lower arch, we made the treatment plan with extraction of upper and lower right first premolar and first molar and the upper left first premolar was used to canine substitution. Then this patient did not need any implants on her maxillary anterior side.

The technique of canine substitution, according to some studies,<sup>1,4-7</sup> includes:

1. Mesial relocate canines to imitate the lateral incisor crown torque (*bond distally*) (Fig. 20).
2. Recontouring of prominent labial ridge and cusp tip of canines before bonding a bracket (Fig. 20).



■ Fig. 21:

*The lingual force can facilitate the process of extraction space closure and prevent mandibular second and third molar tilting and rotation.*

3. Individualized extrusion and intrusion of the canine and first premolar for optimal level of marginal gingival contours.
4. Reshaping and composite resin buildup of canine and first premolar to resemble lateral incisor and canine. To yellowish or dark canines, bleaching or porcelain veneer could be considered.
5. Reshape or restore central incisors to make more optimal display of smile arc.

Brough et al's study<sup>6</sup> ranked the smile attractiveness by judging the photographs of canine substitution with digitally altering the canine morphology and gingival height. If the canines were 10 times brighter, 1.5mm narrower, with less pointed tips than original canines, the smiles were perceived as more attractive. Canine gingival height was the most attractive 0.5mm below the gingival margin of the maxillary central incisor, but was perceived as relatively unattractive 0.5mm above. In this case, extrusion of the canine was not performed

because extensive enamel reduction might lead to tooth sensitivity. The post-treatment intra-oral photo shows that the marginal gingival contour of maxillary left canine was higher than central incisor, but it was acceptable when the patient smiled (Fig. 4). Zachrisson<sup>7</sup> suggested that extrusion of the canine can resolve the higher gingival contour and excessive occlusal contact of extruded canines should be corrected by increasing lingual root torque and grinding their lingual surfaces.

Different extraction sites will increase the complexity of orthodontic treatment.<sup>8</sup> However, patients might get the benefit from extraction of questionable prognosis molars rather than extraction of healthy premolars. The treatment plan to this patient was extraction of the left mandibular first molar instead of the first premolar. According to Williams and Hosila,<sup>9</sup> the chance of successful third molar eruption is much higher when the first molars were extracted. In this case, 22 months after extraction of the first molar, the impacted third molar auto-erupted. A cover-lifting tube was used to replace the buccal tube of second molar and a normal size buccal tube was bonded on the third molar. An open coil spring was activated between the tubes of two molars. There was no auxiliaries required to upright impacted third molars.<sup>10</sup> If the crown of the impacted third molar is insufficiently exposed and the patient wants to finish the treatment earlier, surgical exposure will be considered.<sup>10</sup>

About ten months later, the impacted third molar was aligned into the lower arch. Another challenge of first molar extraction case is space closure. During the period of protracting the second and third molar for space closing, the second and third molar have a tendency to tilt mesially and roll lingually. Sandler et al<sup>13</sup> advise that active space closure should not be

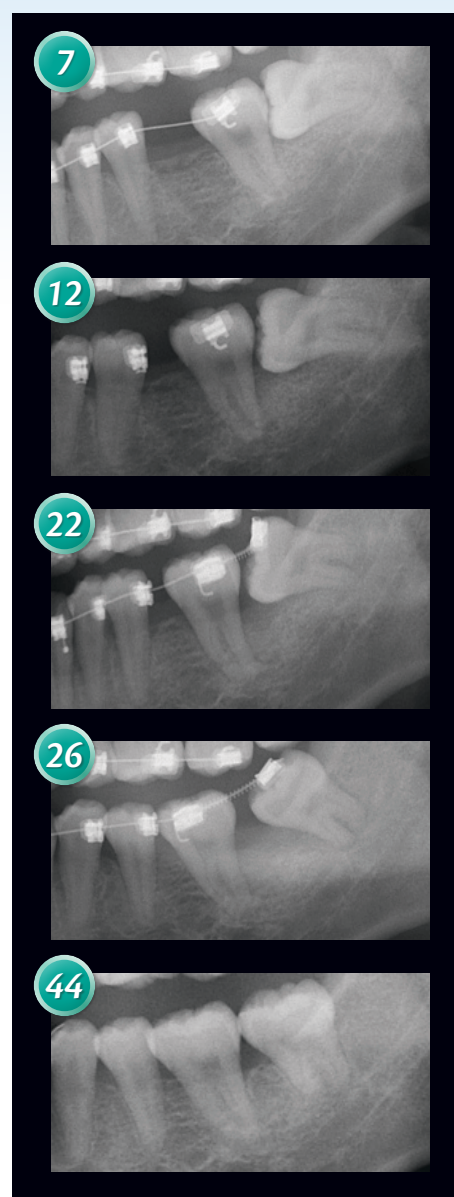


attempted before the lower teeth are well aligned and in full-sized working arch wire. A .016x.025 stainless steel archwire was placed in lower arch. Balancing lingual force was applied by a power chain and two buttons bonded on lingual surface of third molar and second molar. This lingual force can facilitate the process of extraction space closure and prevent mandibular second molar tilting (Fig. 21). In many first molar extraction cases, the total treatment time is determined by the time taken to upright the impacted third molar and bring both the lower second and third molar into a good occlusal position (Fig. 22).

First molar extraction treatment is likely to have less effect on the profile than premolar extraction.<sup>9</sup> After all spaces closed, extra-alveolar miniscrews were used as anchorage to retract the whole dentition. The superimposed tracing indicated significant improvement of protrusive lips (Fig. 19).

## Conclusion

Adults presenting with missing maxillary lateral incisors or anterior crowding but not getting proper orthodontic treatment who only accept restorations, will have compromised esthetic and periodontal results. Orthodontic treatment with canine substitution or space development for restorative replacement is an ideal option for patients. Canine substitution can provide functional long-term results and acceptable esthetic. Another common missing tooth in adults is mandibular first molar. There are many other clinical situations in mandibular first molars such as extensively caries, heavily filled, and endodontic treated with apical lesion. Extraction of these poor long-term prognosis first molars rather



■ Fig. 22:

*Panoramic films indicate the third molar was uprighted and well aligned.*

than healthy first premolars should be considered in orthodontic treatment. Moreover, if the patient has available mandibular third molars, they can be protracted to replace second molars. Detailed case assessment must be made before treatment to ensure that the patient can get the most benefits from this treatment.

## Acknowledgment

Thanks to Ms. Tzu Han Huang and Dr. Sean Peng, a prosthodontist, for proofreading this article.

## References

1. Zachrisson BU, Rosa M, Torreskog S. Congenitally missing maxillary lateral incisors: Canine substitution. *Am J Orthod Dentofacial Orthop* 2011;139:434-45.
2. Kokich VO, Kinzer GA, Janakievski J. Congenitally missing maxillary lateral incisors: Restorative replacement. *Am J Orthod Dentofacial Orthop* 2011;139:434-45.
3. Kokich VG. Maxillary lateral incisor implants: planning with the aid of orthodontics. *Int J Oral Maxillofac Surg* 2004;62:48-56
4. Park JH, Okadake S, Sato Y, Akamatsu Y, Tai K. Orthodontic Treatment of a Congenitally Missing Maxillary Lateral Incisor. *J Esthet Restor Dent* 2010;22:297-313
5. Chang CH. Advanced Damon Course No. 3: Canine Substitution, Beethoven Podcast Encyclopedia in Orthodontics 2011, Newton's A Ltd, Taiwan
6. Brough E, Donaldson AN, Naini FB. Canine substitution for missing maxillary lateral incisors: The influence of canine morphology, size, and shade on perceptions of smile attractiveness. *Am J Orthod Dentofacial Orthop* 2010;138:705.e1-705.e9.
7. Zachrisson BU. Improving the esthetic outcome of canine substitution for missing maxillary lateral incisors. *World J Orthod* 2007;8:72-9
8. Saga AY, Maruo IT, Maruo H, Filho OG, Camargo ES, Tanaka OM. Treatment of an adult with several missing teeth and atrophic old mandibular first molar extraction sites. *Am J Orthod Dentofacial Orthop* 2011;140:869-78
9. William R, Hosila L. The effect of different extraction sites upon incisor retraction. *Am J Ortho* 1976;69:388-410.
10. Lin JJ. The Wisdom of Managing Wisdom Teeth: Part 3. Methods of Molar Uprighting. *IJOI* 2011; vol 24: 4-11
11. Lin JJ. The Wisdom of Managing Wisdom Teeth: Part 1. Lower 3<sup>rd</sup> Molar Extraction in Class III Treatment. *News & Trends in Orthodontics* 2011; vol 22: 4-13
12. Lin JJ. The Wisdom of Managing Wisdom Teeth: Part 2. Lower 2<sup>nd</sup> Molars Extraction to Prevent Painful and Risky Extraction of Horizontally Impacted 3<sup>rd</sup> Molars. *IJOI* 2011; vol 23: 4-17
13. Sandler PJ, Atkinson R, Murray AM. Four for sixes. *Am J Orthod Dentofacial Orthop* 2000;117:418-34.
14. Chang CH. Advanced Damon Course No. 4, 5 : DI & CRE Workshop (1)(2), Podcast Encyclopedia in Orthodontics 2011, Newton's A Ltd, Taiwan.
15. Chang C, Roberts WE. Orthodontics, 3D i-Ortho encyclopedia. Taiwan: Newton's A Ltd, 2012

## Discrepancy Index Worksheet

**TOTAL D.I. SCORE** **35**

### OVERJET

0 mm. (edge-to-edge)	=	
1 – 3 mm.	=	0 pts.
3.1 – 5 mm.	=	2 pts.
5.1 – 7 mm.	=	3 pts.
7.1 – 9 mm.	=	4 pts.
> 9 mm.	=	5 pts.

Negative OJ (x-bite) 1 pt. per mm. per tooth =

 Total = **5**

### OVERBITE

0 – 3 mm.	=	
3.1 – 5 mm.	=	0 pts.
5.1 – 7 mm.	=	2 pts.
Impinging (100%)	=	3 pts.

 Total = **2**

### ANTERIOR OPEN BITE

 0 mm. (edge-to-edge), 1 pt. per tooth  
 then 1 pt. per additional full mm. per tooth

 Total = **0**

### LATERAL OPEN BITE

2 pts. per mm. per tooth

 Total = **0**

### CROWDING (only one arch)

1 – 3 mm.	=	
3.1 – 5 mm.	=	1 pt.
5.1 – 7 mm.	=	2 pts.
> 7 mm.	=	4 pts.

 Total = **7**

### OCCCLUSION

Class I to end on	=	
End on Class II or III	=	0 pts.
Full Class II or III	=	2 pts. per side <u>2</u> pts.
Beyond Class II or III	=	4 pts. per side <u>    </u> pts.
	=	1 pt. per mm. <u>    </u> pts.
	=	additional

 Total = **2**

### LINGUAL POSTERIOR X-BITE

 1 pt. per tooth      Total = **0**

### BUCCAL POSTERIOR X-BITE

 2 pts. per tooth      Total = **0**

### CEPHALOMETRICS (See Instructions)

 ANB  $\geq 6^\circ$  or  $\leq -2^\circ$  = 4 pts.

 Each degree  $< -2^\circ$       x 1 pt. =     

 Each degree  $> 6^\circ$       x 1 pt. =     

#### SN-MP

 $\geq 38^\circ$  = **2 pts.**

 Each degree  $> 38^\circ$  4 x 2 pts. = 8
 $\leq 26^\circ$  = 1 pt.

 Each degree  $< 26^\circ$       x 1 pt. =     

 1 to MP  $\geq 99^\circ$  = **1 pt.**

 Each degree  $> 99^\circ$  3 x 1 pt. = 3

 Total = **14**

### OTHER (See Instructions)

Supernumerary teeth	=	
Ankylosis of perm. teeth	=	x 1 pt. = <u>    </u>
Anomalous morphology	=	x 2 pts. = <u>2</u>
Impaction (except 3 <sup>rd</sup> molars)	=	x 2 pts. = <u>    </u>
Midline discrepancy ( $\geq 3$ mm)	=	@ 2 pts. = <u>    </u>
Missing teeth (except 3 <sup>rd</sup> molars)	=	<u>1</u> x 1 pts. = <u>1</u>
Missing teeth, congenital	=	x 2 pts. = <u>    </u>
Spacing (4 or more, per arch)	=	<u>1</u> x 2 pts. = <u>2</u>
Spacing (Mx cent. diastema $\geq 2$ mm)	=	@ 2 pts. = <u>    </u>
Tooth transposition	=	x 2 pts. = <u>    </u>
Skeletal asymmetry (nonsurgical tx)	=	@ 3 pts. = <u>    </u>
Addl. treatment complexities	=	x 2 pts. = <u>    </u>

Identify:

 Total = **5**

### IMPLANT SITE

Lip line : Low (0 pt), Medium (1 pt), High (2 pts) =     

Gingival biotype : Low-scalloped, thick (0 pt), Medium-scalloped, medium-thick (1 pt), High-scalloped, thin (2 pts) =     

Shape of tooth crowns : Rectangular (0 pt), Triangular (2 pts) =     

Bone level at adjacent teeth :  $\leq 5$  mm to contact point (0 pt), 5.5 to 6.5 mm to contact point (1 pt),  $\geq 7$  mm to contact point (2 pts) =     

Bone anatomy of alveolar crest : H&V sufficient (0 pt), Deficient H, allow simultaneous augment (1 pt), Deficient H, require prior grafting (2 pts), Deficient V or Both H&V (3 pts) =     

Soft tissue anatomy : Intact (0 pt), Defective (2 pts) =     

Infection at implant site : None (0 pt), Chronic (1 pt), Acute (2 pts) =     

 Total = **0**

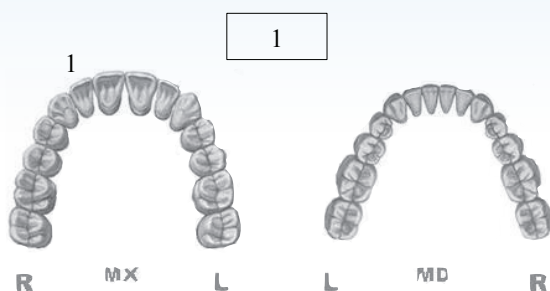


## Cast-Radiograph Evaluation

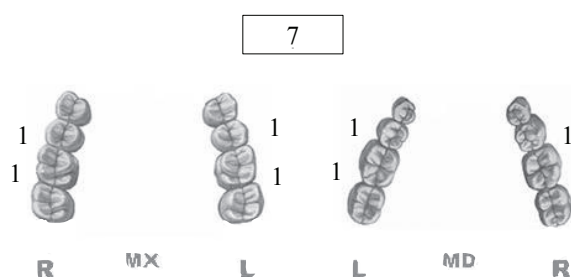
Case # 1 Patient

Total Score: **24**

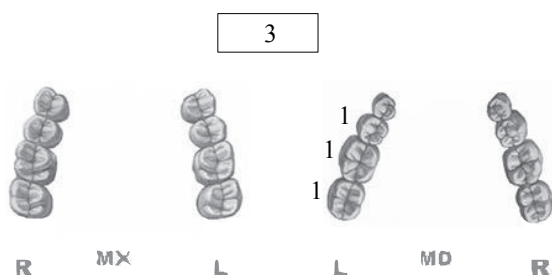
### Alignment/Rotations



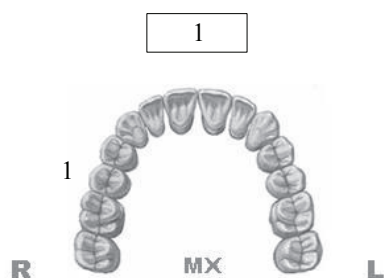
### Marginal Ridges



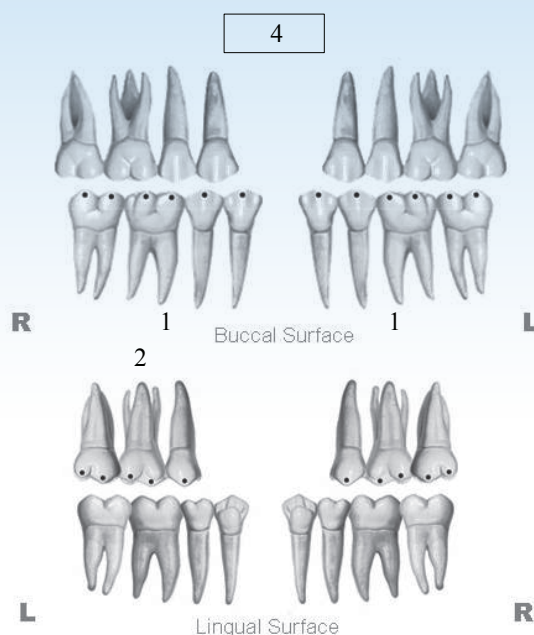
### Buccolingual Inclination



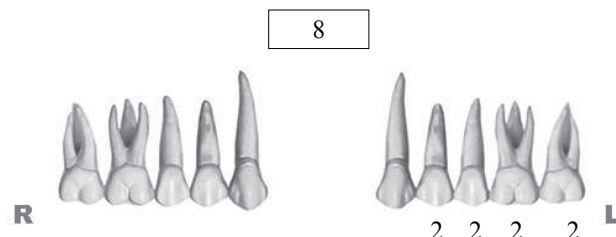
### Overjet



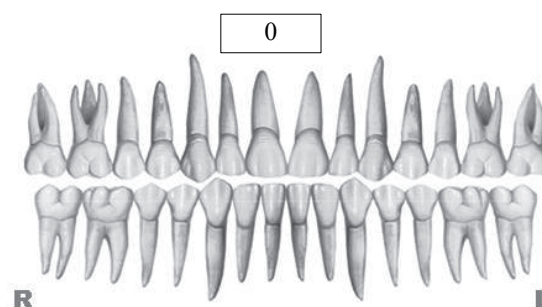
### Occlusal Contacts



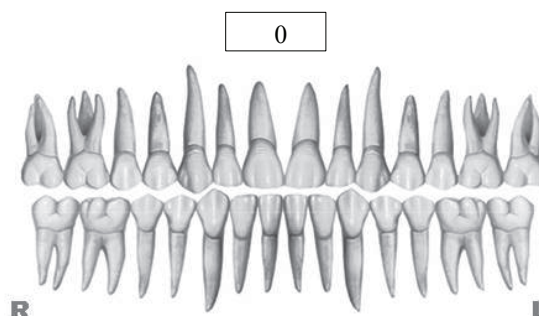
### Occlusal Relationships



### Interproximal Contacts



### Root Angulation



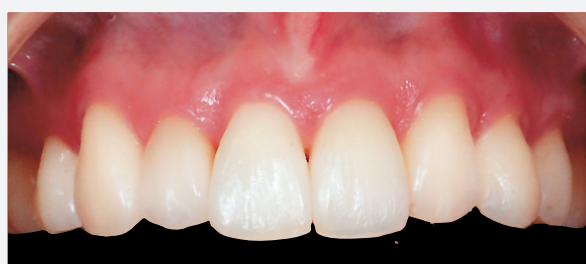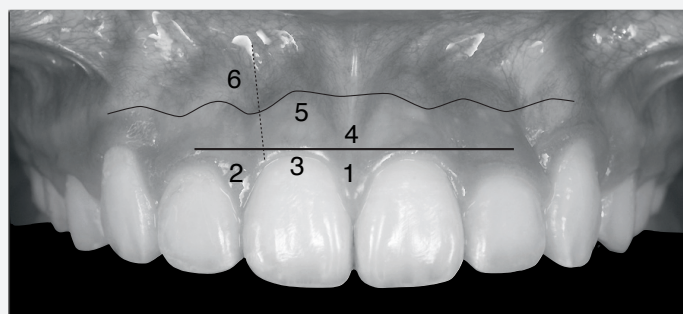
**INSTRUCTIONS:** Place score beside each deficient tooth and enter total score for each parameter in the white box. Mark extracted teeth with "X". Second molars should be in occlusion.

## IBOI Pink & White Esthetic Score

Total Score: =

6

### 1. Pink Esthetic Score



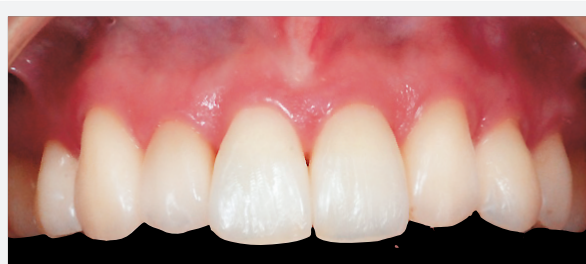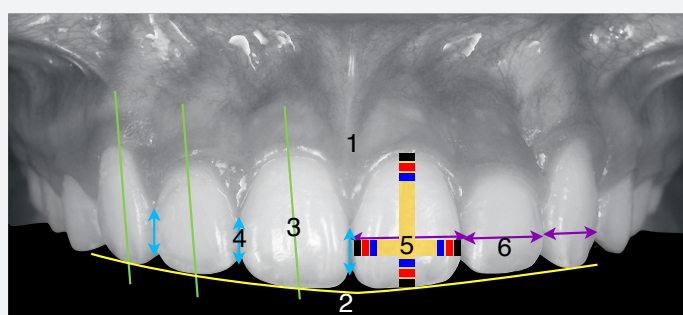
Total =

3

1. Mesial Papilla	0	1	2
2. Distal Papilla	0	1	2
3. Curvature of Gingival Margin	0	1	2
4. Level of Gingival Margin	0	1	2
5. Root Convexity ( Torque )	0	1	2
6. Scar Formation	0	1	2

1. M&D Papilla	0	1	2
2. Keratinized Gingiva	0	1	2
3. Curvature of Gingival Margin	0	1	2
4. Level of Gingival Margin	0	1	2
5. Root Convexity ( Torque )	0	1	2
6. Scar Formation	0	1	2

### 2. White Esthetic Score ( for Micro-esthetics )



Total =

3

1. Tooth Form	0	1	2
2. Mesial & Distal Outline	0	1	2
3. Crown Margin	0	1	2
4. Translucency ( Incisal third )	0	1	2
5. Hue & Value ( Middle third )	0	1	2
6. Tooth Proportion	0	1	2

1. Midline	0	1	2
2. Incisor Curve	0	1	2
3. Axial Inclination (50, 80, 100)	0	1	2
4. Contact Area (50%, 40%, 30%)	0	1	2
5. Tooth Proportion(1:0.8)	0	1	2
6. Tooth to Tooth Proportion	0	1	2