

Hyperdivergent Class III, Open Bite Malocclusion Treated Conservatively

History And Etiology

A 17-year-9-month-old female presented for orthodontic consultation with chief complaints of anterior cross bite, open bite, and irregular dentition. She was previously advised by several orthodontists that surgery was the only viable option for correcting her malocclusion and facial asymmetry (Figs. 1-3). There were no contributing medical, dental or family histories. The etiology of the malocclusion was unknown, but it is probably genetic based on the nature of the malocclusion. The patient was treated to an optimal result as documented in Figures 4-6 without orthognathic surgery, extraoral anchorage or myofunctional therapy. No complex orthodontic appliances, such as rapid palatal expander (RPE) or lingual holding arch, were used. The cephalometric and panoramic radiographs documented the pre-treatment condition (Fig. 7) and the post-treatment results (Fig. 8). The cephalometric tracings before and after treatment are superimposed in Figure 9, and the summary of cephalometric measurements is provided in Table 1.

Diagnosis

Skeletal:

- Skeletal Class I (SNA 84°, SNB 83°, ANB 1°)
- Hyperdivergent mandibular plane angle (SN-MP 46°, FMA 38°)
- Facial asymmetry: mandible deviation to the left

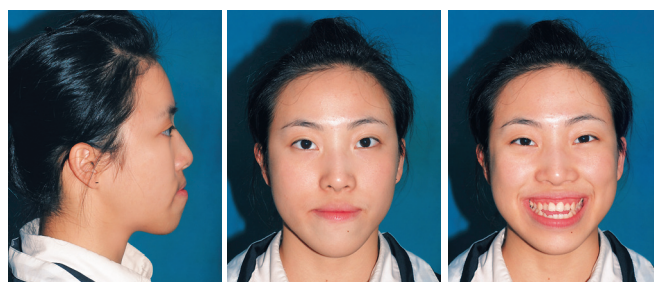


Fig 1: Pretreatment facial photographs

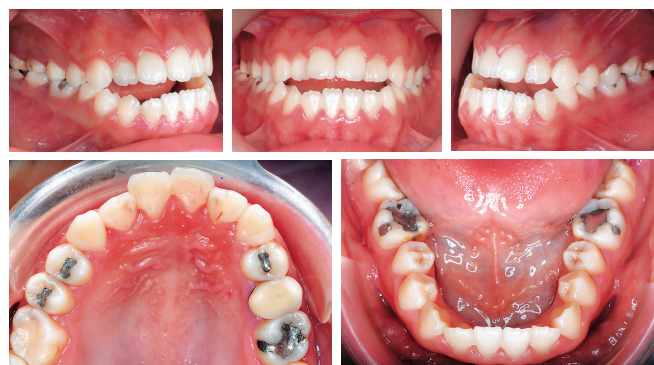


Fig. 2: Pretreatment intraoral photographs

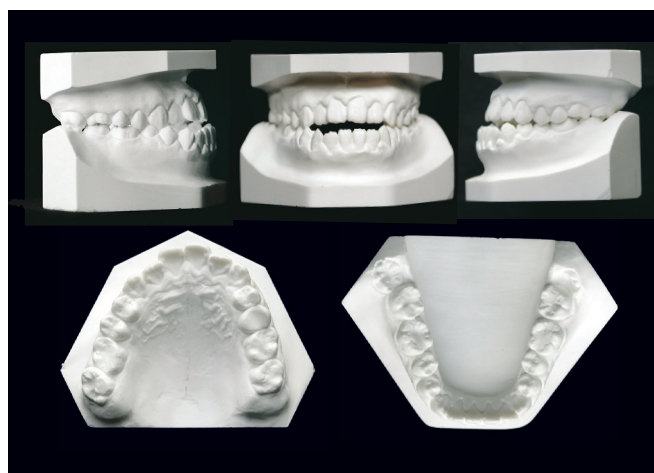
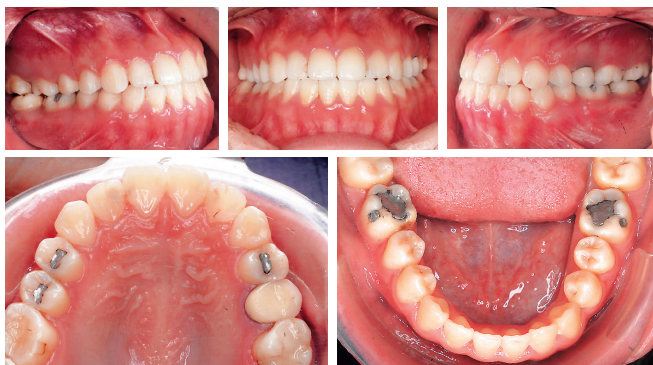
Fig. 3: Pretreatment study models

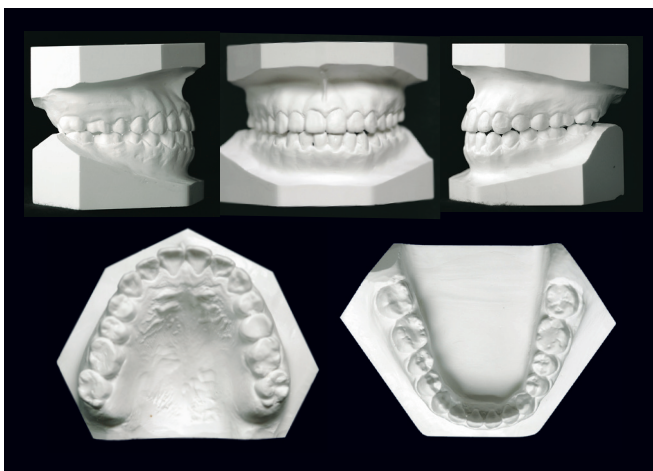
Dr. Ming Chen Lee, Lecturer, Beethoven Orthodontic Course (left)
 Dr. John Jin-Jong Lin, Chief Consultant of IJOI (middle)
 Dr. Eugene W. Roberts, Consultant,
International Journal of Orthodontics & Implantology (right)



■ Fig. 4: Posttreatment facial photographs



■ Fig. 5: Posttreatment intraoral photographs



■ Fig. 6: Posttreatment study models

Dental:

- Bilateral full cusp Class III molar relationship
- Bilateral Class III canine
- In Centric Occlusion the OJ was -3mm, and the OB was -3mm
- 2mm space deficiency in upper arch 1mm space deficiency in lower arch

Facial:

- Moderately convex profile (Fig. 1) Protrusive lower lip

The ABO discrepancy index (*DI*) was 55, as documented in the subsequent *DI* worksheet, which qualifies as a major malocclusion (*DI* >20).

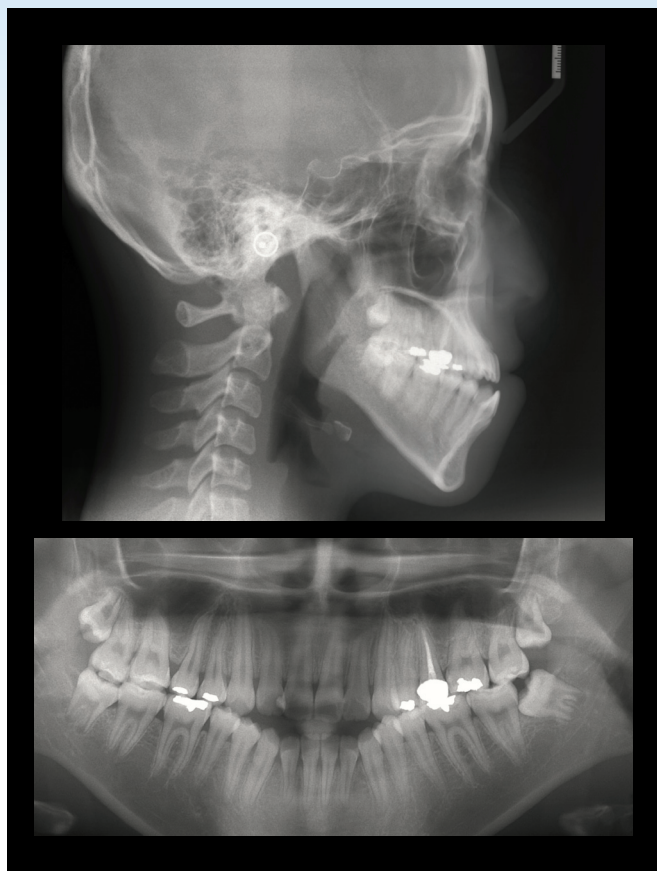
Specific Objectives Of Treatment

The overall objectives of treatment were to achieve a counter-clockwise rotation of the occlusal plane to facilitate the correction of the class III malocclusion, and to retract the mandibular incisors to relieve the negative overjet. The specific treatment objectives were:

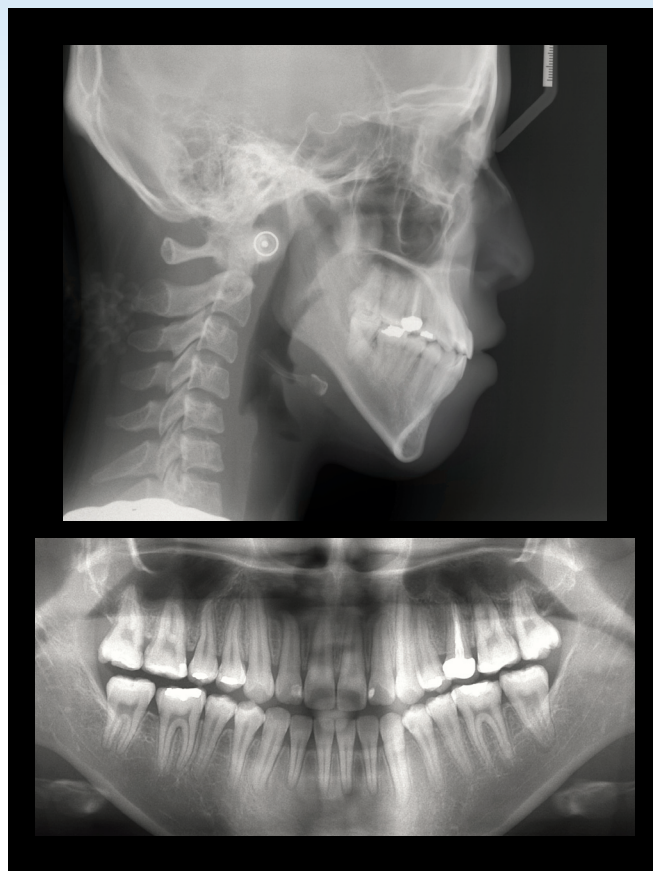
Maxilla (all three planes):

- A - P: Maintain
- Vertical: Maintain
- Transverse: Maintain

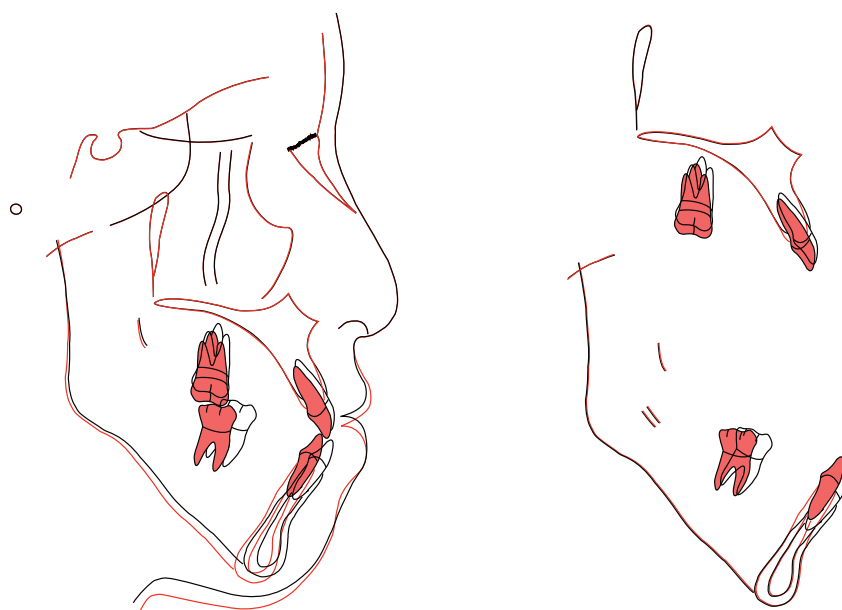
Mandible (all three planes):



■ Fig. 7: Pretreatment pano and ceph radiographs



■ Fig. 8: Posttreatment pano and ceph radiographs



■ Fig. 9:

Superimposed tracings. Superimposition on maxilla revealed retraction and extrusion of anterior teeth, extrusion of molars. The mandible revealed maximal retraction and extrusion of anterior teeth, intrusion and tip back of molars. These contributed to correction of anterior cross-bite and vertical dimension opening.

- A - P: Retract
- Vertical: Modest increase
- Transverse: Maintain

Maxillary Dentition :

- A - P: Retract incisors
- Vertical: Extrude
- Inter-molar / Inter canine Width: Expansion to relieve crowding

Mandibular Dentition:

- A - P: Retract the entire mandibular dentition
- Vertical: Maintain molars and extrude incisors to correct openbite
- Inter-molar / Inter-canine Width: Expansion to relieve crowding

Facial Esthetics:

- Retract lower lip to improve facial balance.

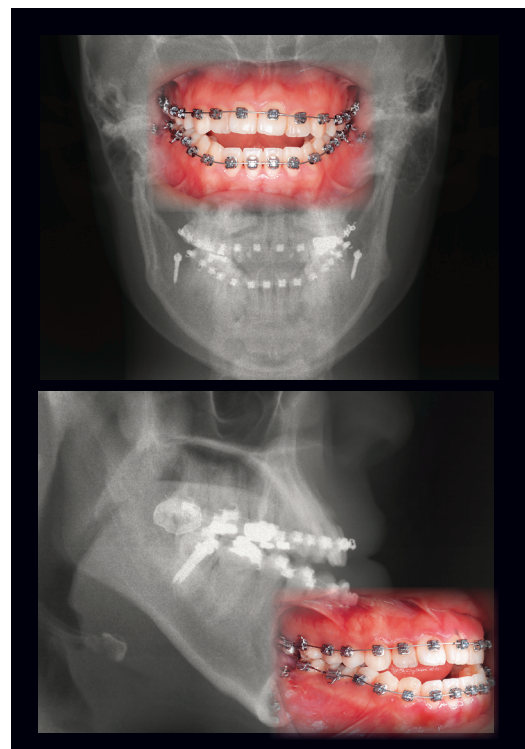
Treatment Plan

Extract all four 3rd molars before orthodontic treatment. The passive self-ligating bracket system (*Damon Q*) was indicated. Bilateral extra-alveolar bone screws (2mmx12mm SS) were inserted in the buccal shelves to serve as osseous anchorage (Figs. 10-11) to resolve the sagittal occlusal discrepancy. Following removal of fixed appliances, the corrected dentition was retained with upper Hawley and lower spring retainers.

Appliances And Treatment Progress

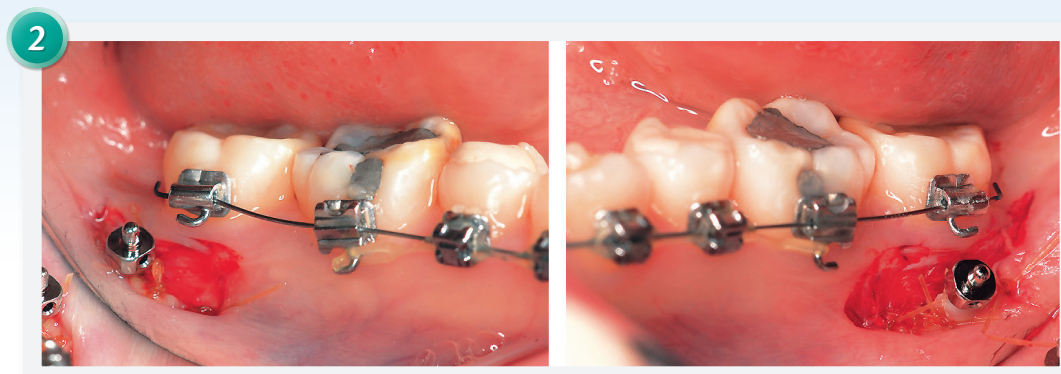
The patient was referred for extraction of all third molars before the start of orthodontic treatment. Low torque brackets, .022" slot Damon Q® (*Ormco*),

were used on the upper arch, and standard torque brackets were bonded on the lower arch. Both arches were initially aligned with .014" CuNiTi arch-wires. In the 1st month of treatment, power chains were applied between the lower first molar and lateral incisors for rotation control (Fig. 12). In the 2nd month, .014x.025" CuNiTi arch-wires were placed, and bone screws (2mmx12mm SS) were installed in the mandibular buccal shelves bilaterally, with apically positioned flap procedures (Fig. 11). The bone screws were used to provide anchorage to retract the entire mandibular dentition while intruding the



■ Fig. 10:

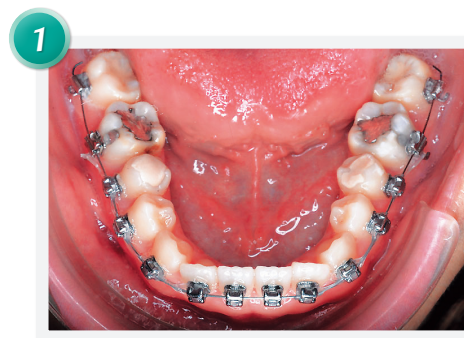2mmx12mm SS bone screws placed 47-46, 36-37 (apically position flap). The PA cephalogram, shows the buccal shelf bone screws were outside the mandibular molar roots, these made the distalization of the whole mandibular dentition possible.



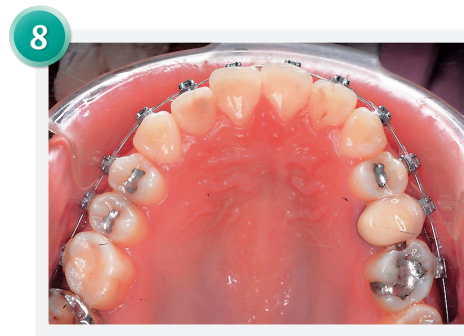■ Fig.11:

The buccal shelf areas had not enough zone of attached gingiva, Two bone screws (2x12mm) were placed with an apically positioned flap around the screws.

molars. In the 8th month, brackets were rebonded as needed and power chains were applied for rotation control (Fig. 13). The lower arch-wire was changed to .017x.025" low friction TMA, and retraction coil springs were applied for retraction of the whole lower arch. In the 10th month, the upper arch-wire was changed to .014x.025" CuNiTi, the lower arch-wire was changed to .019x.025" SS. The closed coil springs (12oz on the right and 11oz on the left) from the bone screws to the canine areas were continued for the correction of sagittal occlusal discrepancy and the lower midline deviation. Square elastic threads (.026x.026", Rocky Mountain, Co. J00181) were tied from the buccal tube of lower second molars to the holes in the platform of the bone screws to intrude the molars, and help correct the anterior open bite. The hook on the lower right second molar was ground off to facilitate continued retraction of the arch (Fig. 14). In the 11th month, the anterior cross-bite was corrected to almost an edge-to-edge position (Fig. 15). In the 13th month, diagonal elastics (3/16, 4.5oz, Kangaroo, Ormco) were used to correct facial midline discrepancy (Fig. 16). After two months, the facial midline was much improved (Fig. 17). In



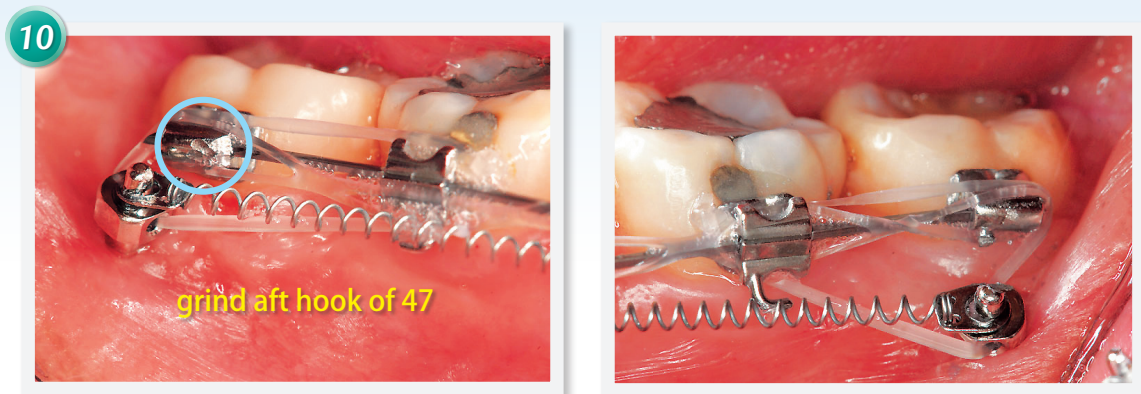
■ Fig. 12: 46-42, 32-36 power chain for correct rotation



■ Fig. 13: 16-12, 22-26 power chain for rotation control

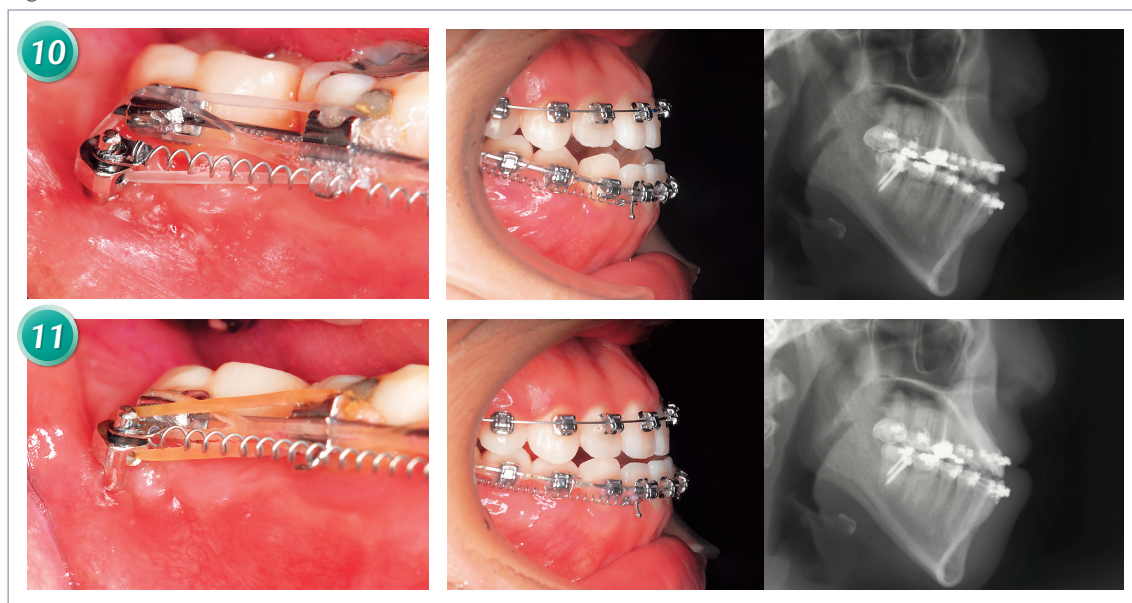
the 18th month, the upper arch-wire was changed to .017x.025" low friction TMA, and the lower bone screws were removed. Use of the diagonal elastics continued.

In the 21st month, the upper arch-wire was changed to .019x.025" low friction TMA. In the 22nd month,



■ Fig.14:

.026x.026 square elastic thread were used to intrude the lower molars. Watch power chain was used to prevent space opening before 2nd molars, put elastic thread through the hole of the mini-screw and tie directly to the 2nd molar tube. During distalization, sometimes the hook of molar tubes will be right in front of the bone screw, for continuing distalization, the hook should be ground off.

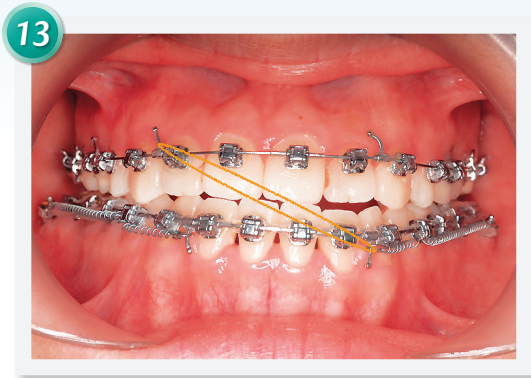


■ Fig.15:

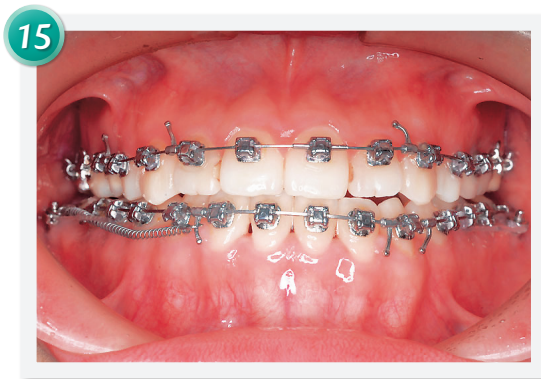After 1 month of retracting the whole dentition distally, the anterior cross-bite was corrected to almost edge-to-edge position, the molars were intruded, notice the distance between screw head and tube hook get much closer.

a panoramic radiograph was exposed to evaluate bracket positions relative to the axial inclinations of the teeth. At that time, the major problem was the distal tipping of the mandibular right 1st molars, and the posterior open bite that resulted from the tip-back effect, due to the retraction of the lower dentition with the buccal shelf bone screws. The

patient requested premature treatment termination, because she was planning to study abroad, so it was necessary to accept the distal crown tipping of the lower molars. Multiple brackets were rebonded and the arch-wires were changed to .016" NiTi. In the 23rd month of treatment, periodontal crown lengthening procedures were recommended for both maxillary

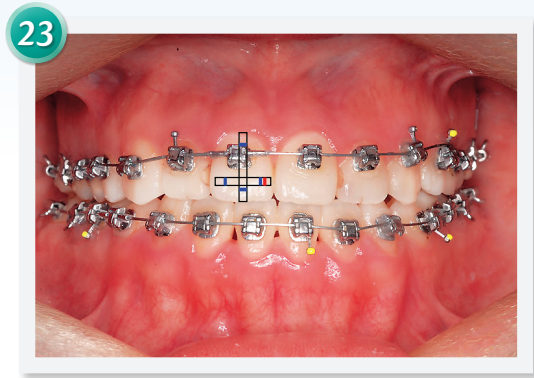


■ Fig. 16:
Kangaroo (3/16, 4.5oz) diagonal elastic to correct facial midline.



■ Fig. 17: After two months, the facial midline was much improved.

cuspid to improve the gummy smile and crown length-to-width ratios (Fig. 18).¹ The upper and lower arch-wires were changed to .014x.025" CuNiTi for final detailing. In the 23rd month of treatment, additional brackets were rebonded for final detailing. The wire sequence was: .014" CuNiTi, .014x.025" CuNiTi, .017x. 025" TMA, .019x.025" TMA, .019x.025" SS, .016" NiTi, and .014x.025" CuNiTi. After 24 months of active treatment (Fig. 19-21), all appliances were removed. Upper Hawley and lower spring retainers were delivered to stabilize the final result.



■ Fig. 18:
Suggest future crown lengthening of 13-23 to correct the gummy smile and to improve the crown length-to-width proportion.

Results Achieved

Maxilla (all three planes):

- A - P: Maintained
- Vertical: Maintained
- Transverse: Maintained

Mandible (all three planes):

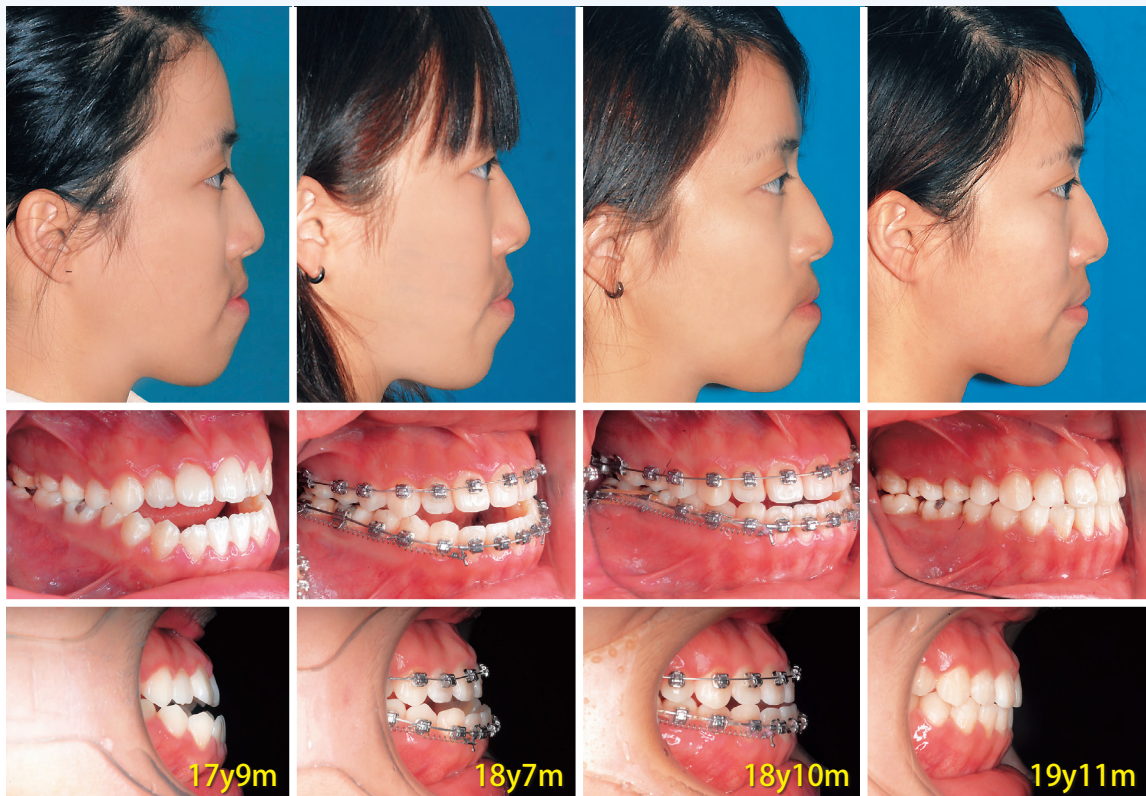- A - P: Retracted
- Vertical: 20 clockwise rotation of the mandibular plane angle
- Transverse: Maintained

Maxillary Dentition:

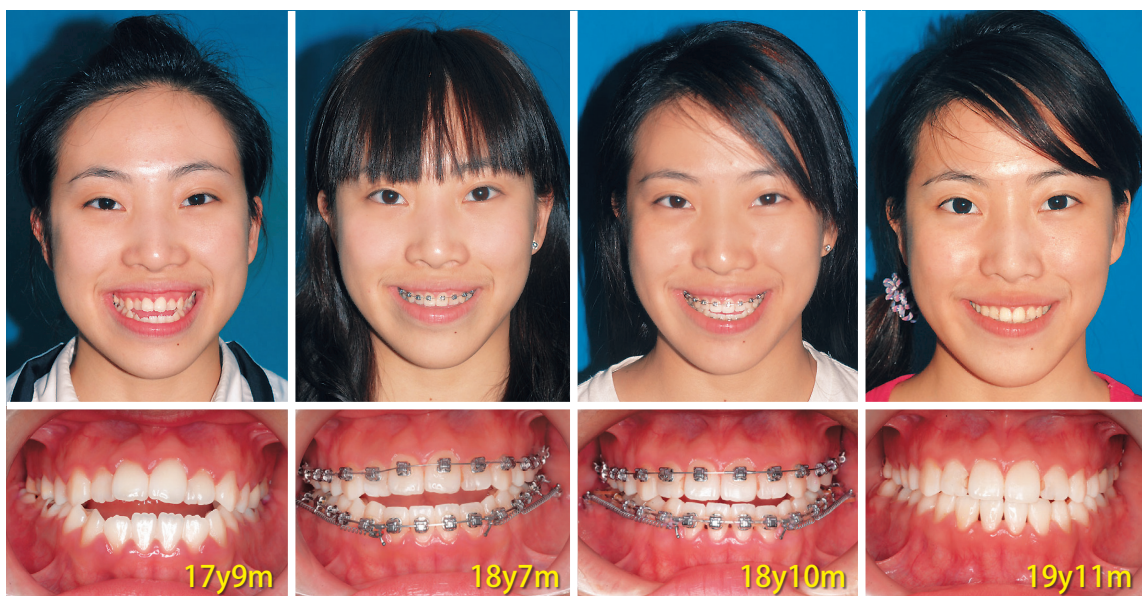- A - P: Incisors extruded, slight lingual tipping of ~10
- Vertical: Extrusion of the entire arch
- Inter-molar / Inter-canine Width: Crowding and cross bite corrected with arch expansion

Mandibular Dentition:

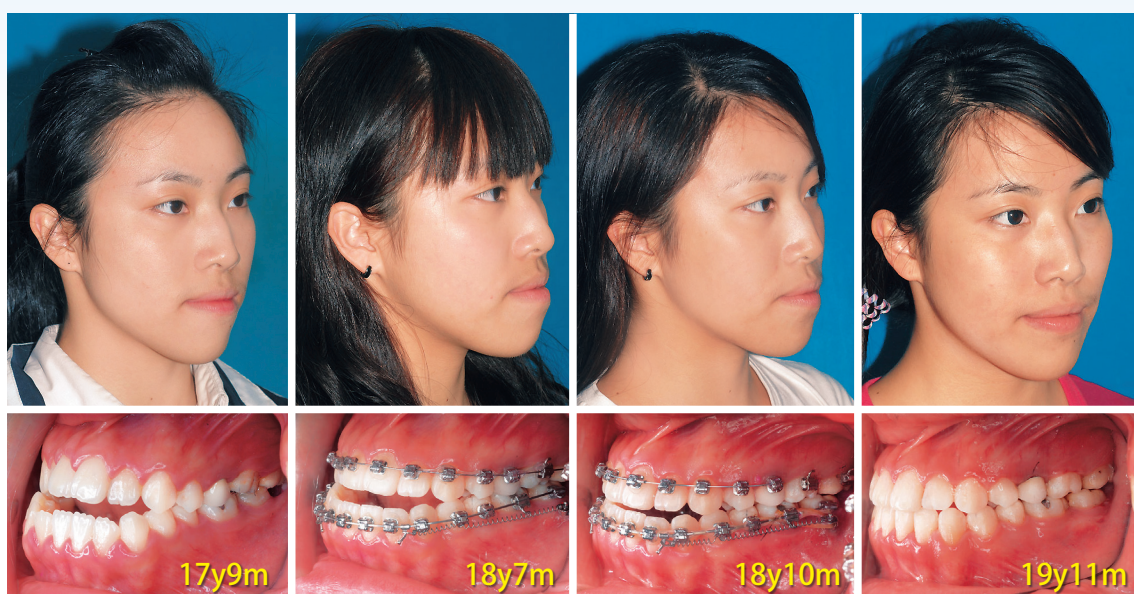- A - P: entire dentition tipped distally
- Vertical: counterclockwise rotation of mandibular occlusal plane and extrusion of incisors



■ Fig. 19: Summary of lateral profile, intraoral photographs follow up and treatment changes.



■ Fig. 20: Summary of frontal profile, intraoral photographs follow up and treatment changes.



■ Fig. 21: Summary of 45 degrees lateral profile, intraoral photographs follow up and treatment changes.

- Inter-molar / Inter-canine Width: Maintained

Facial Esthetics:

- Upper lip retracted
- Lower lip protrusion was improved slightly.

Retention

Upper Hawley and lower spring retainers were delivered, and the patient was instructed to wear them full time for the first six months and nights only thereafter. In addition, the patient was instructed in proper home hygiene and maintenance of the retainers.

Final Evaluation Of Treatment

The ABO Cast-Radiograph Evaluation score was 25 points and IBOI Pink & White score was 4 points, as documented on the forms appearing later in this report. The major discrepancies were uneven

marginal ridges (5 *points*), buccolingual inclination of posterior teeth (9 *points*), loss of some occlusal contacts (4 *points*) and inadequate root parallelism in the upper right and lower left segments (2 *points*). Most of these problems resulted primarily from the tip-back of molars in the lower arch. The OB was 2mm, OJ was 2mm, and the molar relationship were Class I bilaterally. The facial profile was acceptable. Overall, the treatment outcomes for this challenging case were pleasing for both the patient and the clinician.

Discussion

Conservative treatment of a Class III malocclusion, complicated by negative overbite and overjet, has long been challenging for orthodontists. In traditional edgewise treatment, it's quite difficult to correct severe Class III malocclusion without

extraction of lower premolars or molars. Kim's MEAW technique² is well known in Asia, as a powerful multiloop system for correcting anterior openbites, but it is less effective for sagittal problems. For the present patient, the diagnosis indicated passive self-ligating brackets and bone screws as anchorage for traction to retract the entire lower dentition. This method can achieve an excellent result for severe Class III malocclusions without extractions (*other than third molars*) or orthognathic surgery.^{3,4} Three ways have been described for correcting Class III with bone screws:⁵

- (1) Placing interradicular bone screws bilaterally between the upper 2nd premolars and 1st molars, and use Class III elastics. This approach requires patient compliance.
- (2) Insert inter-radicular bone screws between the lower 2nd premolar and 1st molar, bilaterally. Due to limited interradicular space (2-3mm), the retraction of the entire lower dentition is limited.
- (3) Placing bone screws in the retromolar area to retract the entire arch. Since the insertion area on the anchorage screw is behind the 2nd molar, the force application to the main archwire can be complex. Therefore the amount of arch retraction is limited and can only be used for mild Class III correction.

In this case, bone screws were placed on the buccal shelf (Fig. 10) away from the lower molar roots, so the amount of lower arch retraction is sufficient for severe Class III correction.^{3,4} Another limitation to

the extent of retraction of the entire mandibular dentition is the distance between the mandibular 2nd molar and the ascending ramus.⁶ Thus, the 3rd molars should be extracted before the start of orthodontic treatment to prevent them from being impacted, and to create enough space between 2nd molar and the ascending ramus. When large amounts of arch retraction are needed, the gingival hooks on molar tubes may interfere with retraction past the bone screw.^{3,4} For maximum retraction, it is necessary to grind off the interfering hook on the molar tube (Fig. 14).

In general, molar intrusion should be avoided in Class III treatment.⁴ While this concept is true for most Class III cases, the present Class III patient had a retrognathic profile and an open bite. Thus, molar intrusion is very effective mechanics (Fig. 15). The most important issue for non-extraction treatment of open bite with a high mandibular plane angle is the control of molar extrusion to avoid posterior rotation of mandible. However, for the present patient, modest posterior rotation of the mandible was acceptable (Fig. 4).

Using buccal shelf bone screw to retract the whole mandibular arch produces distal tipping of the mandibular molars. For an intrusive force in the mandibular molar region, .026x.026 (Rocky Mountain, Co.) rectangular elastic thread produced traction between the bone screws and the .019x.025 stainless steel main archwire, bilaterally (Fig. 15).^{3,4} Controlling mandibular molar intrusion helped correct the open bite (Fig. 15) and tended to improve the retrognathic

profile. Although the open bite was corrected, the mandibular plane was rotated clockwise 2° (Table 1), due to distal tipping of the mandibular molars and extrusion in the maxillary arch (Fig. 9). The buccal shelf bone screws intruded, or at least prevented extrusion of the lower molars, but this method is only recommended for patients with an acceptable profile. If control of the mandibular plane rotation is essential, upper molar extrusion can be controlled with bone screws in the infrazygomatic crests, bilaterally.

Retracting the entire mandibular dentition with bone screws in the buccal shelves results in tip-back of the molars (Fig. 9).^{7,8,9} The distally tipped molars contributed to the relatively high CRE score

of 25 points due to poor axial inclination, marginal ridge discrepancies, and lack of intermaxillary tooth contacts. The flexibility of the arch-wire is directly proportional to the degree of distal tipping experience by the terminal molar in the arch. To avoid distally tipped mandibular molars, it would be better to retract the mandibular dentition with a stiffer archwire, such as .019x.025" SS to help prevent tip back of lower molars.⁴ The counter clockwise rotation of the occlusal plane is due to the line of force of the distal traction mechanics being occlusal to the center of resistance of the mandibular dentition. It would have been helpful to have progress panoramic radiographs to recognize signs of early stages of distally tipping. The distal tipping could have been compensated by archwire adjustment or repositioning molar brackets. Unfortunately, the treatment had to end before the distal crown tipping of lower molars was corrected, due to the patient's desire to study abroad.

Conclusion

This case report presents a Class III patient with a poor prognosis for orthognathic correction: open bite, lower lip protrusion, no mento-labial sulcus and an orthognathic profile in the centric relation position. Conservative non-surgical treatment with Damon self-ligating system and buccal shelf bone screws proved to be effective for the correction of this type of CI III malocclusion.^{3,4} No airway problems, such as described by Kondo^{10,11,12} were observed; hence, no myofunctional therapy, tongue guards, partial glossectomy, RPE or lingual holding arch

CEPHALOMETRIC			
SKELETAL ANALYSIS			
	PRE-Tx	POST-Tx	DIFF.
SNA°	84°	84°	0°
SNB°	83°	82°	1°
ANB°	1°	2°	1°
SN-MP°	46°	48°	2°
FMA°	38°	40°	2°
DENTAL ANALYSIS			
U1 TO NA mm	10 mm	9 mm	1 mm
U1 TO SN°	113°	112°	1°
L1 TO NB mm	12 mm	10mm	2 mm
L1 TO MP°	80°	73°	7°
FACIAL ANALYSIS			
E-LINE UL	-2 mm	0 mm	2mm
E-LINE LL	5 mm	3 mm	2 mm

■ Table. 1: Cephalometric summary

were indicated. This very difficult malocclusion ($DI = 55$) was treated to an acceptable result ($CRE = 25$). The occlusal relationship could have been improved by placing the buccal shelf bone screws earlier in the treatment sequence.

The patient was pleased to achieve a good result without any extractions except 3rd molars, orthognathic surgery, extraoral anchorage, or complex multiloop archwires. Moreover, successful management of such difficult cases with relatively simple mechanics increases the patient's confidence and trust in the clinician.

Acknowledgment

Thanks to Ms. Tzu Han Huang, Dr. Chris Chang, for proofreading this article.

References

1. Sarver DM. Principle of cosmetic dentistry in orthodontics: Part 1. Shape and proportionality of anterior teeth. *Am J Orthod Dentofacial Orthop* 2004;126:749-53.
2. Kim YH. Anterior open bite and its treatment with multiloop edgewise archwire. *Angle Orthod* 1987;57:290-321.
3. Lin JJ. Long term follow up and management of a severe class III open bite case. *Int J Orthod Implantol* 2012;27:4-16.
4. Lin JJ. Treatment of severe class III with buccal shelf mini-screws. *News & Trends in Orthodontics* 2010;18:4-15.
5. Lin JJ. All about TADs: review of 2nd WIOC. *News & Trends in Orthod* 2011;21:4-22.
6. Huang S. A severe skeletal class III open bite malocclusion treated with non-surgical approach. *Int J Orthod Implantol* 2011;24:28-39.
7. Jung MH, Kim TW. Biomechanical considerations in treatment with miniscrew anchorage. Part 1 the sagittal plane. *J Clin Orthod* 2008;42(2):79-83.
8. Nakamura A, Teratani T, Itoh H, Sugawara J, Ishikawa H. Photoelastic stress analysis of mandibular molars moved distally with the skeletal anchorage system. *Am J Orthod Dentofacial Orthop* 2007;132:624-9.
9. Lin JJ. *Creative Orthodontics : Blending the Damon System & TADs to manage difficult malocclusions*. 2nd ed. Taipei: Yong Chieh; 2010, p.298
10. Kondo E. Nonsurgical and non-extraction treatment of a skeletal class III adult case. *News & Trends in Orthodontics* 2009;13:8-13.
11. Kondo E. Nonsurgical nonextraction treatment of skeletal Class III open bite: Its long-term stability. *Am J Orthod Dentofacial Orthop* 2000;117:267-287.
12. Kondo E. Nonsurgical and nonextraction treatment of skeletal class III patient with severe prognathic mandible. *World J Orthod* 2005;6(3):233-47.



Discrepancy Index Worksheet

TOTAL D.I. SCORE **55**

OVERJET

0 mm. (edge-to-edge)	=	
1 – 3 mm.	=	0 pts.
3.1 – 5 mm.	=	2 pts.
5.1 – 7 mm.	=	3 pts.
7.1 – 9 mm.	=	4 pts.
> 9 mm.	=	5 pts.

Negative OJ (x-bite) 1 pt. per mm. per tooth =

Total = **16**

OVERBITE

0 – 3 mm.	=	0 pts.
3.1 – 5 mm.	=	2 pts.
5.1 – 7 mm.	=	3 pts.
Impinging (100%)	=	5 pts.

Total = **0**

ANTERIOR OPEN BITE

0 mm. (edge-to-edge), 1 pt. per tooth
then 1 pt. per additional full mm. per tooth

Total = **11**

LATERAL OPEN BITE

2 pts. per mm. per tooth

Total = **0**

CROWDING (only one arch)

1 – 3 mm.	=	1 pt.
3.1 – 5 mm.	=	2 pts.
5.1 – 7 mm.	=	4 pts.
> 7 mm.	=	7 pts.

Total = **1**

OCCLUSION

Class I to end on	=	0 pts.
End on Class II or III	=	2 pts. per side <u>8</u> pts.
Full Class II or III	=	4 pts. per side <u>8</u> pts.
Beyond Class II or III	=	1 pt. per mm. <u>8</u> pts. additional

Total = **8**

LINGUAL POSTERIOR X-BITE

1 pt. per tooth Total = **1**

BUCCAL POSTERIOR X-BITE

2 pts. per tooth Total = **0**

CEPHALOMETRICS (See Instructions)

ANB $\geq 6^\circ$ or $\leq -2^\circ$ = 4 pts.

Each degree $< -2^\circ$ _____ x 1 pt. = _____

Each degree $> 6^\circ$ _____ x 1 pt. = _____

SN-MP

$\geq 38^\circ$ = 2 pts.

Each degree $> 38^\circ$ 8 x 2 pts. = **16**

$\leq 26^\circ$ = 1 pt.

Each degree $< 26^\circ$ _____ x 1 pt. = _____

1 to MP $\geq 99^\circ$ = **1 pt.**

Each degree $> 99^\circ$ _____ x 1 pt. = _____

Total = **18**

OTHER (See Instructions)

Supernumerary teeth	_____ x 1 pt. = _____
Ankylosis of perm. teeth	_____ x 2 pts. = _____
Anomalous morphology	_____ x 2 pts. = _____
Impaction (except 3 rd molars)	_____ x 2 pts. = _____
Midline discrepancy (≥ 3 mm)	@ 2 pts. = _____
Missing teeth (except 3 rd molars)	_____ x 1 pts. = _____
Missing teeth, congenital	_____ x 2 pts. = _____
Spacing (4 or more, per arch)	_____ x 2 pts. = _____
Spacing (Mx cent. diastema ≥ 2 mm)	@ 2 pts. = _____
Tooth transposition	_____ x 2 pts. = _____
Skeletal asymmetry (nonsurgical tx)	@ 3 pts. = _____
Addl. treatment complexities	_____ x 2 pts. = _____

Identify: **Trans-alveolar impaction**

Total = **0**

IMPLANT SITE

Lip line : Low (0 pt), Medium (1 pt), High (2 pts)	= _____
Gingival biotype : Low-scalloped, thick (0 pt), Medium-scalloped, medium-thick (1 pt), High-scalloped, thin (2 pts)	= _____
Shape of tooth crowns : Rectangular (0 pt), Triangular (2 pts)	= _____
Bone level at adjacent teeth : ≤ 5 mm to contact point (0 pt), 5.5 to 6.5 mm to contact point (1 pt), ≥ 7 mm to contact point (2 pts)	= _____
Bone anatomy of alveolar crest : H&V sufficient (0 pt), Deficient H, allow simultaneous augment (1 pt), Deficient H, require prior grafting (2 pts), Deficient V or Both H&V (3 pts)	= _____
Soft tissue anatomy : Intact (0 pt), Defective (2 pts)	= _____
Infection at implant site : None (0 pt), Chronic (1 pt), Acute(2 pts)	= _____

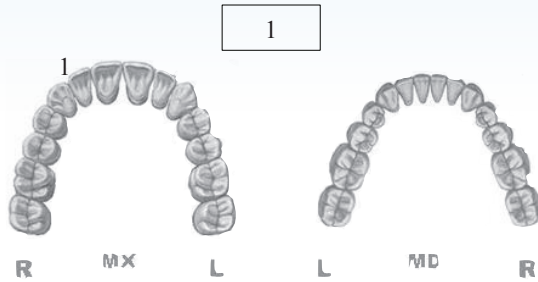
Total = **0**

Cast-Radiograph Evaluation

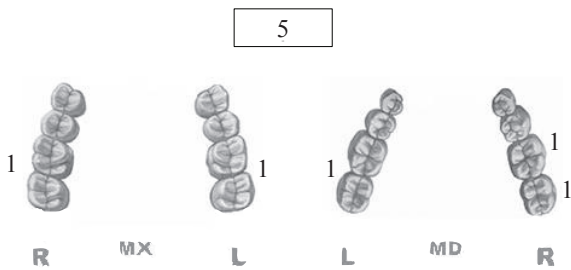
Case # 1 Patient

Total Score: **25**

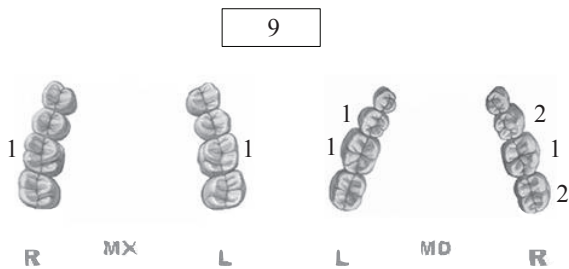
Alignment/Rotations



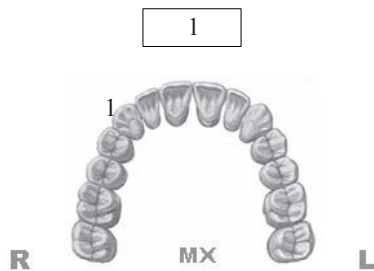Marginal Ridges



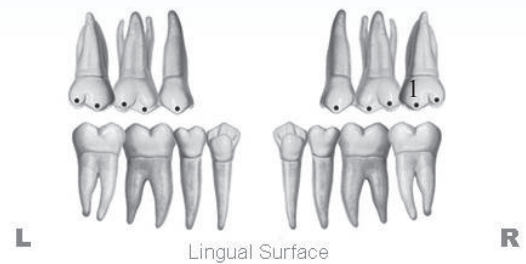
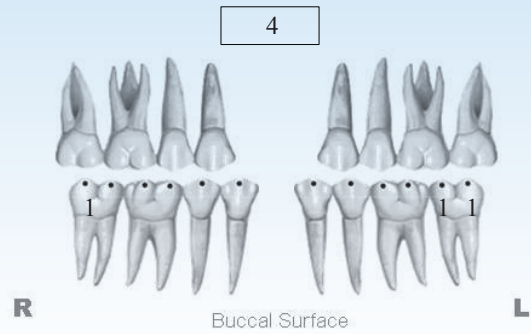
Buccolingual Inclination



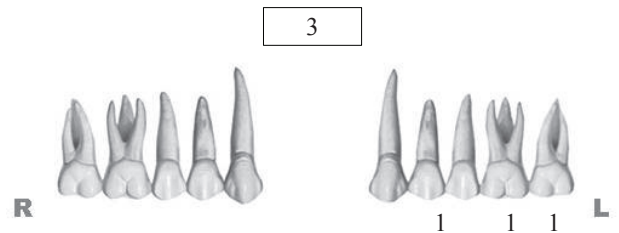
Overjet



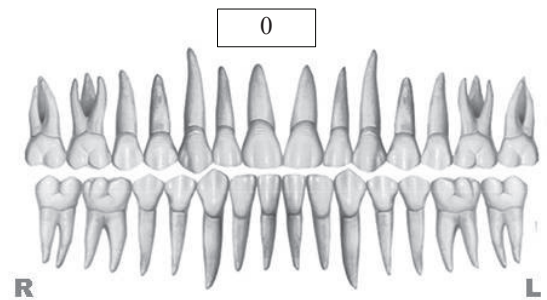
Occlusal Contacts



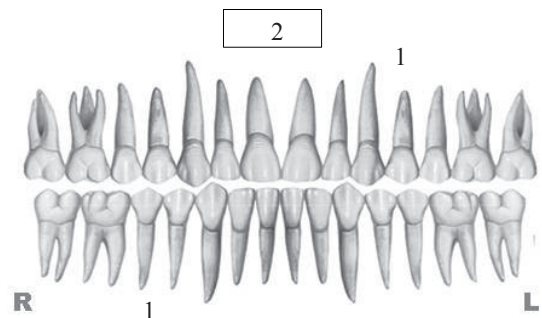
Occlusal Relationships



Interproximal Contacts



Root Angulation



INSTRUCTIONS: Place score beside each deficient tooth and enter total score for each parameter in the white box. Mark extracted teeth with "X". Second molars should be in occlusion.

IBOI Pink & White Esthetic Score

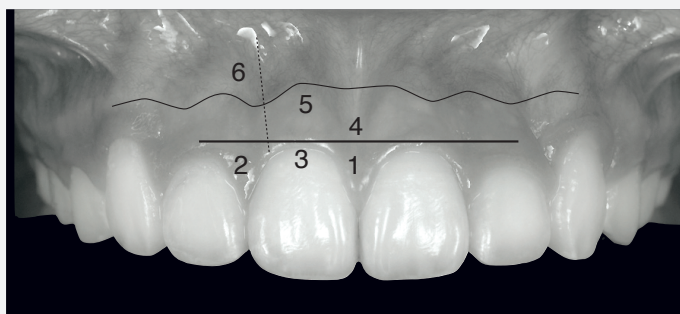
Total Score: =

4

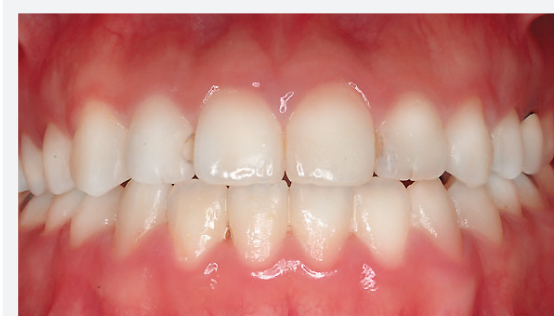1. Pink Esthetic Score

Total =

1



1. Mesial Papilla	0	1	2
2. Distal Papilla	0	1	2
3. Curvature of Gingival Margin	0	1	2
4. Level of Gingival Margin	0	1	2
5. Root Convexity (Torque)	0	1	2
6. Scar Formation	0	1	2

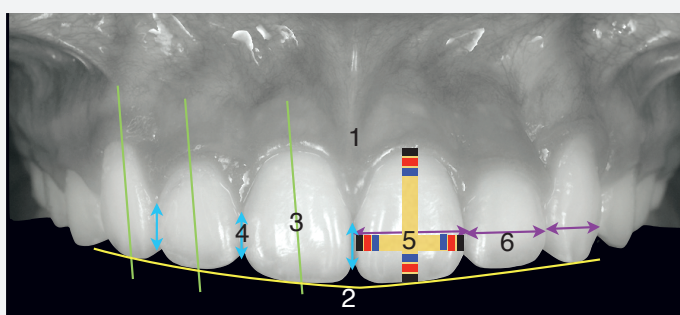


1. M&D Papilla	0	1	2
2. Keratinized Gingiva	0	1	2
3. Curvature of Gingival Margin	0	1	2
4. Level of Gingival Margin	0	1	2
5. Root Convexity (Torque)	0	2	2
6. Scar Formation	0	1	2

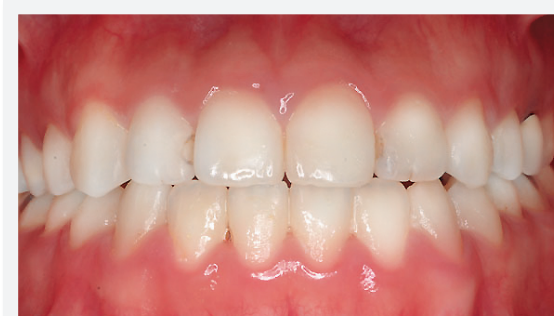2. White Esthetic Score (for Micro-esthetics)

Total =

3



1. Tooth Form	0	1	2
2. Mesial & Distal Outline	0	1	2
3. Crown Margin	0	1	2
4. Translucency (Incisal third)	0	1	2
5. Hue & Value (Middle third)	0	1	2
6. Tooth Proportion	0	1	2



1. Midline	0	1	2
2. Incisor Curve	0	1	2
3. Axial Inclination (5°, 8°, 10°)	0	1	2
4. Contact Area (50%, 40%, 30%)	0	1	2
5. Tooth Proportion(1:0.8)	0	1	2
6. Tooth to Tooth Proportion	0	1	2