

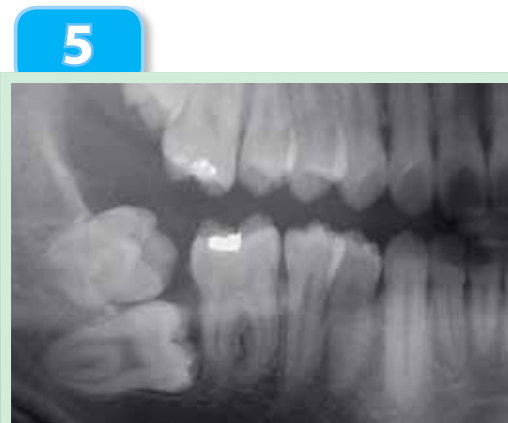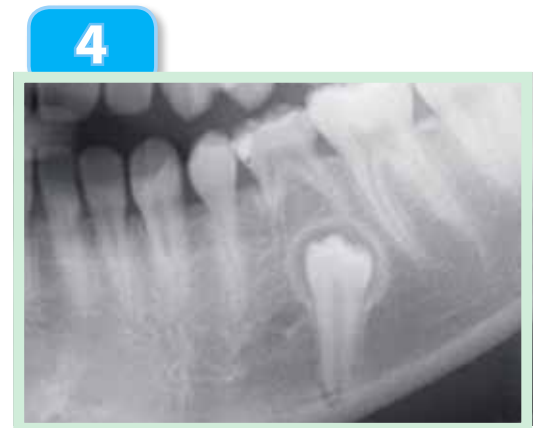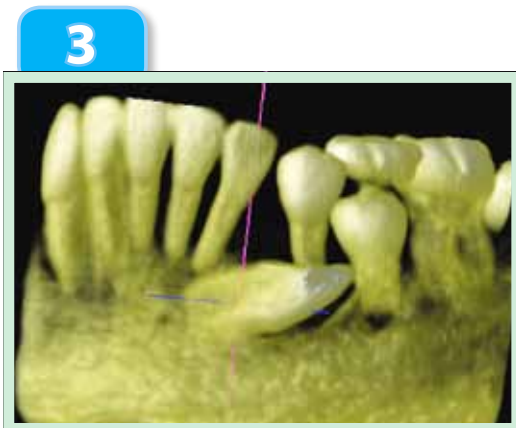
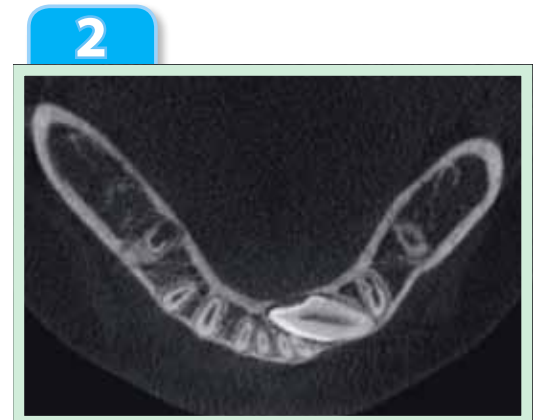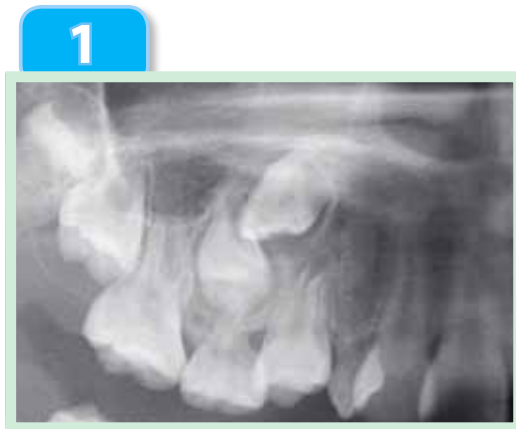OrthoBoneScrew

The Dream Screw for Next Generation's Orthodontists

Beethoven Orthodontic Center, Taiwan

Yu-Lin Hsu, Chris H. N. Chang, W. Eugene Roberts

Tough Cases Made Easy by **OBS**



OrthoBoneScrew

Corporate Headquarters
2F, No. 25, Jian-Jhong
First Road, Hsinchu,
Taiwan 300

Tel: +886 3 5735676
Fax: +886 3 5736777

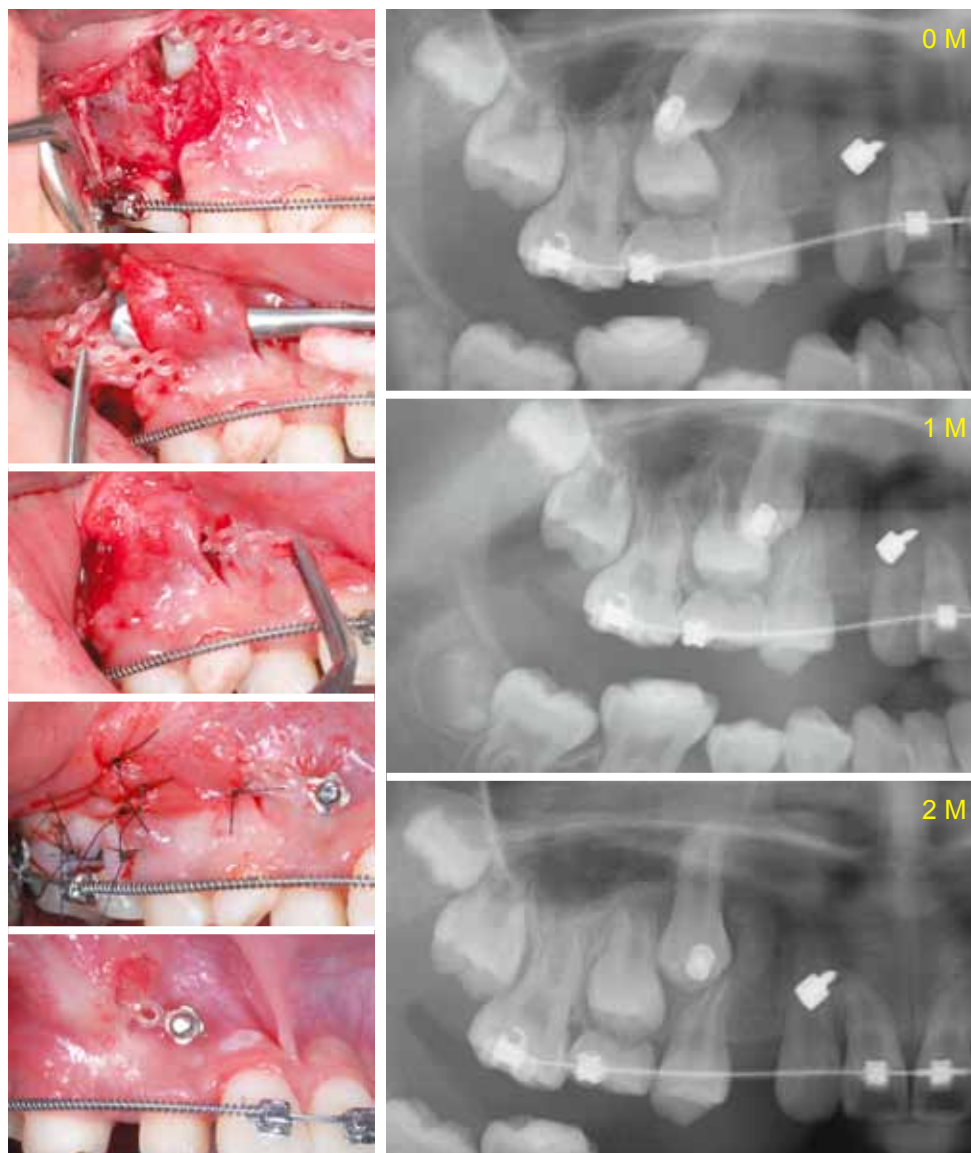
fo@orthobonescrew.com

Upper labially impacted cuspid

1

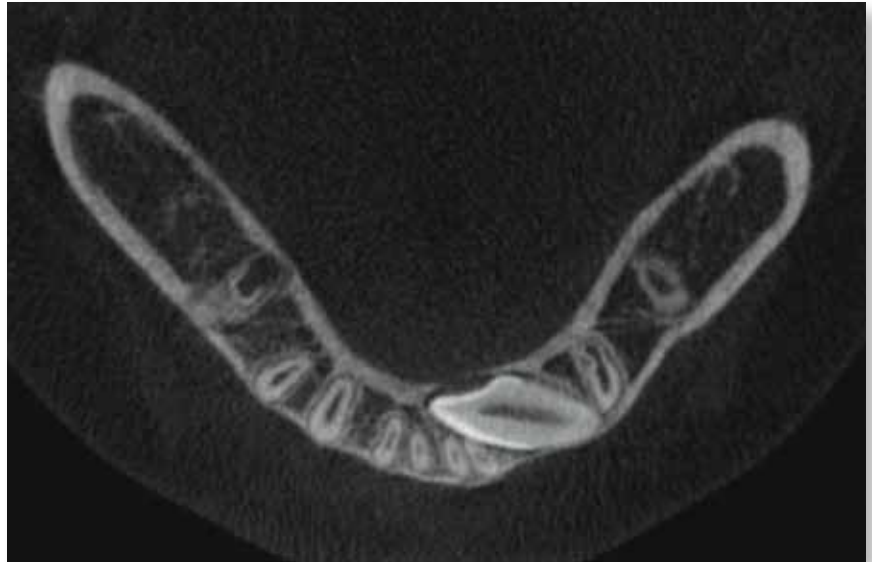
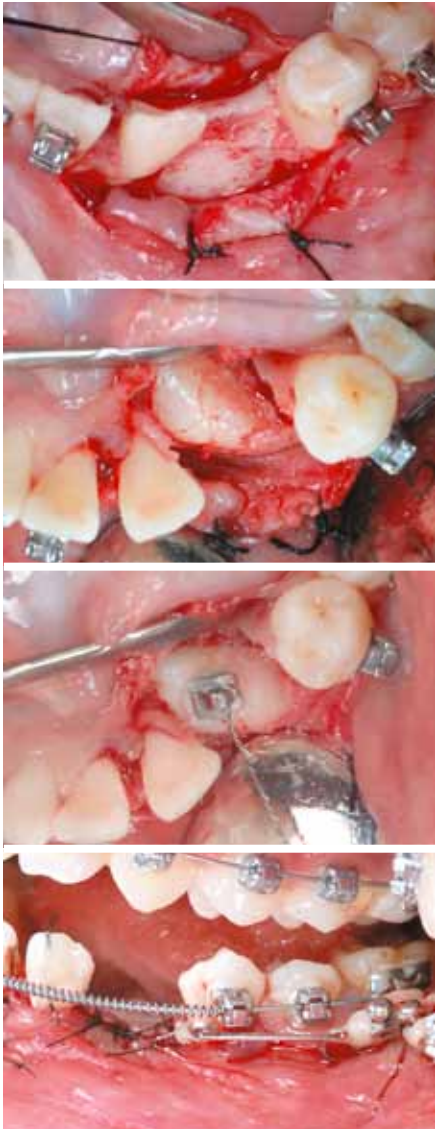
A closed eruption technique
Modified from Vertical Incision Subperiosteal Tunnel Access
VISTA (Dr. Homa Zadeh, USC)

In this case, closed eruption technique was chosen for primary wound healing which is more comfortable than APF. The combination of VISTA technique not only avoid the 2-stage placement of OrthoBoneScrew but also offer a good connection between the OBS and the covered transpositional cuspid. Meanwhile, one should keep OBS as high as possible to make the switch easier. After 2 month-long treatment, this transpositional cuspid has been pulled mesially for 3~4 mm.



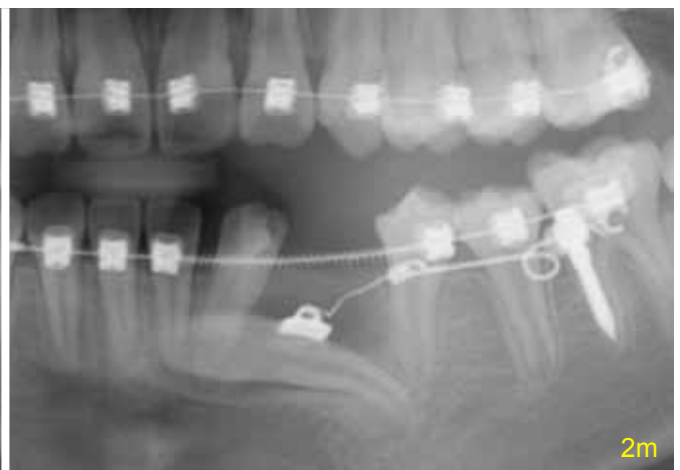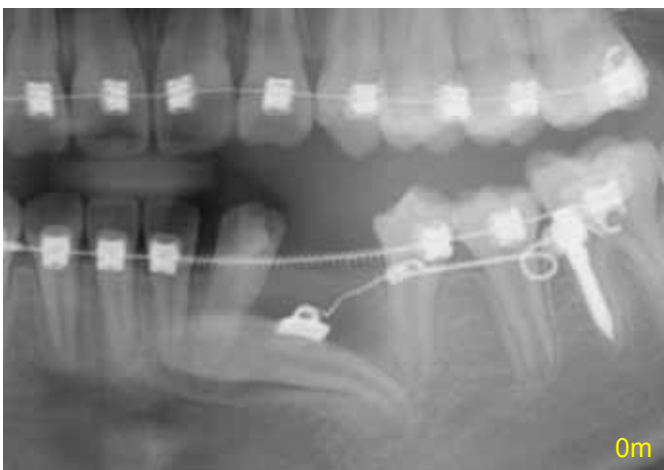Lower sublingual trans-alveolar impacted cuspid

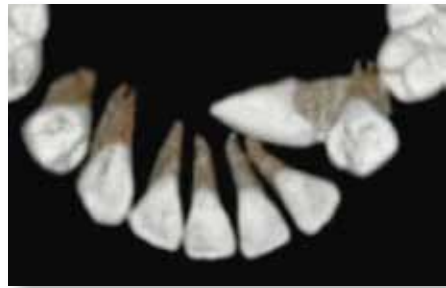
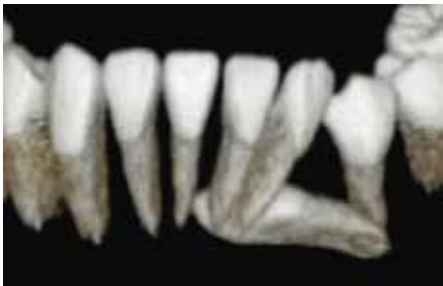2



1st surgery

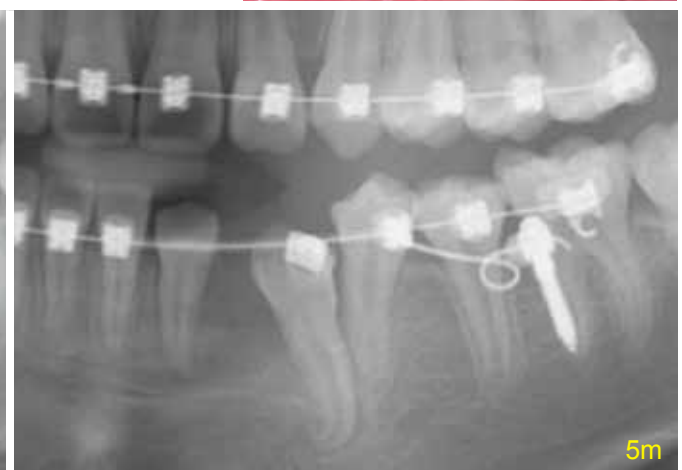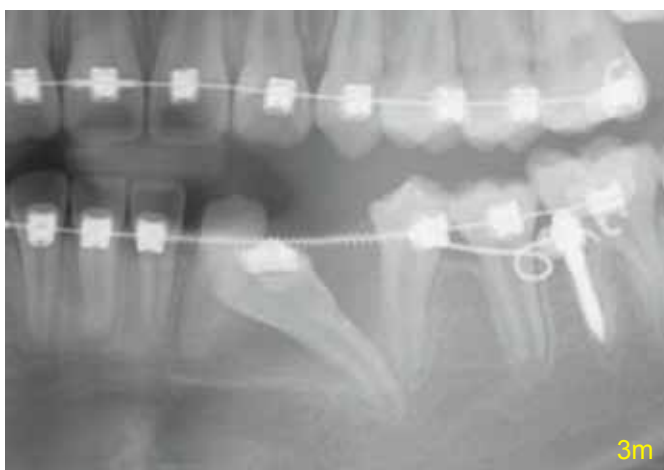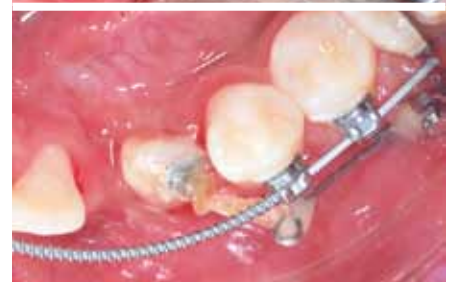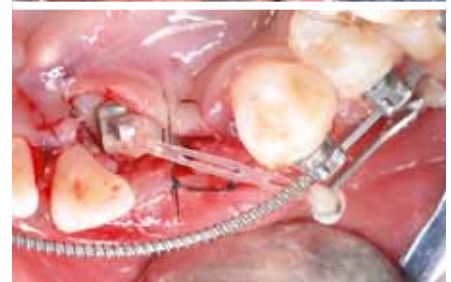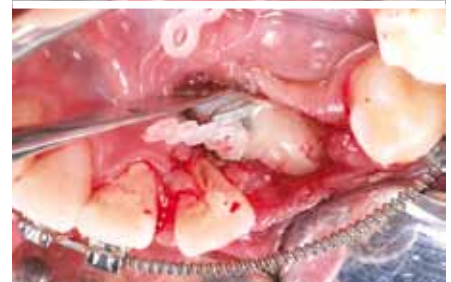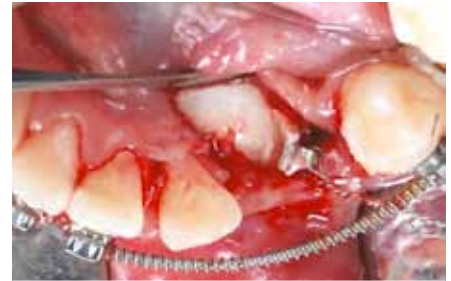The force system was designed to deliver by a .019x.025" SS lever arm and the OBS which was located at buccal shelf. When this lever arm was inserted in the square hole in the OBS and activated, it could upright the trans-alveolar canine first, then moved buccally, and finally elevated to the reserved canine space. During the exposure surgery, it was important to keep the operation field as superficial as possible on both labial and lingual side to avoid cutting the mental nerve and sublingual





2nd surgery

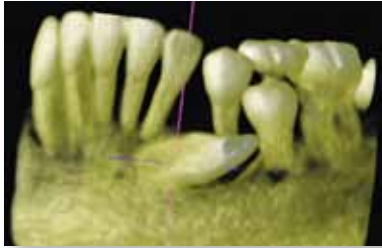
artery. This safety consideration led to a restricted bonding position of the eyelet on the surface of the root. After 2 months from operation, the horizontal impacted canine was upright successfully, and the 2nd exposure surgery was aimed to change the position of the eyelet to the crown. By adjusting the lever arm, the tip of the impacted canine was shown up in the oral cavity 2 months later.



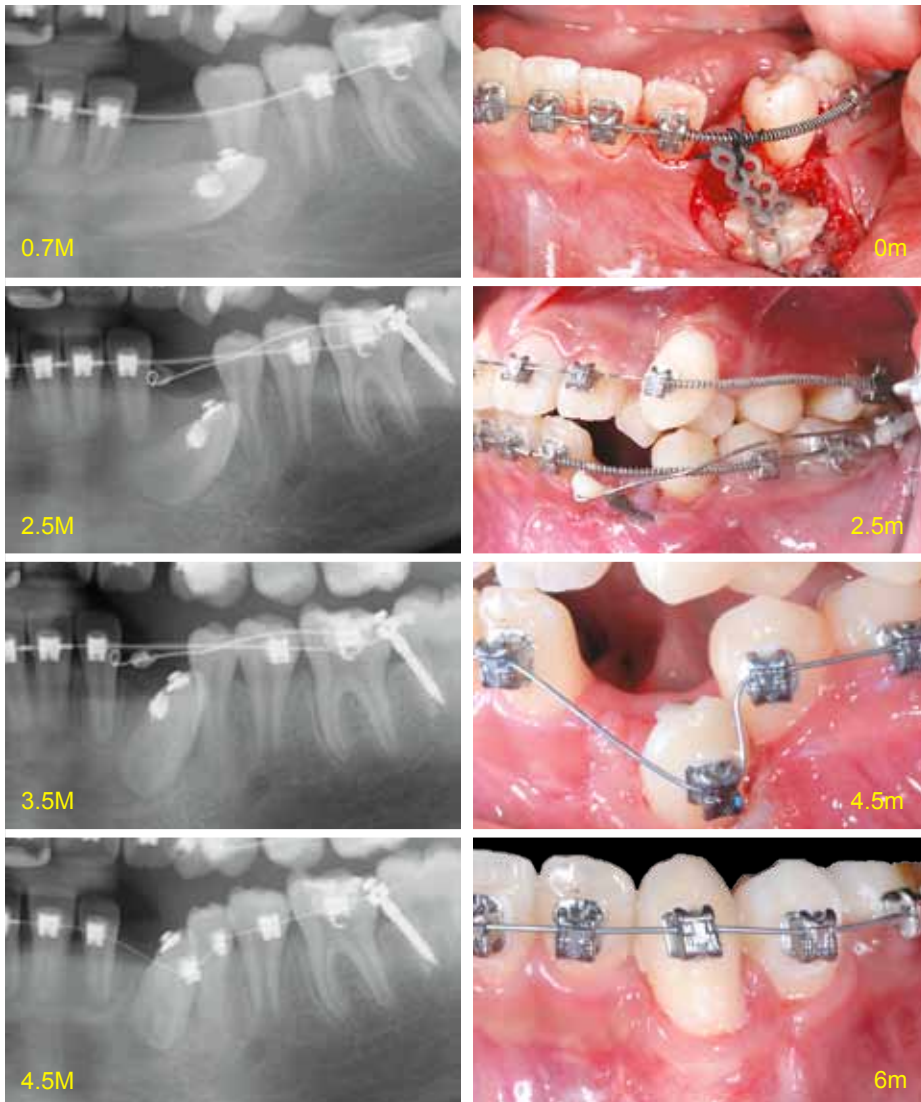
Lower horizontal impacted cuspid

3

Mechanics design:

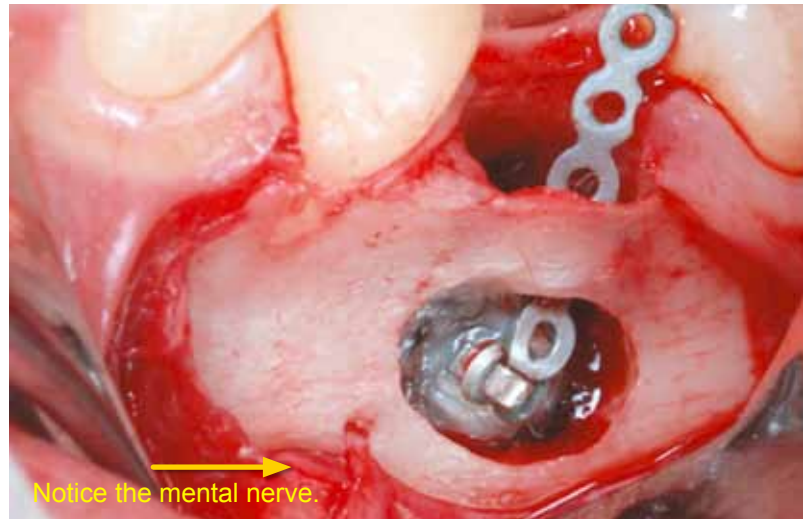
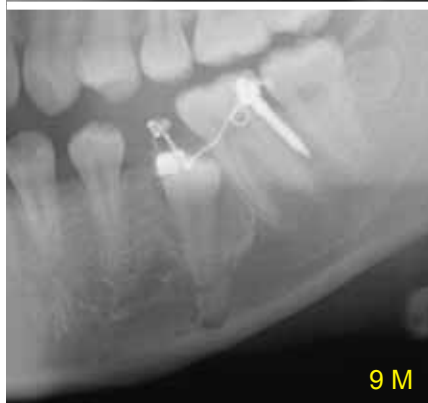
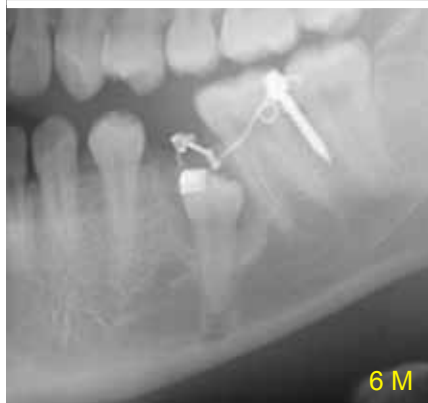
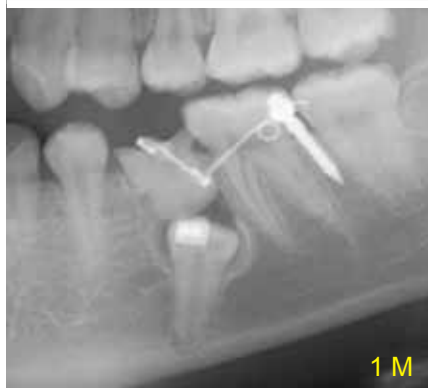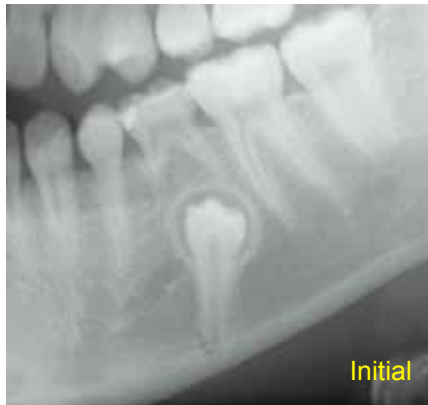A .017x.025" TMA lever arm was consisted of a helical coil on one end and helical attachment on the other end. When this lever arm was inserted in the square hole in the OBS (*located at buccal shelf*) and activated, it could build a force system which protracted the tip of canine first, then moved buccally, and finally elevated to the reserved canine space. If the mechanics were designed to exert force directly from the main arch wire only, it would have been detrimental to the roots of first premolar. During the follow-up visits, the helix was adjusted without taking it out. After three months from operation, the impacted canine was successfully moved away from the previously impacted site and was ready for bracket bonding.

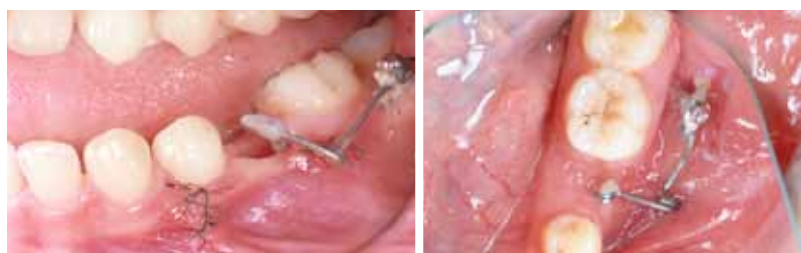

Lower impacted premolar

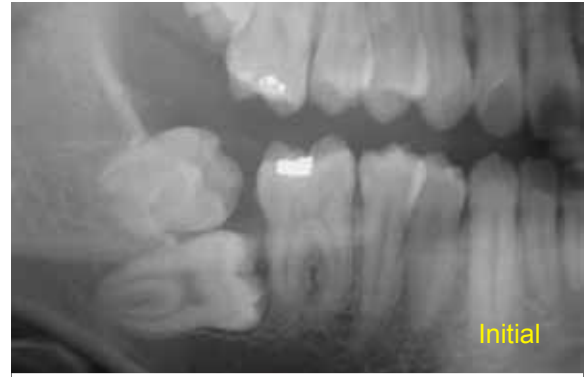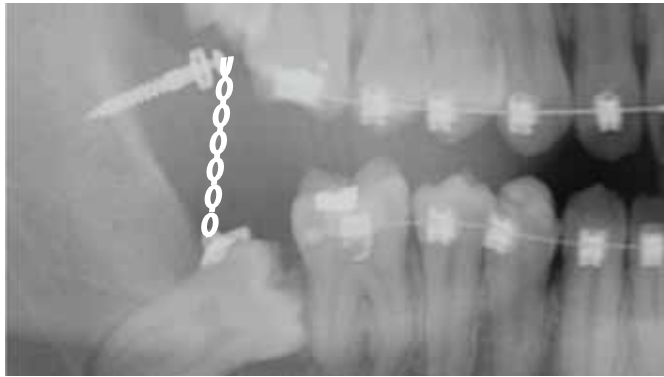
4



A 13-year old female had a lower impacted 2nd premolar, approximately 10 mm deep on the left side. The treatment plan was to extract the 2nd primary molar and pull out the 2nd premolar. During the treatment, the 2nd primary molar was first extracted, followed by bonding an eyelet bracket on the surgically exposed 2nd premolar. Meanwhile, the bone surrounding the crown of the second premolar was reduced until reaching CEJ and a lateral window was made for bracket bonding. An eyelet bracket was bonded on the buccal surface of the deeply impacted second premolar. The OBS was inserted on the left buccal shelf area. A power-chain was attached between a 3D lever arm and the eyelet bracket to extrude the second premolar. This .017x.025" TMA lever arm was consisted of 3 helical coils: one in the middle, two in both ends. When this lever arm was inserted in the square hole of the OBS and activated, it would form a force system which extruded the second premolar directly.



Lower impacted molar 5



A 19-year-and-10-month-old male had lower impacted second and third molars on the right side. The treatment plan was to extract the 3rd molar and upright the 2nd molar. During the treatment, the third molar was first extracted, followed by exposing the second molar surgically. Meanwhile, the bone surrounding the crown of the second molar was removed to CEJ and the second molar was surgically luxated by an elevator. A button was bonded on the distal surface of the second molar. The OBS was inserted on the right ramus of the mandible. An elastic chain was attached between the OBS and the button to upright the second molar. In 4 months, the second molar was uplifted successfully. Finally, a molar tube was bonded for advanced alignment and leveling. An open coil spring was inserted between 1st and 2nd molars to push and upright the 2nd molar.

