

Simplified Open-Window Technique for Palatally Impacted Cuspids



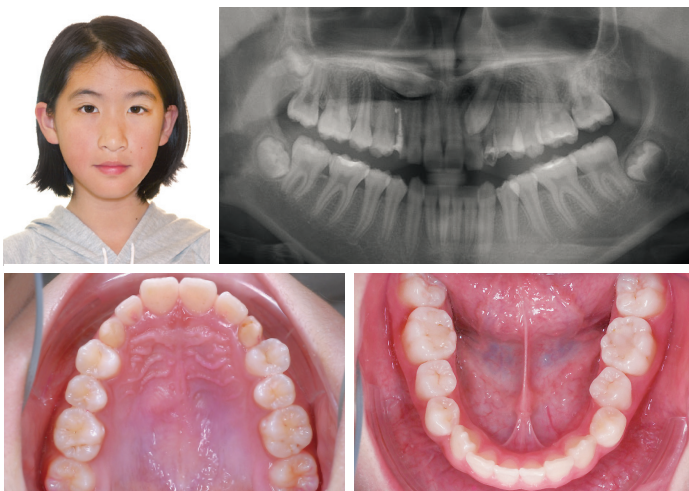Chris H.N. Chang, DDS, Ph.D.
 Director,
 Beethoven Orthodontic Center

Introduction

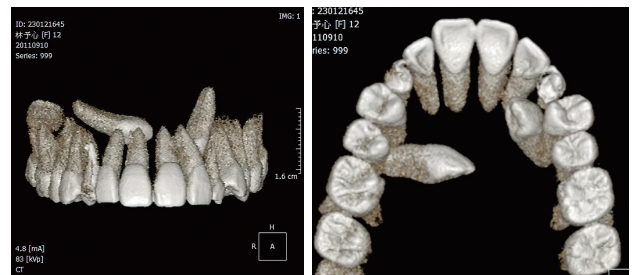
Open window technique is a commonly used surgical option to treat palatally impacted cuspids. This article aims to provide step-by-step illustrations on the surgical procedures so doctors can use them as a checklist before approaching this type of cases.

Case Study

A 12-year-6-month-old female came for consultation. The panorex film showed two upper impacted canines on both sides and two deciduous canines remaining (Fig. 1). CT scan indicates that the impacted cuspids were on the palatal side of the right second premolar and the left first premolar (Fig. 2). This information was used for selecting an appropriate surgical technique. The drawing of the impacted cuspids marks the approximate position (Fig. 3). Detailed surgical procedures of this surgery are discussed at below.



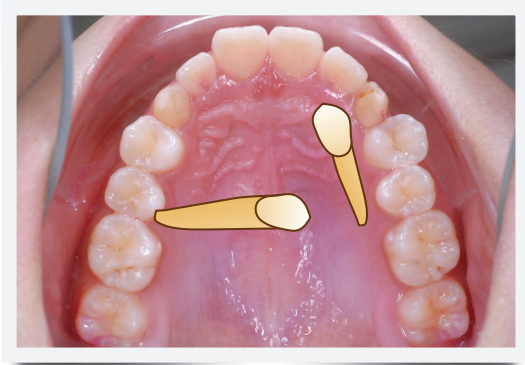
■ Fig. 1: Pretreatment pano radiograph & intraoral photographs.



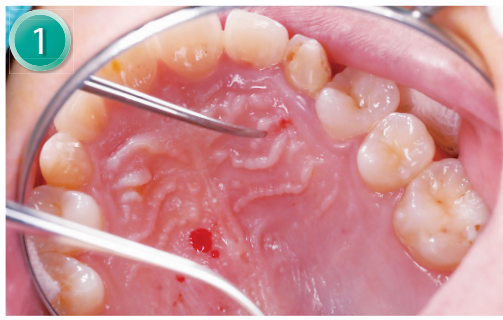■ Fig. 2: Pretreatment CT image. Frontal view and occlusal view reveal that the the crown of impacted cuspids.



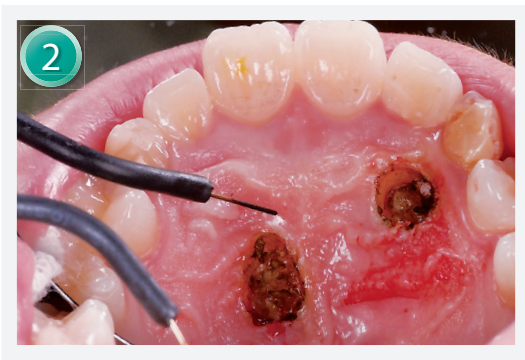Dr. Jack Cheng, Lecturer,
Beethoven Orthodontic Course



■ Fig. 3:
The drawing of the impacted cuspids marks the approximate position.



■ Fig. 4:
After applying local anesthesia, use an explorer to mark the crown.



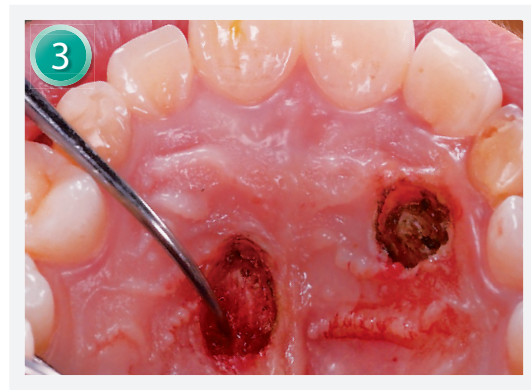■ Fig. 5:
Use a dental electric knife to remove the soft tissue covering the impaction's crown.

Surgical Process

First, local anesthesia was applied in the surgical site and an explorer was used to mark the location of the crown (Fig. 4). When an explorer touches teeth or bones, the sensation is like contacting a smooth or rough surface respectively.

Second, use a dental electric knife to remove the soft tissue covering the impacted cuspids (Fig. 5). By this method, there will be good vision to the surgical field to prevent blood oozing around the soft tissue.

Third, an explorer in an up-down motion is used to measure the covering bone depth and margin (Fig. 6). CT image can provide much diagnostic information on the precise location of the impacted cuspid, but an explorer detection is more effective to sound the depth and margin of the covering bone.



■ Fig. 6:
Use an explorer in an up-down motion to detect the depth and margin of the covering bone.

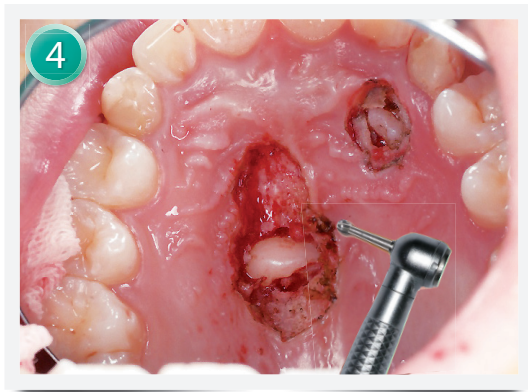Fourth, use a high speed handpiece and carbide round bur to remove the covering bone (Fig. 7).

Fifth, extract 53, 63 primary teeth (Fig. 8).

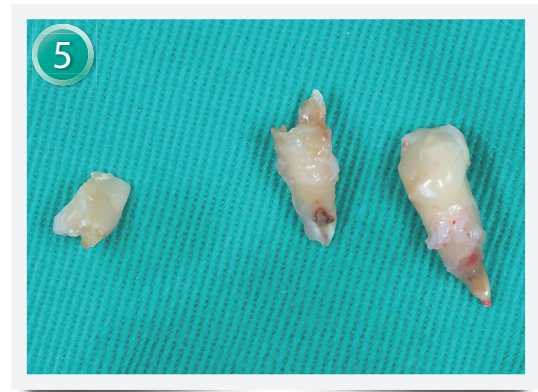Sixth, by using high power suction and an electric knife, these tools facilitate blood coagulation (Fig. 9).

Seventh, use a high speed handpiece and a carbide round bur to removes more bone. The main purpose is to make impacted cuspid more exposure (Fig. 10).

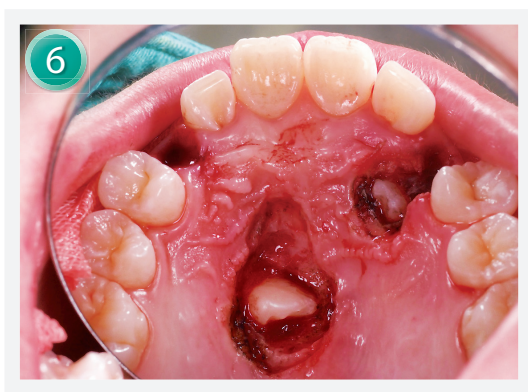Eighth, control bleeding with an electric knife and irrigation with normal saline (Fig. 11).



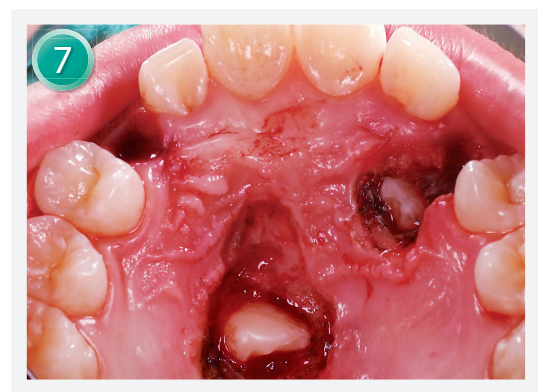■ Fig. 7:
Remove the covering bone with a high speed handpiece and a carbide round bur.



■ Fig. 8:
Extract 53, 63 primary teeth.



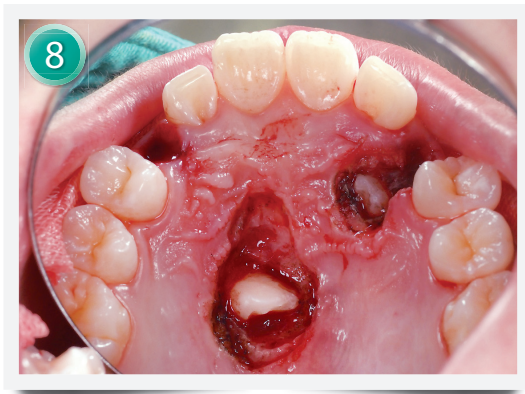■ Fig. 9:
By using high power suction and an electric knife, these tools facilitate blood coagulation.



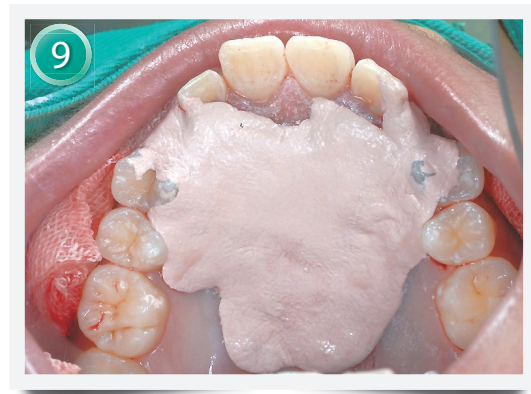■ Fig. 10:
The main purpose is to remove more bone down to CEJ to make impacted cuspid easily to erupt.

Ninth, spreading some vaseline on the gloves as a coating to make COE-PAK stick proof (Fig. 12). Then use it to cover the wound. Apply pressure on COE-PAK against the wound with wet gauzes while pressing blood out. COE-PAK packed into the interdental space will be caught between the undercut (Fig. 13).

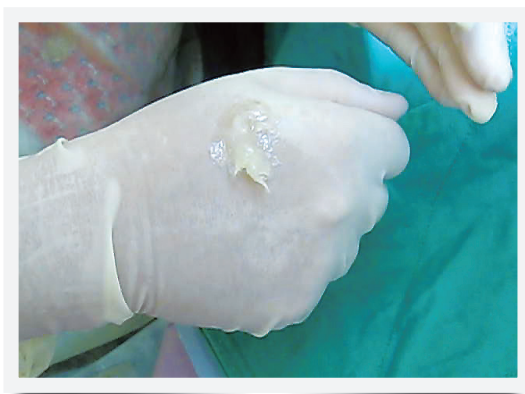COE-PAK can help stop bleeding and cover the wound for patient's comfort. It will delay soft tissue healing and avoid the soft tissue covering the impaction again. The epithelium averagely grows at the rate of 1 mm per day, much faster than autoeruption of the impaction. Remove COE-PAK three days after the surgery and monitor the emergence of the impaction after 3 weeks (Fig. 14).



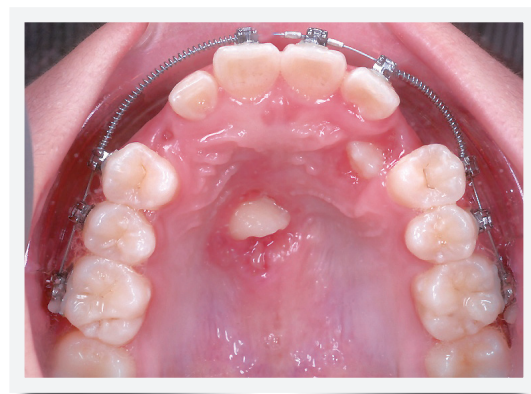■ Fig. 11:
Control bleeding with an electric knife.



■ Fig. 12:
Spread vaseline on the gloves as a coating to make them stick proof.



■ Fig. 13:
Cover the wound with COE-PAK and pack it into the interdental space so it will be caught between the undercut.



■ Fig. 14:
COE-PAK was removed 3 days later. Impacted cuspids start to erupt 3 weeks after the surgery.

Discussion

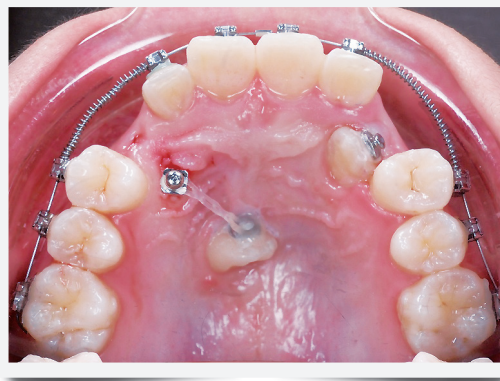Open window technique was used in this case to facilitate auto-eruption of the impaction. When the labial surface of the impaction erupts 7mm, a miniscrew is placed palatally to bring the right impacted cuspid into arch with connecting power chains (Fig. 15). This force system can provide direct retraction, compared with a 3D lever arm (Fig. 16). However, the disadvantage is that screw insertion sites have to be changed in time to apply an appropriate force direction. Meanwhile, one has to pay attention to possible occlusion interferences. Frequent checks on occlusal contacts with articulation is advised.

Conclusion

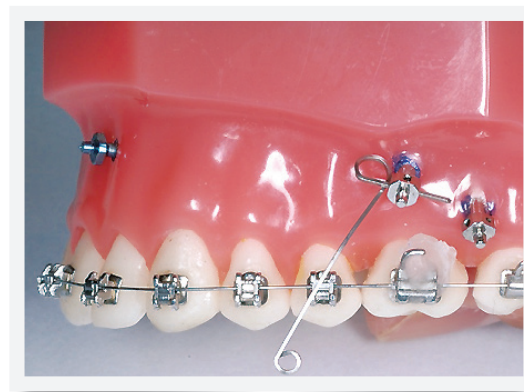Clearing the soft and hard tissue on the traction route is a key step in the treatment of impactions because it can facilitate auto-eruption later on. Traditionally orthodontists would refer these surgeries to oral surgeons. In this article a simplified method is proposed so orthodontists can perform as chair side procedures without referring out to other specialists. As a result, one can have more consistent treatment procedures and results for future study.

References

1. Kokich VG. Surgical and orthodontic management of impacted maxillary canine. *Am J Orthod Dentofacial Orthop* 2004;126:278-83.
2. Hsu YL, Chang C, Roberts WE. OrthoBoneScrew. The dream screw for next generation's orthodontists. *News & Trends in Orthodontics*. 2011;23:34-49
3. Huizing EH, Groot JAM. Functional Reconstructive Nasal Surgery. 2003;25
4. Su B, Hsu YL, Chang C, Roberts WE. Soft Tissue Considerations for the Management of Impactions. *International Journal of Orthodontics & Implantology*. 2011;24:50-59
5. Chang C. Advanced Damon Course, Beethoven Podcast Encyclopedia in Orthodontics 2012, Newon's A Ltd, Taiwan
6. Yeh HY, Chang C, Roberts WE. Step-by-Step on the Open-Window Technique for Upper Palatal Impaction. *International Journal of Orthodontics & Implantology*. 2011;24:40-43



■ Fig. 15:
Two months later, use a palatal miniscrew with power chains to retract right canine.



■ Fig. 16: 2x12 mm OBS with 3D lever arm