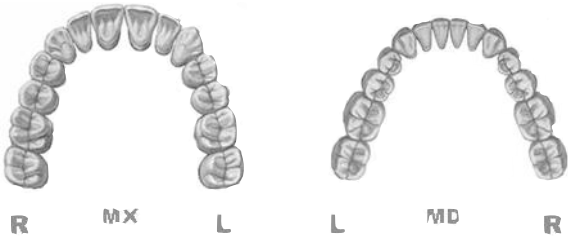


IBOI Cast-Radiograph Evaluation

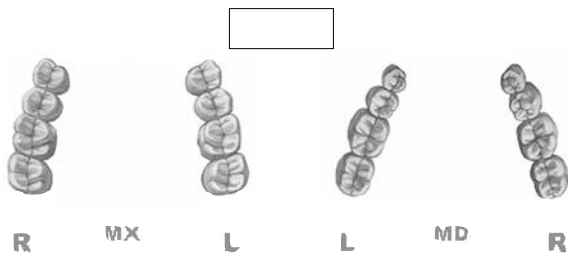
Case # _____ Patient _____

Total Score: _____

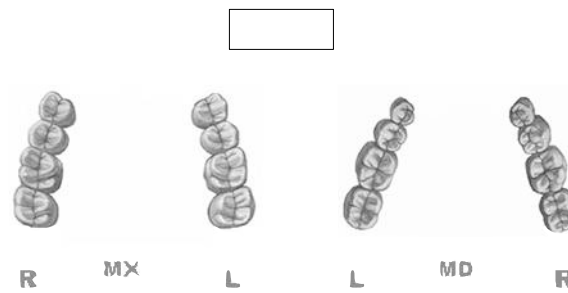
Alignment/Rotations



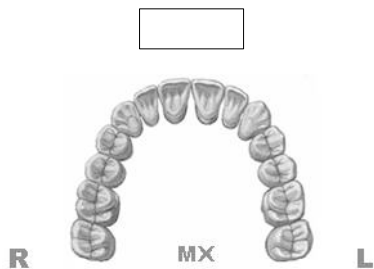Marginal Ridges



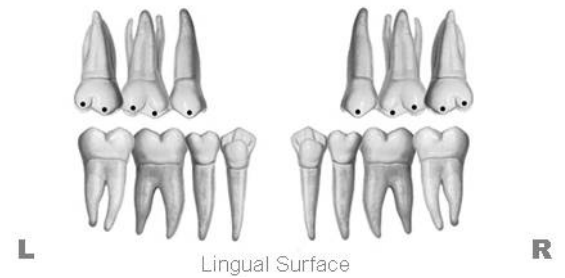
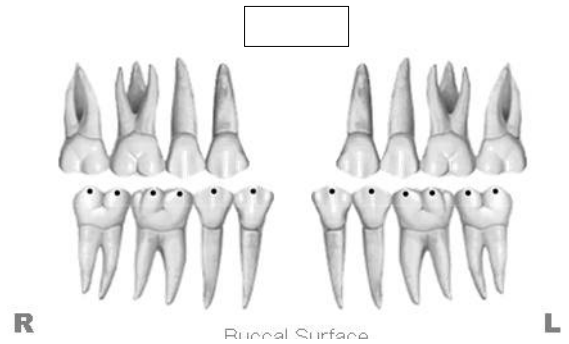
Buccolingual Inclination



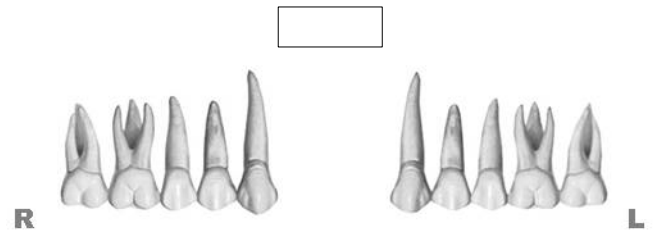Overjet



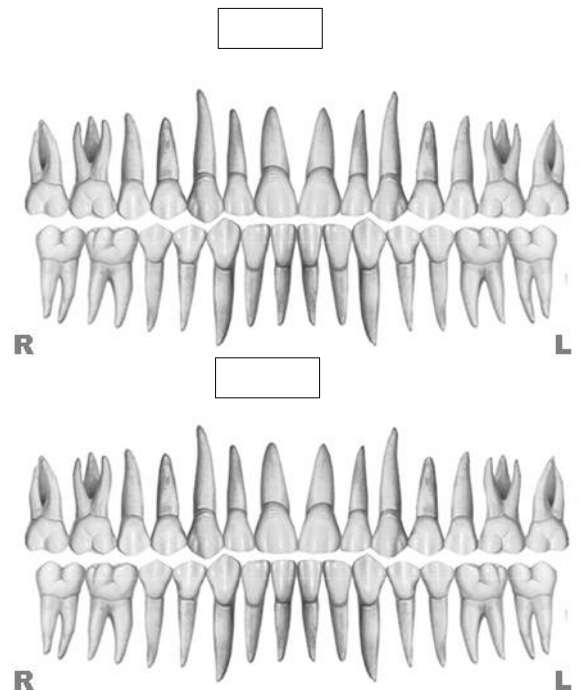
Occlusal Contacts



Occlusal Relationships



Interproximal Contacts



INSTRUCTIONS: Place score beside each deficient tooth and enter total score for each parameter in the white box. Mark extracted teeth with "X". Second molars should be in occlusion.