

Face Mask (FM) Protraction with  
Rapid Maxillary Expansion (RME):  
Is this complicated modality necessary?

Dr. John Jin-Jong Lin

Asymmetric Maxilla with a Functional Shift and Labially  
Blocked-Out Maxillary Canines

Drs. Ariel Chang, Chris Chang & W. Eugene Roberts

Oligodontia and Class II Malocclusion Treated  
with Orthodontics, Bone Augmentation,  
and an Implant-Supported Prosthesis

Drs. Hui-Hwa Chen, Chris Chang & W. Eugene Roberts

Full Cusp Class II Malocclusion with a Deep Overbite

Drs. Sheau-Ling Lin, Chris Chang & W. Eugene Roberts

# IJOI

International Journal of  
Orthodontics & Implantology

Vol. 36 Oct. 1, 2014



Damon Bonding workshop, Penang, Malaysia. 10.20.2014, led by Dr. Chris Chang (center right).

*International Journal of Orthodontics & Implantology* is an experience sharing magazine for worldwide orthodontists and Implantologists. Download it at <http://iaoi.pro>.

《僅供牙科專業人士參閱》

2014~2015

# 熱愛學矯正



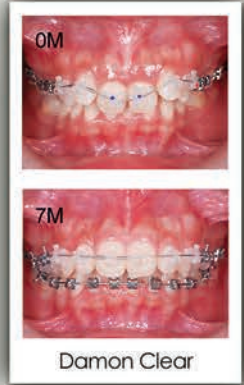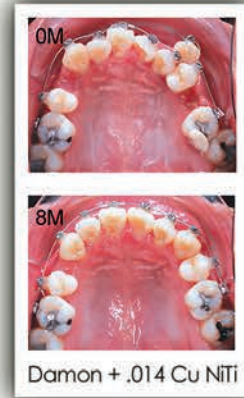## 張慧男 博士



新竹貝多芬齒顎矯正中心負責人  
 中華民國齒顎矯正專科醫師  
 美國齒顎矯正專科醫師學院院士 (ABO)  
 美國印地安那普渡大學齒顎矯正研究所博士

### 學會開始做矯正需多久?

39小時讓您入門矯正。本課程採高效學習法及高效矯正簡報法 - Keynote，在舒適、輕鬆的環境下，學會簡單有效的矯正方法，教室與診間結合，讓您現學現用，立即熟悉各種習得的技巧，而不需太多課後複習。全程以 In-Office Training 方式，用病例帶動分析、診斷，治療計畫與療程技巧，每一步驟皆以圖片及影片教學，讓您很難錯過任何環節，更沒有聽不清楚或無法理解的可能。為提高課後自我學習及臨床印證之效率，另備有教學電子檔，供學員家中研習。我們的終極目標是：用最短時間、最輕鬆的方式，讓每位學員 - 熱愛矯正學、熱愛學矯正。



## Damon矯正課程

【課程】9:00 - 12:00  
 【實習】另外安排

使用最新一代矯正器 Damon Q 進行課程，  
 歡迎舊生報名參加。

全新開課

	台北 (二)	台中 (二)	高雄 (四)	LECTURE	LAB
1	9/30	4/28	5/7	理想入門病例+Damon Q黏著	Bonding (Damon Q) + BT
2	10/7	5/12	5/14	快速矯正療程四部曲	Ceph + Photo
3	10/14	5/26	5/21	簡捷有效的錨定系統	Damon + OrthoBoneScrew I
4	10/28	6/23	6/25	不拔牙與拔牙分析	Damon + OrthoBoneScrew II
5	11/4	6/30	7/16	Damon 診斷流程及微調	Finish Bending
6	11/18	7/14	7/30	完工檢測及報告示範	Fixed Retainer (FR)
7	11/25	7/21	8/13	維持及復發；病例示範	Presentation Demo
8	12/9	8/4	8/27	矯正力學及診斷分析 (1)	DDX + Case Reports I
9	12/23	8/18	9/17	軟硬組織及診斷分析 (2)	DDX + Case Reports II
10	12/30	8/25	9/24	兒童矯正及診斷分析 (3)	DDX + Case Reports III
11	1/6/15	9/1	10/1	成人矯正及診斷分析 (4)	DDX + Case Reports IV

## 矯正植體課程

【課程】9:00 - 12:00  
 【實習】13:30 - 20:00

矯正植體的操作時機、  
 植法與實習、個案討論、  
 臨床跟診及實作示範。



新竹(三)

11/28 (含午、晚餐)

## International workshop

Keynote & management  
 OrthoBoneScrew & Damon

2014

中文B班 11/26 -28

英文B班 12/1 -4

馬來西亞A班 12/11 -13

2015

馬來西亞B班 4/9 -11

英文A班 6/16 -19

亞洲A班 7/2 -4

英文B班 11/24 -27

亞洲B班 10/29 -30

## 矯正進階課程

【新竹】9:00 - 12:00

以病例討論為主軸，培養學員如何正確診斷及快速排除  
 臨床疑點，課程中亦訓練每位學員善用 Keynote。

	新竹 (四)	Paper Reviews	Topics & Case Demo
1	10/2	Bracket Placement	Crowding: Ext. vs. Non-ext.
2	10/9	Impacted Canines	Upper Impacted Teeth
3	10/23	Canine Substitution	Lower Impacted Teeth
4	10/30	Missing 2nd Premolar	Missing: Ant. vs. Post.
5	11/13	DI Workshop	Crossbite: Ant. vs. Post.
6	11/27	CRE Workshop	Open Bite High Angle
7	12/18	Excellence in Finishing (occlusion)	Deep Bite Low Angle
8	1/8/15	Excellence in Finishing (esthetics & perio)	Gummy Smile & Canting
9	2/12	Ortho-Perio-Restore Connection	Esthetic Finishing (Transposition)
10	3/5	Adjunct to Perio	Implant-Ortho
11	3/12	Unhappy Patient	IDT - Adult Complex

## 矯正精修課程

【課程】9:00 - 12:00

協助每位學員了解由古典到現代之文獻，進而應用於實際  
 病例；並藉由DI及CRE讓精緻完工 (Excellent Finishing) 變成  
 易達到的目標。

新竹(二) 精修VI	2014/6/10	7/22	8/19	9/16	11/11	12/16
	2015/1/13	2/10	3/17	4/14	5/19	

## 課程資訊

### 上課地點

#### 【台北】

恆逸資訊中心-達利廳  
 / 台北市復興北路99號12樓  
 (捷運南京東路站旁)

#### 【新竹】

金牛頓藝術科技公司  
 / 新竹市建中一路25號2樓

#### 【台中】

中國文化大學台中教育中心  
 / 台中市西屯區臺灣大道三段  
 658號3樓 (Rich 19 大樓)

#### 【高雄】

國立科學工藝博物館-南館  
 / 高雄市三民區九如一路797號  
 (107研討室)

### 報名專線

湧傑 Yong Chieh

#### 北區

(02) 27788315  
 楊文君 分機#122

#### 中區

(04) 23058915 張馨云

#### 南區

(07) 2260030 王慧靜

\* 每次上課請依最新一期  
 IJOI 公告為主

## Create Your Own Path to Glory

In the last three months, I have travelled and presented in all 5 continents, a personal first and a great source of inspiration and learning of not only an orthodontic nature.

Highlights of my trips include being introduced by Dr. Larry Andrews (*he must be somebody*); receiving not only honorary membership of the South African Society, but also the first ever standing ovation for a guest speaker in their 50 year history; being told I had put Cartagena, Columbia on the orthodontic map. Also I received many comments "very difficult to go back to traditional lectures"; "If people remember anything of this after 10 years, it will be Chris Chang" and a **Paraguay** Dr. who told me her family thought she was crying about a love story, when actually she was watching one of my youtube lessons and couldn't control her emotions!

One question which particularly made me think was a question from a South African who asked, "Why can Taiwan produce Chris Chang?" I don't deny that Taiwan has given me the ability and possibility to flourish, but I also believe that constant observation in life is key to development.

Whilst on safari in Africa, I was reminded of ostriches, which bury their heads in sand to avoid problems. If orthodontists had done that, then Dr Angle would never have created the first edgewise appliance. Furthermore, Dr Larry Andrews' straight wire appliance, Dr Damon's self-ligation system and Taiwan's extra alveolar screw system would also never have come to fruition! We must always have our eyes open, as inspiration comes in many shapes and sizes.

Furthermore, resting on one's laurels is not positive if one wants to further one's career. I personally feel that there are 3 keys to being able to present on the international stage.

1. Good **contents, good case results**
2. Good computer skills, in particular the Keynote software. I have never seen a better one
3. The ability to perform on stage

We are proud that our next annual symposium on November 30<sup>th</sup> 2014 in Taipei will be the first dental symposium to provide the "nuts and bolts" of TED style presentations. I have invited my personal English presentation coach to impart, **Mr. Paul Head**, his expertise and knowledge to you all.

Head up, eyes and ears open. Let inspiration, dedication and conviction flow through you as we continue together furthering our professional skills / on the path to glory.

*Chris Chang*, DDS, PhD, Publisher of IJOI.

### 3 Editorial

#### LIVE FROM THE MASTER

- 4 Face Mask (FM) Protraction with Rapid Maxillary Expansion (RME): Is this complicated modality necessary?

#### IAOI CASE REPORT

- 26 Asymmetric Maxilla with a Functional Shift and Labially Blocked-Out Maxillary Canines
- 52 Oligodontia and Class II Malocclusion Treated with Orthodontics, Bone Augmentation, and an Implant-Supported Prosthesis
- 72 Full Cusp Class II Malocclusion with a Deep Overbite
- 90 Asymmetric Extraction of Adult Orthodontic Treatment

#### FEEDBACK FROM THE WORLD

- 108 Feedback From Beethoven International Workshop in June
- 110 課程心得回饋
- 112 貝多芬獎學金學員心得回饋



Examiner  
Dr. W. Eugene  
Roberts



Examiner  
Dr. Tom Pitts



Examiner  
Dr. John J. J. Lin



Consultant  
Dr. Frederick J.  
Reggenitter



Consultant  
Dr. Tucker Haltom



Consultant  
Dr. J. Michael  
Steffen



Consultant  
Dr. Larry White



Examiner  
Dr. Thomas Han



Examiner  
Dr. Kwang Bum Park



Examiner  
Dr. Homa Zadeh



Examiner  
Dr. Fernando  
Rojas-Vizcaya



Consultant  
Dr. Baldwin W.  
Marchack



Consultant  
Dr. Stephen  
Wallace



Consultant  
Dr. Mark Y. K. Ou



Guest Editor  
Dr. Rungsi  
Thavarungkul



Contributors (left to right):  
Dr. Hong Po Chang, *Consultant*  
Dr. Ming Guey Tseng, *Consultant*  
Dr. John Lin, *Consultant*  
Dr. Frank Chang, *Consultant*  
Dr. Johnny Liaw, *Consultant*  
Dr. Chris Chang, *Publisher*

## Face Mask (FM) Protraction with Rapid Maxillary Expansion (RME): Is this complicated modality necessary?

*The RME/FM approach is very effective for correction of Class III malocclusion, but the method has some disadvantages: heavy force is needed for RME, and the FM requires excellent compliance. This section will pursue the possibility of using relatively simple edgewise mechanics to replace the complicated RME/FM approach. The alternate edgewise treatment option, that is proposed, is predicated on a proper differential diagnosis, emphasis on relatively simple mechanics, avoidance of over-treatment, and providing realistic expectations for the patient, relative to the influence of early treatment on severe prognathic Class III malocclusions. (Int J of Othod Implantol 2014;36:4-21)*

### 1. Development of RME / FM on Class III treatment

In 1944 Oppenheim<sup>1</sup> believed that growth of the mandible could not be controlled, and suggested moving the maxilla forward to counterbalance mandibular protrusion. In the 1960s Delaire et al.<sup>2</sup> stimulated interest in using a face mask for maxillary protraction. Petit<sup>3</sup> modified the Delaire face mask concept, by increasing the amount of force generated by the appliance, thereby decreasing the overall treatment time.

In 1987, McNamara<sup>4</sup> introduced the use of a bonded expansion appliance, with a bilateral section of acrylic occlusal coverage bonded to all teeth in the buccal segments, as anchorage for maxillary protraction. Turley<sup>5</sup> suggested that expansion of the maxilla, prior to protraction, “disarticulates” the maxilla and thus facilitates its forward movement when protracted.

### 2. Treatment timing for the RME / FM approach

The main objective of early face mask treatment is to enhance forward displacement of the maxilla by sutural growth. Histologic studies have shown that the midpalatal suture is broad and smooth during the “infantile” stage (8 to 10 years of age). The suture becomes more squamous and overlapping in the “juvenile” stage (10 to 13 years), and becomes more heavily interdigitated around puberty.<sup>6</sup> Many reports suggest

Dr. John Jin-Jong Lin  
MS, Marquette University  
Chief Consultant of IJOI  
President of TAO ( 2000~2002 )  
Author of *Creative Orthodontics*



that the optimal time for RME/FM is before the age of 8 years. Other articles claim that there is little difference between early (*before 8-10 years old*) or late (*after 8-10 years old*) relative to RME/FM treatment for severe Class III malocclusions.

The limiting factor for Class III treatment is the lack of a clinical appliance that can stop late mandibular growth. Thus, the earlier a patient is treated, the greater the concern about late mandibular growth. Mild to moderate Class III patients can be managed with early treatment without any significant problems. However, early treatment of severe Class III malocclusions is not effective, because the RME/FM cannot stop or even substantially influence mandibular growth. Observation is probably a better approach than early treatment for severe Class III patients. Difficult skeletal Class III problems cannot be effectively managed until growth is complete, so orthopedics during the growing years risks a long, relatively unproductive course of treatment. The patient may be burned out before definitive treatment can be accomplished.

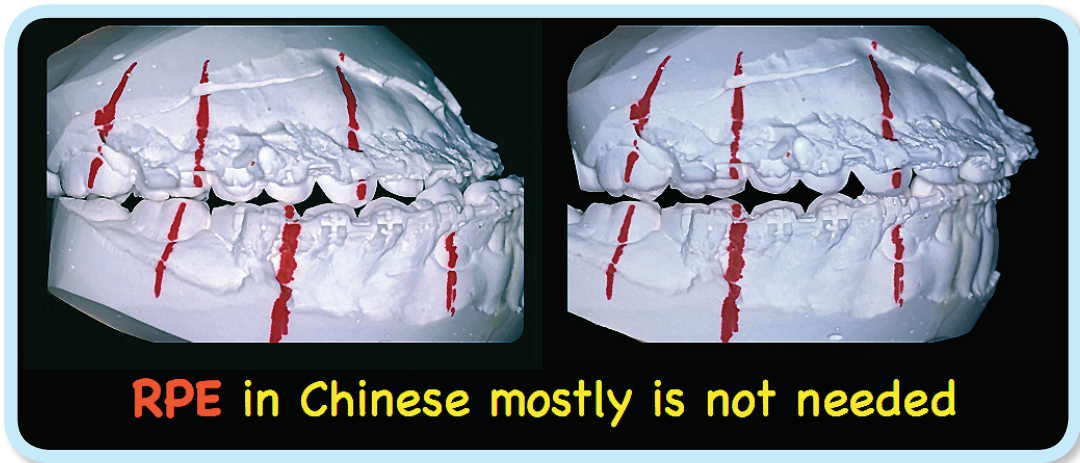
### 3. Is RME really necessary?

In article about rapid palatal expansion (RPE) Haas<sup>7</sup> mentions that expansion alone can advance the maxilla. This publication had a profound influence on many orthodontists, who continue to prescribe RPE for Class III maxillary deficient patients, in hopes of achieving advancement. However a follow-up study by Werz et al.<sup>8</sup> found that maxillary advancement due to RPE treatment is limited and unpredictable; the average amount of advancement was around 0.5mm. So far, there is no definitive, longterm follow-up study that supports substantial maxillary advancement with RPE treatment. However, many orthodontists still believe that RPE combined with face mask protraction (FM + RPE) is effective for treating maxillary deficient patients.

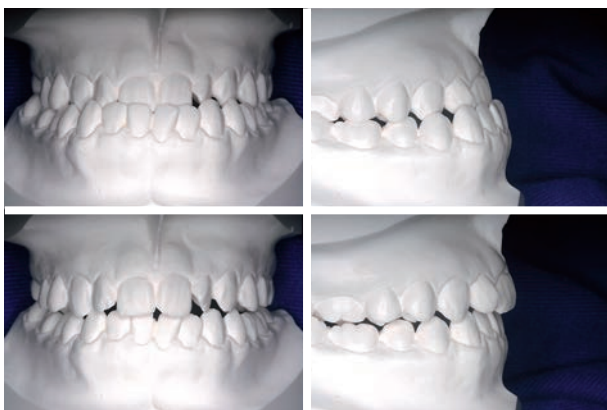
Vaughn<sup>9</sup> and Tortop<sup>10</sup> compared maxillary protraction therapy for Class III malocclusion, with or without rapid palatal expansion, and showed that both are effective for correcting Class III malocclusion. Sugawara<sup>11</sup> used an SAS (*skeletal anchorage system*) mandibular mini-plate to successfully retract the entire mandibular dentition to correct a severe Class III malocclusion. Hugo deClerck<sup>12</sup> prefers maxillary

and mandibular mini-plates, combined with Class III elastics to successfully treat Class III malocclusion. Neither of the latter mini-plate treatment systems used RME (*Rapid Maxillary Expansion*). This review of the literature begs the question: is RME really necessary to effectively treat most Class III malocclusions?

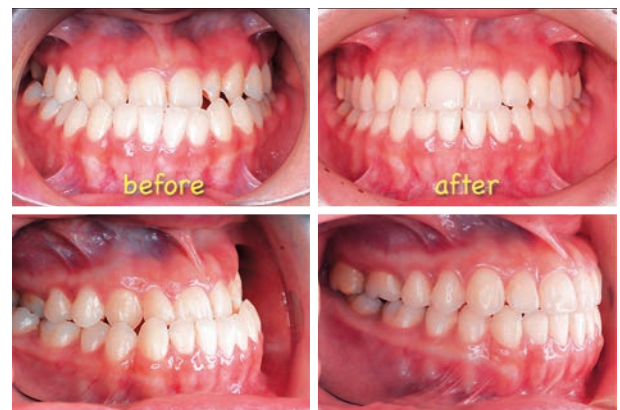RME or RPE may be necessary for some very narrow upper arches, such as cleft lip and palate patients. However, for most Chinese Class III patients, RME is not needed. In preparation for orthognathic surgery on the Chinese Class III patients, Lin<sup>13</sup> found little need for expansion of the maxillary arch. On the contrary, RME often resulted in buccal crossbite of upper second molars (Fig. 1). It was concluded that RME was not indicated for most Chinese Class III malocclusions.



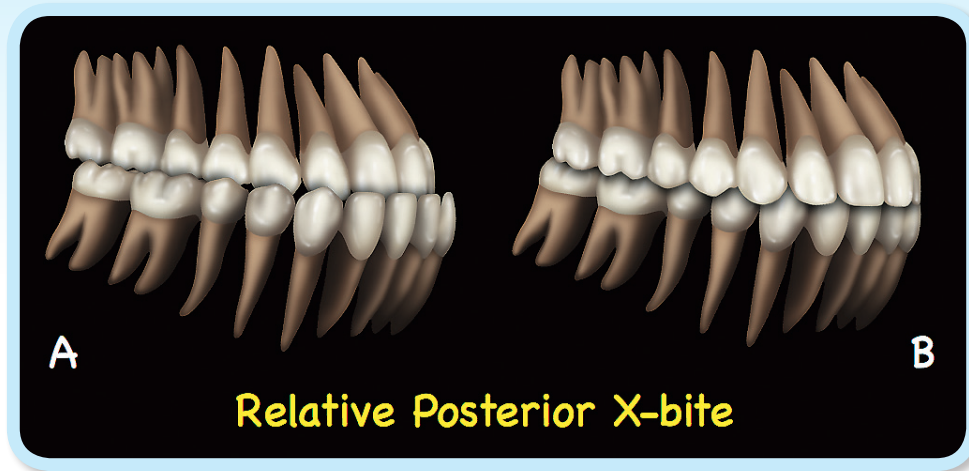
■ **Fig. 1.** A Chinese patient with a severe Class III malocclusion. Before orthognathic surgery, the model was positioned to Class I, but the upper arch not too narrow at all. On the contrary the upper 2<sup>nd</sup> molars were in buccal crossbite, and orthodontic constriction was needed before orthognathic surgery for optimal arch coordination.



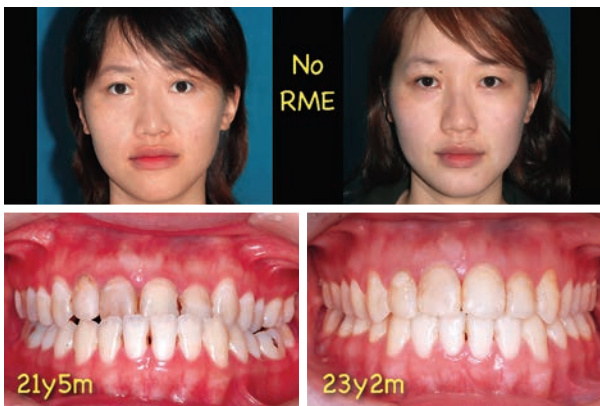■ **Fig. 2A.** A severe Class III malocclusion with buccal crossbite, but after positioning the model into Class I, the buccal crossbite disappeared.



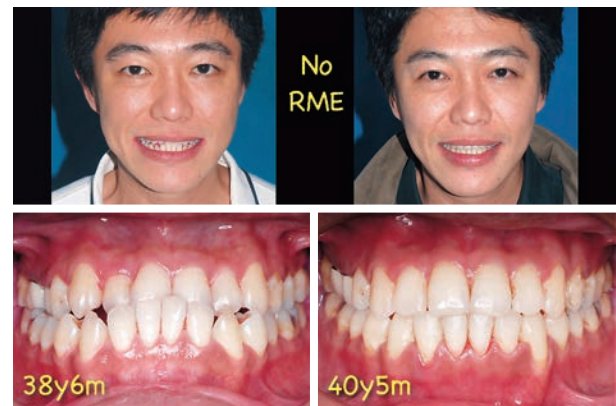■ **Fig. 2B.** The Damon system corrected the Class III relationship to Class I without rapid maxillary expansion. When the sagittal discrepancy was corrected to Class I, the buccal crossbite disappeared.



■ **Fig. 3:** A graphic representation shows the relative buccal crossbite associated with Class III malocclusion.  
 A. Before treatment, there is a complete crossbite of the entire maxillary arch.  
 B. After the Class III buccal segments are corrected to Class I, the crossbite disappears.



■ **Fig. 4:** Using the Damon system, the Class III was corrected to Class I without rapid maxillary expansion. Once the anteroposterior relation was corrected to Class I, the buccal crossbite was gone.



■ **Fig. 5:** The Damon system was used to correct this Class III malocclusion without rapid maxillary expansion. Just after the anteroposterior relation was corrected to Class I, the buccal crossbite gone.

Fig. 2A shows initial casts of a severe Class III malocclusion. When the casts were positioned in a Class I molar relationship, most of the buccal crossbite disappeared. Thus the posterior crossbite is not a transverse but a sagittal problem. Correction of the malocclusion with the Damon system (Fig. 2B) confirmed the prognosis predicted from repositioning the casts (Fig. 2A). A graphic of a relative Class III posterior crossbite shows that when the anterior-posterior aspect of a typical Class III malocclusion is corrected, the buccal crossbite disappears (Figs. 3). Further clinical documentation of this concept is shown in Figs. 4 and 5. Two Class III malocclusions with varying degrees of posterior crossbite, or at least end-to-end occlusion, were treated to Class I. Note, in each instance, the relative buccal crossbite self-corrected after the Class III buccal segments were corrected to Class I.

## 4. RME/FM Treatment for Class III Malocclusions

### (A) Most popular method for early Class III treatment

Chin cap therapy does not change the inherent growth pattern,<sup>14</sup> so it is difficult to achieve a favorable profile for patients with a severe mandibular protrusion. The obvious alternate strategy is to enhance the growth expression of the maxilla. The Delaire<sup>2</sup> face mask method was modified and popularized by Petit,<sup>3</sup> McNamara,<sup>4</sup> and Turley.<sup>5</sup> As summarized in Fig. 6, RME/FM has become the most popular method for early treatment of Class III.<sup>15,16,17,18</sup>

#	Name	Year	Journal	Original	Final	Years of Follow-up (Age range)	Success rate	Research group
1	Hagg	2003	EJO	30	21	8yrs follow-up (8.4y-16.4y)	67%	Hong Kong
2	Westwood	2003	AJODO	34	34	6yrs 7mo follow-up (8y3m-14y4m)	76%	Michigan
3	Wells	2006	Angle O	41	41	5yrs (age?)	75%	North Carolina
				41	22	10yrs (age?)	70%	
4	Masucci	2011	AJODO	30	22	8.5yrs follow-up (9.2y-18.7y)	73%	Italy

■ Fig. 6: Long term follow up studies of RME/FM show that the failure rate is proportional to the length of the follow-up period.

### (B) Lack of a randomized clinical trial

Most of the RME/FM studies are based on Caucasian patients, so the samples are small because Class III malocclusions are rare in this ethnic group. So it is difficult to collect a large unbiased sample from any office or institution. Currently most of the RME/FM treatment recommendations are based on reports from small and often poorly controlled studies.<sup>19,20</sup> No well designed, randomized clinical trials have been reported for any ethnic groups.

### (C) The problems with RME/FM studies

#### (1) Appropriate diagnosis

There are no standard methods for Class III patient selection. Thus, simple dentoalveolar problems are included with severe skeletal Class III cases. So, the same RME/FM treatment method has been used on all subjects regardless of the specific characteristics or severity of there Class III malocclusions.



**(a) Profile assessment in CR**

No published RME/FM studies have used the facial profile in CR to distinguish the severity of the malocclusion. Without an appropriate differential diagnosis, relative simple Class III cases are treated with the complicated RME/FM method, when a simple fixed orthodontics appliance may be more appropriate. Conversely, RME/FM treatment for a severe skeletal Class III malocclusion may be a waste of time and effort, for both the patient and the doctor, because the treatment will relapse and eventually require surgery anyway.

When planning a surgical correction, it is advantageous to begin with a stable malocclusion rather than one that is relapsing from an unstable correction. There may be a place for the RME/FM method, but it will probably be patients with moderate Class III malocclusions that are too severe for orthodontics alone, but not so severe that they will require surgery. The problem has been a lack of the routine application of a reliable differential diagnosis method to assign patients to the most appropriate treatment method.

**(b) Class III molar relationship**

The intermaxillary occlusal relationship can be evaluated in many ways, such as classification of the molars, canine relationships, and overjet. Most of the published studies only mention the Angle molar classification for Class III evaluation. Since not all Class III patients have an anterior crossbite, the molar classification is usually considered to be the most reliable index for assessing the intermaxillary discrepancy. It is proposed that modest Class III molar relationships can be treated with routine fixed orthodontics appliances, and the complex RME/FM is not indicated.

**(c) Functional shift**

The presence or absence of a functional shift is rarely mentioned in RME/FM reports. The greater the functional shift, relative to the intermaxillary discrepancy, decreases the indication for RME/FM intervention. Some studies<sup>15,18</sup> considered a functional shift to be an exclusion criteria. This approach excludes many Class III cases because most young Class III patients have a functional shift. Excluding patients with functional shifts tends to bias the sample toward more severe, skeletal malocclusions, that are less likely to respond favorably to RPE/FM intervention for early orthopedic correction.

**(d) Unreliable Wits appraisals**

Wits analysis has been used for screening Class III patients, but the reliability of this index has been questioned.<sup>21</sup> Westwood<sup>16</sup> used -1.5mm or less, and Masucci<sup>18</sup> favored -2.0mm or less, as an indicator for skeletal Class III malocclusion. However, it is currently proposed that Wits is not a consistent and reliable index for assigning Class III malocclusions for RME/FM treatment.

### (e) Cephalometric evaluation.

There are no specific cephalometric standards for selection of Class III patients for RME/FM treatment. The most common criteria has been a normal mandible and deficient maxilla, but that approach is a relatively subjective criteria for selecting a specific treatment modality.

From the current review of literature, it appears that the criteria for RME/FM is based on anterior crossbite or Class III molars in CO. This approach fails to differentially diagnose the relatively simple from very difficult Class III malocclusions. A reliable differential diagnosis is essential to realistically assign patients to treatment methods, and reliably interpret the results.

## (2) Late mandibular growth

Wells<sup>17</sup> reported that the failure rate for correction of Class III malocclusion with RME/FM at 5 year recall was 20%, and it increased to 25% at 10 year recall. Late mandibular growth was the primary contributing factor.

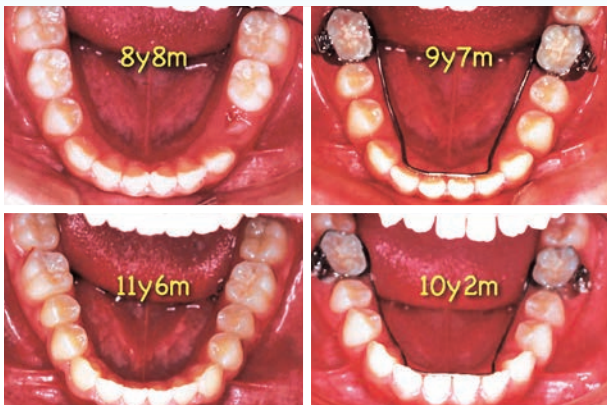
At present, there is no dentofacial orthopedic appliance that can control late mandibular growth. This is the major problem for early RME/FM treatment. Lack of an adequate differential diagnosis results in a relatively high failure rate for severe Class III malocclusions. It would be better to determine which patients are unlikely to have a satisfactory longterm result with RME/FM, and then delay definitive treatment until growth is complete.

## (3) Early treatment and the waste of the precious E space

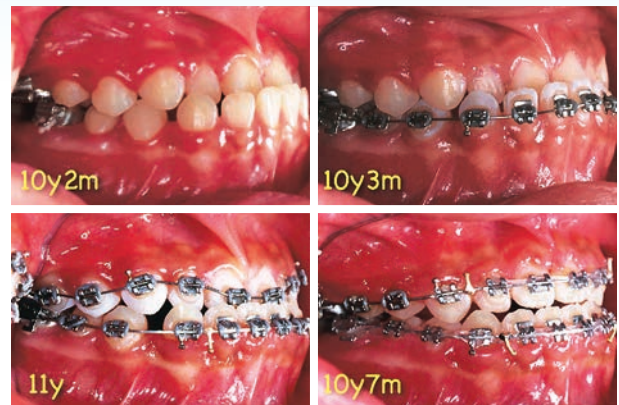
According to Delaire,<sup>2</sup> Class III Caucasian patients should be treated around age 8 to 10 years old to obtain the optimal orthopedic effect. This approach was deemed appropriate because the axial inclination of the maxillary incisors was usually normal, or lingually inclined, and the nasolabial angle was normal to obtuse. However, Asian Class III malocclusions usually are characterized by flared (*labially inclined*) upper incisors and an acute nasolabial angle. Early face mask protraction, usually tips the upper incisors labially, producing upper lip protrusion and a more acute nasolabial angle.

In Ngan's<sup>22</sup> Chinese Class III treatment sample the upper incisor angulation from 93.5 to 103.0°. For a similar Korean RME/FM sample, Sung's<sup>23</sup> post-treatment patient records showed upper incisor flaring, maxillary lip protrusion and a more acute nasolabial angle. The patients may become bimaxillary protrusions, and extractions are necessary to correct the facial profile. These results question the value of early treatment with RME/FM.

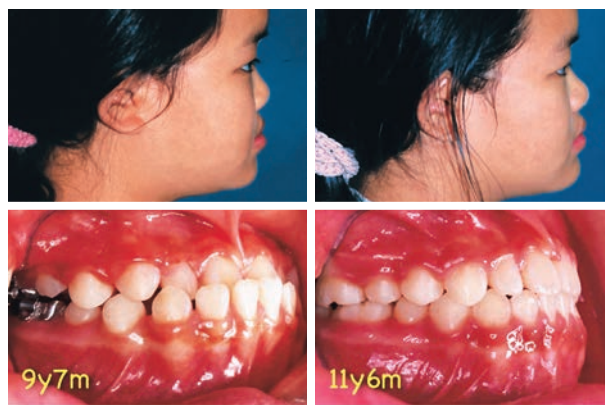An alternate approach to Class III treatment for patients, with labially inclined incisors and a acute nasolabial angle, is to preserve the E space with a lingual holding arch. After the lower permanent teeth have erupted, retract the mandibular anterior segment to correct the anterior crossbite without flaring the maxillary incisors. By utilizing the lower E-spaces, the protrusion of the upper lip and the decrease in the nasolabial angle are avoided. This approach decreases the risk that a second phase of extraction treatment will be needed (Fig 7).



■ **Fig. 7A:**  
*In a anterior crossbite patient, the lower E-space was preserved with a lower lingual arch at the age of 8y8m. By 9y7m there is plenty of E-space for retracting the incisors to correct anterior crossbite.*



■ **Fig. 7B:**  
*After waiting until most of the permanent teeth erupted, the anterior crossbite was corrected mostly by closure of lower E-space. The upper incisor position was maintained.*



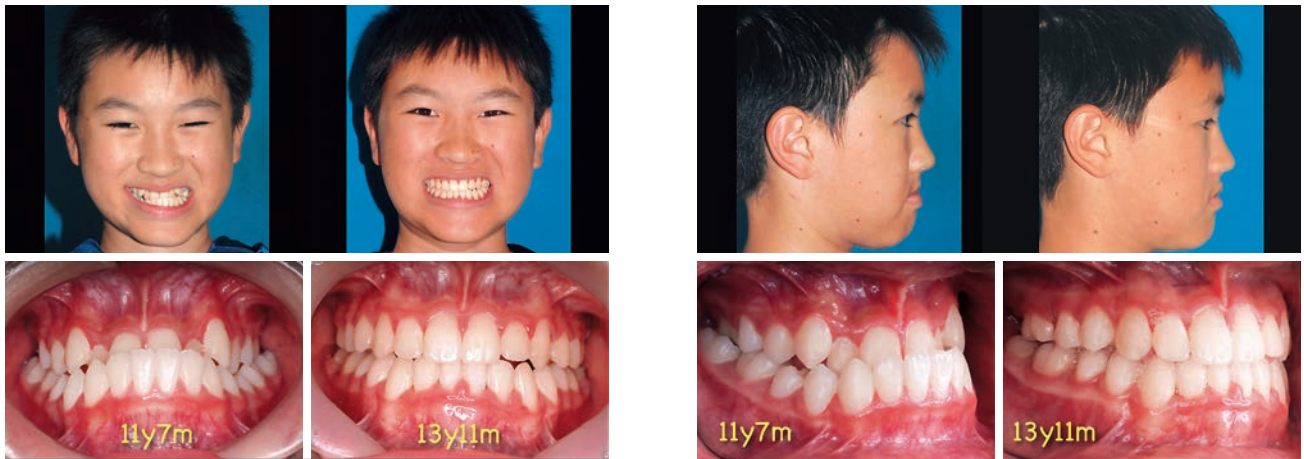
■ **Fig. 7C:**  
*By using the lower E-space, the anterior crossbite was corrected by retracting the lower incisors. The upper incisor inclination and acute nasolabial angle were maintained. Due to late use of the E-space, extraction treatment can be avoided.*

#### (4) Conservative edgewise treatment may be superior to RME/FM

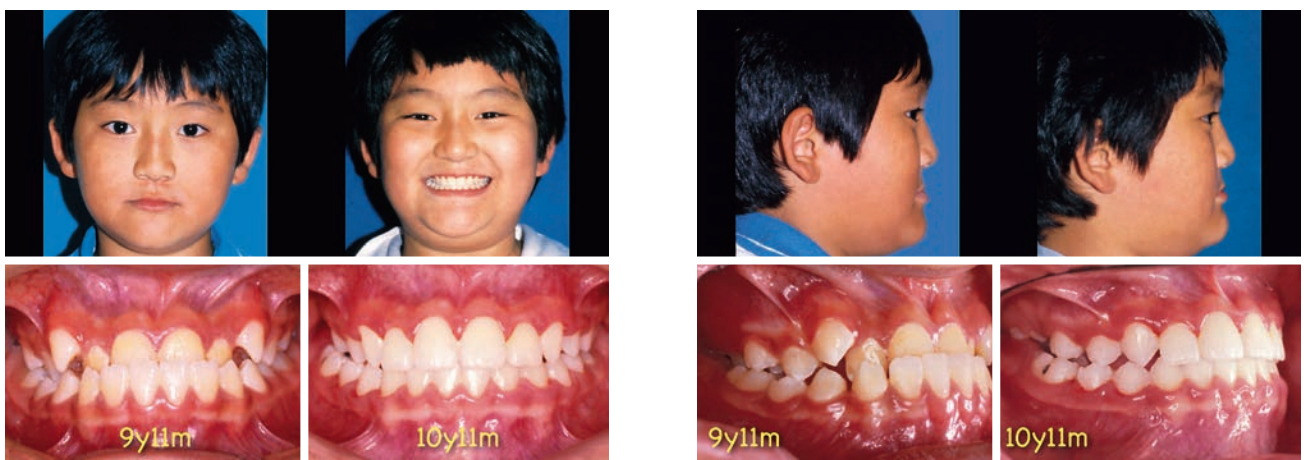In a RME/FM study reported by Westwood,<sup>16</sup> the pre-treatment molar relationship were mild Class III or even Class I, compared to the control group. In that study, it appears that the easier Class III malocclusions were selected for RME/FM treatment. Four long term follow up studies, of RME/FM intervention, report ~24-33% failure rate.<sup>15,16,17,18</sup> Retreatment with extractions and/or orthognathic surgery is needed for the patients who experienced failure. It can be concluded that many of

the patients, who received early intervention, would have been better served with conservative edgewise therapy. The latter is clearly indicated for patients with an orthognathic profile in CR.

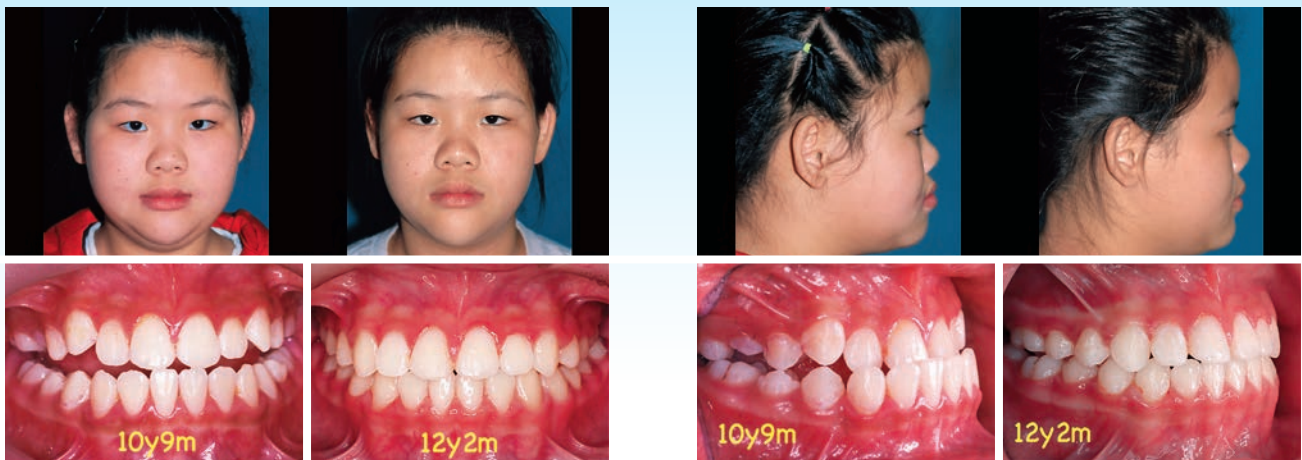
Figs. 8-10 document the diagnosis and conservative edgewise treatment for three severe Class III patients, who would not normally be candidates for this approach. However, the patient and their parents requested early treatment with a fixed orthodontic appliance. All the three patients were treated to Class I. They can enjoy the improved esthetics and function afforded by early treatment, but may still require additional treatment due to expression of late mandibular growth. There was no need to use the RME/FM approach to achieve the same result.



■ Fig. 8: The severe Class III was corrected to Class I with the Damon system. RME/FM treatment was not needed.



■ Fig. 9: A severe Class III case, was treated to Class I occlusion with a standard edgewise appliance without using any complicated RME/FM treatment.



■ Fig. 10:

A severe Class III case, was corrected to Class I with the Damon system, without using any complicated RME/FM treatment.

### (5) Failure of RME/FM may be related to treating severe Class III patients

From the published composite cephalometric tracings, it is clear in Wells<sup>17</sup> report that the failure group had a larger Class III molar relationship initially. It appears that the successfully treated group was predominately mild Class III patients, while the failure group was largely more difficult Class III malocclusions. This is another example where the successful group was composed of relatively mild malocclusions, amenable to conservative treatment with routine fixed appliances. A passive self-ligating bracket system can effectively treat these mild Class III cases in an expeditious manner. The more difficult Class III can also be treated early with conservative mechanics, but follow-up evaluation is recommended after mandibular growth is completed. As previously discussed, RME/FM is not helpful for severe Class III patients in the long term because they usually require definitive treatment after growth is complete.

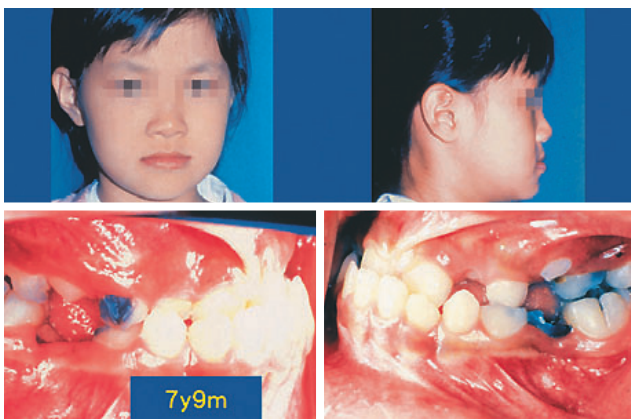
### (6) Normalization of growth for skeletal Class III malocclusions

Burns et al.<sup>24</sup> considered the limits for Class III camouflage treatment. They suggested that it was important to use a chin cap or protraction face mask, to normalize the underlying skeletal discrepancy. However, clinical trials of the "normalization" concept have failed to produce consistent results. Sugawara<sup>14</sup> concluded that it is difficult to achieve a favorable profile correction with orthopedic chin cap therapy in patients who have severe mandibular protrusion. A series of long term follow up studies of RME/FM treatment show that early intervention fails to achieve a satisfactory correction in up to a third of Class III malocclusions.<sup>13,14,15,16</sup> These clinical data indicate that normalization the skeletal growth pattern in Class III patients is unlikely.

For mild Class III problems, it may be possible to achieve an adequate camouflage result, that will be satisfactory longterm. However, if early treatment is desired for a skeletal Class III malocclusion,

it is important for the clinician to emphasize that treatment, prior to completion of mandibular growth, is usually temporary. If patients and the family have unrealistic expectations, they will not only be dissatisfied with the predictable relapse, but will probably also lose confidence in the clinician.

According to the cases documented in Figs. 11 and 12, RME/FM is capable of advancing the maxilla in a short period of time to improve the mid face concavity (Figs. 11A-C). However, this treatment does not normalize the growth pattern. It is a short-term camouflage effect that is likely to relapse with additional mandibular growth (Fig.11D). Fig. 12 shows a 7y1m male, treated to a good result at

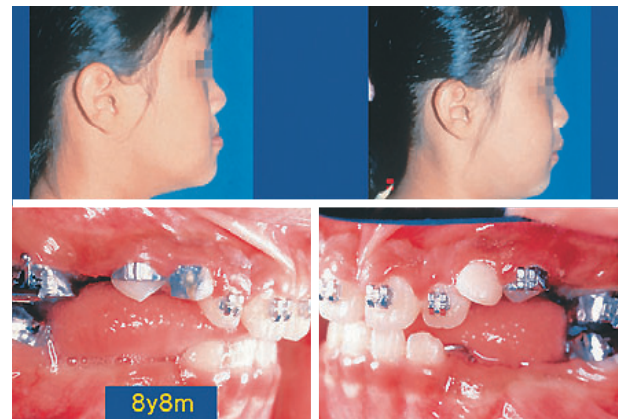


■ Fig. 11A: 7y9m

**Profile :** Prognathic.  
**Class :** Severe Class III molar  
**Functional Shift:** Yes

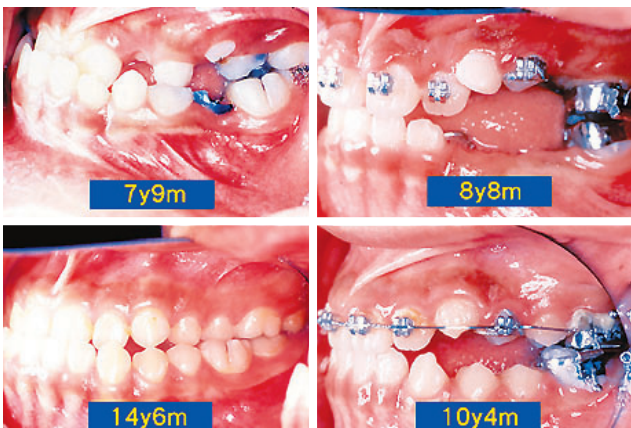
A severe Class III patient with prognathic profile in CR and a functional shift. The prognosis is not good.

(Courtesy Dr. Tony Wu).



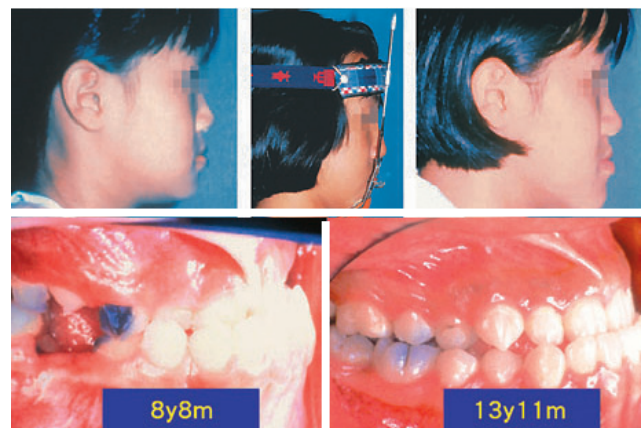
■ Fig. 11B: 8y8m

The patient shown in Fig. 11A had received RME/FM treatment. The profile became orthognathic within a short period of time. Hence, using RME/FM can produce a short-term orthopedic effect.



■ Fig. 11C:

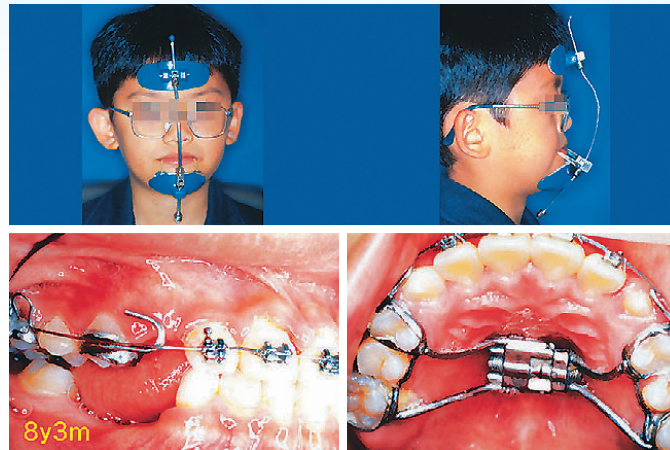
**7y9m~14y6m:** This Class III malocclusion patient underwent RME/FM treatment to achieve a Class II occlusion. At 1y8m later (age 10y4m), this patient had a Class I occlusion with shallow anterior overbite. By 14y6m of age, a complete relapse had occurred and the resulting Class III occlusion had severity similar to the pre-treatment condition.



■ Fig. 11D:

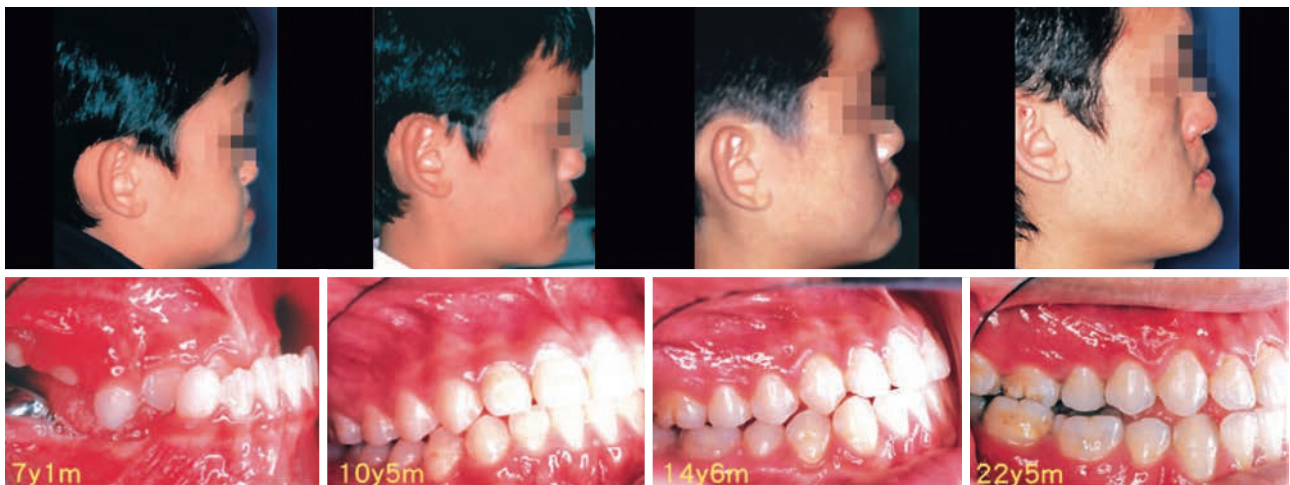**8y8m~13y11m:** Although RME/FM produced an adequate treatment result short-term, but long-term follow-up showed a complete relapse to a severe Class III malocclusion with a prognathic profile.

age 10y5m with RME/FM treatment, who subsequently relapses to a severe Class III malocclusion by about 22 years of age. These results demonstrate that RME/FM treatment is not capable of normalizing growth to produce a satisfactory, long-term orthopedic effect. RME/FM treatment in the mixed and early permanent dentition should be considered a temporary measure.



■ Fig. 12A:

A Class III patient with a severe Class III molar relationship and prognathic profile, received early RME/FM treatment. (Courtesy Dr. Mogan Shen)



■ Fig. 12B: 7y1m

**Profile :** Severe Prognathic

**Class :** Severe Class III malocclusion

**Functional Shift :** No

This is a patient had a severe prognathic profile and Class III malocclusion, but no functional shift. He was treated with RME/FM.

**10y5m:** 6 months after RME/FM treatment, the crossbite was corrected, overbite was decreased, and the facial profile was only slightly prognathic.

**14y6m:** Follow-up 4y and 1m after treatment, showed that the molar and canine had relapsed to Class III occlusion, and the original prognathic profile had returned.

**22y5m:** Mandible continued to grow and develop into a severe Class III malocclusion with a prognathic profile that is worse than when the patient was younger. This patient requires retreatment with orthognathic surgery.

## (7) Summary of RME/FM

In the short term, the RME/FM appliance appears to produce a substantial orthopedic effect, but long term, this favorable response is usually negated by the late mandibular growth. A better approach is to perform a differential diagnosis, to separate the mild from the severe Class III malocclusions, rather than performing early orthopedic RME/FM treatment on all of them.

Patients who are Class I or slightly Class III in CR are best treated with fixed appliances. More severe Class III patients will probably require definitive treatment with orthognathic surgery once growth is complete. If the more severe Class III patients request early treatment, and understand that the result is likely to be temporary, they are best treated with a fixed appliance like the Damon system. The RME/FM approach is more complex and cooperation dependent.

### Facts about RME/FM Treatment

Short term orthopedics (+)

Long term orthoepdics (-)

Useful on easy mild Class III

Useless on severe Class III

#### ■ Fig. 13:

**RME/FM treatment:** mild Class III can be treated with fixed appliances, but severe Class III must wait for growth to cease.

## (8) Mini-plate protraction of the maxilla

TADs technology cannot replace proper diagnosis. Fig. 14 is a brief analysis of three published reports outlining the treatment of anterior crossbite. The first report<sup>35</sup> is about Le Fort I surgery combined with maxillary protraction. The second article<sup>26</sup> uses maxillary mini-plates for maxillary protraction. The third article<sup>12</sup> employs four mini-plates for skeletal anchorage to treat a Class III malocclusion: the plates are placed bilaterally in both the posterior maxilla and anterior mandible (*lower canine*) areas:



	Article	Malocclusion Type	Critique
1	Küçükkeleş N, et al 2011 (Le Fort I+RME/FM)	Class I anterior crossbite.	Should be an easy anterior crossbite treatment, by using the E-space; there is no need for Le Fort I surgery.
2	Cha et al. 2011 (mini-plate/FM)	A skeletal Class III with maxillary deficiency and mandibular prognathism. 8y5m - age 14y?	<ul style="list-style-type: none"> <li>• Lack of long term follow up</li> <li>• Age of patient was not provided</li> <li>• Waste of precious lower E-space</li> </ul>
3	Hugo De Clerck (mini-plate/mini-plate)	Case 1: Class III, functional shift 10y - 11y8m	No beginning CR profile, should be an easy orthodontic case.
		Case 2: Class I, 10y2m - 12y1m	Creates CII problem. Over treatment to Class II, no need.
		Case 3: Severe Class III sub 11y - 15y9m	Severe one, the prognathic profile and asymmetry will relapse.

■ Fig. 14: Critique of published reports of Class III treatment

### (1) Küçükkeleş et al. Report

*"Rapid maxillary expansion compared to surgery for assistance in maxillary face mask protraction. Küçükkeleş N, et al Angle Orthod 2011 Jan;81(1):42-49."*

#### Basic Information:

This study compared 18 cases treated by RME/FM versus 16 cases treated by incomplete Le Fort I osteotomy and RME/FM. The conclusion of this study finds that the surgically assisted FM treatment was more rapid and effective in maxillary protraction compared to the RME and FM treatment.

#### Critique:

1. In this article, only one case was treated with an incomplete Le Fort I osteotomy plus RME/FM. The female patient had a straight profile, plenty of E-space, Class I molar, and an anterior crossbite. *This case could be corrected with routine orthodontics by conserving the E-space, for retraction of the lower incisors, to help correct the crossbite.*

2. An appropriate method for differential diagnosis helps avoid invasive surgical treatment if there is not a clear indication. This finding highlights the importance of carefully examining case reports relative to case classification, diagnosis and long-term results.
3. When a Class I or slight Class III patient with an anterior crossbite is treated with RME/FM, the correction often results in the buccal segments becoming Class II. If there was a substantial functional shift at the start of treatment, an excessive overjet and retrognathic profile can occur, indicating the RME/FM approach was inappropriate. Thus, a reliable differential diagnosis before beginning treatment is critical to efficient management of anterior crossbite malocclusions.

## (2) Cha et al. Report

*"Maxillary protraction with miniplates providing skeletal anchorage in a growing Class III patient. Cha BK, et al. Am J Orthod Dentofacial Orthop 2011 Jan;139(1):99-112."*

### Basic Information:

This is a case report for a female with a Class III subdivision malocclusion. The patient was aged 8 years and 5 months and her chin deviated to the right side. She underwent 14 months of miniplate/FM protraction followed by finishing with fixed appliances. The patient was followed for 27 months after treatment. No precise age was provided for the final records, but it is estimated that she was ~14 years old.

### Critique:

1. The facial profile photograph appears to be a bimaxillary protrusion. If that was the chief complaint, four quadrants of asymmetric premolar extraction might be a better treatment option. That would be a simpler and less invasive solution, compared to miniplates and face mask.
2. If the patient preferred nonextraction treatment, then a lingual arch could be placed to preserve the large mandibular E-spaces. Once the buccal segments erupted, the anterior crossbite could be corrected primarily by retraction of the lower anterior segment using the E-spaces for anchorage. Using this approach, the lips could be retracted and there would be no need for invasive mini-plate/FM treatment.
3. The original diagnosis overemphasized maxillary deficiency and failed to consider the original dental and skeletal asymmetry. After 14 months of protraction treatment, the skeletal and dental midlines

were still asymmetric, and remained so at 27 months after appliance removal. In this patient, the invasive mini-plate and protraction treatment did not lead to an optimal result. Routine orthodontics mechanics utilizing the E-spaces, and/or asymmetric extraction of premolars would probably have produced a better result.

### (3) De Clerck Report.

*"Orthopedic traction of the maxilla with miniplates: a new perspective for treatment of midface deficiency. De Clerck H, et al. J Oral Maxillofac Surg 2009;67:2123-9."*

#### Basic Information:

**Case 1:** The patient has a functional shift and presents with a mild Class III relationship. There is no facial profile in CR, so the three rings differential diagnosis is not possible. If the facial profile was orthognathic in CR, a relatively simple orthodontics treatment plan would have been possible.

**Case 2:** There was a very small mesial step, so it classified as a borderline Class I case.

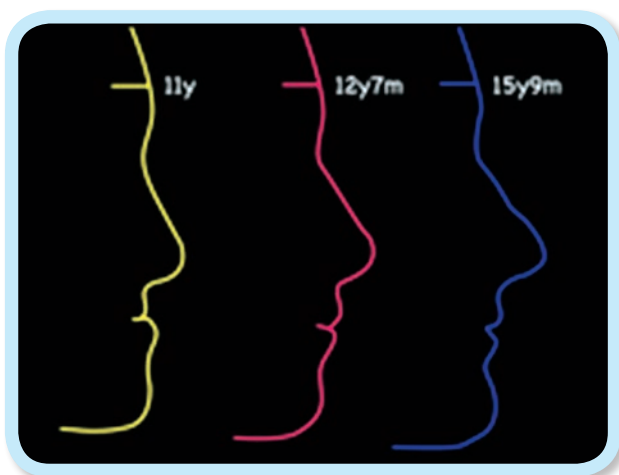**Case 3:** Indeed, this is a very severe Class III asymmetric malocclusion.

#### Comments:

**Case 1:** This appears to be a mild Class III, amenable to routine orthodontics treatment, without invasive mini-plates for skeletal anchorage.

**Case 2:** This is basically a Class I case that was treated to Class II, with an overjet.

**Case 3:** This is a very severe Class III malocclusion; invasive mini-plates are warranted.



■ Fig. 15:

*From the superimposition of Hugo De Clerck's case 3, at age 15y9m, the mandible grew forward a great deal, even though the Class III elastics between the miniplates had protracted the maxilla considerably. The treatment did not stop late mandibular growth. (diagram made from Hugo De Clerck's published records)*

### Critique:

1. Placing mini-plates over in the posterior maxilla avoids problems with teeth, but the bone is thin, so there is concern about failure. In young patients it is difficult to place a mini-plate in the mandibular anterior region because of the potential to damage the developing canines. Overall, mini-plates in young patients is a technic sensitive surgery, requiring a well trained and experienced surgeon. Few orthodontists have access to such surgeons.
2. Mini-plates and long periods of elastics wear is worthwhile if a severe prognathic Class III patient can be corrected permanently. However, the results of case 3 appear to be only a temporary solution. The follow up records indicate the overjet was substantially reduced at the age of 15y9m, and in future follow up, a more asymmetrical and prognathic profile is expected (Fig 4).
3. Cases 1 and 2 did not require invasive surgery. Routine orthodontic mechanics, such as the Damon system, could treat these patients to a satisfactory result without surgery.
4. The mini-plate anchorage protocol can produce amazing skeletal results, but it is curious that no RME was used. RME is usually necessary for treatment of skeletal Class III, Caucasian patients.

### References

1. Oppenheim A. A possibility for physiologic orthodontic movement. *Am J Orthod Oral Surg* 1944;30:277-328, 345-368.
2. Delaire VJ, Verdon P, Floor J. Ziele und Ergebnisse extraoraler Züge in postero-anteriorer Richtung in Anwendung einer orthopädischen Maske bei der Behandlung von Fällen der Klasse III. *Fortschr Kiefer Orthop* 1976;37:246-262.
3. Petit H. Adaptations following accelerated facial mask therapy in clinical alteration of the growth face. In: McNamara JA Jr, Ribbens KA, Howe RP (eds). *Clinical Alteration of the Growing Face*, monograph 14, Craniofacial Growth Series. Ann Arbor, MI: University of Michigan, 1983.
4. McNamara JA Jr. An orthopedic approach to the treatment of Class III malocclusion in growing children. *J Clin Orthod* 1987;21:598-608.
5. Turley P. Orthopedic correction of Class III malocclusion with palatal expansion and custom protraction headgear. *J Clin Orthod* 1988;22:314-325.
6. Melsen B, Melsen F. The postpubertal development of the palatomaxillary region studied on human autopsy material. *Am J Orthod* 1982;82:329-342.
7. Haas AJ. Rapid expansion of maxillary dental arch and nasal cavity by opening the midpalatal suture. *Angle Orthod* 1961;31:73-90.
8. Wertz RM, Dreskin M. Midpalatal suture opening: a normative study. *Am J Orthod* 1977;71(4):367-81.
9. Vaughn GA, Mason B, Moon HB, Turley PK. The effects of maxillary protraction therapy with or without rapid palatal expansion: a prospective, randomized clinical trial. *Am J Orthod Dentofacial Orthop* 2005 Sep;128(3):299-309.
10. Tontop T, Keykubat A, Yuksel S. Facemask therapy with and without expansion. *Am J Orthod Dentofac Orthop* 2007;132:467-474.
11. Sugawara J, et al. Distal movement of mandibular molars in adult patients with the skeletal anchorage system. *Am J Orthod Dentofacial Orthop* 2004;125:130-8.

12. De Clerck HJ, Cornelis MA, Cevidanes LH, Heymann GC, Tulloch CJ. Orthopedic traction of the maxilla with miniplates: a new perspective for treatment of midface deficiency. *J Oral Maxillofac Surg* 2009 Oct;67(10):2123-9. doi: 10.1016/j.joms.2009.03.007.
13. Lin JJ. *Creative Orthodontics: Blending the Damon system & TADs to manage difficult malocclusions*. 2<sup>nd</sup> ed. 2010, Yong Chieh Enterprise Co, Ltd., Taiwan.
14. Sugawara J, et al. Long-term effects of chin cap therapy on skeletal profile in mandibular prognathism. *Am J Orthod Dentofacial Orthop* 1990 Aug;98(2):127-33.
15. Hägg U, et al. Long-term follow-up of early treatment with reverse headgear. *Eur J Orthod* 2003 Feb;25(1):95-102.
16. Westwood PV, et al. Long-term effects of Class III treatment with rapid maxillary expansion and facemask therapy followed by fixed appliances. *Am J Orthod Dentofacial Orthop* 2003 Mar;123(3):306-20.
17. Wells AP, et al. Long-term efficacy of reverse pull headgear therapy. *Angle Orthod* 2006 Nov;76(6):915-22.
18. Masucci C, et al. Stability of rapid maxillary expansion and facemask therapy: a long-term controlled study. *Am J Orthod Dentofacial Orthop* 2011 Oct;140(4):493-500.
19. Proffit WR. *Contemporary Orthodontics*. 4<sup>th</sup> ed. St Louis: C.V. Mosby; 2007, p. 300.
20. Borrie F, Bearn D. Early correction of anterior crossbites: a systematic review. *J Orthod* 2011 Sep;38(3):175-84. doi: 10.1179/146531211414443.
21. Lin JJ, Cheung W. Reliability of Wits analysis. *Clinical Dentistry* 1984;4(2):88-92.
22. Ngan PW, Hagg U, Yiu C, Wei SH. Treatment response and long-term dentofacial adaptations to maxillary expansion and protraction. *Semin Orthod* 1997 Dec;3(4):255-64.
23. Sung SJ, Baik HS. Assessment of skeletal and dental changes by maxillary protraction. *Am J Orthod Dentofacial Orthop* 1998 Nov;114(5):492-502.
24. Burns NR, Musich DR, Martin C, Razmus T, Gunel E, Ngan P. Class III camouflage treatment: what are the limits? *Am J Orthod Dentofacial Orthop* 2010 Jan;137(1):9. e. 1-9. e.13.
25. Küçükkeleş N, et al. Rapid maxillary expansion compared to surgery for assistance in maxillary face mask protraction. *Angle Orthod* 2011 Jan;81(1):42-49.
26. Cha BK, et al. Maxillary protraction with miniplates providing skeletal anchorage in a growing Class III patient. *Am J Orthod Dentofacial Orthop* 2011 Jan;139(1):99-112.





2014 iAOI年度大會

# 牙科簡報也可以像 TED talk 一樣？

分享說話精簡、打動人心的秘訣

11/30(日)09:00 ~ 17:00

台灣金融研訓院

(台北市中正區羅斯福路三段62號)

## 報名方式

報名專線: 03-5711377

線上報名: <http://iaoi.org>

## 報名費用

	10/31前報名	11/01後報名
會員價	3600元	5000元
非會員價	5000元	7000元

入會費	年費	第一階段資格考
1000元	3000元	9000元 <del>12000元</del> (含入會費、年費、考試及證書費)

- 「會員」為已註冊並繳交入會費、2014年費之醫師。
- 學生、住院醫師享「非會員價 半價優惠」。
- 報名本活動後，恕不退費。

## 帳戶資訊

戶名：國際矯正植牙學會

銀行代號：815 日盛銀行 光復分行

帳號：105-273-762-10000

\*匯款後，請務必來電03-5711377核帳

TED簡報是目前公認最跨領域、國際化、切合時代脈動的一系列國際演講。講者必須要在短短18分鐘內有效倡導自己認為「值得散播的概念」(ideas worth spreading)。

這類精簡、實務的演講風格與我們iAOI的個案報告十分類似。為此，TED這種演講形式對有志從事演講的實務工作者和教育者來說，就是非常重要的訓練模式。

今年，除了請到國內知名的矯正植牙專家外，我們特別邀請張慧男醫師私人的寫作和公開演講教練-Paul Head來為我們現場分析這幾個專家的演講技巧和提昇表現的方法。除此之外，我們也有五場院士候選人和一位院士發表個案報告，您也可以運用一樣的技巧來評判這幾位院士的表現。

參與此盛會，您不但可以了解最新的矯正植牙治療趨勢，也可以有效提昇您的演講功力。請您千萬不要錯過！

## 2014 iAOI年度大會 議程表

時間	議程	主講者
08:00-09:10	iAOI 第一階段Board 資格考	
09:10-09:20	報到	
09:30-11:00	成人複雜案例	張慧男醫師、Mr. Paul Head
11:00-11:30	中場休息	
11:30-12:10	Diplomate 口頭報告一、二	李雙安、陳惠華醫師
12:10-13:00	午餐	
13:00-13:50	咬合傾斜之處理	廖炯琳、石伊弘醫師
13:50-14:30	Diplomate 口頭報告三、四	曾令怡、林詩詠醫師
14:30-15:00	中場休息	
15:00-15:50	CBCT在TAD的臨床運用	林錦榮醫師
15:50-16:30	Diplomate 口頭報告五	邱上珍醫師
	Ambassador 口頭報告一	張銘珍醫師
16:30-17:00	Diplomate 授證儀式	
17:00-17:10	閉幕	



# International Association for Orthodontists & Implantologists

For more information on benefits and requirements of iAOI members, please visit our official website: <http://iaoi.pro>.

# Join the *iAOI*, the future of dentistry!

## How to join iAOI?

Certified members of the Association are expected to complete the following three stages of requirements.

### 1. Member

Doctors can go to <http://iaoi.pro> to apply for membership to join iAOI. Registered members will have the right to purchase a workbook in preparation for the entry exam.

### 2. Board eligible

All registered members can take the entry exam. Members will have an exclusive right to purchase a copy of iAOI workbook containing preparation materials for the certification exam. The examinees are expected to answer 100 randomly selected questions out of the 400 ones from the iAOI workbook. Those

who score 70 points or above can become board eligible.

### 3. Diplomate

Board eligible members are required to present three written case reports, one of which has to be deliberated verbally. Members successfully passing both written and verbal examination will then be certified as Diplomate of iAOI.

### 4. Ambassador

Diplomates will have the opportunity to be invited to present six ortho-implant combined cases in the iAOI annual meeting. Afterwards, they become Ambassador of iAOI and will be awarded with a special golden plaque as the highest level of recognition in appreciation for their special contribution.

2015

3/22 09:00-17:00

# 從青少年矯正到 合併植牙治療的省思

主講：張慧男及貝多芬團隊



徐玉玲

安徒生兒童牙科院長  
貝多芬矯正課程講師  
國際矯正植牙學會院士



曾淑萍

彼德潘牙醫診所院長  
台中大大兒童牙醫診所醫師  
國際矯正植牙學會院士



曾令怡

高雄醫學大學學士  
小雅牙醫診所醫師  
國際矯正植牙學會院士

## 早期矯正治療 的綜合考量

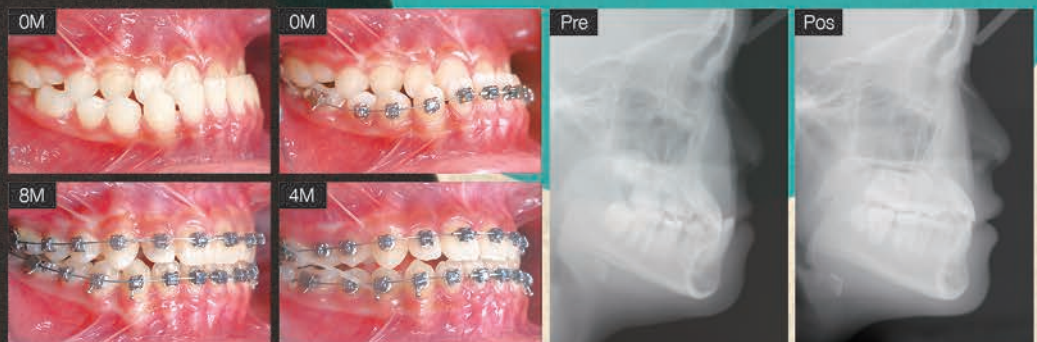

兒童牙科的早期治療主要在處理萌發中的恆齒問題，以促進骨骼的正常發展，並減輕日後矯正的複雜度。因此，早期治療的重點在於解決眼前的局部問題，但臨床上卻缺乏針對患者整體情況做出完整診斷、擬定全面的治療計畫，並依據此計畫決定適當的介入時機。講者將整理多年經驗並明確指出臨床診斷依據，幫助我們決定什麼樣的情況該進行早期介入，而哪些往往是造成消耗病患治療熱情，以及醫師延長治療時間的早期治療陷阱。希望透過本演講可以協助醫師輕鬆判斷「如何執行」或「不執行」早期治療。



彭緯綸

安徒生兒童牙醫診所醫師  
成大醫學中心兒童牙科代訓醫師  
國際矯正植牙學會院士

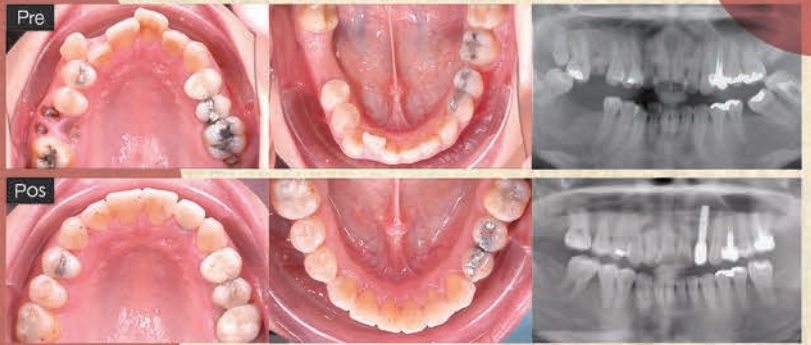



# 2

## 矯正與植牙 合併治療的思考流程

矯正與植牙的聯結，是目前的牙醫趨勢。植牙前，經由矯正治療能夠給予牙齒妥善的空間規劃；矯正中，透過預先補骨、補肉可以改善植牙環境，甚至藉由放置植體來減少後續骨整合所需的時間，並作為矯正的錨定，矯正與植牙的關係實在密不可分。因此，現今患者越來越能夠接受矯正與植牙兩者的合併治療，治療計畫的安排與思考流程乃越趨重要。張慧男醫師將帶領貝多芬與金牛頓團隊示範矯正與植牙合併治療的病例，並延伸探討兩者間合併治療的注意事項，引領大家從治療開始到結束，一步步地檢視這類案例的處理要點。



**蘇笠璋**

金牛頓植牙中心院長  
南加大植牙課程台灣負責人  
國際矯正植牙學會院士



**陳惠華**

成大口醫部牙周病科兼任主治醫師  
建志牙醫診所主治醫師  
國際矯正植牙學會院士



**林詩詠**

長青牙醫聯盟特聘專任醫師  
諾貝爾牙醫診所副院長  
國際矯正植牙學會院士



**李雙安**

高雄醫學大學牙醫學士  
滿祥聯合牙醫診所醫師  
國際矯正植牙學會院士

### 演講 時刻表

#### 早期矯正治療的綜合考量

09:00~10:10 曾令怡+彭緯綸 / 張慧男

10:40~12:10 曾淑萍+徐玉玲 / 張慧男

12:00~13:00 午餐

#### 矯正與植牙合併治療的思考流程

13:00~14:30 李雙安+林詩詠 / 張慧男

15:00~16:30 陳惠華+蘇笠璋 / 張慧男

主辦單位：台北醫學大學牙醫學系台南區校友會

協辦單位：湧傑企業股份有限公司

演講地點：國立成功大學醫學院第三講堂(台南市小東路1號)

費用：3/13前北醫及台南市牙醫師公會會員1500元，  
非會員 2000元，研究生及住院醫師 800元。

3/13後北醫及台南市牙醫師公會會員2500元，  
非會員 3000元，研究生及住院醫師 1500元。

**報名專線** 07-226-0030 王小姐  
02-2778-8315分機122 楊小姐

報名方式：請先電話報名，三日內劃撥費用

郵政劃撥帳號：17471807

戶名：湧傑企業股份有限公司

\* 參加者發給繼續教育學分

本文宣品僅供牙科診所及醫師參考，禁止張貼或擺置於公眾可瀏覽及取閱之處。

## Asymmetric Maxilla with a Functional Shift and Labially Blocked-Out Maxillary Canines

### Summary

The Discrepancy Index (DI) was 17 for a 12y9m male with bilateral blocked-out upper cuspids, unilateral anterior crossbite, right Class II molar relationship, and a mandibular dental midline deviated 4mm to the right. A non-extraction treatment with intermaxillary elastics for 21 months resulted in a good dental outcome: cast-radiograph evaluation (CRE) of 26 with a pink and white dental esthetics score (P&W) of 3. The patient failed to grow as expected to compensate for extrusion of mandibular, so the mandible rotated posteriorly, but lip competence was maintained. Although miniscrew osseous anchorage was recommended to correct the side effects of Class II elastics, the patient declined because the convex profile was acceptable. However, from an orthodontics perspective it would have been preferable to retract the maxillary dentition with extra-alveolar (E-A) miniscrews to prevent bite opening and lower incisor flaring. This case teaches three important lessons: 1. obtain permission before treatment to use miniscrews if indicated, and 2. nonextraction treatment of high angle patients with Class II elastics may result in stability problems, and 3. progress records are recommended before the finishing stage to plan the final detailing. (Int J of Othod Implantol 2014;36:26-48)

#### Key words:

blocked-out, crossbite, functional shift, midline discrepancy, Class II malocclusion, non-extraction, miniscrew, extra-alveolar anchorage

### History and Etiology


A 12-year-and-9-month-old boy was referred by his dentist for orthodontic consultation (Fig. 1). His chief complaints were a severely crowded upper dentition and high cuspids (Figs. 2-3). There was no contributing medical or dental history, and the patient failed to report any habits contributing to his malocclusion. The mandibular midline was shifted 4 mm to the right in relation to the facial midline (Figs. 4-5). The clinical examination revealed a relatively long face, tapered facial form, steep mandibular plane angle, decreased maxillary width, and a tooth-size to arch-length discrepancy. The dentofacial pattern suggests the malocclusion was primarily environmental due to an inadequate history of masticatory loading and decreased biting strength. The narrow maxillary arch was associated with an inadequate perimeter to accommodate the entire dentition, resulting in blocked-out canines and a functional shift due to a palatally displaced right lateral incisor.

The patient and his parents wanted to avoid extractions and use of miniscrews. For a high angle patient with an anterior openbite tendency, conservative treatment with intermaxillary elastics may result in a skeletal compromise unless the patient has a favorable growth pattern. Because of the patient/parent preference

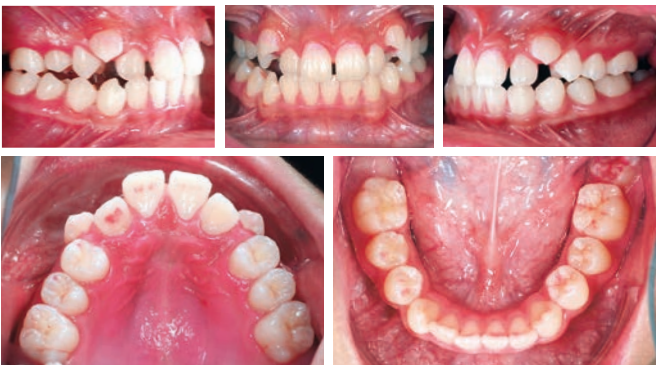**Dr. Ariel Chang,**  
Instructor, Beethoven Orthodontic Course (Left)

**Dr. Chris Chang,**  
Founder, Beethoven Orthodontic Center  
Publisher, International Journal of Orthodontics & Implantology (middle)

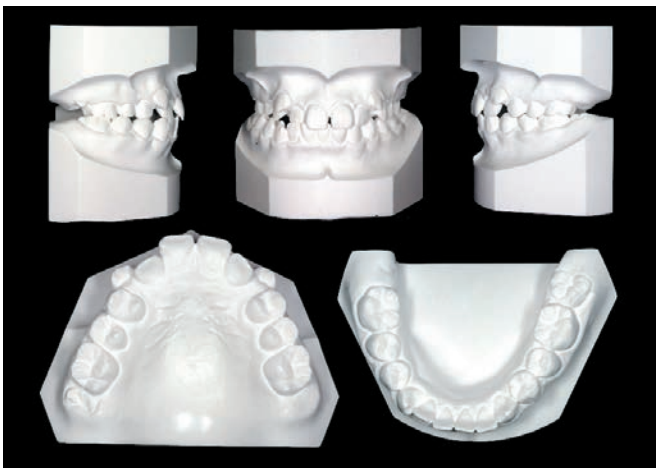**W. Eugene Roberts,**  
Consultant, International Journal of Orthodontics & Implantology (right)



■ Fig. 1: Pre-treatment facial photographs

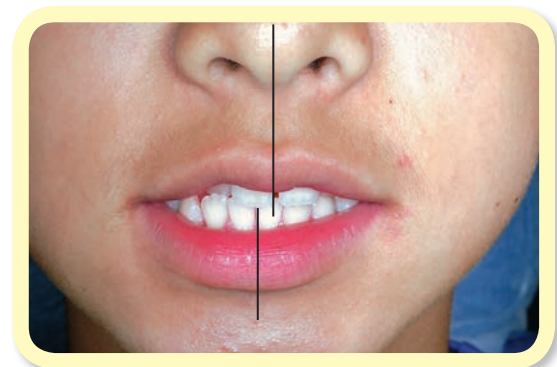

■ Fig.2:  
Pre-treatment intraoral photographs document bilateral blocked-out upper cuspids, upper right lateral incisor crossbite and lower midline shift to right side.

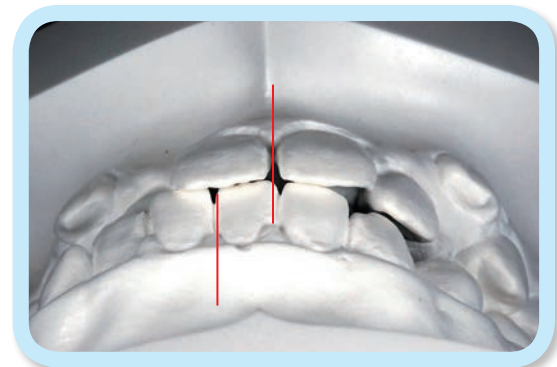


■ Fig.3:  
Pre-treatment study models (casts) reveal molar relationship was Class II on right side and Class I on left side.

and the age of the patient indicated good growth potential, conservative treatment was indicated, but it should be carefully monitored. A full set of diagnostic records were collected at 14 months into treatment to assess progress (Figs. 22-30). After 21 months of active treatment, all fixed appliances were removed and post-treatment records were collected (Figs. 31-34).



■ Fig. 4:  
Mandibular dental midline shifted to right side of maxillary and facial midlines



■ Fig. 5: Midline shift and upper right lateral incisor crossbite

## Diagnosis

The pre-treatment photographs, radiographic records and study models were obtained 08-13-2010: age: 12y11m

### Skeletal:

- Class II Pattern (SNA 83°, SNB 78°, ANB 5°)
- High mandibular plane angle (SN-MP 36°, FMA 31°)

### Dental:

- Angle Classification: *Subdivision (asymmetry) Class II right, Class I left*
- Midlines: *Mandibular dental midline was 4 mm to the right of the facial and maxillary midlines*
- Tooth Size Arch Length Discrepancy:  
Maxillary: 13 mm,  
Mandibular: 2 mm
- Blocked-out maxillary canines (#6 & #11)
- Cross bite: *Upper right (UR) lateral incisor, both premolars and the second molar (#4, 5 and 7)*
- Partially impacted: *Lower right (LR) second molar (#31) Slight flaring of the lower incisors*
- ABO Discrepancy Index : 17 as documented in the subsequent work sheet

### Facial:

- Convex profile

### Radiographic\Panoramic:

- Partially impacted LR #31; all four 3<sup>rd</sup> molars were present (Fig. 36)

## Specific Objectives of Treatment

### Maxilla (all three planes):

- A - P: *Allow for expression of normal growth*

- Vertical: *Allow for expression of normal growth*
- Transverse: *Allow for expression of normal growth*

### Mandible (all three planes):

- A - P: *Allow for expression of normal growth*
- Vertical: *Allow for expression of normal growth*
- Transverse: *Allow for expression of normal growth*

### Maxillary Dentition

- A - P :  
Molars: *Retract on the right side*  
Incisors: *Maintain*
- Vertical :  
Molars: *Maintain*  
Incisors: *Maintain*
- Inter-molar Width: *Increase*
- Inter-canine Width: *Decrease*
- Buccolingual Inclination: *Maintain*

### Mandibular Dentition

- A - P :  
Molars: *Maintain*  
Incisors: *Maintain*
- Vertical :  
Molars: *Maintain*  
Incisors: *Maintain*
- Inter-molar Width: *Maintain*
- Inter-canine Width: *Maintain*
- Buccolingual Inclination: *Maintain*

### Facial Esthetics: *Maintain*

### Other :

- Correct mandible functional shift and midline deviation due to crossbite of #7

## Treatment Plan

With the reservations previously noted, a non-extraction treatment is indicated. Full fixed appliance with anterior bite turbos on both upper central incisors to correct the anterior cross bite and functional shift. Use unilateral Class II early light short elastics (ELSE)(Quail 3/16" 2 oz, right side) to correct right Class II buccal segment. Interproximal reduction of lower dentition as needed to provide space for the partially impacted lower right 2<sup>nd</sup> molar. Progress records midterm to reassess the conservative approach. Apply up and down elastics and detail the final occlusion. Retain the corrected dentition with fixed retainers and clear overlay retainers. Remove all 3<sup>rd</sup> molars at the age of ~18.

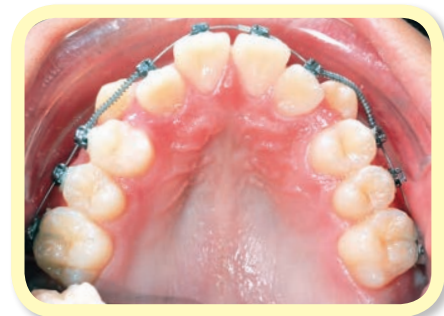## Appliances and Treatment Procedures

A .022" slot Damon Q bracket system (Ormco, Glendora, CA) with low torque maxillary incisor brackets to control flaring for the correction of crowding.<sup>1,2</sup> The Damon four archwire sequence was followed.<sup>3</sup> The initial upper archwire was .014" CuNiTi fitted with open coil springs between the lateral incisors and first premolars to create spaces for the blocked-out upper canines (Fig. 6). An anterior bite turbo was placed on the lower right lateral incisor to temporarily open the vertical dimension of occlusion (VDO) to correct the cross bite (Fig. 7). One month later, space was adequate to align the upper canines and the crossbite was corrected. The bite turbo was removed and standard torque brackets were bonded on the upper cuspids and the lower dentition. Initial archwires were .014" CuNiTi. Two drop-in hooks were fitted in the vertical slots of the upper canines to secure Class II early light short elastics (Quail 3/16" 2 oz) as shown in Figs. 8 and 9. Four months later, the brackets on both upper

canines were repositioned to approximate the long axis of the tooth. In the 6<sup>th</sup> month, both canines reached the occlusal plane (Fig. 10) but the lower midline was still deviated 2 mm to the right. Two drop-in hooks were fitted in the vertical slots of the lower canines to secure parallel elastics (Ostrich 3/4" 2 oz) to correct the midline (Fig. 11).

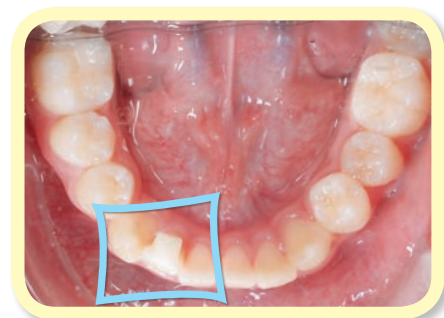In the 7<sup>th</sup> month, rectangular .014"x.025" CuNiTi archwires were placed. Two types of elastics were used: 1. bilateral Class II elastics (Fox 1/4" 3.5 oz), and 2. midline elastics (Dolphin 5/16" 3 oz, followed by Fox 1/4" 3.5 oz) from #11-22 and positioned under the brackets of #24-27 (Figs. 12-14). The brackets on teeth #4, 10, and 21-23 were repositioned.

## Initial Light-Wire Phase: 0~6<sup>th</sup> month .014" CuNiTi:



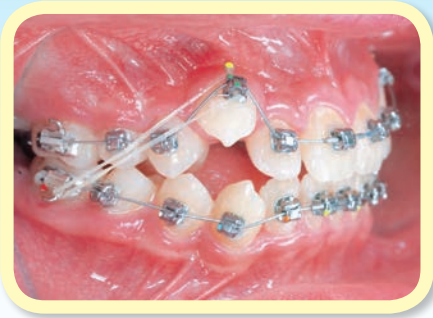■ Fig. 6:

Open coil springs between upper lateral incisors and first premolars

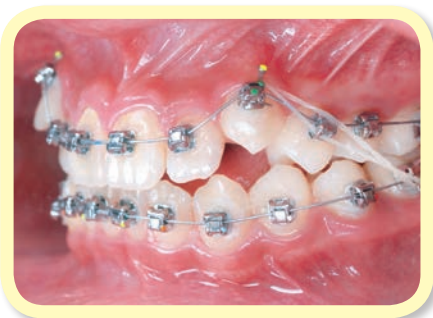

■ Fig. 7:

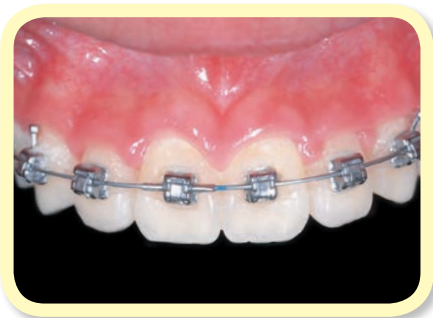An anterior bite turbo bonded on lower right lateral incisor



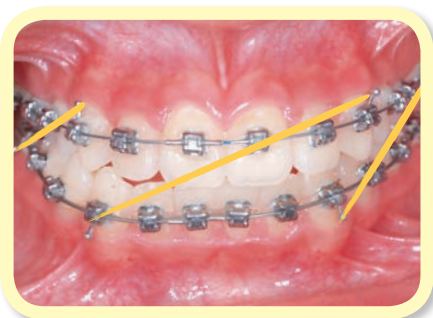
■ Fig. 8: ELSE (Quail 3/16" 2 oz) on right side (2<sup>nd</sup> month)



■ Fig. 9: ELSE (Quail 3/16" 2 oz) on left side (2<sup>nd</sup> month)



■ Fig. 10: Cuspids reached occlusal plane (6<sup>th</sup> month)



■ Fig. 11:  
Parallel elastics (Ostrich 3/4" 2 oz) were used to correct midline discrepancy (6<sup>th</sup> month)

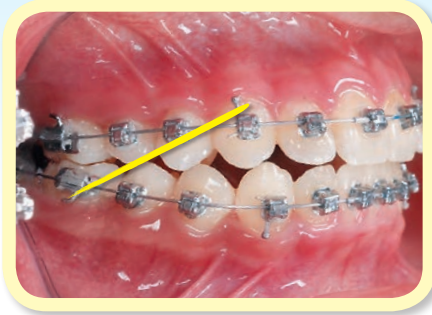
At 13 months, .017"x .025" TMA archwires were engaged. Anterior up and down elastics (*Giraffe 3/4" 3.5 oz*) and L-shaped elastics (*Fox 1/4" 3.5 oz*) were applied as shown in Figs. 15-17. Late in treatment, vertical elastics (Figs. 18-20) were used to seat the occlusion, as will be subsequently described.

In the 14<sup>th</sup> month of active treatment, the progress records were collected (Figs. 21-24). The dental casts and radiographs were assessed using the Cast Radiograph Evaluation (CRE) developed by the American Board of Orthodontics (ABO) (Figs. 25-30) and the score was 56, as documented in the subsequent form. At this stage, the patient and his parents were advised that OrthoBoneScrews® (*Newton's A, Hsinchu, Taiwan*) in the infrazygomatic crests (IZC) were indicated to control the posterior rotation of the mandible and incisal flaring, but the preference was to continue using intermaxillary elastics.

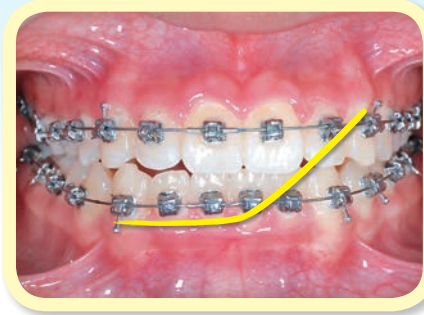
In the 17<sup>th</sup> month, a .019 x.025" stainless steel (SS) archwire was placed in the upper arch. One month later, a .016x.025" SS archwire was placed on the lower arch. SS ligature wires were tied in a figure of 8 pattern to maintain the firm contacts of the anterior teeth in both arches. Since the use of miniscrews on the IZCs was declined, the upper arch was expanded and the upper anterior teeth were retracted to resolve open-bite and flaring problems.

In the final stages of the treatment, detailing was accomplished with first and third order bends. To improve the posterior occlusion, the maxillary arch wire was cut distal to the canines and modified vertical elastics were applied: *Giraffe 3/4" 3.5 oz* in the anterior segment and *Chipmunk 1/8" 3.5 oz* in

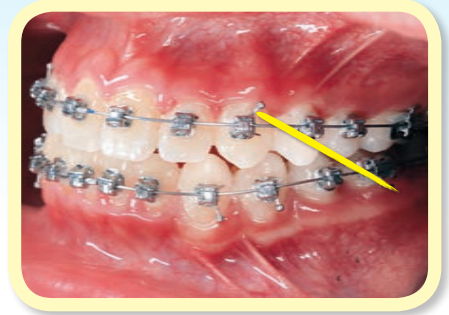
High-Tech Edgewise : 7<sup>th</sup>~12<sup>th</sup> month .014x.025" CuNiTi



■ Fig. 12:  
Class II elastics (Fox 1/4" 3.5 oz) on right side

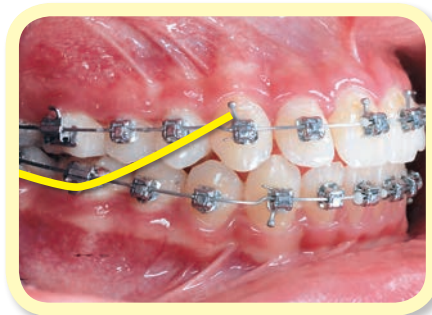

■ Fig. 13:  
Elastics (Dolphin 5/16" 3 oz) to correct midline discrepancy

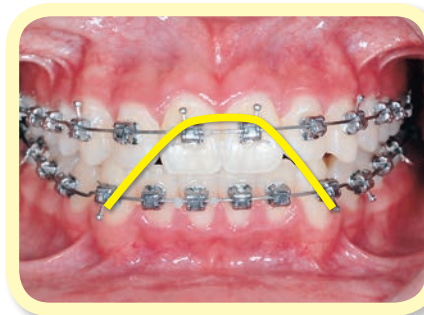


■ Fig. 14:  
Class II elastics (Fox 1/4" 3.5 oz) on left side

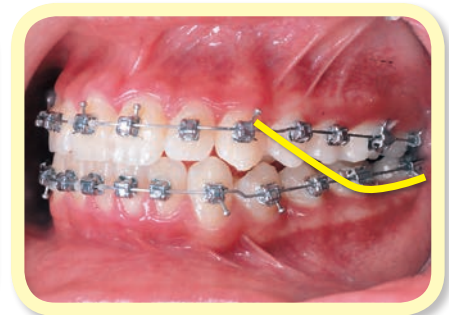
High-Tech Edgewise : 13<sup>th</sup>~16<sup>th</sup> month .017x.025 TMA



■ Fig. 15:  
L-shaped elastics (Fox 1/4" 3.5 oz) on right side to correct molar relationship

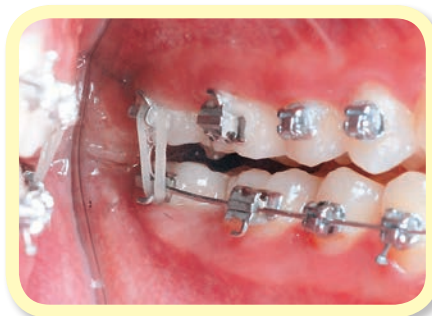

■ Fig. 16:  
Anterior up and down elastics (Giraffe 3/4" 3.5 oz) to close anterior open contact

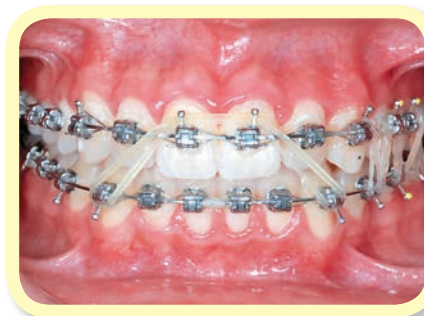

■ Fig. 17:  
L-shaped elastics (Fox 1/4" 3.5 oz) on left side to correct molar relationship

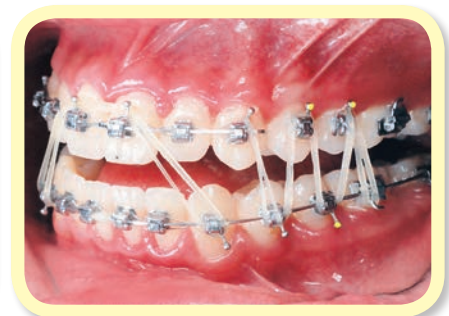Major Mechanics & Finishing : 17<sup>th</sup>~21<sup>st</sup> month .016/.019x.025 SS



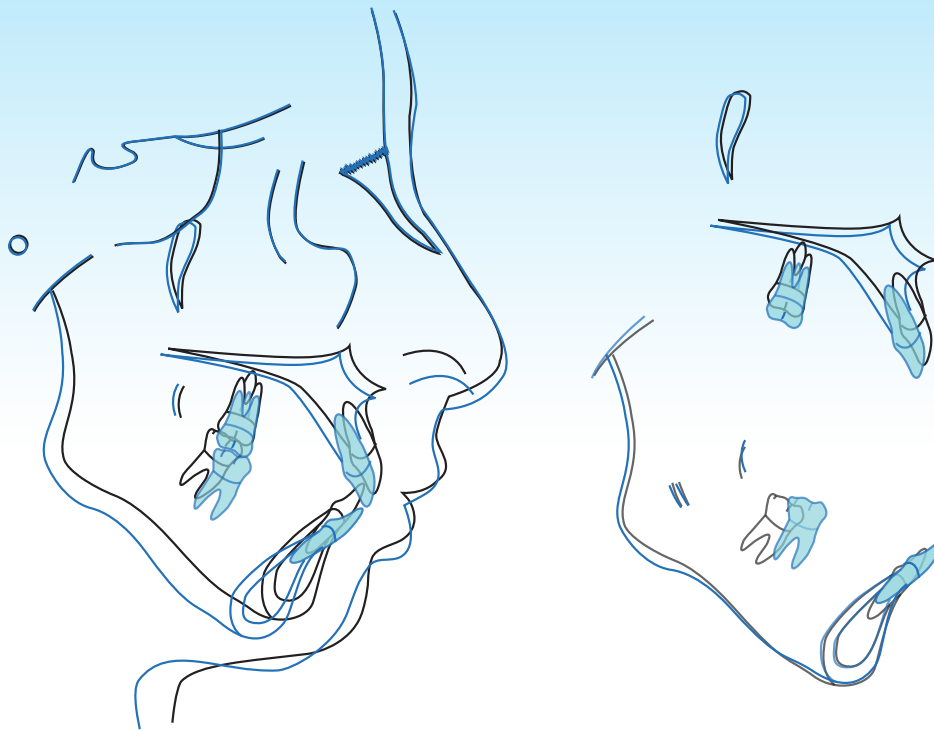
■ Fig. 18:  
Posterior up and down elastics (Chipmunk 1/8" 3.5 oz) between right second molars



■ Fig. 19:  
Anterior up and down elastics (Giraffe 3/4" 3.5 oz) to close anterior open contact

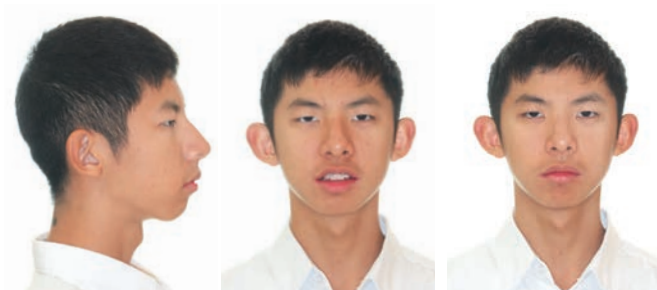

■ Fig. 20:  
The maxillary arch wire was cut distally to the cuspids. Vertical elastics (Giraffe 3/4" 3.5 oz) were applied to achieve optimal intermaxillary contacts.

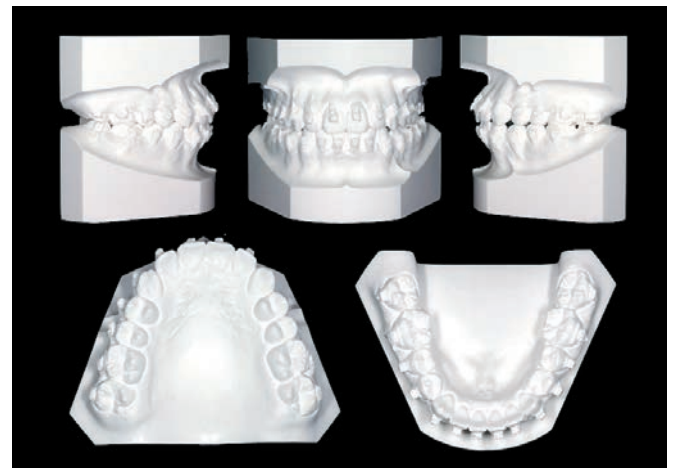

■ Fig. 21:

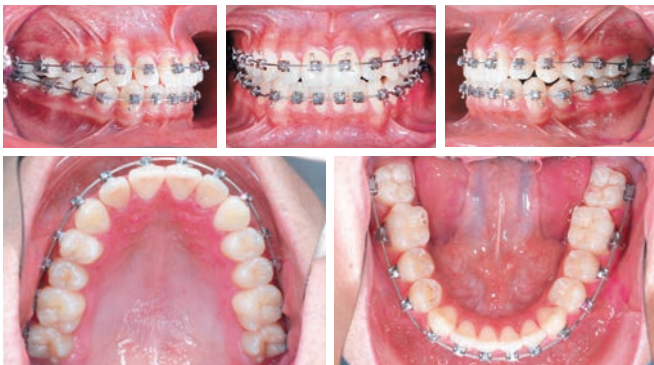Superimposed cephalometric tracings show dentofacial changes over 14 months of treatment. All teeth in both arches were extruded and the mandibular incisors were flared. The mandible rotated posteriorly and the face was more convex, but the lips remained competent.



■ Fig.22: Progress facial photographs at 14 months



■ Fig.24: Progress study models (casts) at 14 months



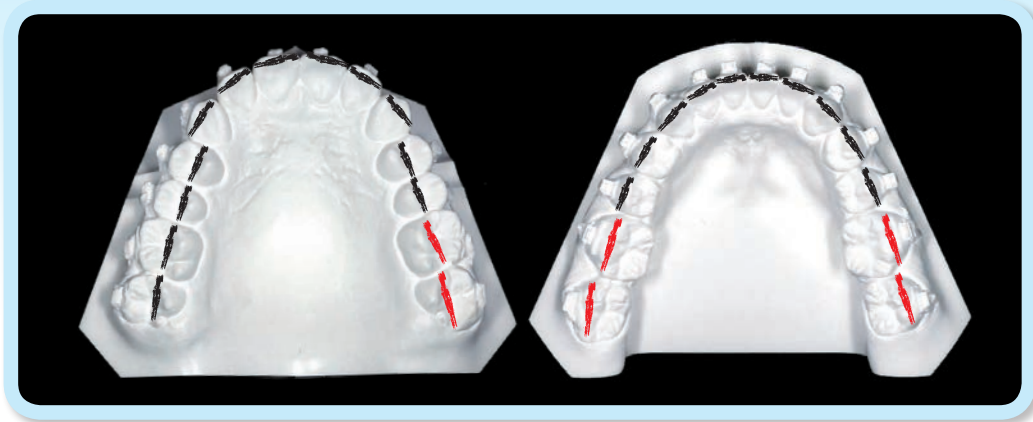
■ Fig.23: Progress intraoral photographs at 14 months

the posterior segments<sup>4-6</sup> (Figs. 18-20). Once optimal interdigtation and intermaxillary contacts were achieved, all fixed appliances were removed.

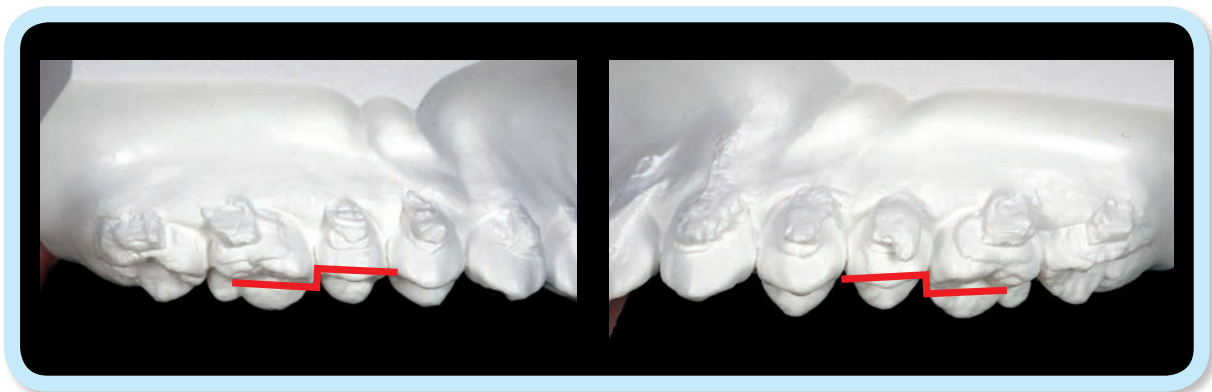
### Treatment Progress

Following 14 months of treatment (age 14y1m) all goals were assessed on a full set of progress records

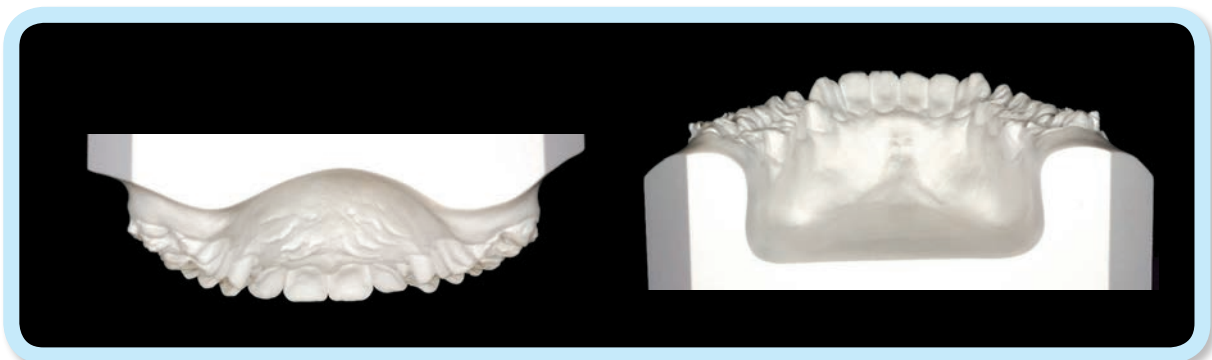




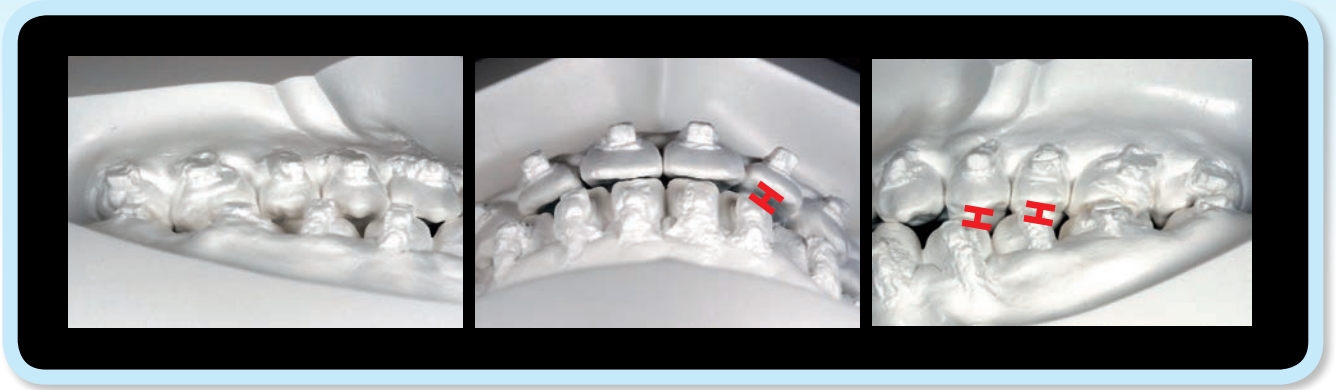■ **Fig. 25:**  
 Progress casts were assessed for alignment and rotation; black lines indicate acceptable alignment and red lines reveal discrepancies.



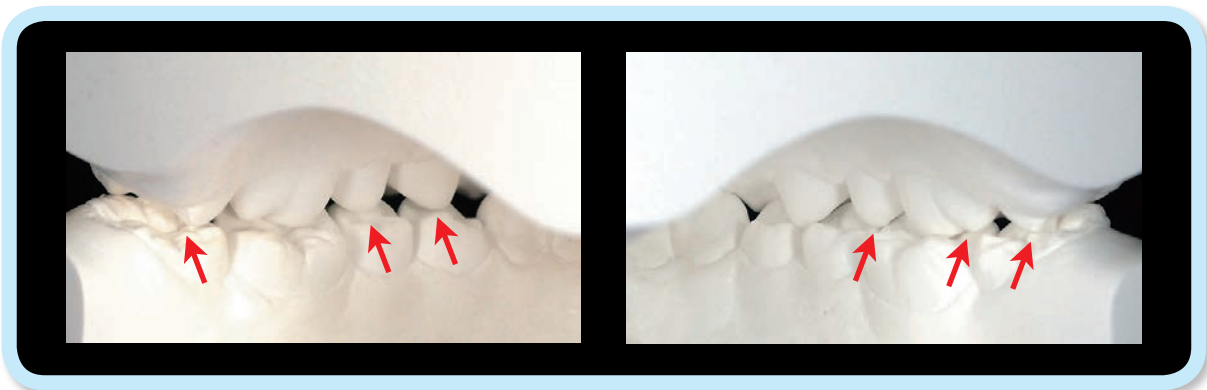
■ **Fig. 26:**  
 Progress casts were assessed for marginal ridge alignment; red lines reveal discrepancies. Correction was made by positioning brackets more occlusal on first molars and more gingival on the second premolars.



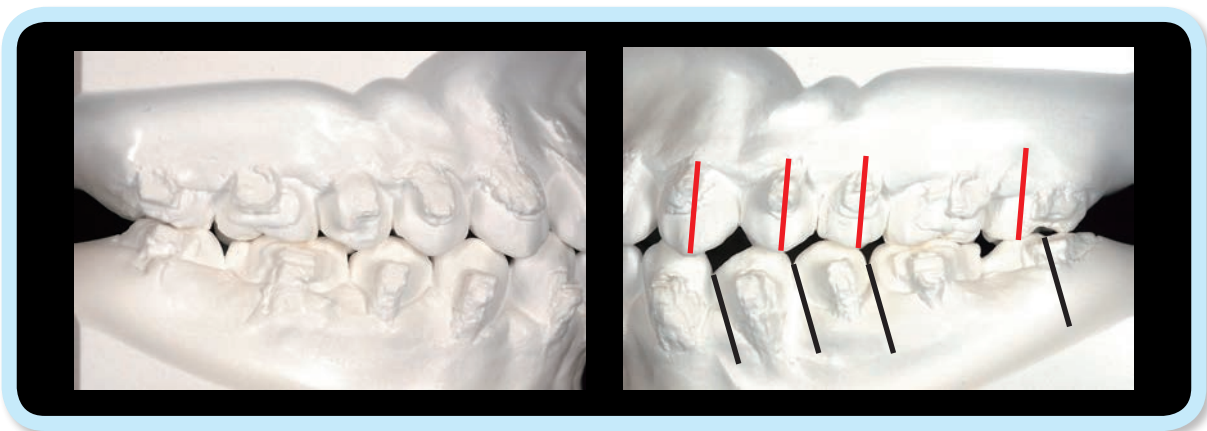
■ **Fig. 27:**  
 Progress casts were assessed for buccolingual inclinations; discrepancies were corrected by placing progressive torque in the rectangular archwires.



■ Fig. 28: Progress casts were assessed for overjet; the red marks reveal discrepancies that were scored.



■ Fig. 29: Progress casts were assessed for maxillary lingual cusp contacts; six cusps (red arrows) were more than 1mm out of contact, so the total score was 12.



■ Fig. 30: Progress casts were assessed occlusal relationships (interdigitation); red lines mark cusps that should interdigitate with interproximal contacts, marked with black lines. All discrepancies were 1-2mm, so 4 points were scored.

taken on 12-02-2011. As illustrated in Figs. 21-30, this re-evaluation identified the following problems:

### Mandibular Dentition

- A - P : *Incisors: Flared*
- Vertical :
  - a. *Molars: Extruded*
  - b. *Incisors: Extruded*
- Inter-molar Width: *Constricted*
- Buccolingual Inclination: *Lingual Tipping*

### Treatment Needed for an Optimal Finish

A plan was devised to improve alignment, based on cephalometric superimpositions and the CRE score of 56 :

- Reposition brackets on teeth #3 & #14 to correct marginal ridge discrepancies
- Apply progressive lower posterior buccal crown torque to correct excessive lingual tipping
- Detailing bends to correct rotations
- Arch coordination to improve occlusal relationships and contacts
- IZC Miniscrews to reduce incisor flaring, correct Class II molar relationship and control bite opening

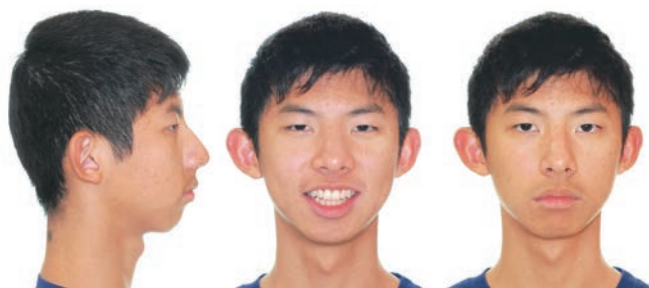### Treatment Concerns and Summary

After correction of functional shift due to the cross bite of #7, the Class II molar relationship as well as the deviated midline had been resolved. Creating space to relieve crowding has resulted in protrusion and flaring of upper and lower incisors. The bite turbo and Class II elastics, in the absence of favorable growth, had increased the vertical dimension of occlusion (VDO) and produced posterior rotation of the mandible. IZC miniscrews were needed to

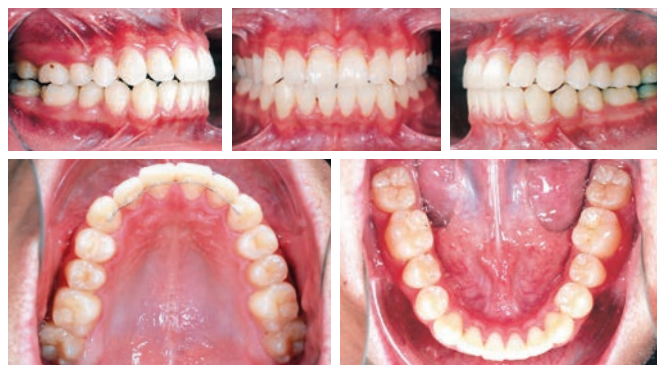control these side effects. Estimated treatment time is ~6 more months.

### Results Achieved

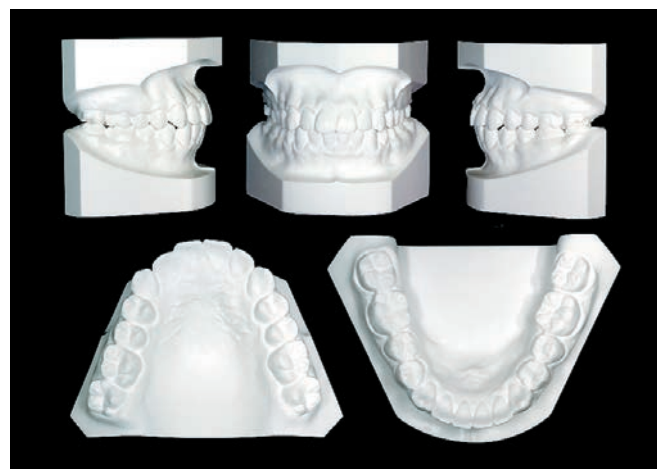At age 14y8y after an active treatment time of 21 months, all fixed appliances were removed and post-treatment records (Figs. 31-36) were taken on 07-09-2012.



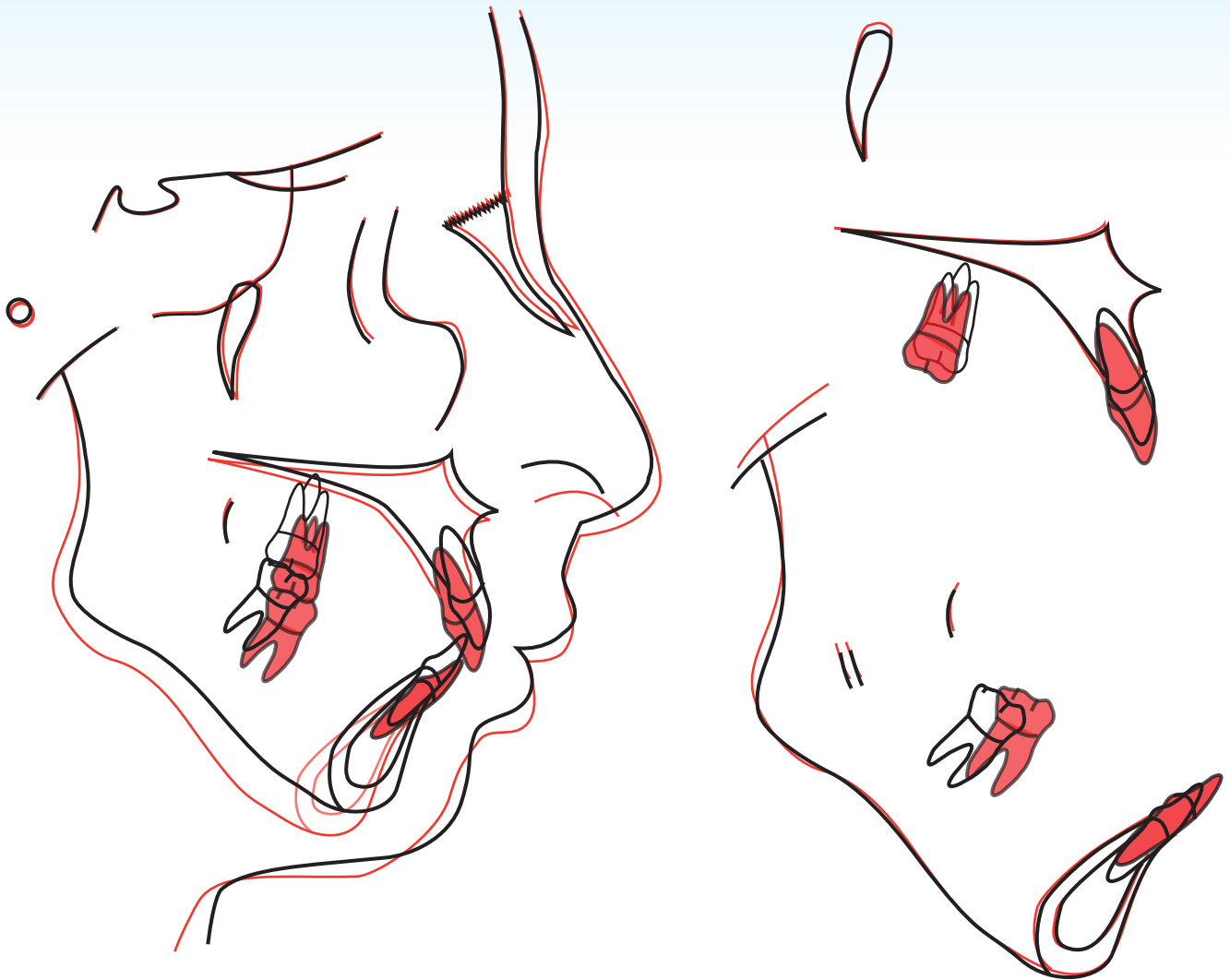
■ Fig.31: Post-treatment facial photographs at 21 months



■ Fig. 32: Post-treatment intraoral photographs at 21 months



■ Fig.33: Post-treatment study models show Class I molar relationship on both sides



■ Fig. 34:

Superimposition of pre-treatment and post-treatment ceph tracings demonstrate the dentofacial changes following 21 months of active treatment.

The maxilla was retracted slightly and the mandible had grown vertically. This patient is a vertical grower.

Upper incisors were flared due to regaining the spaces for blocked-out cuspids.

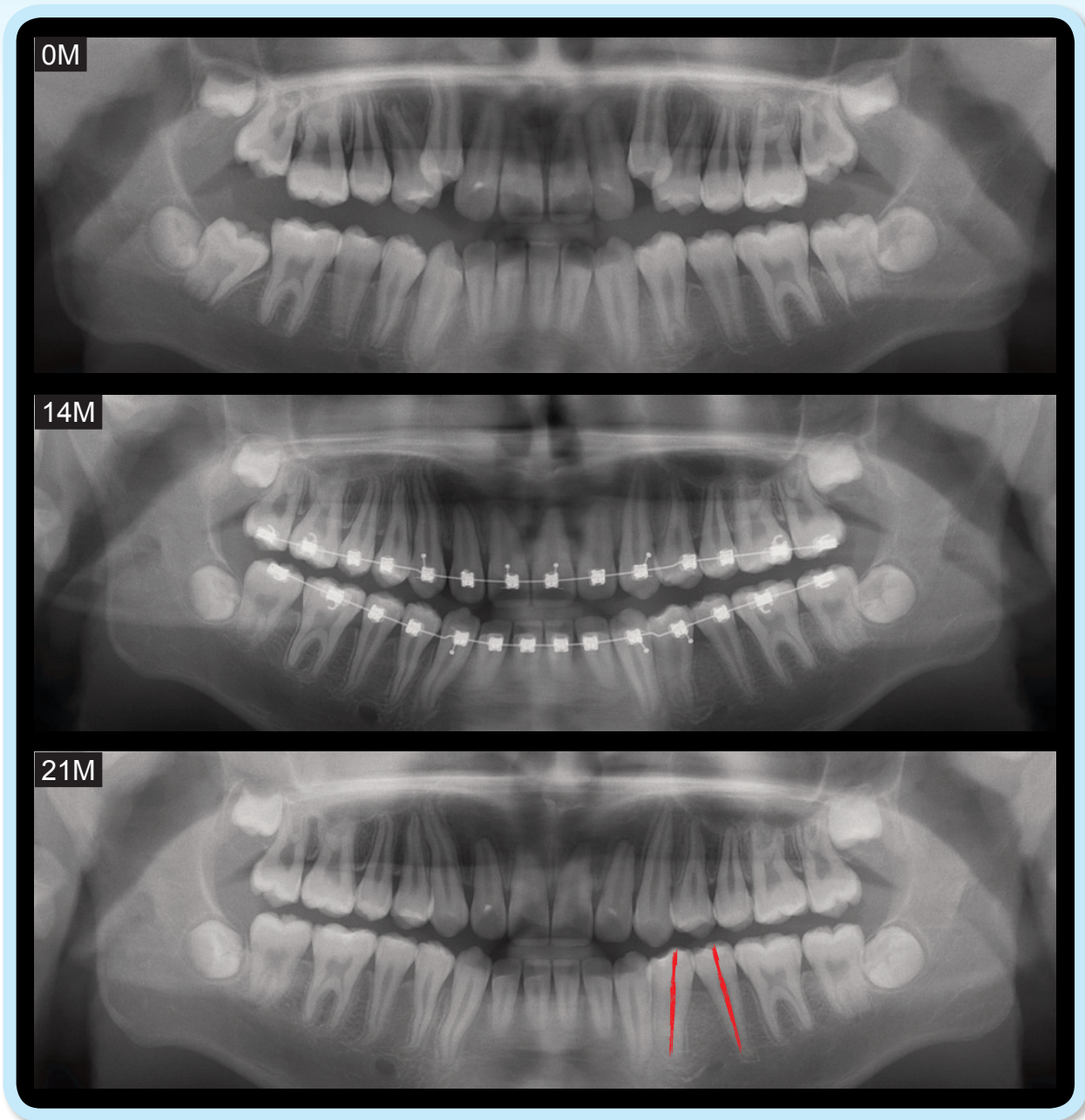
Upper dentition was extruded due to the use of Class II elastics and normal eruption of dentition at this stage.

Upper molars had also been distalized by Class II elastics.

Flaring and extrusion of lower incisors were noticed due to the extensive use of Class II elastics.

The Class II elastics also hinged open the mandible.

The right lower molar was moved forward to achieve Class I molar relationship and to correct the asymmetrical functional shift.

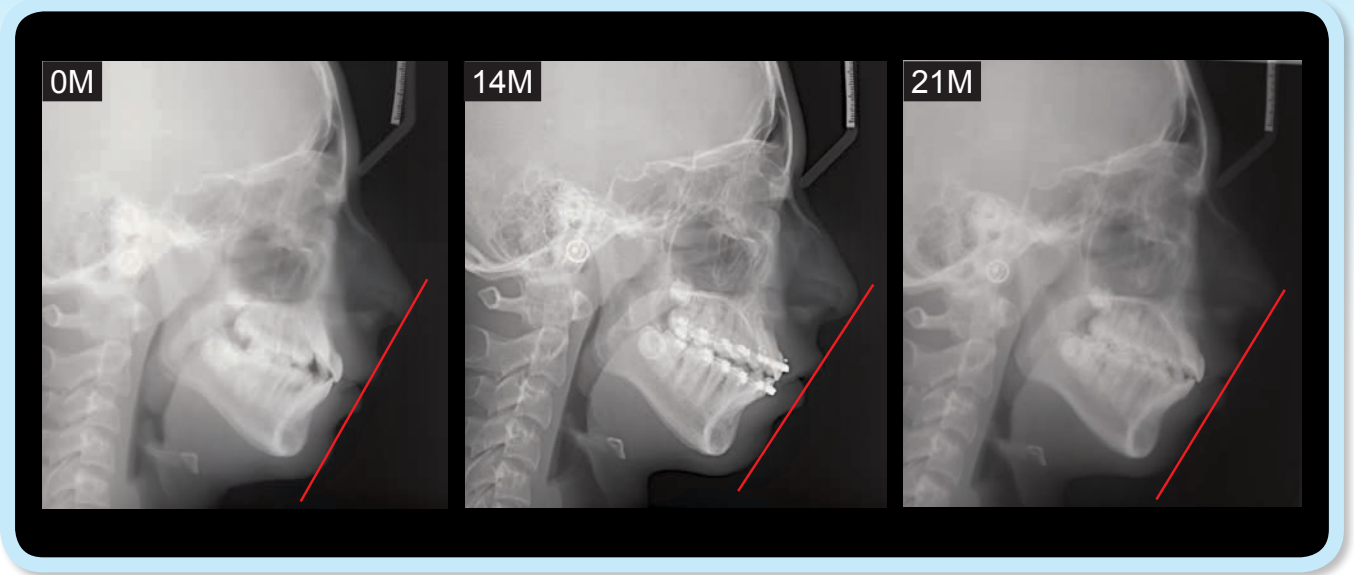


■ Fig. 35:

A series of three panoramic radiographs at 0, 14 and 21 months document the treatment effects.

Root alignment discrepancies, marked by red lines, resulted in a total of two points on the CRE score.

The axial inclination of the second premolar is within 1 mm but the discrepancy for the first premolar is more than 1 mm, so two points are scored.



■ Fig.36:

A series of three cephalometric radiographs (0, 14 and 21 months) document the dentofacial and skeletal affects of treatment. Despite the opening of the VDO, the relationship between upper/lower lips to the E-line remained acceptable. Flaring of the incisors noted at 14 months was improved at 21 months.

**Maxilla (all three planes):**

- A - P: Retracted
- Vertical: *Increased*
- Transverse: *Expanded*

**Mandible (all three planes):**

- A - P: Maintained
- Vertical: *Increased*
- Transverse: *Maintained*

**Maxillary Dentition**

- Alignment: #2 rotated mesial side out
- Anchorage: Retraction of upper molars
- Incisor Control: Flared
- Vertical: *Increased*
- A - P: Retracted
- Inter-molar Width: *Increased*
- Inter-canine Width: *Maintained*
- Marginal Ridges: *discrepancies from inadequate*

*alignment of teeth #2 & 14*

- Buccolingual Inclination: #2, 3, 14, 15 flared
- Rotations: *Acceptable*

**Mandibular Dentition**

- Alignment: #19 mesial side in
- Anchorage: *Extrusion of molars*
- Incisor Control: *Flared*
- A - P: *Maintained*
- Vertical: *Increased*
- Inter-molar Width: *Decreased*
- Inter-canine Width: *Increased*
- Marginal Ridges: *Discrepancy on #31*
- Buccolingual Inclination: *Lingual tipping on #18, 19, 30, 31*
- Rotations: #27 mesial side in, #29 mesial side out

**Facial Esthetics:**

- Lower lip profile was slightly protrusive

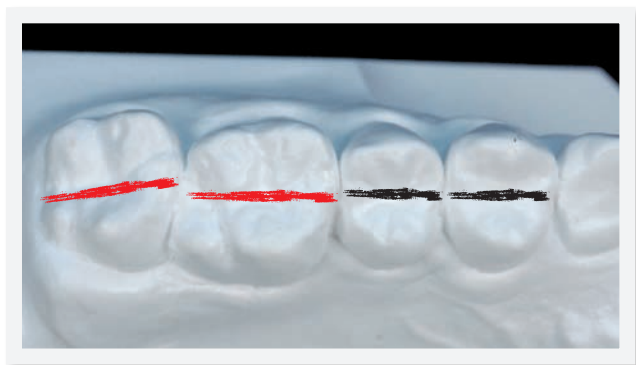
## Retention

An upper fixed 3-3 retainer was bonded on all teeth. Upper and lower clear overlay retainers were delivered, with instructions to wear them full time for the first 6 months, but nights only thereafter. Home care and training for retainer maintenance was provided.

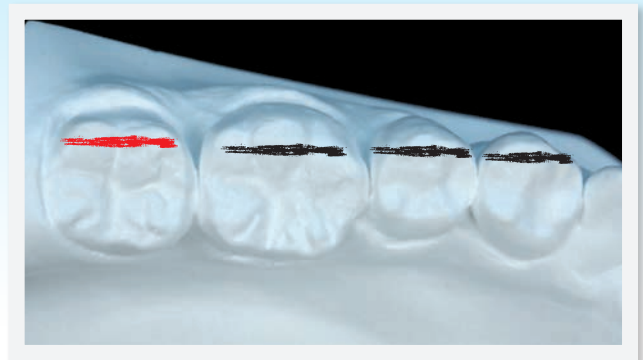
## Final Evaluation of Treatment

The final alignment was assessed at 26 points with the ABO CRE as documented on the form that appears later in this report. This was considered an excellent result for the moderately severe malocclusion ( $DI = 17$ ).<sup>15</sup> The soft and hard tissue in the esthetic zone were also pleasing as will be subsequently documented.<sup>16</sup> The following deviations from ideal were noted: Alignment and rotation: 5 points were scored for buccal position of second molars, and distal out rotation of the lower left canine (Figs. 37-39).

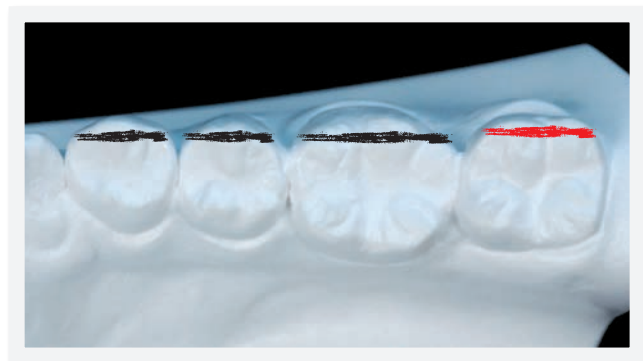
- Marginal ridge discrepancies: 3 points were scored for maxillary premolars and molars (Figs. 40-41).
- Buccolingual inclination: 12 points were scored for molar discrepancies (Fig. 42).



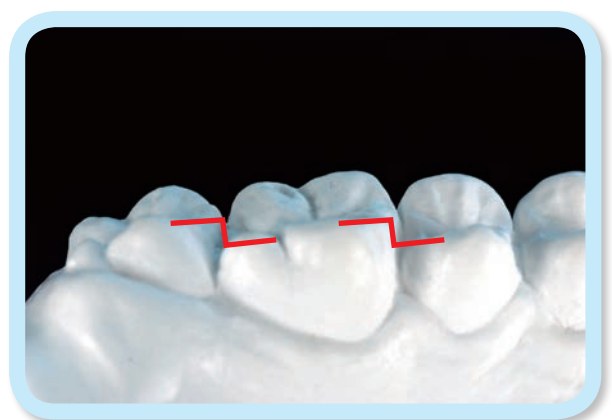
■ **Fig. 37:**  
At 21 months, red lines marked discrepancies in maxillary fossae alignment.



■ **Fig. 38:**  
At 21 months, a red line marks a discrepancy in alignment of the buccal cusps for the lower left 2<sup>nd</sup> molar.

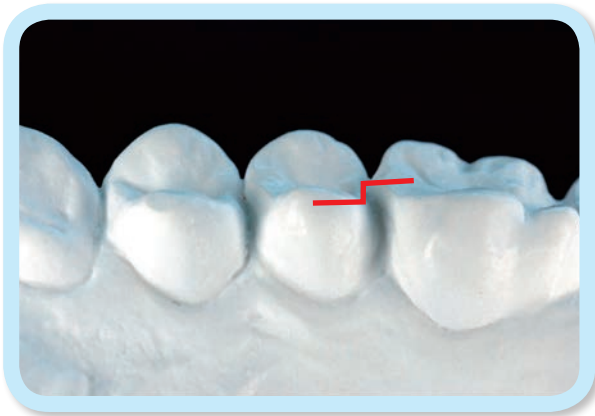

■ **Fig. 39:**  
At 21 months, a red line marks a discrepancy in alignment of the buccal cusps for the lower right 2<sup>nd</sup> molar.

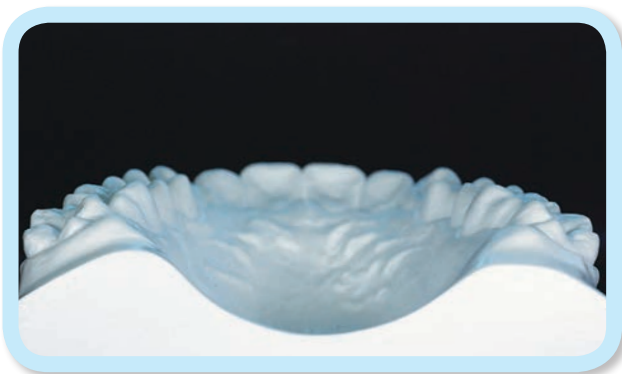


■ **Fig. 40:**  
At 21 months, marginal ridge discrepancies between upper right 1<sup>st</sup> and 2<sup>nd</sup> molars are marked with red lines.

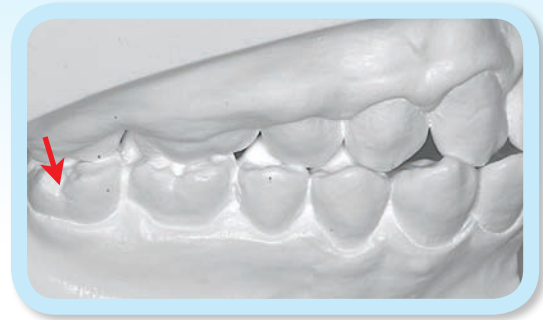- Occlusal contacts: 3 points were scored for absence of contacts on second molars (Figs. 43-44).
- Root Angulation: 2 points were scored for inadequate alignment of the lower left premolars (Fig. 35).



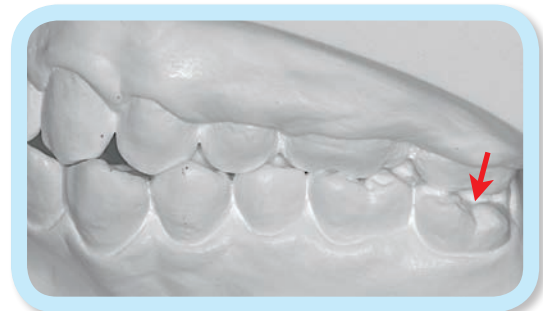■ **Fig. 41:**  
At 21 months, a marginal ridge discrepancy between the upper left 2<sup>nd</sup> premolar and 1<sup>st</sup> molar



■ **Fig. 42:**  
At 21 months, large buccolingual inclination problems are noted for maxillary molars that are tipped buccally to compensate for the narrow maxilla.



■ **Fig. 43:**  
At 21 months, lack of occlusal contact is noted between the left 2<sup>nd</sup> molars.



■ **Fig. 44:**  
At 21 months, lack of occlusal contact is noted between the right 2<sup>nd</sup> molars.

## Discussion

The dental aspects of the current malocclusion were well treated, but there were problems with the skeletal management. Initially, two conservative approaches were considered for correcting the crowding and incisal flaring in the presence of a high mandibular plane angle and open bite tendency: 1. extractions followed by retraction of the anterior segments, and 2. non-extraction treatment using extra-alveolar (E-A) miniscrews<sup>7</sup> to retract the buccal segments. Unfortunately, the patient and his parents declined both miniscrews and extractions. Since the pre-treatment lip relationship and E-line were



acceptable (Fig. 36), a short-term anterior bite turbo and Class II elastics were used. In the absence of significant forward growth, the risks were flaring of the incisors and opening of the VDO. The progress evaluation showed little significant growth, flaring of the incisors, and opening of the VDO. Again the use IZC miniscrews was proposed but the option was declined. Both the patient and his parents were pleased with the progress and preferred to finish the correction with intermaxillary elastics. Warning was again provided that stability may be a problem.

Anterior crossbite affecting only one or two teeth is usually due to ectopic eruption of one or more maxillary incisors. The most common etiologic factor for non-skeletal anterior crossbite is lack of space for maxillary permanent incisors, which is often manifest as palatal displacement of lateral incisors and blocked out canines.

An asymmetric posterior crossbite may be associated with a functional shift of the mandible to the crossbite side. Clinically, the posterior teeth occlude normally on one side but there is a contralateral crossbite. The etiology may be dental, skeletal, or neuro-muscular, but the problem is frequently associated with a narrow maxillary dental arch.<sup>8</sup> Ectopic eruption of maxillary incisor in palatal version may create a functional shift that results in a narrowing of the maxilla due to cheek pressure on the contralateral side. Alternately, a developmentally small maxilla may be too narrow to accommodate the mandible, so one side assumes a normal occlusion and the opposite side is in crossbite. The inference of posterior cusps when closing may result in a functional shift and changes the habitual

rest position. Subsequent adaptation to a unilateral crossbite may lead to asymmetric mandibular growth and development of TMD.<sup>9-13</sup>

Unilateral crossbite with a functional shift should be treated as early as possible because spontaneous correction is rare. For the present patient, the etiology of crossbite appears to be both skeletal and dental. The ectopic eruption of the right maxillary lateral incisor probably caused premature loss of the adjacent deciduous canine, resulting in a unilateral Class II molar relationship on the right side. The treatment plan attempted to reverse the etiology by retracting the right buccal segment with Class II elastics while opening space for the canine and expanding the maxilla. The molar relationship was corrected to Class I and the midline deviation was resolved. However, the use of a bite turbo and Class II elastics caused a posterior rotation of the mandible creating a more Class II molar relationship bilaterally.

Class II elastics generate clockwise moments on each arch, relative to their centers of resistance. These mechanics result in an opening of the bite, posterior rotation of the mandible, steepening of the plane of occlusion, and flaring of the lower incisors. For patients with a high mandibular plane angle, it is preferable to use an extraction treatment modality or E-A miniscrew anchorage to retract the maxillary dentition as needed without extruding the posterior segments and flaring the lower incisors. Unfortunately the latter two options were repeatedly declined in favor of Class II elastics. At the finish, the dental result was good but there was a significant skeletal compromise, that may result in stability problems.

Anchorage control is a challenging problem in orthodontic treatment. First molars are the primary anchorage units. Including second molars, enhances anchorage but does not completely stabilize the posterior segments. In comparison with conventional anchorage, E-A miniscrews provide osseous anchorage, preventing the undesirable side effects on the posterior segments.<sup>14-18</sup> Osseous anchorage is useful for various types of tooth movement. There are minimal anatomic limitations and the devices are relatively simple to place. The advantages are less traumatic surgery, immediate loading after placement, reduction of treatment time, and enhanced clinical efficiency. In addition, there is less cost, pain, sensitivity or allergic reaction.

The distance from the upper and lower lips to the E-line increased from 1.0 mm to 1.5 mm and from 0.5 mm to 3.0 mm, respectively. The principal deficit with treatment was a more recessive chin. Nevertheless, the facial profile remained balanced without lip strain. Overall, there was a significant improvement in both alignment and function, so the patient was well satisfied with the treatment.

Buccolingual inclination of the second molars indicated a lack of upper buccal root torque and lower lingual root torque. Arch expansion and detailed third order wire bending are needed in the finishing stage to correct these deficiencies. These are typical problems for patients with a narrow maxilla, and even when corrected may not be stable. It was not advisable to expend the treatment plan to correct problems with an uncertain prognosis.

The root angulation of the lower left premolars was not parallel. This discrepancy was recognized early in the progress record, but it presented an interesting dilemma. If the root of #21 were to be tipped distally to make it parallel with #20, then an unesthetic embrasure might be created between #21 and #11. This problem is due to a morphological variation in the buccal cusp of the lower first premolar, which is a common Chinese characteristic.

Non-extraction treatment without E-A miniscrew anchorage certainly increased the degree of difficulty for correcting the current malocclusion. In retrospect, it would have been wise to concentrate on convincing the patient and his family of the necessity for E-A miniscrew anchorage before the start of treatment. It is difficult for patients to appreciate skeletal problems when they note that the dental correction is proceeding as they expected. With appropriate E-A anchorage, it would have been possible to achieve the dental correction with a better facial result, and avoid the flaring of the lower incisors to compensate for the posterior rotation of the mandible.<sup>17-18</sup>

## Conclusion

This case report demonstrates sufficient space is crucial for canine eruption. Open coil springs can create space, but they tend to flare incisors. Although the application of class II elastics can retract buccal segments and resolve the upper anterior flaring, the mechanics produce undesirable side effects that increase facial convexity and

jeopardize lower incisor stability. E-A miniscrews are superior to conventional anchorage for high angle patients with an openbite tendency, so they should be a prospective consideration. All 3<sup>rd</sup> molars should be removed at the age of ~18.

## Acknowledgment

Thanks to Mr. Paul Head for proofreading this article.

## References

- Pitts T. Begin with the end in mind: bracket placement and early elastics protocols for smile arc protection. *Clinical Impressions* 2009;17(1):4-13.
- Yeh HY. Beethoven Orthodontic Center's Effective Bonding Procedure. *Int J Ortho Implantol* 2013;33:102-108.
- Alan B. Review: A conversation. The Damon system: questions and answers. *Clinical Impressions* 2005;14(1):4-13.
- Steffen JM, Haltom FT. The five-cent tooth positioner. *J Clin Orthod* 1987;21:528-529.
- Chang CH. Advanced Damon Course No. 8: Excellence in Finishing. Beethoven Podcast Encyclopedia in Orthodontics [podcast]. Hsinchu: Newton's A Ltd; 2011.
- Chang CH. Basic Damon Course No. 5: Finish Bending. Beethoven Podcast Encyclopedia in Orthodontics [podcast]. Hsinchu: Newton's A Ltd; 2011.
- Lin JJ. Creative orthodontics: blending the Damon system and TADs to manage difficult malocclusions, 2<sup>nd</sup> ed. Taipei: Young Chieh; 2010.
- Kazuo H, et al. Morphologic Characteristics of the Dentition and Palate in Cases of Skeletal Asymmetry. *Angle Orthod*. 2004;74(1):26-30.
- Annicceda SA, et al. Posterior Crossbite and Functional Changes. A Systematic Review. *Angle Orthod* 2009;79 (2):380-386.
- Andrup L, et al. Orthodontics in 12-year-olds. Evaluation of treatment in the primary and mixed dentition in general dental practice. *Tandläkartidningen* årg 91 nr 3 1999.
- Binder RE. Correction of posterior crossbites: diagnosis and treatment. *Pediatric Dentistry* 2004;26(3):266-272.
- Kennedy DB, et al. Unilateral posterior crossbite with mandibular shift: a review. *Journal-Canadian Dental Association*, 2005;71(8):569-573.
- Hesse KL, et al. Changes in condylar position and occlusion associated with maxillary expansion for correction of functional unilateral posterior crossbite. *American J of Orthod and Dentofacial Orthop* 1997;111(4):410-418.
- Prabhat KC, et al. Treatment of Class II malocclusion with noncompliance miniscrew implant-supported distalization system. *Journal of the World Federation of Orthodontists* 2012;1.2: e. 79-86.
- Srinivas N, et al. Evaluation of clinical efficiency of micro implant as an anchorage in comparison with conventional first molar anchorage. *J Int Oral Health* 2012;4(1):33-41.
- Park HS, et al. Nonextraction treatment with micro screw implants. *Angle Orthod* 2004;74(4):539-549.
- Chang CH, Roberts WE. Stability of mini-screws on buccal shelves: a retrospective study of 1680 mini-screw insertions by the same orthodontist. *Int J Orthod Implantol* 2013;30:76-78.
- Chang CH, Roberts WE. A Retrospective Study of the Extra-alveolar Screw Placement on Buccal Shelves. *Int J Orthod Implantol* 2013;32:80-89.
- Chang CH. Advanced Damon Course No. 4, 5: DI & CRE Workshop (1)(2). Beethoven Podcast Encyclopedia in Orthodontics [podcast]. Hsinchu: Newton's A Ltd; 2011.
- Su B. IBOI Pink & White Esthetic Score. *Int J Orthod Implantol* 2012;28:80-85.



## Edward H. Angle Society Cephalometric Summary

Area	Measurement	A <sup>1</sup>	A <sup>2</sup> (progress)	B	Difference A <sup>1</sup> - B
<b>Maxilla to Cranial Base</b>	SNA	83	82	82	1
<b>Mandible to Cranial Base</b>	SNB	78	77	76	1
	SN-Go-Gn	36	37	37	0
	FMA	31	32	32	0
<b>Maxillo-Mandibular</b>	ANB	5	5	6	1
<b>Maxillary Dentition</b>	1 to NA (mm)	3.5 mm	5 mm	4.5 mm	1
	1 to SN	106.5	109	107.5	1
	6-6 (mm) (casts)	48 mm	49 mm	49 mm	1
<b>Mandibular Dentition</b>	1 to NB (mm)	7 mm	13 mm	11.5 mm	4.5
	1 to Go-Gn	98	103	100	2
	6-6 (mm) (casts)	45 mm	44 mm	44 mm	1
	3-3 (mm) (casts)	27 mm	27.5 mm	27.5 mm	0.5
<b>Soft Tissue</b>	Esthetic Plane	U: 1 mm L: 0.5 mm	U: 1 mm L: 2 mm	U: 1.5 mm L: 3 mm	U: 0.5 L: 2.5

A<sup>1</sup> Pretreatment records

A<sup>2</sup> Interim or progress records if indicated

B Posttreatment records

\* NOTE: **Difference between A1 and B.** It is not required for Affiliates to use negative or positive signs to indicate this value. Show only the number difference between the two values. **Note, additional measurements may be used for evaluation. Please place these on additional sheet.**

# Discrepancy Index Worksheet

**TOTAL D.I. SCORE** 17

**OVERJET**

- 0 mm. (edge-to-edge) = 1 pt.
- 1 – 3 mm. = 0 pts.
- 3.1 – 5 mm. = 2 pts.
- 5.1 – 7 mm. = 3 pts.
- 7.1 – 9 mm. = 4 pts.
- > 9 mm. = 5 pts.

Negative OJ (x-bite) 1 pt. per mm. per tooth

Total = 2

**OVERBITE**

- 0 – 3 mm. = 0 pts.
- 3.1 – 5 mm. = 2 pts.
- 5.1 – 7 mm. = 3 pts.
- Impinging (100%) = 5 pts.

Total = 0

**ANTERIOR OPEN BITE**

0 mm. (edge-to-edge), 1 pt. per tooth  
then 1 pt. per additional full mm. per tooth

Total = 0

**LATERAL OPEN BITE**

2 pts. per mm. per tooth

Total = 0

**CROWDING** (only one arch)

- 1 – 3 mm. = 1 pt.
- 3.1 – 5 mm. = 2 pts.
- 5.1 – 7 mm. = 4 pts.
- > 7 mm. = 7 pts.

Total = 7

**OCCLUSION**

- Class I to end on = 0 pts.
- End on Class II or III = 2 pts. per side      pts.
- Full Class II or III = 4 pts. per side 4 pts.
- Beyond Class II or III = 1 pt. per mm.      pts.  
additional

Total = 4

**LINGUAL POSTERIOR X-BITE**

1 pt. per tooth Total = 2

**BUCCAL POSTERIOR X-BITE**

2 pts. per tooth Total = 0

**CEPHALOMETRICS** (See Instructions)

ANB  $\geq 6^\circ$  or  $\leq -2^\circ$  = 4 pts.

Each degree  $< -2^\circ$       x 1 pt. =     

Each degree  $> 6^\circ$       x 1 pt. =     

**SN-MP**

$\geq 38^\circ$  = 2 pts.

Each degree  $> 38^\circ$       x 2 pts. =     

$\leq 26^\circ$  = 1 pt.

Each degree  $< 26^\circ$       x 1 pt. =     

1 to MP  $\geq 99^\circ$  = 1 pt.

Each degree  $> 99^\circ$       x 1 pt. =     

Total = 0

**OTHER** (See Instructions)

- Supernumerary teeth      x 1 pt. =
- Ankylosis of perm. teeth      x 2 pts. =
- Anomalous morphology      x 2 pts. =
- Impaction (except 3<sup>rd</sup> molars)      x 2 pts. =
- Midline discrepancy ( $\geq 3$ mm) @ 2 pts. = 2
- Missing teeth (except 3<sup>rd</sup> molars)      x 1 pts. =
- Missing teeth, congenital      x 2 pts. =
- Spacing (4 or more, per arch)      x 2 pts. =
- Spacing (Mx cent. diastema  $\geq 2$ mm) @ 2 pts. =
- Tooth transposition      x 2 pts. =
- Skeletal asymmetry (nonsurgical tx) @ 3 pts. =
- Addl. treatment complexities      x 2 pts. =

Identify:

Total = 2

# Cast-Radiograph Evaluation

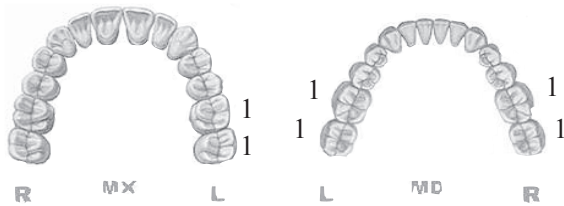
## Interim-Treatment Progress

PROGRESS : 14<sup>th</sup> month in treatment

Total Score: **56**

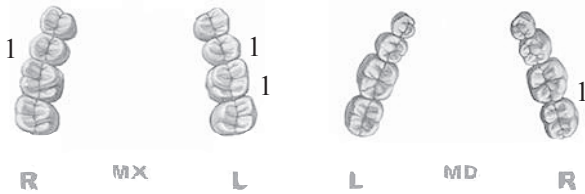
### Alignment/Rotations

**6**



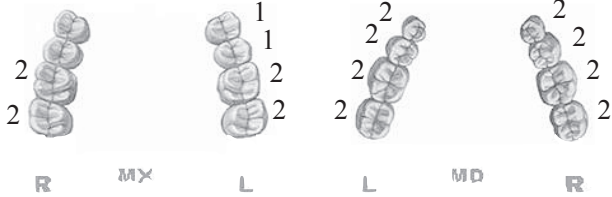
### Marginal Ridges

**3**



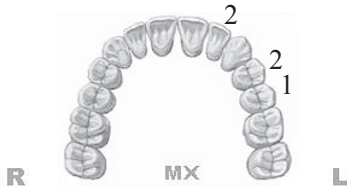### Buccolingual Inclination

**26**



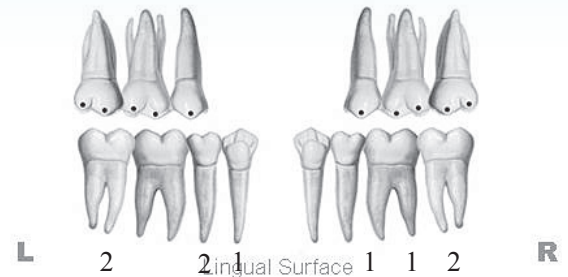
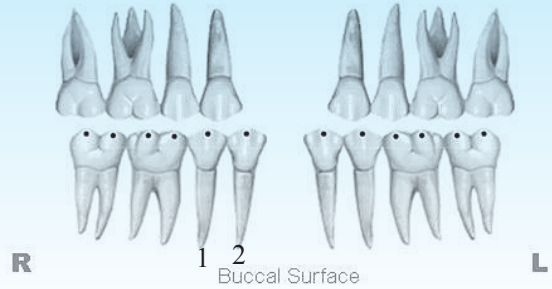
### Overjet

**3**



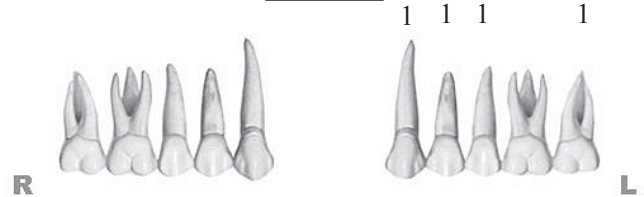
### Occlusal Contacts

**12**



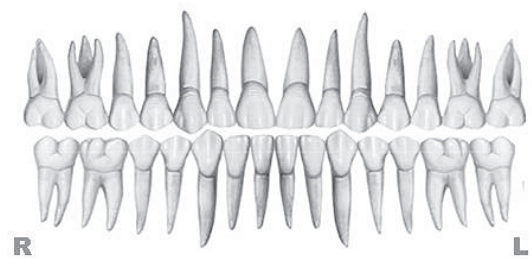
### Occlusal Relationships

**4**



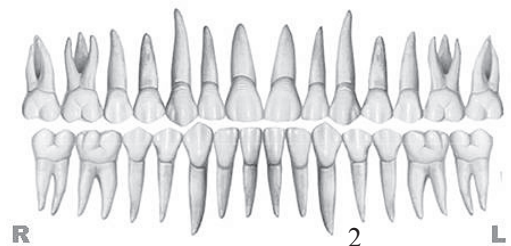
### Interproximal Contacts

**0**



### Root Angulation

**2**

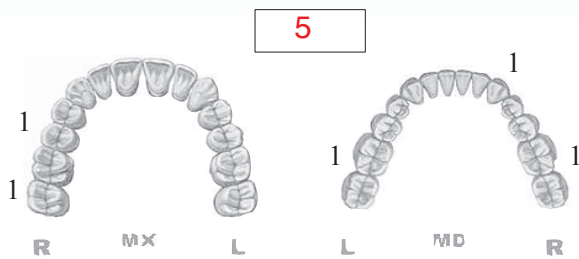


**INSTRUCTIONS:** Place score beside each deficient tooth and enter total score for each parameter in the white box. Mark extracted teeth with "X". Second molars should be in occlusion.

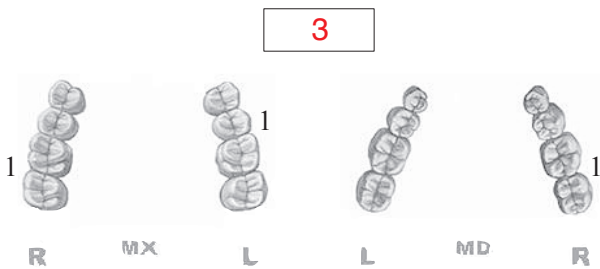
**Cast-Radiograph Evaluation**  
Interim-Treatment Progress

Total Score: **26**

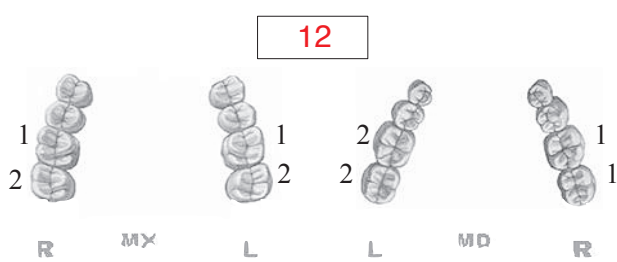
**Alignment/Rotations**



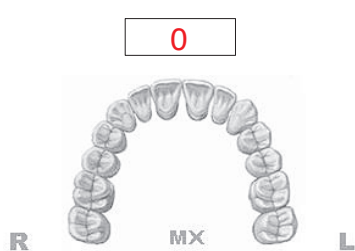**Marginal Ridges**



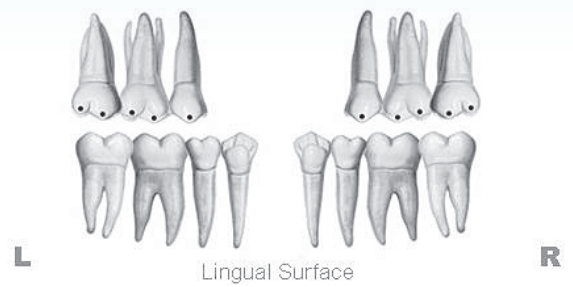
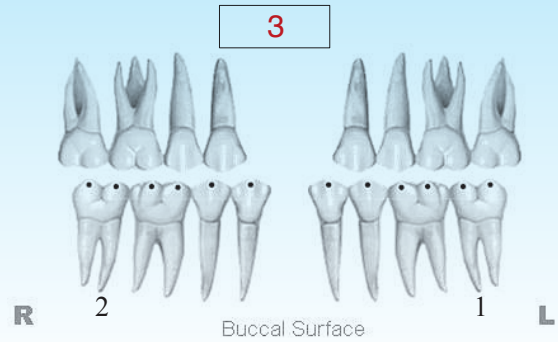
**Buccolingual Inclination**



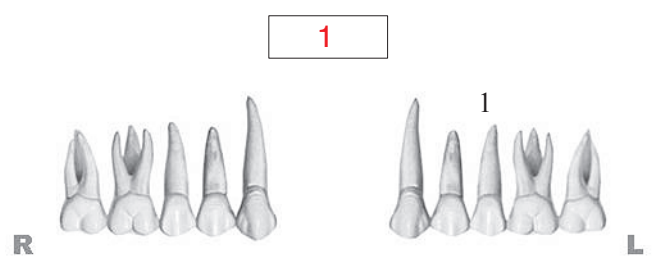
**Overjet**



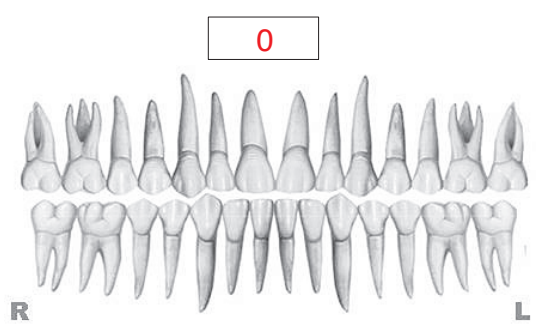
**Occlusal Contacts**



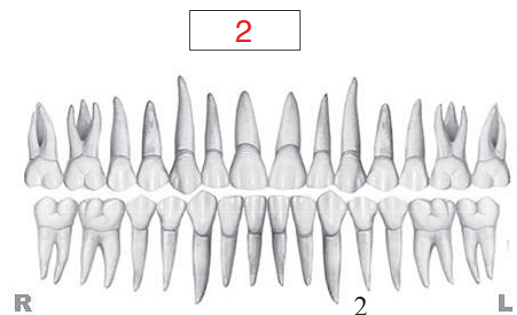
**Occlusal Relationships**



**Interproximal Contacts**



**Root Angulation**

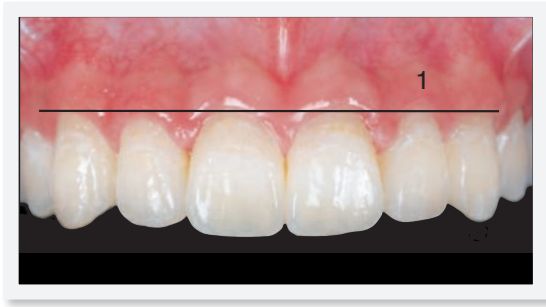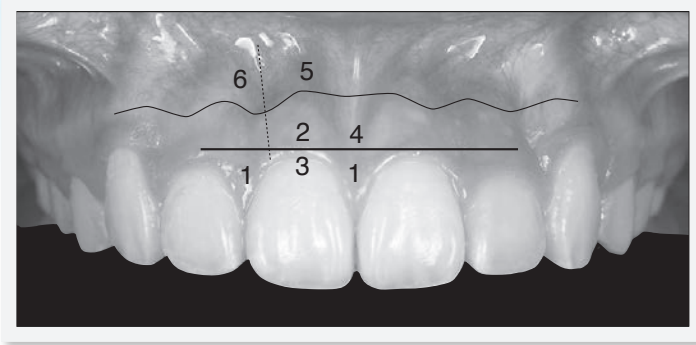


**INSTRUCTIONS:** Place score beside each deficient tooth and enter total score for each parameter in the white box. Mark extracted teeth with "X". Second molars should be in occlusion.

## IBOI Pink & White Esthetic Score (Before Surgical Crown Lengthening)

Total Score: = 3

### 1. Pink Esthetic Score

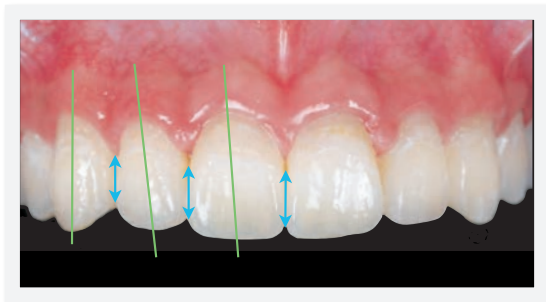
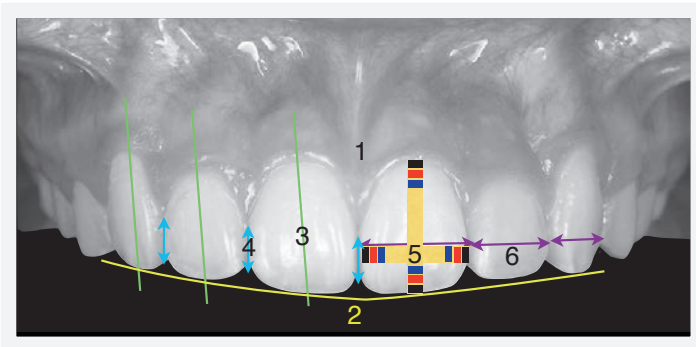


Total = 1

1. Mesial Papilla	0	1	2
2. Distal Papilla	0	1	2
3. Curvature of Gingival Margin	0	1	2
4. Level of Gingival Margin	0	1	2
5. Root Convexity ( Torque )	0	1	2
6. Scar Formation	0	1	2

1. M & D Papillae	<span style="border: 1px solid red; border-radius: 50%; padding: 2px;">0</span>	1	2
2. Keratinized Gingiva	<span style="border: 1px solid red; border-radius: 50%; padding: 2px;">0</span>	1	2
3. Curvature of Gingival Margin	<span style="border: 1px solid red; border-radius: 50%; padding: 2px;">0</span>	1	2
4. Level of Gingival Margin	0	<span style="border: 1px solid red; border-radius: 50%; padding: 2px;">1</span>	2
5. Root Convexity ( Torque )	<span style="border: 1px solid red; border-radius: 50%; padding: 2px;">0</span>	1	2
6. Scar Formation	<span style="border: 1px solid red; border-radius: 50%; padding: 2px;">0</span>	1	2

### 2. White Esthetic Score ( for Micro-esthetics )




Total = 2

1. Midline	0	1	2
2. Incisor Curve	0	1	2
3. Axial Inclination (5°, 8°, 10°)	0	1	2
4. Contact Area (50%, 40%, 30%)	0	1	2
5. Tooth Proportion (1:0.8)	0	1	2
6. Tooth to Tooth Proportion	0	1	2

1. Midline	<span style="border: 1px solid red; border-radius: 50%; padding: 2px;">0</span>	1	2
2. Incisor Curve	<span style="border: 1px solid red; border-radius: 50%; padding: 2px;">0</span>	1	2
3. Axial Inclination (5°, 8°, 10°)	0	<span style="border: 1px solid red; border-radius: 50%; padding: 2px;">1</span>	2
4. Contact Area (50%, 40%, 30%)	0	<span style="border: 1px solid red; border-radius: 50%; padding: 2px;">1</span>	2
5. Tooth Proportion (1:0.8)	<span style="border: 1px solid red; border-radius: 50%; padding: 2px;">0</span>	1	2
6. Tooth to Tooth Proportion	<span style="border: 1px solid red; border-radius: 50%; padding: 2px;">0</span>	1	2





Keep It Square and Straight

# 舌側矯正之 全面進化

方中帶直

## 講師介紹

### Dr. Kyoto Takemoto

- World Society of Lingual Orthodontics (Founding Member, Former President)
- World Board of Lingual Orthodontists (Board Member)
- European Board of Orthodontics (Board Member)
- European Society of Lingual Orthodontics (Honorary Member)
- Japanese Orthodontic Society (Specialty Certified)
- Japanese Association of Adult Orthodontics (Specialty Certified)
- Japanese Lingual Orthodontic Association (Specialty Certified)
- Ferrara University (Visiting Professor)
- Royal College of Surgeons Edinburgh (Fellow)



## 報名資訊

時間：2014.11/02-03 (Sun.-Mon.)

地點：財團法人張榮發基金會

地址：台北市中正區中山南路11號 8F 國際會議廳

主辦單位：臺灣舌側矯正研討會&臺灣楓城牙醫學會

協辦單位：湧傑企業股份有限公司

收費：2 days

2014/10/03 前會員7,000元 非會員9,000元 學生3,500元

2014/10/04 後會員8,000元 非會員10,000元 學生4,000元

報名方式：請於報名後3日劃撥費用至

戶名：湧傑企業股份有限公司 帳號：17471807

報名電話：02-27788315 #122 楊's #123李's

0955309108 藍明賢醫師

## 課程內容

舌側矯正透過數位化科技的彎線技術在近年來逐漸被廣泛運用。然而，往往需要經由非常複雜的彎線及調整才能成功地完成治療。

為了減少複雜的彎線需求並配合 L.S.W. (Lingual Straight Wire) 的應用，我們發展出了**Square Slot Bracket System**。換句話說，舌側矯正已經正式進入到直線系統的年代。在 E-line 診所，我們從2006年開始就已經將全新 L.S.W. 系統套用在所有臨床案例當中。

2007年，我們先研發了第一代 Square Slot Bracket System (STb SL)來搭配 L.S.W.，之後再改良設計出新款 Square Slot Bracket，並正式命名為 **ALIAS**。

**ALIAS** 三大理念：

**Square Slot**：精準掌控牙齒移動過程，有利於正確地預測治療結果。

**Straight Wire**：精準的矯正器黏著，搭配 Full Sized 用線，可大量減少彎線需求。

**Passive Self-ligation System**：減少摩擦力，實踐人性化矯正。

在此次演講中將介紹有關於全新 **Square Slot** 矯正器的生物力學。並分享結合 **ALIAS** 三大理念的臨床案例。

\* 本文宣品僅供牙科診所及牙醫師參考，禁止張貼或擺置於公眾可瀏覽及取閱之處

\* 因應個人資料保護法，當您或由湧傑業務幫您填寫此訂購單或(報名資料表)時，即視為同意您的個人資料由本公司在蒐集目的之範圍內予以處理及利用

# Beethoven International Damon, OBS & VISTA Workshop

2014 12/1~12/4, 2015 6/16~6/19, 11/24~27



## LECTURER: Dr. Chris Chang

CEO, Beethoven Orthodontic and Implant Group. He received his PhD in bone physiology and Certificate in Orthodontics from Indiana University in 1996. As publisher of *International Journal of Orthodontics & Implantology*, he has been actively involved in the design and application of orthodontic bone screws.



## LECTURER: Dr. John Lin

President of the Jin-Jong Lin Orthodontic Clinic. Dr. Lin received his MS. from Marquette University and is an internationally renowned lecturer. He's also the author of Creative Orthodontics and consultant to *International Journal of Orthodontics & Implantology*.

### Dear Chris:

[...] My development as lecturer and orthodontist has evolved greatly. Thanks to this great experience, I came back from Taiwan with the best and latest technique, knowledge, valuable and practical tools, including how to make successful presentations using the resources of MAC technology-rightly led by you in your country. I have also received invaluable and unparalleled academic material on the proper use, benefits and applications of mini-implants.

I will always be thankful not only to you but also to your friendly and dedicated wife, your clinic team in which I found a model for organization, care and functionality. I will never forget all the attentions received and all the time spent on my professional development regardless of the multiple occupations and other responsibilities you all have[...].



Dr. Patricia Vergara Villarreal (right)  
Orthodontist, the Military University.CIEO. of Bogota

### Dear Chris:

[...]I can only say that the Workshop exceeded my expectation and it was truly amazing. Lectures by the world class orthodontists (Dr. Chris Chang and Dr. John Lin), and wealth of knowledge from your many years of dedication, wisdom, and clinical experiences were evident through the cases you presented. I am also very much appreciative of the opportunity to observe you actively and effortlessly practicing what you teach through the chair-side observation session held in your very busy practice.

First, as an innovative educator, you encouraged us to be innovative. Second, you taught us your system and showed us tools in Damon and OBS for us to succeed and duplicate it in each of our own practices. Third, you motivated us to continue to continually improve the system. Personally, I am very grateful and thankful for these three pieces of advice you gave to us[...].



John K.S. Tong, DDS, MAGD  
Cupertino, California USA

For more information and registration, visit

<http://iworkshop.beethoven.tw>



Like

Chris Chang



On Facebook

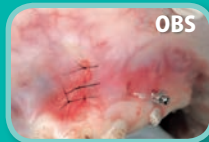
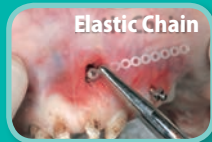
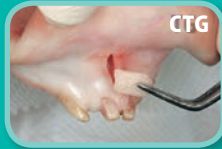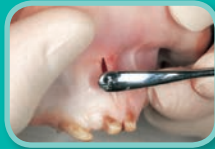# VISTA for Impacted Cuspids In-house Workshop (Pig Jaw)



VISTA for Impacted Cuspids in-office workshop includes one half-day hands-on practice:

1. VISTA with Screw Placement
2. VISTA with Connective Tissue Graft
3. Suture Technique



VISTA:  
Vertical Incision Subperiosteal Tunnel Access

## Damon, OBS & VISTA



### Day 1

- 13:00—14:00 Welcome Lunch
- 14:00—14:40 Orientation
- 14:40—15:00 Introduction of Beethoven Dental Group
- 15:00—18:30 Chair-side observation

### Day 2

- 9:00—10:30 Optimized Orthodontic Treatment I  
*Dr. Chris Chang*
- 10:30—11:00 Break
- 11:00—12:30 Optimized Orthodontic Treatment II  
*Dr. Chris Chang*
- 12:30—13:50 Lunch
- 14:00—15:00 Screw Model Practice
- 15:00—18:30 Chair-side observation

### Day 3

- 09:00—10:00 VISTA for Impacted Cuspids
- 10:00—10:10 Break
- 10:10—12:30 Damon + Screw *Dr. John Lin*
- 12:30—13:30 Lunch
- 14:00—17:00 VISTA for Impacted Cuspids In-office Workshop (Pig Jaw)



### Day 4 - Keynote

- 09:00—10:00 Introduction of Keynote: Organize your patient files for presentation
- 10:00—10:10 Break
- 10:10—11:30 Key Presentation Principles I
- 11:30—13:30 Lunch
- 14:00—15:30 Key Presentation Principles II
- 15:30—15:45 Break
- 15:45—17:00 Make it Visual

## Keynote Workshop

Make your presentation great

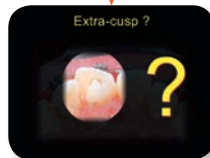
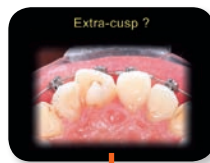"I've been a Keynote user and lecturer for 9 years. In June I had the opportunity to attend Newton's A's Introductory Keynote course. To my surprise, I still learn a lot from this supposed to be basic course.

If you think this is a computer course that will show you step-by-step how to use the application, please reconsider. This course is to teach you hands-on, clinical presentation tips. After this course I'm sure that any of you can go back and give a better presentation in your daily dental practice.

If you want to improve communication in your practice, and with patients, this 8-hour course is definitely worth it."

~ **Dr. Rungsi Thavarungkul, Thailand**

*Lecturer, Advanced Keynote Animation and Illustration Workshop*



## Damon & OBS Workshop

includes two half-day lectures, two half-day chair-side observation sessions, one model practice and one surgical hands-on session.

*Registration fees cover local transportation, meals and two nights of shared accommodation (double occupancy). Airport pick up is available upon request with additional charges.*

**Fees: USD 2,600**

Early bird rate:

USD 200 off by 2014 10/01, 2015 4/16, 9/24

## Keynote Presentation workshop

includes one day of lecture and hands-on practice, focusing on improving your professional digital communication skills. The workshop adopts the Macintosh (Apple) system and its native presentation software, Keynote '09.

*Registration fees cover local transportation, meals and one nights of shared accommodation (double occupancy).*

**Fees: USD 500**

Early bird rate:

USD 100 off by 2014 10/01, 2015 4/16, 9/24

## Registration:

A 50% deposit is required to complete registration.

To make a payment by wire, please contact us at [course@newtonsa.com.tw](mailto:course@newtonsa.com.tw) or call +886-3-5735676 for more information.



# Oligodontia and Class II Malocclusion Treated with Orthodontics, Bone Augmentation, and an Implant-Supported Prosthesis

## Summary

A 29 year female presented with a partially edentulous, compensated Class II malocclusion. There were twelve missing permanent teeth including two third molars; nine were congenitally missing. Cephalometrics revealed an underlying Class II skeletal pattern: facial convexity 15°, ANB angle 4° and lower incisor to mandibular plane angle of 106°. The lack of molar antagonists on the right side resulted in an unstable occlusion that was associated with a large mandibular edentulous space (area teeth #29-31) as well as extruded upper and lower molars (teeth #3 and 32). Diagnostically, this acquired malocclusion had an ABO Discrepancy Index (DI) of 18, with 3 additional points added for an unfavorable implant site, resulting in an overall interdisciplinary DI of 21 points. The patient preferred no extractions, orthodontics only in the upper arch, and decided against replacing an unesthetic maxillary anterior fixed prosthesis. Interdisciplinary care involved space closure in the left quadrant and arch alignment. The maxillary right 1<sup>st</sup> molar was intruded with buccal and lingual temporary anchorage devices, augmented with a temporary implant-supported prosthesis. The lower right atrophic edentulous ridge was split and spread to receive two implants to restore teeth #29 and 30 with an implant-supported prosthesis. Despite the limitations on treatment options, an optimal occlusion was achieved, as evidenced by a Cast-Radiograph Evaluation (CRE) = 26. The atrophic lower right implant site was successfully restored as evidenced by a 5 point score on the Implant-Abutment Transition and Position Analysis. The Pink & White dental esthetics were not scored because there were no changes in the esthetic zone. (*Int J Ortho Implantol* 2014;36:52-69)

### Key words:

oligodontia, self-ligating bracket, bone splitting and spreading, implant-supported prostheses

## History and Etiology

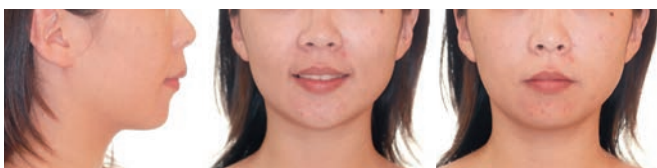A 29-year old woman presented with a chief complaint of chewing problems due to multiple missing teeth (Figs. 1-3). Despite malocclusion complexity, Discrepancy Index (DI) =18 and significant limitations imposed on the scope of treatment, the final result was good (Figs. 4-8), as evidenced by a CRE of 26 points. Cephalometric documentation of the treatment is presented in Fig. 9.

There were a number of important diagnostic considerations for the successful management of this severe problem. Pre-treatment photographs (Figs. 1-2) revealed a symmetrical face, relatively convex profile, and a nasolabial angle that was within normal limits (WNL). An unesthetic fixed prosthesis restored the missing right lateral incisor. The medical history was noncontributory. Dental history and radiographic evaluation (Fig. 7) was consistent with a congenital oligodontia because nine permanent teeth (excluding third molars) were

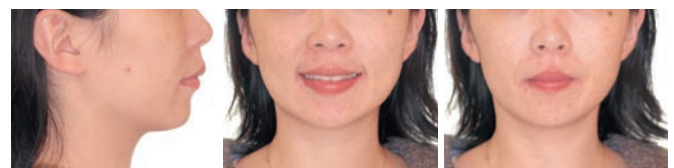**Dr. Hui-Hwa Chen,**  
Lecturer, Beethoven Orthodontic Course (Left)

**Dr. Chris Chang,**  
Founder, Beethoven Orthodontic Center  
Publisher, International Journal of Orthodontics & Implantology (middle)

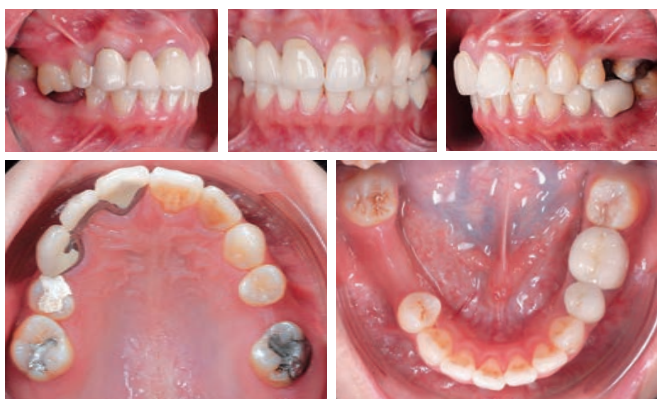**W. Eugene Roberts,**  
Consultant, International Journal of Orthodontics & Implantology (right)



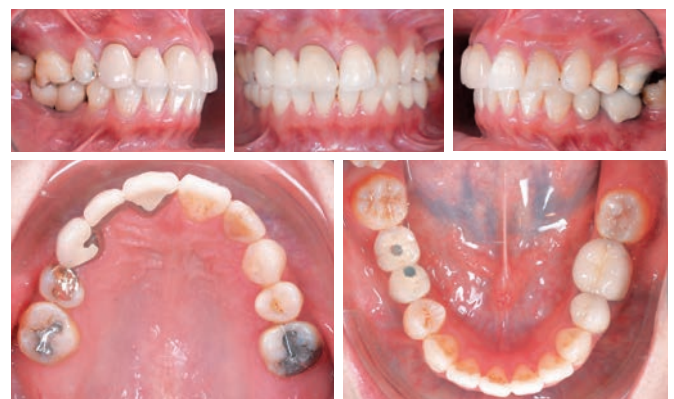■ Fig. 1: Pre-treatment facial photographs



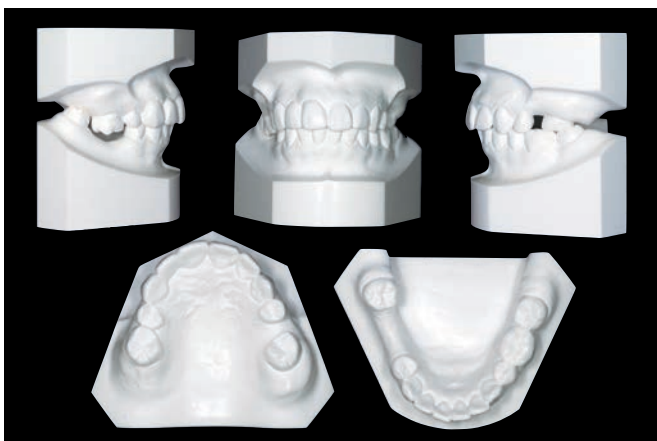■ Fig. 4: Post-treatment facial photographs



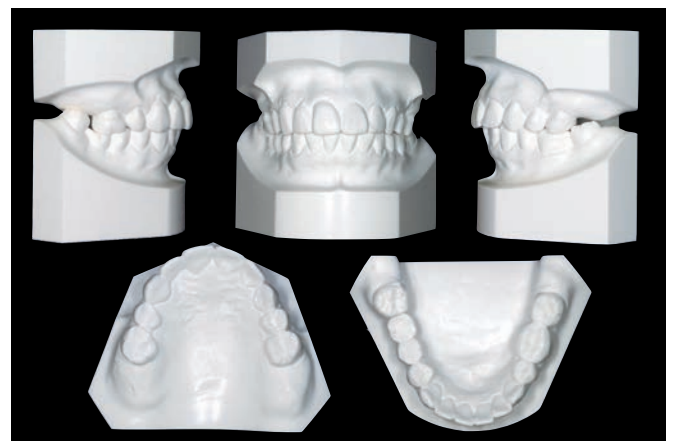■ Fig. 2:  
Pre-treatment intraoral photographs reveal extrusion of the upper right first (#3) and lower right (#31) third molars, and edentulous spaces in upper left and lower right quadrants.



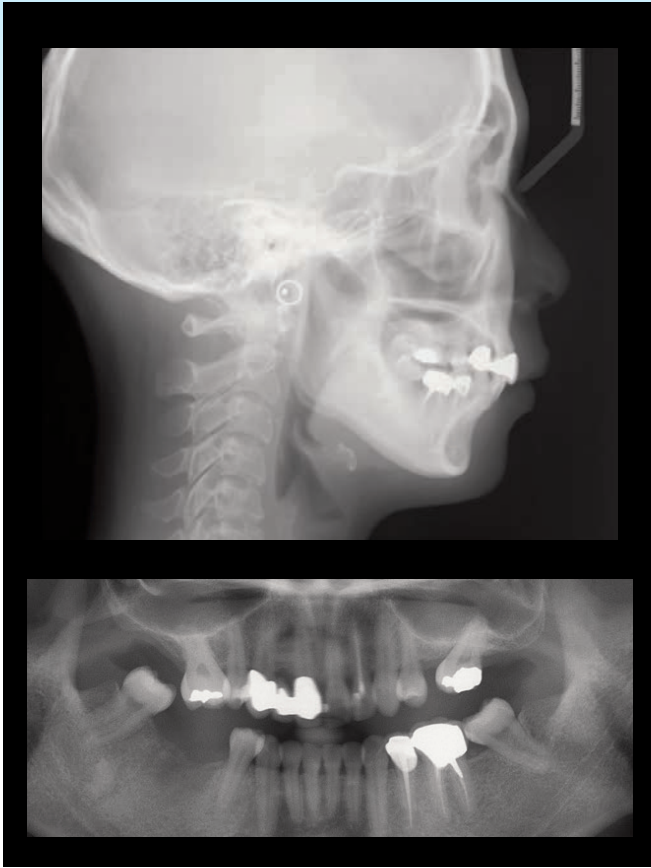
■ Fig. 5:  
Post-treatment intraoral photographs document the final alignment and stabilization of the occlusion with an implant-supported prostheses in the lower right posterior quadrant.



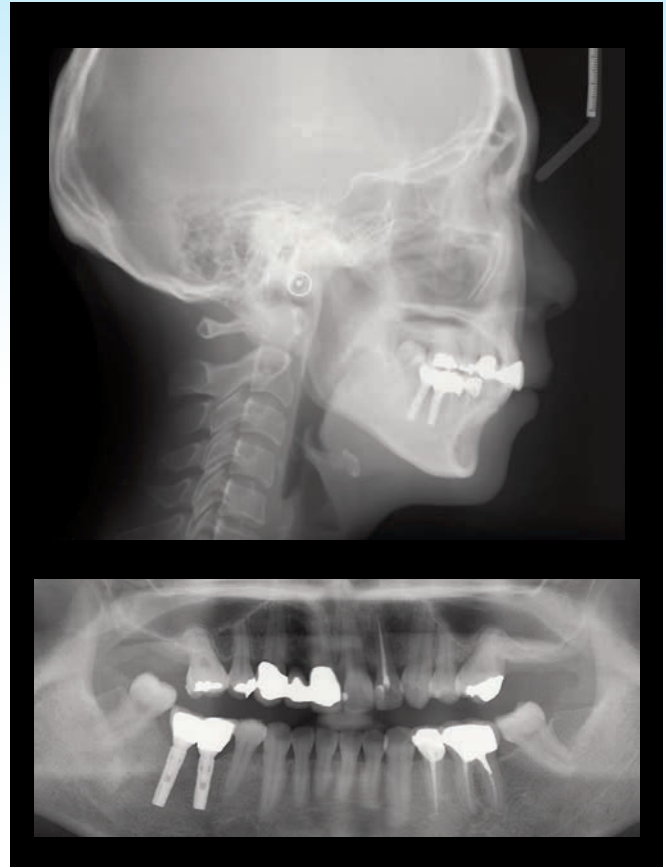
■ Fig. 3: Pre-treatment study models (casts)



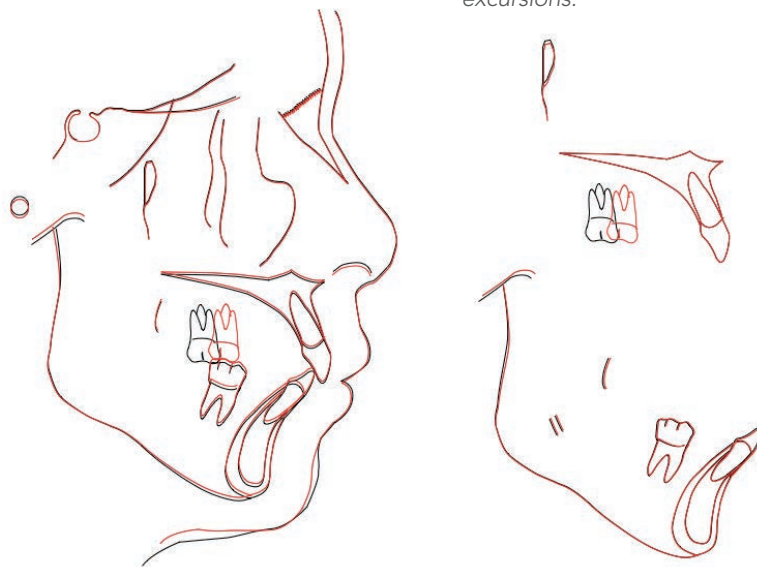
■ Fig. 6: Post-treatment study models (Casts)



**Fig. 7:** Pre-treatment panoramic and cephalometric radiographs document the unstable occlusion, due to edentulous spaces and extrusion of unopposed molars.



**Fig. 8:** Post-treatment panoramic and cephalometric radiographs document the final alignment and stabilization of the occlusion with an implant-supported prostheses. The patient chose to retain the unopposed lower right third molar contrary to professional advice. There is concern that it may cause soft tissue irritation and interfere with protrusive excursions.



**Fig. 9:** Pre-treatment (black) and post-treatment (red) cephalometric tracings are superimposed on stable skeletal structures of the anterior cranial base (left), maxilla (upper right) and mandible (lower right). Note that the upper left first molar was protracted during space closure because of the anchorage provided by the overbite.

CEPHALOMETRIC			
SKELETAL ANALYSIS			
	PRE-Tx	POST-Tx	DIFF.
SNA°	87°	87°	0°
SNB°	83°	83°	0°
ANB°	4°	4°	0°
SN-MP°	29°	29°	0°
FMA°	22°	22°	0°
DENTAL ANALYSIS			
U1 TO NA mm	4 mm	4 mm	6 mm
U1 TO SN°	110°	109°	1°
L1 TO NB mm	8 mm	8 mm	0 mm
L1 TO MP°	106°	106°	0°
FACIAL ANALYSIS			
E-LINE UL	2 mm	2 mm	0 mm
E-LINE LL	2 mm	2 mm	0 mm

Table 1: Cephalometric summary

missing, including the maxillary left lateral incisor and all four second premolars. The initial panoramic radiograph (Fig. 9) was consistent with at least one molar extraction in the lower right segment. Overall, there was a total of 12 missing teeth, two of which were third molars. The loss of the lower right mandibular molar resulted in an unstable, asymmetric occlusion (Figs. 3 and 7). The latter was associated with a large mandibular edentulous space (*area teeth #29-31*) and extruded upper and lower molars (*teeth #3 and 32*).

### Diagnosis

#### Skeletal:

- Skeletal Class II (SNA 87°, SNB 83°, ANB 4°)
- Low mandibular plane angle (SN-MP 29°, FMA 22°)
- Condylar heads are relatively symmetric (Fig. 10)

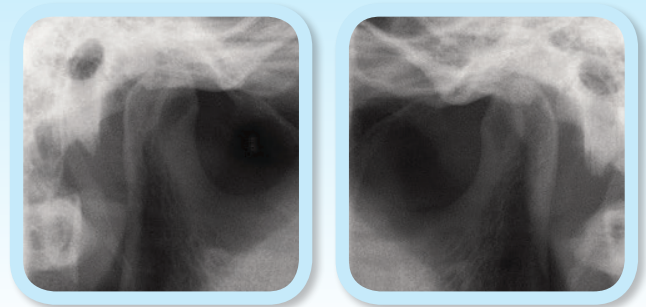


Fig. 10: Radiographic images of the mandibular condyles document symmetrical temporomandibular relationships.

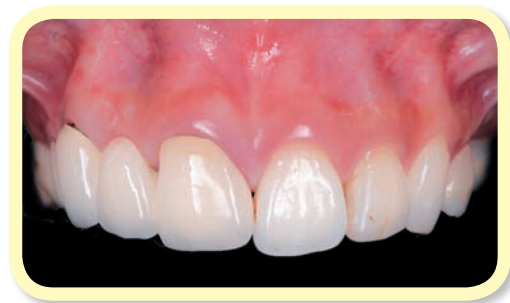

Fig. 11: The unesthetic anterior prostheses was not a priority for the patient. There was no orthodontic or restorative treatment in the maxillary anterior esthetic zone.

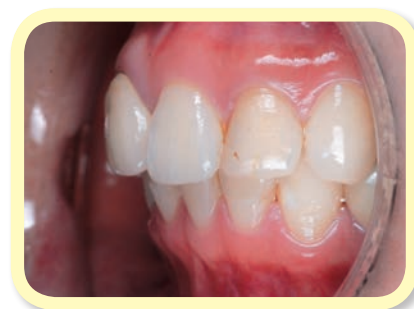

Fig. 12: The apparent large overjet of the incisors is partially masked by the increased axial inclination of the lower incisors and the moderately deep overbite of 3.5mm.

#### Dental:

- Unesthetic maxillary anterior segment (Fig. 11) and large overjet (Fig. 12)
- Canine relationship: Class II right and Class I left (Fig. 3)
- Midlines: facial, maxillary and mandibular midlines are coincident (Figs. 1-3)

- Upper right first (<sup>#</sup>3) and lower right third molars (<sup>#</sup>31) are extruded
- Missing Teeth: <sup>#</sup>1, 2, 4, 7, 13, 15, 16, 18, 20, 29, 30, and 31
- Spaces: *multiple edentulous spaces in both arches*
- Caries in upper right first premolar

#### Facial:

- Convex profile (*Figs. 1, 7 and 9*)
- Slightly protrusive upper and lower lips
- Facial symmetry; unesthetic maxillary dental smile-line due to maxillary anterior prostheses (*Fig. 11*)

The ABO Discrepancy Index (DI) was 18; the major discrepancies were missing teeth and flared lower incisors. A further 3 points were deducted for the compromised implant site: thin gingival biotype, different horizontal bone level relative to adjacent teeth and knife-edge osseous ridge. The overall DI was 21, as shown in the subsequent worksheet.<sup>1,2</sup>

### Treatment Objectives

The clinical objectives were to optimally restore occlusal function and esthetics with interdisciplinary treatment, involving full fixed orthodontics treatment and implant-supported prostheses as follows:

- Gain space between bilateral upper first premolars and first molars for implant-supported crowns.
- Create sufficient interarch space and bone width for implant placement in the mandibular right second premolar and molar region.

- Replace unesthetic maxillary anterior fixed prosthesis, and restore temporary restoration in the upper right first premolar with a gold inlay.
- Extract the lower right third molar to avoid extrusion and protrusive interference.

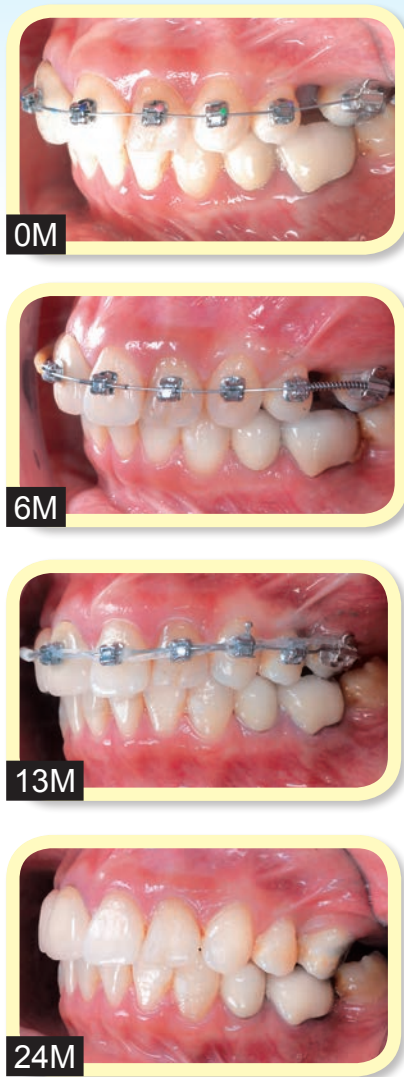### Treatment Alternatives

The patient **only** agreed to portions of the proposed treatment plan. Orthodontics treatment was restricted to the maxillary arch for space closure and alignment to prepare for an implant-supported prostheses to restore the lower right first molar and second premolar. Extraction of lower right third molar was deleted and the patient did not want to replace the unesthetic maxillary anterior prosthesis. A compromised treatment plan was devised that involved orthodontics to close space in the upper arch and level the occlusal plane to create sufficient interarch space for a lower right implant-supported prosthesis. The patient was informed that this treatment plan revision would probably result in compromised dental axial inclinations, no improvement in maxillary esthetics, and leave an unopposed lower third molar, that would likely contribute to future soft tissue and occlusion problems. The patient accepted these limitations and decided to proceed with treatment.

### Treatment Plan and Sequence

1. Fixed orthodontic appliance in the upper arch
2. Compressed NiTi open coil spring mesial to <sup>#</sup>14 for uprighting, followed by space closure to move it mesially using the overbite as anchorage (*Figs. 7 and 13*).





■ **Fig. 13:** Orthodontics alignment and space closure in the maxillary arch is documented at the start (0M), 6 months (6M), 12 months (12M) and at the end of 24 months (24M) of active treatment.

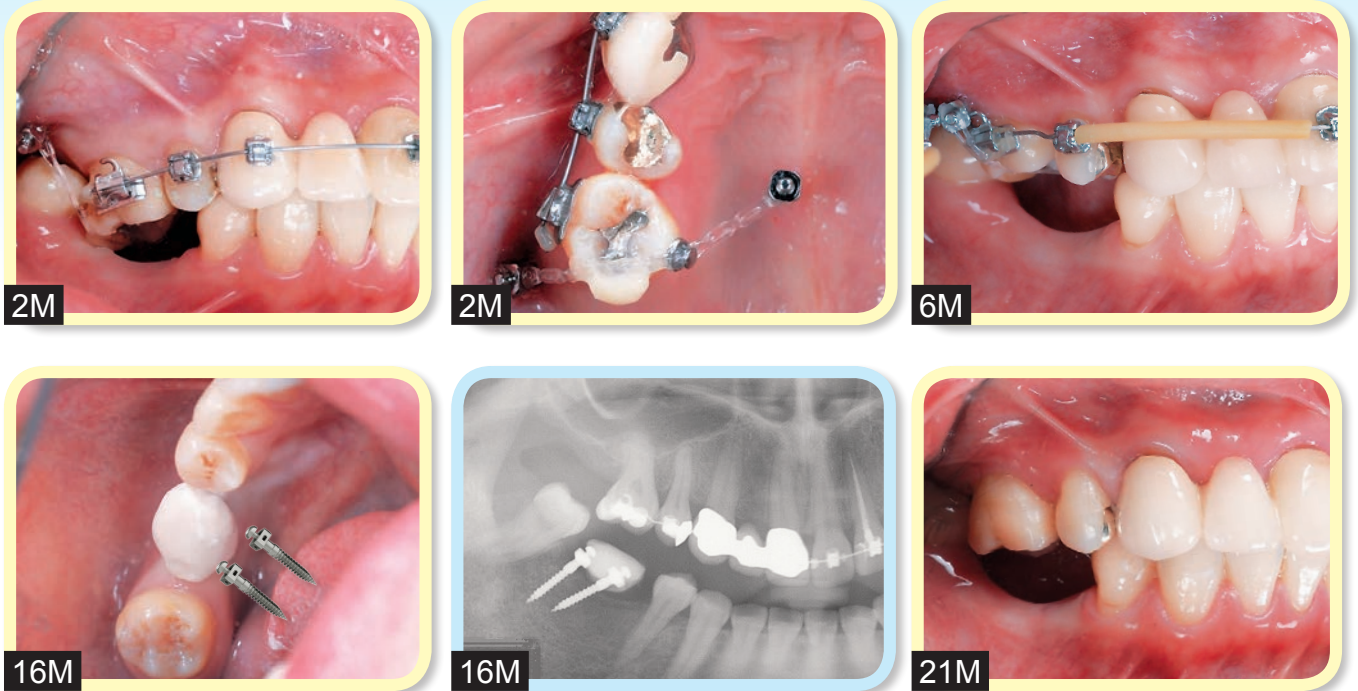
3. Intrude upper right first molar by leveling the arch and intruding by placing a temporary prosthesis in the lower right edentulous space.
4. Fabricated in gold inlay for the upper right first premolar.

5. Place implants in the lower right second premolar and first molar regions by using bone splitting and spreading.
6. Once the implants integrate, restore with a fixed crowns.
7. Retention of the corrected malocclusion using a clear retainer for both the maxillary and mandibular arches.

### Appliances and Treatment Progress

Damon Q® .022" brackets with standard torque (Ormco, Glendora CA) were bonded on the maxillary teeth. The initial wire was .014" CuNiTi. In the 2<sup>nd</sup> month, the arch wire was changed to .018" CuNiTi. In the 3<sup>rd</sup> month, two 2x12mm OrthoBoneScrews (OBS) (Newton's A, Ltd, Taiwan) were inserted in the palate and right infrazygomatic crest. Power chains were attached from tooth #3 to the OBSs on both the buccal and palatal surfaces to intrude the extruded molar (Fig. 14). In the 4<sup>th</sup> month, a compressed NiTi open coil spring was placed on the mesial of the upper left first molar (#14) to correct its axial inclination and the archwire was changed to a .014x.025" CuNiTi. Subsequently, the upper left space was closed with a power chain and the arch wire was changed to .017x.025" TMA in the 7<sup>th</sup> month. These mechanics were designed to protract #14 using the overbite as anchorage (Fig. 13).

In the 16<sup>th</sup> month, a temporary fixed prosthesis was constructed to apply occlusal pressure on #3 to assist with its intrusion. The temporary prostheses was made by inserting two OBSs in the lower right edentulous area. Fuji II Glass Ionomer Cement Type II



■ Fig. 14:

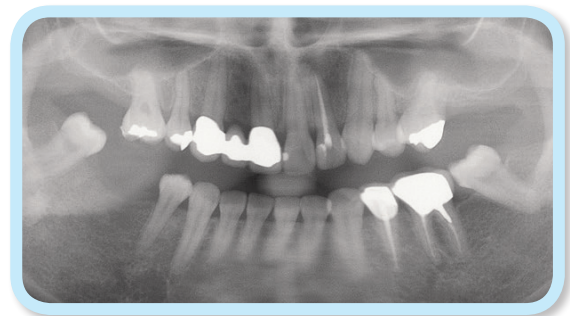
Progress photographs for 2-21 months of orthodontics treatment show the intrusion of the upper right first molar. At 2 months (2M) power chains were anchored by OBSs to deliver intrusive force on the buccal and the lingual. At 16 months (16M) a temporary prosthesis was constructed to oppose the extruded tooth #3. Note at 21 months (21M) there is adequate interocclusal space created for an implant-supported prosthesis.

(GC America, Alsip IL) was used to connect the screws and create an occlusal surface (Fig. 14).

In the 19<sup>th</sup> month, the bracket position was changed to a more mesial inclination on the upper left second molar via progressive archwires: .018"CuNiTi, .014x.025"CuNiTi and .017x.025" TMA. A panoramic radiograph was exposed to evaluate root alignment (Fig. 15). In the 23<sup>rd</sup> month, all brackets were removed, and a clear overlay retainer was delivered for the upper arch.

The patient was then scheduled for the final restorative procedures. The temporary restoration in the upper right first premolar was replaced with

a gold inlay, and two implants were placed to permanently restore teeth #29 and 30.



■ Fig. 15:

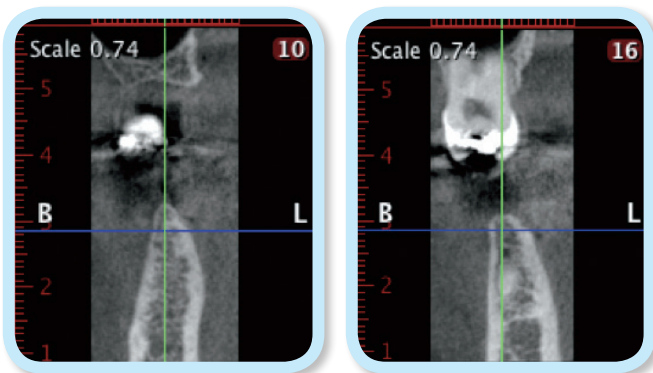
Following orthodontics a panoramic radiograph documents the pre-prosthetic preparation of the maxillary arch. There was no orthodontics treatment in the lower arch.

### Implant Placement

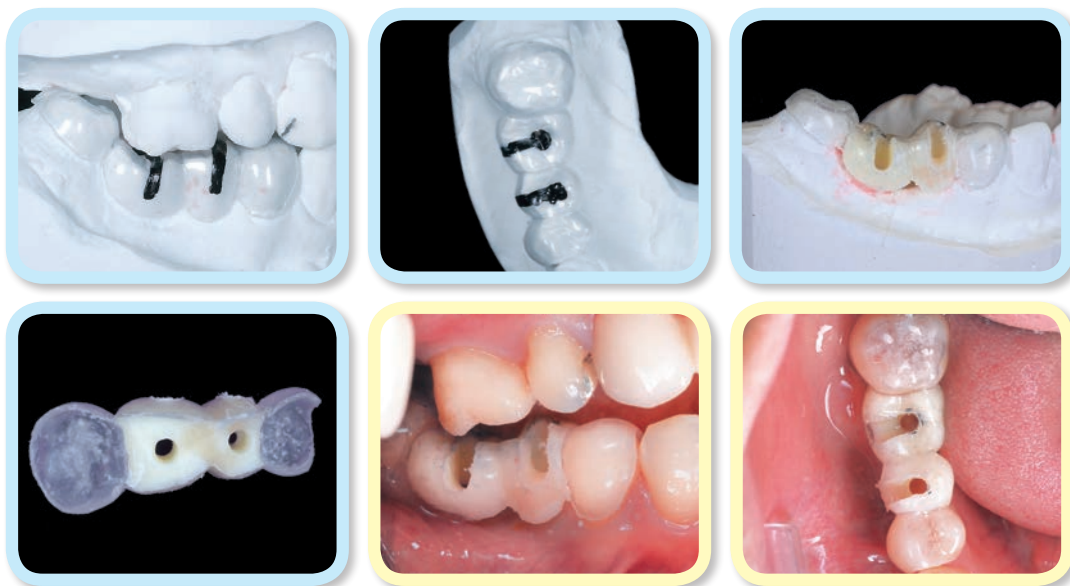A preoperative CBCT scan was used to evaluate the alveolar bone volume (Fig. 16). Tooth #29 area was 12 mm in height x 3.8 mm in width and the tooth #30 area was 14 mm in height x 3.8 mm in width. Since there was insufficient bone volume in both areas, simultaneous bone splitting and spreading was indicated prior to implant placement. A surgical stent facilitated precise implant placement in three dimensions (Fig. 17). The implant fixture was

positioned 3 mm below the future crown margin and no closer than 1.5 mm to the adjacent teeth.<sup>3</sup>

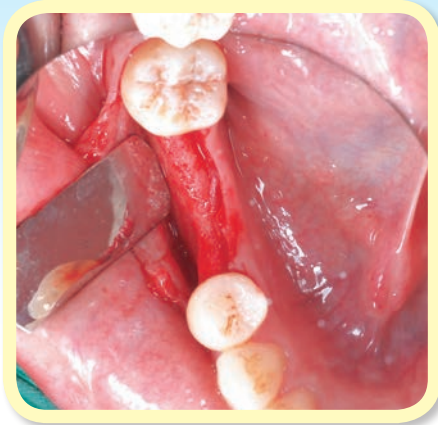
In the #29-30 area, a crestal incision was performed along the lingual line angle with a No.15c scalpel. Sulcular incisions were made on the buccal and lingual sides of the adjacent teeth to achieve adequate flap reflection (Fig. 18). After exposing the bone with full-thickness flaps, the knife-edged crestal bone was trimmed with a diamond bur until 4.5mm of bone width was achieved (Fig. 19). The bone was then split using a disc that was .025mm thick and 3.2mm deep (Fig. 20). The surgical stent was fitted to guide the lance and twist drills for the initial osteotomy (Figs. 21-23); the final depth of the osteotomy corresponded to the implant length. A surgical guide pin (Fig. 24) was placed in the osteotomy, and a periapical radiograph revealed the implant in the #29 area almost impinging on the root of #28 (Fig. 25 ). A Linderman side cutting drill was used to change the direction of the osteotomy to parallel the adjacent tooth (Fig. 26).



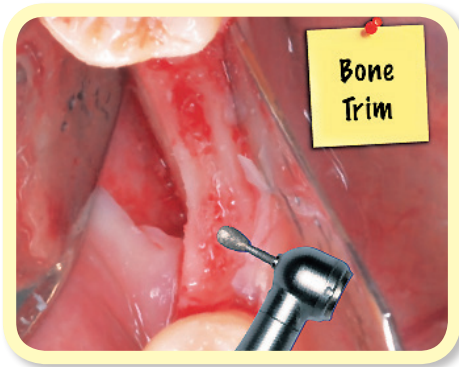
■ Fig. 16: A preoperative CBCT scan shows the narrow width of the lower right edentulous arch.



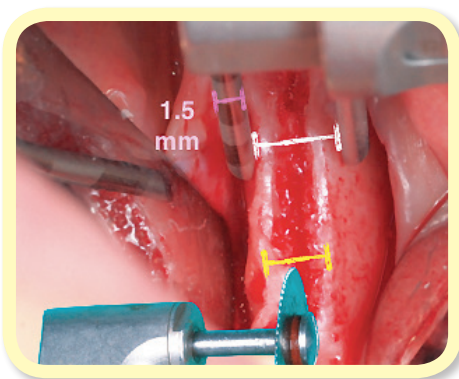
■ Fig. 17: A resin surgical stent was used as a drill guide.



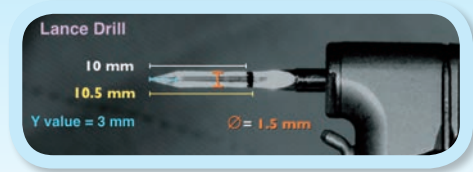
■ Fig. 18:  
A crestal incision was performed at the lingual line angle of the edentulous ridge.



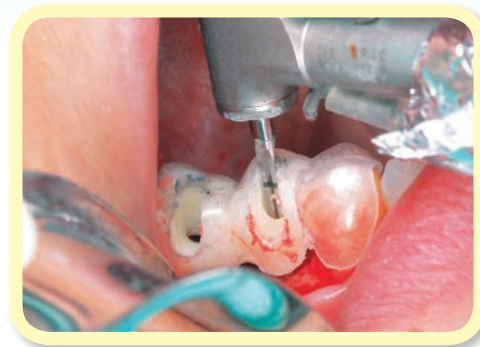
■ Fig. 19:  
The narrow crestal ridge of bone was reduced with a diamond bur until the ridge was  $\geq 4.5\text{mm}$  in width.



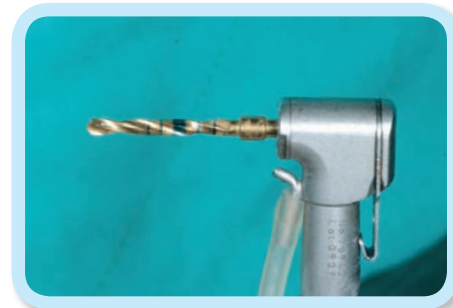
■ Fig. 20:  
A disc was used to split the bone through the marrow space.



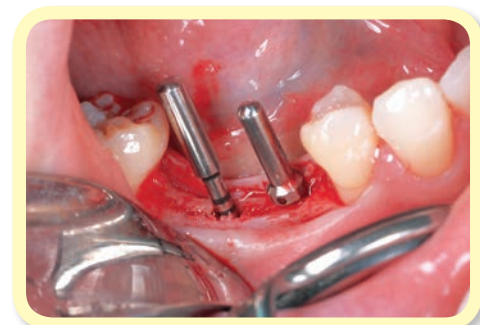
■ Fig. 21:  
The initial osteotomy was performed with a lance drill as shown.



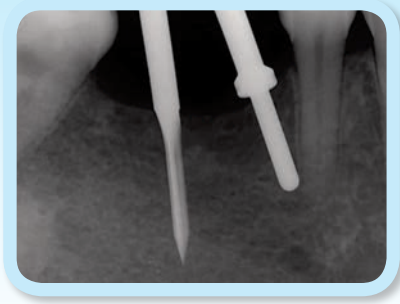■ Fig. 22:  
The surgical stent was fitted to the adjacent teeth to guide the lance and twist drills for the initial osteotomy.



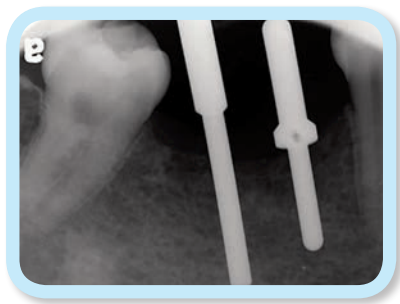
■ Fig. 23:  
The twist drill enlarged the osteotomy formed by the lance drill.



■ Fig. 24:  
Surgical guide pins were inserted in each osteotomy to check the orientation.

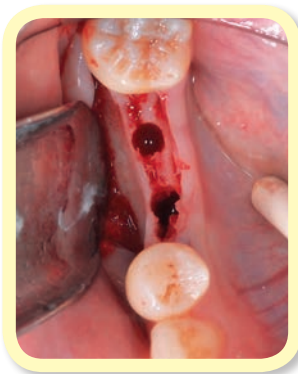


■ **Fig. 25:**  
The mesial osteotomy is almost in contact with the root of tooth #28.



■ **Fig. 26:**  
A Linderman side-cutting drill was used to correct the direction of the osteotomy in the area of teeth #29.

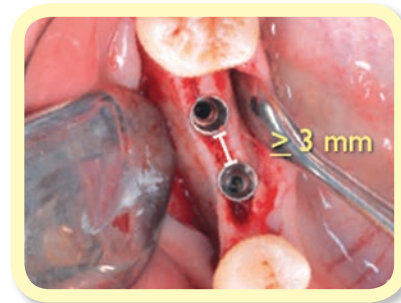
The distance between the buccal and lingual cortical plates (Fig. 27) was increased with a bone spreading kit by progressively inserting tapered rods of increasing diameter (Fig. 28). Two implant fixtures (Ø3.8 X 12mm, Ø3.8 X 14 mm, A+ System, MegaGen® Taiwan) were installed (Fig. 29). The implants achieved adequate primary stability, so healing abutments were placed (Fig. 30). The flap was repositioned and closed with 5-0 nylon sutures (Fig. 31).



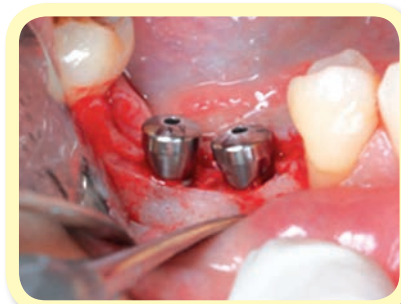■ **Fig. 27:**  
The osseous ridge was expanded with a bone spreading kit.



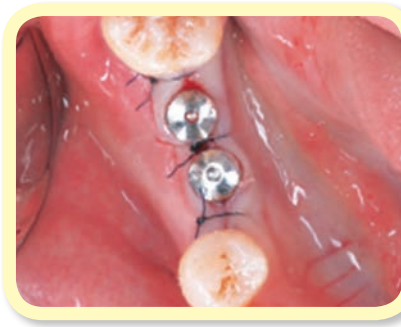■ **Fig. 28:**  
The bone spreading kit is a series of tapered root-form pins (socket formers) that progressively increase the diameter of the osteotomies.



■ **Fig. 29:**  
Two implant fixtures were installed.

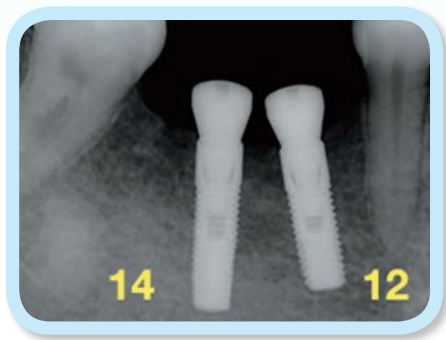


■ **Fig. 30:**  
Healing abutments were placed on the implant fixtures.

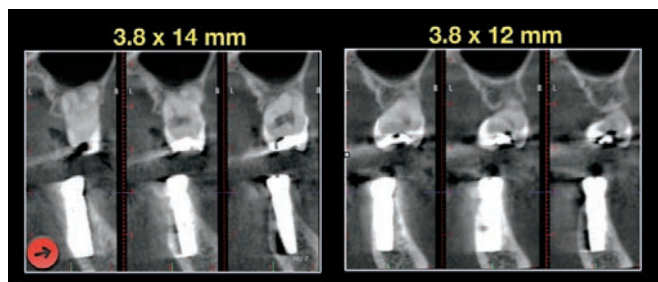


■ **Fig. 31:**  
The soft-tissue flap was sutured around the healing abutments with 5-0 nylon.

Post-operative periapical radiographs were taken to assess the position and angulation of the implants (Fig. 32). Although the two implants were not parallel, their position was adequate because modified abutments could facilitate the prosthesis fabrication.



**Fig. 32:**  
A post-operative radiograph shows that two implants 12mm and 14mm in length were not parallel.




**Fig. 33:**  
Left: A post-operative CBCT scan reveals that the apical third of the 14mm implant is nearly penetrating the lingual plate of bone (red arrow).  
Right: The 12mm implant is well within the lingual plate of bone.

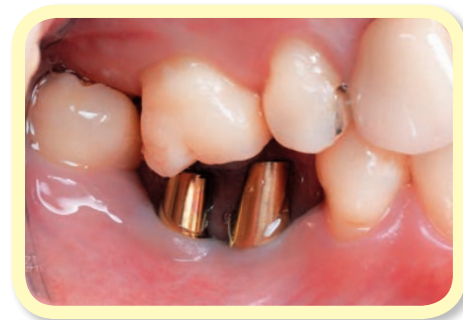A post-operative CBCT scan revealed the apical third of the implants were near the lingual plate. (Fig. 33)

### Implant Prostheses Fabrication

The multi-post abutments ( $\varnothing 5.00$  mm and 2.00 mm cuff height) were fitted and the abutments were modified with a diamond bur for occlusal clearance while maintaining a desirable soft tissue contour



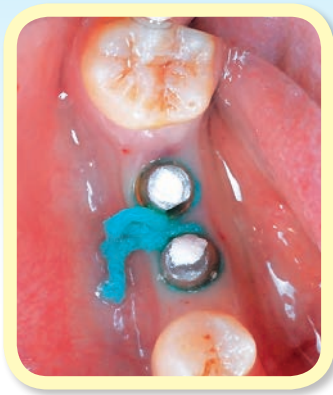**Fig. 34:**  
Abutments are adjusted with a diamond bur to provide adequate occlusal clearance.



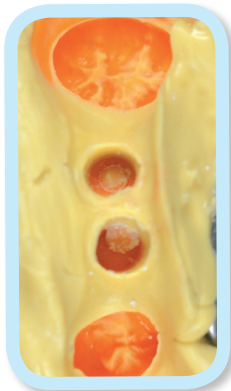**Fig. 35:**  
Trying in the adjusted posts demonstrates that there is 2mm of occlusal clearance, which is adequate for the fabrication of the porcelain fused to metal crown.

(Fig. 34). The abutment's post height was reduced to provide the 2mm of occlusal clearance necessary for fabrication of a porcelain fused to metal crown (Fig. 35).

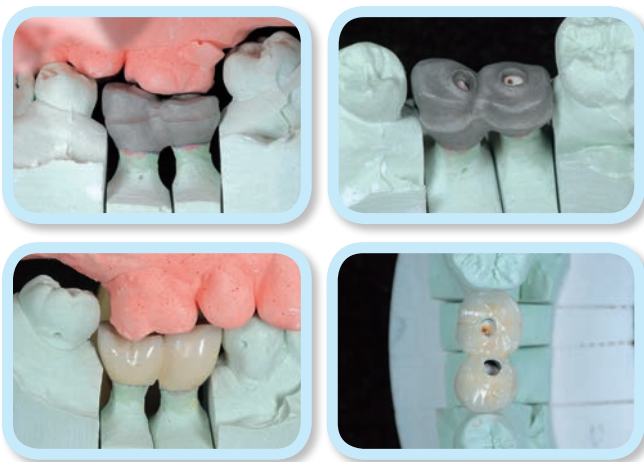Before taking an impression to fabricate the prostheses, the abutment screws were torqued to 30-N-cm with a screw driver and a torque ratchet. Gingival retraction cords were positioned in the peri-implant sulcus with a packing-placement instrument (Fig. 36). A direct impression was obtained with polyvinyl siloxane and it was poured with type IV dental stone (Fig. 37). The casts were subsequently articulated using check-bite records. A metal coping



**Fig. 36:**  
Gingival retraction cord is packed into the peri-implant sulcus.



**Fig. 37 :**  
Following removal of the retraction cord, a direct impression with polyvinyl siloxane captures the margins of the abutments.



**Fig. 38:**  
The upper photographs show the metal coping for the prosthesis, and the lower photographs illustrate the completed final prostheses.

was fabricated by the laboratory, and the marginal integrity was verified clinically with a dental explorer (Fig. 38). After completion of the final prostheses, an appropriate fit of the contact area was confirmed with dental floss. After clinical adjustment and verification of the fit and occlusion, the permanent crowns were luted into place with permanent cement (*Hybond® Shofu Dental Corp., Kyoto, Japan*). The holes on the occlusal surface of the crowns were filled with composite resin.

### Results Achieved

Maxilla (all three planes):

- A - P: *Maintained*
- Vertical: *Maintained*
- Transverse: *Maintained*

Mandible (all three planes):

- A - P: *Maintained*
- Vertical: *Maintained*
- Transverse: *Maintained*

Maxillary Dentition

- A - P: *All space closed, mesial translation of the left molar*
- Vertical: *Upper right first molar intruded*
- Inter-molar / Inter-canine Width: *Maintained*

Mandibular Dentition

- A - P: *Maintained*
- Vertical: *Maintained*
- Inter-molar / Inter-canine Width: *Maintained*

Facial Esthetics: *Maintained*

## Final Evaluation of Treatment

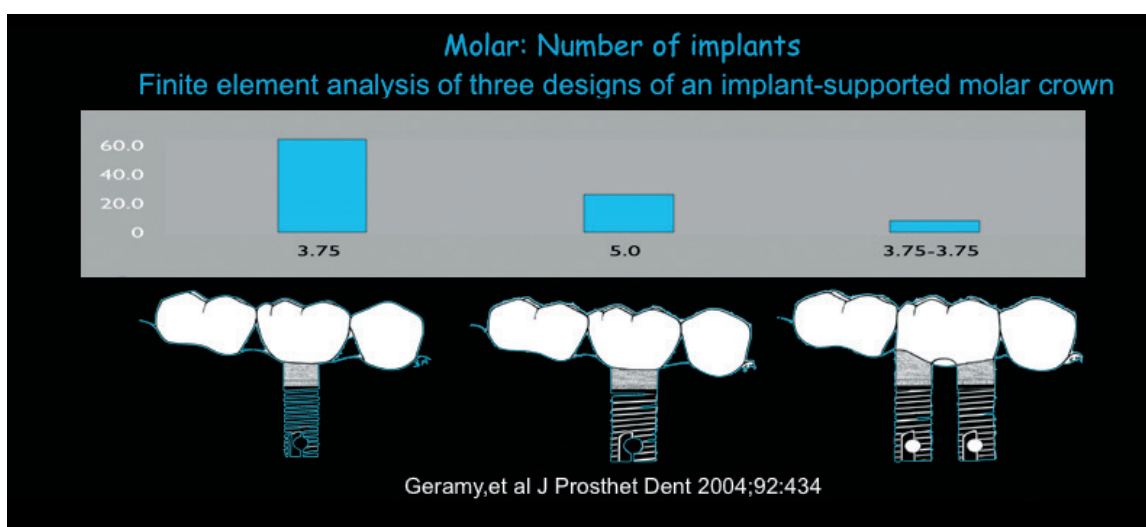
The ABO Cast-Radiograph Evaluation (CRE) score was 26 points.<sup>1,2</sup> The major discrepancy was excessive overjet of multiple teeth (6 points). Occlusal function (contacts) was improved by closing the space between the left maxillary first premolar and first molar. The functional occlusion was stabilized by restoring the missing mandibular right second premolar and first molar with an implant-supported prostheses with a double implant design (Fig. 39). Overall, the patient was quite satisfied with the improvement in her occlusal function.

## Discussion

Reconstruction with orthodontics treatment and implants stabilized the temporomandibular relationship and improved the chewing efficiency of the patient. There are several methods to optimize space for implants, but orthodontics treatment is the most conservative, because it preserves the

integrity of the teeth and minimizes the need for prosthetic restorations. Anchorage with OBSs is very effective mechanics for tooth intrusion.<sup>4,5,6</sup> The most ideal sites for the OBSs are the infrazygomatic crest, maxillary palate (2mm on either side of the midline), and the buccal shelf of the mandible.

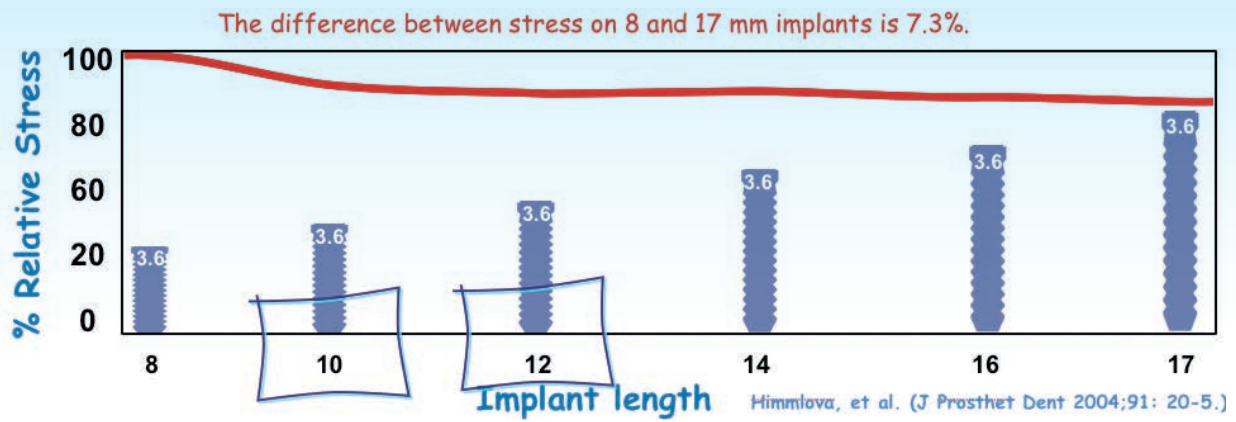
Himmlova et al.<sup>7</sup> reported that the ideal length for implants is in the range between 10-12mm, and the ideal width is between 4.2-5.0mm (Figs. 40 and 41). When the crown of a tooth is loaded eccentric to its axial inclination, damaging moments (stress) can be generated that tend to displace and flex the implant relative to its supporting bone (Figs. 40 and 41). The double-implant design substantially decreases stress in the sagittal plane (Fig. 39).<sup>8</sup> The same principle applies when two implants are used to replace two adjacent teeth. The implants selected to restore the lower right quadrant were Ø3.8X 12mm long and Ø3.8X 14 mm long.



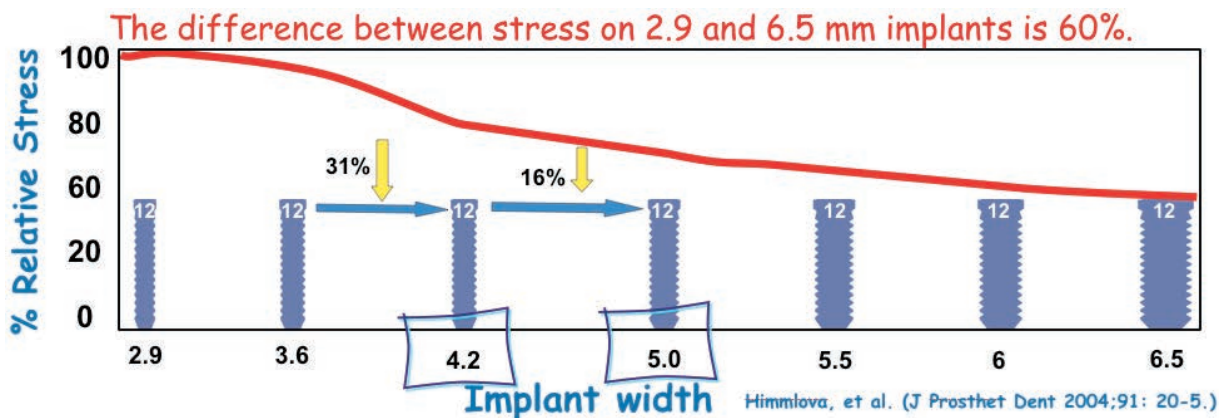
■ Fig. 39:

When the pontic is loaded off-center, the double-implant design (right) produces substantially less moment on the implant head, resulting in damped displacement, compared with either of the single-implant designs (left and center). Figure adapted from Geramy A, Morgano SM. J Prosthet Dent 2004;92:434-40.<sup>5</sup>





■ Fig. 40: The stress on implants is inversely related to length. The optimal implant length is ~10-12mm. Figure adapted from Himmlova L, Dostalova T, Kacovsky A, Konvickova S. J Prosthet Dent 2004;91:20-5.<sup>4</sup>



■ Fig. 41: With respect to moderating stress, the optimal implant width is ~4.2-5.0mm. Figure adapted from Himmlova L, Dostalova T, Kacovsky A, Konvickova S. J Prosthet Dent 2004;91:20-5.<sup>4</sup>

There are four common methods for classification of soft and hard tissue defects.<sup>9,10,11,12</sup> Wang<sup>13</sup> modified Seibert's<sup>12</sup> scheme to create the HVC (*horizontal, vertical, combination*) ridge deficiency classification for assessing vertical and horizontal discrepancies. The latter is a practical method that is widely used for conveying the difficulty in restoring the ridge. The three broad categories are still present: Class I, II, and III defects are classified as horizontal (H), vertical (V), and combination (C) defects. Each category is further subdivided into small (*s*, ≤ 3mm), medium

(*m*, 4 to 6 mm), and large (*l*, ≥ 7mm) subcategories. Both soft and hard tissue defects are considered in this classification scheme. Treatment options are suggested based on the HVC classification. The lower right edentulous ridge was classified as a small horizontal defect, so an appropriate treatment approach is an onlay bone graft. The present patient was treated with an attractive alternative procedure: bone splitting, spreading and immediate implant placement. The latter approach (Figs. 27-31) saves treatment time and is often more predictable,

because there is no need for a bone grafting procedure and healing phase before placing the implants.

## Conclusion

Oligodontia with additional missing teeth resulted in a severe acquired malocclusion. Malocclusions associated with a mutilated dentition may require orthodontics, bone augmentation, implants, and prostheses to achieve an optimal functional outcome. Orthobonescrews (OBSs) are versatile temporary anchorage and prosthetic devices for correcting unstable occlusions. The bone splitting procedure is effective for managing an atrophic edentulous ridge to receive implant-supported prostheses.

## References

1. Chang CH. Advanced Damon Course No. 4,5: DI & CRE Workshop (1)(2). Beethoven Podcast Encyclopedia in Orthodontics [podcast]. Hsinchu: Newton's A Ltd; 2011.
2. Chang CH. Advanced Damon Course No. 9: Excellence in Finishing, Beethoven Podcast Encyclopedia in Orthodontics [podcast]. Hsinchu: Newton's A Ltd; 2011.
3. Chang CH. The 2B-3D rule for implant planning, placement and restoration. *Int J Orthod Implantol* 2012;27:96-101.
4. Lin JJ. Creative orthodontics blending the Damon System & TADs to manage difficult malocclusions. 2<sup>nd</sup> ed. Taipei: Yong-Chieh; 2010. p. 209-226.
5. Chang CH, Roberts WE. Stability of mini-screws on buccal shelves: a retrospective study of 1680 mini-screw insertions by the same orthodontist. *Int J Orthod Implantol* 2013;30:76-78.
6. Chang CH, Roberts WE. A retrospective study of the extra-alveolar screw placement on buccal shelves. *Int J Orthod Implantol* 2013;32:80-89.
7. Himmlova L, Dostalova T, Kacovsky A, Konvickova S. Influence of implant length and diameter on stress distribution: A finite element analysis. *J Prosthet Dent* 2004;91:20-5.
8. Geramy A, Morgano SM. Finite element analysis of three designs of an implant-supported molar crown. *J Prosthet Dent* 2004;92:434-40.
9. Seibert JS. Reconstruction of deformed, partially edentulous ridges, using full thickness onlay grafts. Part I. Technique and wound healing. *Compend Contin Educ Dent* 1983;4:437-453.
10. Allen EP, Gainza CS, Farthing GG, Newbold DA. Improved technique for localized ridge augmentation. A report of 21 cases. *J Periodontol* 1985;56:195-199.
11. Lekholm U, Zarb G. Patient selection and preparation. In: Brånemark P-I(ed). *Tissue-Integrated Prostheses: Osseointegration in Clinical Dentistry*. Chicago: Quintessence, 1985:199-209.
12. Misch CE, Judy KW. Classification of partially edentulous arches for implant dentistry. *Int J Oral Implantol* 1987;4:7-13.
13. Wang HL, Al-Shammari K. HCV ridge deficiency classification: A therapeutically oriented classification. *Int J Periodontics Restorative Dent* 2002;22:335-343.
14. Sethi A, Kaus T. Maxillary ridge expansion with simultaneous implant placement: 5-year results of an ongoing clinical study. *Int J Oral Maxillofac Implants* 2000;15:491-499.
15. Scipioni A, Bruschi GB, Calesini G. The edentulous ridge expansion technique: A 5-year study. *Int J Periodontics Restorative Dent* 1994;14:451-459.



# Discrepancy Index Worksheet

**TOTAL D.I. SCORE** 21

**OVERJET**

- 0 mm. (edge-to-edge) =
- 1 – 3 mm. = 0 pts.
- 3.1 – 5 mm. = 2 pts.
- 5.1 – 7 mm. = 3 pts.
- 7.1 – 9 mm. = 4 pts.
- > 9 mm. = 5 pts.

Negative OJ (x-bite) 1 pt. per mm. per tooth =

Total = 0

**OVERBITE**

- 0 – 3 mm. = 0 pts.
- 3.1 – 5 mm. = 2 pts.
- 5.1 – 7 mm. = 3 pts.
- Impinging (100%) = 5 pts.

Total = 0

**ANTERIOR OPEN BITE**

0 mm. (edge-to-edge), 1 pt. per tooth  
then 1 pt. per additional full mm. per tooth

Total = 0

**LATERAL OPEN BITE**

2 pts. per mm. per tooth

Total = 0

**CROWDING** (only one arch)

- 1 – 3 mm. = 1 pt.
- 3.1 – 5 mm. = 2 pts.
- 5.1 – 7 mm. = 4 pts.
- > 7 mm. = 7 pts.

Total = 0

**OCCLUSION**

- Class I to end on = 0 pts.
- End on Class II or III = 2 pts. per side  pts.
- Full Class II or III = 4 pts. per side  pts.
- Beyond Class II or III = 1 pt. per mm.  pts.  
additional

Total = 0

**LINGUAL POSTERIOR X-BITE**

1 pt. per tooth Total = 0

**BUCCAL POSTERIOR X-BITE**

2 pts. per tooth Total = 0

**CEPHALOMETRICS** (See Instructions)

ANB  $\geq 6^\circ$  or  $\leq -2^\circ$  = 4 pts.

Each degree  $< -2^\circ$   x 1 pt. =

Each degree  $> 6^\circ$   x 1 pt. =

**SN-MP**

$\geq 38^\circ$  = 2 pts.

Each degree  $> 38^\circ$   x 2 pts. =

$\leq 26^\circ$  = 1 pt.

Each degree  $< 26^\circ$   x 1 pt. =

1 to MP  $\geq 99^\circ$  = 1 pt.

Each degree  $> 99^\circ$  7 x 1 pt. = 7

Total = 8

**OTHER** (See Instructions)

- Supernumerary teeth  x 1 pt. =
- Ankylosis of perm. teeth  x 2 pts. =
- Anomalous morphology  x 2 pts. =
- Impaction (except 3<sup>rd</sup> molars)  x 2 pts. =
- Midline discrepancy ( $\geq 3$ mm) @ 2 pts. =
- Missing teeth (except 3<sup>rd</sup> molars) 10 x 1 pts. = 10
- Missing teeth, congenital  x 2 pts. =
- Spacing (4 or more, per arch)  x 2 pts. =
- Spacing (Mx cent. diastema  $\geq 2$ mm) @ 2 pts. =
- Tooth transposition  x 2 pts. =
- Skeletal asymmetry (nonsurgical tx) @ 3 pts. =
- Addl. treatment complexities  x 2 pts. =

Identify:

Total = 10

**IMPLANT SITE**

- Lip line : Low (0 pt), Medium (1 pt), High (2 pts) =
- Gingival biotype : Low-scalloped, thick (0 pt), Medium-scalloped, medium-thick (1 pt), High-scalloped, thin (2 pts) = 1
- Shape of tooth crowns : Rectangular (0 pt), Triangular (2 pts) =
- Bone level at adjacent teeth :  $\leq 5$  mm to contact point (0 pt), 5.5 to 6.5 mm to contact point (1 pt),  $\geq 7$  mm to contact point (2 pts) = 1
- Bone anatomy of alveolar crest : H&V sufficient (0 pt), Deficient H, allow simultaneous augment (1 pt), Deficient H, require prior grafting (2 pts), Deficient V or Both H&V (3 pts) = 1
- Soft tissue anatomy : Intact (0 pt), Defective ( 2 pts) =
- Infection at implant site : None (0 pt), Chronic (1 pt), Acute (2 pts) =

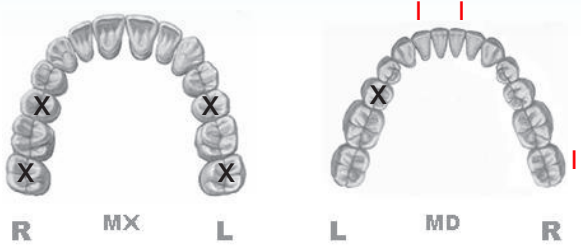
Total = 3

# Cast-Radiograph Evaluation

Total CRE Score 26

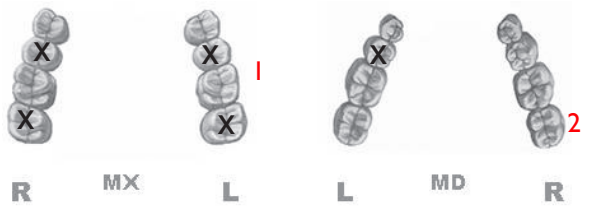
## Alignment/Rotations

3



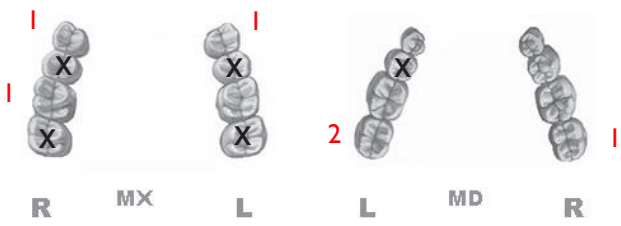
## Marginal Ridges

3



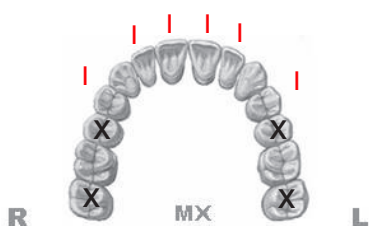
## Buccolingual Inclination

6



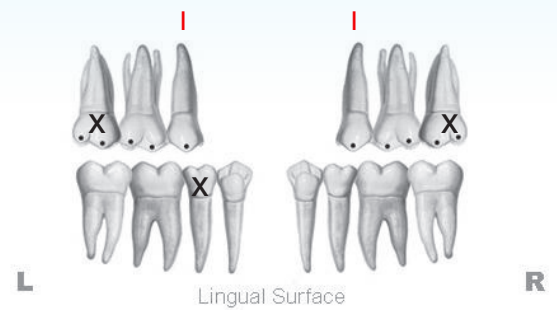
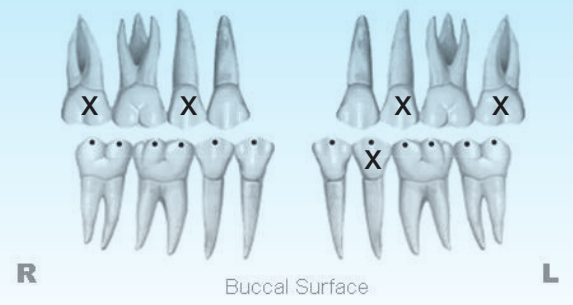
## Overjet

6



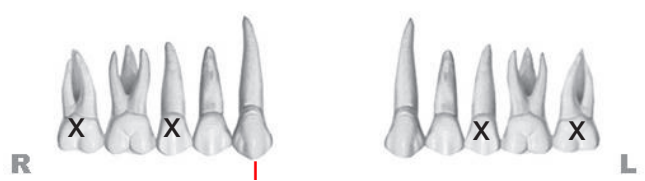## Occlusal Contacts

2



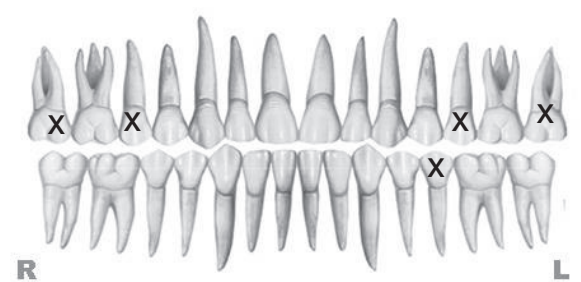
## Occlusal Relationships

1



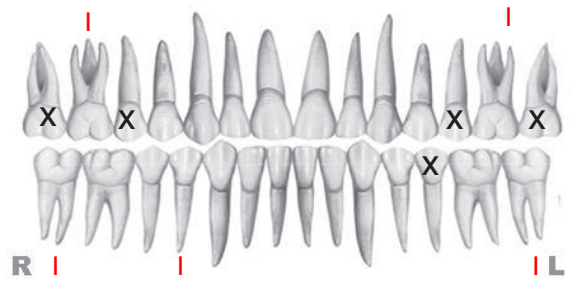
## Interproximal Contacts

0



## Root Angulation

5



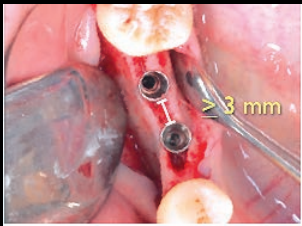
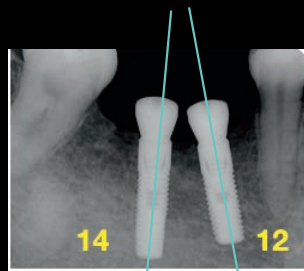
**INSTRUCTIONS:** Place score beside each deficient tooth and enter total score for each parameter in the white box. Mark extracted teeth with "X". Second molars should be in occlusion.

# Implant-Abutment Transition & Position Analysis Total Score: = 5

## 1. Implant Position

### Implant Position

1. M-D	2. B-L	3. Depth	4. Angulation	5. Distance to tooth
Center	2mm	3mm	Max. 15°	≧ 1.5mm

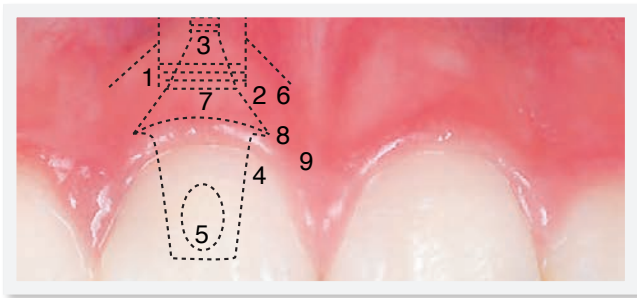
**I 45** Total = 1

- 1. M & D ( Center )  0  1  2
- 2. B & L ( Buccal 2 mm )  0  1  2
- 3. Depth ( 3 mm )  0  1  2
- 4. Angulation ( Max. 15° )  0  1  2
- 5. Distance to Adjacent Anatomy  0  1  2

**I 46** Total = 0

- 1. M & D ( Center )  0  1  2
- 2. B & L ( Buccal 2 mm )  0  1  2
- 3. Depth ( 3 mm )  0  1  2
- 4. Angulation ( Max. 15° )  0  1  2
- 5. Distance to Adjacent Anatomy  0  1  2

## 2. Abutment transition Contour



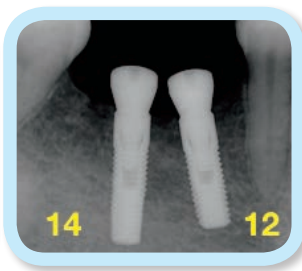
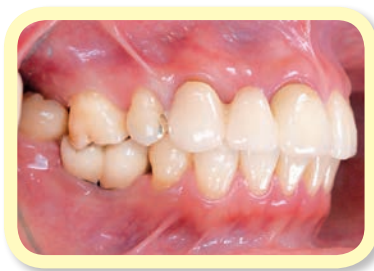E : external connection,  
 I : internal connection,  
 S : screw type,  
 C : cement type,  
 P : palatal/central,  
 B : buccal

**I 45** Total = 2

- 1. Fixture Cervical Design N  Y
- 2. Platform Switch N  Y
- 3. I-A Connection Type E  I
- 4. Abutment Selection S  C
- 5. Screw Hole Position P  B
- 6. Marginal Bone Loss N  Y  0  1  2
- 7. Modified Gingival Contour N  Y  0  1  2
- 8. Gingival Height N  Y  0  1  2
- 9. Crown margin fitness N  Y  0  1  2

**I 46** Total = 2

- 1. Fixture Cervical Design N  Y
- 2. Platform Switch N  Y
- 3. I-A Connection Type E  I
- 4. Abutment Selection S  C
- 5. Screw Hole Position P  B
- 6. Marginal Bone Loss N  Y  0  1  2
- 7. Modified Gingival Contour N  Y  0  1  2
- 8. Gingival Height N  Y  0  1  2
- 9. Crown margin fitness N  Y  0  1  2





西班牙

# 地中海鑲復學院 (MPI) 進修團

主辦單位：金牛頓藝術科技

時間：2015年4月15~22日

地點：Castéllon, Spain



## 行程安排

- 04/15 台灣出發
- 04/16 抵達巴塞隆納
- 04/17~18 自選行程：巴塞隆納觀光 - 狂野藝術重鎮
- 04/19 自選行程：瓦倫西亞觀光  
抵達Castéllon - 西班牙地中海風情
- 04/20~21 MPI 課程：進階假牙講座及模型操作  
伴有遊艇觀光，佛朗明哥舞蹈及豐富特色餐點
- 04/22 離開巴塞隆納
- 04/23 抵達台灣

## 團費及內容

- (1) 課程學費：81000元台幣 (2000歐元) / 2天  
含全彩紙本講義，電子黑白講義，  
全套假牙 (含軟硬組織、下顎頭骨等) 模型組，及MPI紀念品。
  - (2) 巴塞隆納市區觀光：未定，含當地導遊。
  - (3) 瓦倫西亞觀光：4000台幣，含當地導遊。
  - (4) 六天住宿費 / 雙人房：12,000台幣
  - (5) 當地交通：未定
  - (6) 機票 / 經濟艙：45,000台幣，預計搭乘國泰 + 瑞士航空
- 以上費用皆為暫定，共計 **約15萬台幣**。  
預計招收人數：**20人**，南加大植牙課程校友及學員優先。

報名方式：03-5735676 或 [course@newtonsa.com.tw](mailto:course@newtonsa.com.tw) 朱央如



第6期

# 2015 Newton's Implant

## 金牛頓植牙論壇

■ **時間**：2015年03月20日起，上午 9:00~12:00 ■ **地點**：金牛頓教育中心（新竹市建中一路25號2樓）

現在的牙科治療已經是各科統合彙整的時代，**協同矯正、植體、牙周、補綴**讓治療成果臻於完美是我們追求的目標。2015年的課程規劃再突破，精選四年來在台舉辦 **USC 南加大植牙進修課程精華**，由在臨床及演講領域裡經驗豐富的張慧男、蘇筌璋和邱上珍醫師共同主講，並導讀**經典期刊**、深入分析 **iAOI 精緻完工案例**，化繁為簡。植牙入門者可以輕鬆、有效率地學習，專科醫師也可獲得全新的植牙概念及技術，持續精進！



### 關於植牙論壇的定位與期許：

1. 將目前眾多植牙演講精華，重新整理過在自己的場合報告。
2. 提供訓練平台供學員報告自己的case，從中相互學習。
3. 提升助教的演講技巧，培養新講師群。
4. 作為未來IAOI矯正植牙專科醫師考試的考前訓練班。

**費用：25,000 元**

2015/01/31前特惠 22,000元，贈送課程視訊。  
單堂報名 3,000 元（不含視訊）

**報名專線**：03-5735676 黃登鍵先生

**銀行代碼**：815 日盛銀行光復分行

**匯款帳號**：109-25203060-000

**戶名**：金牛頓藝術科技股份有限公司

	日期	USC 學程精選 (主講：張慧男、蘇筌璋、邱上珍醫師)	經典期刊導讀	iAOI 經典案例
1	3/20	Dr. Homa: Biomechanical considerations, ridge preservation	Introduction of implant system, ridge preservation	Case 01
2	4/24	Dr. Homa: Decision tree for reduced bone volume	Short implant vs immediate implant	Case 02
3	5/22	Dr. Homa: Vertical Incision Subperiosteal Tunnel Access(VISTA)	VISTA: cross link etween ortho & implant	Case 03
4	6/26	Dr. Fernando: Prosthetic consideration in implant therapy	2B3D rule - single implant	Case 04
5	7/31	Dr. Fernando: Implant site planning	2B3D rule - multiple implants	Case 05
6	8/21	Dr. Fernando: Material selection, loading protocol	Smile design	Case 06
7	9/18	Dr. Chiu: Case presentation - Full mouth rehabilitation	GBR	Case 07
8	10/23	Dr. Wallace: Sinus lifting	Sinus lifting	Case 08
9	11/20	Dr. Baldwin: Abutment selection	Abutment selection	Case 09
10	12/18	Dr. Baldwin: Implant occlusion	Implant occlusion	Case 10

## Full Cusp Class II Malocclusion with a Deep Overbite

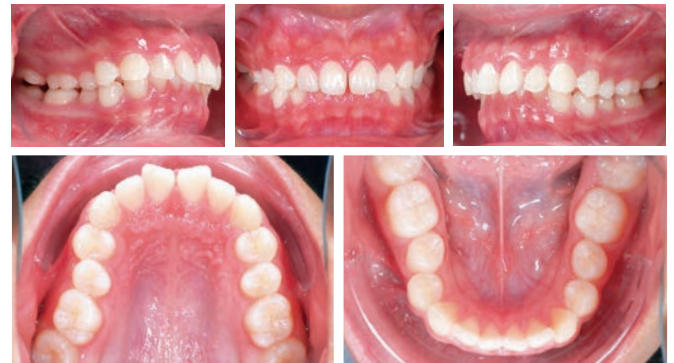### SUMMARY

A skeletal and dental Class II malocclusion in a adolescent male with incompetent lips was managed with non-extraction orthodontics treatment. The impinging deep overbite was resolved with an anterior bite turbo. The skeletal and dental Class II relationships were corrected with Class II elastics and miniscrews that were inserted as anchorage in the infrazygomatic crests bilaterally. A tooth positioner was used to finish the occlusion. Overall, this moderately difficult malocclusion (DI=20) was finished in an excellent result (CRE=24) in ~21 months, but there were some side effects associated with rapidly opening the bite. (Int J of Othod Implantol 2014;36:72-86)

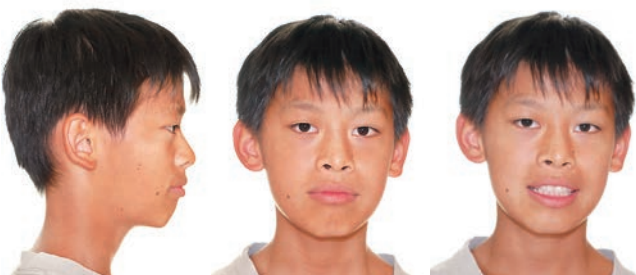**Key word:** Class II, deep overbite, miniscrews, tooth positioner.

### History and Etiology

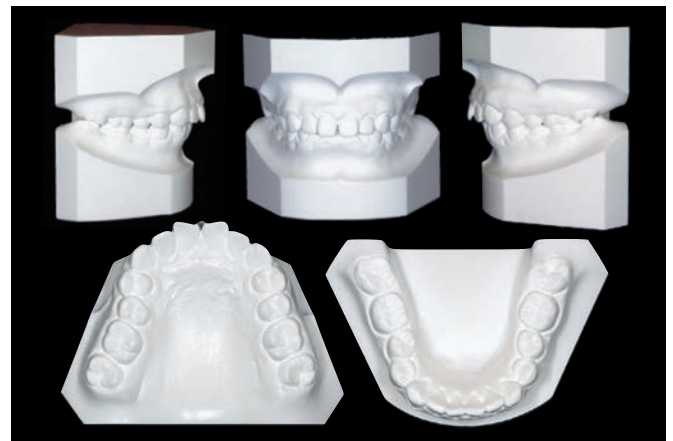A 13-year-11-month-old boy was referred by his dentist for orthodontic consultation (Fig. 1). The chief concern was an impinging deep overbite (Figs. 2 and 3). A diastema was noted between the upper central incisors (Fig. 2). No known habits contributing to the malocclusion were reported. However, hypermentalalis activity associated with lip closure (Fig. 1) suggests the malocclusion is primarily environmental, secondary to a moderate lip trap



■ Fig. 2: Pre-treatment intraoral photographs show an impinging deep overbite that obscures the view of the lower anterior teeth.



■ Fig. 1: Pre-treatment facial photographs show strained lips on closure: flat chin contour in the profile view, dimpled chin pattern due to hypermentalalis activity in the frontal view. Note that the chin dimpling disappears when the lips are opened for the smiling view.



■ Fig. 3: Pre-treatment study models (casts)

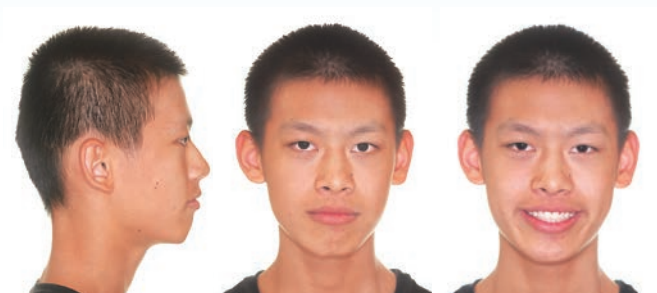

**Dr. Sheau-Ling Lin,**  
Instructor, Beethoven Orthodontic Course (left)

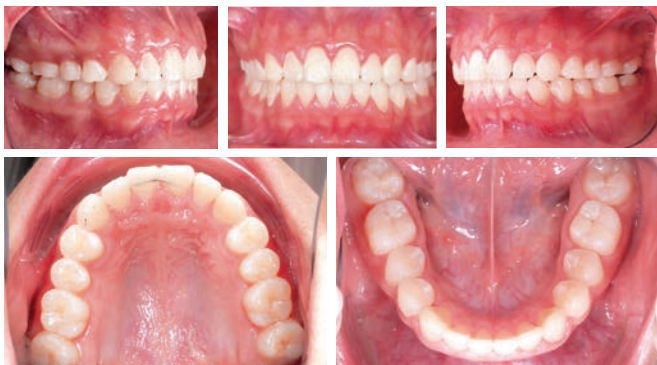**Chris Chang, DDS, PhD.**

Founder, Beethoven Orthodontic Center  
Publisher, International Journal of Orthodontics & Implantology (Middle)

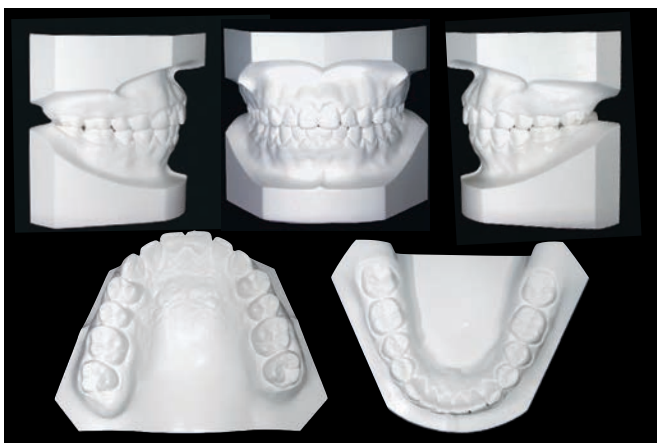**W. Eugene Roberts, Consultant,**  
International Journal of Orthodontics & Implantology (Right)



**Fig. 4:**  
Post-treatment facial photographs show lip strain on closure.



**Fig. 5:**  
Post-treatment intraoral photographs document that the deep overbite was successfully resolved.



**Fig. 6:** Post-treatment study models (casts)

when the lips are in repose. The patient was treated to an acceptable result as documented in Fig. 4-9.

## Diagnosis

### Skeletal:

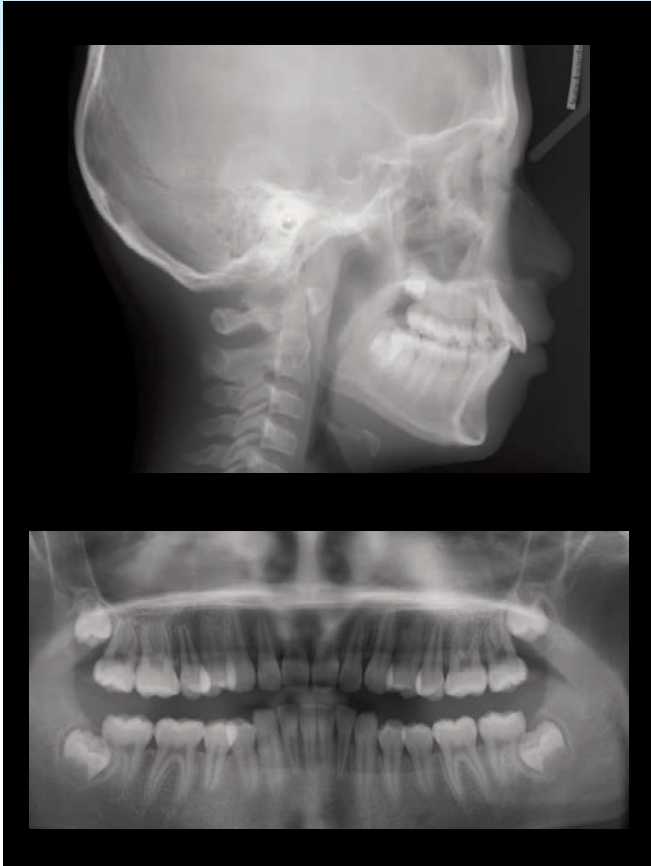
- Skeletal Class II (SNA 85°, SNB 79°, ANB 6°)
- Normal mandibular plane angle (SN-MP 29°, FMA 21°)

### Dental:

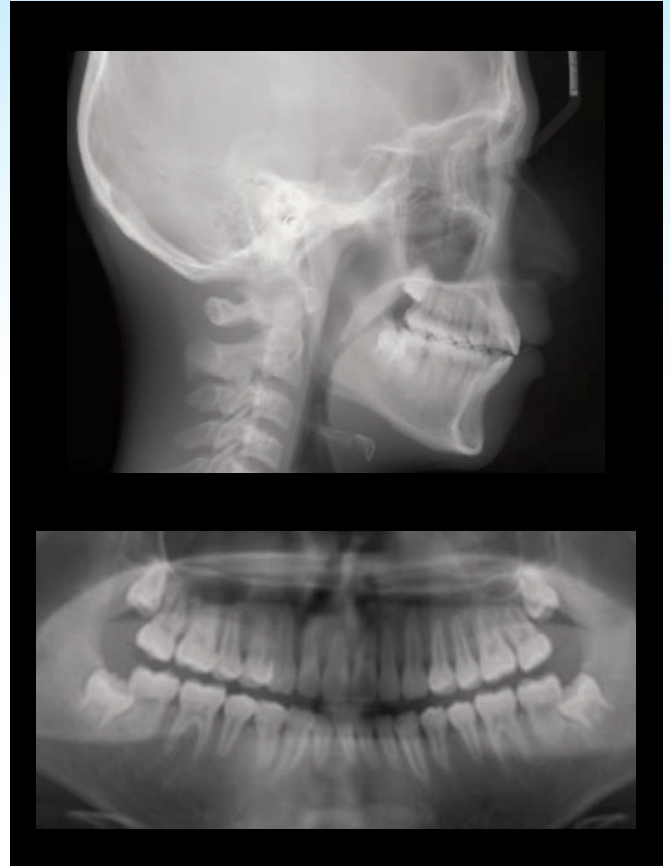
- Bilateral Class II molar relationship, full cusp discrepancy on the left side (Fig. 3)
- 100% impinging deep overbite with lingual recession of the gingiva on the Mx central incisors (Figs. 2 & 3)
- Overjet (OJ) 5 mm (Fig. 10)
- Mild crowding of about 2 mm in upper arch, and 1 mm in the lower arch
- Diastema <1.0 mm between maxillary central incisors (Fig. 11)
- Maxillary dental midline 1 mm to the right of the facial midline
- Deep Curve of Spee (Fig. 12)

### Facial:

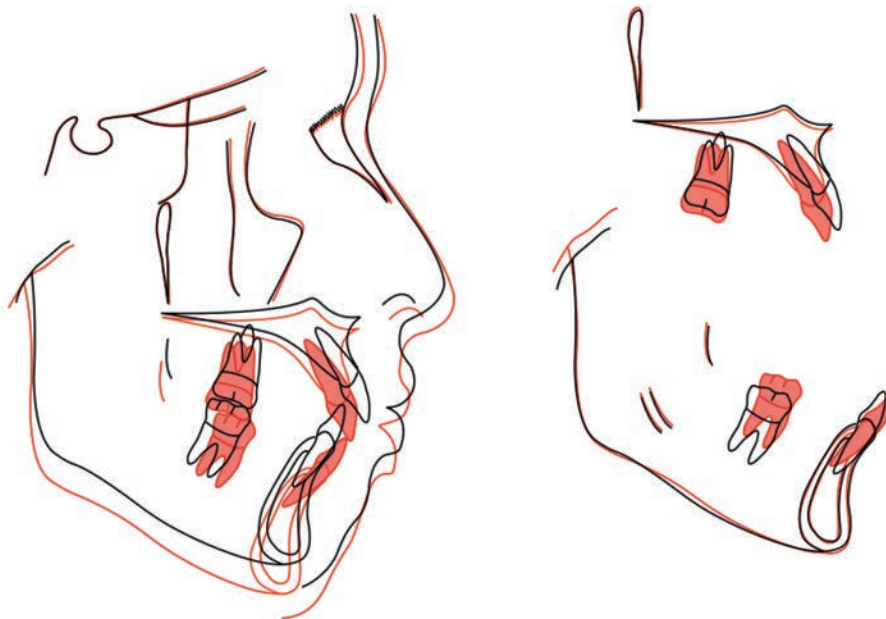
- Mild convex profile with protrusive lips Lip strain on closing, as evidenced by a dimple pattern on the chin due to hypermentalis activity



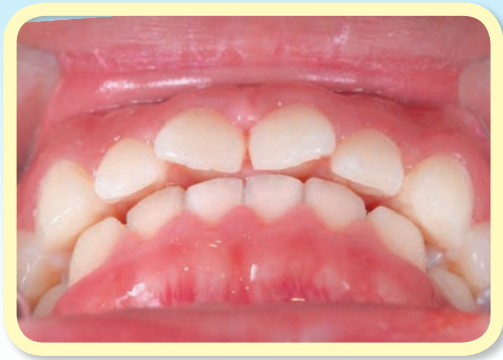■ **Fig. 7:**  
Pre-treatment cephalometric and panoramic radiographs reveal a deep overbite and increased curve of Spee.



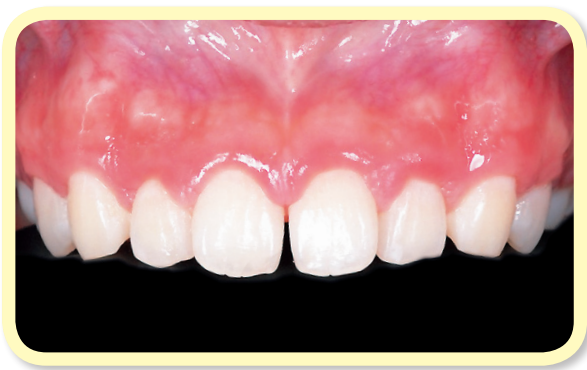■ **Fig. 8:**  
Post-treatment cephalometric and panoramic radiographs document the correction of the deep overbite the excessive curve of Spee



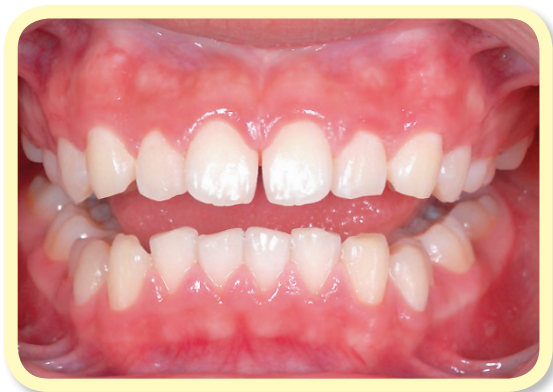■ **Fig. 9:**  
Superimposed tracings document retraction of maxillary anterior teeth and posterior rotation of the mandible. The mandibular molars were extruded and the lower incisors were slightly flared.



**Fig. 10:** Pre-treatment a 100% deep impinging overbite is associated with distal out rotation of the maxillary central incisors.



**Fig. 11:** Pre-treatment and intra-oral frontal photographs reveals a maxillary midline diastema.



**Fig. 12:** An open-mouth frontal view of the dentition shows the deep curve of Spee.

The ABO Discrepancy Index (DI) was 20 as shown in the subsequent worksheet.

### Specific Objectives of Treatment

Maxilla (all three planes):

- A - P: Retract
- Vertical: Allow for normal expression of growth
- Transverse: Maintain

Mandible (all three planes):

- A - P: Allow for normal expression of growth
- Vertical: Allow for normal expression of growth
- Transverse: Maintain

Maxillary Dentition

- A - P: Retract the entire maxillary arch
- Vertical: Maintain the molars and intrude the incisors

CEPHALOMETRIC			
SKELETAL ANALYSIS			
	PRE-Tx	POST-Tx	DIFF.
SNA°	85°	83°	2°
SNB°	79°	78°	1°
ANB°	6°	5°	1°
SN-MP°	29°	30°	1°
FMA°	21°	22°	1°
DENTAL ANALYSIS			
U1 TO NA mm	6 mm	3 mm	3 mm
U1 TO SN°	110°	108°	2°
L1 TO NB mm	7 mm	9 mm	2 mm
L1 TO MP°	98°	102°	4°
FACIAL ANALYSIS			
E-LINE UL	2 mm	-0.5 mm	2.5 mm
E-LINE LL	5 mm	3 mm	2 mm

■ Table 1: Cephalometric summary

- Inter-molar Width: *Increase*
- Inter-canine Width: *Maintain*
- Buccolingual Inclination: *Maintain*

#### Mandibular Dentition

- A - P: *Maintain the molars and intrude the incisors*
- Vertical: *Maintain the molars and intrude the incisors*
- Inter-molar Width: *Increase*
- Inter-canine Width: *Maintain*
- Buccolingual Inclination: *Maintain*

#### Facial Esthetics: Correct incompetent

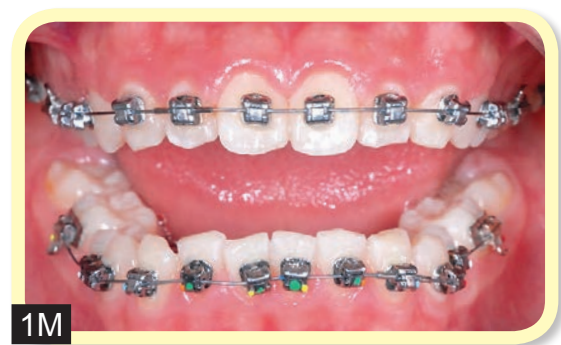**Other:** Correct Curve of Spee by intruding the lower incisors

### Treatment Plan

A non-extraction treatment plan included correcting the deep overbite, leveling the Curve of Spee, coordinating the arches, and normalizing the soft tissue profile. Both arches will be bonded with a full fixed orthodontic appliance, with bite turbos placed on the lingual surface of both central incisors to correct the deep bite and curve of Spee. Class II molar relationship was to be corrected with early-light-short elastics (2 oz). Miniscrews were planned bilaterally in the infrazygomatic crests for retracting the maxillary arch to correct the Class II relationship. Up & down elastics (2 oz) were prescribed to detail the occlusion before removing the fixed appliances, and then the final occlusion was to be achieved with a positioner. An upper clear retainer and both upper and lower fixed retainers were planned to retain the

corrected dentition. Removal of the four 3<sup>rd</sup> molars at the age of 18 is recommended.

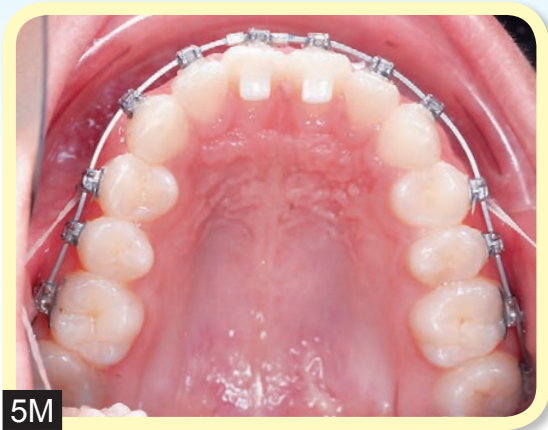A 0.022" slot Damon Q bracket system (*Ormco*) was used. The maxillary arch was bonded with high torque brackets on the anteriors, and low torque brackets for the mandibular arch (*Fig. 13*). The archwire sequences for both arches was .014 CuNiTi, .016 CuNiTi, .014 x .025 CuNiTi, and .017 x .025 TMA. Class II elastics (*early-short-light*) were used to correct the A-P discrepancy during the .014 CuNiTi archwire stage.



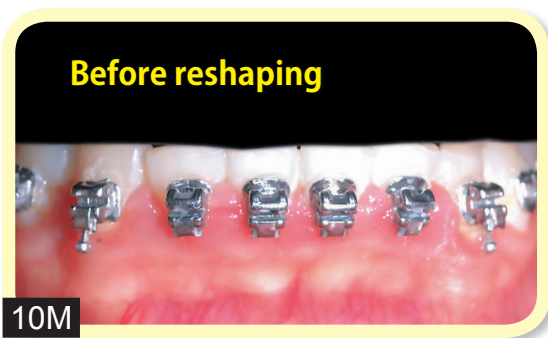■ **Fig. 13:**

*High torque brackets were bonded on the maxillary incisors, and low torque brackets were used for the mandibular incisors.*

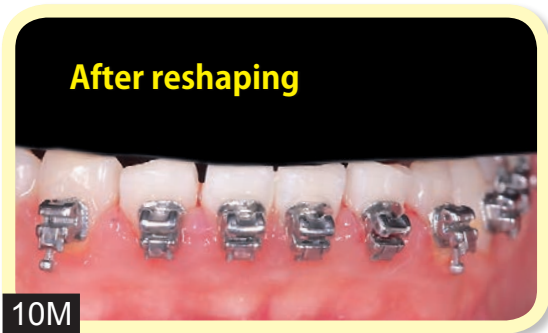In the 5<sup>th</sup> month of treatment, the composite resin bite turbos were placed on the palatal surface of the upper central incisors to open the bite and allow the molars to erupt in order to correct the impinging deep bite situation<sup>1</sup> (*Fig. 14*). In the 11<sup>th</sup> month of active treatment, reshaping the contour of all the mandibular central and the lateral incisors was carried out so the irregular surface of the teeth that would not disturb the alignment (*Figs. 15-*



■ **Fig. 14:**  
Composite resin bite turbos were bonded on the lingual surface of the maxillary central incisors.

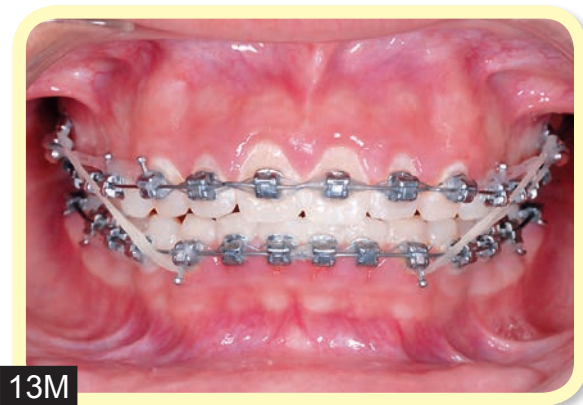

■ **Fig. 15:**  
At 10 months of treatment, the lower incisors required reshaping.

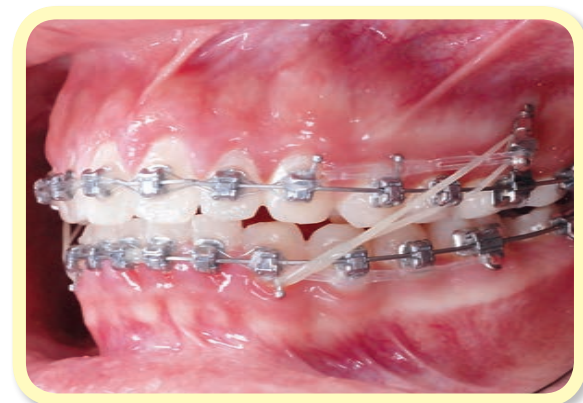


■ **Fig. 16:**  
The lower incisors were reshaped, and the spaces were subsequently closed with elastomeric chains.

16). One month later, two miniscrews (2x12 mm, OrthoBoneScrew®, Newton's A, Inc.) were inserted bilaterally in the infrazygomatic crests<sup>1,2</sup> to serve as anchorage to retract the entire maxillary dentition (Fig. 17 A & B). When both arches were in the .017 x .025 TMA archwire stage, elastometric chains were attached from the upper canines to the miniscrews, and class III elastics were used from the lower canines to the miniscrews.



■ **Fig. 17-A:**  
Miniscrews, inserted bilaterally in the infrazygomatic crests, were subsequently used to anchor Class III elastics, extending to drop-in hooks on the lower cuspids.

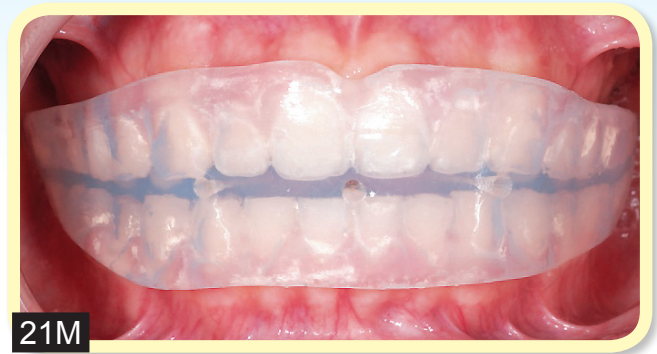

■ **Fig. 17-B:**  
A lateral view shows the Class III elastics between the lower canines and the upper posterior miniscrews.

Bracket repositioning was performed as indicated by sequential panoramic films during several appointments, and wire bending was performed for detailing the occlusion during the final stages of the treatment. In the 19<sup>th</sup> month of treatment, up and down elastics were applied on the 2<sup>nd</sup> molars to settle the tip-back side effect, which had been caused by retraction of the maxillary arch using miniscrews for anchorage.

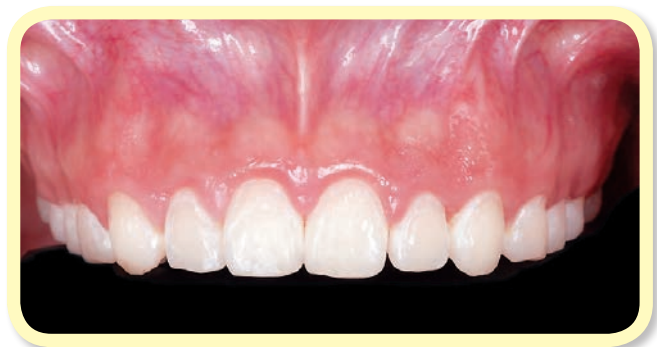A tooth positioner was prescribed to establish an optimal functional occlusion. At the appointment prior to removing the fixed appliances, impressions and a wax bite registration were taken and sent to a commercial orthodontic laboratory to fabricate the tooth positioner. The patient was informed that the braces would be removed at the next appointment and a positioner would be used to finish the occlusion.

After 21 months of active treatment, all the appliances were removed and a mouthguard-type tooth positioner was delivered (Fig. 18). The patient was instructed to wear it four hours a day for the first two weeks, during which the patient was asked to repeatedly clench into the positioner and then release. The patient was instructed to perform this “exercise” for 15 minutes every hour while wearing the appliance. After two weeks of the tooth positioner application, the treatment was finished and the retainers were delivered (Fig. 19). Post-treatment cephalometric and panoramic radiographs (Fig. 8), as well as superimpositions of cephalometric tracings (Fig. 9) document the final result.



■ Fig. 18:

At 21 months, a mouthguard-type tooth positioner was delivered to finish the occlusion.



■ Fig. 19:

Post-treatment photograph of the frontal view of the maxilla shows the final alignment.

## Results Achieved

### Maxilla (all three planes):

- A - P: Retracted
- Vertical: Increased
- Transverse: Expanded

### Mandible (all three planes):

- A - P: Retracted
- Vertical: Increased
- Transverse: Expanded

### Maxillary Dentition

- A - P: *Retracted maxillary arch*
- Vertical: *Maintained*
- Inter-molar Width: *Increased*
- Inter-canine Width: *Maintained*

### Mandibular Dentition

- A - P: *Maintained*
- Vertical: *Increased*
- Inter-molar Width: *Increased*
- Inter-canine Width: *Decreased*

### Facial Esthetics:

- Lower lip profile was improved but the lips were still incompetent. Chin dimples were still noted in the frontal photograph of the face (Fig. 4) because of mentalis muscle contraction when the lips are closed.

### Superimpositions:

- As the maxilla extruded, it was retracted, but the mandible was rotated posteriorly.

Upper incisors were retracted bodily and slightly extruded, but the lower incisors were flared. Extrusion of the lower molars was attributed to the extensive use of Class II elastics.

### Retention

After two weeks of tooth positioner application, a fixed retainer was bonded on the lingual surface of the two maxillary central incisors to prevent the

teeth from returning to pre-treatment positions (*rotation & spacing*). The upper and lower clear overlay retainers were delivered. The patient was instructed to wear them full time for the first 6 months and nights only thereafter. In addition, the patient was instructed in the proper home hygiene care and maintenance of the retainers.

### Final Evaluation of Treatment

Critical assessment of this case with the ABO Cast-Radiograph Evaluation and IBOI Pink & White score resulted in scores of 24 and 2 respectively, as documented on the forms appearing later in this report. The major discrepancies were in the occlusal relationships (8 *points*), marginal ridges (5 *points*), alignment/rotations (3 *points*), and occlusal contacts (2 *points*). The patient's chief concern (*deep impinging overbite*) was successfully treatment, and his lip profile has been improved but the lip incompetence remained. The patient was satisfied with the treatment outcome (Fig. 20).



■ **Fig. 20:**  
Post-treatment photograph shows the patient with Dr. Chris Chang.

## Discussion

Angle Class II Division 1 malocclusions represents a large proportion of the average orthodontist's caseload.<sup>3</sup> There are multiple approaches for managing Class II Division 1 malocclusion. The diagnosis and treatment plan should carefully consider facial profile, skeletal pattern, growth potential, and severity of the malocclusion. The treatment protocol as well as the malocclusion severity can influence the efficiency of orthodontic treatment.<sup>4</sup> Therapeutic options include removable functional appliances, fixed functional appliances, headgear, intermaxillary elastics and/or tooth extractions. Removable functional appliances are usually best suited to patients in the late mixed dentition, while fixed functional appliances are best in the early permanent dentition.<sup>5</sup> However, the effectiveness of functional appliances on enhancing mandibular growth in the short term remains controversial.<sup>6</sup> Since the current patient had a major Class II discrepancy and his growth potential was questionable, a dentoalveolar correction was indicated to achieve the most efficient treatment for a full cusp Class II malocclusion as rapidly as possible. Extractions were not a good option due to mild crowding and convex profile. Excessive retraction of the anterior teeth may increase the nasolabial angle and decrease incisal inclination, which could increase the severity of the deep bite. Therefore, a non-extraction treatment protocol was chosen, utilizing a full fixed appliance, Class II elastics and maxillary posterior miniscrews.

Anchorage is considered the most critical factor when correcting a Class II Division 1 malocclusion. To reinforce anchorage, various auxiliaries can be used, including headgear, lingual arch, transpalatal arch, Nance holding arch and intermaxillary elastics. However, anchorage control that requires patient compliance may be problematic. Dental implants, miniscrews, and miniplates are increasingly popular for skeletal anchorage that does not depend on compliance. These devices can provide stationary anchorage for various types of tooth movement<sup>7</sup> without active patient cooperation. According to the retrospective study by Yao et al.,<sup>8</sup> skeletal anchorage has achieved better control than other options in both the anteroposterior and vertical directions during treatment of maxillary dentoalveolar protrusion. Correction of Class II malocclusion is facilitated by greater retraction of the maxillary incisors, less posterior anchorage loss, and counterclockwise mandibular rotation, especially for patients with a hyperdivergent face.<sup>8</sup> Among the devices available, miniscrews as temporary anchorage devices (TADs) are commonly used because of the following advantages:<sup>4</sup>

1. Easy placement and removal
2. A variety of maxillary and mandibular locations are available for placement
3. Minimal operation and postoperative discomfort<sup>9</sup>



4. No need for complicated clinical and laboratory procedures to facilitate precise implant placement
5. Can be immediately loaded Correction of deep overbite can be accomplished in different ways depending on the treatment goals chosen for individual patients.<sup>10,11</sup> There are four general treatment options to consider:<sup>12</sup>

1. Extrude the posterior segment

2. Intrude the maxillary incisors

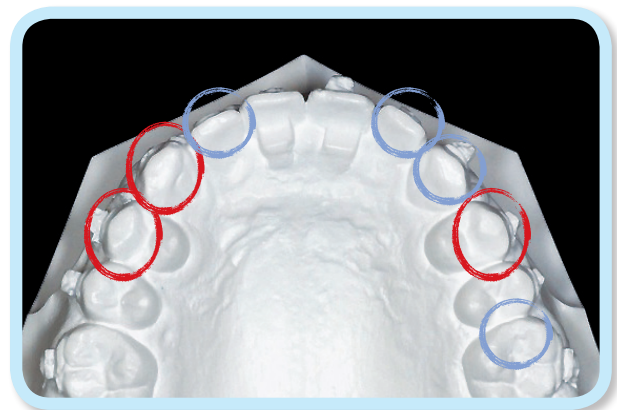
3. Intrude the mandibular incisors

4. Flare the maxillary and/or mandibular incisors

For the present patient, anterior bite turbos were placed to allow posterior teeth to extrude. This method is advantageous for correcting the deep bite, creating interocclusal space and eliminating the intercusp locking. All of these effects facilitate the correction of the Class II relationship.<sup>13,14</sup> Bite turbos and Class II elastics are a good combination to solve Class II deep bite problem, but there are risks if the patient does not have good growth potential for forward rotation of the mandible. These mechanics rotate the mandible posteriorly (*clockwise*), extrude the mandibular molars, and increase the axial inclination of the lower incisors. Taking the side effects on the anterior teeth into consideration, high torque brackets were chosen for the upper incisors

and low torque brackets for the lower incisors. Despite this precaution, lower incisor angulation to the mandibular plane increased from 98° to 102°. In retrospect, it may have been better to treat this case with miniscrews and a lower base arch to intrude the mandibular incisors.<sup>10</sup> However, miniscrews can also produce unwanted side effects, such as tip-back of the molars and a posterior open bite. However these side effects can be at least partially controlled by using a lighter force and extending the treatment time.

The patient was found to have an unconscious bruxism habit that was evidenced by generalized wear facets on multiple teeth (*Fig. 21*). The etiology appeared to be a predisposition to nocturnal bruxism that was manifest after the deep impinging overbite was relieved. Attrition can occur with



■ **Fig. 21:**

Following the opening of the occlusion with bite turbos, generalized wear facets were noted on multiple teeth in the maxillary arch (circles). The facets were distinguished as less (blue circles) or more (red circles) severe.

normal masticatory function but it is usually a manifestation of parafunctional habits such as nocturnal bruxism.<sup>15</sup> Parafunction is thought to have a multifactorial etiology: occlusal, psychological or originating within the central nervous system.<sup>16</sup> However, Caroline et al.<sup>15</sup> found no relationship between bruxism and orthodontics; neither the need for nor the provision of orthodontic treatment contributes to increased tooth wear. Parafunction can lead to mobility of the dentition, severe occlusal wear, displacement of the aligned arches and sometimes pain. Recommended treatment includes the medication Klonopin® (*clonazepam*) 1mg one hour prior bedtime, reduction of acidity in the diet which softens tooth structure, fabrication of an occlusal nightguard to protect the teeth, and restoration of the damaged tooth structure as necessary.<sup>15</sup>

The purpose of the tooth positioner for the present patient was to establish an optimal functional occlusion. Using a tooth positioner, rather than final finishing with archwires, is purported to have 3 advantages :

1. It allows the fixed appliances to be removed sooner.
2. It improves articulation of the teeth and massages the gingiva, which is usually swollen after comprehensive orthodontic treatment.
3. It helps develop lip competence and facial muscle tone.

According to Yongjong et al.,<sup>18</sup> wearing a tooth positioner improves alignment and rotation, overjet, occlusal relationship, inter-proximal contact, and root angulation. For the present patient, improved occlusal relationships, closure of inter-proximal contacts, proper overbite and optimal overjet were all achieved. However, good patient compliance is needed and that is the most important consideration in determining the efficacy of the method.<sup>18</sup>

In addition to a successful outcome, a treatment protocol must also provide good long-term stability of the dental relationships. Long-term changes in tooth alignment can occur, so Niall et al.<sup>19</sup> suggest that it is not appropriate to evaluate final treatment results at the end of active treatment. Long-term follow-up evaluation is an important consideration for all patient treatment outcomes.

## Conclusion

Class II Division 1 with a deep bite is a common malocclusion. The choice of treatment should consider the patient's facial profile, skeletal pattern, growth potential, and severity of the malocclusion. Bite turbos and Class II elastics are a good combination for rapidly resolving a severe Class II deep bite malocclusion. This method may be advantageous for patients who have competent lips, but limited growth potential; however, opening the bite may also lead to unintended consequences such as flaring of the lower incisors, lingual tipping of the upper incisors, and incompetent lips. Overall,

extra-alveolar skeletal anchorage, miniscrews buccal to the maxillary molars, may achieve better control of Class II correction in three dimensions, particularly for patients with incompetent lips.

## Acknowledgment

Thanks to Teacher Paul Head, Dr. Hsin Yin Yeh and Ben Lin for proofreading this article.

## References

1. Cozza P, Baccetti T, Franchi L, De Toffol, McNamara JA Jr. mandibular changes produced by functional appliances in Class II malocclusion: a systematic review. *Am J Orthod Dentofacial Orthop* 2006;129:599.e1-12.
2. Marsico E, Gatto E, Burrascano M, Matarese G, Cordasco G. Effectiveness of orthodontic treatment with functional appliances on mandibular growth in the short term. *Am J Orthod Dentofacial Orthop*. 2011;139:24-36.
3. Chang CH. Basic Damon Course No. 3: Danom + OrthoBoneScrew I, Beethoven Podcast Encyclopedia in Orthodontics 2011, Newton's A Ltd, Taiwan.
4. Lin JJ. A new method of placing orthodontic bone screws in IZC. *New & Trends in Orthodontics* 2009;vol 13:4-7.
5. Zhang N, Bai Y, and Li S. Treatment of a Class II Division 1 malocclusion with miniscrew anchorage. *Am J Orthod Dentofacial Orthop* 2012;141:e85-e93.
6. Moschos AP. Orthodontic treatment of Class II malocclusion with miniscrew implants. *Am J Orthod Dentofacial Orthop* 2008;134:604.e1-604.e16.
7. Shingo K et al. Class II malocclusion treated with miniscrew anchorage: Comparison with traditional orthodontic mechanics outcomes. *Am J Orthod Dentofacial Orthop* 2009;135:302-309.
8. Yao CC, Jane et al. Comparison of treatment outcomes between skeletal anchorage and extraoral anchorage in adults with maxillary dentoalveolar protrusion. *Am J Orthod Dentofacial Orthop* 2008;134:615-624.
9. Shingo K et al. Clinical use of miniscrew implants as orthodontic anchorage: Success rates and postoperative discomfort. *Am J Orthod Dentofacial Orthop* 2007;131:9-15.
10. Charles JB. Biomechanics of deep overbite correction. *Semin Orthod* 2001;7:26-33.
11. Hsu YL et al. ABO case report: A Class II deep bite case. *New & Trends in Orthodontics* 2009;vol 15:56-63.
12. David MS. Soft-tissue-based diagnosis and treatment planning. *Clinical Impression* 2005;14:1:21-26.
13. Samir EB. Class II malocclusion: Diagnostic and clinical considerations with and without treatment. *Semin Orthod* 2006; 12:11-24.
14. Jeff K. Honing Damon system mechanics for the ultimate in efficiency and excellence. *Clinical Impression* 2008;16:1:23-28.
15. Harpenau LA et al. Diagnosis and management of dental wear. *J Calif Dent Assoc*. 2001Apr;39(4):225-231
16. Nissani M. A bibliographical survey of bruxism with special emphasis on non-traditional treatment modalities. *J Oral Sci* 2011 Jun;43(2):73-83.
17. Caroline WM et al. Relationship between malocclusion, orthodontic treatment, and tooth wear. *Am J Orthod Dentofacial Orthop* 2009;136:529-535.
18. Yongjong P et al. Tooth positioner effects on occlusal contacts and treatment outcomes. *Angle Orthod* 2008;78:1050-1056.
19. Niall JP McG et al. Long-term occlusal and soft-tissue profile outcomes after treatment of Class II Division 1 malocclusion with fixed appliances. *Am J Orthod Dentofacial Orthop* 2011;139:362-368.



# Discrepancy Index Worksheet

**TOTAL D.I. SCORE** = 20

**OVERJET**

0 mm. (edge-to-edge) =  
 1 – 3 mm. = 0 pts.  
 3.1 – 5 mm. = 2 pts.  
 5.1 – 7 mm. = 3 pts.  
 7.1 – 9 mm. = 4 pts.  
 > 9 mm. = 5 pts.

Negative OJ (x-bite) 1 pt. per mm. per tooth =

Total = 2

**OVERBITE**

0 – 3 mm. = 0 pts.  
 3.1 – 5 mm. = 2 pts.  
 5.1 – 7 mm. = 3 pts.  
 Impinging (100%) = 5 pts.

Total = 5

**ANTERIOR OPEN BITE**

0 mm. (edge-to-edge), 1 pt. per tooth  
 then 1 pt. per additional full mm. per tooth

Total = 0

**LATERAL OPEN BITE**

2 pts. per mm. per tooth

Total = 0

**CROWDING** (only one arch)

1 – 3 mm. = 1 pt.  
 3.1 – 5 mm. = 2 pts.  
 5.1 – 7 mm. = 4 pts.  
 > 7 mm. = 7 pts.

Total = 1

**OCCCLUSION**

Class I to end on = 0 pts.  
 End on Class II or III = 2 pts. per side 2 pts.  
 Full Class II or III = 4 pts. per side 4 pts.  
 Beyond Class II or III = 1 pt. per mm. 4 pts. additional

Total = 6

**LINGUAL POSTERIOR X-BITE**

1 pt. per tooth Total = 0

**BUCCAL POSTERIOR X-BITE**

2 pts. per tooth Total = 0

**CEPHALOMETRICS** (See Instructions)

ANB (≥ 6°) or ≤ -2° = 4 pts.  
 Each degree < -2° \_\_\_\_\_ x 1 pt. = \_\_\_\_\_  
 Each degree > 6° \_\_\_\_\_ x 1 pt. = \_\_\_\_\_

SN-MP  
 ≥ 38° = 2 pts.  
 Each degree > 38° \_\_\_\_\_ x 2 pts. = \_\_\_\_\_  
 ≤ 26° = 1 pt.  
 Each degree < 26° \_\_\_\_\_ x 1 pt. = \_\_\_\_\_

1 to MP ≥ 99° = 1 pt.  
 Each degree > 99° \_\_\_\_\_ x 1 pt. = \_\_\_\_\_

Total = 4

**OTHER** (See Instructions)

Supernumerary teeth \_\_\_\_\_ x 1 pt. = \_\_\_\_\_  
 Ankylosis of perm. teeth \_\_\_\_\_ x 2 pts. = \_\_\_\_\_  
 Anomalous morphology \_\_\_\_\_ x 2 pts. = \_\_\_\_\_  
 Impaction (except 3<sup>rd</sup> molars) \_\_\_\_\_ x 2 pts. = \_\_\_\_\_  
 Midline discrepancy (≥3mm) @ 2 pts. = \_\_\_\_\_  
 Missing teeth (except 3<sup>rd</sup> molars) \_\_\_\_\_ x 1 pts. = \_\_\_\_\_  
 Missing teeth, congenital \_\_\_\_\_ x 2 pts. = \_\_\_\_\_  
 Spacing (4 or more, per arch) \_\_\_\_\_ x 2 pts. = \_\_\_\_\_  
 Spacing (Mx cent. diastema ≥ 2mm) @ 2 pts. = \_\_\_\_\_  
 Tooth transposition \_\_\_\_\_ x 2 pts. = \_\_\_\_\_  
 Skeletal asymmetry (nonsurgical tx) @ 3 pts. = \_\_\_\_\_  
 Addl. treatment complexities \_\_\_\_\_ x 2 pts. = 2

Identify: Lip Incompetence

Total = 2

**IMPLANT SITE**

Lip line : Low (0 pt), Medium (1 pt), High (2 pts) = \_\_\_\_\_  
 Gingival biotype : Low-scalloped, thick (0 pt), Medium-scalloped, medium-thick (1 pt), High-scalloped, thin (2 pts) = \_\_\_\_\_  
 Shape of tooth crowns : Rectangular (0 pt), Triangular (2 pts) = \_\_\_\_\_  
 Bone level at adjacent teeth : ≤ 5 mm to contact point (0 pt), 5.5 to 6.5 mm to contact point (1 pt), ≥ 7 mm to contact point (2 pts) = \_\_\_\_\_  
 Bone anatomy of alveolar crest : H&V sufficient (0 pt), Deficient H, allow simultaneous augment (1 pt), Deficient H, require prior grafting (2 pts), Deficient V or Both H&V (3 pts) = \_\_\_\_\_  
 Soft tissue anatomy : Intact (0 pt), Defective ( 2 pts) = \_\_\_\_\_  
 Infection at implant site : None (0 pt), Chronic (1 pt), Acute( 2 pts) = \_\_\_\_\_

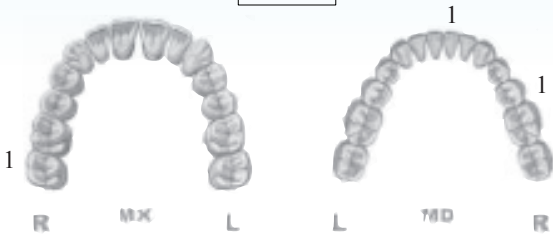Total = 0

# Cast-Radiograph Evaluation

Total Score: **24**

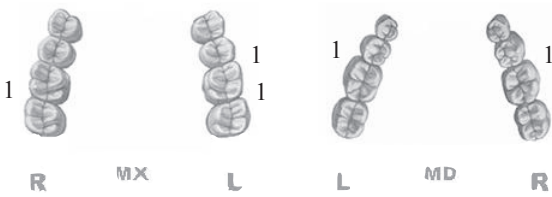
## Alignment/Rotations

3



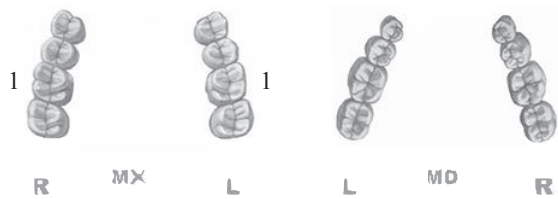
## Marginal Ridges

5



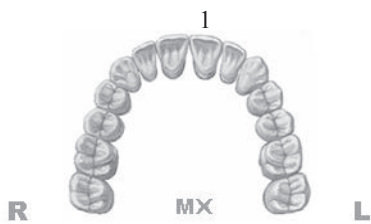## Buccolingual Inclination

2



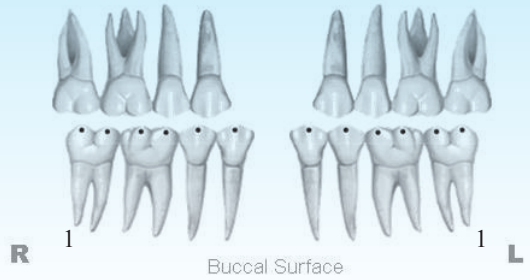
## Overjet

1

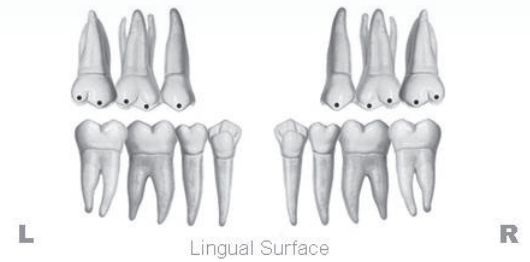


## Occlusal Contacts

2



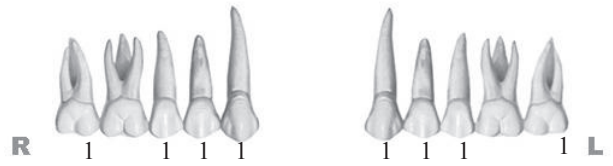
Buccal Surface



Lingual Surface

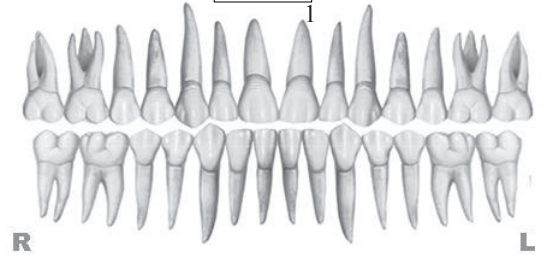
## Occlusal Relationships

8



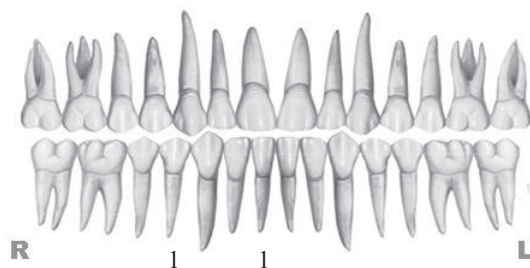
## Interproximal Contacts

1



## Root Angulation

2

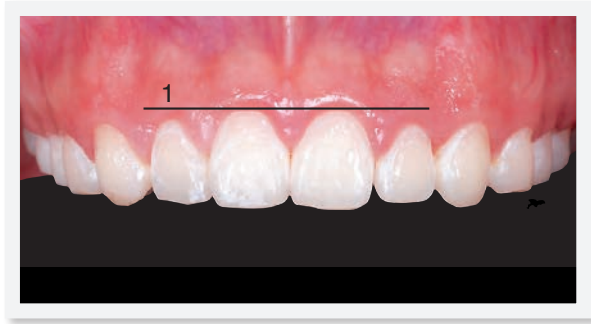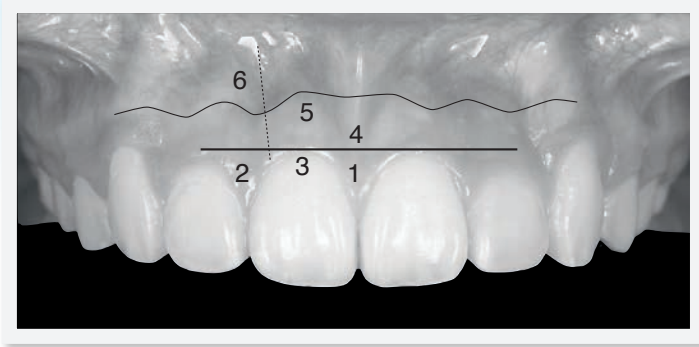


**INSTRUCTIONS:** Place score beside each deficient tooth and enter total score for each parameter in the white box. Mark extracted teeth with "X". Second molars should be in occlusion.

# IBOI Pink & White Esthetic Score

Total Score: = 2

## 1. Pink Esthetic Score

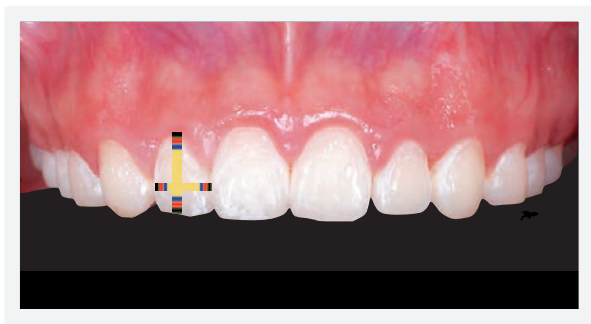
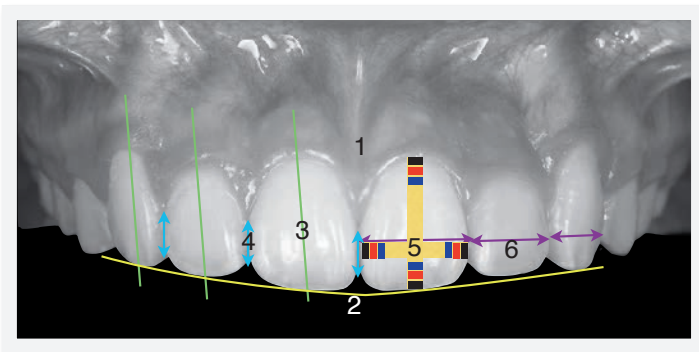


Total = 1

1. M & D Papillae	0	1	2
2. Keratinized Gingiva	0	1	2
3. Curvature of Gingival Margin	0	1	2
4. Level of Gingival Margin	0	1	2
5. Root Convexity ( Torque )	0	1	2
6. Scar Formation	0	1	2

1. M & D Papillae	<span style="border: 1px solid red; border-radius: 50%; padding: 2px;">0</span>	1	2
2. Keratinized Gingiva	<span style="border: 1px solid red; border-radius: 50%; padding: 2px;">0</span>	1	2
3. Curvature of Gingival Margin	0	<span style="border: 1px solid red; border-radius: 50%; padding: 2px;">1</span>	2
4. Level of Gingival Margin	<span style="border: 1px solid red; border-radius: 50%; padding: 2px;">0</span>	1	2
5. Root Convexity ( Torque )	<span style="border: 1px solid red; border-radius: 50%; padding: 2px;">0</span>	1	2
6. Scar Formation	<span style="border: 1px solid red; border-radius: 50%; padding: 2px;">0</span>	1	2

## 2. White Esthetic Score ( for Micro-esthetics )



Total = 1

1. Midline	0	1	2
2. Incisor Curve	0	1	2
3. Axial Inclination (5°, 8°, 10°)	0	1	2
4. Contact Area (50%, 40%, 30%)	0	1	2
5. Tooth Proportion (1:0.8)	0	1	2
6. Tooth to Tooth Proportion	0	1	2

1. Midline	<span style="border: 1px solid red; border-radius: 50%; padding: 2px;">0</span>	1	2
2. Incisor Curve	<span style="border: 1px solid red; border-radius: 50%; padding: 2px;">0</span>	1	2
3. Axial Inclination (5°, 8°, 10°)	<span style="border: 1px solid red; border-radius: 50%; padding: 2px;">0</span>	1	2
4. Contact Area (50%, 40%, 30%)	<span style="border: 1px solid red; border-radius: 50%; padding: 2px;">0</span>	1	2
5. Tooth Proportion (1:0.8)	0	<span style="border: 1px solid red; border-radius: 50%; padding: 2px;">1</span>	2
6. Tooth to Tooth Proportion	<span style="border: 1px solid red; border-radius: 50%; padding: 2px;">0</span>	1	2



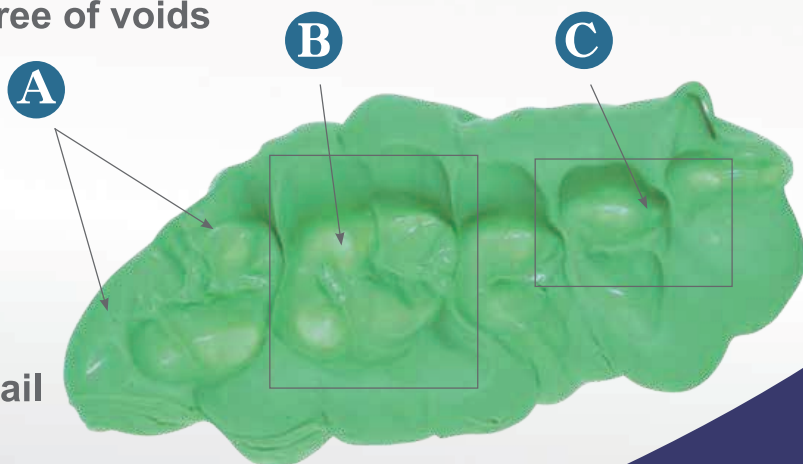
## Take 1 Advanced Bite Registration

**加成型印模材** Take 1 Advanced Bite completes the Take 1 Advanced portfolio providing you a complete solution within a single family of products.

**A** 材料均勻並無氣泡的釋出  
Material is uniform and free of voids

**B** 傑出的咬合接觸  
Exceptional contact

**C** 絕佳的咬合面細節  
Excellent anatomical detail



# Hands-on Course

補綴不囉唆：

## 補綴基本 蹲步馬

Dr. 杜哲光 X Dr. 吳如惠

台北、台中、高雄

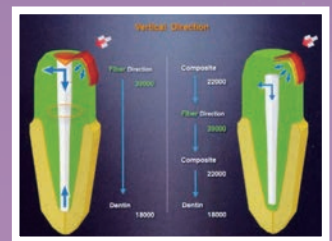
### 演講內容

Post 與 Core 之  
臨床考量與操作技巧

臨床上需要以固定補綴物來恢復牙齒形態及功能的症例中，有許多因為齒質不足等原因而無法提供適當的固持效果，因此需要利用冠心與根柱以強化上部固定補綴物之固持力。口腔內之各式外力可視為震度不一的地震，冠心與根柱需有多少級數之防震係數，端視材料與工法。

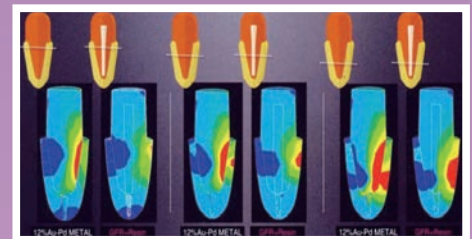
在臨床上，時常觀察到因為未能確實製作冠心根柱，而導致補綴物脫落之病例不勝枚舉。其中有許多例子失敗的原因，可能是將抵抗冠心脫落之主要維持裝置完全寄託於根管內之故。牙根之長度、寬度不一定都符合治療上之需求，彎曲根管的情形亦不少見，在此情況下欲將有充分長度及寬度之維持裝置完全設置於根管內並非容易的工作。此課程中加以闡述臨床的要求及重點！

冠心與根柱之選擇與製作看似簡單，卻包含了許多臨床上的考量以及各種不同的方法與材料，然而卻鮮少有人重視，本次繼續教育將針對冠心與根柱之操作技巧及各種臨床應用方法加以介紹，並以Fiber Post 與 Resin Cement 做為實際模型操作材料，期使各位醫師對 Post 與 Cement 之應用有更深入的了解。



### 牙科黏著劑系統 選擇之臨床考量

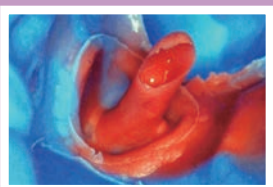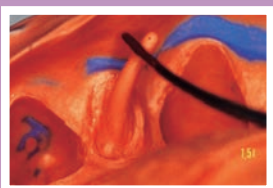
市面上有許多不同種類的牙科黏著劑(如ZPC、PC、GIC 和 Resin Cement 等)，而相同種類的牙科黏著劑又有各種廠牌，每家廠商都說自家廠牌最好，而身為牙醫師的您要如何去判定？臨床上，您如何選擇牙科黏著劑？您每一個 case 都是用同一種牙科黏著劑嗎？希望由這一堂牙科黏著劑的簡介，提供臨床醫師對各種牙科黏著劑的認識，進而瞭解其特性且比較各種不同牙科黏著劑、材料的使用步驟、操作時間的差異與臨床使用上之選擇。



### 印模方法的選擇、準備 與印模成敗因果之探討

印模製取的精密度直接關係到鑲復物製作的成敗，在臨床工作中，要取得精確的印模，除與印模材料的選擇有關外，還與牙醫師印模的方法與操作技巧有關。印模採用何種方法端看病人口腔缺牙位置、廠商配件之設計、印模材料之適用等，以期獲得可接受之主模型，從而減低其對鑲復物支台齒與其牙周組織可能形成之潛在壓力，以增加鑲復物的使用壽命。

希望藉由本次繼續教育能提供臨床醫師，對印模這個門診必備的動作，有一較清楚之概念，進而減少印模發生之錯誤，提高醫師、助理與病患更佳之診療品質。





# 報名 資訊

- 主辦單位** 高雄醫學大學附設中和紀念醫院牙科部
- 協辦單位** 湧傑企業股份有限公司
- 時間** 2014年 09/21 高雄 9:00am - 5:00pm  
10/19 台中 9:00am - 5:00pm  
11/16 台北 9:00am - 5:00pm
- 地點** 高雄：高雄市三民區十全一路100號 / 高雄醫學大學學術研究大樓B2  
台中：台中市西屯區台灣大道3段658號3樓 / 中國文化大學台中教育中心RICH 19大樓  
台北：台北市復興北路99號15樓 / 犇亞會議中心
- 報名方式** 請於報名後3日內劃撥費用至  
戶名：湧傑企業股份有限公司 帳號：17471807  
請先電話報名 (各班限額30名，額滿為止)
- 報名電話** 高雄 07-226-0030  
台中 04-2305-8915  
台北 02-2778-8315 #124、#125
- 費用** 會員 \$3000元 /非會員 \$4000元  
費用含hands-on材料，並贈送  
1. NX3 Dual-Cure 樹脂黏著劑一支  
2. Take1 Advanced LB Wash 加成型印模材一盒  
3. OptiDisc General Kit 半透明拋光沙輪組一組
- 學分** 參加者發給繼續教育學分



## 講師 介紹

### 杜哲光

高雄醫學大學牙醫學學士 / 高雄醫學大學牙醫學碩士  
台灣牙醫植體醫學會專科醫師 / 台灣牙周補綴醫學會專科醫師  
中華民國牙體復形學會專科醫師  
中華民國鑲復牙醫學會專科醫師  
高雄醫學大學附設中和紀念醫院臨床教育訓練部牙科訓練室主任  
高雄醫學大學附設中和紀念醫院牙科部補綴科主治醫師  
高雄醫學大學牙醫學系助理教授

### 吳如惠

高雄醫學大學牙醫學碩士  
高雄醫學大學中和紀念醫院牙科部主治醫師  
中華民國家庭牙醫學會專科醫師  
高雄醫學大學口腔衛生學系助理教授

# Asymmetric Extraction of Adult Orthodontic Treatment

## History and Etiology

A 50-year-old female was referred by her dentist for orthodontic consultation (Fig. 1). Her chief concerns were crowding and protrusion of the maxillary anterior teeth (Figs. 2 and 3). There were no contributory medical problems. The clinical exam revealed: 1. maxillary incisor protrusion with an overjet of about 8 mm, 2. two three-unit bridges to replace missing 1<sup>st</sup> molars, 3. crown on the lower left 1<sup>st</sup> molar, and 4. three missing teeth (*maxillary left 1<sup>st</sup> molar, mandibular right 1<sup>st</sup> molar and left central incisor*). The patient was treated to an acceptable result as documented in Figs. 4-9. The cephalometric and panoramic radiographs document the pre-treatment conditions (Fig. 7) and the post-treatment results (Fig. 8). The cephalometric tracings before and after treatment are superimposed in Fig. 9. The details for diagnosis and treatment will be discussed below.

## Diagnosis

### Skeletal:

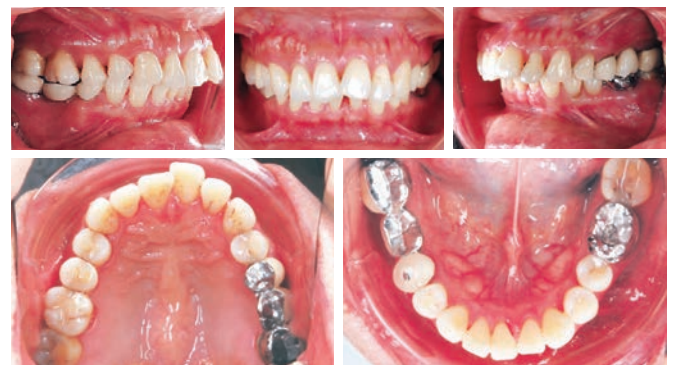- Skeletal Class II ( $SNA\ 77^\circ$ ,  $SNB\ 69.5^\circ$ ,  $ANB\ 7.5^\circ$ )
- Mandibular plane angle ( $SN-MP\ 38^\circ$ ,  $FMA\ 31^\circ$ )

### Dental:

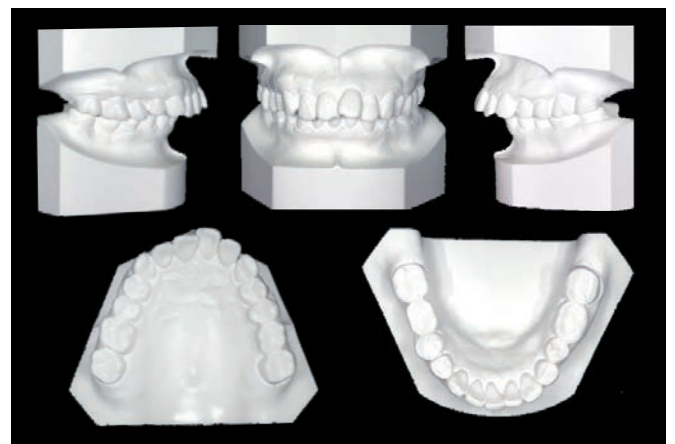- Molar relationships: *Right Class II; Left Class I; 8mm*



■ Fig. 1: Pre-treatment facial photographs



■ Fig. 2: Pre-treatment intraoral photographs

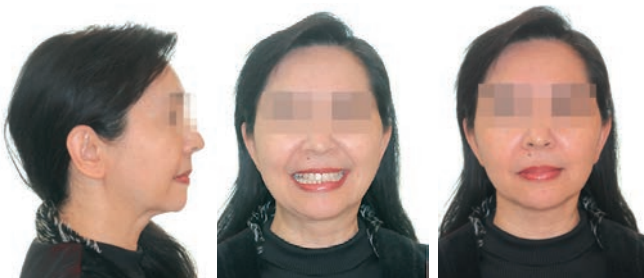

■ Fig. 3: Pre-treatment study models

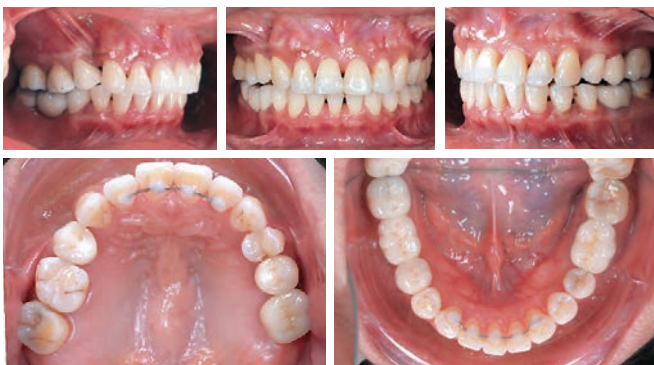**Dr. Ming-Jen Chang,**  
Lecturer, Beethoven Orthodontic Course (Left)

**Dr. Chris Chang,**  
Founder, Beethoven Orthodontic Center  
Publisher, International Journal of Orthodontics & Implantology (middle)

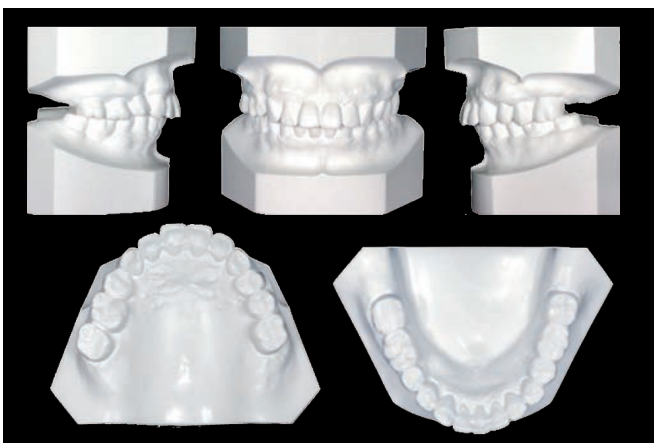**W. Eugene Roberts,**  
Consultant, International Journal of Orthodontics & Implantology (right)



■ Fig. 4: Post-treatment facial photographs



■ Fig. 5: Post-treatment intraoral photographs



■ Fig. 6: Post-treatment study models

overjet; 6mm overbite (Fig. 10). Labially inclined mandibular incisors ( $112^\circ$ )

- Missing teeth: maxillary left 1<sup>st</sup> molar, mandible right 1<sup>st</sup> molar and left central incisor
- Unesthetic prostheses: three-unit bridges to replaced missing molars, and a metal crown on the lower left 1<sup>st</sup> molar

**Facial:**

- Maxillary protrusion with upper lip strain.

The ABO Discrepancy Index (DI) was 38 as shown in the subsequent worksheet.

**Specific Objectives of Treatment**

**Maxilla (all three planes):**

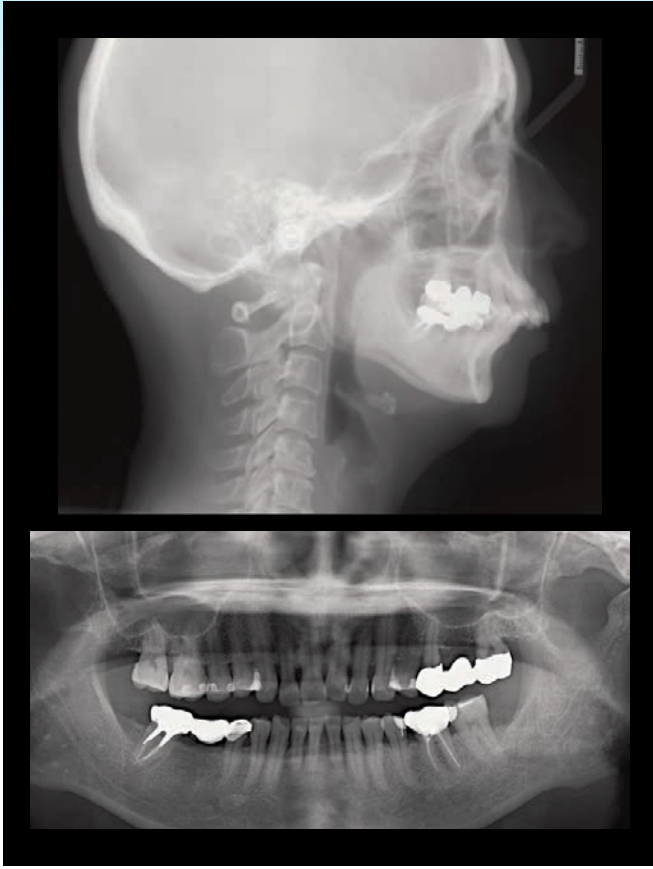
- A - P: *Retract.*
- Vertical: *Maintain.*
- Transverse: *Maintain.*

**Mandible (all three planes):**

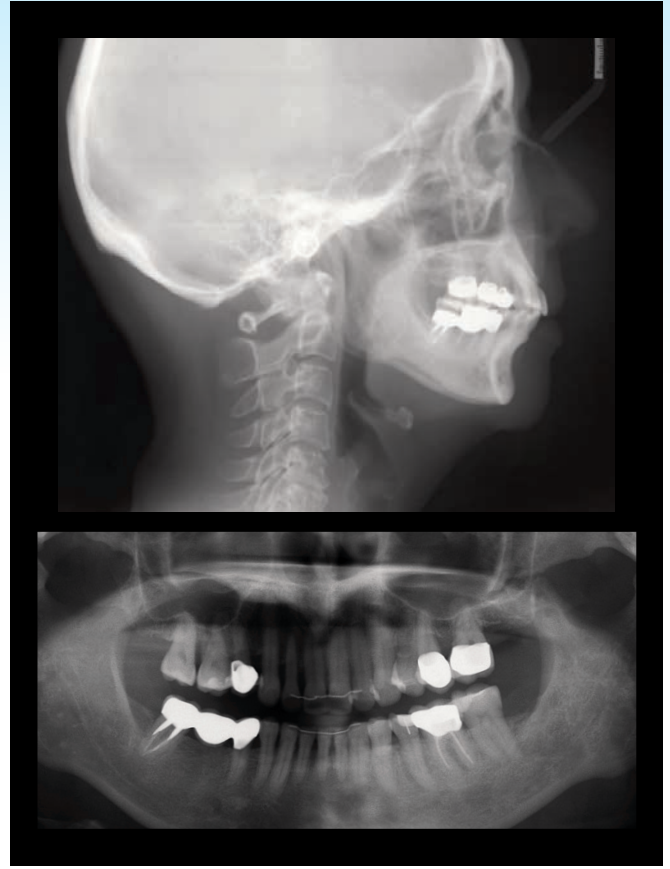
- A - P: *Maintain.*
- Vertical: *Maintain.*
- Transverse: *Maintain.*

**Maxillary Dentition**

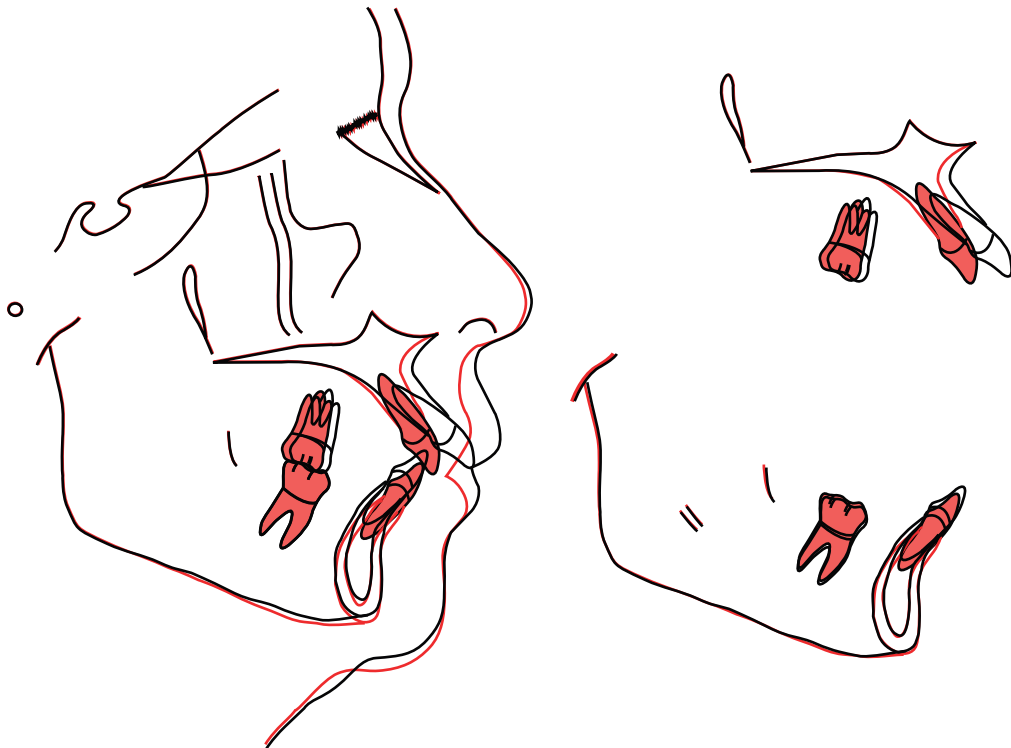
- A- P: *Retract incisors, protract posterior segments bilaterally.*



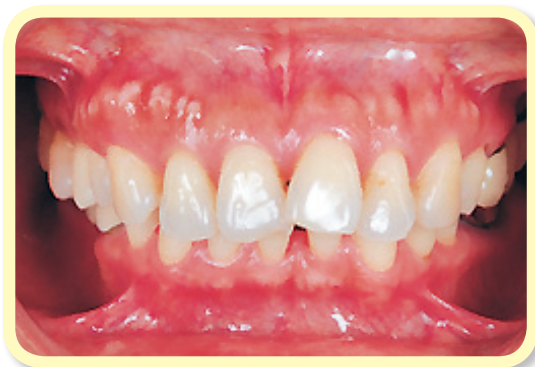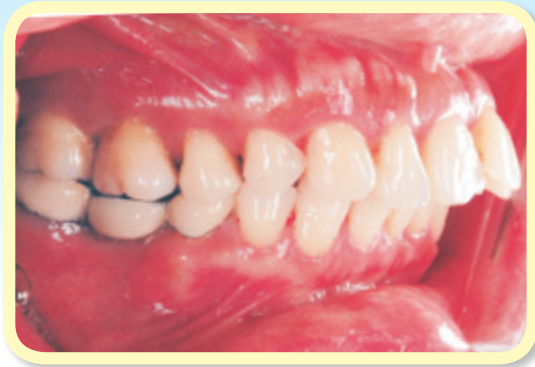■ Fig. 7: Pre-treatment pano and ceph radiographs



■ Fig. 8: Post-treatment pano and ceph radiographs



■ Fig. 9: Superimposed tracings show 1. the upper anterior teeth and molar retracted. 2. the lower anterior intruded.



■ Fig. 10:

The maxillary incisor was protrusion with an overjet of about 8 mm and 6 mm overbite.

- Vertical: *Maintain.*
- Inter-molar Width: *Maintain.*

#### Mandibular Dentition:

- A - P: *Maintain.*
- Vertical: *Maintain.*
- Inter-molar / Inter-canine Width: *Maintain.*

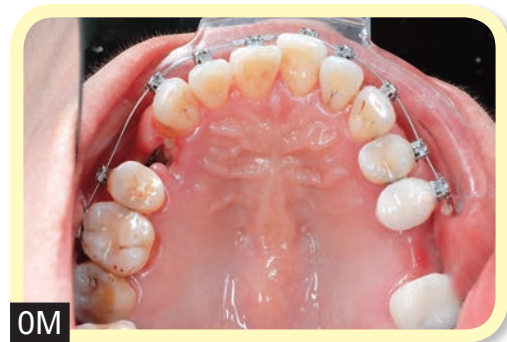#### Facial Esthetics:

- Reduce upper lip protrusion.

### Treatment Plan

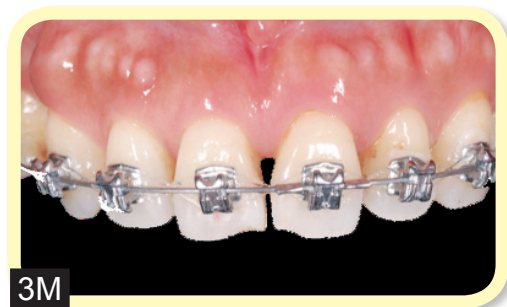Extraction treatment with a full fixed orthodontic appliance was indicated to retract and level the upper dentition and align the lower arch. In the initial stage of the treatment, the upper right first

premolar was extracted to relieve upper anterior crowding (Fig. 11), and OrthoBoneScrew® (OBS) anchorage was used to assist in anterior protrusion correction. Power chains were used to close the extraction spaces. Detail bending and settling elastics produced the final occlusion. The bonded appliances were removed and the corrected dentition was retained with fixed retainers from the maxillary right lateral incisor to the left lateral incisor, and from the mandibular right canine to the left canine. Clear overlay retainers were constructed for both arches.



■ Fig. 11:

The right first premolar was extracted, the three-unit bridge from the left 2<sup>nd</sup> premolar to 2<sup>nd</sup> molar was removed, and the temporary crowns were place on both abutments.



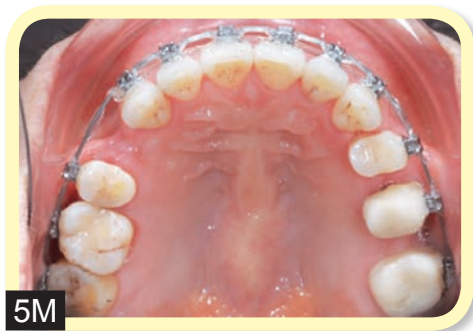■ Fig. 12:

The black triangle between the maxillary central incisors was corrected with interproximal stripping and power tube traction to close the resulting space.

## Appliances and Treatment Progress

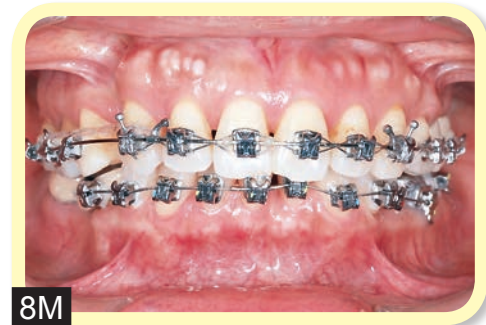The right first premolar was extracted, the three-unit bridge from the left 2<sup>nd</sup> premolar to 2<sup>nd</sup> molar was removed, and the temporary crowns were placed on both abutments (Fig. 11). A .022" slot Damon D3MX bracket system (Ormco) was used, and the maxillary incisors were bonded with high torque brackets. The initial archwire was .014" CuNiTi.

After one and half months of initial alignment and leveling, the archwire was changed to .014x.025" CuNiTi. Meanwhile, the black triangle between the maxillary central incisors was corrected with interproximal stripping and power tube traction to close the resulting space (Fig. 12). In the 4<sup>th</sup> month, the archwire was changed to .017x.025" low friction TMA in the upper arch. Open coil springs were used to open spaces between the upper left canine and left 1<sup>st</sup> premolar, as well as between the left 1<sup>st</sup> premolar and 2<sup>nd</sup> premolar (Fig. 13). Opening space facilitated the restoration of caries on the upper left 1<sup>st</sup> premolar. In the 8<sup>th</sup> month of active treatment, the maxillary anterior segment was ligated with a

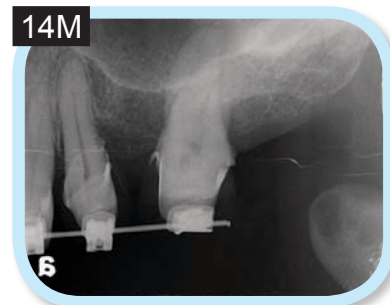

■ **Fig. 13:**  
Open coil springs were used to open spaces between the upper left canine and left 1<sup>st</sup> premolar, as well as between the left 1<sup>st</sup> premolar and 2<sup>nd</sup> premolar.

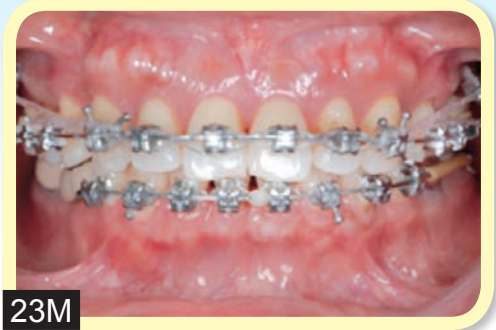Figure-eight tie using a .012" stainless steel ligature, and the mandibular arch was bonded with standard torque brackets (Fig. 14). After fourteen months of treatment, a bony defect was noted distal to the upper left 2<sup>nd</sup> premolar. Periodontal therapy was indicated and closely monitored with follow-up checks (Fig. 15). In the 23<sup>th</sup> month, the lower arch archwire was changed to .017x.025" TMA and the anterior segment was ligated with a Figure-eight tie. At the same time, two miniscrews (2x12 mm OrthoBoneScrew®, Newton's A Ltd, Taiwan.) were inserted into the infrazygomatic crests bilaterally. The elastometric chains were attached from upper right and left canines to the screws (Fig. 16). During the active treatment period, the brackets



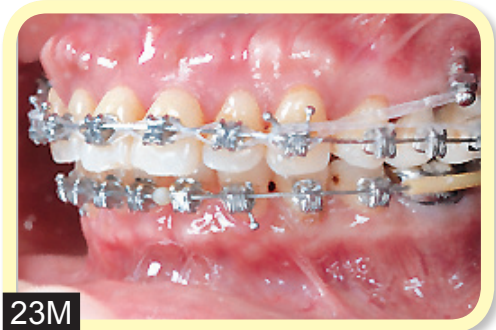■ **Fig. 14:**  
The maxillary anterior segment was ligated with a Figure-eight tie using a .012" stainless steel ligature, and the mandibular arch was bonded with standard torque brackets.



■ **Fig. 15:**  
A bony defect was noted distal to the upper left 2<sup>nd</sup> premolar.



23M



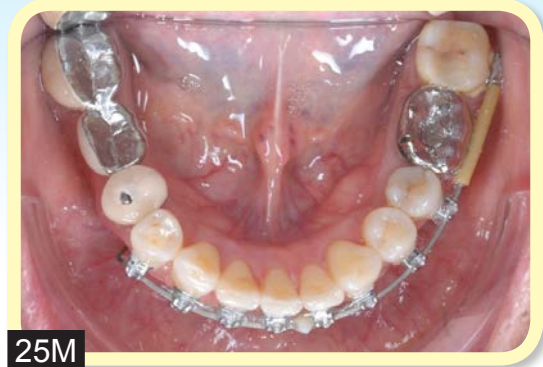23M

■ Fig. 16:

The mandibular anterior segment was ligated with a Figure-eight tie. Two miniscrews were inserted into the infrazygomatic crests bilaterally. The elastometric chains were attached from upper right and left canines to the screws.

on the lower right 2<sup>nd</sup> premolar and left 1<sup>st</sup> molar were frequently loose, because the lower right 2<sup>nd</sup> premolar was a three-unit porcelain fused to metal bridge, and the left 1<sup>st</sup> molar was a single metal crown. It is usually difficult to retain bonded brackets on these prosthetic materials.

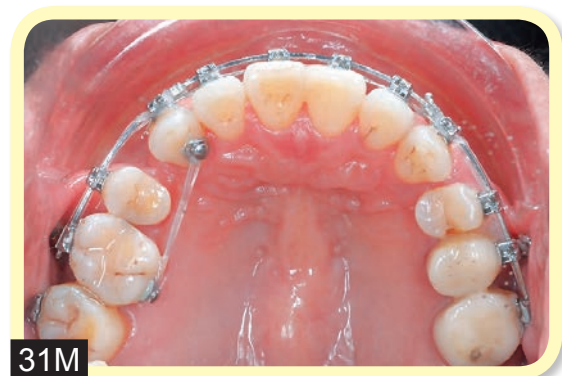The lower archwire was sectioned to the right 1<sup>st</sup> premolar and an archwire sleeve was inserted between the left 2<sup>nd</sup> premolar and 2<sup>nd</sup> molar area (Fig. 17). In the 31<sup>st</sup> month, the upper right 1<sup>st</sup> premolar extraction space was still not completely closed. Two buttons were bonded on the palatal side of the upper right canine and 1<sup>st</sup> molar and a power chain was activated between the two (Fig. 18).



25M

■ Fig. 17:

The lower archwire was sectioned to the right 1<sup>st</sup> premolar and an archwire sleeve was inserted between the left 2<sup>nd</sup> premolar and 2<sup>nd</sup> molar area.

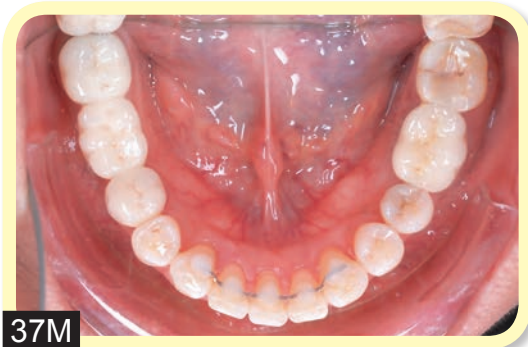
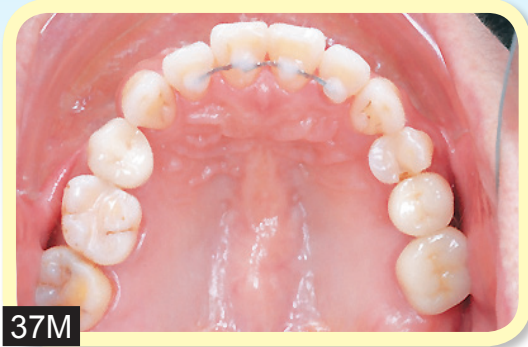
31M

■ Fig. 18:

Two buttons were bonded on the palatal side of the upper right canine and 1<sup>st</sup> molar and a power chain was activated between the two.

After 37 months of active treatment, all appliances were removed. Four months after fixed appliance removal, porcelain crowns and fixed partial dentures were constructed to replace the previous metal prostheses (Fig. 19). The corrected dentitions were retained with fixed anterior retainers in both arches: 1. maxillary right lateral incisor to left lateral incisor, and 2. mandibular right canine to left canine. Clear overlay retainers were delivered on both arches.



■ **Fig. 19:**  
Four months after fixed appliance removal, porcelain crowns and fixed partial dentures were constructed to replace the previous metal protheses.

## Results Achieved

### Maxilla (all three planes):

- A - P: Retracted.
- Vertical: Maintained
- Transverse: Maintained

### Mandible (all three planes):

- A - P: Maintained
- Vertical: Increased ~2mm
- Transverse: Maintained

### Maxillary Dentition

- A - P: Decreased axial inclination and retraction of central incisors, extraction spaces were closed.

- Vertical: *Maintained.*
- Inter-molar / Inter-canine Width: *Maintained.*

### Mandibular Dentition

- A - P: *Alignment and intrusion of anterior teeth.*
- Vertical: *Maintained.*
- Inter-molar / Inter-canine Width: *Maintained.*

### Facial Esthetics:

- Protrusive upper lip was retracted, decreased bimaxillary lip prominence.

## Retention

The fixed retainers were bonded on all maxillary incisors and from canine to canine in the mandibular arch. The upper and lower clear overlay retainers were delivered with instructions for full time wear for the first 6 months and nights only thereafter. The patient was carefully instructed in the home care and maintenance of the retainers.

## Final Evaluation of Treatment

The American Board of Orthodontics (ABO) Cast-Radiograph Evaluation (CRE) score was 26 points. The major discrepancy was an occlusal relationship problem (10 points), which reflected an inadequate correction of the Class II buccal segments. The final interdigitation of the buccal segments was a compensated Class II occlusion, due to severe mandibular retrusion (SNB 69.5°). The IBOI pink and white esthetic score was 3.

The upper anterior incisors were retracted and upper extraction spaces were closed to resolve the



patient's chief complaints. Pleasing dental esthetics were achieved by correcting the excessive overjet, overbite and extraction space. However, close follow-up is indicated to monitor the tendency for extraction spaces to reopen.

Overall, there was a significant improvement in both dental esthetics and occlusion. The facial esthetics, associated with a decreased lip profile and excessive nasolabial angle, were acceptable considering the occlusal compromise necessitated by the severe mandibular retrusion.

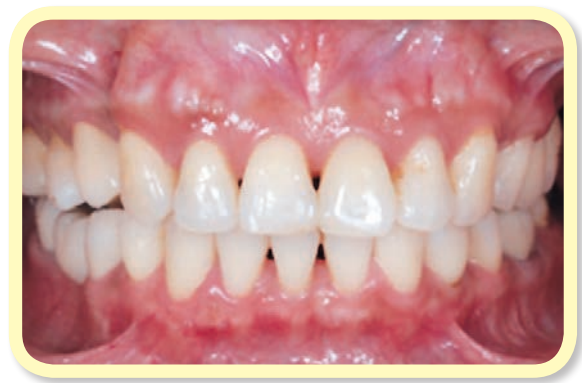## Discussion

Skeletal Class II malocclusions should be treated according to the anteroposterior discrepancy, age of the patient, and expected compliance. Orthopedic methodology include extraoral anchorage, functional appliances, and temporary anchorage devices (TADs). Dentoalveolar compensation can be accomplished with fixed appliances and Class II inter-maxillary elastics. Extraction space is helpful for correcting overjet and a midline discrepancy. In addition to correcting the dental Class II relationship, an important objective of dentofacial orthopedic treatment is to produce a good facial balance.

The extraction pattern can involve maxillary and/or mandibular premolars. The extraction of only 2 maxillary premolars is generally indicated when there is no crowding or cephalometric discrepancy in the mandibular arch. Extraction of a premolar in each quadrant is indicated primarily for crowding in the mandibular arch, and/or a cephalometric discrepancy in growing patients. Correction of Class

II malocclusion with excessive overjet in an adult usually requires maximum anchorage, when only 2 maxillary premolars are extracted. Anchorage can be supplemented with an extraoral appliances, but that require rigorous patient compliance. However, when a Class II malocclusion is treated with premolar extractions in all four quadrants, there is an even greater need for anchorage. Consequently, successful treatment increasingly depends on patient compliance, so the result may be compromised.<sup>1</sup> Overall, treatment of Class II malocclusions with maxillary extractions only, or with extractions of premolars in both arches, has similar long-term post-treatment stability.<sup>2</sup>

For the present patient, the overjet was 8 mm and the overbite was 6mm. Correction of a large overjet and deep-bite is difficult in adult patients. The treatment plan for these patients usually involves extraction of the maxillary first premolars. As shown in Fig. 7, the upper left first molar was missing, so the asymmetric extraction of the upper right first premolar was indicated. Closing the extraction spaces to improve the overjet and overbite is a relatively simple approach, but posterior anchorage



■ Fig. 20: Post-treatment intra-oral frontal photo

can be a problem, requiring headgear, orthodontic bone screws, or intermaxillary elastics.<sup>3</sup>

As a general rule, orthodontics only is not indicated for a positive overjet greater than 8 mm, a negative overjet of 4 mm or greater, and/or a transverse discrepancy greater than 3 mm. However, deep overbite patients can usually be treated without extractions or surgery.<sup>4</sup>

Patient with Class II malocclusions may be Class I on one side and Class II on the other, resulting in an asymmetric occlusal relationship that complicates orthodontic treatment. Depending on the degree of asymmetry, treatment approaches by quadrant include symmetric extraction of 4 premolars and asymmetric extraction of 3 premolars. The 4-premolar-extraction approach has the potential

to produce a final occlusion with bilateral Class I molar and canine relationships. On the other hand, asymmetric extraction of 3 premolars (2 maxillary premolars and 1 mandibular premolar on the Class I side) will produce Class I canine and molar relationships on one side, with a Class II molar and Class I canine relationships on the Class II side. With either approach, the maxillary and mandibular dental midlines can be corrected to coincide with the midsagittal plane (*facial midline*).<sup>5</sup>

Orthodontic treatment combined with either miniscrew anchorage or headgear can achieve acceptable results with overjet reduction and improvement of facial profile in patients with skeletal Class II malocclusion. However, miniscrew anchorage does not require patient cooperation, so the treatment prognosis is more predictable.<sup>6</sup>

According to the A-line of Alvarez et al.,<sup>7</sup> there was a severe anterior position of the maxillary incision roots, indicating the use of high-torque brackets and bilateral miniscrews in the infrazygomatic crests. This approach allowed for the correction of the maxillary incisor inclination without compromising the antero-posterior position of the maxilla.

Miniscrews have a high success rate of approximately 90% and they provided sufficient anchorage immediately after placement surgery for orthodontic tooth movement. In addition, miniscrews placed without a mucoperiosteal incision or flap surgery result in significantly reduced pain and discomfort after implantation. Miniscrews have suitable characteristics for orthodontics anchorage.<sup>8</sup> When a midline discrepancy is present (*Figs. 1-3*), the incisors can be aligned and moved to their optimum

CEPHALOMETRIC			
SKELETAL ANALYSIS			
	PRE-Tx	POST-Tx	DIFF.
SNA°	77°	74.5°	-2.5°
SNB°	69.5°	69.5°	0°
ANB°	7.5°	5°	-2.5°
SN-MP°	38°	39°	1°
FMA°	31°	32°	1°
DENTAL ANALYSIS			
U1 TO NA mm	9 mm	5 mm	-4 mm
U1 TO SN°	113°	97°	-16°
L1 TO NB mm	9 mm	9 mm	0mm
L1 TO MP°	112°	110°	-2°
FACIAL ANALYSIS			
E-LINE UL	2 mm	-5 mm	-7 mm
E-LINE LL	0 mm	-2 mm	-2 mm

■ Table 1: Cephalometric summary

location with a fixed appliance, supplemented by intermaxillary elastics.

The CRE score was 24, with most of the points reflecting a problem in the sagittal occlusal relationship (*interdigitation*). The etiology of the malocclusion involved asymmetric extractions, so treatment was directed at achieving the best occlusal alignment by utilizing extraction spaces supplemented with posterior maxillary miniscrews. Fortunately, it was possible to correct the midline, close space and achieve an optimal posterior interdigitation. The Pink & White esthetic score was 3, reflecting problematic areas in the maxillary anterior: inadequate soft tissue papilla between the central incisors (*black triangle*) and irregular incisal edges.

## Conclusion

Extraction in only one quadrant is a common approach for resolving asymmetric malocclusions in adults. If there is excessive overjet and/or a midline discrepancy, it is important to optimally manage the space with supplemental anchorage, such as bilateral infrazygomatic miniscrews. Palatal buttons for attachment of power chains are helpful for efficient space closure and control of rotations.

The present difficult malocclusion ( $DI = 38$ ) was treated to an acceptable result as documented by a  $CRE = 24$ , and a Pink and White esthetic score of 3. The patient was pleased with the dental and facial result, although her lips were relatively flat and the nasolabial angle was excessive. Considering the patient's severely retrusive mandible, this was an optimal facial result.

## Acknowledgment

Thanks to Mr. Paul Head for proofreading this article.

## References

1. Guilherme J, Adriana CB, Jose FCH, Marcos RE, Leniana SN. Class II treatment success rate in 2- and 4- premolar extraction protocols. *Am J Orthod Dentofacial Orthop* 2004;125:472-9.
2. Guilherme J, Vladimir LS, Ruben LS, Marcos J, and Marcos RE. Long-term stability of Class II malocclusion treated with 2- and 4-premolar extraction protocols. *Am J Orthod Dentofacial Orthop* 2009;136:154.e. 1-154. e. 10.
3. Wu S, Chang CH, Roberts WE. Impinging Overbite and Large Overjet. *iAOI Case Report* 2011;18:192-9.
4. Douglas S, Al MB, Steven JL, and Daniel ML. Determining the limits of orthodontic treatment of overbite, overjet, and transverse discrepancy: A pilot study. *Am J Orthod Dentofacial Orthop* 2006;129:804-8.
5. Guilherme J, Eduardo AD, Jose ' FCH, Marcos RE, and Karina Jero^ nimo RSL. Class II subdivision treatment success rate with symmetric and asymmetric extraction protocols. *Am J Orthod Dentofacial Orthop* 2003;124:257-64.
6. Kuroda S, Yamada K, Deguchi T, Kyung HM, and Teruko TY. Class II malocclusion treated with miniscrew anchorage: Comparison with traditional orthodontic mechanics outcomes. *Am J Orthod Dentofacial Orthop* 2009;135:302-9.
7. Alvarez, et al. The A Line: a new guide for diagnosis and treatment planning. *JCO* 2001;35:556-569.
8. Kuroda S, Yamada K, Deguchi T, Kyung HM, Teruko TY. Clinical use of miniscrew implants as orthodontic anchorage: Success rates and postoperative discomfort. *Am J Orthod Dentofacial Orthop* 2007;131:9-15.
9. Chang CH. Advanced Damon Course No. 8: Excellence in Finishing, Beethoven Podcast Encyclopedia in Orthodontics [podcast]. Hsinchu: Newton's A Ltd; 2011.
10. Chang CH. Advanced Damon Course No. 4,5 : DI & CRE Workshop (1)(2)., Beethoven Podcast Encyclopedia in Orthodontics [podcast]. Hsinchu: Newton's A Ltd; 2011.
11. Chang CH. Basic Damon Course No.5: Finish Bending, Beethoven Podcast Encyclopedia in Orthodontics [podcast]. Hsinchu: Newton's A Ltd; 2011.
12. Huang S. Tom Pitts': Secrets of Excellent Finishing. *News & Trends in Orthodontics* 2009;14:6-23.



# Discrepancy Index Worksheet

**TOTAL D.I. SCORE**      **38**

**OVERJET**

0 mm. (edge-to-edge)	=	
1 – 3 mm.	=	0 pts.
3.1 – 5 mm.	=	2 pts.
5.1 – 7 mm.	=	3 pts.
7.1 – 9 mm.	=	4 pts.
> 9 mm.	=	5 pts.

Negative OJ (x-bite) 1 pt. per mm. per tooth =

**Total** = **4**

**OVERBITE**

0 – 3 mm.	=	0 pts.
3.1 – 5 mm.	=	2 pts.
5.1 – 7 mm.	=	3 pts.
Impinging (100%)	=	5 pts.

**Total** = **3**

**ANTERIOR OPEN BITE**

0 mm. (edge-to-edge), 1 pt. per tooth  
then 1 pt. per additional full mm. per tooth

**Total** = **0**

**LATERAL OPEN BITE**

2 pts. per mm. per tooth

**Total** = **0**

**CROWDING** (only one arch)

1 – 3 mm.	=	1 pt.
3.1 – 5 mm.	=	2 pts.
5.1 – 7 mm.	=	4 pts.
> 7 mm.	=	7 pts.

**Total** = **1**

**OCCCLUSION**

Class I to end on	=	0 pts.
End on Class II or III	=	2 pts. per side <u>4</u> pts.
Full Class II or III	=	4 pts. per side <u>4</u> pts.
Beyond Class II or III	=	1 pt. per mm. <u>4</u> pts. additional

**Total** = **4**

**LINGUAL POSTERIOR X-BITE**

1 pt. per tooth      Total = **0**

**BUCCAL POSTERIOR X-BITE**

2 pts. per tooth      Total = **0**

**CEPHALOMETRICS**      (See Instructions)

ANB  $\geq 6^\circ$  or  $\leq -2^\circ$  = 4 pts. **4**

Each degree  $< -2^\circ$  \_\_\_\_\_ x 1 pt. = \_\_\_\_\_

Each degree  $> 6^\circ$  **1** x 1 pt. = **1**

**SN-MP**

$\geq 38^\circ$  = 2 pts. **2**

Each degree  $> 38^\circ$  \_\_\_\_\_ x 2 pts. = \_\_\_\_\_

$\leq 26^\circ$  = 1 pt.

Each degree  $< 26^\circ$  \_\_\_\_\_ x 1 pt. = \_\_\_\_\_

1 to MP  $\geq 99^\circ$  = 1 pt. **1**

Each degree  $> 99^\circ$  **13** x 1 pt. = **13**

**Total** = **21**

**OTHER**      (See Instructions)

Supernumerary teeth	_____ x 1 pt. = _____
Ankylosis of perm. teeth	_____ x 2 pts. = _____
Anomalous morphology	_____ x 2 pts. = _____
Impaction (except 3 <sup>rd</sup> molars)	_____ x 2 pts. = _____
Midline discrepancy ( $\geq 3$ mm)	_____ @ 2 pts. = _____
Missing teeth (except 3 <sup>rd</sup> molars)	<b>3</b> x 1 pts. = <b>3</b>
Missing teeth, congenital	<b>1</b> x 2 pts. = <b>2</b>
Spacing (4 or more, per arch)	_____ x 2 pts. = _____
Spacing (Mx cent. diastema $\geq 2$ mm)	_____ @ 2 pts. = _____
Tooth transposition	_____ x 2 pts. = _____
Skeletal asymmetry (nonsurgical tx)	_____ @ 3 pts. = _____
Addl. treatment complexities	_____ x 2 pts. = _____

Identify:

**Total** = **5**

**IMPLANT SITE**

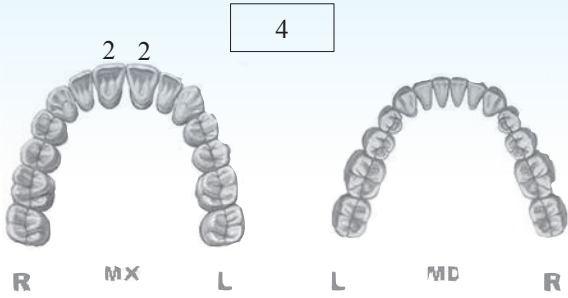
Lip line : Low (0 pt), Medium (1 pt), High (2 pts)	= _____
Gingival biotype : Low-scalloped, thick (0 pt), Medium-scalloped, medium-thick (1 pt), High-scalloped, thin (2 pts)	= _____
Shape of tooth crowns : Rectangular (0 pt), Triangular (2 pts)	= _____
Bone level at adjacent teeth : $\leq 5$ mm to contact point (0 pt), 5.5 to 6.5 mm to contact point (1 pt), $\geq 7$ mm to contact point (2 pts)	= _____
Bone anatomy of alveolar crest : H&V sufficient (0 pt), Deficient H, allow simultaneous augment (1 pt), Deficient H, require prior grafting (2 pts), Deficient V or Both H&V (3 pts)	= _____
Soft tissue anatomy : Intact (0 pt), Defective ( 2 pts)	= _____
Infection at implant site : None (0 pt), Chronic (1 pt), Acute ( 2 pts)	= _____

**Total** = **0**

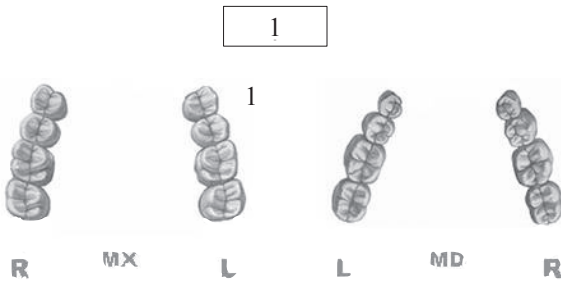
# Cast-Radiograph Evaluation

Total Score: **24**

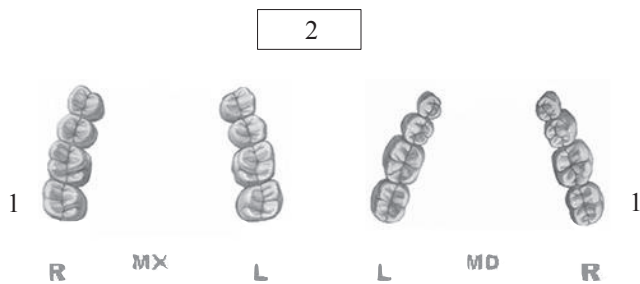
## Alignment/Rotations



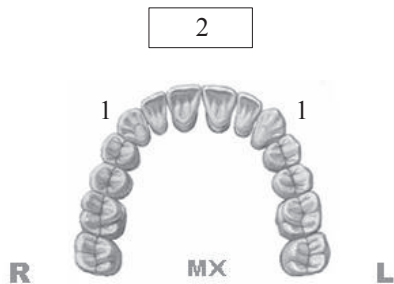
## Marginal Ridges



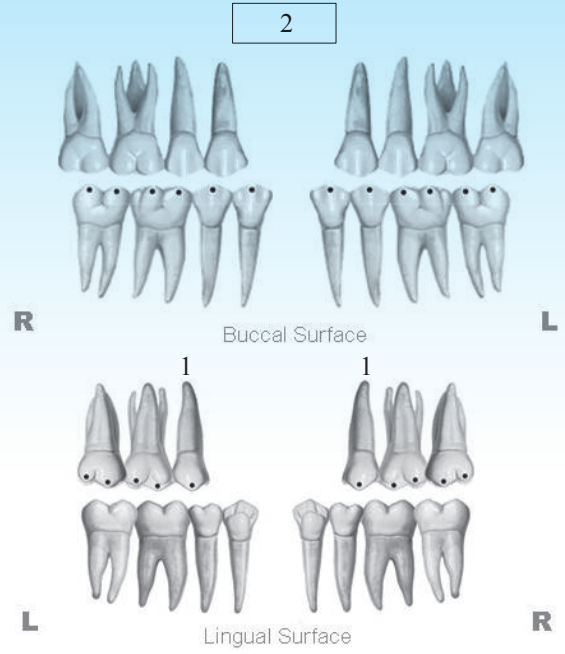
## Buccolingual Inclination



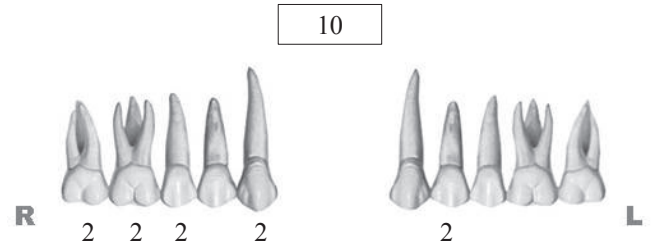
## Overjet



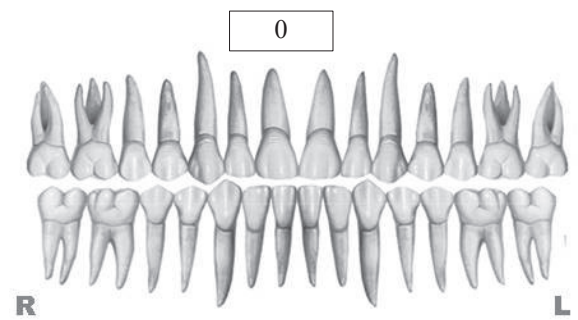
## Occlusal Contacts



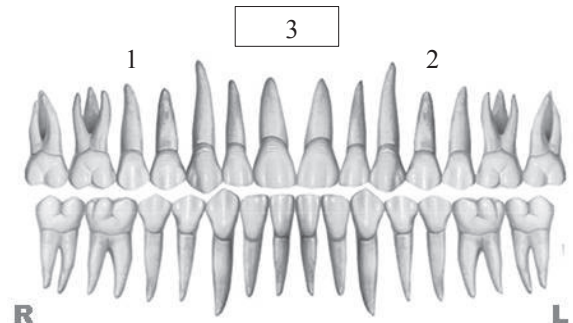
## Occlusal Relationships



## Interproximal Contacts



## Root Angulation

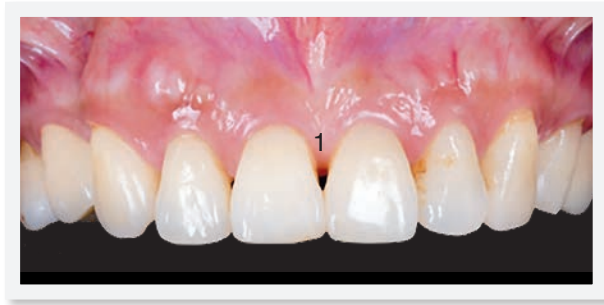
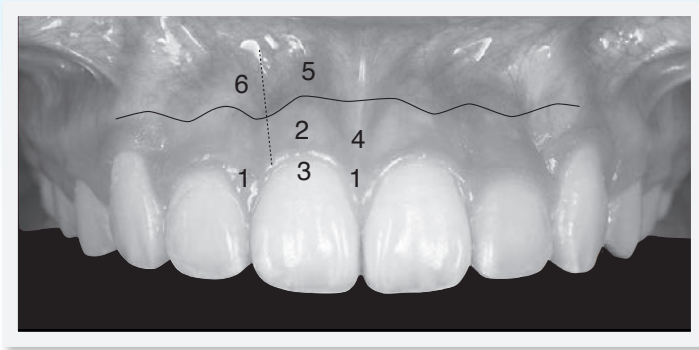


**INSTRUCTIONS:** Place score beside each deficient tooth and enter total score for each parameter in the white box. Mark extracted teeth with "X". Second molars should be in occlusion.

# IBOI Pink & White Esthetic Score

Total Score: = 3

## 1. Pink Esthetic Score

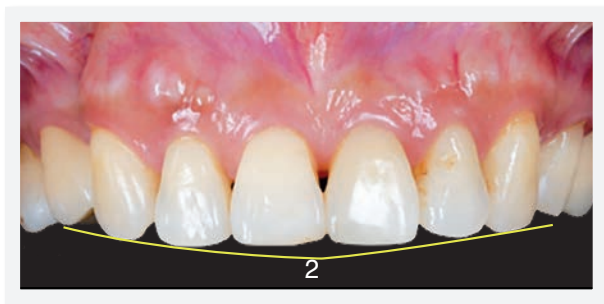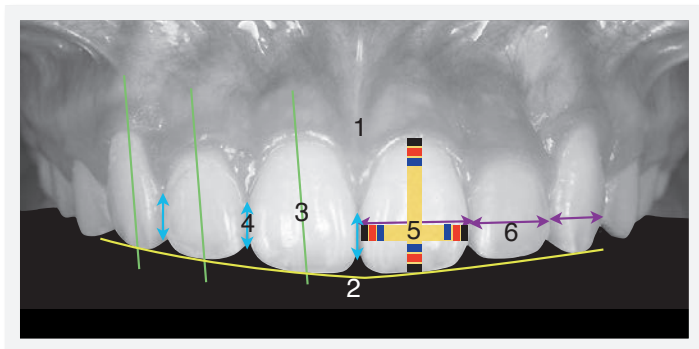


Total = 1

1. M & D Papillae	0	1	2
2. Keratinized Gingiva	0	1	2
3. Curvature of Gingival Margin	0	1	2
4. Level of Gingival Margin	0	1	2
5. Root Convexity ( Torque )	0	1	2
6. Scar Formation	0	1	2

1. M & D Papillae	0	1	2
2. Keratinized Gingiva	0	1	2
3. Curvature of Gingival Margin	0	1	2
4. Level of Gingival Margin	0	1	2
5. Root Convexity (Torque)	0	1	2
6. Scar Formation	0	1	2

## 2. White Esthetic Score ( for Micro-esthetics )



Total = 2

1. Tooth Form	0	1	2
2. Mesial & Distal Outline	0	1	2
3. Crown Margin	0	1	2
4. Translucency ( Incisal third )	0	1	2
5. Hue & Value ( Middle third )	0	1	2
6. Tooth Proportion	0	1	2

1. Midline	0	1	2
2. Incisor Curve	0	1	2
3. Axial Inclination ( 5°, 8°, 10° )	0	1	2
4. Contact Area ( 50%, 40%, 30% )	0	1	2
5. Tooth Proportion ( 1:0.8 )	0	1	2
6. Tooth to Tooth Proportion	0	1	2

# 貝多芬牙醫視訊百科全書

Learn anytime,  
anywhere!



## 矯正研習包

由矯正名師張慧男醫師深入淺出的生動教學，讓您在短短78堂課的課程裡，完全掌握結合最新的矯正系統Damon以及矯正骨釘OBS的實用治療秘訣。無論是矯正新手或是想要持續進修的專科醫師都不可錯過！

- 矯正基礎 Damon Q
- 矯正進階 Advanced
- 矯正植體 OrthoBoneScrew

- 矯正精修 Finishing I (Topic 01-11)
- 矯正精修 Finishing II (Topic 12-22)
- 矯正精修 Finishing III (Topic 23-33)
- 矯正精修 Finishing IV (Topic 34-44)
- 矯正精修 Finishing V (Topic 45-55) **New**



## 植牙精進包

由矯正名師張慧男醫師主持，邀集國內外植牙講師，整理當前植牙的熱門主題，透過55堂課的專題演講和個案分析，讓您在植牙學習之路上不斷精進！

- 植牙論壇 Implant Forum I (Topic 01-11)
- 植牙論壇 Implant Forum II (Topic 12-22)
- 植牙論壇 Implant Forum III (Topic 23-33)
- 植牙論壇 Implant Forum IV (Topic 34-44)
- 植牙論壇 Implant Forum V (Topic 45-55) **New**



## awesome packages

## 診所行銷包

還在苦於不知如何利用科技行銷診所特色？推廣專業服務？透過系統化的助理訓練課程，囊括「矯正」、「植牙」、「兒童牙科」結合三領域的**案例解說**和**衛教示範**，讓您輕鬆運用iPad科技行銷您的專業診所！

- 衛教示範病例 E-consultation: Ortho, Pedo, Implant
- 助理訓練 Assistant



E化病例衛教電子書

終身會員

## 享好康

凡2008年起  
曾購買任一系列貝多芬視訊課程  
皆可享有右側優惠

- **免費更新**課程，包含 E-Consultation矯正衛教篇皆有全新有聲檔可供免費更新。  
(不含精修VF、植牙論壇VIF)
- **無聲升有聲**：凡單購無聲視訊課程，皆可付些微差額，升級最新有聲課程。
- 免費安裝矯正植牙國際 **電子期刊**
- **iOS系統健檢**

請洽 **金牛頓** (03)573-5676

<http://www.orthobonescrew.com>

Newton's A

新竹市建中一路25號2樓

B-201209 1020-0000

# RENEW

# 好評推薦

## 買

限時

50% off

### Copper NiTi Wire x10 盒 感溫鎳鈦合金線 (定價：\$2,400元/盒)

感溫鎳鈦合金線的“熱”反應特質可以改變矯正線的特性，提供持續穩定的微力量，適用於矯正初期 Leveling & Aligning。病人體驗人性化舒適矯正的同時，醫師可更精準有效率的掌控牙齒移動。

“Copper Ni-Ti. has received tremendous attention since its introduction in 1997. It is a quaternary (nickel, titanium, copper and chromium) alloy with distinct advantages over traditional nickel titanium alloys. It can consistently generate a more constant force over longer activation periods than nickel titanium alloys. It is more resistant to permanent deformation than nickel titanium wire and exhibits better springback”.

by M. Alan Bagden, D.M.D. Springfield, Virginia

Clinical Impressions/VOL.9, No.1, 2000




## 送

### Low Friction TMA x5 盒 低磨擦鈦鉬合金線 (定價：\$4,800元/盒) (非 Low Friction Colored TMA)

矯正線表面經過特殊處理，大幅降低約 70% 的摩擦力，幾乎接近與 Stainless Steel 相同摩擦力，但線的硬度僅只有 SS 的一半。適用於矯正中期 Torque 調整以及細節微調。

“Titanium molybdenum alloy (TMA) wire has demonstrated superior clinical properties including high springback, low and intermediate force levels, good formability, and weldability, Unlike other common archwires, it contains no nickel, and thus is better tolerated by many patients”.

JCO/ VOLUME 29



總代理 湧傑 YONG CHIEH 北區：02-27788315 中區：04-23058915 南區：07-2260030

- 衛署醫器輸壹字第006857號 · 010513號 · 不得更換產品內容及顏色
- 本優惠專案僅適用於牙醫診所 · 本公司保留贈品更換之權利 · 本公司保留更改及終止活動辦法與條款之權利
- 本文宣品僅供牙科診所及牙醫師參考，禁止張貼或擺置於公眾可瀏覽及取閱之處



自2014.09.26 起至2014.12.25止

Axis | SybronEndo



- K-Files #06~#40 定價 \$340/盒
- Triple-Flex #08~#40 定價 \$340/盒
- Reamers #06~#40 定價 \$340/盒
- K-Flex #06~#40 定價 \$400/盒
- Hedstrom #15~#40 定價 \$480/盒
- Pathfinder 21mm、25mm 定價 \$550/盒

## 購買 100 盒 Hand Files

### Touch'n Heat 馬來膠熱融機 1 台



《定價34,000》

總代理 湧傑 YONG CHIEH 訂購專線：北區 (02)2778-8315 · 中區 (04)2305-8915 · 南區 (07)226-0030

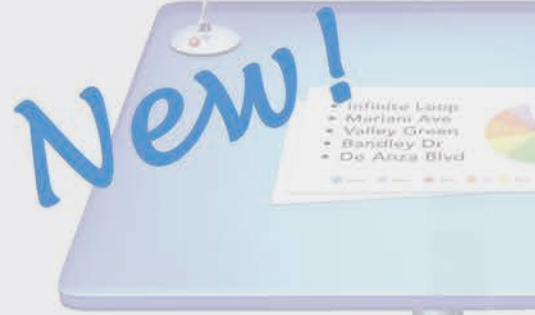\* 本文宣品僅供牙科診所及牙醫師參考，禁止張貼或擺置於公眾可瀏覽及取閱之處 \* 本優惠專案僅適用於牙醫診所

\* 本公司保留贈品更換之權利 \* 本公司保留更改及終止活動辦法與條款之權利

\* 衛署醫器輸字第010982號 \* 衛署醫器輸壹字第009148號



# 最新版 Keynote Workshop 高效簡報學習法 系列課程



輕鬆製作簡報

繪圖簡報達人



## K1 簡報聖經 2015.07.09

看過太多充滿複雜文字和圖表的幻燈片，聽過就忘了的演講嗎？這堂課將教您如何製作目眩神迷、印象深刻的簡報。透過小班教學，貼身指導，讓您在八小時裡輕鬆掌握簡報技巧。


學習重點：1. 操作入門 2. 演講常見十大謬誤 3. 資料視覺化技巧



## K2 Dr.Kokich 令人屏息的十大演講秘訣 2015.08.06

這堂課將為各位介紹世界牙醫界的天王講師 Dr. Kokich 的十大演講秘訣，讓您在進階的課程中更加掌握演講設計的關鍵原則，不但讓您知其然，更知其所以然！

學習重點：1. Dr. Kokich 十大演講秘訣 2. 準備演講九步驟 3. 多媒體剪輯



## K3 賈伯斯令人目眩神迷的五項演講技巧 2015.09.03

這堂課將為大家逐步解析跨界演講大師賈伯斯是如何說出打動人心、價值數十億美金的關鍵故事。透過逐步的分析拆解，要讓您也可以成為獨具魅力的演講人。

學習重點：1. 賈伯斯五項演講技巧 2. 幻燈片設計概念 3. 幻燈片修改應用



講師  
Dr. Rungsi Thavarungkul

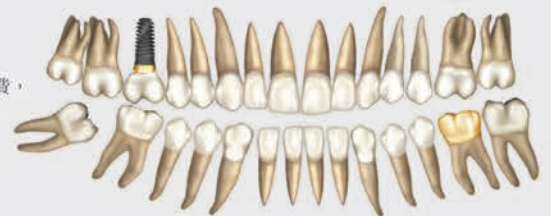
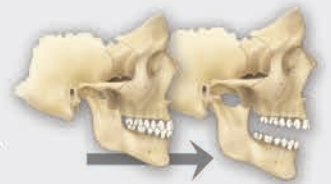## K4 K5 K6 精修繪圖及動畫技巧 2014.12.05-07 2015.11.28-30 35,000元

- 世界第一堂最完整的最新版 Keynote 6 課程。
- 在 Keynote 內繪製插圖，並運用動畫效果完美呈現。
- 利用 Keynote 創造複雜的構件。
- 完美整合 Keynote 實用技巧及牙科診間運用。

報名2014 K456 課程即 贈送 2013 及 2014 課程視訊 (價值 40,000元)。

備註：

1. 限額 25 名，以繳費順序為依據。
2. 舊生重溫價 9,000 元，限額 6 名。
3. 若取消報名，10/23 前退款將扣除 10% 行政手續費，10/24 後扣除 30% 行政手續費。



**49折!**  
Keynote  
高效學習寶典

~~93,000~~  
46,000元

本寶典包含：

- (1) K1-K3 (18,000元)
- (2) K4-K6 (35,000元)
- (3) 2013、2014 課程視訊 (40,000元)

備註：

- (1) 課程當日之前結清款項才能享有本優惠。
- (2) 舊生報名K1-K3須繳500元訂金/堂，課程日退還。
- (3) 若取消報名，適用下述K4-6退款說明。

報名專線：03-5735676

上課地點：金牛頓藝術科技  
新竹市建中一路25號2樓

匯款帳號：

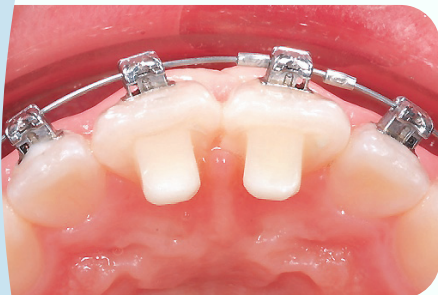- 銀行代碼：815 日盛銀行 光復分行
- 匯款帳號：109-25203060-000
- 戶名：金牛頓藝術科技股份有限公司

**Newton's A**  
金牛頓藝術科技

# Bite Turbo 2.0版

全新登場

## 加長版 BT



由張慧男醫師親自研發的加長版 BT，讓您在短時間內，解決各種深咬及較大的水平差距(OJ)，是矯正不可或缺的工具之一。

## Bite Turbo 2.0 超值組合包

包含：

手柄 x1

BT頭 x6

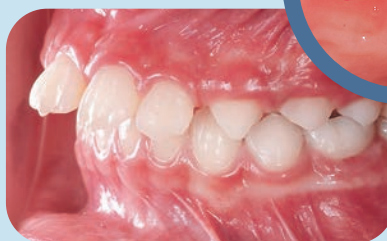BT頭 加長版 x6

Button x6

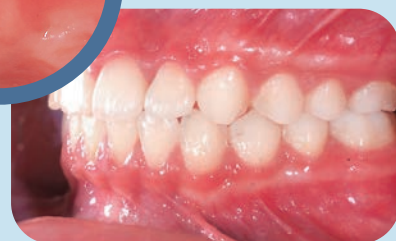## 經典 BT 使用範例

一個輕巧 BT，  
輕鬆改善嚴重的深咬，  
及水平差距(OJ)問題。

使用前



使用後



消毒方式：化學藥水浸泡消毒  
代理商：金牛頓藝術科技股份有限公司  
電話：+886-3-5735676  
地址：新竹市建中一路25號2樓

**Newton's A**  
<http://orthobonescrew.com>

## Feedback From Beethoven International Workshop in June



It had been a long time since a lecturer left me astonished, and Dr. Chris Chang did it. In his course he taught us everything he knows without holding back, from start to finish. By combining knowledge and clinical skills, he knows how to make the course a great learning experience.

I now have learnt a different way to diagnose and treat class II and Class III patients.

I want to thank Dr. Chang, his wife and the wonderful staff at the clinic and the people at Newton's A for taking such a good care of us.

The course is a must in every orthodontist office.

I think the course can be improved by having more lecture time, in topics related to case failures, and unexpected problems during treatment.

*Dr. Chris Chang thank you for an outstanding course.*



*Dr. David Nissan*

Professor Universidad Tecnológica de México  
Private Practice (México)



*Dear Dr. Chang,*

I want to thank you for the recent course at your office and for having opened your practice so we can see how the concepts can be achieved.

This course is an excellent way to arm oneself with great tools and tips to improve our daily practice in Orthodontics, helping us make the patient's life happier (*and ours as well*). I want to highlight the simple and humble way of teaching in this course, and the very kind and thoughtful attentions to us.



*Dr. Alvaro Marti*



When I stumbled on Dr. Chris Chang's published articles sometime ago, I knew it was something I had been looking for to elevate my orthodontic practice. I subsequently took his course, Beethoven International Orthodontic Workshop, to witness firsthand how he treated difficult malocclusion with ease, with live patients and a full/busy schedule. Dr. Chang's technique is absolutely amazing and cutting-edge that I will use to transform my orthodontic practice. I strongly feel that Dr. Chang's orthodontic treatment strategy should be in the

core curriculum of any orthodontic residency. Anybody who wants to be a top-tiered orthodontist MUST incorporate Dr. Chris Chang's technique into his/her practice.

I admire Dr. Chang for his love for orthodontics and his generosity to share various aspects of his personal life. At the end of course, Dr. Chang gave two books for each of the participants; the books were not about orthodontics. The books were to share his core belief that we professionally need to keep learning, keep innovating, and do what we love to do in order to be the best we can be. This course, to me, was not only about orthodontics. Dr. Chang and his wife's kindness, generosity, and their love for a fuller life is contagious.

 *Robert J Chen*

DMD, MS

*New Age Braces, Specialist in Orthodontics and Dentofacial Orthopedics*



I personally benefited from the unique opportunity to interact with Dr. Chang and observe his practice at the Center.

I have been privileged to know a wonderful mentor who was prepared to share his knowledge and experience unconditionally. It also helps when the participants are highly qualified and motivated individual dentists and dental specialists of different disciplines from Australia, Brazil, Italy, Malaysia and Mexico.

One cannot help but admire the professional qualities and character of the man himself. Dr. Chang was passionate in all his undertakings from golf, music and art to dentistry. He pursued excellence uncompromisingly and yet remains humble and curious despite his many achievements with an undiminished desire to acquire new knowledge so that he can serve his patients with distinction and in keeping with the traditions of his intellectual mentor, Dr. Edward. H. Angle. He joins the pantheon of my mentors who include Professor Branemark, Dr. Patrick Henry and Dr Palo Malo.



Datin *Dr. Kamsiah Gulam Haider*

*Kuala Lumpur*

## 課程心得回饋

### 學習大師，成為大師

在學習矯正的路上，至今雖然只有短短不到四年的時間，一路走來，心中卻有著滿滿的幸福與踏實的感受。我是何其有幸，有機會在今生能向大師學習，感恩地依循著大師為後進鋪設的道路前進，才能順利地走出從未夢想過的學習成就。



有人問我是如何做到的？其實，我真的不知道自己有什麼捷徑，但只要是張醫師與高老師交待的事，我一定會確實且盡力地完成。「聽話照做」就是我前進的第一步。

第二步「守本分」：

張醫師一直提醒我們要注意細節、把基本功練好，我就告訴自己要回到課程中當助教，持續不斷地複習基本功，讓自己一直維持在教學相長的態度。

第三步「沒有慧根也要會跟」：

其實我並不是一個很聰明的學生，不過我秉持著外號「張會跟」的功力，一路從基礎班、進階班、精修班、植牙論壇，甚至是 Keynote 系列教學... 等課程，不放過每一個跟隨張醫師學習的機會，這樣的過程也著實讓我隨時保有最新的牙科資訊！

說真的，我沒有任何的規劃和技巧，只是一路跟隨張醫師的步伐往前邁進，這就是我的方法。不問太多為什麼，只有開始做，才會到達，相信我，我們大家一定都做得得到。

*Yes, we can!*



張銘珍  
馬來西亞Damon講師



Dear 張醫師、高老師、道山您們好：

很開心參加 10 月 3 日的助理訓練課程，以及下午、晚間的診所見習活動，心裡有滿滿的收穫和感動。上午的助理訓練課程讓我發現以前拍照時都沒注意到的細節，還學到一個超殺的撇步，那就是，拍前牙 overjet 特寫時，可以請病人頭往上仰。我以前都沒想到這個技巧，以致於每次拍這類特寫時，都會遇到幾乎要碰觸到病人胸部的窘境。

我還學到倒著黏下顎的 low torque 時，可以先把 gauge 剪短，這樣既不會防礙黏著，也可以留住 gauge，把它當做長軸的依據。這些收穫讓我終於意識到為何「看別人做很簡單，自己做卻不順」，原來是我沒有用心想解決辦法。

這是第三次來貝多芬見習了，第一次是升大五的暑假，第二次是上基礎班的時候，前兩次我都吸收有限，應該是沒有全心全意專注學習的關係；直到這次因為自己開始做矯正、懂點皮毛，才懂得珍惜機會。因此，跟診時不敢浪費任何一分鐘，且用心思考每個 case 的治療計劃，並針對每個張醫師的診療步驟勤做筆記。

很感謝張醫師讓我有這個機會跟診學習，還一邊指導我的 case、解答我的疑惑；也很感謝高老師的熱情照顧，還有道山對課程的幫忙及安排。回到高雄，心裡仍然興奮，迫不及待想把當天所學跟我姊分享。偶爾充電一下真好，我們要繼續追隨張老大和貝多芬的精神：「點滴改進，盡心盡力」。

謝謝！祝身體健康

吳尚恆 高雄市聯盟牙醫診所



### 一場好的演講，往往可以改變一個人的一生

「夢想」原來真的可以「實現」，我終於能夠成為張慧男醫師矯正學的「正式學生」了！

2009 年，因緣際會下聽了張老師的一場演講，進而開始加入矯正的行列；2010 年，到新竹貝多芬診所見習，更是給了我很大的啟示。張老師對專業認真的態度，甚至整個貝多芬診所及金牛頓公司的合作精神，徹底實踐了「盡心盡力，點滴改進」的理念！這種由上至下充滿幸福感的企業精神，深深感動且吸引著我！

每每上張老師的課，都讓人「如沐春風」，欣喜地不能自己。在矯正的路上，讓戰戰兢兢的我，有如看到一絲曙光，鼓起勇氣、放下雜念，堅定地跟著張老師的步伐，自信前進！

選擇跟隨張老師學習，是我最有智慧的選擇，因為張老師的課有以下四大特色：

- 一、以實際案例，帶出矯正的理論。
- 二、將困難簡單化 (Real artists simplify)。
- 三、生動有趣的演講，讓我能百分百投入學習！
- 四、搭配 Dr. Rungsi 精美的牙科插圖，讓矯正過程影像化、視覺化，使學習更印象深刻！

讓我更感恩的是，因為張老師的關係，有幸加入 USC 的 Dr. Homa 所帶領的大家庭，認識到更多優秀、為患者思量、樂於分享的台灣醫師，使我在矯正之外，更結合植牙的學習，與其他醫師一起學習與進步。向張老師看齊，終身學習，活出更好的自己！

感恩老師的啟發與教誨，必定努力做個「認真的好學生」，帶給患者更完整的治療，不忘師恩，謝謝您！

陳依虹

President, Family Care Dental in Malaysia



## 貝多芬獎學金學員心得回饋

Since I am going to start working in the coming months, it helps me greatly to learn how an efficient clinic operates, the quality of the staff is simply remarkable. In contrast to what I have been previously told, I was surprised to find out that it is actually possible to use all Apple computer and software in the clinic.

This 3 days program gave me a really strong boost, I was 99% sure I want to become an orthodontist, now the number is 120%!

洪翊銘

Tom Hung Universidad CEU Cardenal Herrera



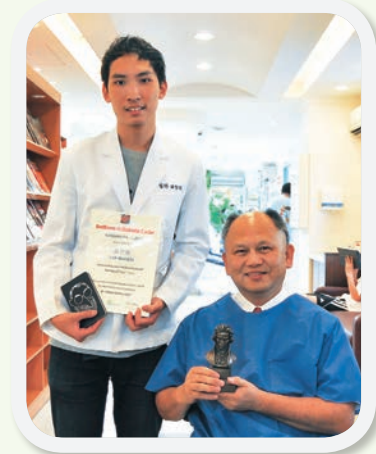除了矯正和植牙等牙科知識外，張醫師的經營方式和診所的設計與管理對我來說是最大的收穫！

「 Always be prepared. 」是我在課堂上印象最深刻的一點，隨時做好準備才不會讓機會溜走，我想這也是張醫師之所以能如此成功的原因之一吧。另外貝多芬集團的規模和營運模式也是我前所未見的，在這兩天的參觀之後，瞭解到這的每件事都是經過完善的計劃以及超有效率的 SOP 來達成的，這樣的管理模式很值得我們學習。

這次能夠加入貝多芬獎學金計劃，真的是上輩子燒了好香。

學到超級多實用的知識和啟發，還有很多觀念上的改變，不僅止於矯正方面，更重要的是在經營和學習的態度上讓我有許多反思。謝謝貝多芬集團提供如此好的機會給我們，讓我在成為牙醫的道路上更有方向和動力。

希望能保有此時此刻的熱情和夢想一直前進！



曲智煥 台北醫學大學



在這裡能見到許多之前未曾見過甚至是想像過的。診所經營的架構，並將要處理的事情化繁為簡，增進效率。但其中最重要的一點，是學習到張醫師把每一件事情、每一個 case **用心做好的態度**，不僅是對病患的負責與口碑保證、更是**對自己的期許與交代**！

很開心可以來到這裡！張醫師真的是很成功又厲害的醫師，不止是醫師，更是藝術家、企業家與教育家。

徐筱涵 台北醫學大學

在這三天兩夜中，越是投入張醫師設計的課程和活動，越能體會到張醫師的用心。深深覺得自己是**何其榮幸能得到這個機會**。無論是簡報的報告技巧、診所見實習以及其他豐富的內容，都讓我在這個暑假得到了滿滿的收穫。最後張醫師也以「**點滴改進，盡心盡力**」勉勵我們，希望我們能持續進步。

十分感謝貝多芬獎學金讓我有機會參加這次的活動，也感謝張醫師的用心及投入。

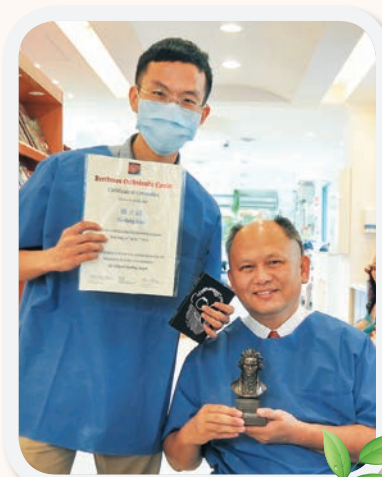再次謝謝張醫師及貝多芬齒顎矯正中心！

陳昱仰 台北醫學大學

*A single journey can change a course of life.*

我在這次的貝多芬獎學金活動中獲益良多。張醫師點出演講的成功要訣，其中第一項就是「**Always be prepared.**」。在見習貝多芬矯正診所過後，對於這句話得到更深的印證。張醫師對於醫療的每一個環節都一絲不苟。用最簡潔有效的方式記錄病例，而且對於細節非常注重。他跟我們說：「**矯正沒有大技巧，只有小技巧。如果每一個小技巧都做不好，那矯正就不用做了！**」

**真的非常幸運能入取這次的貝多芬獎學金見習**。如果學弟妹問我貝多芬講學金課程如何。我一定會大大推薦，然後比個讚！因為**讀萬卷書不如行百里路**。實際來外面看看別人怎麼做，想法可以更加開闊。而且張慧男醫師又是矯正的一代宗師，能在張醫師的診所見習絕對收穫豐富！



廖立揚 台北醫學大學



李米思 台北醫學大學

張醫師以及其團隊的無私分享這裡所擁有的寶貴資源，無論是矯正學方面的知識、高效率的團隊分工合作、診所經營的技巧或是新穎的電腦課程，都可以在活動中一窺究竟。珍貴的點點滴滴，都大方的和我們分享，讓我們在學習矯正的路途中，有了全新的感受。

在三天兩夜的活動中，貝多芬的用心，流暢的行程和充實的內容，讓活動的每個環節都感受的出來經過細心的安排，讓我的暑假又多了一個可以分享的故事。真的很開心能參加這次的見習活動，也鼓勵學弟妹們一定不要錯過這樣的機會！謝謝貝多芬獎學金。



陳薇宇 高雄醫學大學

結合科技與醫療，貝多芬矯正中心在縝密的規劃、精密的流程中增進效益。在張醫師對美的極致要求下，不只是在治療過程，連對於病例的整理，資料的收集都是一種美與科技的結合。讓對於執業環境感到陌生的我們，也體會到張醫師的深厚經驗，並了解到輔助科技以及助理訓練的魔力。

在這幾天行程中，最令我印象深刻的便是張醫師的演講。我感到非常榮幸能從張醫師、以及其他醫師的演講中，化繁為簡地了解到矯正和植牙的互相搭配，牙齦的修補技術、以及上顎竇的補骨技術。這些相當複雜的知識竟然能化為簡潔且重點明確的Keynote，讓我深感佩服且覺得獲益良多。

## 大陸醫師見習心得回饋

尊敬的張博士與高老師：

很感謝您們給予的這次學習機會。雖然第一次訪問貝多芬矯正中心和金牛頓，但兩位對工作的熱誠敬業和永攀高峰深深打動了我。

透過張醫師的一個個不可思議的優秀病例，我看到了一個國際標準矯正醫療中心。

在這裡有超高的醫療技術，默契的團隊配合，高效率流程操作，更有美輪美奐的病例簡報，我震撼于此！

真的受益良多，感恩無限，深予祝福。



遼寧大連 王丹醫師

# 貝多芬青少年高爾夫邀請賽

## Beethoven Junior Golf Invitational

# 2015



### 宗旨

秉持貝多芬齒顎矯正堅持完美與感動之創院精神，藉由高爾夫運動參與，養成健康運動的習慣，活絡人際間的互動，致力推動高爾夫運動人口倍增，回饋於社會並鼓勵具潛力之青少年選手，發展出國家或世界級驕傲。

### 參賽資格

凡愛好高爾夫球之貝多芬、金牛頓及安徒生之業餘球友均可報名，預定參加人數為160名（額滿為止）。

### 比賽日期

時間：2015年元旦(星期四)早上06:30  
地點：東方日星高爾夫俱樂部

### 配對練習賽

2014年12月31日(星期三)早上07:30開球（邀請30位）

### 報名方式

11月28日前向新竹市體育會高爾夫球委員會報名  
電話：03-5385155，傳真：03-5380951  
Email：chunhong@mail.ypu.edu.tw

免報名費，果嶺、球車、桿弟費（約2000元逕付球場櫃台）等自理。

主辦單位：貝多芬齒顎矯正中心  
協辦單位：東方日星高爾夫俱樂部、金牛頓藝術科技、安徒生兒童牙醫、彼德潘兒童青少年牙醫、金牛頓植牙中心  
承辦單位：新竹市體育會、高爾夫球委員會

### 比賽方式

採18洞同時開球（06:50AM同時開球）方式進行。

**社會組：**總桿及淨桿前三名頒發獎盃，以新新貝利賽制取淨桿前10名及BB獎另頒發獎品。

**學生組：**男、女公開A、B、C組共6組，依據各組18洞總桿成績計算，錄取各組成績前三名頒發獎狀獎勵（需優於各組桿數門檻）。

**技術獎：**遠距獎2名、近洞獎4名、2近洞獎2名、3近洞獎2名。

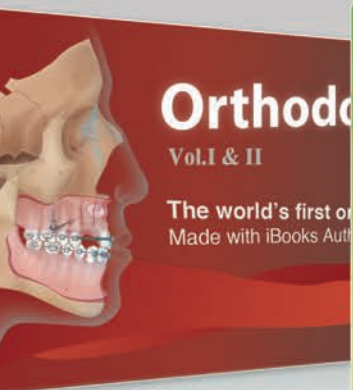
### 比賽組別



組別	年齡限制	男子	女子	冠軍	亞軍	季軍			
社會組	業餘球友	白梯	紅梯	總、淨桿前三名頒發獎盃及獎品					
學生組	年齡限制	男子	女子	1	2	3	4	5	6
公開A組	年滿15歲未滿23歲	藍梯	白梯	需79桿(含)以下始列入排名頒獎					
國中B組	年滿12歲未滿15歲	白梯	白梯	需85桿(含)以下始列入排名頒獎					
國小C組	年滿10歲未滿12歲	白梯	紅梯	需99桿(含)以下始列入排名頒獎					

註：年齡分組以比賽日期104年元月1日0時為基準日。





# BDE

## Beethoven Dental Encyclopedia

世界上最完整的牙醫百科資料庫

限時免費!



App of the Best



免費下載

本程式相容於 iPad、iPhone 和 iPod touch

## BDE – 貝多芬牙醫視訊百科

限時免費

貝多芬牙醫視訊百科提供專業的牙醫線上課程，可隨時隨地觀看最新矯正及植牙的診療案例，開創行動學習新紀元。所有課程皆由國際知名講師－張慧男醫師主講，藉由循序漸進的課程安排與豐富內容，讓您獲得深度、有趣的學習經驗。您也可以透過本程式閱讀「國際矯正植牙期刊」(International Journal of Orthodontics and Implantology) 各期完整內容，一覽矯正與植牙結合的精闢案例剖析。

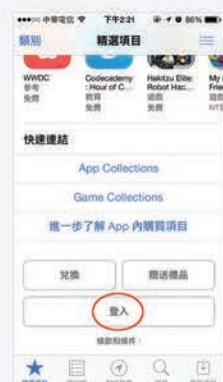Available on the App Store



## 下載說明 – Step by Step



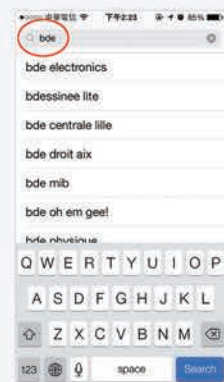
1. 點選 App Store。



2. 「登入」您的 Apple ID。



3. 或是「建立一個新的 Apple ID」。



4. 搜尋關鍵字「BDE」。



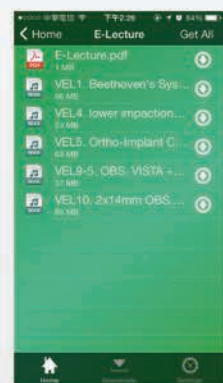
5. 點選「免費」並「安裝」。



6. 下載完成！



7. 開始享受精采課程吧，按右方箭頭即可下載！



如果您對我們的付費視訊內容、醫療產品有興趣，或對這個應用程式有任何建議，都歡迎寄信到 [app@newtonsa.com.tw](mailto:app@newtonsa.com.tw)。

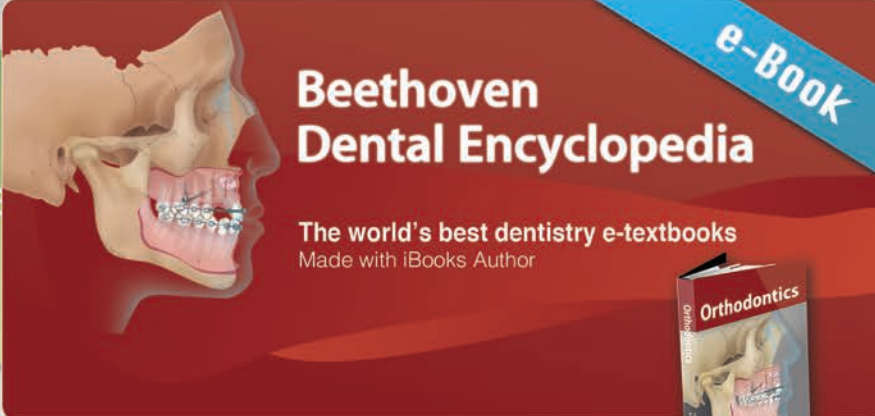
<http://www.orthobonescrew.com>  
E-mail: [app@newtonsa.com.tw](mailto:app@newtonsa.com.tw) TEL : 03-5735676



# BDE

## Beethoven Dental Encyclopedia

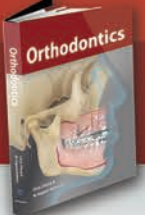
The most Completed dentist database in the world



**Beethoven Dental Encyclopedia**

The world's best dentistry e-textbooks  
Made with iBooks Author

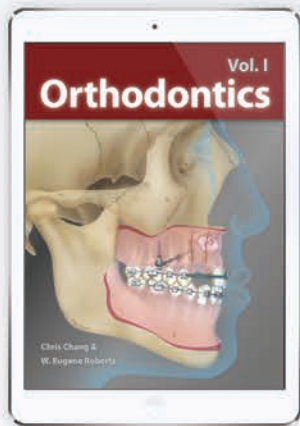
**e-Book**



Chris Chang  
DDS, PhD



e-Book of the Best



**+ BUY BOOK**

This book requires iBooks 3.0 or later and iOS 5.0 or later.

## Beethoven Dental Encyclopedia

### e-Books collection

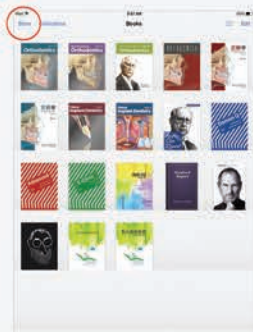
Beethoven Orthodontic and Implant Group has published the International Journal of Orthodontics and Implantology since 2007. This Journal features excellently finished case reports evaluated by objective grading systems. The Orthodontics and Implant Dentistry eBook series is a special selection of exciting cases with interactive functions and multimedia resource. Once opening this book, your understanding of dentistry will never be the same!



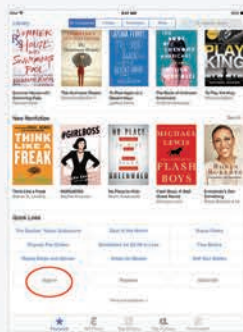
### Manual – Step by Step



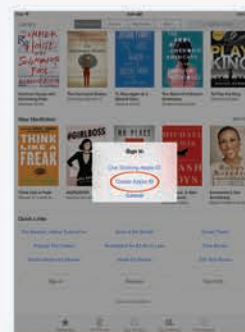
1. Launch "iBooks" app on your iPad.



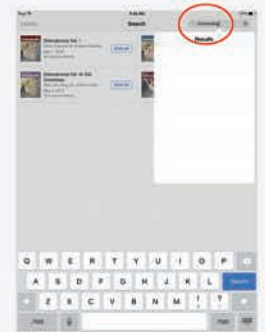
2. Click "Store."



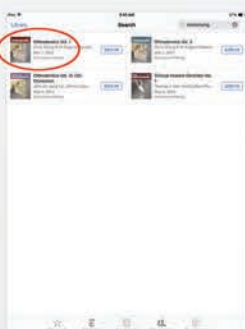3. "Sign in" with your Apple ID.



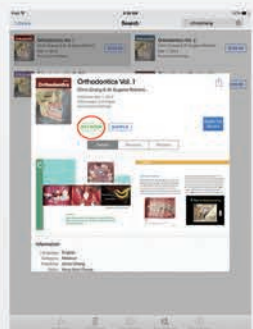4. "Create Apple ID" if you don't have one.



5. Search for "chrischang."



6. Click the book's icon.



7. Check the price and click "BUY BOOK."

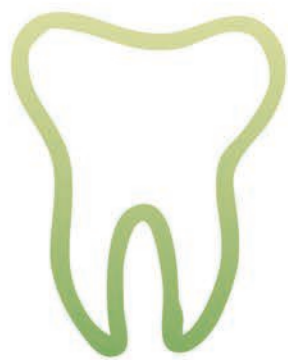

8. Once downloaded, click the book's icon to launch the e-book and enjoy the awesome content!

**If** you have any question, or are interested in our medical products, contact [app@newtonsa.com.tw](mailto:app@newtonsa.com.tw) for more information.

<http://www.orthobonescrew.com>  
E-mail: [app@newtonsa.com.tw](mailto:app@newtonsa.com.tw) TEL : +886-3-5735676

Limited Free



# BDE

## Beethoven Dental Encyclopedia

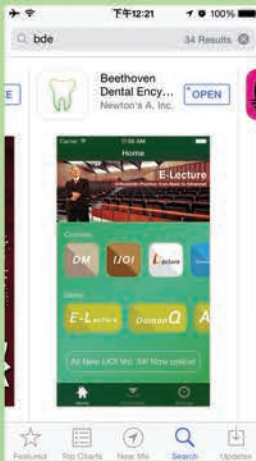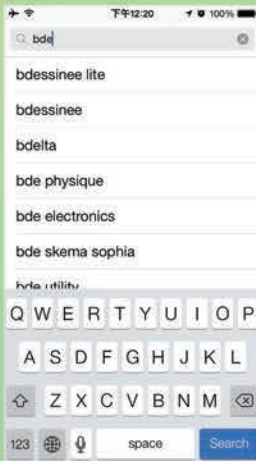
The most completed dentist database in the world

BDE offers professional orthodontic and implant video courses. Members can watch the latest dentistry treatment from the comfort of their home. All courses are instructed by Dr. Chris Chang. This step-by-step practical course will make your learning an informative and fun experience. You can also have access to International Journal of Orthodontics and Implantology from the App.

Available on the iPhone  
**App Store**

Go to <http://iaoi.pro> for more latest videos.

E-mail: [app@newtonsa.com.tw](mailto:app@newtonsa.com.tw)  
TEL : +886-3-5735676

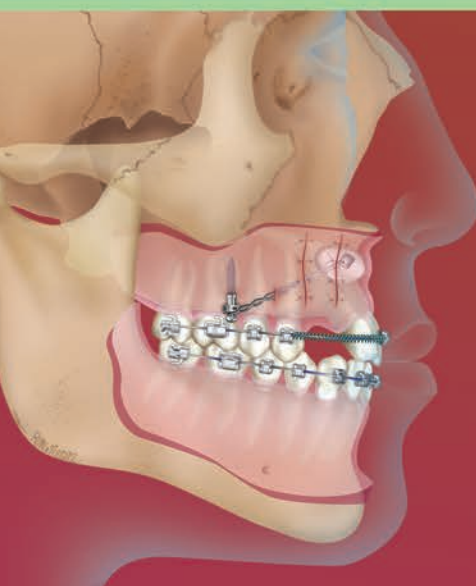


With your personal account, you can watch the courses (streaming video) online on your iPad and iPhone without occupying your storage.

You can also download the video to your iPad and iPhone. This allows you to watch your saved files anywhere anytime.

**BDE**

1. Go to App Store, search for "BDE" and install the app.
2. Launch the app and enjoy the videos!

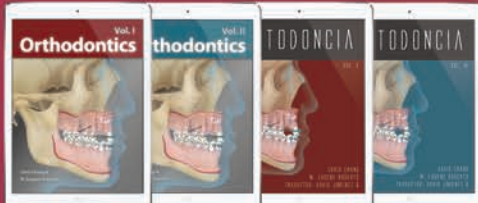

# The world's best Dental e-Textbook

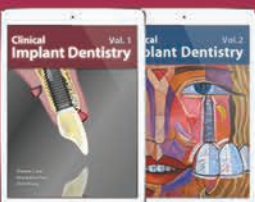
Made by iBooks Author

e-Book

Beethoven Orthodontic and Implant Group has published the International Journal of Orthodontics and Implantology since 2007. This Journal features excellently finished case reports evaluated by objective grading systems. The Orthodontics and Implant Dentistry eBook series is a special selection of exciting cases with interactive functions and multimedia resource. Once opening this book, your understanding of dentistry will never be the same!



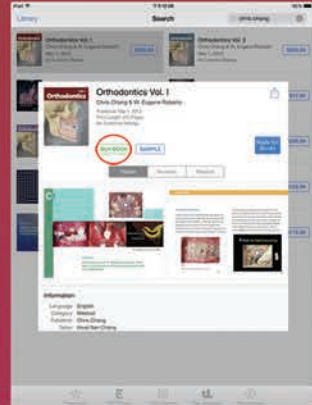
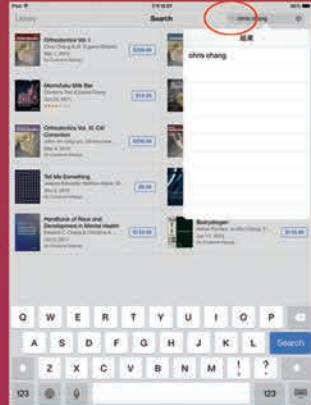
Orthodontics Series



Implant Dentistry Series

Available on the **iBookstore**

**chris chang**



1. Search for "chris chang" in iBookstore.
2. Check the price and click "BUY BOOK."

# OrthoBoneScrew



Designed and recommended  
by **Dr. Chris Chang**

Chris Chang, DDS, PhD



## Smooth Mushroom Head

For comfort & retention of  
elastic chain

## 4-way Rectangular Holes

For lever arm to solve  
impacted tooth

## Double Neck Design

Easy hygiene control  
& extra attachment

**Order information**

[info@newtonsa.com.tw](mailto:info@newtonsa.com.tw)

[www.orthobonescrew.com](http://www.orthobonescrew.com) +886-3-5735676

貝多芬 齒顎矯正中心  
**Beethoven**

**Newton's A**

B-201204 0000-0000

"From this book we can gain a detailed understanding of how to utilize this ABO system for case review and these challenging clinical cases from start to finish."

*Dr. John Jin-Jong Lin, Taipei, Taiwan*

"I'm very excited about it. I hope I can contribute to this e-book in some way."

*Dr. Tom Pitts, Reno, Nevada, USA*

"A great idea! The future of textbooks will go this way."

*Dr. Javier. Prieto, Segovia, Spain*

No other book has orthodontic information with the latest techniques in treatment that can be seen in 3D format using iBooks Author. It's by far the best ever.

*Dr. Don Drake, South Dakota, USA*

"Chris Chang's genius and inspiration challenges all of us in the profession to strive for excellence, as we see him routinely achieve the impossible."


*Dr. Ron Bellohusen, New York, USA*

This method of learning is quantum leap forward. My students at Oklahoma University will benefit greatly from Chris Chang's genius.

*Dr. Mike Steffens, Oklahoma, USA*

"Dr. Chris Chang's innovation eBook is at the cutting edge of Orthodontic Technology... very exciting!"

*Dr. Doraida Abramowitz, Florida, USA*



"Dr. Chris Chang's first interactive digital textbook is ground breaking and truly brilliant!"

*Dr. John Freeman, California, USA*

"Tremendous educational innovation by a great orthodontist, teacher and friend."

*Dr. Keyes Townsend Jr, Colorado, USA*

"I am awed by your brilliance in simplifying a complex problem."

*Dr. Jerry Watanabe, California, USA*

"Just brilliant, amazing! Thank you for the contribution."

*Dr. Errol Yim, Hawaii, USA*

"Beyond incredible! A more effective way of learning."

*Dr. James Morrish Jr, Florida, USA*



Doctors were excited about creating attracted slides and expected teeth alignment with their Mac in Introductory Keynote Workshop.

ISSN 2079-6862



9 772079 686201