

**Case Report Review: Treatment of Class III
with RME/FM and/or Skeletal Anchorage**

Dr. John Lin

**Class II and Labially Impacted Maxillary Canines
on Both Sides**

Drs. Bo Cun Kuo, Chris Chang & W. Eugene Roberts

**Implant-orthodontic Combined Treatment:
Over-erupted Molar and Scissors-bite Correction**

Drs. Bill Su, Chris Chang & W. Eugene Roberts

**Anterior Crowding with a Block-in Peg-shaped
Lateral Incisor**

Drs. Wei Lun Peng, Chris Chang & W. Eugene Roberts

IJOI

International Journal of
Orthodontics & Implantology

Vol. 26 Apr. 1, 2012



Special lecturer of the 2012 Newton's A Implant Forum, Dr. Tseng, Chuen Chyi (front center), in Dr. Chris Chang's (front right) study room together with residents of Beethoven Orthodontic and Newton's Implant center.

International Journal of Orthodontics & Implantology is an experience sharing magazine for worldwide orthodontists and Implantologists. Download it at <http://iaoi.pro>

2012

熱愛學矯正



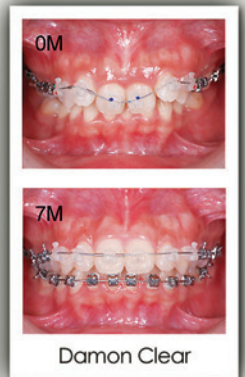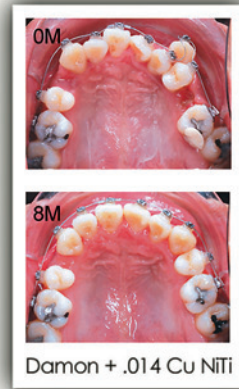張慧男 博士



新竹貝多芬齒顎矯正中心負責人
 中華民國齒顎矯正專科醫師
 美國齒顎矯正專科醫師學院院士 (ABO)
 美國印地安那普渡大學齒顎矯正研究所博士

學會開始做矯正需多久?

39小時讓您入門矯正。本課程採高效學習法及高效矯正簡報法 - Keynote，在舒適、輕鬆的環境下，學會簡單有效的矯正方法，教室與診間結合，讓您現學現用，立即熟悉各種習得的技巧，而不需太多課後複習。全程以 In-Office Training 方式，用病例帶動分析、診斷，治療計畫與療程技巧，每一步驟皆以圖片及影片教學，讓您很難錯過任何環節，更沒有聽不清楚或無法理解的可能。為提高課後自我學習及臨床印證之效率，另備有教學電子檔，供學員家中研習。我們的終極目標是：用最短時間、最輕鬆的方式，讓每位學員 - 熱愛矯正學、熱愛學矯正。



Damon矯正課程

【課程】9:00 - 12:00
 【實習】另外安排

使用最新一代矯正器 Damon Q 進行課程，歡迎舊生報名參加。

台中 高雄 台北
 (二) (四) (二)

LECTURE

LAB

1	6/5	6/7	10/2	理想入門病例+Damon Q黏著	Bonding (Damon Q) + BT
2	6/26	6/21	10/9	快速矯正療程四部曲	Ceph + Photo
3	7/3	6/28	10/23	簡捷有效的錨定系統	Damon + OrthoBoneScrew I
4	7/17	7/12	11/6	不拔牙與拔牙分析	Damon + OrthoBoneScrew II
5	7/24	7/19	11/27	Damon 診斷流程及微調	Finish Bending
6	7/31	8/2	12/4	完工檢測及報告示範	Fixed Retainer (FR)
7	8/7	8/9	12/11	維持及復發；病例示範	Presentation Demo
8	8/21	8/23	1/8/13'	矯正力學及診斷分析 (1)	DDX + Case Reports I
9	8/28	8/30	3/5	軟硬組織及診斷分析 (2)	DDX + Case Reports II
10	9/4	9/6	3/26	兒童矯正及診斷分析 (3)	DDX + Case Reports III
11	9/11	9/13	4/9	成人矯正及診斷分析 (4)	DDX + Case Reports IV

矯正植體課程

【課程】9:00 - 12:00
 【實習】13:30 - 20:00

矯正植體的操作時機、植法與實習、個案討論、臨床跟診及實作示範。

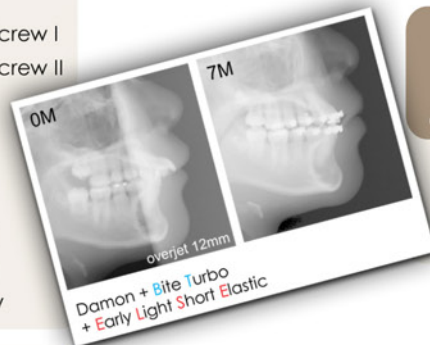
新竹(五) 9/21 (含午、晚餐)



International workshop

Keynote & management
 OrthoBoneScrew & Damon

A班 6/12-14
 B班 11/13-15



矯正進階課程

【新竹】9:00 - 12:00
 【高雄】14:00 - 17:00

以病例討論為主軸，培養學員如何正確診斷及快速排除臨床疑點，課程中亦訓練每位學員善用 Keynote。

新竹 高雄

(四) (四)

Paper Reviews

Topics & Case Demo

1	7/5	10/4	Bracket Placement	Crowding: Ext. vs. Non-ext.
2	7/26	10/11	Impacted Canines	Upper Impacted Teeth
3	9/27	11/8	Canine Substitution	Lower Impacted Teeth
4	11/1	11/22	Missing 2nd Premolar	Missing: Ant. vs. Post.
5	11/29	12/6	DI Workshop	Crossbite: Ant. vs. Post.
6	12/20	12/27	CRE Workshop	Open Bite High Angle
7	1/3/13'	1/10/13'	Excellence in Finishing (occlusion)	Deep Bite Low Angle
8	2/21	3/7	Excellence in Finishing (esthetics & perio)	Gummy Smile & Canting
9	3/21	3/28	Ortho-Perio-Restore Connection	Esthetic Finishing (Transposition)
10	4/25	4/11	Adjunct to Perio	Implant-Ortho
11	5/2	4/18	Unhappy Patient	IDT - Adult Complex

助理訓練課程

【課程】10:00 - 14:30
 【實習】15:00 - 20:00

每梯次共兩堂課程與技術操作，內含照相技術、Morph 與公關衛教之電腦資料處理；另安排一次診所見習。

新竹(五) 10/5、12 (含午、晚餐)



課程資訊

上課地點

【台北】
 恆毅資訊中心 畢卡索廳
 / 台北市復興北路號99號12樓
 (捷運南京東路站旁)

【新竹】
 金牛頓藝術科技公司
 / 新竹市建中一路25號2樓

【台中】
 中國文化大學台中教育中心
 / 台中市西屯區中港路二段
 128之2號3樓

【高雄】
 國立科學工藝博物館-南館
 / 高雄市三民區九如一路797號
 (107研討室)

報名專線

湧傑 Yong Chieh

北區

(02) 27788315

楊文君 / 邵美珍

中區

(04) 23058915 張馨云

南區

(07) 5361701 王慧靜

* 每次上課請依最新一期
 IJOI 公告為主

矯正精修課程

【課程】9:00 - 12:00

協助每位學員了解由古典到現代之文獻，進而應用於實際病例；並藉由DI及CRE讓精緻完工 (Excellent Finishing) 變成易達到的目標。

新竹(二) 精修IV 5/22 6/19 7/10 8/14 9/18 10/16 11/20 12/18
 1/15/13' 3/19 4/16

Let's make 3D Ortho Encyclopedia happen!

The recently published *3D iBooks Ortho* has become one of the most talked about orthodontic educational text even before its official launch on Apple's iBookstore. In addition to conventional text and photos, this e-book incorporated the interactive features of e-learning by adding 3D images and lectures narrated by the authors. This detailed, case-oriented collection of finished cases, judged by the respected ABO standards, is truly first of its kind. Its wide variety of cases, supplemented by clips of surgical procedures, make learning orthodontics easier than ever. One example is the treatment of impaction. This book provides simple and thorough guidelines to these otherwise complex or deemed unsolvable impaction cases. People just love to learn when it's [engaging, practical and effortless](#).

Encouraged by the positive feedback I have received about this book, I'd like to take one step further by inviting my colleagues worldwide to share your cases. I hope together we can create the first orthodontic e-encyclopedia for all. For those of you who have read this book, I hope you are inspired to contribute your cases to enrich this clinical collection. By sharing our collective learning and teaching wisdom, we can expand this playground of orthodontics to places beyond our imagination.

I once read a quote, "people can be divided into three groups, those who make things happen, those who watch things happen and those who wonder what's happening." I hope you will join me in making wonderful things happen. Let's make 3D Ortho Encyclopedia your best first step!

Chris Chang DDS, PhD, Publisher

3 Editorial

LIVE FROM THE MASTER

4 Case Report Review: Treatment of Class III with RME/FM and/or Skeletal Anchorage

IAOI CASE REPORT

20 Class II and Labially Impacted Maxillary Canines on Both Sides

36 Implant-orthodontic Combined Treatment: Over-erupted Molar and Scissors-bite Correction

56 Anterior Crowding with a Block-in Peg-shaped Lateral Incisor

FEATURE

74 The Close Eruption Technique for Trans-alveolar Impacted Lower 1st Premolar

INTERDISCIPLINARY TREATMENT

82 Restoration of the Upper and Lower Dental Arches with Monolithic Zirconia-fixed Detachable Prostheses: Clinical Report after Three Years of Use

FEEDBACK FROM THE WORLD

96 Feedback on the 3D iBooks Ortho



Examiner
Dr. W. Eugene
Roberts



Examiner
Dr. Tom Pitts



Examiner
Dr. John J. J. Lin



Consultant
Dr. Frederick J.
Regennitter



Consultant
Dr. Tucker Haltom



Consultant
Dr. J. Michael
Steffen



Consultant
Dr. Larry White



Examiner
Dr. Kwang Bum Park



Examiner
Dr. Homa Zadeh



Examiner
Dr. Fernando
Rojas-Vizcaya



Consultant
Dr. Baldwin W.
Marchack



Consultant
Dr. Stephen
Wallace



Consultant
Dr. Mark Y. K. Ou



Guest Editor
Dr. Rungsi
Thavarungkul



Editors (from left to right) :

Yu Lin Hsu, *Associate Editor*
Tzu Han Huang, *Associate Editor*
Billy Su, *Chief Editor*
Sabrina Huang, *Associate Editor*
Steven Lee, *Associate Editor*
Dennis Hsiao, *Associate Editor*
Chester Yu, *Chief Editor*
Grace Chiu, *Associate Editor*

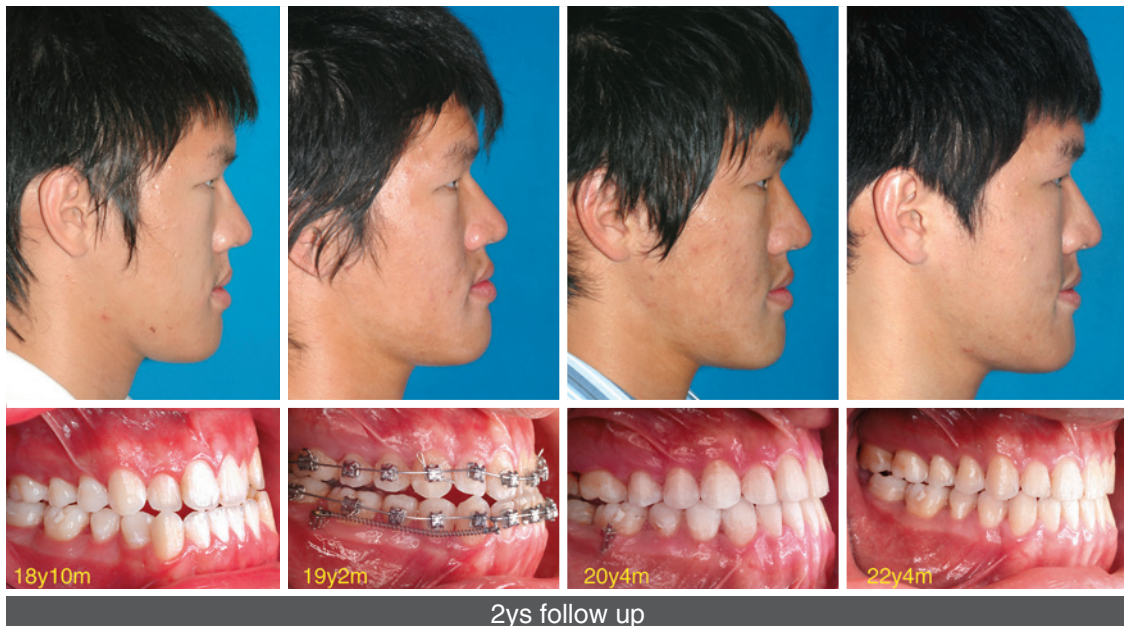


Contributors (left to right) :
Dr. Hong Po Chang, *Consultant*
Dr. Ming Guey Tseng, *Consultant*
Dr. John Lin, *Consultant*
Dr. Frank Chang, *Consultant*
Dr. Johnny Liao, *Consultant*
Dr. Chris Chang, *Publisher*

Case Report Review: Treatment of Class III with RME/FM and/or Skeletal Anchorage

A. Introduction

The author was recently invited to speak at the 2012 Damon Forum on the topic of Class III treatment. In response to many comments received during the lecture as well as throughout the conference regarding the effectiveness of the Damon system for Class III treatment, the author aims to provide a literature review of case reports on Class III treatment. Personal comments are also provided for each case. The author argues that, based on extensive personal clinical experiences, patients of easy to moderate Class III conditions present no needs for complex protocols or devices, such as RME/FM, mini-plate/FM, mini-plate/mini-plate. For severe Class III cases, early treatment with RME/FM, mini-plate/FM, mini-plate/mini-plate can provide short term therapeutic effects, but the result will be compromised by further mandibular growth. So far no appliances have been proven to have sustainable effects on stopping mandibular growth later in time. On the other hand, for adult patients with an orthognathic or acceptable mild prognathic profile, the powerful light force Damon system (Fig. 2), and the combined use of buccal shelf mini-screws (Figures 1, 3), can provide satisfactory camouflage treatment results without orthognathic surgeries.



■ Fig.1:

A severe Class III patient with an orthognathic profile. As long as the patient can accept the original profile, he can be treated with extra-alveolar buccal shelf bone screws. After this case, the author re-evaluated many cases originally treated with buccal shelf mini-screws.



Dr. John Jin-Jong Lin
MS, Marquette University
Chief Consultant of IJOI
President of TAO (2000~2002)
Author of *Creative Orthodontics*

B. Cases Report Analysis from the Literature

Summary of Class III Treatment

#	Author	Age & Diagnosis	Summary of Comments
C1	Turley 1988, 1996 (RME/FM)	Case 1 Mild CIII, CO prognathic profile. 7y3m - ?	No CR orthognathic profile, suitable for regular edgewise appliances.
		Case 2 Severe CIII sub, long term follow up. 9y1m -?	RME/FM cannot have orthopedic effect on severe prognathic Class III patients.
C2	Hong 2005 (Onplant/FM)	Severe CIII sub with prognathic profile. 11y5m - 12y5m Maxillary retrusion	Lack of long term follow up, should be a simple extraction case which need long term follow up.
C3	Hsu et al. 2008 (Alt-RAMEC/FM)	<ul style="list-style-type: none"> Severe CIII sub with prognathic profile. Skeletal Class III with maxillary deficiency 11y8m - 15y6m 	<ul style="list-style-type: none"> Maxillary protraction cannot stop late mandibular growth. Relapse already at Age 15y6m. Alt-RAMEC protocol cannot change the prognathic profile. Need long term followup, re-treatment by surgery is indicated if an orthognathic profile is desired.
C4	Cha et al. 2011 (mini-plate/FM)	A skeletal Class III with maxillary deficiency and mandibular prognathism. 8y5m - 14y ?	<ul style="list-style-type: none"> Lack of long term follow up. Without details on age. Waste of precious lower E-space.
C5	Küçükkeleş N, et al 2011 (Le Fort I+RME/FM)	Class I anterior crossbite.	Should be an easy anterior crossbite treatment, by using the E-space, no need for Le Fort I surgery.
C6	Hugo De Clerck (mini-plate/mini-plate)	Case 1 Class III with functional shift 10y - 11y8m	No beginning CR profile, should be an easy orthodontic case.
		Case 2 Class I, 10y2m - 12y1m	Creates CII problem. Over treatment to Class II, no need.
		Case 3 Severe Class III sub 11y - 15y9m	Severe one, the prognathic profile and asymmetry will relapse.
C7	Wilmes B. 2011 (Hybrid Hyrax/ Mento-plate)	Case 1 Severe CIII Sub 9y - 9y9m	Waste of lower E-space, severe CIII Sub, needs long term follow up.
		Case 2 Severe crowding case 12y - 13y8m	Can be treated with Damon by nonextraction therapy.

C1 RME/FM = Rapid Maxillary Expansion + Face Mask protraction.

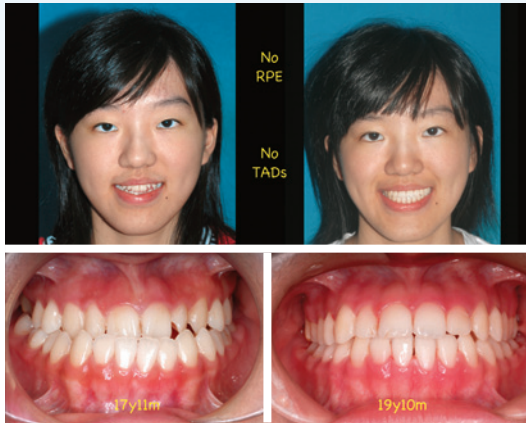C2 Onplant/FM = Palatal onplant + Face Mask protraction.

C3 Alt-RAMEC = Liou's Alternate Rapid Maxillary Expansions and Constrictions.

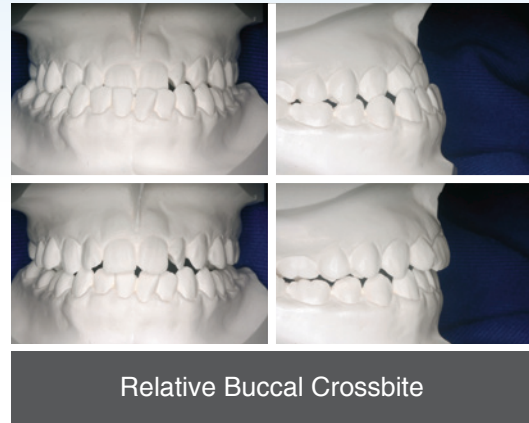
C4 Mini-plate over the zygomatic region.

C6 Mini-Plate/Mini-Plate = Hugo De Clerck's zygomatic mini-plate to lower canine region mini-plate, using Class III elastics.

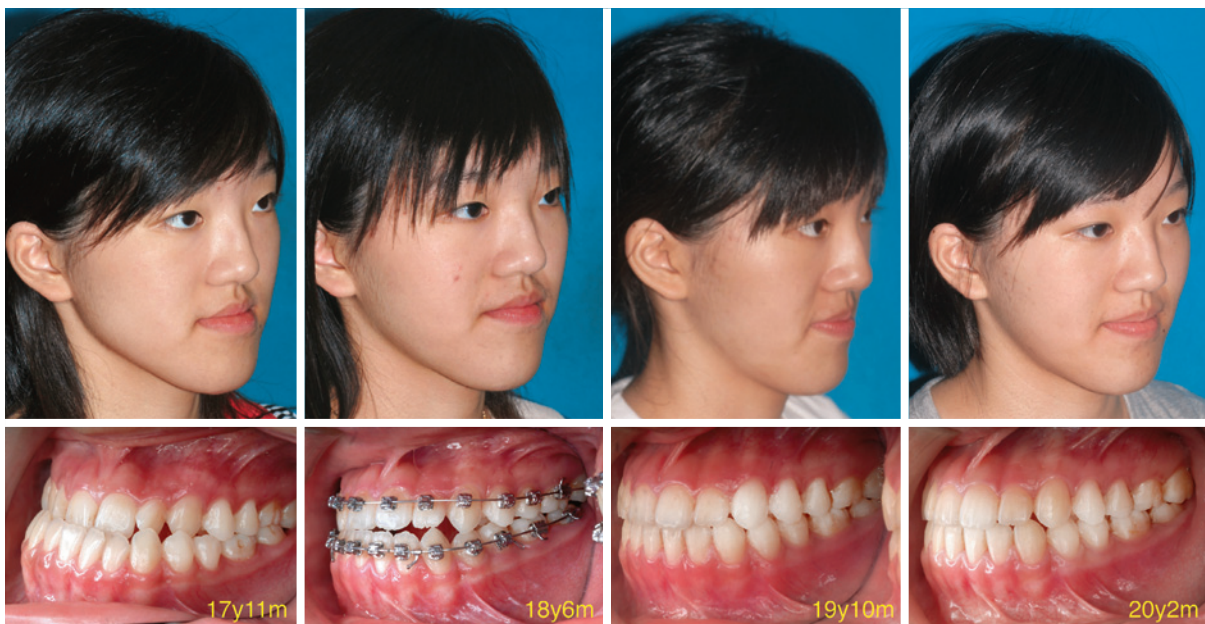C7 Hybrid Hyrax = Mini-screw reinforced Hyrax, as upper molar skeletal anchorage. Mento-plate with two extensions for Class III elastics.



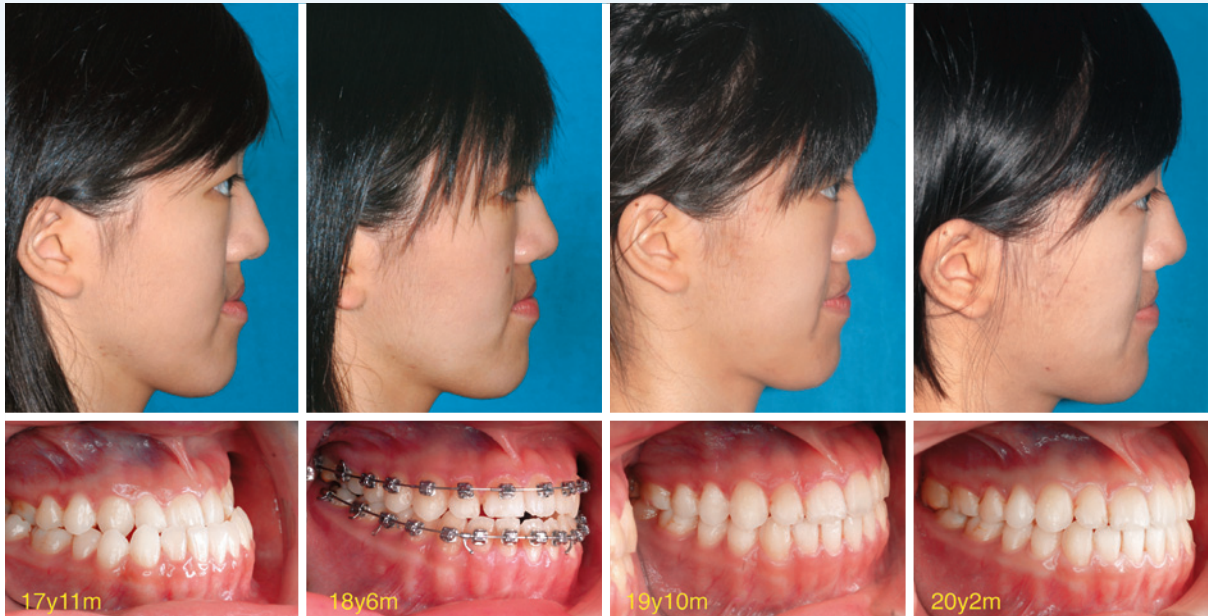■ Fig. 2A:
 Another severe Class III with orthognathic profile. The relative narrow upper arch was corrected purely in the Damon system.



■ Fig. 2B:
 By positioning the model from a CI III relationship to CI, the buccal crossbite could not be noticed. This suggests that the significant buccal crossbite can sometime be a relative buccal crossbite. As long as the anteroposterior problem is solved, the transverse buccal crossbite can also be alleviated. No RME is needed in this case.

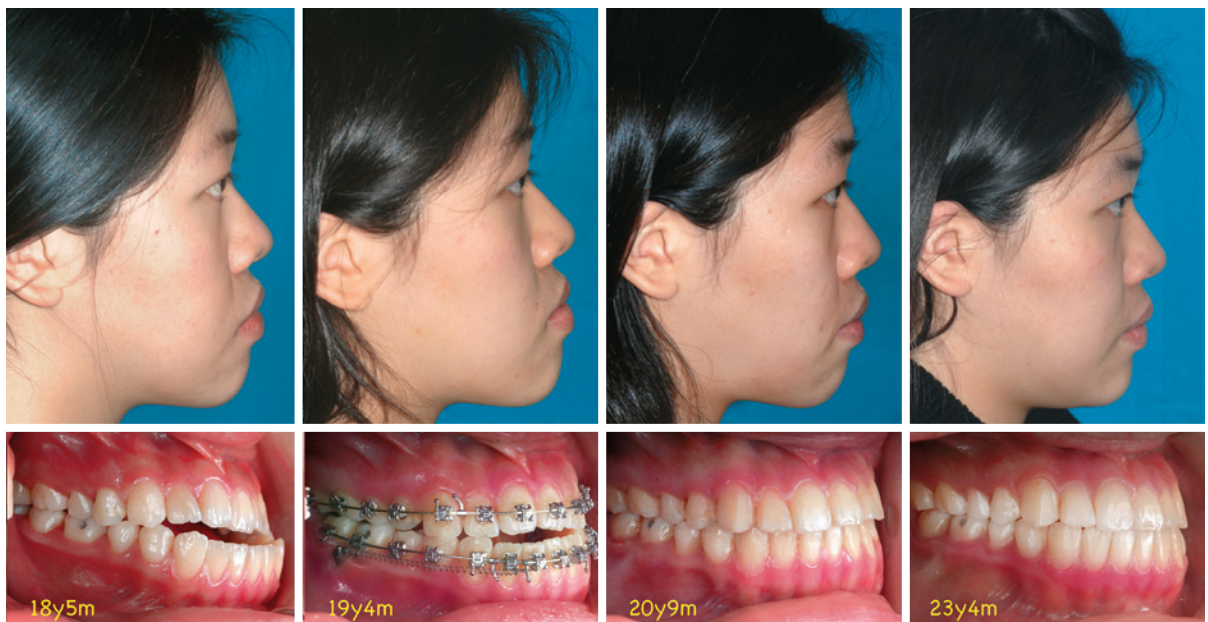

■ Fig. 2C:
 This case was treated with the Damon system only.



■ Fig. 2D:

No TADs were used in this case.



■ Fig. 3:

This severe Class III open bite was treated with the Damon system combined with buccal shelf mini-screws.

C1. Turley's Cases

<p>Orthopedic Correction of Class III Malocclusion with Palatal Expansion and Custom Protraction Headgear. Turley PK. J Clin Orthod. 1988 May;22(5):314-25.</p>	<p>Orthopedic Correction of Class III Malocclusion: Retention and Phase II Therapy. Turley PK. J Clin Orthod. 1996 Jun;30(6):313-24.</p>
---	--

Basic Information

Two Class III cases with long term follow up.

Case 1: A mild Class III case. Although the profile seems prognathic, the author suspects there might be functional shift at the beginning of treatment, contributing to a seemingly prognathic profile.

If considering the Class III malocclusion, it can be corrected easily with traditional fixed appliance.

Case 2: At the beginning, the patient has maxillary retrusion and severe prognathic mandible. In addition, the chin deviates to the right. This should be a case with very poor prognosis.

Lin's Comment

Case 1: The patient first presented as a mild Class III case. One should not be misled by the prognathic CO profile. Simple edgewise appliances can provide good long term results without using RME/FM. If the lower E-space can be maintained and used, the treatment will be much easier.

Case 2: This is a severe Class III subdivision case. After treatment, the mandible continued to grow further asymmetrically. Notice that, after phase I treatment, the chin still deviated to the right, and the profile became more prognathic. The lower dental midline also deviated to the right, coinciding with the chin deviation. The author suspects the follow up would find the chin continued to deviate to the right as most Class III asymmetry cases do. Eventually Dr. Turley had to remove the delayed exfoliated left lower 2nd deciduous molar(*with congenital missing of the left lower 2nd premolar*) to correct the relapsed anterior crossbite and lower dental midline by using the edentulous space of lower 2nd premolar.

Unfortunately in the two articles, there was no further information about the relapse of this Class III subdivision case. Although the edentulous lower 2nd premolar space was used to correct midline relapse and achieved an acceptable occlusal relationship, the profile has become more prognathic and presents asymmetric chin point. This case provided an example of failed orthopedic correction. For this type of severe Class III sub case, it is impossible to achieve the so-called orthopedic correction by RME/FM.

C2. Hong's Case

Use of onplants as stable anchorage for facemask treatment: a case report. Hong H, et al. Angle Orthod. 2005 May;75(3):453-60.

Basic information

Diagnosis: Maxillary retrusion with hypoplasia of the infraorbital region.

Only one case used the palatal onplant anchorage and a face mask.

Treatment time: 1 year of treatment, no follow up.

Diagnosis:

- (1) Buccal occlusion severe Class III relationship on the right while buccal occlusion Class II relationship on the left.
- (2) There is an impacted left upper canine. The upper midline deviated to the left due to this impacted canine. If the left upper canine were not impacted, the upper midline would have been more on the right side and the upper and lower dental midline would have been even more deviated.
- (3) The occlusal characteristics provided above indicate a severe Class III subdivision case and poor prognosis due to future growth.
- (4) Lower lip protrusion was noted, and the chin deviated to the left.

Treatment results:

Though there was no individual forward movement of the maxillary molars and minimal extrusion of the maxillary molars, the maxilla was still displaced forward.

The upper lip became more protruded after treatment which makes her bidental protrusion more prominent. Also the left upper impacted canine and both arch crowding were not aligned yet. In order to improve dental and facial profile, four bicuspid extraction will be indicated.

Lin's Comments:

- (1) The original diagnosis has over-emphasized maxillary retrusion, and neglected the severe asymmetry and maxillary arch space deficiency.
- (2) This is a severe Class III subdivision asymmetry case. The asymmetry will intensify during the active growth period. The onplant and protraction cannot correct the asymmetric growth at all.
- (3) If we consider the impacted left upper canine, no matter how far the maxillary dentition is protracted, the midline is still severely deviated.
- (4) Alternative treatment option can be, four bicuspid extraction to correct the right side Class III malocclusion. This way space can be gained for the eruption of impacted left upper canine and simplify the treatment. No onplant/FM will be needed. However, considering this was a severe Class III sub case, the chance of re-treatment is quite high.

C3. Hsu's Case

A Case Report. Doubled hinged rapid maxillary expander using alternate rapid maxillary expansions and constrictions, combined with face mask protraction, dental skeletal evaluation. Hsu MJ et al. J. Taiwan Assoc Orthod 20(2):42-53, 2008.

Basic Information

Diagnosis: 11y8m - 15y6m

Skeletal Class III with maxillary deficiency, cleft lip and palate with maxillary hypoplasia.

Treatment:

The Alt-RAMEC/FM combined protocol is very effective in the correction of severe Class III cases. However, the follow up after 1 year and 2 months already revealed obvious relapse at the age of 15 years and 6 months.

Lin's Comments:

- (1) Dr. Eric Liou's unique Alt-RAMEC/FM method attracted a lot of attention worldwide. Orthodontists in Australia, Italy and the US have tried to repeat this method. Neither Dr. Liou's nor those following cases provided long term follow up results.
- (2) Although this is an effective way of treating severe Class III, it does not change the patient's original prognathic profile. The diagnosis has over-emphasized maxillary deficiency and neglected severe mandibular protrusion at the beginning.
- (3) At 14 years and 4 months, the profile is still prognathic. Although at 15 years and 6 months, the post treatment profile seems to be much improved, it is mainly due to postural change.
- (4) One should notice that at 15 years and 6 months, the bite already relapsed to an edge to edge relationship, and there are 2 to 3 years more before late mandibular growth completed. The occlusion will worsen in time.

C4. Cha's Case

Maxillary protraction with miniplates providing skeletal anchorage in a growing Class III patient. Cha BK, et al. Am J Orthod Dentofacial Orthop. 2011 Jan;139(1):99-112.

Basic Information

This is a female, Class III sub case, aged 8 years and 5 months, with her chin deviating to the right side. She underwent 14 months of miniplate/FM protraction with fixed appliance treatment and was in follow up for 27 months. No exact age was indicated in the final record. It is estimated the final record was taken at around 14 years old.

Lin's Comments

- (1) The protracted face has bidental protrusion. If the chief complaint was bidental protrusion, then 4 premolars extraction might be a better treatment option. This way one could use a much simpler approach without involving traumatic invasive miniplate/FM appliances.
- (2) If the patient preferred nonextraction treatment, then the lower lingual arch could be placed in the lower arch to keep the large E-space on the lower arch. After permanent dentition formed completely, the anterior crossbite could be corrected mostly by retraction of lower dentition by using the E-space. Lip protrusion on both upper and lower side could simultaneously be alleviated. Hence, there is no need for traumatic invasive mini-plate/FM treatment in this case.
- (3) The original diagnosis over-emphasized maxillary deficiency and failed to consider the original severe dental and skeletal asymmetry. Notice that, after 14 months of protraction treatment, the skeletal and dental midline was still off. 27 months after appliance removal, the skeletal and dental midline was still off and it will worsen during active growth. In this case the invasive and traumatic mini-plate / protraction treatment did not lead to a satisfactory result.

C5. Küçükkeleş's Case

Rapid maxillary expansion compared to surgery for assistance in maxillary face mask protraction. Küçükkeleş N, et al. Angle Orthod. 2011 Jan;81(1):42-49.

Basic Information

This study compared 18 cases treated by RME/FM versus 16 cases treated by incomplete Le Fort I osteotomy and RME/FM. The conclusion of this study finds that the surgically assisted FM treatment was more rapid and effective in maxillary protraction compared to the RME and FM treatment.

Lin's Comments

1. In the article the author only presented one case treated with incomplete Le Fort I + RME/FM when this female patient had a straight profile, plenty of E-space, Class I molar and anterior crossbite. This case could be corrected easily with maintaining and using the E-space later on to correct the simple anterior crossbite.

2. For this case, improper diagnosis and inappropriate invasive surgical treatment were executed. One could not help but question the treatment for the other 33 patients. This finding highlights the importance of carefully examining case reports in terms of case classification, diagnosis and long-term results.
3. The patient had been treated from Class I to Class II with a large overjet and a retrognathic profile. It means the original anterior crossbite had been mistreated and became another problem, Class II malocclusion and requires further orthodontic intervention.

C6. De Clerck's Cases

Rapid maxillary expansion compared to surgery for assistance in maxillary face mask protraction.
Küçükkeleş N, et al. Angle Orthod. 2011 Jan;81(1):42-49.

Basic Information

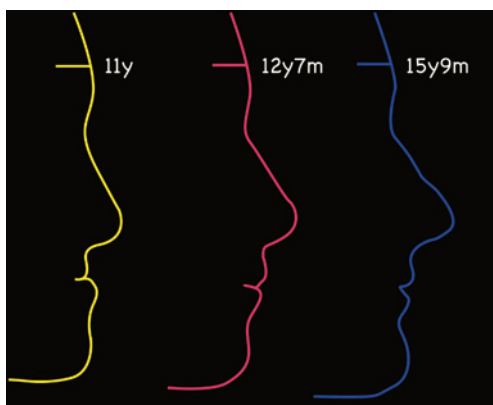- Case 1:** The patient has functional shift and presents a mild Class III relationship. One may suspect it to be an orthognathic profile if the CR is considered.
- Case 2:** very small mesial step, a borderline Class I case.
- Case 3:** indeed a very severe Class III asymmetrical case.

Lin's Comment

- Case 1:** an easy mild Class III, no need to do invasive mini-plate treatment.
- Case 2:** basically a Class I, been treated to Class II, creates an Class II overjet problem.
- Case 3:** a very severe Class III.
1. Placing upper mini-plate over infrazygomatic region is not too difficult. However, putting a mini-plate over lower canine region is a very difficult procedure. One needs to avoid damaging the developing lower canine. Overall it's a technic sensitive surgery, especially for a young patient around age 10. Four mini-plates for a young patient is a major comprehensive surgery.
 2. It's worthwhile if the procedure indeed can correct severe prognathic Class III permanently. However, the severity of case 3 significantly decreased its successful rate. The follow up records indicate the overjet

was already reduced at the age of 15 years and 9 months and future follow up is expected to find the profile to be more asymmetrical and prognathic (Fig. 4).

3. In comparison, case 1 and case 2, in the author's opinion, presented no needs for traumatic invasive surgeries. The Damon system can treat these two cases easily without surgery.
4. In this mini-plate / mini-plate protocol, the treatment result is amazing. But in this system, no RME was used. We have to reassess the need of RME in Class III treatment.



■ Fig. 4:

From the superimposition of Hugo De Clerck's case 3, at age 15y9m the mandible grew forward a lot, even though the mini-plate/mini-plate Class III elastic had protracted the maxilla a lot forward. Nothing was effective in stopping late mandibular growth. (diagram made from C6 case 3)

C7. Wilmes' Cases

Early Class III treatment with a hybrid hyrax-mentoplate combination. Wilmes B, et al. J Clin Orthod. 2011 Jan;45(1):15-21.

Basic Information

Case 1: 9y → 9y9m

This severe Class III subdivision case did not provide complete clinical records with the front facial photo missing.. The patient presented with plenty of lower E-space. In the author's view, there is no need to perform an invasive early treatment. Simply by maintaining the E-space, one can correct the anterior crossbite in a much easier way later.

Case 2: 12y → 13y8m

This is a severe crowding case. Protraction of maxilla is not urgent.

Lin's Comment

1. The facial asymmetry of case 1 worsened after the treatment. Since the patient was just 9 years and 9 months old, the asymmetric growth is unavoidable and therefore makes the treatment result unsustainable. The author prefers to maintain the E-space, after full permanent dentition is complete, and then to start correction of the anterior crossbite by using the E-space. One should carefully monitor the asymmetric growth and re-evaluate in follow up.
2. Case 2 is a severe crowding case. An alternative treatment option is to use the Damon system to align and gain space for the impacted upper right and lower right 2nd premolars to erupt. After the Hybrid-Hyrax / mentoplate treatment, the upper arch became too forward. Protraction of maxillary dentition cannot solve the crowding. For severe crowding cases, one should avoid too much upper anterior protraction. After maxillary protraction treatment, extraction is indicated.

C. Problem of Studies of Class III Treatment

- (1) Mis-diagnosis: inaccurate diagnosis of the malocclusion often leads to difficult and unnecessary treatment for easy Class I cases. (C5, C6)
- (2) Lack of long term follow up: many cases noted in the review presented incomplete records, such as missing detailed age information and long term follow up. For severe Class III, short term early treatment may only provide a temporarily satisfactory but unsustainable result. The evaluation of the treatment effectiveness cannot be made without data from long term follow up. (C2, C3, C4, C5, C6, C7)
- (3) Waste of precious E-space: for Class III patients with lower E-space, if maintained properly, after permanent dentition is reached, it can be used for retraction of lower dentition, and correction of anterior crossbite. The less protrusive upper incisors can also reduce lower lip protrusion. (C1, C4, C7)
- (4) Loose definition of maxillary retrusion: classification of malocclusion is often misguided by a prognathic CO profile, without careful examination of the patient's CR profile. (C1, C2, C3, C4, C5, C6, C7)
- (5) False assumption of a normalized post treatment growth: it is often assumed that growth will be normalized after the protraction of maxillary dentition or skeletal protraction. (C1, C2, C3, C4, C5, C6, C7)
- (6) Questionable effectiveness of appliances for stopping late mandibular growth: no long term clinical evidence has proven the effectiveness of appliances for stopping the late mandibular growth (C1, C2, C3, C4, C5, C6, C7)

D. Conclusion

1. RME/FM is an effective protocol to treat Class III malocclusion, but not too many Class III malocclusion cases require this complex treatment protocol.
2. Patients now have simpler and less painful treatment options, other than RPE, and similar extra-oral appliances.
3. Early treatment cannot prevent relapse due to late mandibular growth.
4. For severe Class III patients with a prognathic CR profile, regardless any intra or extra-oral appliances used, the prognathic profile will not change. Meanwhile, it tends to worsen due to late mandibular growth. If a prognathic profile is acceptable, Damon system can be considered as a simple and effective option with its MEAW-like effect.
5. The Damon system is also effective for young, moderate Class III patients with a good profile..
6. For severe Class III adult patients with a good orthognathic profile, the Damon system alone can achieve a satisfactory camouflage result. For severe Class III open bite patients, the combined use of the Damon system and miniscrews have proven to be a powerful solution in the author's experience (Fig. 3).
7. There is no doubt that the use of mini-plate/mini-plate is a more effective way to orthopedically protract the maxilla forward, compared with RME/FM.
8. The biggest problem for Class III studies, is the lack of precise definition of maxillary retrusion. The criteria of deficient maxilla or retrusive maxilla are often subjective and inconsistent. Hence, the conclusions generated from these studies are often questionable.
9. Many of the studies on FM / RME, or mini-plate cases, have put excessive emphasis on the protraction of the maxilla, and neglected the important diagnosis of the original prognathic mandible, and the initial problems of asymmetric growth.

Special Thanks to

Tzu-Han Huang's English editing.



中華民國齒顎矯正學會

10656 台北市大安區復興南路一段352號11樓之3
Tel: 02-2702-5499

3rd WIOC TADs Review

主 題 3rd WIOC TADs Review

講 師 林錦榮醫師、張慧男醫師、廖炯琳醫師、劉人文醫師、林政毅醫師

主辦單位 中華民國齒顎矯正學會

地 點 台北市青少年育樂中心六樓國際會議廳（台北市仁愛路一段17號）

日 期 101年6月10日 09:00~17:00

費 用 5月30日前 齒顎矯正學會 會員2000元 非會員2500元
5月31日後 齒顎矯正學會 會員3000元 非會員3500元

★ 本會學生會員依會員價半價優待

報名方式 1. 劃撥帳號14969234 戶名：社團法人中華民國齒顎矯正學會
2. 線上刷卡，網址<http://www.tao.org.tw/on-line-pay.jsp>。

本會授予專科醫師認證7學分，非專科醫師依「衛生署醫事人員繼續教育積分管理辦法」登錄7學分，公務人員登錄「公務人員終身學習時數」6小時。
請攜帶身份證或健保卡於上午和下午各刷卡報到乙次

課程安排

時 間	講 題	講 師
9:00 - 10:00	Interdisciplinary treatment with TADs	廖炯琳醫師
10:00 - 11:00	The Legacy of Miniscrews	張慧男醫師
15 min	Coffee break	
11:15 - 12:15	What I learned from the masters at 3 rd WIOC. Is it really "no limit" for TADs applications?	林政毅醫師
	午餐	
13:45 - 14:45	Biomechanics of TADs	劉人文醫師
15 min	Coffee break	
15:00 - 16:00	Class III TADs Tx in 3 rd WIOC	林錦榮醫師
16:00 - 17:00	Q & A (1小時)	





2012 Beethoven International Damon & OBS Workshop

OrthoBoneScrew and Damon workshop includes two half-day lectures, two half-day chair-side observation sessions, one model practice and one case discussion session.

The costs also covers local transportation, two days of food and two nights of shared accommodation(double occupancy). Airport pick up is available upon request with additional charges.

Cost: USD 1,400;

For May session, register before 4/12 discount \$200 off; before 5/12 discount \$100 off

Keynote Presentation workshop includes a total of 6.5-hours of lecture and hands-on practice, focusing on improving your professional communication skills. The workshop will use Macintosh computers and its presentation software, Keynote 09. The costs also covers one day of food and one night of shared accommodation (double occupancy).

Cost: USD 350

For May session, register before 4/12 discount \$100 off; before 5/12 discount \$ 50 off

Registration:

A 50% deposit is required to confirm registration. To make a payment by wire, please contact Ms. Rita Yeh by email,

rita@newtonsa.com.tw

or call +886-3-5735676



LECTURER: Dr. John Lin

President of the Jin-Jong Lin Orthodontic Clinic. Dr. Lin received his MS. from Marquette University and is an internationally renowned lecturer. He's also the author of

Creative Orthodontics and chief consultant to *International Journal of Orthodontics & Implantology*.

Dear Chris:

I must say what I learnt these few days is possibly much more than what I learn in the past few years. You obviously had surpassed my expectation.

I learn how one could create a kingdom out of a little town; how one could **manage an efficient patient flow in a shortest possible time frame with the biggest possible number**; I further learn that how one should **delegate the works effectively, empower the staff systematically and inspire them spontaneously to be contributory to the growth of the organization**.

I also reckon that effective presentation does not depend on how flowery the language we use but on how we connect to the audience and engage their attention to our flow of thoughts. An effective presentation needs an effective tool to support the deed.



*Dr. How Kim Chuan, Malaysia (middle)
President of the Malaysian Dental Association*



2012 Workshop Dates: 6/12-14, 11/13-15

LECTURER: Dr. Chris Chang

President of the Beethoven Orthodontic Center. He received his PhD in bone physiology and Certificate in Orthodontics from Indiana University in 1996. As publisher of International Journal of Orthodontics & Implantology and author of 3D iBooks Ortho, he has been actively involved in the design and application of bone screws.



Day 1

- 13:00—14:00 Welcome Lunch
- 14:00—14:40 Orientation
- 14:40—15:00 Introduction of Beethoven and Anderson Clinic
- 15:00—18:30 Chair-side observation

Day 2

- 9:00—10:30 Optimized Orthodontic Treatment I
Dr. Chris Chang
- 10:30—11:00 Break
- 11:00—12:30 Optimized Orthodontic Treatment II
Dr. Chris Chang
- 12:30—13:50 Lunch
- 14:00—15:00 Model Practice
- 15:00—18:30 Chair-side observation

Day 3

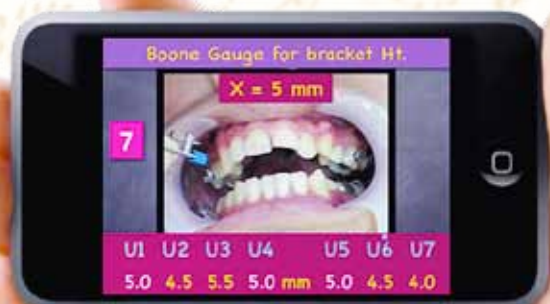- 09:00—10:00 6 Essentials of the new Damon Q
- 10:00—10:10 Break
- 10:10—12:30 Damon + Screw *Dr. John Lin*
- 12:30—13:30 Lunch

Day 3

- 14:00—15:30 Introduction of Keynote:
Organize your patient files for presentation
- 15:30—15:45 Break
- 15:45—17:00 Key Presentation Principles I

Day 4

- 09:00—10:00 Key Presentation Principles II
- 10:00—10:10 Break
- 10:10—11:30 Make it Visual
- 11:30—13:30 Lunch



Class II and Labially Impacted Maxillary Canines on Both Sides

History and Etiology

A 12-year-1-month male was referred by his dentist for orthodontic consultation (Fig. 1). His chief concern was delayed eruption of upper canines (Figures 2, 3) and cross bite of the upper left lateral incisor. There was no other contributory medical or dental history. As documented in Figures 4-6, the patient was treated to a near ideal outcome. Before and after treatment radiographic documentation is provided in Figures 7 and 8, as well as in the cephalometrics table.

Panoramic radiography (Fig. 7) revealed that both maxillary canines are impacted, and 3D CT images show that both were labially impacted. The etiology of the malocclusion was deemed to be insufficient space due to a constricted maxilla and the premature loss of the deciduous maxillary canines.

Diagnosis

Skeletal:

Skeletal Class I (SNA 80°, SNB 77°, ANB 3°)

Mandibular plane angle (SN-MP 33°, FMA 24°)

Dental:

Right full cusp Class II molar relationship

Left end-on Class II molar relationship

OJ 1.5mm; OB 1.5mm

UR3 & UL3 are labially impacted

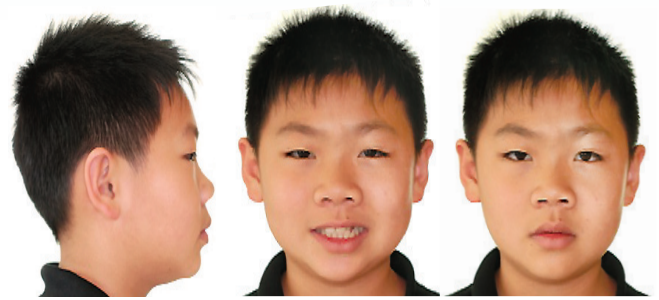


Fig. 1: Pretreatment facial photographs

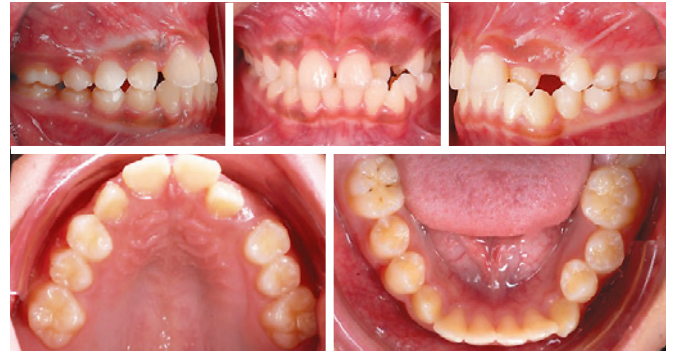

Fig. 2: Pretreatment intraoral photographs

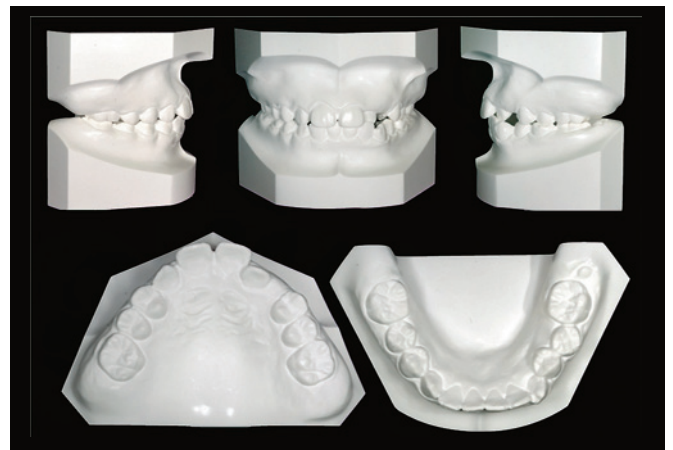

Fig. 3: Pretreatment study models

Dr. Bo Cun Kuo, Lecturer, Beethoven Orthodontic Course (right)
 Dr. Chris Chang, Director, Beethoven Orthodontic Center (middle)
 Dr. W. Eugene Roberts, Consultant,
International Journal of Orthodontics & Implantology (left)



■ Fig.4: Posttreatment facial photographs

UL2 is in anterior cross bite
 UL5 and LL5 are in posterior cross bite
 ABO Discrepancy Index: 19

Facial:

Convex profile within normal limits (WNL)
 Competent lips

Specific Objectives of Treatment

Maxilla (all three planes):

- A - P: Allow for normal expression of growth
- Vertical: Allow for normal expression of growth
- Transverse: Maintain

Mandible (all three planes):

- A - P: Allow for normal expression of growth
- Vertical: Allow for normal expression of growth
- Transverse: Maintain

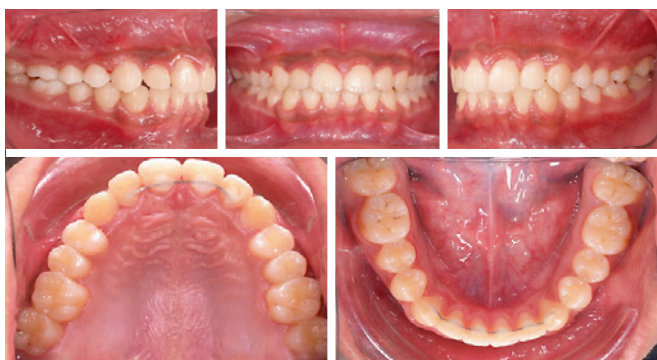Maxillary Dentition:

- A - P: Correct cross bite of UL2, create space for UL3
- Vertical: Allow for normal extrusion with growth
- Inter-molar: Expansion for impacted UR3 and UL3

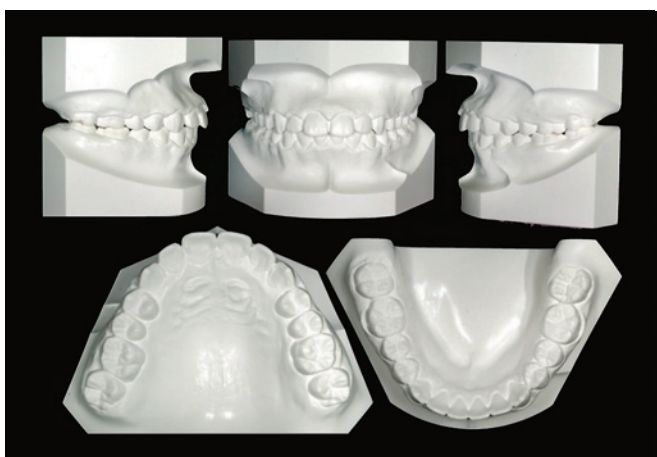Mandibular Dentition:

- A - P: Retract incisors
- Vertical: Allow for growth-related extrusion
- Inter-molar/Inter-canine Width: Expansion to correct crowding

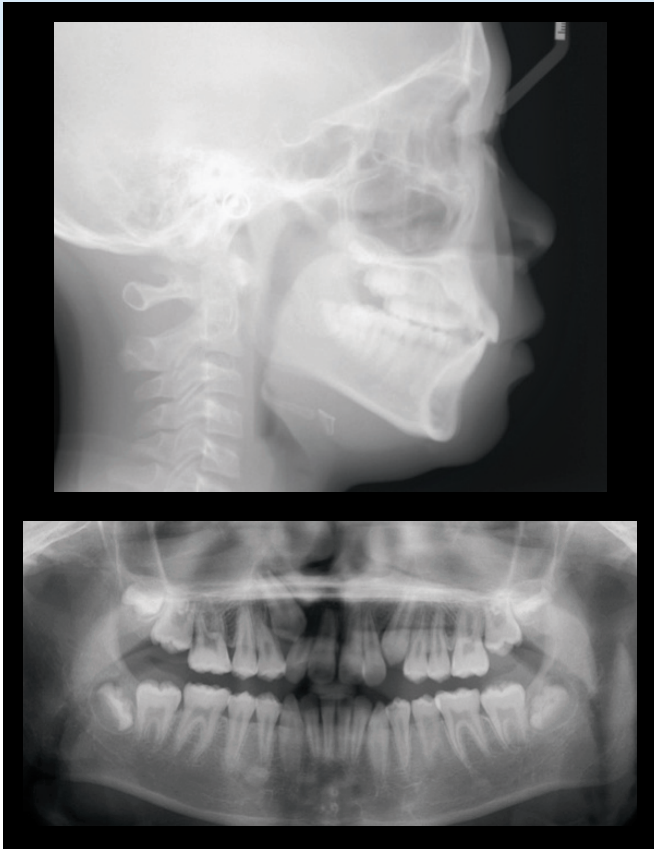
Facial Esthetics: Maintain facial balance



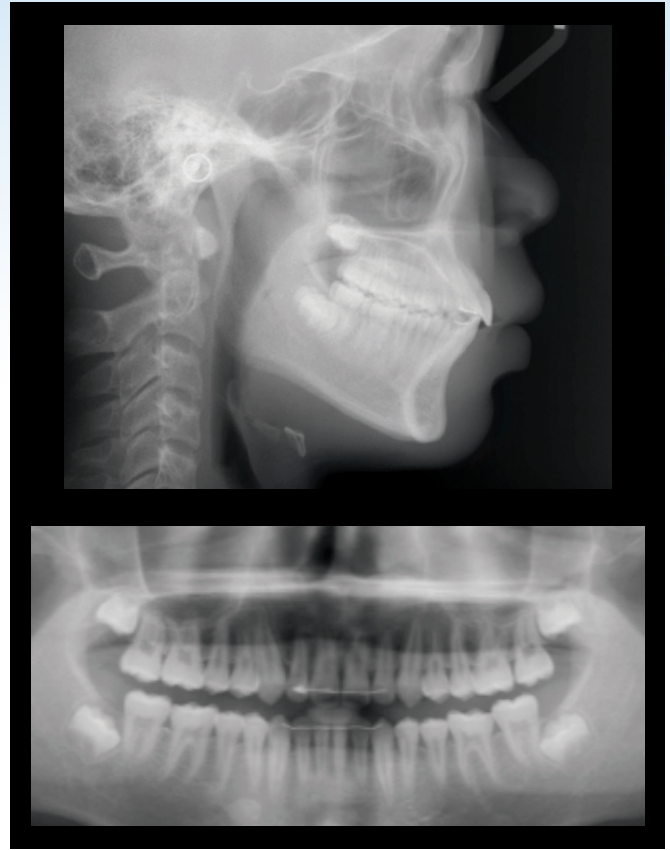
■ Fig.5: Posttreatment intraoral photographs



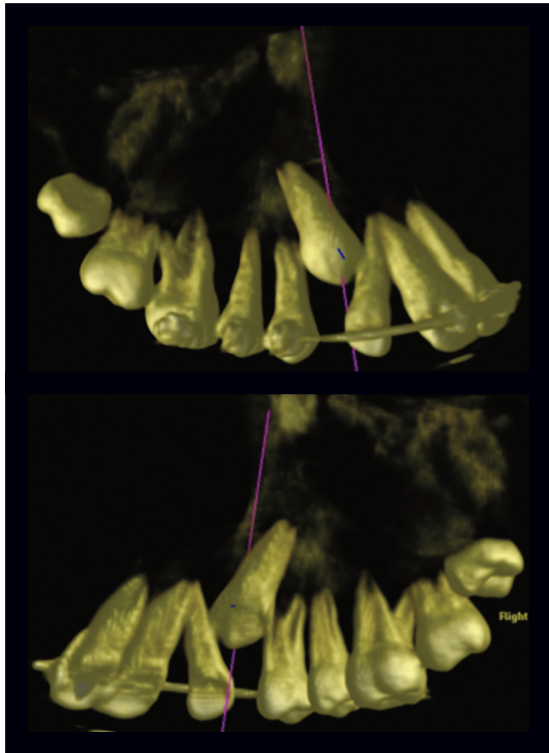
■ Fig.6: Posttreatment study models



■ Fig. 7: Pretreatment pano and ceph radiographs



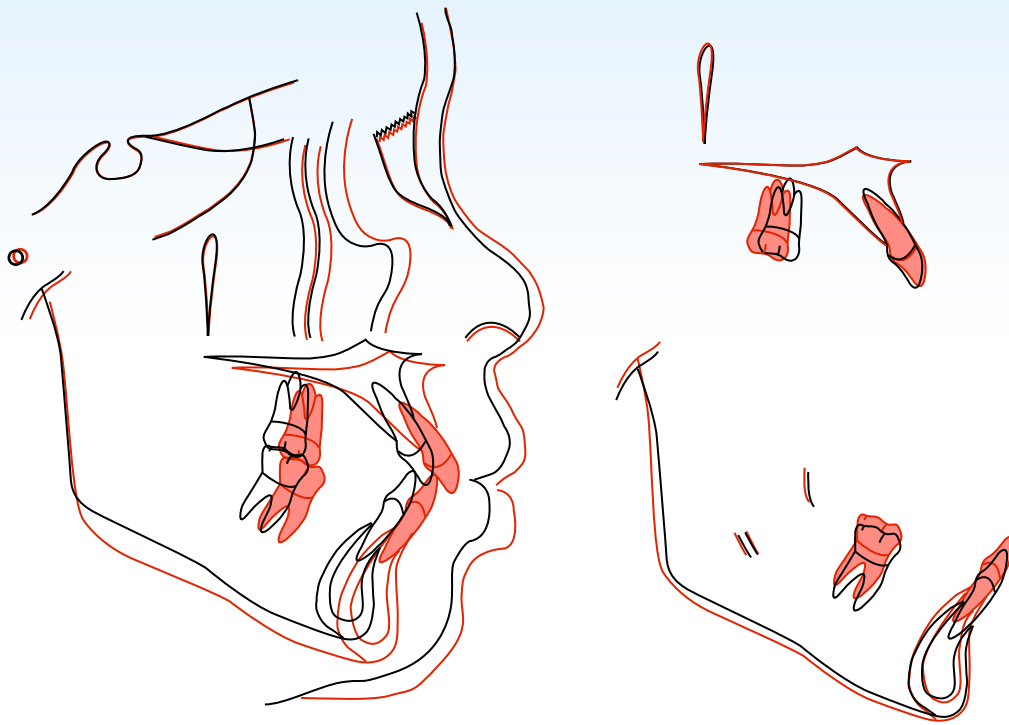
■ Fig. 8: Posttreatment pano and ceph radiographs



■ Fig. 9: 3D images for upper right impacted tooth

CEPHALOMETRIC			
SKELETAL ANALYSIS			
	PRE-Tx	POST-Tx	DIFF.
SNA°	80°	82°	2°
SNB°	77°	79°	2°
ANB°	3°	3°	0°
SN-MP°	33°	30°	-3°
FMA°	24°	21°	-3°
DENTAL ANALYSIS			
U1 TO NA mm	4.0 mm	3.0 mm	-1.0 mm
U1 TO SN°	116°	113°	-3°
L1 TO NB mm	3.5 mm	4.0 mm	0.5 mm
L1 TO MP°	100°	103°	3°
FACIAL ANALYSIS			
E-LINE (U)	2.0 mm	2.5 mm	0.5 mm
E-LINE (L)	1.5 mm	3.0 mm	1.5 mm

■ Table. Cephalometric summary



■ Fig. 10: Superimposed tracings

Treatment Plan

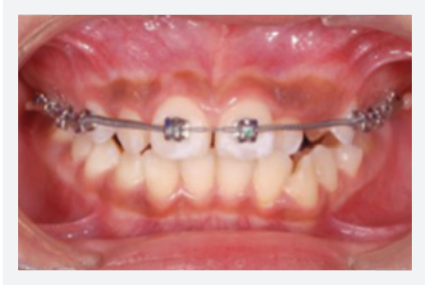Considering the patient's normal convexity and age, non-extraction treatment with a full fixed orthodontic appliance was indicated to align and level the dentition. Since this male patient was only 12 years old, there was considerable potential for additional chin projection, as the mandible rotates anteriorly with growth. Extracting permanent teeth may be detrimental to lip protrusion and facial esthetics after growth is completed. Damon D3MX low torque brackets (*Ormco*) with an .022" slot were selected because this self-ligation system can induce light force to increase arch width and create space for crowding and/or unerupted anterior teeth. Correcting crowding and aligning unerupted

anterior teeth, with non-extraction treatment, requires low torque brackets. Low torque brackets help avoid flaring of anterior teeth during leveling. In the initial stage of active treatment, coil springs were used to create space for the impacted canines (*Fig. 11*). A bite turbo was cemented on LL1 to open up the bite to facilitate correction of the crossbites (*Fig. 14*). A .014 CuNiTi wire was used to tip the UL2 to resolve the anterior cross bite. Class II elastics were used to resolve the sagittal occlusion discrepancy. When the fixed appliances were removed and the corrected dentition was retained with fixed anterior retainers in both arches and a clear overlay on the upper arch.

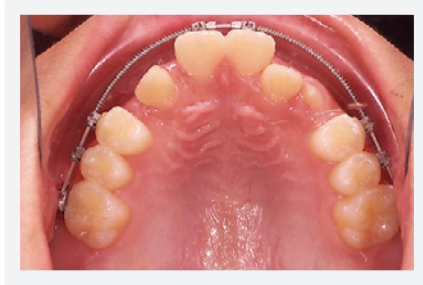
Appliances and Treatment Progress

A .022" slot Damon D3MX low torque brackets (*Ormco*) were bonded on all permanent teeth. Two sections of open coil springs were applied to create space for the impacted maxillary canines. To avoid lateral incisor root resorption, no bracket was bonded on the UR2 initially (*Fig. 11*). Four months later, the upper left canine had spontaneously erupted (*Fig. 12*). In the 16th month, the upper left canine had reached the occlusal plane (*Fig. 13*). In the 25th month, to help correct the cross bite of UL2 and LL1, a composite bite turbo was bonded on the

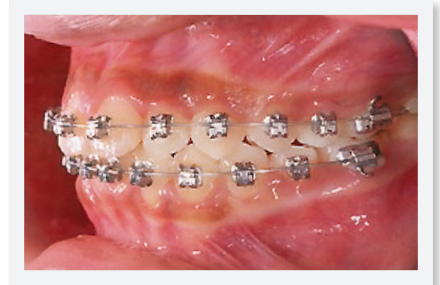lower left lateral incisor (*Figures 14, 15*). The cross bite of the lateral incisor was corrected in the 27th month, and the bite turbo was removed. After 29 months, the crown of upper right canine had spontaneously erupted, and then a Damon D3MX bracket (*Ormco*) was bonded on it (*Fig. 16*). After another four months, the upper right canine reached the occlusal plane (*Fig. 17*). Class II elastics (3-3.5 oz) were used for two months to correct the Class II molar relationships. All appliances were removed after 34 months of active treatment.



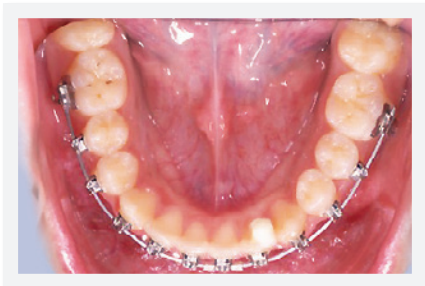■ Fig. 11:
Open coil springs, one between #5 and #7, the other #10 and #12



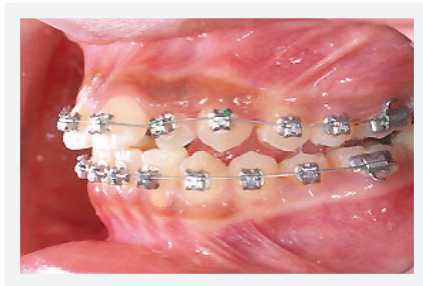■ Fig. 12:
#11 erupted



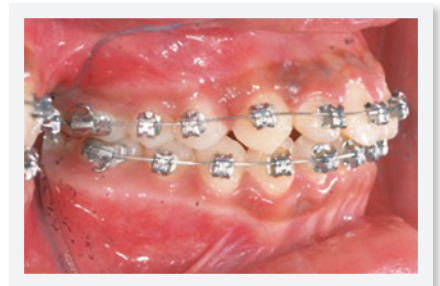■ Fig. 13:
#11 completely erupted



■ Fig. 14:
#23 Bite turbo



■ Fig. 15:
Bite turbo on #23 in the 13 completely erupted



■ Fig. 16:
The D3MX bracket was bonded on #6

Results Achieved

Maxilla (all three planes):

- A - P: Optimal growth expression
- Vertical: Optimal growth expression
- Transverse: Maintained

Mandible (all three planes):

- A - P: Optimal growth expression
- Vertical: Optimal growth expression
- Transverse: Maintained

Maxillary Dentition:

- A - P: Increased axial inclination of the incisors
- Vertical: Impacted canines uncovered and optimally aligned
- Inter-molar/Inter-canine Width: Optimal growth expression

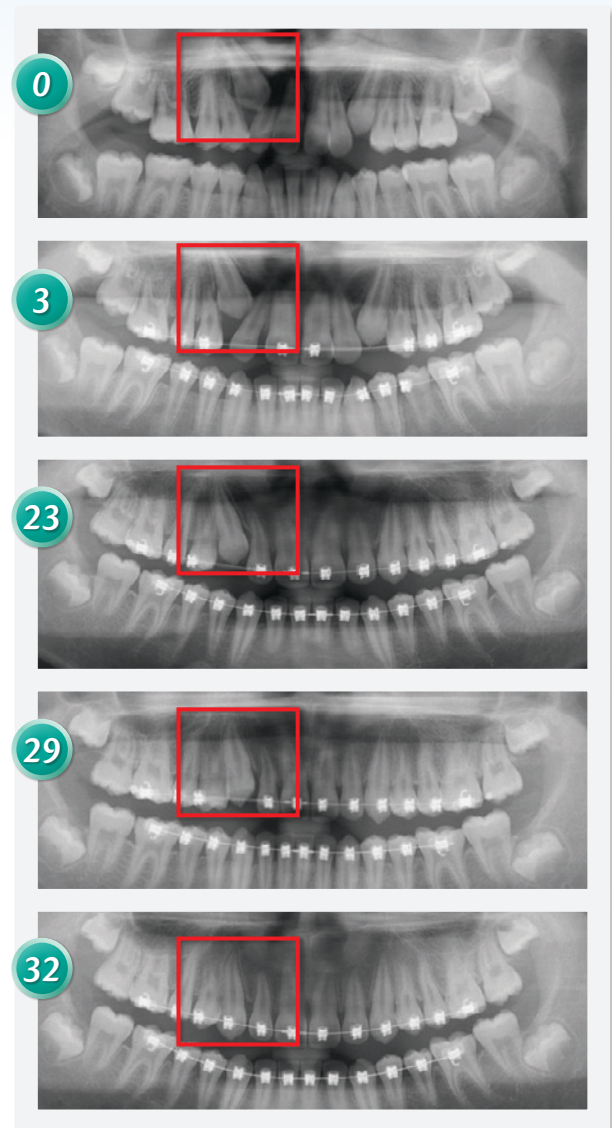
Mandibular Dentition:

- A - P: Retracted
- Vertical: Extruded incisors, molars maintained
- Inter-molar/Inter-canine Width: Optimal growth expression

Facial Esthetics: A pleasing profile with competent lips was achieved

Retention

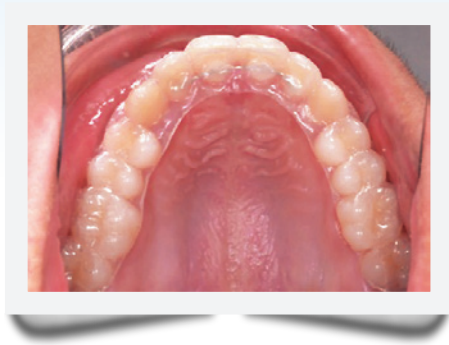The upper fixed 2-2 and the lower fixed 3-3 retainers were bonded on every tooth. An upper clear overlay retainer was delivered (Fig. 18). The patient was instructed to wear it full time for the first 6



■ Fig. 17:

X-ray films showed the movement of the upper impacted canines.

months and nights only thereafter. The patient was also informed about proper home hygiene and maintenance of the retainers.



■ Fig. 18: Upper fixed retainer

Final Evaluation of Treatment

The ABO Cast-Radiograph Evaluation was scored at 14 points. The major discrepancies were malalignment (5 points) and uneven marginal ridges (6 points). The IBOI pink and white esthetic score was 6.

The distance from the upper and lower lip to the E-line increased from 2mm to 2.5mm and 1.5mm to 3mm, respectively.

The impacted canines were in optimal alignment after treatment. The gingival esthetics was pleasing. The root prominence was satisfactory. From the radiographs, the root alignment was ideal, and no external root resorption (EARR) was presented.

The molar and canine relationships are both Class I. The over bite and overjet are ideal. Overall, the treatment results were pleasing to the patient and the clinician

Discussion

About one third of impacted maxillary canines are positioned labially or within the alveolus.¹ Labial impaction of a maxillary canine is either due to ectopic migration of the canine crown over the root of the lateral incisor or shifting of the maxillary dental midline, causing insufficient space for the canine to erupt.² Olive³ suggested that opening space for the canine crown with routine orthodontic mechanics may allow for spontaneous eruption of impacted canines. Bishara⁴ claimed that facially impacted canines have the potential to erupt without surgical intervention. In this case, the labially impacted canines spontaneously erupted without any surgery.

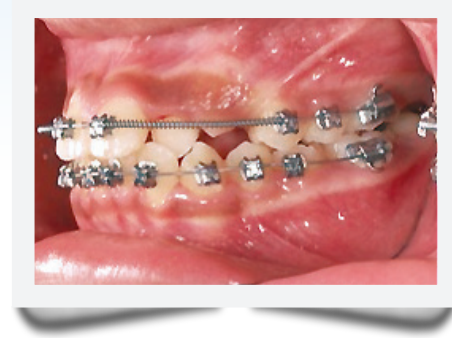For space expansion, Kokich⁵ suggested that brackets are placed on the teeth in the maxillary arch, and coil springs are required to move the first premolar and central incisor apart. It is best not to place brackets on the maxillary lateral incisor initially. If brackets are placed on all maxillary teeth, including the lateral incisor, the root of it may be forced toward the labial side. If the canine crown is occupying this space, root resorption could occur. In the patient, the brackets were bonded on upper left and right lateral incisors in the 12th month. In the 34th month, no root resorption was found in the final radiograph.

Warford et al⁶ mentioned that patients with canine impactions experience longer treatment time than those without, due to displacement of the tooth

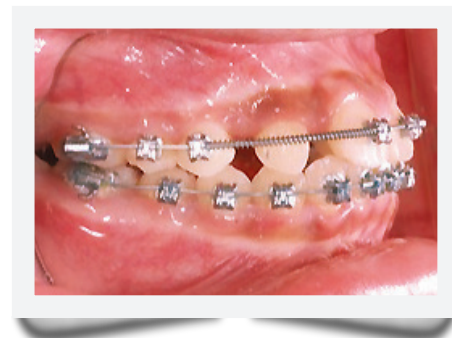
from the occlusal plane. Smith⁷ reported that the mean value of the rates of eruption for maxillary canines was .08 mm per week. Prior to emergence the rate of eruption may be quite slow, and it may take 2-4 years for a tooth to reach the oral cavity. Upon entering the oral cavity, however, the rate of movement can be very rapid (*1mm per month*). Nevertheless, it may take the tooth 1-2 years to fully reach the occlusal plane. The distance from the occlusal plane to the UR3 was more than that to the UL3. It took 32 months for the UR3 to reach the occlusal plane and only 12 months for the UL3.

The space between the UL2 and the UL4 was 5 mm, and there was no space between the UR4 and UR2. In the 16th month the left impacted canine reached the occlusal plane. In the 29th month the right one was also on the occlusal plane. This case demonstrated that the amount of space needed is directly related to treatment time.

The initial molar occlusal relationship was Class II and it was treated to Class I bilaterally. Two mechanical aspects of the treatment process changed the molar relationship: 1. open coil springs 2. Class II elastics. Coil springs enlarged the space and pushed the upper premolars and molars backward. In the 4th month, the molar relationship was corrected to Class I (Fig. 23). The left and right coil springs were removed in the 12th and 29th month respectively. In the 32nd month, Class II elastics were used to adjust the overjet of anterior teeth and maintain the Class I molar relationship.



■ Fig. 23:
Class I molar relationship in the 4th month, left view



■ Fig. 24:
Class I molar relationship in the 4th month, right view

Tooth eruption is defined as the movement of a tooth from its site of development within the alveolar process to its functional position in oral cavity. The eruption process can be divided into two easily definable parts: intraosseous and supraosseous (Weinmann, 1944).⁸ Supraosseous events include the movement of teeth, once part of the crown is above the alveolar crest. In this phase of eruption, teeth move beyond the alveolar crest to its position of occlusal function. There are several possible mechanism of tooth eruption: 1. Root formation 2. Anabolic bone modeling 3. Dental follicle expansion,

4. Periodontal ligament traction. Experimental evidence suggests that changes in alveolar bone adaptation (*bone formation and resorption*), in response to periodontal ligament traction, plays a key role in supraosseous eruption. Histologic work by Magnusson (1968)⁹ gave rise to the hypothesis that changes in permeability of the periapical periodontal ligament vascular bed, i.e., resulting in increased fluid effusion, that contributed to eruptive force. Subsequent studies with intracardially injected 131I-fibrinogen are consistent with this hypothesis.¹⁰ It has been reported that labial displacement of the upper permanent canine is most frequently associated with crowding. A lack of space was diagnosed in 60%–90% of patients with impacted upper canines. Subjects with maxillary canine impactions also may have a transverse maxillary deficiency. About 42% of displaced maxillary canines erupted spontaneously within one-year period after removal of the primary canine and expansion of the dental arch.¹¹ It demonstrated that the space was critical to spontaneous tooth eruption.

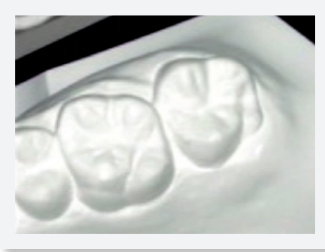For creating space, roots angulation and torque control present significant challenges. Using open coil springs to create space may result in anterior teeth flaring out. The post treatment cephalometric film demonstrated that no excessive flaring was noted. The positive outcome was attributed to the use of low torque brackets on the anterior

teeth. The slots of these low torque brackets were specially angulated, to allow the arch wire to induce low torque and light force on teeth. Hence, the flaring out of the anterior teeth was avoided by light force.

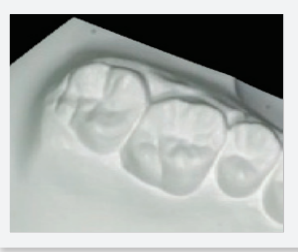The initial DI^{12,13} score was 19, indicating a moderate malocclusion for an ABO case report. The ABO Cast-Radiograph Evaluation score was 14 points, within the usual acceptable range for a board case. The major discrepancies were 5 points for tooth rotations (*Figures 19-22*) and 6 points for uneven marginal ridges (*Figures 25-27*). A realistic treatment plan should be designed in advance.

Upper and lower lips are slightly protrusive in the finish profile. Since the patient was only 15 years old, his face and jaw bone still had significant growth potential, the profile should be monitored in post-treatment follow up.

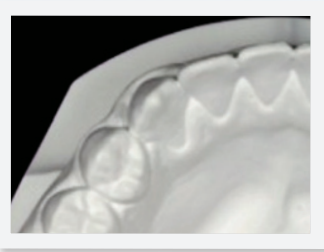For retention, the upper fixed retainer did not extend to maxillary canines. This approach maintains incisor alignment, but still allows the canines to function independently. The latter is important because previously impacted teeth tend to intrude. If they are tied to incisor with a fixed retainer, the entire maxillary anterior segment could be affected by the canines' tendency to relapse.




■ Fig. 19:
distal-in upper left 1st molar



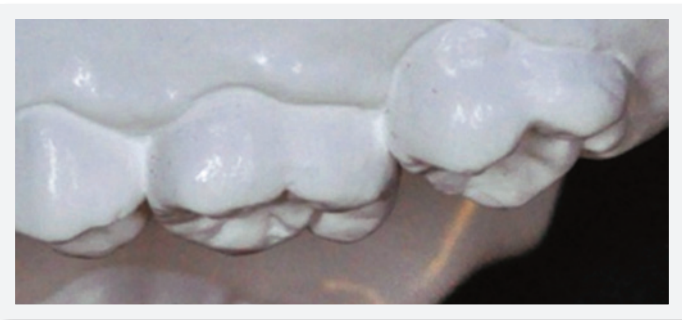■ Fig. 20:
distal-in upper right 1st molar



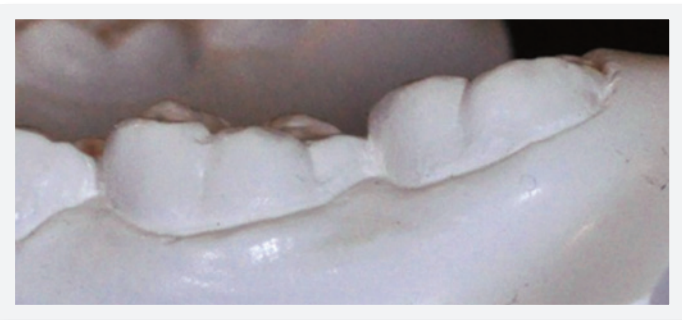■ Fig. 21:
distal-in lower left canine



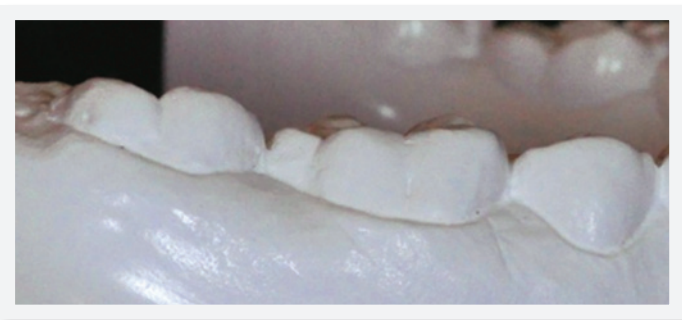■ Fig. 22:
Mesial-in lower left 2nd molar



■ Fig. 25:
Marginal discrepancy between upper left 1st molar and 2nd molar



■ Fig. 26:
Marginal discrepancy between lower left 1st molar and 2nd molar



■ Fig. 27:
Marginal discrepancy between upper right 1st molar and 2nd molar

Conclusion

This case report demonstrates the eruption potential of labially impacted maxillary canines provided with sufficient space. The impacted canine may be easily treated with fixed orthodontic appliance without surgical treatment. Labially impacted teeth can occur bilaterally in the same maxillary arch. The treatment strategies must consider enough space expansion. Roots resorption of the teeth adjacent to the impacted canine should be avoided. Open coil springs can create space and correct the Class II molar relationship, but flaring out of anterior teeth can be avoided by light force.

Acknowledgment

Thanks to Ms. Tzu Han Huang for proofreading this article.

References

1. Bass T. Observation on the misplaced upper canine tooth. *Dent Pract Dent Rec* 1967;18:25-33.
2. Kokich VG. Surgical and orthodontic management of impacted maxillary canines. *Am J Orthod Dentofacial Orthop* 2004;126:278-83
3. Olive RJ. Orthodontic treatment of palatally impacted maxillary canines. *Aust Orthod J* 2002;18:64-70.
4. Bishara SE. Impacted maxillary canines: A review. *Am J Orthod Dentofacial Orthop* 1992;101:159-171.
5. Kokich VG, Mathews DP. Impacted teeth: Orthodontic and surgical considerations. In: McNamara JA, editor. *Orthodontics and dentofacial orthopedics*. Ann Arbor (Mich): Needham Press; 2001.
6. Warford JH, Grandhi RK, Tira DE. Prediction of maxillary canine impaction using sectors and angular measurement. *Am J Orthod Dentofacial Orthop* 2003;124:651-5
7. Smith RG. A clinical study into the rate of eruption of some human permanent teeth. *Archives of Oral Biology*, Volume 25, Issue 10, 1980:675-681
8. Weinmann JP. Eruption of the teeth. In *Oral Histology and Embryology* chap. XI, B.J.Orban, Ed.C.V.Mosby, St. Louis 1944;301-319.
9. Magnusson B. Tissue Changes During Molar Tooth Eruption. *Transactions of the Royal School of Dentistry, Stockholm and Umeå*, Vol. 13, 1968: 1-122
10. Gorski JP, Marks SC. Current Concepts of the Biology of Tooth Eruption *Critical Reviews in Oral Biology and Medicine* 1992;3(3):185-206
11. Smailienė D, Šidlauskas A, Lopatienė K, Guzevičienė V, Juodžbalys G. Factors Affecting Self-Eruption of Displaced Permanent Maxillary Canines. *Medicina (Kaunas)* 2011;47(3): 163-9
12. Chang C. Advanced Damon Course No. 4,5 : DI & CRE Workshop (1)(2), Podcast Encyclopedia in Orthodontics 2012, Newton's A Ltd, Taiwan
13. Chang C, Roberts WE. *Orthodontics*, 3D iBooks Ortho., Taiwan: Newton's A Ltd, 2012.

IBOI Discrepancy Index Worksheet**TOTAL D.I. SCORE** 19**OVERJET**

0 mm. (edge-to-edge)	=	1 pt.
1 – 3 mm.	=	0 pts.
3.1 – 5 mm.	=	2 pts.
5.1 – 7 mm.	=	3 pts.
7.1 – 9 mm.	=	4 pts.
> 9 mm.	=	5 pts.

Negative OJ (x-bite) 1 pt. per mm. per tooth

Total = 2**OVERBITE**

0 – 3 mm.	=	0 pts.
3.1 – 5 mm.	=	2 pts.
5.1 – 7 mm.	=	3 pts.
Impinging (100%)	=	5 pts.

Total = 0**ANTERIOR OPEN BITE**0 mm. (edge-to-edge), 1 pt. per tooth
then 1 pt. per additional full mm. per toothTotal = 0**LATERAL OPEN BITE**

2 pts. per mm. per tooth

Total = 0**CROWDING** (only one arch)

1 – 3 mm.	=	1 pt.
3.1 – 5 mm.	=	2 pts.
5.1 – 7 mm.	=	4 pts.
> 7 mm.	=	7 pts.

Total = 1**OCCLUSION**

Class I to end on	=	0 pts.
End on Class II or III	=	2 pts. per side <u>2</u> pts.
Full Class II or III	=	4 pts. per side <u>4</u> pts.
Beyond Class II or III	=	1 pt. per mm. <u> </u> pts.
		additional

Total = 6

EXAM YEAR

ID#

LINGUAL POSTERIOR X-BITE1 pt. per tooth Total = 1**BUCCAL POSTERIOR X-BITE**2 pts. per tooth Total = 0**CEPHALOMETRICS** (See Instructions)ANB $\geq 6^\circ$ or $\leq -2^\circ$ = 4 pts.Each degree $< -2^\circ$ _____ x 1 pt. = _____Each degree $> 6^\circ$ _____ x 1 pt. = _____**SN-MP** $\geq 38^\circ$ = 2 pts.Each degree $> 38^\circ$ _____ x 2 pts. = _____ $\leq 26^\circ$ = 1 pt.Each degree $< 26^\circ$ _____ x 1 pt. = _____1 to MP $\geq 99^\circ$ = 1 pt.Each degree $> 99^\circ$ _____ x 1 pt. = _____Total = 5**OTHER** (See Instructions)

Supernumerary teeth	_____ x 1 pt. = _____
Ankylosis of perm. teeth	_____ x 2 pts. = _____
Anomalous morphology	_____ x 2 pts. = _____
Impaction (except 3 rd molars)	<u>2</u> x 2 pts. = <u>4</u>
Midline discrepancy (≥ 3 mm)	@ 2 pts. = _____
Missing teeth (except 3 rd molars)	_____ x 1 pts. = _____
Missing teeth, congenital	_____ x 2 pts. = _____
Spacing (4 or more, per arch)	_____ x 2 pts. = _____
Spacing (Mx cent. diastema ≥ 2 mm)	@ 2 pts. = _____
Tooth transposition	_____ x 2 pts. = _____
Skeletal asymmetry (nonsurgical tx)	@ 3 pts. = _____
Addl. treatment complexities	_____ x 2 pts. = _____

Identify:

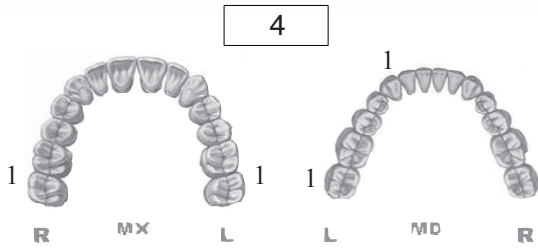
Total = 4

IBOI Cast-Radiograph Evaluation

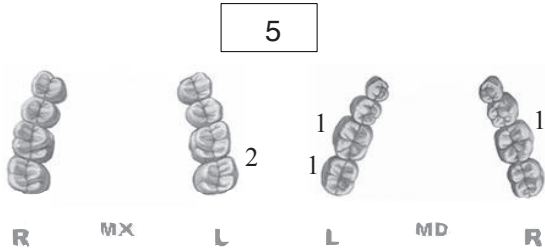
Case # Patient

Total Score: **14**

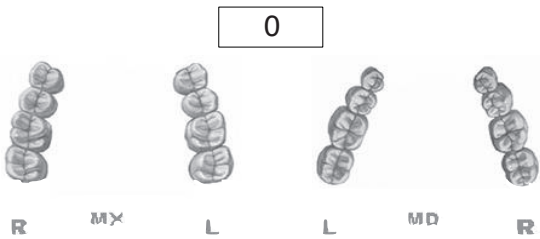
Alignment/Rotations



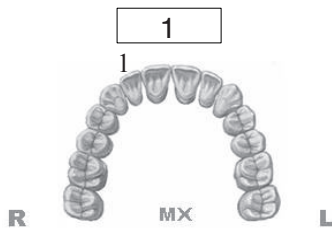Marginal Ridges



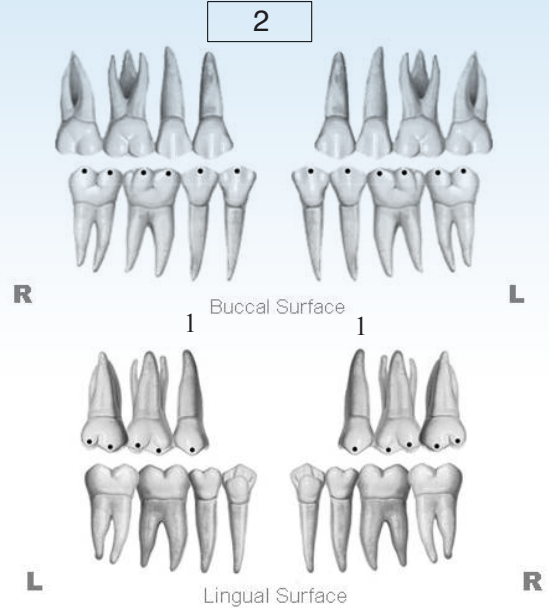
Buccolingual Inclination



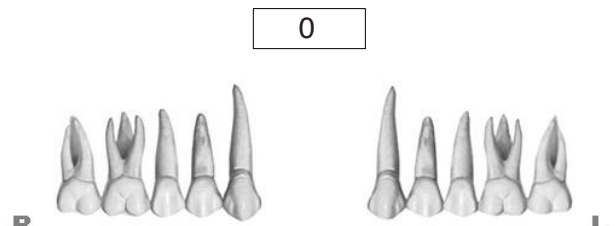
Overjet



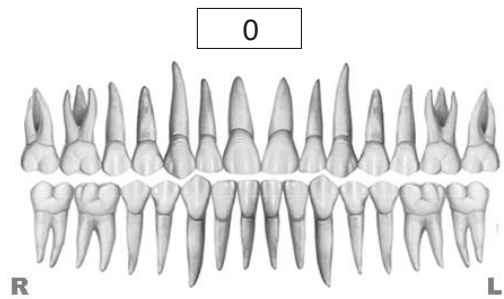
Occlusal Contacts



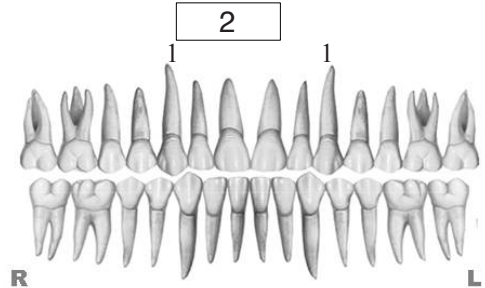
Occlusal Relationships



Interproximal Contacts



Root Angulation



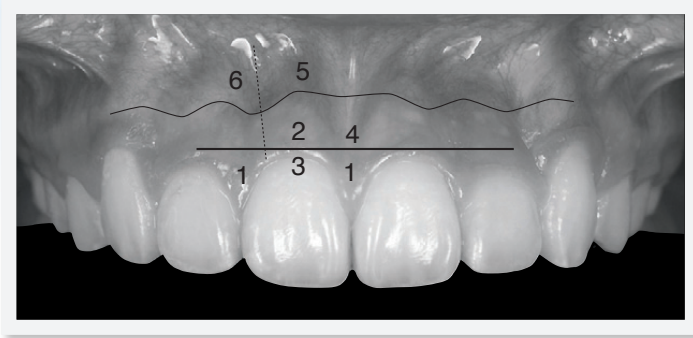
INSTRUCTIONS: Place score beside each deficient tooth and enter total score for each parameter in the white box. Mark extracted teeth with "X". Second molars should be in occlusion.

IBOI Pink & White Esthetic Score

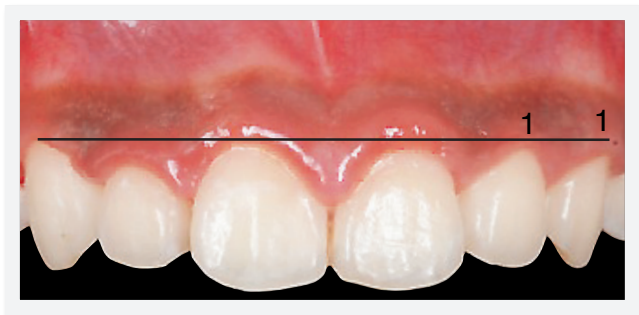Total Score: = 6

1. Pink Esthetic Score

Total = 2



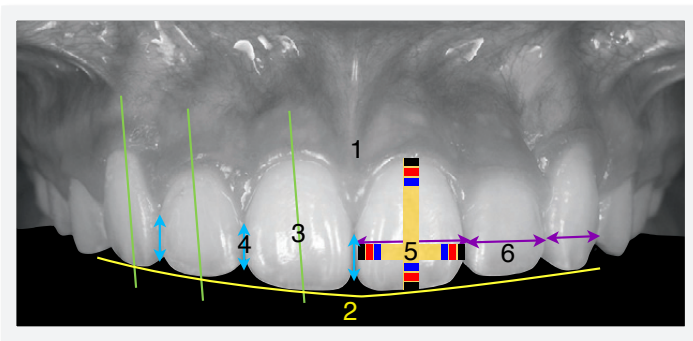
1. Mesial Papilla	0	1	2
2. Distal Papilla	0	1	2
3. Curvature of Gingival Margin	0	1	2
4. Level of Gingival Margin	0	1	2
5. Root Convexity (Torque)	0	1	2
6. Scar Formation	0	1	2



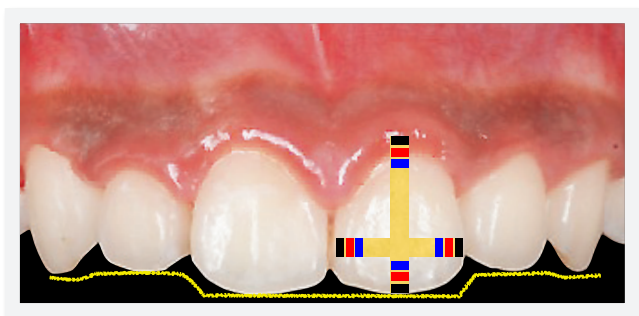
1. M & D Papilla	0	1	2
2. Keratinized Gingiva	0	1	2
3. Curvature of Gingival Margin	0	1	2
4. Level of Gingival Margin	0	1	2
5. Root Convexity (Torque)	0	1	2
6. Scar Formation	0	1	2

2. White Esthetic Score *(for Micro-esthetics)*

Total = 4



1. Midline	0	1	2
2. Incisor Curve	0	1	2
3. Axial Inclination (5°, 8°, 10°)	0	1	2
4. Contact Area (50%, 40%, 30%)	0	1	2
5. Tooth Proportion (1: 0.8)	0	1	2
6. Tooth to Tooth Proportion	0	1	2



1. Midline	0	1	2
2. Incisor Curve	0	1	2
3. Axial Inclination (5°, 8°, 10°)	0	1	2
4. Contact Area (50%, 40%, 30%)	0	1	2
5. Tooth Proportion (1: 0.8)	0	1	2
6. Tooth to Tooth Proportion	0	1	2

DAMON® SYSTEM

More than straight teeth™

DAMON®
CLEAR



DAMON³™
MX



DAMON®



3 戴蒙系統鉅作，愛用好評如潮 大台柱全面回饋

《高CP值好物》Damon 3MX × 《常勝軍推薦》Damon Q × 《指標性美力》Damon Clear

DAMON®
CLEAR

戴蒙可麗兒透明矯正器

- ◆超完美的晶瑩透明：超透明外觀與 Passive Self-ligation 展現無懈可擊的雙功能
- ◆Polycrystalline Alumina 結構材質設計：提供堅硬、穩定的力量支持，且不易變色
- ◆Customized Base 專利雷射噴砂黏著底座設計：黏著强度高，debonding 施力更舒適
- ◆Removable Positioning gauge：提供矯正器黏著定位的便利與準確性

DAMON®

迷你舒適型
戴蒙快速矯正器



- ◆體積超迷你
- ◆SpinTek Slide 舒適旋轉開關容易
- ◆四面堅固管壁設計
- ◆移動式尺規黏著位置更準確
- ◆17-4 不銹鋼材質結構更堅硬耐久

DAMON³™

高科技舒適型
戴蒙矯正器



- ◆Vertical Slot 置放抽取式矯正鉤 Drop-in Hook
- ◆17-4 高品質不銹鋼結合高精密工業 MIM 製造，展現極佳強度及耐久度
- ◆四面堅固管壁設計，移動牙齒超快速、超低摩擦力，超舒適
- ◆Funnel Slide 漏斗型快速閥門及擋板設計，開關簡單，換線快速

戴蒙系統鉅作，愛用好評如潮 3大台柱全面回饋

即日起至6/25止

10人份

20人份

50人份

DAMON 3MX

贈品

- ① .014 Damon Copper Ni-Ti 10條
- ② .014x.025 Damon Copper Ni-Ti 10條
- ③ .019x.025 Damon SS 10條

特價NT\$ **90,000**



贈品

- ① .014 Damon Copper Ni-Ti 20條
- ② .014x.025 Damon Copper Ni-Ti 20條
- ③ .019x.025 Damon SS 20條
- ④ D3MX器械 1支

特價NT\$ **180,000**



贈品

- ① Damon Copper Ni-Ti 100條(任選)
- ② Bondable Tube 200顆 (6th四象限各50顆)

特價NT\$ **450,000**



DAMON

贈品

- ① .014 Damon Copper Ni-Ti 10條
- ② .014x.025 Damon Copper Ni-Ti 10條
- ③ .019x.025 Damon SS 10條

特價NT\$ **100,000**



贈品

- ① .014 Damon Copper Ni-Ti 20條
- ② .014x.025 Damon Copper Ni-Ti 20條
- ③ .019x.025 Damon SS 20條
- ④ Damon Q 器械 1支
- ⑤ Enlight(光照含氟矯正專用黏著劑) 1支
- ⑥ Ortho Solo(多功能光照黏著基底劑) 1瓶

特價NT\$ **200,000**



贈品

- ① Damon Copper Ni-Ti 150條(任選)
- ② Bondable Tube 120顆 (6th四象限各30顆)

特價NT\$ **500,000**



DAMON CLEAR
Upper 3-3

DAMON

贈品

- ① .014 Damon Copper Ni-Ti 10條
- ② .014x.025 Damon Copper Ni-Ti 10條

特價NT\$ **112,000**



贈品

- ① .014 Damon Copper Ni-Ti 20條
- ② .014x.025 Damon Copper Ni-Ti 20條
- ③ .019x.025 Damon SS 20條

特價NT\$ **224,000**



贈品

- ① Damon Copper Ni-Ti 100條(任選)
- ② Clear Debonding Plier 1支
- ③ Bondable Tube 80顆 (6th四象限各20顆)

特價NT\$ **560,000**



SDC
SWISS
dentacare
QUALITY DENTAL PRODUCTS

SDC Prostrip Kit

贈品

- ① 3D Wedge
- ② 3D Wedge專用鑷子
- ③ Tray Stand
- ④ 6片裝 Prostrip Refill

特價NT\$ **48,000**



數量有限，贈品送完為止

SDC Mini Ortho Kit

加購優惠**7折**



Implant-orthodontic Combined Treatment: Over-erupted Molar and Scissors-bite Correction

History and Etiology

A 28-year-2-month-old male was referred for orthodontic consultation by his family dentist (Fig. 1). His chief concern was the restorative need for a missing lower molar (Figures 2, 3). A pre-prosthetic orthodontic plan was proposed. There was no contributory medical or dental history. Clinical examination revealed a Class I molar relationship on the right, but the left premolars were Class II (Figures 2, 3). The mandibular dental midline was 3 mm to the left of the facial and maxillary midlines. Cast evaluation documented the following dental problems: 1. scissors-bite over upper second molars bilaterally. 2. extrusion of the maxillary left first molar. 3. minor crowding in both arches. The patient was treated to an acceptable result as documented in Figures 4-9, as will be subsequently discussed.

Diagnosis

Skeletal:

Skeletal Class I ($SNA\ 83^\circ$, $SNB\ 80^\circ$, $ANB\ 3^\circ$)

Mandibular plane angle ($SN-MP\ 32^\circ$, $FMA\ 28^\circ$)

Dental:

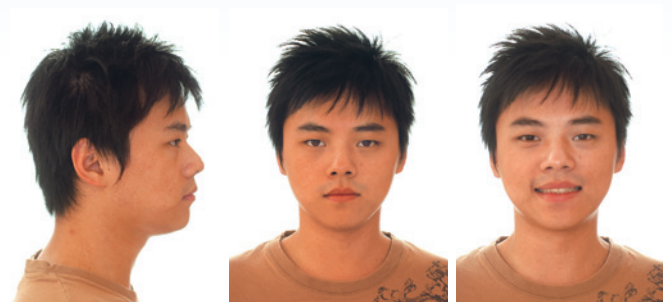Class I molar relationship on the right side, left buccal segment is Class II

The overbite and overjet were both 2 mm

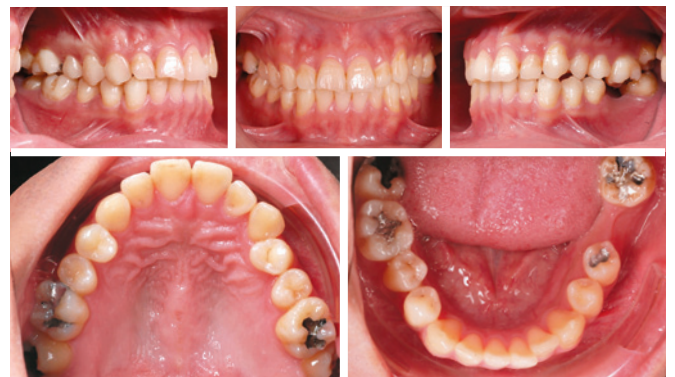The mandibular dental midline was 2 mm to the left of the facial and maxillary midlines

The lower left first molar is missing

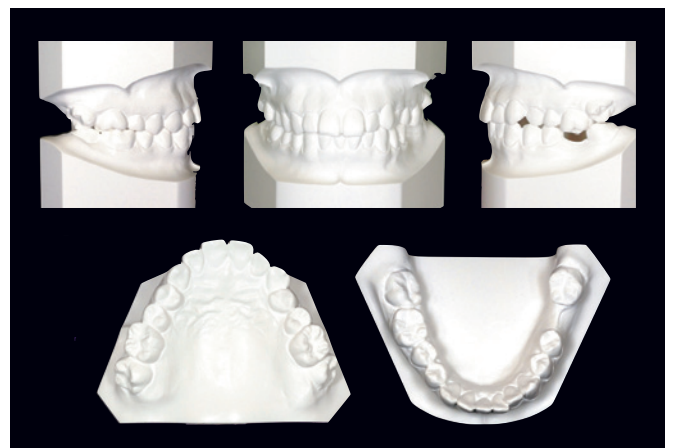Slight crowding in both the upper and lower arches



■ Fig. 1: Pretreatment facial photographs



■ Fig. 2: Pretreatment intraoral photographs



■ Fig. 3: Pretreatment study models

Dr. Bill Su, Director, Newtons Implant Center (right)
 Dr. Chris Chang, Director, Beethoven Orthodontic Center (middle)
 Dr. W. Eugene Roberts, Consultant,
International Journal of Orthodontics & Implantology (left)



Scissors-bite of the second molars bilaterally (Fig. 10)
 Extrusion of the maxillary left first molar (Fig. 10)
 Lingual cross-bite of the left first premolars.

Facial:

Profile and lip position are within normal limits (WNL)



■ Fig. 4: Posttreatment facial photographs

The IBOI Discrepancy Index (DI) was 16 as shown in the subsequent worksheet.¹

Specific Objectives of Treatment

Maxilla (all three planes):

- A - P: Maintain
- Vertical: Maintain
- Transverse: Maintain

Mandible (all three planes):

- A - P: Maintain
- Vertical: Maintain
- Transverse: Maintain

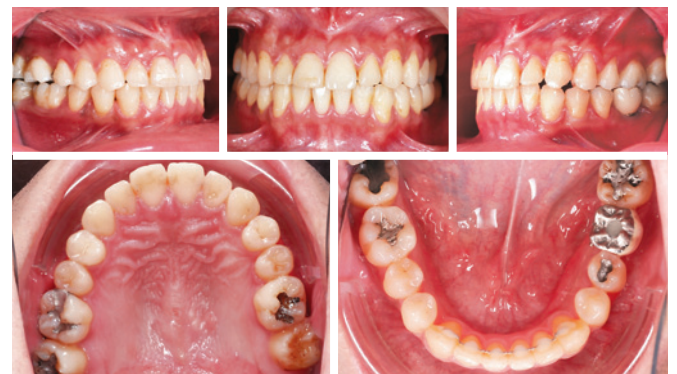Maxillary Dentition

- A - P: Maintain
- Vertical: Maintain
- Inter-molar Width: Maintain

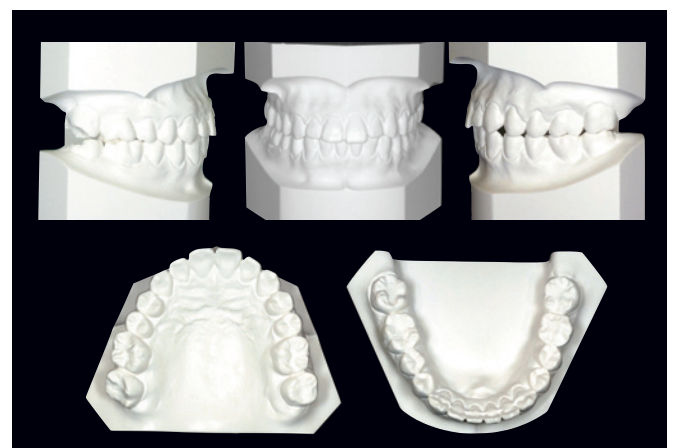Mandibular Dentition

- A - P: Maintain
- Vertical: Maintain
- Inter-molar / Inter-canine Width: Maintain

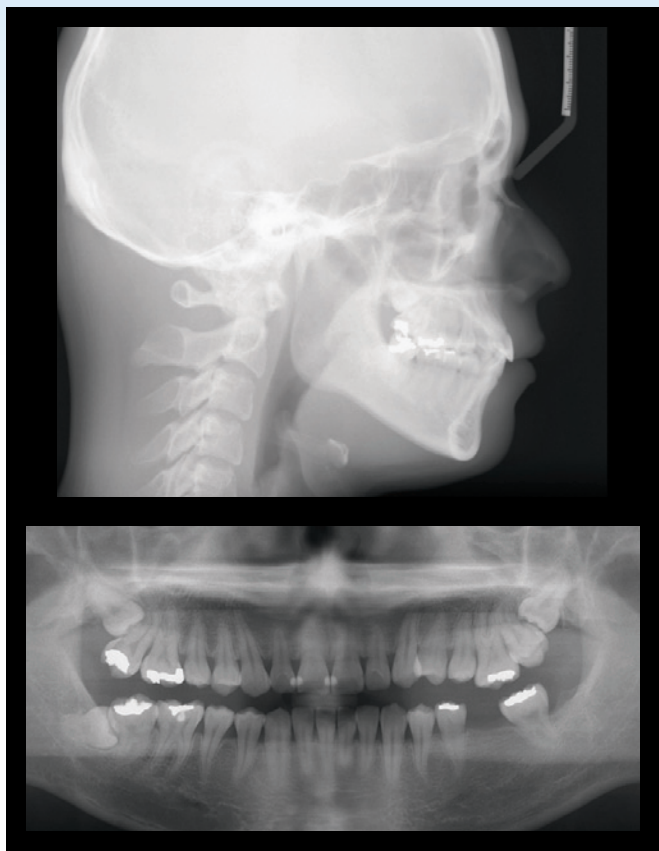
Facial Esthetics: Maintain



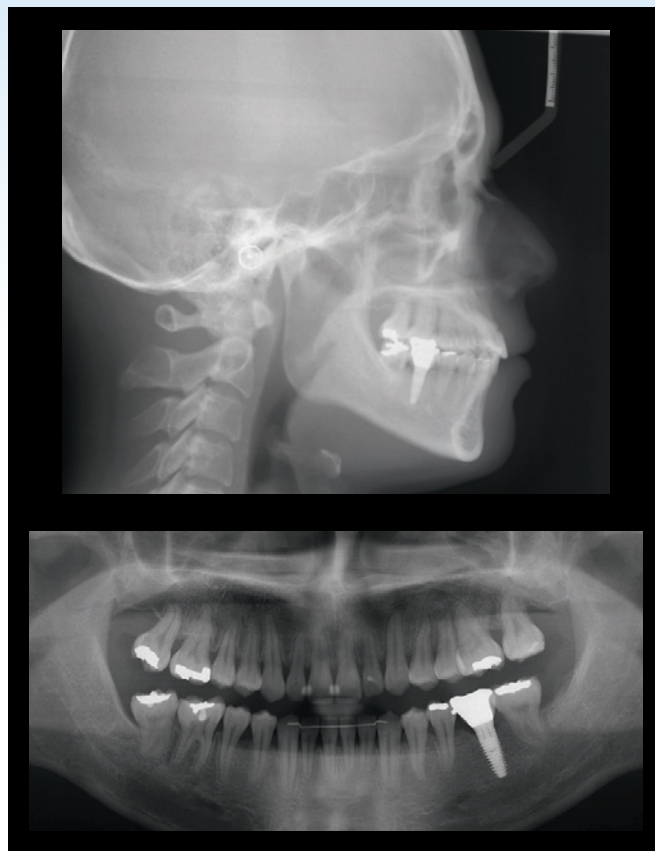
■ Fig. 5: Posttreatment intraoral photographs



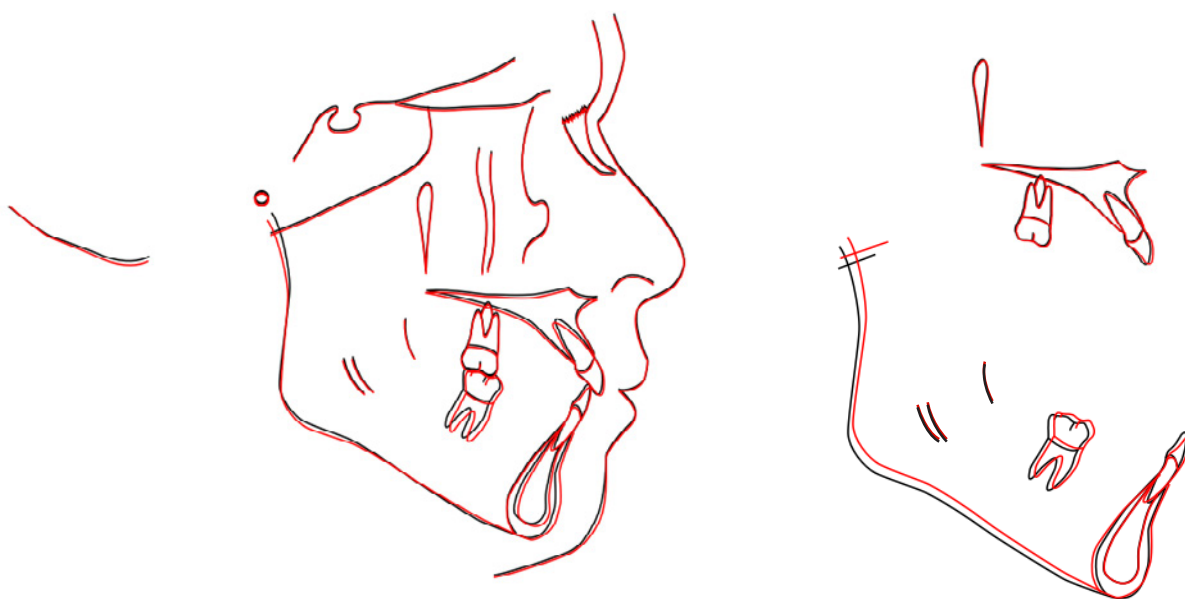
■ Fig. 6: Posttreatment study models



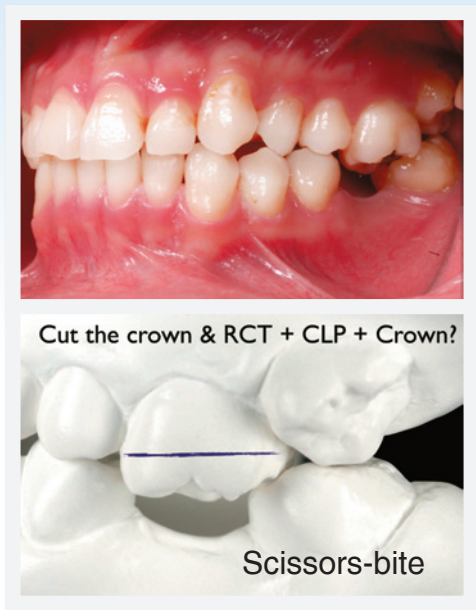
■ Fig.7: Pretreatment pano and ceph radiographs



■ Fig. 8: Posttreatment pano and ceph radiographs



■ Fig. 9: Superimposed tracings, Maintain Mx. & Md. A-P position, slightly flared U & L incisors.



■ Fig. 10:

Over-extrusion of a maxillary molar usually results from loss of its antagonist. The elongated edentulous space in the dentoalveolar process may lead to functional disturbances and occlusal interferences, that prove challenging for prosthetic reconstruction.

Treatment Plan

Non-extraction treatment with a full fixed orthodontic appliance was indicated to align and level the dentition. Occlusal posterior bite turbos were placed on the lower right first molar and cross elastics were used for the second molar scissors-bite correction. To intrude the supra-erupted molar (Fig. 10), an extra-alveolar miniscrew (2x12 mm, OrthoBoneScrew, Newton's A, Inc.) was inserted in the hard palate, 3 mm away from mid-palatal suture (Fig. 11).²

Inter-maxillary elastics were used to correct the sagittal discrepancy and the occlusion was detailed with finishing bends. Fixed appliances were removed and the corrected dentition was retained with fixed anterior retainers on the lower arch and a clear overlay retainer on the upper arch.

CEPHALOMETRIC			
SKELETAL ANALYSIS			
	PRE-Tx	POST-Tx	DIFF.
SNA°	83°	83°	0°
SNB°	80°	81°	1°
ANB°	3°	2°	1°
SN-MP°	32°	33°	1°
FMA°	28°	29°	1°
DENTAL ANALYSIS			
U1 TO NA mm	5 mm	5 mm	0 mm
U1 TO SN°	112°	113°	1°
L1 TO NB mm	5 mm	6 mm	1 mm
L1 TO MP°	87°	89°	2°
FACIAL ANALYSIS			
E-LINE UL	0 mm	-1 mm	-1 mm
E-LINE LL	0 mm	0 mm	0 mm

■ Table. Cephalometric summary

Treatment Progress

For fixed appliance treatment, .022" slot Damon D3MX brackets (Ormco) were selected. The archwire sequence was: .014 NiTi, .016 NiTi, .014x.025 NiTi, .017x.025 TMA, and .016x.025 SS. Occlusal bite turbos, made with glass ionomer cement, were placed on lower right first molar. A button was bonded on the lingual side of the lower right second molar to accommodate upper and lower criss-cross elastics for scissors-bite correction.^{3,4} After six months of initial alignment and leveling, a panoramic film was taken. All malaligned brackets were rebonded.

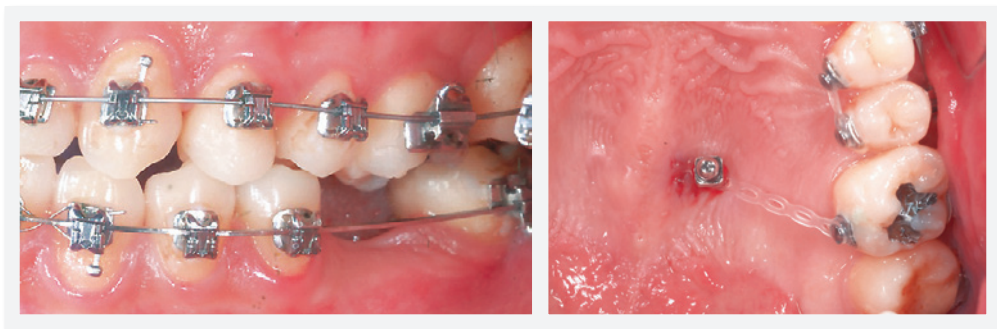
In the 17th month, an extra-alveolar miniscrew (2x12 mm, OrthoBoneScrew, Newton's A, Inc.) was inserted in the hard palate, 3 mm away from mid-palatal suture (Fig. 11). The miniscrew was connected to a lingual button on UL6, by a power chain designed to intrude the supra-erupted molar.

Implant Placement Procedures

The lower excessive space, due to the missing LL6 was slightly closed by sliding mechanics with power chains over an .016x22 SS wire. In the 18th month, an implant was installed to replace the missing LL6, using a surgical stent to guide the correct position of the fixture (Fig. 12).⁵ After opening of a full thickness

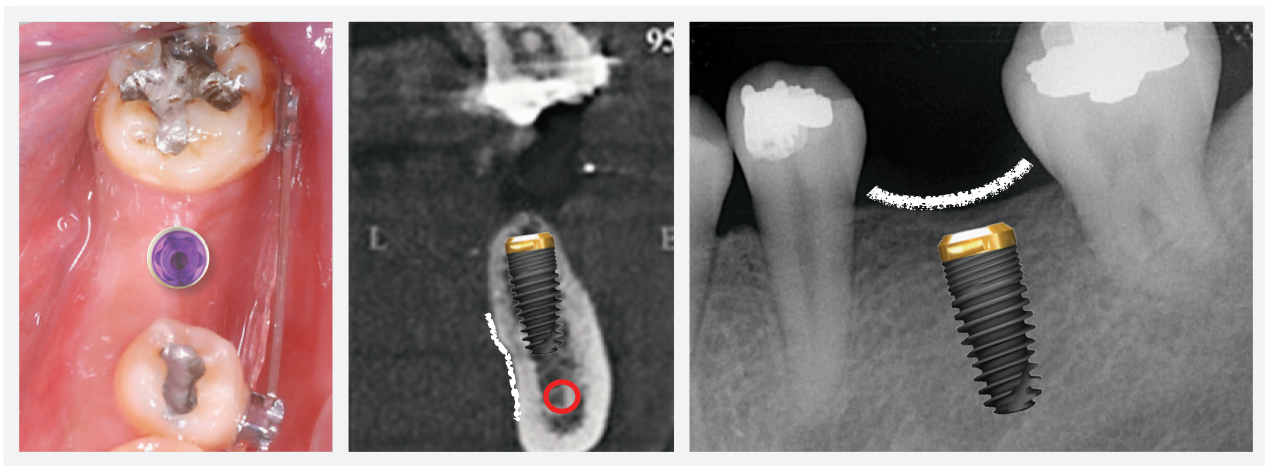
flap, the buccal flap was sutured on the cheek and lingual flap was tied with a needle holder and across over the mouth corner in order to obtain a clear surgical view (Fig. 13).

After the flap was elevated, the sharp edge of the



■ Fig. 11:

To intrude the palatal cusp of the supra-erupted molar, an extra-alveolar miniscrew (2x12 mm, OrthoBoneScrew, Newton's A, Inc.) was inserted in the hard palatine, 3 mm away from mid-palatal suture.

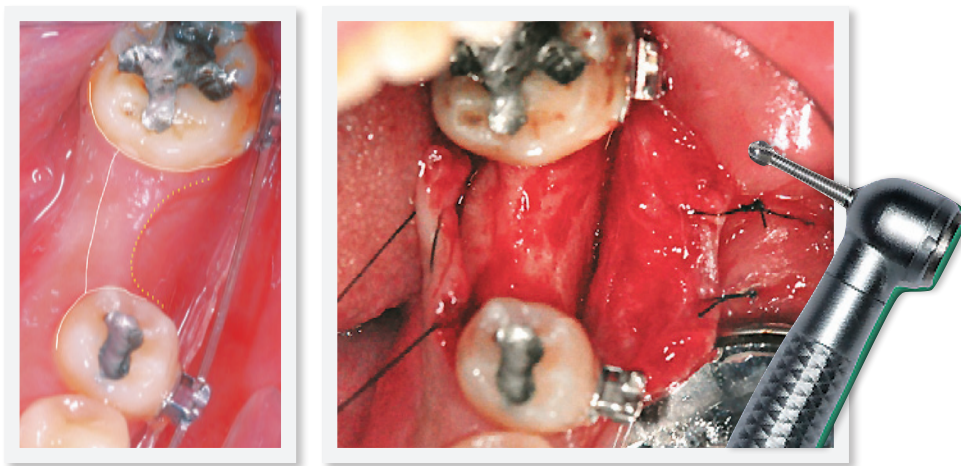


■ Fig. 12:

There are five factors for ideal implant position as follows: 1. M-D (center), 2. B-L (2 mm buccal bone thickness), 3. Depth (3mm depth from crown margin), 4. Angulation (max. 15°), 5. Distance to adjacent tooth / implant (≥ 1.5 mm for tooth, ≥ 3 mm for implant). From the CBCT slice view, anatomic risk factors on the mandible (inf. alveolar n. and lingual concavity) should be concerned.

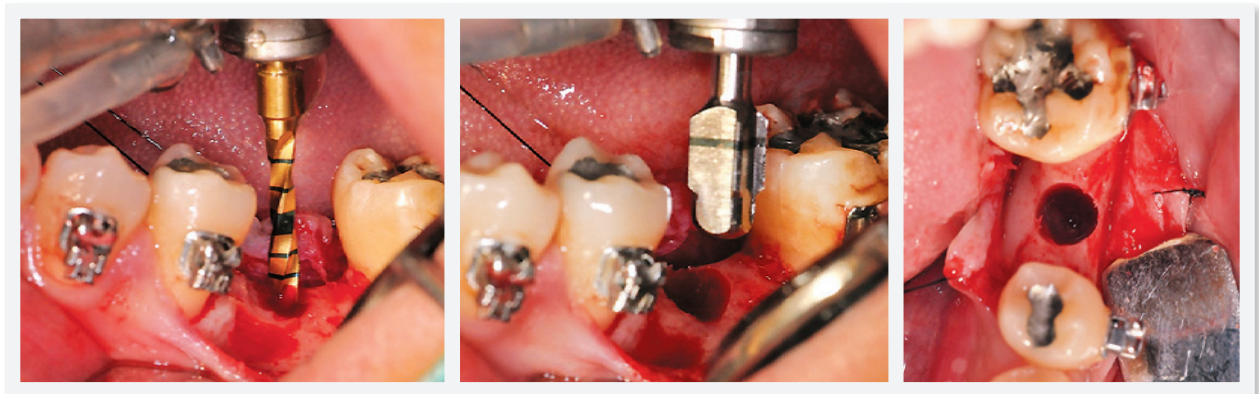
bone was removed with a carbide round bur. From the occlusal view of the ridge, there was enough width to place 4.8 diameter implant (Fig. 13). Following the recommended drilling protocol,⁶ a 4.8x11.5mm wide diameter fixture with pre-mounted abutment was placed (Fig. 14). The healing abutment

with a 3 mm gingival height was placed and the flap was sutured with direct loop interrupted 5-0 nylon suture (Fig. 15). Fig. 16 is a view of the postoperative radiographs. Figures 18, 19 show the 3 and 9-month, respectively, postoperative intra-oral photos and peri-apical films.



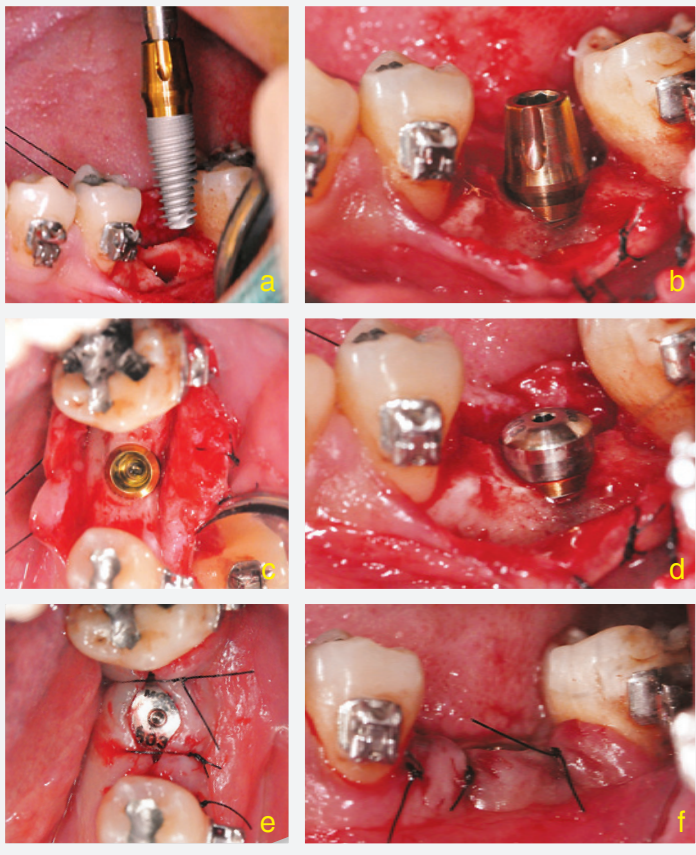
■ Fig. 13a, b:

Intra-sulcular and lingual horizontal incision were made and elevated the flap. the buccal flap was sutured on the cheek and lingual flap was tied with needle holder and across over the mouth corner in order to obtain the clear surgical view. Remove the sharp edge on the alveolar crest with carbide round bur.

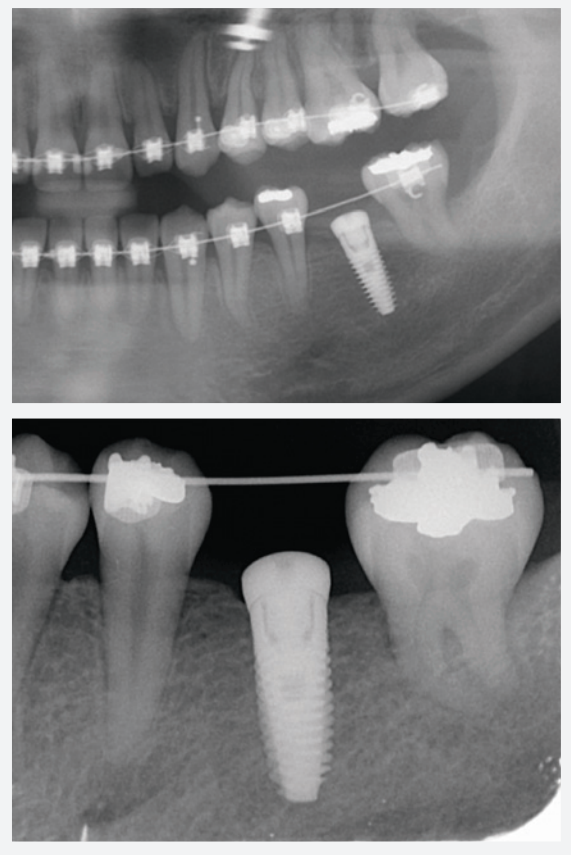


■ Fig. 14a, b, c:

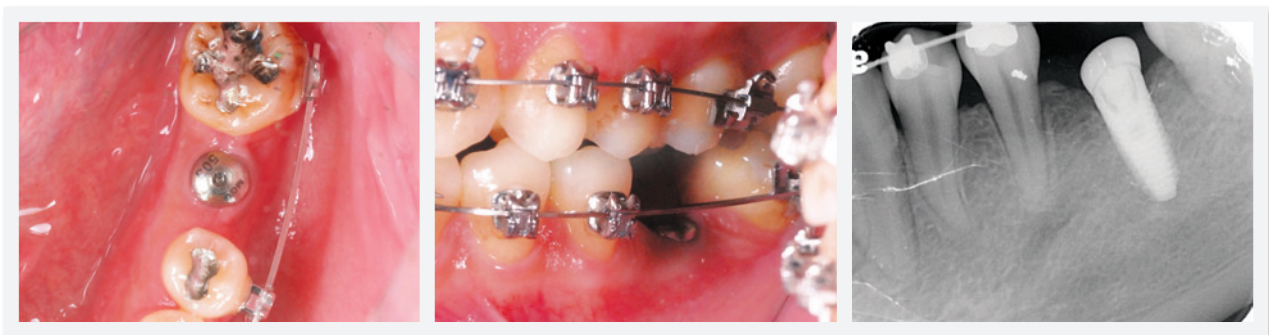Osteotomy procedure followed standard drilling sequence.



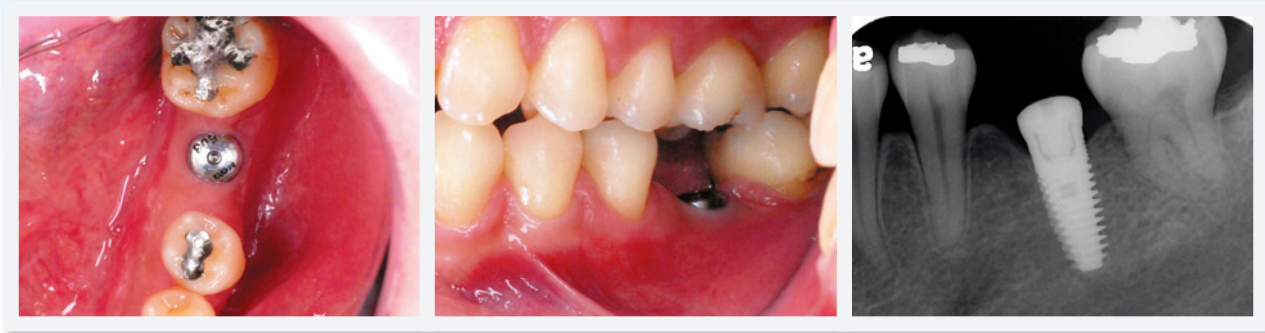■ Fig. 15a, b, c, d, e, f:
 4.8x11.5mm wide diameter fixture with premounted abutment was placed. The healing abutment with 3 mm gingival height replaced the abutment and sutured the flap with direct interrupted suture (5-0 Nylon).



■ Fig. 16:
 Post-Op panorex and periapical films



■ Fig. 17a, b, c: In the 21th of orthodontic tx. 3 months post-Op intra-oral photos and periapical film.

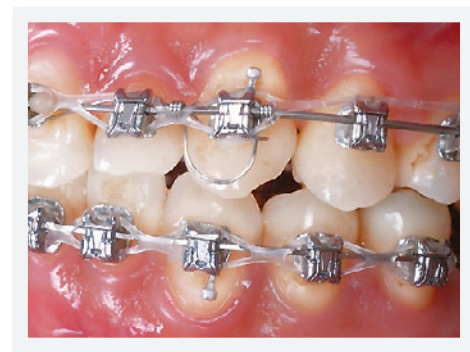

■ Fig. 18a, b, c: In the 28th of orthodontic tx. 9 months post-Op intra-oral photos and periapical film.

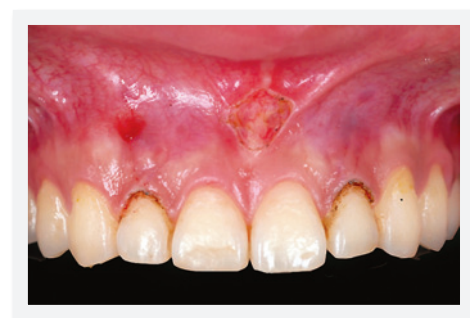Orthodontic Finishing

In the 19th month of treatment, a torquing spring was applied upside down on the UL3 for labial root torque (Fig. 19). Prefinish records, consisting of study casts and panoramic film, were reviewed to assess alignment, marginal ridge discrepancies etc. according to American Board of Orthodontics' (ABO) evaluation standards, using the Cast-Radiographic Evaluation sheet. Teeth with second order axial inclination problems were adjusted by rebonding the brackets.⁷

In the 27th month, the upper archwire was sectioned distal to the canines, one month prior to the completion of treatment. Light up and down elastics (2 oz) were used for final detailing. Appliances were removed and retainers were delivered. Maxillary midline frenectomy and gingivoplasty of the maxillary lateral incisors was accomplished with a diode laser (Fig. 20). The single implant to replace the missing LL6 for #36 was referred for restorative care (Figures 21-26).⁸



■ Fig. 19:
In the 19th month of treatment, a torquing spring was applied upside down on the UL3 for labial root torque.

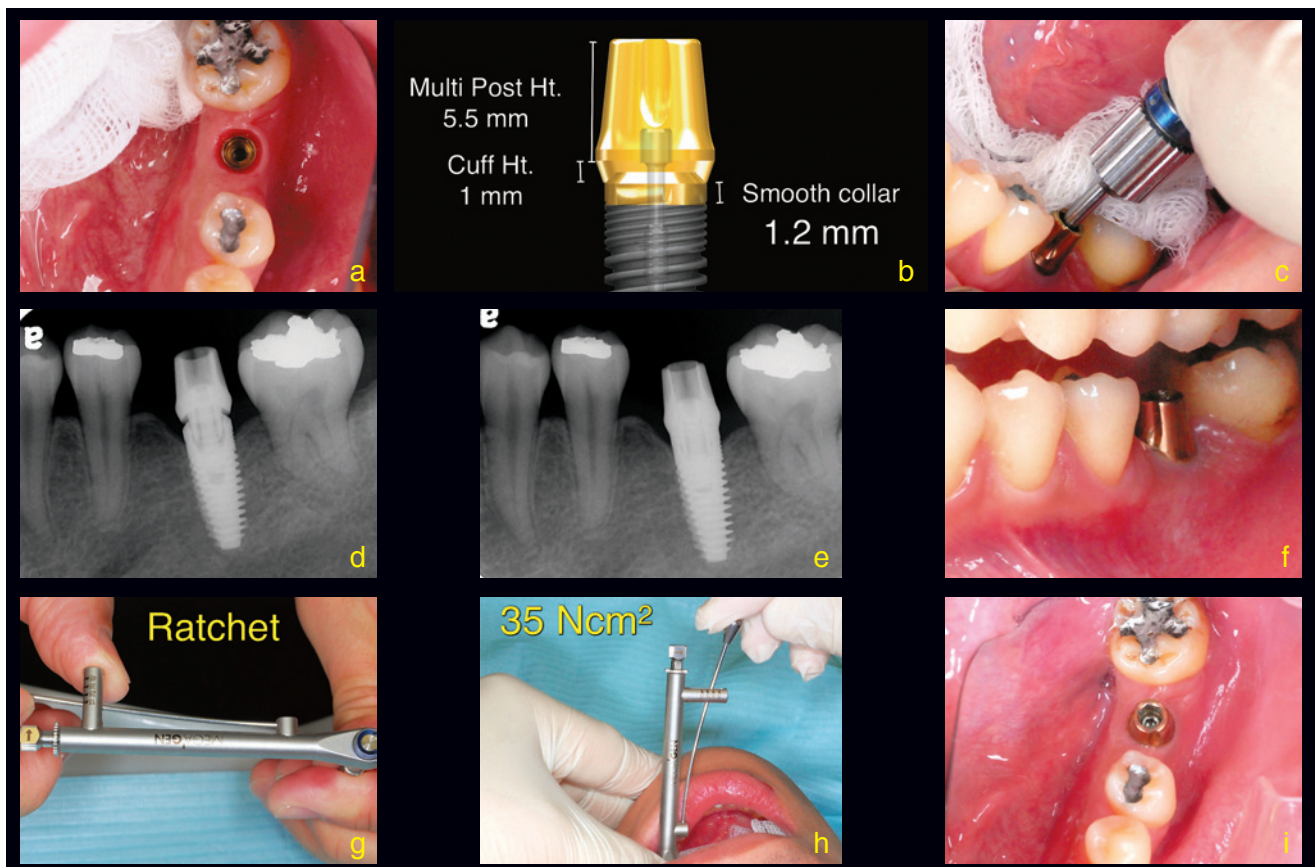


■ Fig. 20:
Maxillary midline frenectomy and gingivoplasty of the maxillary lateral incisors was accomplished with a diode laser.

Implant Prosthesis Fabrication

The healing abutment was removed and replaced with a multi-post abutment that had a 5.5 mm post height and 1 mm cuff height from the implant fixture.⁹ Fig. 21d showed the abutment did not seat completely, so it was adjusted until the abutment was well seated. The torque ratchet was applied on the screw until 35 Ncm was achieved (Fig. 21). A direct impression, made with polyvinyl siloxane, was poured with type IV dental stone, and the casts were subsequently articulated using the appropriate check-bite records (Fig. 22). Metal coping was

fabricated by the laboratory, and marginal integrity was verified with a dental explorer (Fig. 23). Appropriate tightness of the contact area was confirmed with dental floss (Fig. 24). The occlusal area was made of metal, with a screw access hole, and porcelain was baked onto the buccal surface (Fig. 25). After clinical adjustment and verification of the fit and occlusion, the definitive crown was completed and luted to place with permanent cement. The screw access hole was filled with composite resin (Fig. 26).¹⁰



■ Fig. 21a, b, c, d, e, f, g, h, i:

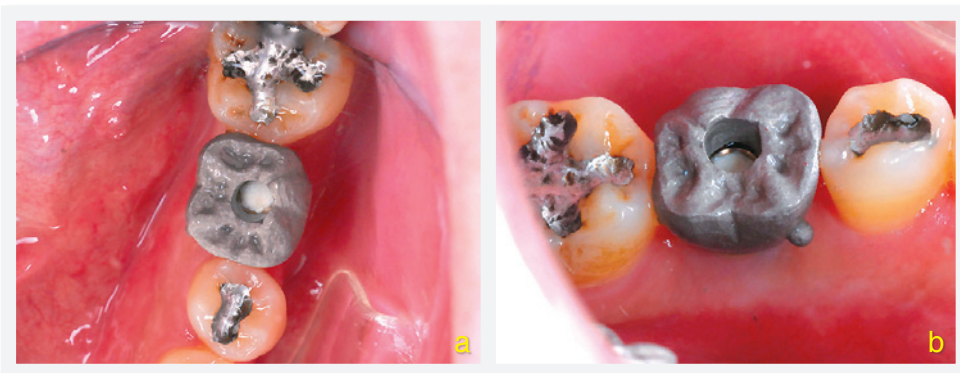The healing abutment was removed and replaced with a multi-post abutment that had a 5.5 mm post height and 1 mm cuff height from the implant fixture. Fig. 21d showed the abutment did not seat completely, so it was adjusted until the abutment was well seated. The torque ratchet was applied on the screw until 35 Ncm was achieved.



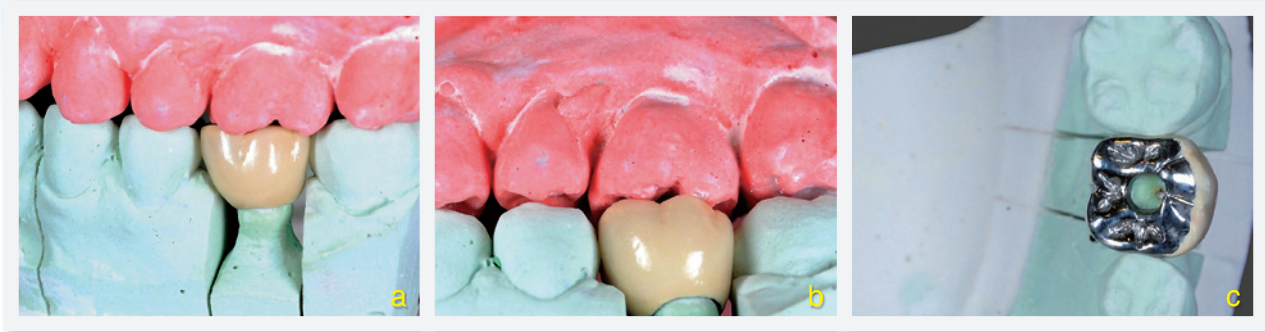■ Fig. 22a, b:
A direct impression, made with polyvinyl siloxane, was poured with type IV dental stone, and the casts were subsequently articulated using the appropriate check-bite record



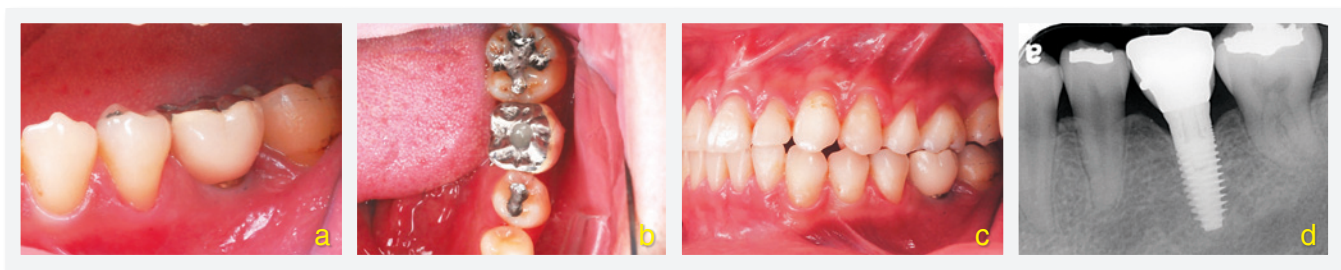■ Fig. 23a, b, c:
Metal coping was fabricated by the laboratory, and marginal integrity was verified with a dental explorer.



■ Fig. 24a, b:
Appropriate tightness of the contact area was confirmed with dental floss.



■ Fig. 25a, b, c: The final prosthesis.



■ Fig. 26a, b, c, d:

After clinical adjustment and verification of the fit and occlusion, the definitive crown was completed and luted to place with permanent cement. The screw access hole was filled with composite resin.

Results Achieved

Maxilla (all three planes):

- A - P: Maintained
- Vertical: Maintained
- Transverse: Maintained

Mandible (all three planes):

- A - P: Maintained
- Vertical: Maintained
- Transverse: Maintained

Maxillary Dentition

- A - P: Slightly flared incisors ~1 degree
- Vertical: Maintained
- Inter-molar / Inter-canine Width: Maintained

Mandibular Dentition

- A - P: Flared incisors ~2 degrees
- Vertical: Extruded molars
- Inter-molar / Inter-canine Width: Maintained

Facial Esthetics: Maintained

Retention

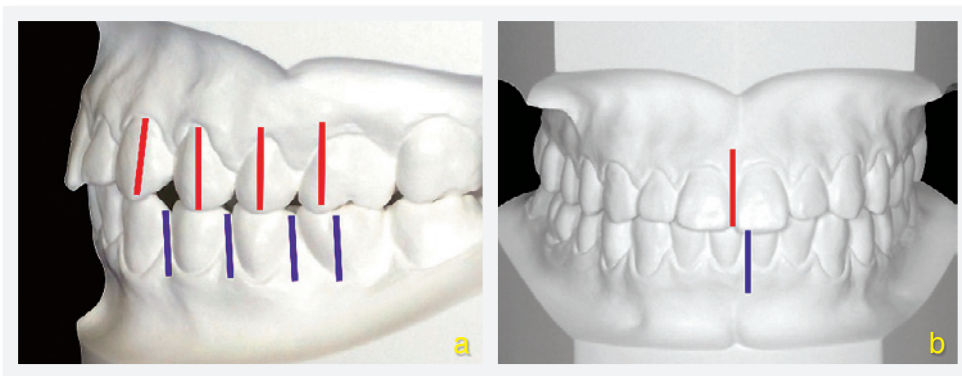
The lower fixed retainer 3-3 was bonded on every tooth. An upper clear overlay was delivered. The patient was instructed to wear it full time for the first 6 months and nights only thereafter. The patient was instructed relative to home care and maintenance of the retainers.

Final Evaluation of Treatment

The IBOI Cast-Radiograph Evaluation scored at 26 points, which was deemed satisfactory for a board case report. The major discrepancies were problems in alignment/rotation, marginal ridge discrepancies, inclination, occlusal contacts and occlusal relationships. The lower midline was shifted to the left for about 2mm, resulting in a Class II molar, premolar and canine relationship on the left side (Fig. 27). Overall, there was significant improvement in both the alignment of the edentulous area and final occlusion. The patient was satisfied with the improved chewing function on the left side.

Discussion

Over-extrusion of a maxillary molar usually results from loss of its antagonist. The elongated edentulous space in the dentoalveolar process may lead to functional disturbances and occlusal interferences, that prove challenging for prosthetic reconstruction. Conventional options for correcting the problem include: 1. coronal reduction of the molar crown, which may require root canal therapy and a full coverage restoration, or 2. posterior subapical osteotomy, with the risks of general anesthesia and molar devitalization, as well as high cost. Orthodontic intrusion of maxillary molars is difficult because a force applied on the buccal surface tends to move the root palatally, resulting in excessive occlusal prominence of the palatal cusp. Conventional techniques for intrusion require anchorage reinforcement by incorporating multiple teeth in the anchorage segment and/or the use of extraoral devices that depend heavily on patient cooperation. Routine orthodontics mechanics often result in extrusion of the anchorage teeth rather



■ Fig. 27a,b:

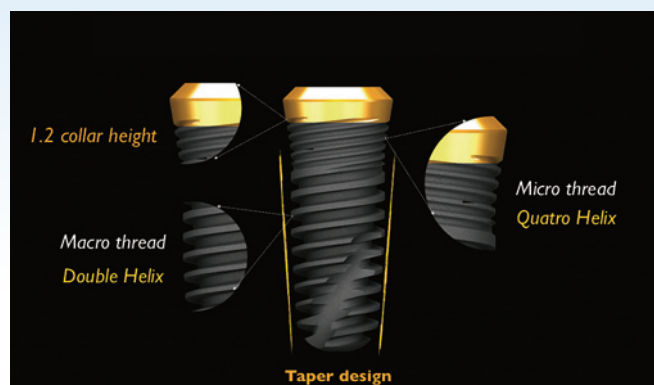
The lower midline was shifted to the left for about 2mm, resulting in a Class II molar, premolar and canine relationship on the left side.

than intrusion of the extruded tooth. Preventing this side effect is the key to successful intrusion.

Skeletal anchorage, including dental implants, surgical miniplates, and miniscrews, is growing in popularity because they provide relatively rigid anchorage. For the present patient, a miniscrew was placed 2 to 3 mm away from the midpalatal suture to provide anchorage for molar intrusion. Placing the miniscrew away from the midpalatal suture avoids disturbing an important site for growth and skeletal adaptation in the maxilla. To inhibit root resorption, intrusive force levels should be kept relatively low. Although an optimal force has not yet been established for intrusion with miniscrews.¹¹

Regarding to implant selection, the Taiwan Star system (*TS system*) was selected for its tapered design, 1.2 mm smooth collar, micro thread subcollar segment, and macro thread substructure (*Fig. 28*). The macro-thread substructure has a double helix design, with deep threads and a cutting edge at the apex. These surface features can provide faster and smoother self-tapping and a strong initial stability even in type IV bone (*Fig. 29*).¹² The micro-thread subcollar segment was introduced on the Astra Tech Implant System as early as 1992 and can reduce the peak stress values in the bone, inhibiting load-induced marginal bone loss¹³. Quatro-helix design can provide more initial bone contacts, prevent early bone loss and achieve faster osseointegration (*Fig. 30*).¹³

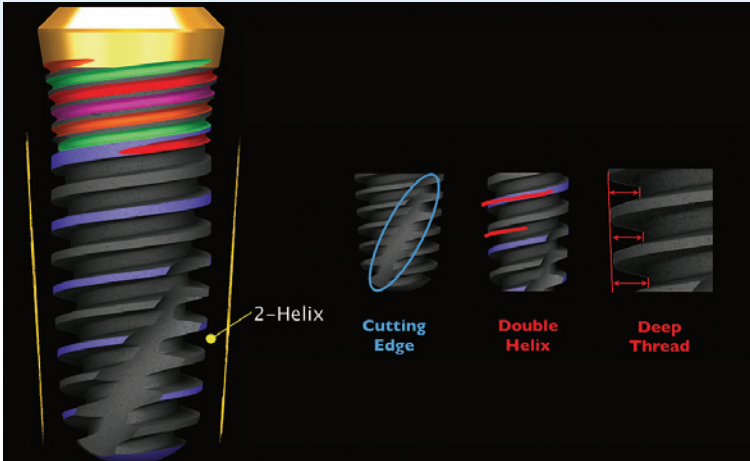
When the implant fixture is placed at the same bone level, different implant designs will cause different



■ *Fig. 28:*

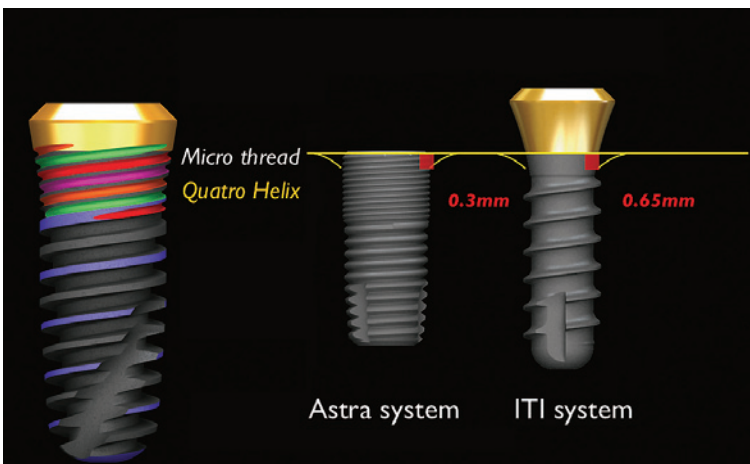
The Taiwan Star system (TS system) was selected for its tapered design, 1.2 mm smooth collar, micro thread subcollar segment, and macro thread substructure.

amounts of the bone loss. The TS system has a 1.2 mm smooth collar on the neck. Such implant fixtures can be placed on the submerged type or non-submerged type (*Fig. 31*). For the Submerged position (1.2mm smooth collar below the bone level), the marginal bone loss may be equal to the external system, that is ~1.5 mm (*Fig. 32*). As for the non-submerged position (1.2mm smooth collar above the bone level), the average marginal bone loss of the ITI system is 0.65mm.¹⁴ The TS system has a micro-thread design similar to the Astra system and is compatible with platform switching abutments. The marginal bone loss may be much less than ITI system and equal to 0.3 mm (*Fig. 33*).¹⁴ For the present patient, the implant fixture was placed with a non-submerged method and a 2 piece multi-post abutment was selected. The crown margin was slightly supra-gingival (*Fig. 26a*). The cement was readily removed and the oral hygiene around smooth collar was easily maintained. This approach was acceptable for the lower posterior “unesthetic” zone. The supra-gingival crown margin could be



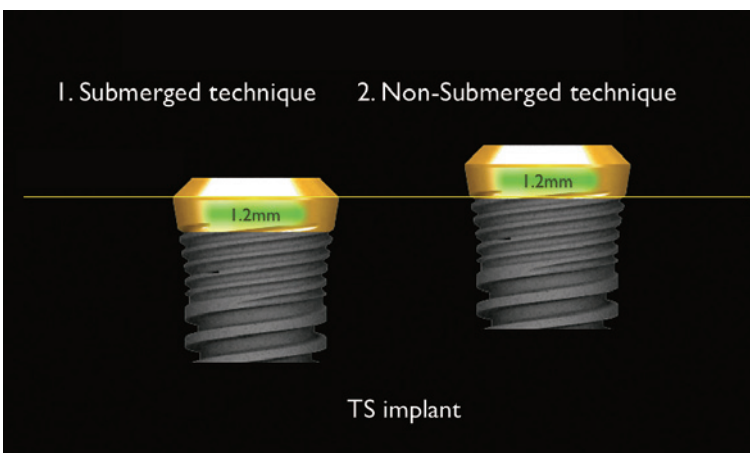
■ Fig. 29:

The macro-thread substructure has a double helix design, with deep threads and a cutting edge at the apex. These surface features can provide faster and smoother self-tapping and a strong initial stability even in type IV bone.



■ Fig. 30:

The micro-thread subcollar segment was introduced on the Astra Tech Implant System as early as 1992 and can reduce the peak stress values in the bone, inhibiting load-induced marginal bone loss. Quatro-helix design can provide more initial bone contacts, prevent early bone loss and achieve faster osseointegration.



■ Fig. 31:

The TS system have 1.2 mm smooth collar on the neck. we can place the implant fixture on the submerged type or nonsubmerged type.

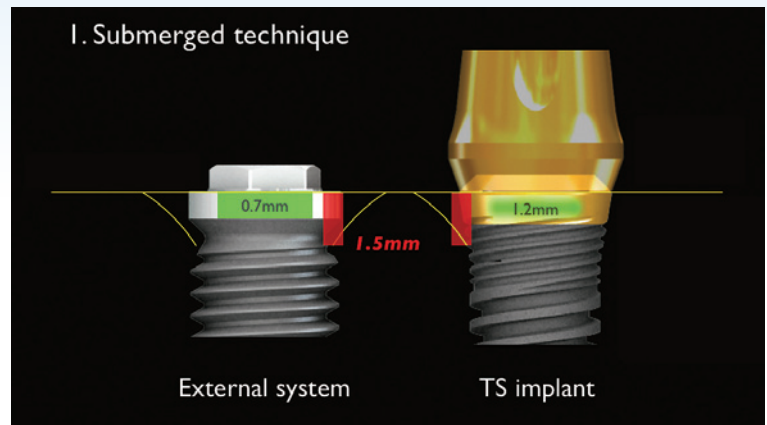
moved more apically and the restoration would be more natural-looking. The ideal implant location should be based on the cervical contour of the planned restoration planned at 3mm depth and 2mm to the lingual (*note: preserve at least 2mm of buccal bone plate*). If the buccal bone plate is less than 2mm (*Fig. 34a*), the options are: 1. place the implant more lingually, 2. choose a smaller diameter implant fixture, and/or 3. augment buccal bone with GBR procedure (*Figures 34b, c, d*), to improve buccal bone thickness.

Conclusion

Premature loss of lower first molars is frequently observed in Taiwan. This condition often results in extrusion of the antagonist maxillary molar, mesial-tilting of mandibular second molar, occlusal interferences, and great difficulty for future prosthetic reconstruction. This article attempts to present an alternative implant-ortho, combined treatment strategy for addressing this common issue. Details on the orthodontic and implant treatment process are provided as a guide to clinicians.¹⁸

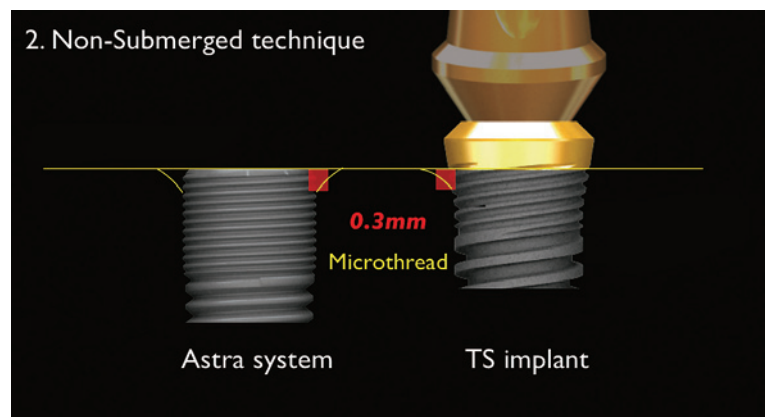
Acknowledgment

Thanks to Ms. Tzu Han Huang and Dr. Park for proofreading this article.



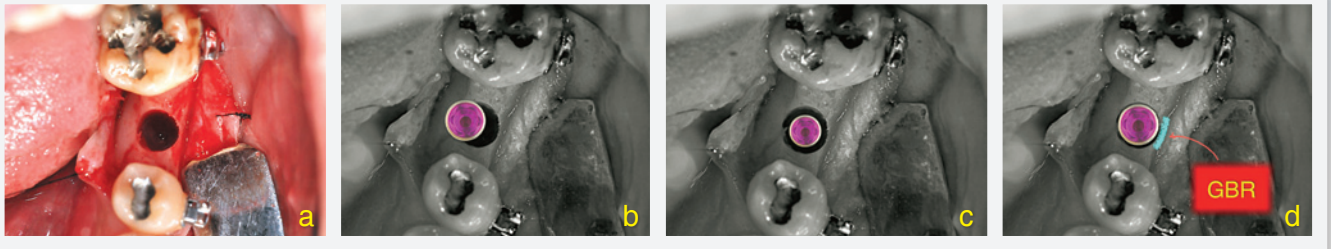
■ Fig. 32:

For the Submerged position (1.2mm smooth collar below the bone level), the marginal bone loss may be equal to the external system, that is ~1.5 mm.



■ Fig. 33:

For the non-submerged position (1.2mm smooth collar above the bone level), the average marginal bone loss of the ITI system is 0.65mm. The TS system has a micro-thread design similar to the Astra system and is compatible with platform switching abutments. The marginal bone loss may be much less than ITI system and equal to 0.3 mm.



■ Fig. 34a, b, c, d:

If the buccal bone plate is less than 2mm, we can: 1. place the implant more lingually (b), 2. choose the smaller diameter implant fixture (c), 3. augment buccal bone with GBR procedure, to improve the buccal bone thickness (d).

References

1. Su B. The ABO Discrepancy Index: A Measure of Case Complexity. *News & Trends in Orthodontics* 2009;13:24-27.
2. Tseng SP, Chang CH, Roberts WE. Impacted Maxillary Canines on Both Sides: One Palatally and One Labially. *News & Trends in Orthodontics* 2011;22:22-35.
3. Su B, Chang HN, Roberts WE. Molar Scissors-bite Correction. *News & Trends in Orthodontics* 2009;16:84-92.
4. Wu CY, Chang HN, Roberts WE. Impinging Overbite and Large Overjet. *News & Trends in Orthodontics* 2009;14:42-48.
5. Hsieh CL, Fernando RV. Prosthetics Considerations in Treatment Planning-The Restoration of the Cervical Contour: A Key to Implant Planning, Placement, and Restoration. *News & Trends in Orthodontics* 2011;21:82-88.
6. <http://www.tplusimplant.com.tw/p2-products.asp>
7. Huang CH. American Board of Orthodontics: Objective Grading System for Dental Casts and Panoramic Radiographs. *News & Trends in Orthodontics* 2009;13:28-31.
8. Hsiao HY, Su B, Hsu YL et al. Approaching Efficient Finishing: Hard and Soft Tissue Contouring. *News & Trends in Orthodontics* 2008;11:16-22.
9. Liou FY, Baldwin WM. Principles of Abutment Selection for the Single Implant. *News & Trends in Orthodontics* 2011;22:74-82.
10. Patel D, Invest JC, Tredwin CJ. An Analysis of the Effect of a vent hole on excess cement expressed at the crown-abutment margin for cement-retained implant crowns. *J Prosthodont.* 2009 Jan;18 (1):54-59.
11. Farzin H, Shahin B, Azam SM et al. Intrusion of Supra-erupted molars Using Miniscrews: Clinical Success and Root resorption. *Am J Orthod Dentofacial Orthop.* 2011;139:S170-175.
12. <http://www.tplusimplant.com.tw/p2-products5.asp>
13. Daniel B, Willian M, Belser UC. Optimizing Esthetics for Implant Restorations in the Anterior Maxilla: Anatomic and surgical Considerations. *Int J Oral Maxillofac Implants.* 2004;19 (SUPPL):43-61.
14. Lee DW, Choi YS, Park KH et al. Effect of Microthread on the Maintenance of Marginal Bone Level: A 3-year Prospective Study. *Clin Oral Implants Res.* 2007;18 (4):465-470.
15. Chang CH. Advanced Damon Course No. 9: Molar Scissors-bite Correction. *Beethoven Podcast Encyclopedia in Orthodontics* 2011, Newton's A Ltd, Taiwan
16. Chang CH. Implant Forum Course No. 1: IAOI Case Demo: Ortho-implant Combined Case. *Beethoven Podcast Encyclopedia in Orthodontics* 2011, Newton's A Ltd, Taiwan
17. Chang CH. Advanced Damon Course No. 4,5 : DI & CRE Workshop (1) (2)., *Podcast Encyclopedia in Orthodontics* 2011, Newton's A Ltd, Taiwan.
18. Chang C, Roberts WE. *Orthodontics, 3D iBooks Ortho.*, Taiwan: Newton's A Ltd, 2012.

IBOI Discrepancy Index Worksheet

TOTAL D.I. SCORE = 16

OVERJET

0 mm. (edge-to-edge) = _____
 1 – 3 mm. = 0 pts.
 3.1 – 5 mm. = 2 pts.
 5.1 – 7 mm. = 3 pts.
 7.1 – 9 mm. = 4 pts.
 > 9 mm. = 5 pts.
 Negative OJ (x-bite) 1 pt. per mm. per tooth = _____

Total = 0

OVERBITE

0 – 3 mm. = 0 pts.
 3.1 – 5 mm. = 2 pts.
 5.1 – 7 mm. = 3 pts.
 Impinging (100%) = 5 pts.
 Total = 0

ANTERIOR OPEN BITE

0 mm. (edge-to-edge), 1 pt. per tooth
 then 1 pt. per additional full mm. per tooth
 Total = 0

LATERAL OPEN BITE

2 pts. per mm. per tooth
 Total = 0

CROWDING (only one arch)

1 – 3 mm. = 1 pt.
 3.1 – 5 mm. = 2 pts.
 5.1 – 7 mm. = 4 pts.
 > 7 mm. = 7 pts.
 Total = 0

OCCLUSION

Class I to end on = 0 pts.
 End on Class II or III = 2 pts. per side _____ pts.
 Full Class II or III = 4 pts. per side _____ pts.
 Beyond Class II or III = 1 pt. per mm. _____ pts.
 additional
 Total = 2

LINGUAL POSTERIOR X-BITE

1 pt. per tooth Total = 1

BUCCAL POSTERIOR X-BITE

2 pts. per tooth Total = 4

CEPHALOMETRICS (See Instructions)

ANB ≥ 6° or ≤ -2° = 4 pts.
 Each degree < -2° _____ x 1 pt. = _____
 Each degree > 6° _____ x 1 pt. = _____
 SN-MP
 ≥ 38° = 2 pts.
 Each degree > 38° _____ x 2 pts. = _____
 ≤ 26° = 1 pt.
 Each degree < 26° _____ x 1 pt. = _____
 I to MP ≥ 99° = 1 pt.
 Each degree > 99° _____ x 1 pt. = _____

Total = 0

OTHER (See Instructions)

Supernumerary teeth _____ x 1 pt. = _____
 Ankylosis of perm. teeth _____ x 2 pts. = _____
 Anomalous morphology _____ x 2 pts. = _____
 Impaction (except 3rd molars) _____ x 2 pts. = _____
 Midline discrepancy (≥3mm) @ 2 pts. = 2
 Missing teeth (except 3rd molars) x 1 pts. = 2
 Missing teeth, congenital _____ x 2 pts. = _____
 Spacing (4 or more, per arch) _____ x 2 pts. = _____
 Spacing (Mx cent. diastema ≥ 2mm) @ 2 pts. = _____
 Tooth transposition _____ x 2 pts. = _____
 Skeletal asymmetry (nonsurgical tx) @ 3 pts. = _____
 Addl. treatment complexities 2 x 2 pts. = 4

Identify:

Total = 8

IMPLANT SITE

Lip line : Low (0 pt), Medium (1 pt), High (2 pts) = 0
 Gingival biotype : Low-scalloped, thick (0 pt), Medium-scalloped, medium-thick (1 pt), High-scalloped, thin (2 pts) = 1
 Shape of tooth crowns : Rectangular (0 pt), Triangular (2 pts) = 0
 Bone level at adjacent teeth : ≤ 5 mm to contact point (0 pt), 5.5 to 6.5 mm to contact point (1 pt), ≥ 7mm to contact point (2 pts) = 0
 Bone anatomy of alveolar crest : H&V sufficient (0 pt), Deficient H, allow simultaneous augment (1 pt), Deficient H, require prior grafting (2 pts), Deficient V or Both H&V (3 pts) = 0
 Soft tissue anatomy : Intact (0 pt), Defective (2 pts) = 0
 Infection at implant site : None (0 pt), Chronic (1 pt), Acute(2 pts) = 0

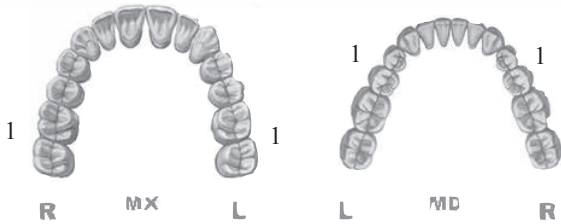
IBOI Cast-Radiograph Evaluation

Case # 1 Patient

Total Score: **26**

Alignment/Rotations

4

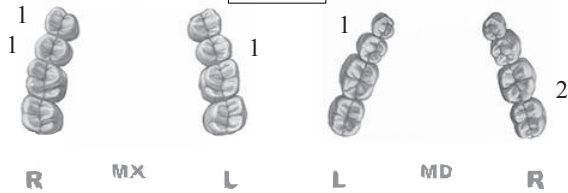


2 1
1

2 2

Marginal Ridges

6



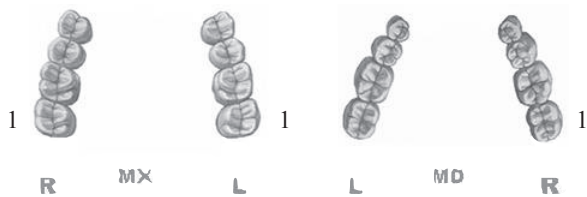
Occlusal Relationships

4

1
1 1 1 1

Buccolingual Inclination

3

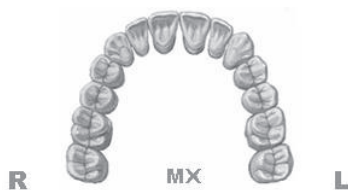

Interproximal Contacts

0

Overjet

0



1

1

INSTRUCTIONS: Place score beside each deficient tooth and enter total score for each parameter in the white box. Mark extracted teeth with "X". Second molars should be in occlusion.

ENDODONTIC SOLUTIONS

Strategies for Endodontic

Predictability and Profitability

競爭力 雙贏策略
抓對重點 · 超越盲點

Dr. Glassman
June 03, 2012 - Taipei

INTRODUCTION OF LECTURE

臨床上，造成根管治療失敗的原因繁雜，最常見的則是根管未徹底清創修形完全，以及封填不緻密等問題。

此次演講中將教導醫師如何利用高科技的技術、便利的

機器準確定位 apex constriction。並詳細探討鎳鈦銼針系統的設計特點與使用方法，利用鎳鈦旋轉銼針 TF 修形達成令人滿意且可預期的治療效果。

在3D形態的根管中，採用

Continuous Wave 封填技術，達成緻密無滲漏的根管封填。期望參加者能善用各種器具，透過簡單、快速有系統的步驟，在臨床上有自信的展現高品質的根管治療技術，提昇根管治療的品質。



SPEAKER

Dr. Gary Glassman graduated from the University of Toronto, Faculty of Dentistry in 1984 graduated from the Endodontology Program at Temple University in 1987 where he received the Louis I. Grossman Study Club Award for academic and clinical proficiency in Endodontics. The author of numerous publications, Dr. Glassman lectures globally on endodontics and is on staff at the University of Toronto, Faculty of Dentistry in the graduate department of endodontics. Gary is a fellow of the Royal College of Dentists of Canada, and the endodontic editor for Oral Health dental journal. He maintains a private practice, Endodontic Specialists in Toronto, Ontario, Canada. He can be reached through his website www.rootcanals.ca.

Organizer

台北醫學大學口腔醫學院
牙醫學系 牙髓病學科

Co-Organizer

台北醫學大學附設醫院牙髓病科
台北醫學大學萬芳醫院牙髓病科
台北醫學大學署立雙和醫院牙髓病科
湧傑企業股份有限公司

Time

2012.6 / 03 週日 9:00am~5:00pm

Venue

台北醫學大學綜合大樓 16F 演講廳
台北市信義區吳興街250號

Speaker

Dr. Gary Glassman

Fee

5/15 前會 員2500元
非 會員3000元
學生會員2000元
5/15 後會 員3500元
非 會員4000元
學生會員3000元

Certification

參加者發給繼續教育學分證明

LECTURE INFORMATION

Registration

請先電話報名：
TEL：(02)2778-8315 #124 王's
並於三日內劃撥款項
劃撥戶名：湧傑企業股份有限公司
帳號：17471807

凡報名繳費即**贈送**：
TF 旋轉金鋼鎳鈦銼針一組
TF Gutta Percha TF 馬來膠針一組



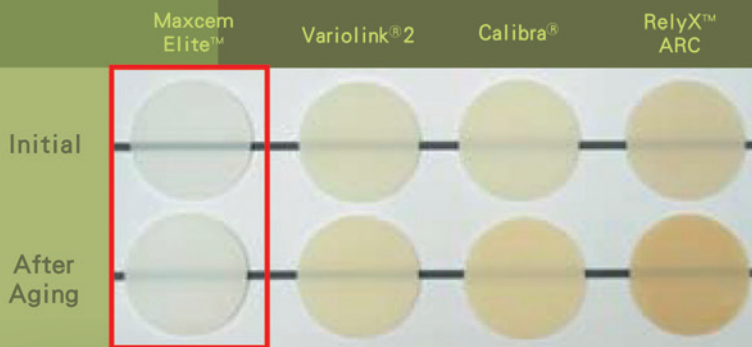Maxcem



高強度二合一多功能樹脂黏著劑

Elite Self-Etch Self-Adhering Resin Cement

Maxcem Elite與傳統樹脂黏著劑的色彩穩定度比較表
(Clear Shade自聚合後置於37°C水中經過28週之結果)



Ease of use

自動混合管操作快速簡單

Color stability

色彩穩定性極佳不易變色

Bond strengths between 22-36 MPa

超高黏著強度

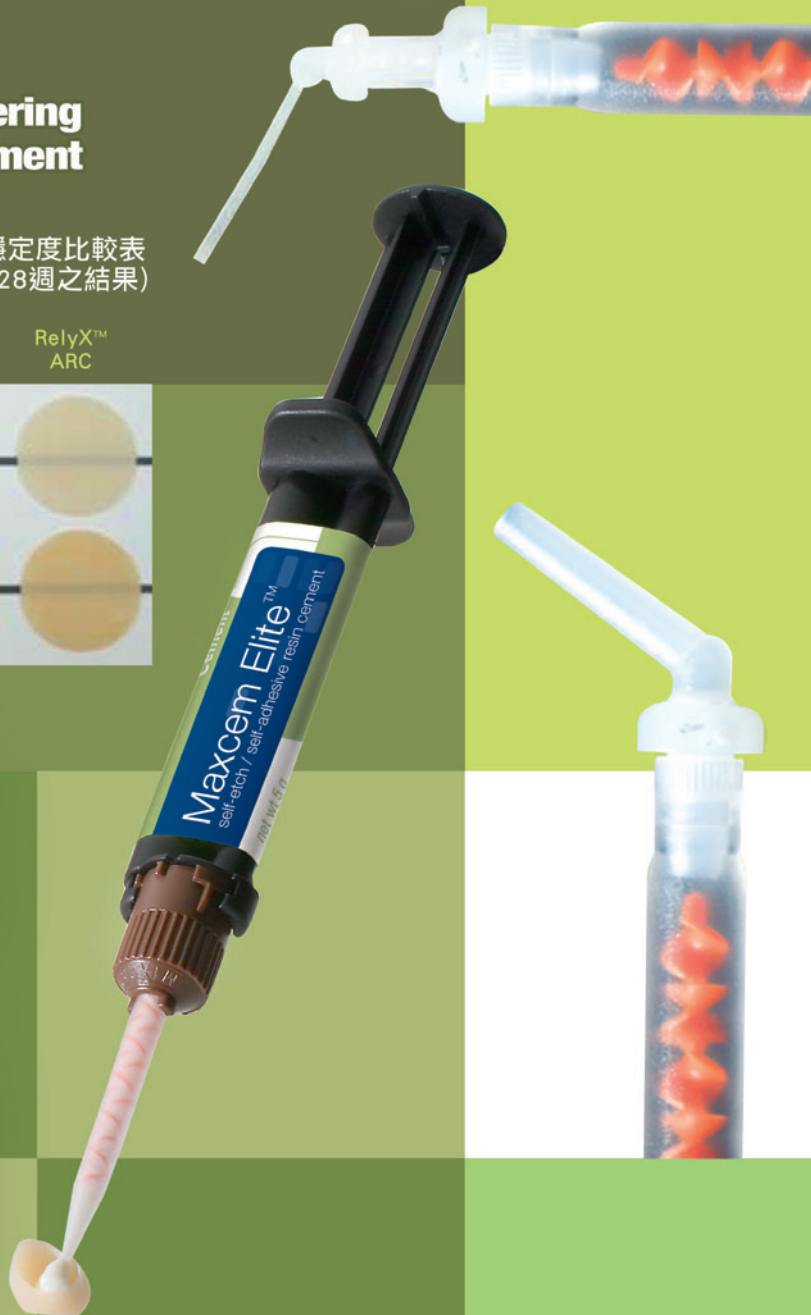Efficient self-cure mechanism

無光線照射也能完全聚合

Compatibility with common substrates

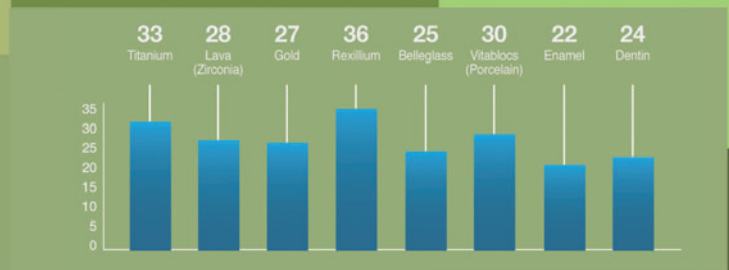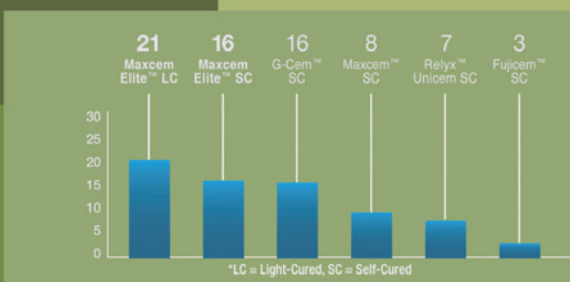
適用各種復形體：

Crowns, Bridges, Implants, Inlays, Onlays, Posts.....



Maxcem Elite(光照聚合)對各式復形體材質的黏著強度 (MPa)

樹脂黏著劑對象牙質的黏著強度(MPa)



Anterior Crowding with a Block-in Peg-shaped Lateral Incisor

History and Etiology

A 15-year-8-month female came to ask for full mouth evaluation because of the crooked display of her teeth when she smiled. After intraoral examination, both arches showed anterior crowding. A palatally malposed maxillary lateral incisor was noted (Fig. 9). There was no systemic diseases and known drug allergy. Her oral hygiene was acceptable. She received operative dental treatment in the past. There was no history of dental trauma or oral habits, and no significant signs and symptoms of temporomandibular dysfunction.

Diagnosis

Skeletal:

Skeletal Class I ($SNA\ 80^\circ$, $SNB\ 77^\circ$, $ANB\ 3^\circ$).

Dental:

Bilateral Class I molar relationship.

Severe crowding in both upper and lower arches. The lower dental midline shift 3 mm to left of the facial midline.

Block-out of #6, 11, 22, 27.

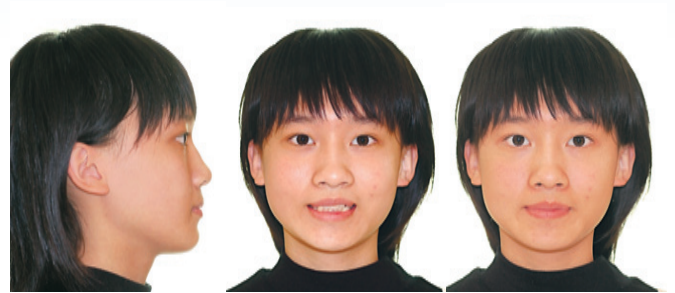
Anterior crossbite of #7, 27

Anomalous morphology of #7

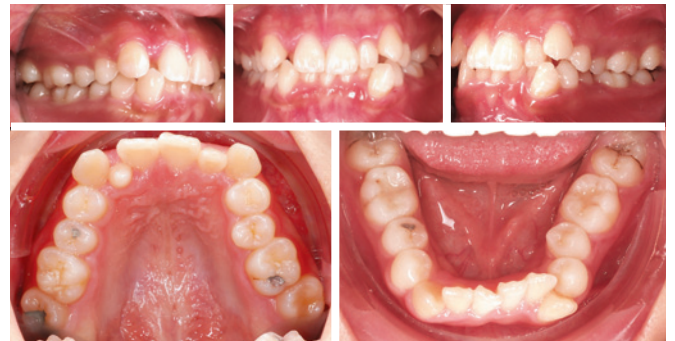Facial:

Straight profile with acceptable lip position.

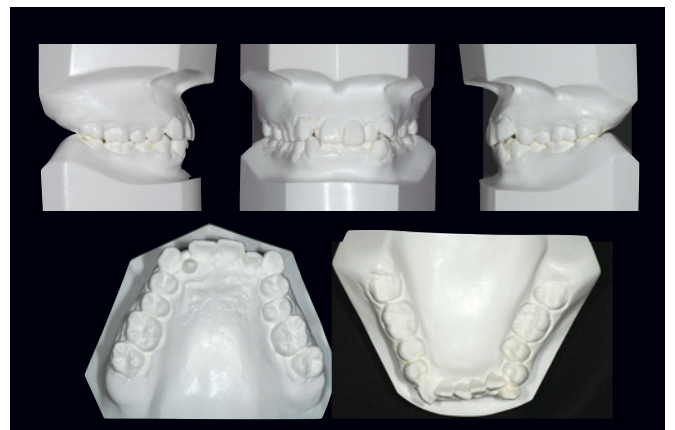Acceptable vertical proportion.



■ Fig. 1: Pretreatment facial photographs

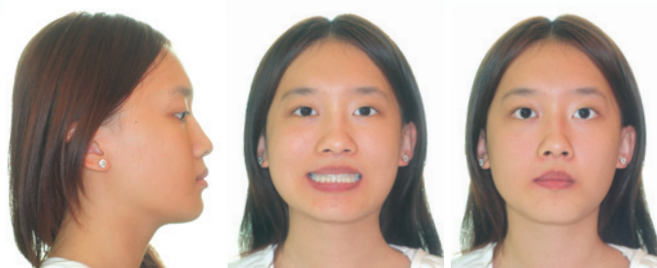

■ Fig. 2: Pretreatment intraoral photographs

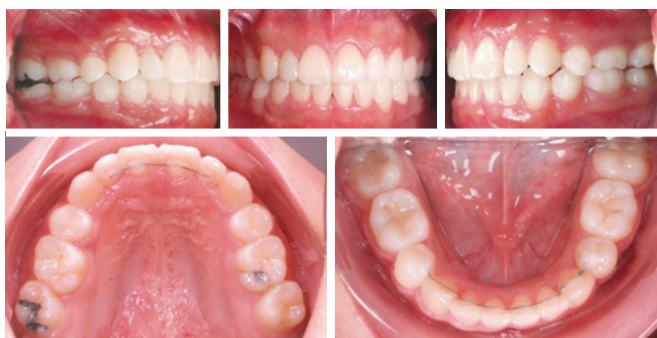

■ Fig. 3: Pretreatment study models

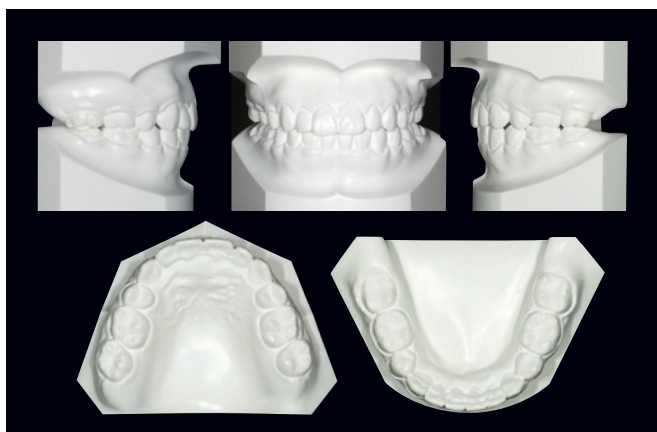Dr. Wei Lun Peng, Lecturer, Beethoven Orthodontic Course (right)
 Dr. Chris Chang, Director, Beethoven Orthodontic Center (middle)
 Dr. W. Eugene Roberts, Consultant,
International Journal of Orthodontics & Implantology (left)



■ Fig. 4: Posttreatment facial photographs



■ Fig. 5: Posttreatment intraoral photographs



■ Fig. 6: Posttreatment study models

Specific Objectives of Treatment

Maxilla (*all three planes*):

- A - P: Maintain.
- Vertical: Maintain a normal growth pattern
- Transverse: Maintain.

Mandible (*all three planes*):

- A - P: Maintain.
- Vertical: Allow normal expression of growth
- Transverse: Maintain.

Dentition :

- Maintain Class I molar relationship.
- Level both upper and lower dentition
- Correct #7, 27 crossbite
- Restore the morphology of #7

Facial Esthetics: Maintain straight profile.

Treatment Plan

For a straight profile with crowding dentition, extraction is often considered as an appropriate treatment option. In our present case, extraction of four bicuspids to create space was indicated. Considering significant amalgam fillings on the occlusal surface of #4 and #29, four second premolars were decided to be extracted and keep the relatively healthy and intact four first premolars. Besides, extraction of four second premolars could prevent a dish-in profile. In order to create space for #7 and solve the crossbite of #7 and #27, open coil springs

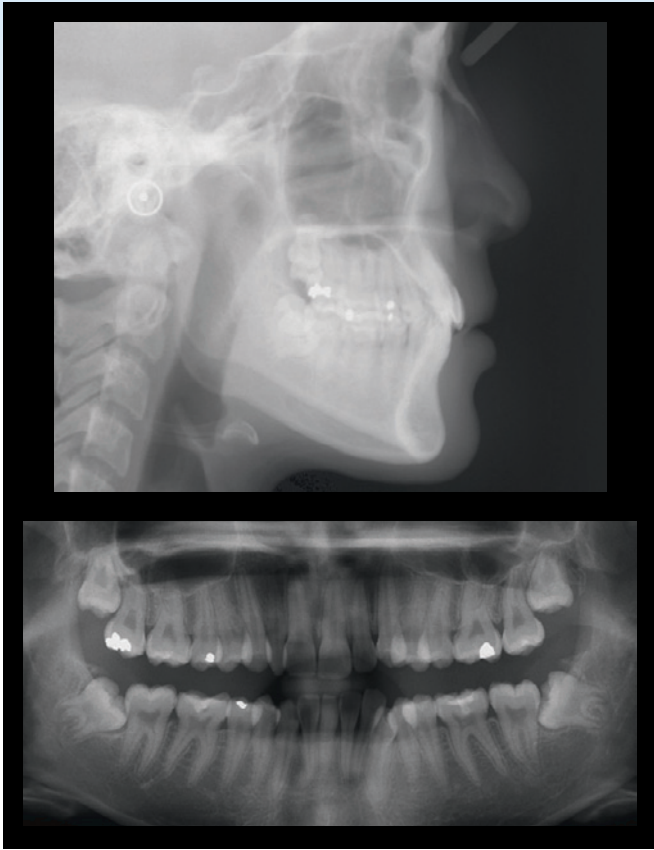


Fig.7: Pretreatment pano and ceph radiographs

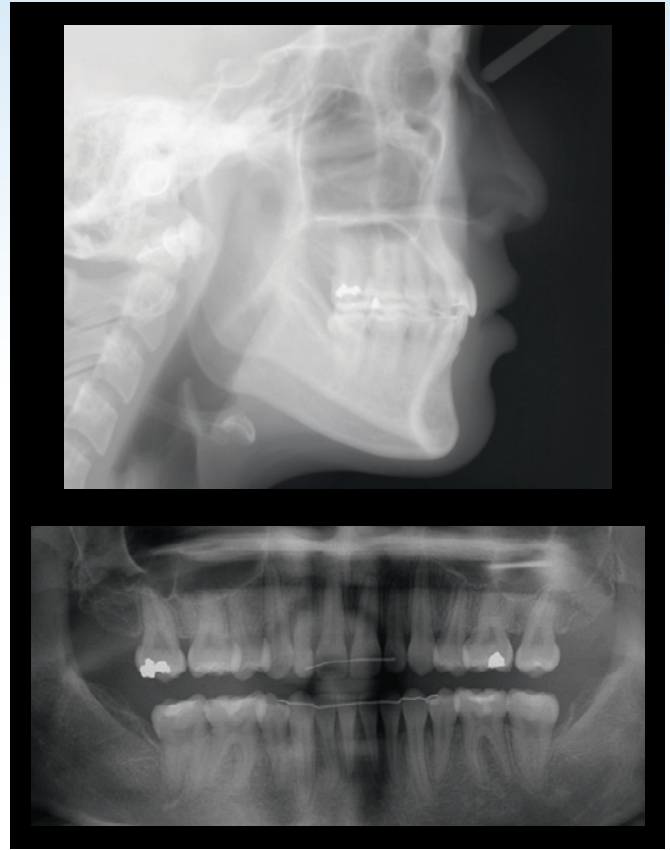


Fig. 8: Posttreatment pano and ceph radiographs

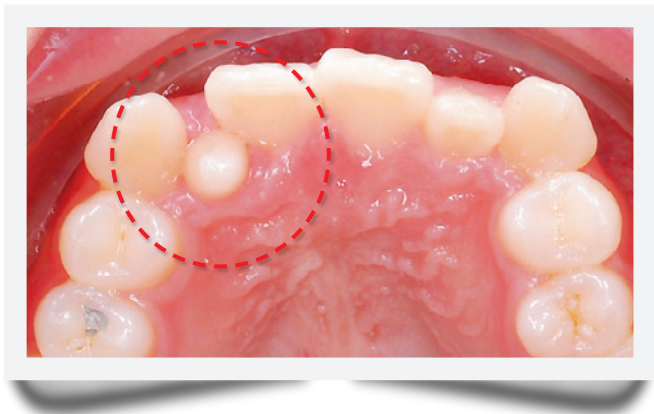


Fig. 9:
A maxillary peg lateral incisor was noted, which needed to create enough space for alignment and to be restored into a normal morphology.

CEPHALOMETRIC			
SKELETAL ANALYSIS			
	PRE-Tx	POST-Tx	DIFF.
SNA°	80°	79.5°	0.5°
SNB°	77°	76.5°	0.5°
ANB°	3°	3°	0°
SN-MP°	36°	37°	1°
FMA°	26°	27°	1°
DENTAL ANALYSIS			
U1 TO NA mm	2 mm	3 mm	1 mm
U1 TO SN°	103°	105°	2°
L1 TO NB mm	1 mm	2 mm	8 mm
L1 TO MP°	77°	85°	-1°
FACIAL ANALYSIS			
Upper lip to E-LINE	-2 mm	-1 mm	1 mm
Lower lip to E-LINE	-0.5 mm	1 mm	1.5 mm

Table. Cephalometric summary

and anterior bite turbos were used. Class II elastics were applied for retracting anterior teeth and resolve occlusal discrepancy. The esthetics of #7 was also an important issue. Restoration can be achieved by direct bonding composite resin, veneer, or a full coverage crown. After finishing the treatment, fixed appliances were removed and the corrected dentition was retained with fixed anterior retainers on both upper and lower arch, and a clear retainer overlay on the upper arch. Four third molars could be extracted before, during, or after the orthodontic treatment.

Appliances and Treatment Progress

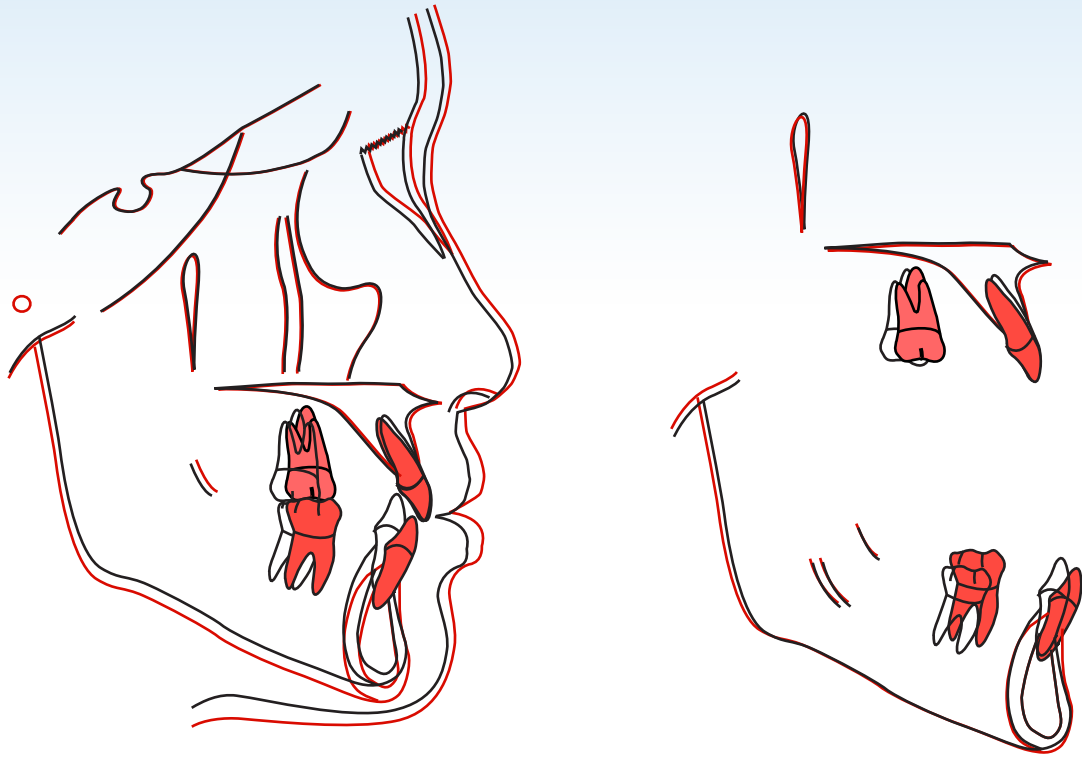
After four second premolars were extracted, .022" Damon MX® bracket (*Ormco*) were bonded on both arches, and .014" CuNiTi wires were placed to align the dentition. Meanwhile, an open coil spring was inserted in the upper arch to create space for #7. In the 7th month of the treatment,, #7 received gingivectomy for a better bonding position. In the 8th month of the treatment, the arch wire were changed to .017×.025" low friction TMA in the upper arch and .014×.025" CuNiTi wire was placed in the lower arch. In the 11th month, #7 was restored with composite resin and the bracket position was changed again. In the 17th month .016×.025 SS wire and .019×.025" SS wire were used on the lower and upper archwire respectively. Power tubes were used to close the remaining space, followed by extraction of four third molars. The appliance was removed in the 27th month of the treatment. Fixed anterior retainers on both upper and lower arch, and a clear, overlay retainer on the upper arch, were delivered. Gingivoplasty was performed on both upper lateral incisors, and central incisors, with diode laser to improve the crown length-to-width proportion.

Final Evaluation of Treatment

The IBOI Cast-Radiograph Evaluation scored at 28 points, which was deemed to qualify as a board case report.

Major problems include more buccal tipping of both upper second molar, resulting in discrepancies in alignment, marginal ridge, buccal-lingual inclination, overjet, and occlusal contacts. In the meantime, the root angulation of eight teeth, #5, 7, 18, 21, 26, 28, 30 and #31, were not precisely parallel as indicated in the panorex. It was suspected that the mesial side of the bracket were bonded more gingivally than the distal side, and it resulted in distal tilting the second molars. Therefore, the long axis of the root could not be parallel, because both upper and lower molar bracket pad were designed to have a buccal groove with it. Dr. Tom Pitts suggested that the bracket placement protocol for maxillary first molar is to fit the buccal groove region of the pad into the buccal groove of the tooth in a mesio-distal(M-D) position, and keep the occlusal edge of the first molar tube on the M-D contact line. The M-D positioning for the maxillary second molar tube is the same as the first molar. In terms of occlusogingival (O-G) positioning, the bracket is 1.5 mm more occlusally than the first molar. For lower first and second molars, the buccal groove of the molar tube were centered to the buccal groove of the tooth in M-D positioning while occlusogingivally, the bracket molar pads were 0.5 mm gingivally to M-D contact line. In addition, the first and the second molar bracket were at the same height. Fig. 11 illustrantes the ideal bracket placement of maxillary and mandibular molars.¹

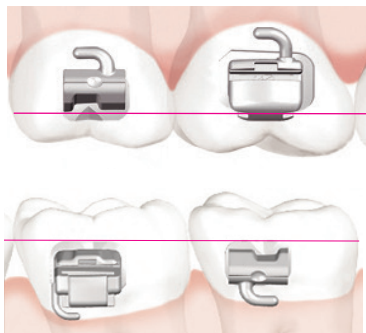
Her straight profile and the proportion of the face were maintained. Dental midline was corrected. Both side of the molar relationship was Class I. Tooth display of anterior region was improved.

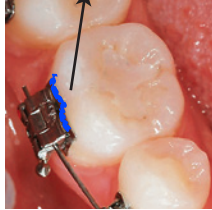


■ Fig. 10:

Superimposed tracings:

Class I molar relationship was retained. The ramus and the body of the mandible kept growing throughout the treatment. The roots of upper incisors torqued palatally slightly; the crown of lower incisors tipped labially. Mild deepbite was improved and the straight profile was maintained. Maxillary and mandibular 1st molars were protracted to close the excessive space



	M-D	O-G
Maxillary 1 st molar	Center buccal tip of the tube pad over buccal groove of tooth.	Position occlusal edge of tooth pad at M-D contact line.
Maxillary 2 nd molar		Position occlusal edge of tooth pad 1.5 mm more occlusally than 1st molar.
Mandibular 1 st molar		Position occlusal edge of tooth pad 0.5 mm gingivally to M-D contact line.
Mandibular 2 nd molar		The same as Md. 1 st molar.

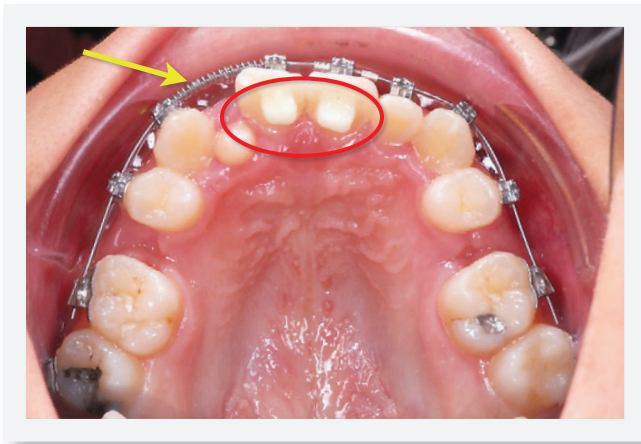
■ Fig. 11:

Bracket Placement of maxillary and mandibular molars (Dr. Tom Pitt's presentation)

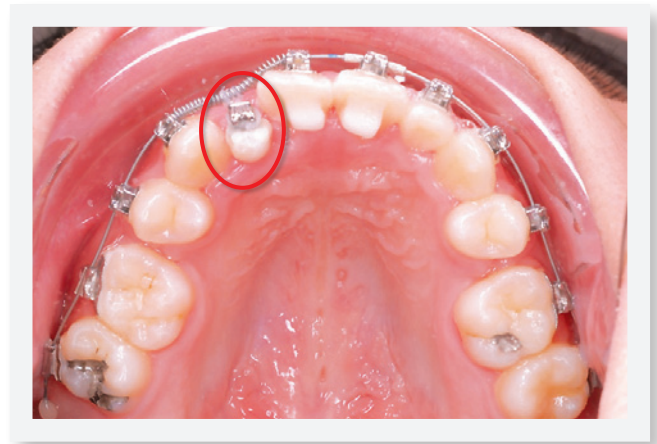Discussion

Maxillary lateral incisors vary in forms more than any other tooth in the mouth except the third molars.² A peg-shaped lateral incisor could be defined as a developmental anomaly of the maxillary lateral incisor that result in a small peg in shape.³ Peg shaped lateral incisors occur in approximately from

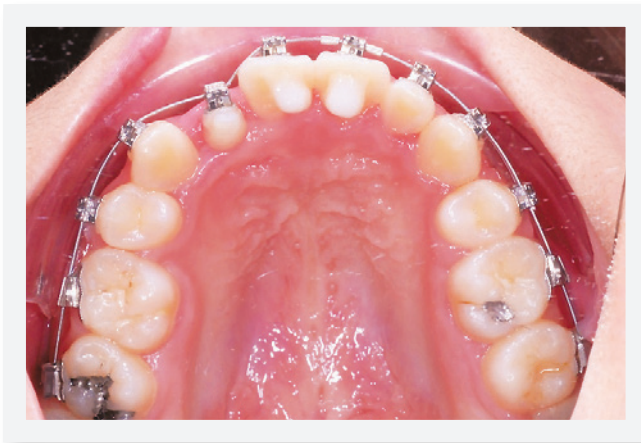2% to 5% of the general population, and women show a slightly higher frequency than men.⁴⁻⁶ There is no significant difference between the occurrence rate in Peg-shaped anomalies presented in right or left, uni- or bilaterally. In this case report, this is a female with a unilateral peg-shaped lateral incisor.³



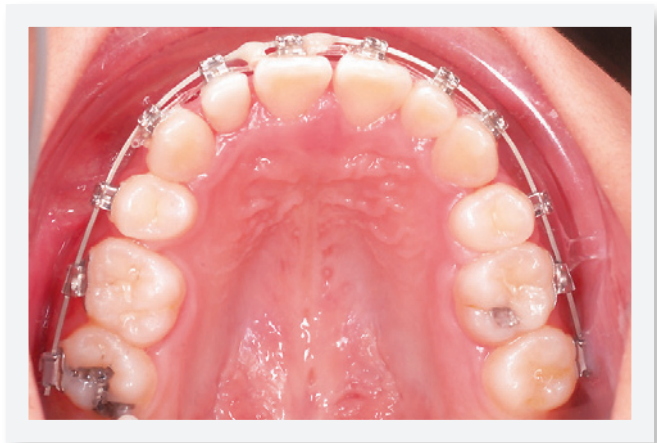■ Fig. 12:
The 1st month. An open coil spring (yellow arrow) was inserted to create enough space for the peg lateral incisor. Bite turbos (blue circle) were applied to correct anterior crossbite.



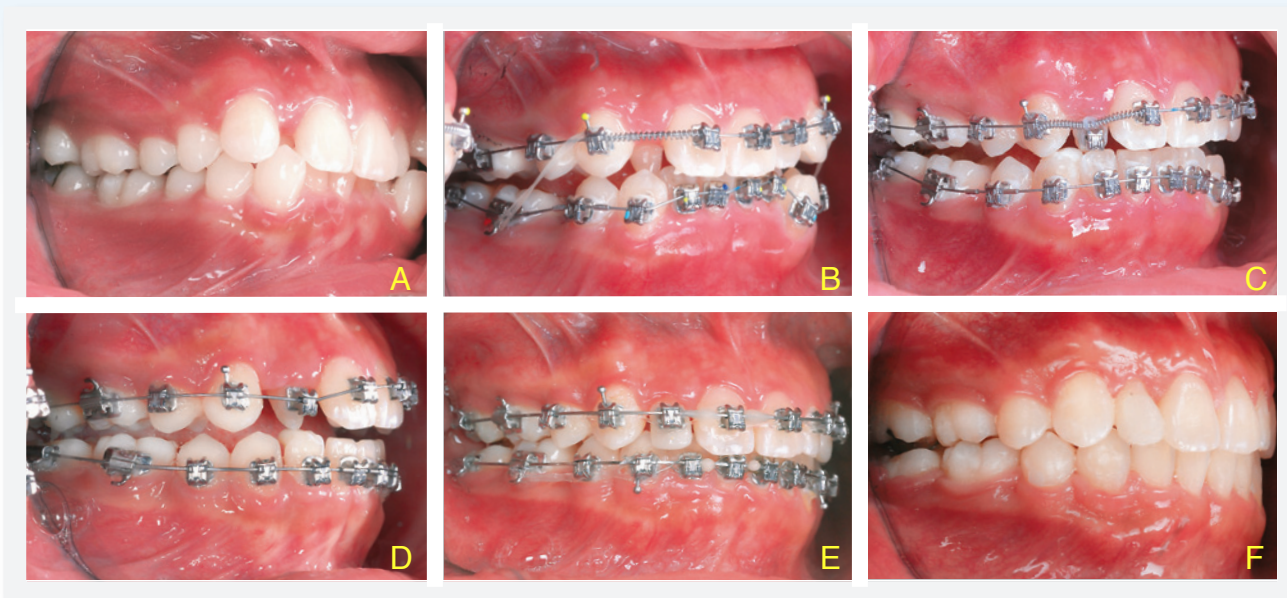
■ Fig. 13:
The 4th month. When space was created for the lateral incisor, it was bonded with a bracket. In addition, a power tube was used and banded together with the archwire to move the tooth more buccally.



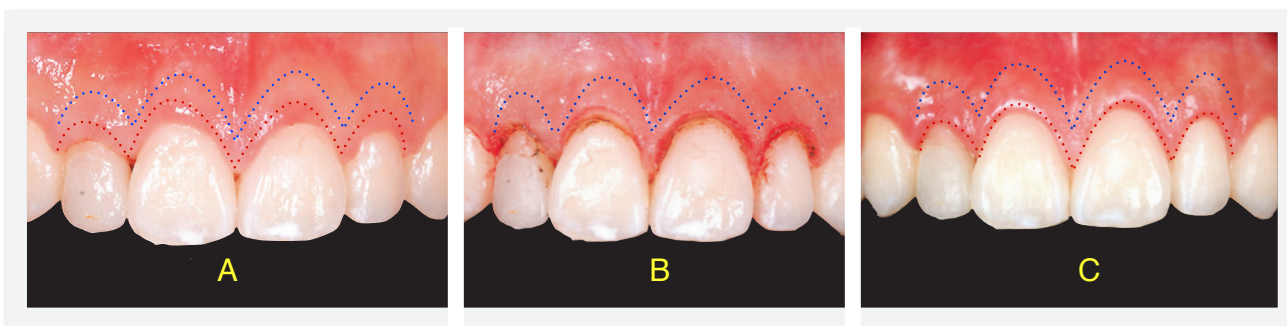
■ Fig. 14:
The 7th month. Lateral incisor was aligned, and sufficient space was created to restore it into a normal shape.



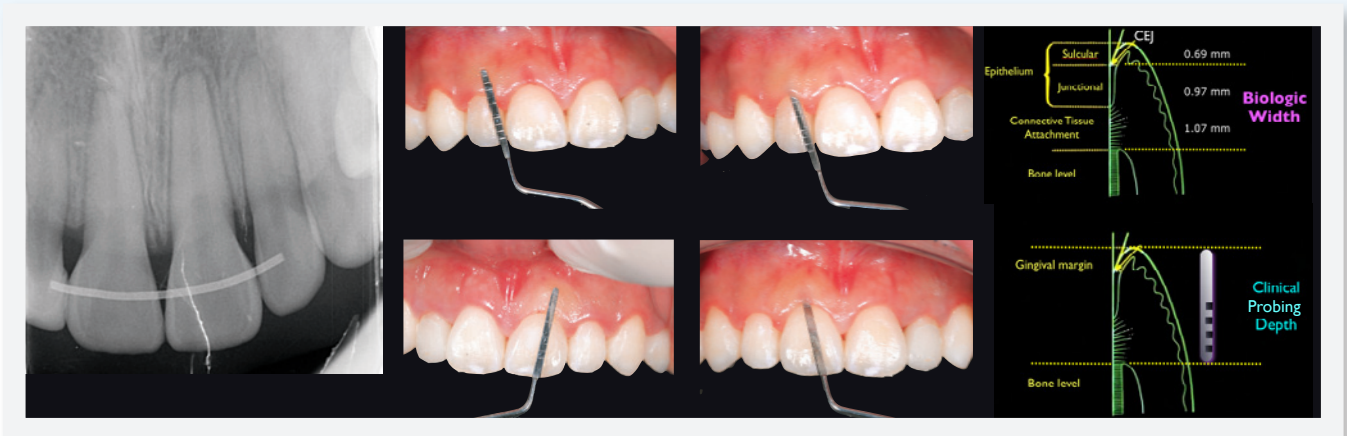
■ Fig. 15:
The 18th month. Lateral incisor was restored with composite resin. A power tube was used to close the excessive space.



■ Fig. 16:
 Lateral view. The peg lateral incisor was behind the lower canine before treatment. Open coil springs and bite turbos were used to obtain the space between maxillary central incisor and canine, then the lateral incisor could move buccally and correct the crossbite. Moreover, the space provided the peg lateral incisor to be restored into a normal shape. Finally, the lateral incisor was aligned and the excessive space was closed by the power tube.
 A: pre-treatment; B: 1st month; C: 4th month; D: 7th month; E: 18th month; F: post-treatment



■ Fig. 17:
 Gingivoplasty was performed for a better crown length-to-width proportion. The blue line imitates the bone level of the teeth; the red line marks the ideal gingival height.
 A: before gingivoplasty; B: probing depth and marking the ideal gingival height, and thus diode laser was used; C: 1 month follow-up after treatment.



■ Fig. 18:

After the ideal gingival height was estimated, X-ray was reviewed to evaluate the bone level and probed depth with an explorer. Due to equal bone level and mild excessive free gingiva, gingivoplasty was performed and the biological width was maintained.

Peg lateral is usually associated with other dental anomalies, such as tooth agenesis,^{4,7,8} maxillary canine-first premolar transposition,⁵ palatal displacement of one or both maxillary canine,⁷ buccal displacement of maxillary canine,^{9,14} and mandibular lateral incisor-canine transposition.¹⁰ In cases of concomitant dental anomalies, the prevalence suffers significant increase from normal prevalence.⁹⁻¹¹ In this case combined with anterior crowding, the block-out of right upper and lower canines, and the crossbite between right upper lateral incisor and lower canine might be associated with this dental anomaly.

There are several treatment options for malformed lateral incisors. A periapical film should be taken to

evaluate if the lateral incisor could be preserved. Treatment planning may include extraction and non-extraction of the lateral incisor.^{3,12,13}

1. Extraction of lateral incisor:¹⁴⁻¹⁷

A. Canine substitution:

To move adjacent maxillary canines forward, one can reshape them to simulate the extracted malformed lateral incisors. However, it is only suitable for the following situations, such as Class II molar relationship with excess overjet, Class I molar relationship with lower arch crowding which extraction is an indication, protrusive face, and the shape and color of the canine could match with the adjacent central incisor;

B. Implant placement:

Nowadays, implant placement is a common way to replace a missing tooth. Considering not only the high success rates, this type of restoration could also prevent injuries to the adjacent teeth. To achieve a stable esthetic and healthy outcome with dental implants, the effects on the surrounding hard and soft tissues should be taken into consideration.

C. Resin-bonded fixed partial denture (FTP), cantilever FTP, or conventional full coverage bridge:

Resin-bonded FTP, the so-called Maryland bridge, is the most conservative technique among tooth-supported restorations. But there are some limits for placing this kind of restoration. Patients with no history of bruxism, immobile abutment, and shallow overbite would decrease its failure rate.

Due to sufficient root length and crown dimensions, canine is an ideal abutment for Cantilever FTP. For long-term success of a cantilevered bridge, avoid pontic contact in excursive movements. In case eccentric contact remains on the pontic, it increases the risks of loosening of the bridge, migration of the abutment, and fracture.

The least conservative of all tooth-supported restorations is a conventional full-coverage FPD. Therefore, this kind of treatment option is only considered when the adjacent teeth require restoration for structural reasons such as caries or fracture.

2. Non-extraction of lateral incisor:

To stand the canines in a Class I relationship and to restore the tooth structure and morphology of a peg-shaped lateral incisor

A. Direct composite resin filling:

It is the most conservative technique to restore the lateral incisor into a normal shape. It could be applied within one dental visit and is more economic than other restorations. However, composite resin would discolor, or failure if the tooth structure provides insufficient retention and resistance.

B. Ceramic veneer:

Ceramic veneers are ideal restorations for peg lateral incisors in adult patients, since the gingival level might change in young patients. Tooth preparation is minimal in depth, virtually insuring an enamel substrate will remain. Furthermore, ceramic veneers possess greater clinical appearance than composite resin fillings, and also they are stain-resistant. If the peg lateral incisor were extremely small in size, or lack of the sufficient amount of enamel to provide the major bonding strength for the veneers, a full coverage crown might be an optimal restoration.

C. Full coverage crown:

A full coverage crown increases the size of the tooth both mesiodistally and buccolingually. Due to better retention and resistance, the risk of bonding failure and fracture is lower than veneers. The amount of the ferrule remaining

on the tooth should be evaluated before preparation.

The non-extraction way is more conservative if the situation is allowed, especially for young patients. Most of these cases need to receive orthodontic treatment in the first place to align the teeth, then create adequate space for the reshaped lateral incisor. Some cases are complicated by combining canine transposition or crossbite.^{18,19} Finally, gingivoplasty may be necessary for better gingival display and more structure for increasing retention when bonding to composite resin.²⁰

This case report details the treatment of a single unilateral peg-shaped maxillary lateral incisor along with the conservative treatment proposed.

A open coil spring was used to create space for lateral incisor in the beginning of the treatment. When the space was available, the bracket was bonded to lateral incisor for initial alignment. Then gingivectomy was performed to facilitate a proper bonding position. Afterwards, #7 was restored in a normal shape by composite resin to restore its shape. Moreover, a bite-turbo was bonded to help correct anterior crossbite. After all fixed appliances were removed, the esthetics of soft and hard tissue were re-evaluated. Consideration of soft tissue management should include: 1. oral hygiene; 2. X-ray taking; 3. probing; 4. attached gingiva.²¹ The ideal gingival height was marked, and the bone level was detected by probing depth. It revealed shorter crown length and mild excessive free gingival tissue of four upper incisors surrounded by equal bone level. Gingivoplasty by diode laser

was arranged to achieve more ideal crown length-to-width proportion and maintain the biological width.²² Table 2. compares the consideration for soft tissue management that help achieve esthetic requirements.

Gingiva Health	○	○
Attached Gingiva	○	○
Probing	Equal Bone Level	Bony Descrepancy
Operation	Gingivectomy	Surgical Crown Lengthening

■ Table 2. Consideration of soft tissue operation

Conclusion

Peg lateral incisors are common problems in our daily practice. They also have a huge impact on esthetics. It is important for orthodontists to develop an efficient routine to solve this problem. Specific considerations should include the followings:

1. There are several treatment options for managing peg lateral incisors, including extraction and non-extraction methods. Each of the treatment option should consider the conditions of the lateral incisor and adjacent teeth.
2. Should the teeth be restored before, during, or after orthodontic treatment are based on the treatment planning.
3. Orthodontists play an important role in providing sufficient coronal and apical space for future restoration or implant placement.

Acknowledgements

Thanks to Dr. Yu Lin Hsu, Dr. Bill Su, and Huang Tzu Han for proofreading this article.

References

- Pitts TR. Begin with the end in mind: Bracket placement and early elastic protocols for smile arc protection. *Ormco clinical impressions* 2009; 17:2-11
- Major M, Ash S, J Nelson. The permanent maxillary incisors, Dental Anatomy.
- Farhat A, Jawaria A, Shazia A. Prevalence of peg laterals and small size lateral incisors in orthodontic patients- A study. *Pakistan Oral & Dental Journal* 2011;31:88-91.
- Meskin LH, Gorlin RJ. Agenesis and peg shaped permanent maxillary lateral incisors. *J Dent Res* 1969;27:563-73.
- Al-Emran S. Prevalence of hypodontia and developmental malformations of permanent teeth in Saudi Arabia school children. *Br J Orthod* 1990;17:115-18.
- Alvesal L, Portin P. The inheritance pattern of missing, peg shaped and strongly mesiodistally reduced upper lateral incisors. *Acta Odontol Scand* 1969; 27:563-75.
- Villani S, Stellzig A, Komposch G, Ipodontia considerazioni sulla terapia orthodontia nell'agenesia dell'incisive laterale superior permanente. *Minerva Stomatol* 1995;44:211-22.
- Ucheonye IJ, Tokunbo AA. Prevalence of peg shaped laterals in south western Nigeria: A comparison of field and clinic findings. *Int J of Dent Science*, 2010;8:2.
- Peck L, Peck S, Attia Y. Maxillary canine-first premolar transposition, associated dental anomalies and genetic basis. *Angle Orthod* 1993;63:99-109.
- Peck S, Peck L, Kataja M. Prevalence of tooth agenesis and peg shaped maxillary lateral incisors associated with palatally displaced canine (PDC) anomaly. *AJODO* 1996; 110:441-43.
- Alvesal L, Portin P. The inheritance pattern of missing, peg shaped and strongly mesiodistally reduced upper lateral incisors. *Acta Odontol Scand* 1969; 27:563-75.
- Linda G. Treatment options for peg-shaped laterals using direct composite bonding. *International Dentistry SA*. 2010;12:26-33.
- Counihan D. The orthodontic restorative management of the peg-lateral. *Dental Update* 2000; 27: 250-256.
- Kokich VO Jr, Kinzer GA, Janakievski J. Congenitally missing maxillary lateral incisors: Restorative replacement. *AJODO* 2011; 139:435-445
- Kokich VO Jr, Kinzer GA. Managing Congenitally Missing Lateral Incisors. Part I: Canine Substitution. *JERD* 2005; 17:5-10
- Kokich VO Jr, Kinzer GA. Managing Congenitally Missing Lateral Incisors. Part II: Tooth-Supported Restorations. *JERD* 2005; 17:76-84
- Kokich VO Jr, Kinzer GA. Managing Congenitally Missing Lateral Incisors. Part III: Single-Tooth Implants. *JERD* 2005; 17:202-210
- Loh KW. Management of Buccally Erupted Canines and Lower Midline Deviation- A Case Report. *News & Trends in Orthodontics*. 2009; 16:64-67.
- Wu S, Chang C, Roberts WE. An Anterior Crossbite and Block-out Canine- ABO Case Report. *News & Trends in Orthodontics*. 2009; 16:76-82.
- Su B, Chang C, Roberts WE. Highly Positioned and Transalveolar Impacted Maxillary Canine: iAOI Case Report. *IJOI* 2011; 24:14-24.
- Hsiao HY, Hsu YL, Lee YL, Su B, Chang. Approaching efficient finishing-hard and soft tissue contouring. *News & Trends in Orthodontics*. 2008; 11:16-22.
- Chiu SC. Let's talk about biological width. *News & Trends in Orthodontics*. 2010; 18:70-72.
- Chang C. Basic Damon Course No. 4: Damon + OrthoBoneScrew II, Podcast Encyclopedia in Orthodontics 2012, Newton's A Ltd, Taiwan.
- Chang C, Roberts WE. *Orthodontics, 3D iBooks Ortho.*, Taiwan: Newton's A Ltd, 2012.

DISCREPANCY INDEX WORKSHEET

CASE # PATIENT

TOTAL D.I. SCORE **21**

OVERJET

- 0 mm. (edge-to-edge) = 1 pt.
- 1 – 3 mm. = 0 pts.
- 3.1 – 5 mm. = 2 pts.
- 5.1 – 7 mm. = 3 pts.
- 7.1 – 9 mm. = 4 pts.
- > 9 mm. = 5 pts.

Negative OJ (x-bite) 1 pt. per mm. per tooth =

Total =

OVERBITE

- 0 – 3 mm. = 0 pts.
- 3.1 – 5 mm. = 2 pts.
- 5.1 – 7 mm. = 3 pts.
- Impinging (100%) = 5 pts.

Total =

ANTERIOR OPEN BITE

0 mm. (edge-to-edge), 1 pt. per tooth
then 1 pt. per additional full mm. per tooth

Total =

LATERAL OPEN BITE

2 pts. per mm. per tooth

Total =

CROWDING (only one arch)

- 1 – 3 mm. = 1 pt.
- 3.1 – 5 mm. = 2 pts.
- 5.1 – 7 mm. = 4 pts.
- > 7 mm. = 7 pts.

Total =

OCCLUSION

- Class I to end on = 0 pts.
- End on Class II or III = 2 pts. per side pts.
- Full Class II or III = 4 pts. per side pts.
- Beyond Class II or III = 1 pt. per mm. pts.
additional

Total =

EXAM YEAR
ID#

LINGUAL POSTERIOR X-BITE

1 pt. per tooth Total =

BUCCAL POSTERIOR X-BITE

2 pts. per tooth Total =

CEPHALOMETRICS (See Instructions)

ANB $\geq 6^\circ$ or $\leq -2^\circ$ = 4 pts.

Each degree $< -2^\circ$ x 1 pt. =

Each degree $> 6^\circ$ x 1 pt. =

SN-MP

$\geq 38^\circ$ = 2 pts.

Each degree $> 38^\circ$ x 2 pts. =

$\leq 26^\circ$ = 1 pt.

Each degree $< 26^\circ$ x 1 pt. =

1 to MP $\geq 99^\circ$ = 1 pt.

Each degree $> 99^\circ$ x 1 pt. =

Total =

OTHER (See Instructions)

- Supernumerary teeth x 1 pt. =
- Ankylosis of perm. teeth x 2 pts. =
- Anomalous morphology x 2 pts. =
- Impaction (except 3rd molars) x 2 pts. =
- Midline discrepancy (≥ 3 mm) @ 2 pts. =
- Missing teeth (except 3rd molars) x 1 pts. =
- Missing teeth, congenital x 2 pts. =
- Spacing (4 or more, per arch) x 2 pts. =
- Spacing (Mx cent. diastema ≥ 2 mm) @ 2 pts. =
- Tooth transposition x 2 pts. =
- Skeletal asymmetry (nonsurgical tx) @ 3 pts. =
- Add. treatment complexities x 2 pts. =

Identify:

Total =

Exam Year	<input type="text"/>
ABO ID#	<input type="text"/>

Examiners will verify measurements in each parameter.

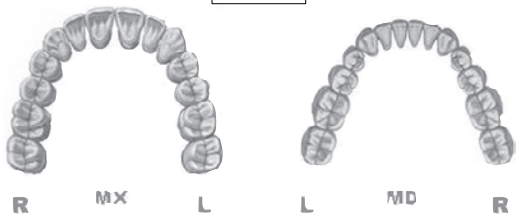
Occlusal Contacts

ABO Cast-Radiograph Evaluation (Rev.6-1-08)

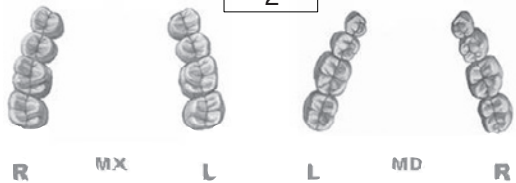
Case # Patient

Total Score:

Alignment/Rotations

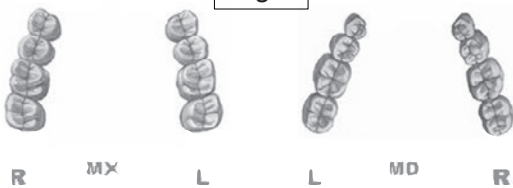


Marginal Ridges



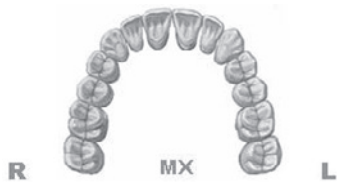Occlusal Relationships

Buccolingual Inclination



Interproximal Contacts

Overjet



Root Angulation

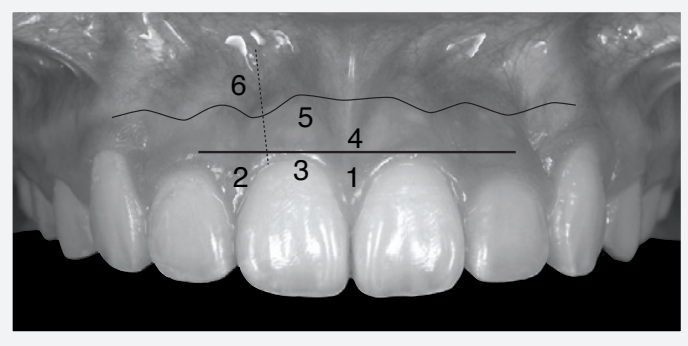
INSTRUCTIONS: Place score beside each deficient tooth and enter total score for each parameter in the white box. Mark extracted teeth with "X". Second molars should be in occlusion.

IBOI Pink & White Esthetic Score

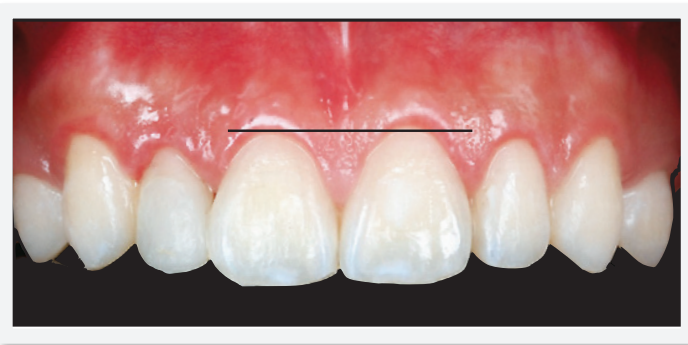Total Score: = 2

1. Pink Esthetic Score

Total = 1



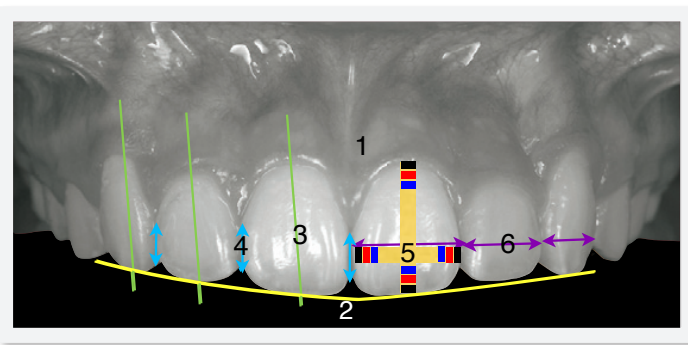
1. Mesial Papilla	0	1	2
2. Distal Papilla	0	1	2
3. Curvature of Gingival Margin	0	1	2
4. Level of Gingival Margin	0	1	2
5. Root Convexity (Torque)	0	1	2
6. Scar Formation	0	1	2



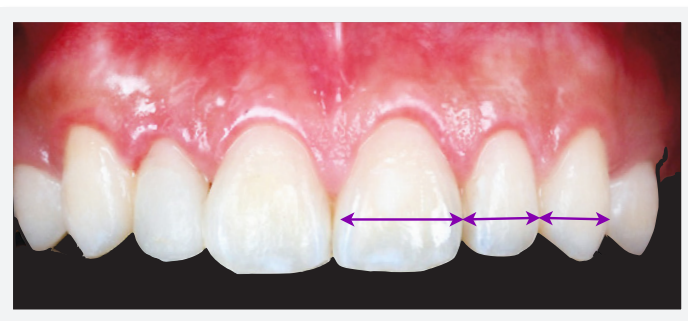1. M & D Papilla	0	1	2
2. Keratinized Gingiva	0	1	2
3. Curvature of Gingival Margin	0	1	2
4. Level of Gingival Margin	0	1	2
5. Root Convexity (Torque)	0	1	2
6. Scar Formation	0	1	2

2. White Esthetic Score (for Micro-esthetics)

Total = 1



1. Tooth Form	0	1	2
2. Mesial & Distal Outline	0	1	2
3. Crown Margin	0	1	2
4. Translucency (Incisal third)	0	1	2
5. Hue & Value (Middle third)	0	1	2
6. Tooth Proportion	0	1	2



1. Midline	0	1	2
2. Incisor Curve	0	1	2
3. Axial Inclination (5°, 8°, 10°)	0	1	2
4. Contact Area (50%, 40%, 30%)	0	1	2
5. Tooth Proportion (1: 0.8)	0	1	2
6. Tooth to Tooth Proportion	0	1	2

早期矯正治療的陷阱 及植牙介入的時機

2012.9.9

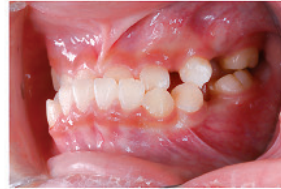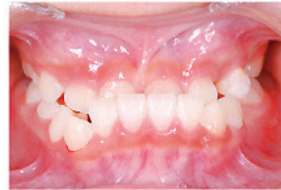演講資訊

兒童牙科的早期治療主要在針對萌發中的恆齒問題處理，以促進骨骼的正常發展，並減輕日後矯正的複雜度。因此，早期治療的重點主要在解決眼前的局部問題，而臨床上常見的問題是缺乏針對患者整體的情況做出完整的診斷，擬定全面的治療計畫，並且依據此計畫來決定適當的介入時機。

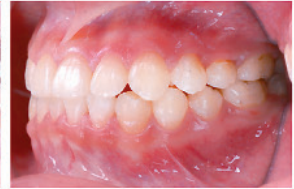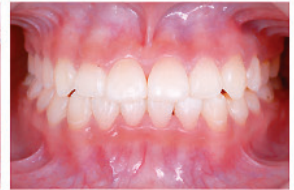本演講希望透過四個完整的案例報告來說明決定早期治療的重要關鍵，從詳盡的資料蒐集，給予正確的診斷和擬定完整的治療計畫後，決定最理想的矯正流程，包括先天性缺牙與植牙介入的時機探討。唯有透過詳實的個案報告，臨床工作者才能具體地了解及分析如何做出早期治療裡的每個關鍵判斷。

最後，講者將依據多年的臨床經驗，整理出明確的臨床診斷依據，幫助我們決定什麼樣的情況下該進行早期介入，而哪些往往是造成消耗病患治療熱情，以及造成醫師延長治療時間的早期治療陷阱。希望透過本演講可以協助醫師輕鬆的判斷「如何執行」或「不執行」早期治療。

pre. tx

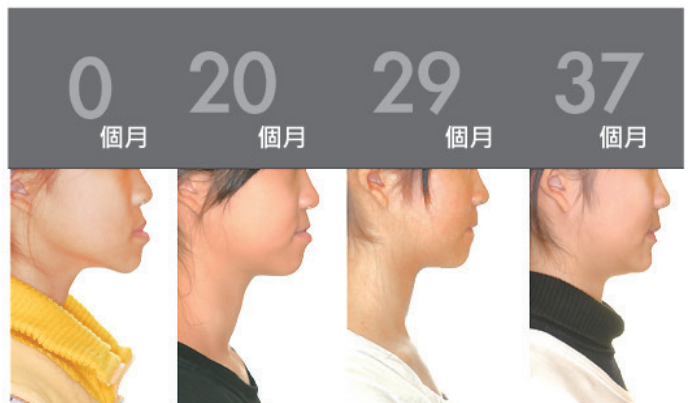

post. tx



演講時刻表

08:30-09:00	報到
09:00-10:20	曾淑萍,張慧男
10:20-10:50	Break
10:50-12:10	彭緯綸,張慧男
12:10-13:30	Lunch
13:30-14:50	徐玉玲,張慧男
14:50-15:20	Break
15:20-16:40	黃瓊嬋,張慧男
16:40-17:00	Discussion



演講資訊

主辦單位	台北醫學大學牙醫學系台南區校友會
協辦單位	湧傑企業股份有限公司
時間	2012年 9/9 (日) 9:00am - 5:00pm
地點	國立成功大學醫學院第三講堂 地址：701台南市小東路1號
費用	2012.8/31前會員1000元，非會員1500元 2012.8/31後會員2500元，非會員3000元
報名專線	07-536-1701 王小姐 02-2778-8315分機125 張小姐
報名方式	請先電話報名，三日內劃撥費用 郵政劃撥帳號:17471807 戶名：湧傑企業股份有限公司
學分證明	參加者發給繼續教育學分證明 (紙本學分費100元)

講師介紹

張慧男 醫師

新竹貝多芬齒顎矯正中心負責人
中華民國齒顎矯正專科醫師
美國齒顎矯正專科醫師學院院士(ABO)
美國印第安那普渡大學齒顎矯正研究所博士



徐玉玲 醫師

高雄醫學大學牙醫學士
安徒生兒童牙醫診所負責人
貝多芬矯正課程講師

曾淑萍 醫師

陽明大學牙醫學士
中華民國兒童牙科醫學會專科醫師
安徒生兒童牙醫診所醫師

彭緯綸 醫師

中國醫藥大學牙醫學士
成大醫學中心兒童牙科代訓醫師
安徒生兒童牙醫診所醫師

黃瓊嬋 醫師

成大醫學中心牙科兼任主治醫師
中華民國齒顎矯正學會專科醫師
大蘋果牙醫診所院長

矯正學習新紀元

張慧男醫師高效矯正科技學習法

- 講義電子化 - iPad看講義，省下紙張浪費
- 筆記電子化 - 可畫重點及記錄重點
- 課程視訊化 - 課程細節的複習與預習

參加**2012**基礎班

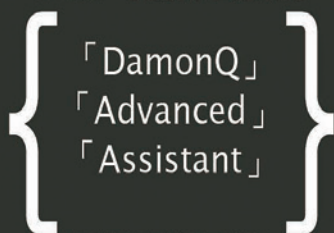
送

iPad + 全套JOI

「國際矯正植牙期刊」



iPad 可選擇替換為



視訊課程三選一

貝多芬矯正中心見習獎學金辦法



目的：

為促進國內牙科學術教育與牙科實務工作間的學習交流，並鼓勵國內牙醫系所學生在學期間能認識牙科實務操作環境，貝多芬齒顎矯正中心、安徒生兒童牙科、金牛頓植牙中心與金牛頓藝術科技特聯合提供本獎學金以及三天觀摩見習的機會。

實習目標：

1. 提昇對牙醫實務操作環境與診所管理的認識與了解。
2. 學習如何應用資訊科技來提昇實務工作效率。
3. 觀摩矯正、兒童專科診所與植牙中心的經營模式。

聯絡人：葉芳如

聯絡地址：新竹市建中一路25號2樓

聯絡方式：03-573-5676

電子郵件：rita@newtonsa.com.tw

- ★ 甄選對象：全台灣牙醫系四升五年級學生
- ★ 名額：每校3-5名
- ★ 獎助內容：三天二夜五星級飯店住宿以及見習期間餐飲費補助。
- ★ 遴選方式：學期成績在全班前30%或成績平均在75分以上，且對牙科實務展現積極學習的態度。
- ★ 見習時間：101年7月26日（四）-7月28日（六）
- ★ 申請截止日期：101年6月30日，以郵戳為憑。
- ★ 檢覆文件：該學年成績單影本（一份），自傳（請簡述學習經歷及申請目的）。請將申請文件郵寄到：新竹市建中一路25號2樓葉小姐收。



參加完這次的見習活動，我只能用嘆為觀止來形容，雖然在學術、技術方面的學習可能不能在這短短三天使我們全盤了解，但是就如同張慧男醫師對我們所言：「這次見習的重要性是給你們一個啟發。」在貝多芬、金牛頓、安徒生裡面的每一處所見所聞，都不斷衝擊我的思考，不斷地想：「為什麼有人能做到這樣地步？」、「原來還有這樣的做事方法！」在這邊三天之中我覺得絕對可以讓我們學習到的就是面對事情、處理事情的態度；因為張慧男醫師有

了passion、practice、persistence的信念，他能有凡事都盡可能做到最好的熱忱，這種精益求精、鍥而不捨的態度感染了在醫師身邊工作的所有人，讓大家在正向的環境中互相進步成長。對我來說，這次見習給我的啟發就是讓我在往後的日子中不斷思考該如何成為一個擁有passion、practice、persistence且具有領導特質的人。



國防醫學院 謝尹騰

這次能夠獲選參加貝多芬獎學金實習覺得非常幸運且收穫良多，不管是聽講課程的安排還是到貝多芬齒顎矯正中心及安徒生兒童牙醫診所的見習，每每都讓我對習得的新事物或見聞感到驚喜不已。也由於創辦人張慧男醫師對電腦硬體軟體的重視，以致不論在醫師經營的金牛頓藝術科技中心或診所內皆使用蘋果電腦，而教學課程更由於有Morph軟體的輔助，讓平常艱深難懂的植體、矯正教學簡單起來。

除了牙科相關學習活動外，也很感謝貝多芬另外安排了教授我們演講祕訣及自傳履歷書寫要點的課程，使我們未來不論在校內還是職場上能比他人更突出，爭取更好的機會。歷經這三天的實習課程，腦中猶記得此活動創辦人—張慧男醫師送給我們的良言：「每天只要做對一件事就好了！持續下去，十年下來必定能有不錯的成就。凡是皆要抱著持之以恆，不被挫折打敗的心！」



台北醫學大學 謝春怡

The Close Eruption Technique for Trans-alveolar Impacted Lower 1st Premolar



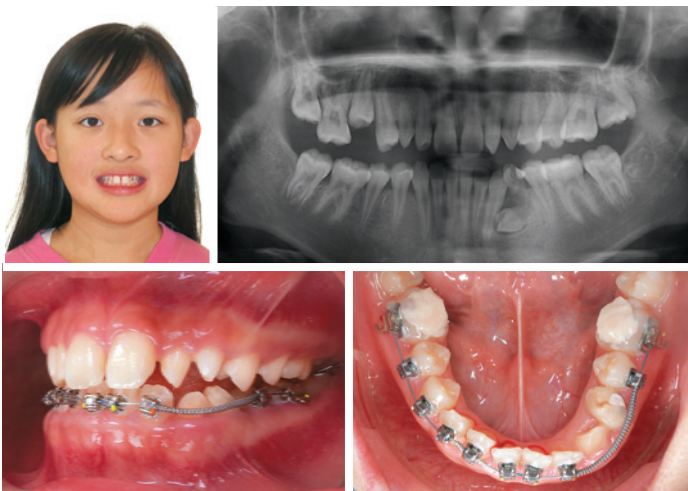Chris Chang, DDS, Ph.D.
Director,
Beethoven Orthodontic Center

Introduction

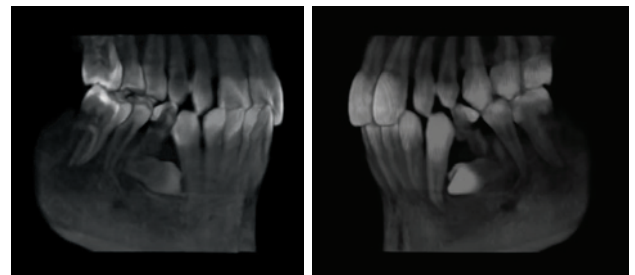
The close window technique is an ideal surgical option to treat trans-alveolar impacted premolar. This article aims to provide step-by-step illustrations on the surgical procedures that can improve safety, mechanics and healing of the wound so doctors can use them as a checklist before approaching this type of cases.

Case Study

A 13-year-11-month-old female came for consultation. The panorex film showed one trans-alveolar impacted lower 1st premolar and one deciduous 1st molar remaining on the left side (Fig. 1). CT scans indicate that the crown of the lower 1st premolar was impacted on the distal-buccal side of the canine and the root was impacted on the mesial-lingual side of the lower 2nd premolar (Fig. 2). The distance between the mental nerve and CEJ of the impacted lower 1st premolar is measured at 7mm. An appropriate surgical technique is then selected based on the provided information.¹ Illustrations of the impacted lower 1st premolar and the mental nerve mark the approximate position (Fig. 3). Detailed surgical procedures of this surgery are discussed at below.



■ Fig 1. Pretreatment pano radiograph & intraoral photographs.



■ Fig. 2:

Pretreatment CT image. Frontal view and rear view reveal that the crown of impacted lower 1st premolar is impacted by middle site of the root of lower canine. And the distance between the mental nerve and the CEJ of the impacted lower 1st premolar is 7mm.



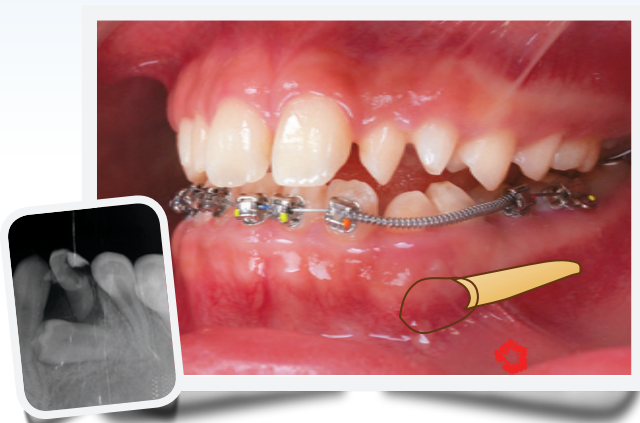Dr. Hsi Yuan Lin, Lecturer,
Beethoven Orthodontic Course

Surgery Process

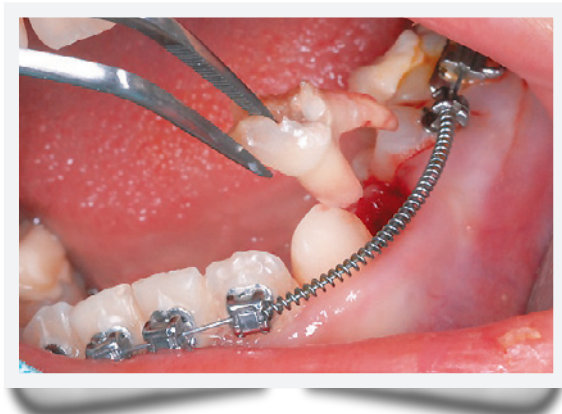
First, local anesthesia was applied in the surgical site and the deciduous 1st molar was extracted (Fig. 4).

Second, use a #12 blade to make an incision along the sulcus from the distal-buccal side of 2nd premolar to the mesial-buccal side of canine. Select a #15c blade to make a full thickness vertical incision from the mesial side of canine to the connective tissue area over the distal side of lateral incisor (Fig. 5). The design of the vertical incision offered a good vision to the surgical field, allowed for more blood supply to the flap, and decreased the chance of damage to the mental nerve.^{2,3} It is important to inform patients about temporary loss of feeling over the mental area in advance.

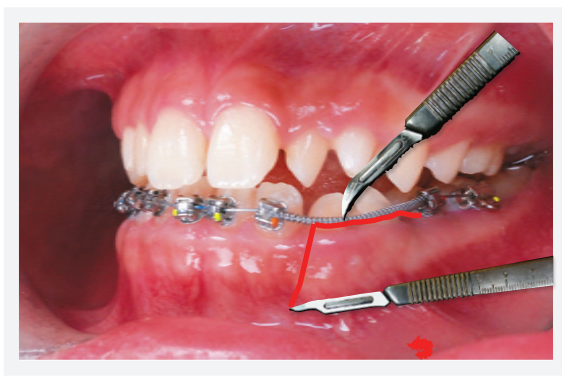Third, use a periosteum elevator to raise the flap to have full visual access to the crown of impacted tooth and an explorer in an up-down motion to measure the thickness of covering bone and the margin between the tooth and the bone (Fig. 6).



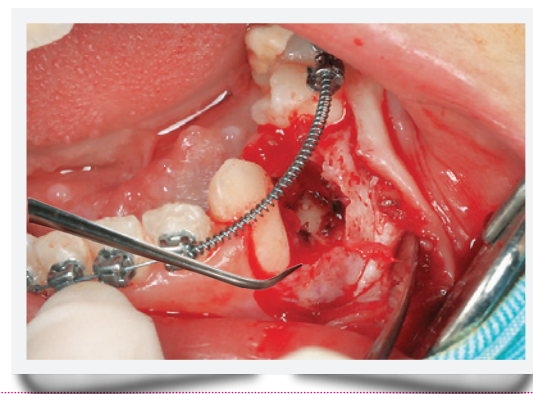
■ Fig. 3:
Illustrations of the impacted lower 1st premolar and the mental nerve mark the approximate position.



■ Fig. 4:
After applying local anesthesia, extract the deciduous 1st molar.



■ Fig. 5:
Use #12 and #15c blades to make sulcular & vertical incisions respectively.



■ Fig. 6:
Use a periosteum elevator to raise the flap and an explorer to detect the thickness and the margin of the covering bone.

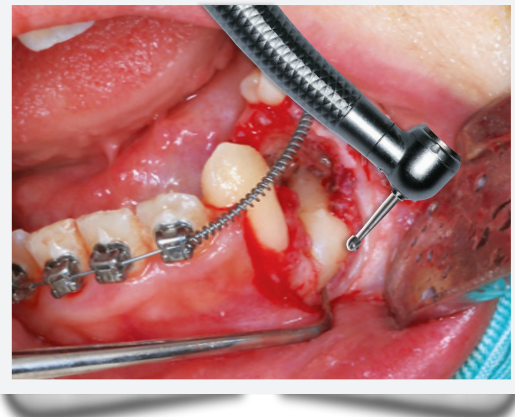Although the CT image can provide much diagnostic information on the location of the impacted lower 1st premolar, using an explorer for detection is more effective. When an explorer touches teeth, one will feel it is in contact with a smooth surface whereas when contacting bone, one will feel a rough surface.

Fourth, a high speed handpiece and a carbide round bur were used to remove the covering bone carefully to avoid tooth damage (Fig. 7). All the removed bone will regenerate because the controlled orthodontic extrusion will induce new bone formation from PDL.

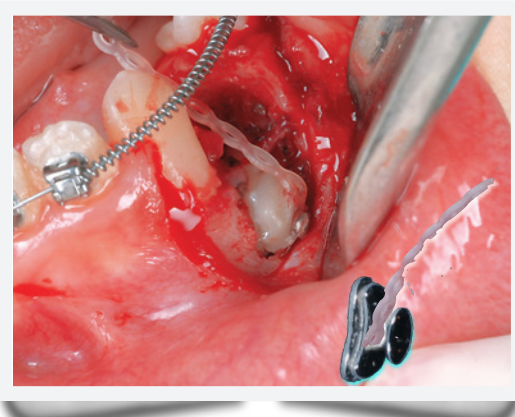
Fifth, put a button and connect it with a section of power chain (the clear and gray color are strongly recommended). After etching and bonding agent were applied, bond the button with a power chain onto the crown portion of the impacted tooth, and grab the power chain inside the archwire (Fig. 8). It is important to make sure that the surface of the button-power chain connection was covered by flowable resin to avoid loosening.

Sixth, suture the vertical incision of the flap with 6-0 Nylon by direct loop interrupted suture method with 6mm ears for minimal tissue trauma (Fig. 9).

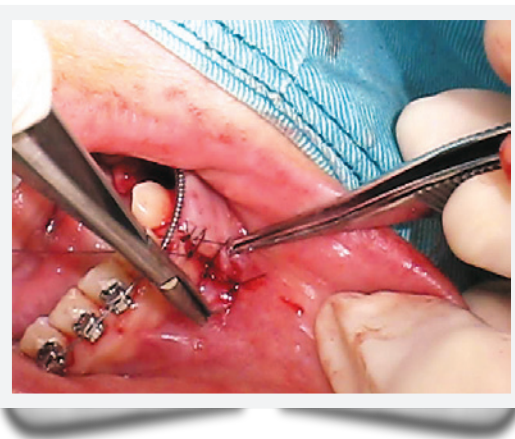
Seventh, use an explorer to punch a hole reaching the cortical bone to make an indentation for a miniscrew (OrthoBoneScrew, 2x12mm stainless steel with holes, Newton's A, Inc.) on the buccal shelf of the permanent 1st molar.^{4,5} The position of the hole is better to be located over the keratinized tissue to avoid inflammation. Insert the miniscrew into the cortical bone on the buccal shelf of permanent 1st molar over the keratinized tissue (Fig. 10).



■ Fig. 7:
Remove the covering bone with a high speed handpiece and a carbide round bur.



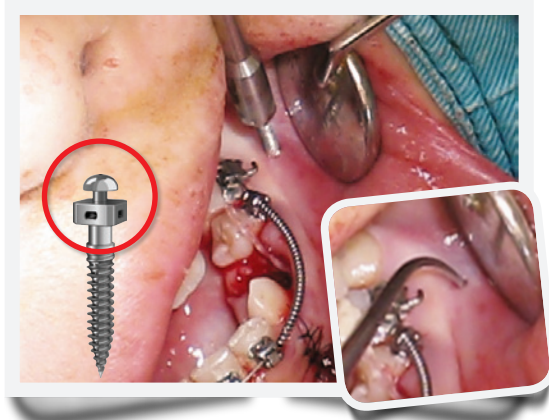
■ Fig. 8: Bond a button with a power chain.



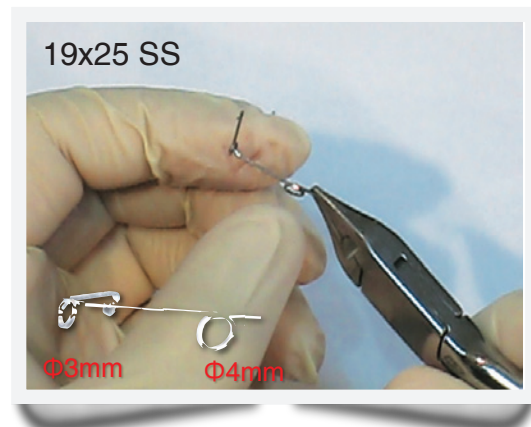
■ Fig. 9:
Suture the vertical incision with 6-0 Nylon for minimal tissue trauma.

Eighth, fabricate a double joints lever arm with a 19x25 stainless steel wire by bird beak plier (Fig. 11). Put the lever arm into the hole of the miniscrew and make sure the tail have been bended. It is essential to ensure the force design allow the impacted 1st premolar to be pulled out occlusally and slightly buccally (Fig. 12).⁶

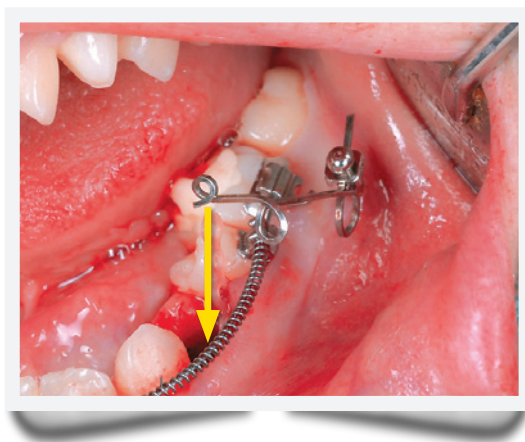
Ninth, push the lever arm downward and pass through the power chain to activate the double joints lever arm (Fig. 13). Adding some flowable resin onto the junction of the lever arm and the power chain will decrease the chance of separation.



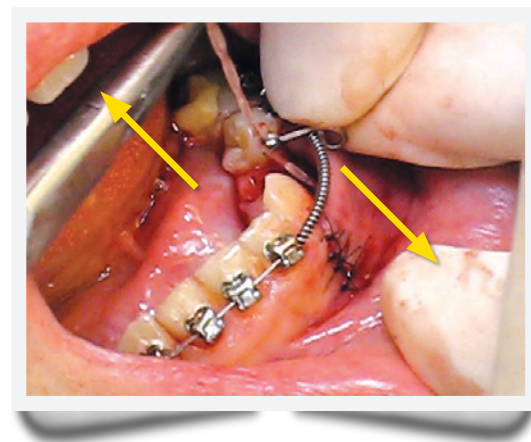
■ Fig. 10:
Use an explorer to make an indentation and insert a miniscrew on the buccal shelf.



■ Fig. 11:
Fabricate the double joints lever arm by a bird beak plier.



■ Fig. 12:
Put the level arm into the holes on the neck of the screw and test out the force mechanism.



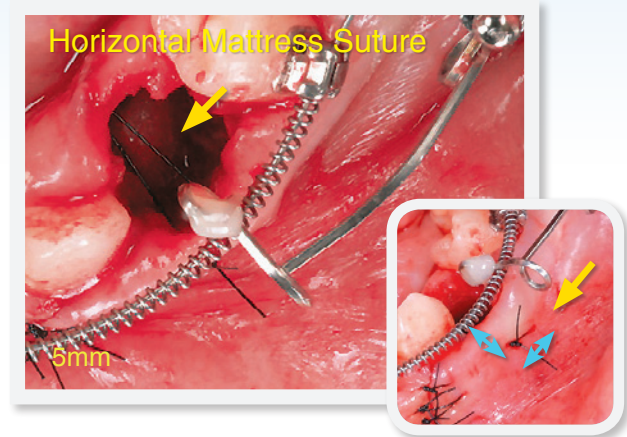
■ Fig. 13:
Push the level arm downward, and activate the double joints level arm by passing through the power chain.

Tenth, ligate the buccal and lingual flaps together with 5-0 Nylon by the horizontal mattress suture to stabilize the wound (Fig. 14).

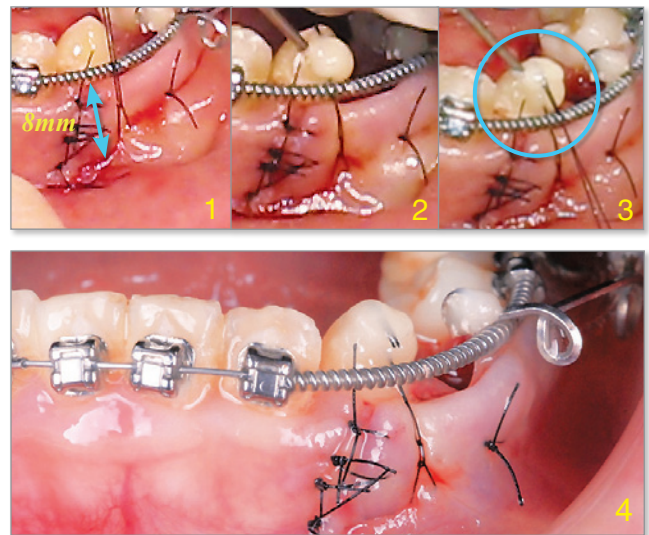
Eleventh, perform a coronally repositioned flap with 6-0 Nylon to prevent gingival recession and minimize tissue trauma (Fig. 15).⁷ After etching and bonding the buccal surface of canine, pull the buccal flap upward with 6-0 Nylon by horizontal mattress suture, and the amount of flap to be pulled is about 2mm. Then affix the stitch on the canine with flowable resin. It is important to secure the reverse tail with flowable resin again to increase retention of suture. Keep the suture for at least three weeks for better healing.

Twelfth, press the flap with a gauze soaked in normal saline solution for 10 minutes to prevent dead space and decrease wound swelling and inflammation (Fig. 16).

Thirteenth, COE-PAK was used to cover the wound, and wet gauzes laid on top of COE-PAK to make it touching the wound closely while pressing blood out. COE-PAK packed into the interdental space should be caught between the undercut. Spreading some vaseline on the gloves as a coating to make COE-PAK stick proof. COE-PAK can help stop bleeding and cover the wound for patient's comfort. It will delay soft tissue healing and avoid the soft tissue covering the wound for the epithelium averagely grows at the rate of 1 mm per day. Remove COE-PAK three days after the surgery and monitor the emergence of the impaction in three weeks (Fig. 17)⁸⁻¹⁰.



■ Fig. 14: Use the horizontal mattress suture to hold the buccal and lingual flaps with 5-0 Nylon.

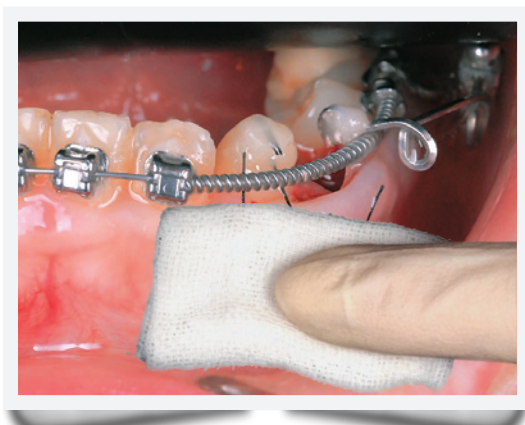


■ Fig. 15: Use coronally repositioned flap with 6-0 Nylon to prevent gingival recession.

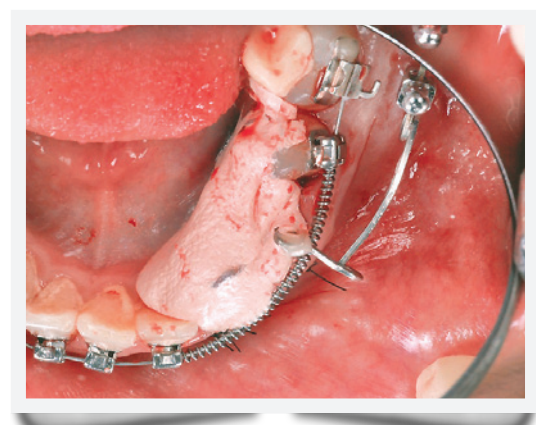
Discussion

According to the procedures of the operation, ten key tips are summarized below for treating impacted lower 1st premolar (Fig. 18).

1. Assess the 3D imaging with CBCT to determine the precise location of impactions and the surrounding nerves.
2. Do not bond adjacent teeth to prevent root resorption.
3. Design the incision lines to avoid mental nerve damage.
4. Isolate the margin between the impaction and the bone with an explorer.
5. Trim the bone covering the impaction adequately to facilitate the movement of the impacted tooth.
6. Create a stable force mechanism by bonding a button attached with a power chain on the surface of the impacted tooth.
7. Use a miniscrew (*OrthoBoneScrew, 2x12mm stainless steel with holes, Newton's A, Inc.*) and insert a double joints lever arm bended with 19x25 stainless steel to form the force mechanism.
8. Use the direct loop interrupted suture, horizontal mattress suture and reposition the flap coronally to prevent soft tissue rupture, recession and scar formation.
9. Cover the wound with COE-PAK to stop bleeding, enhance patient comfort, and prevent soft tissue covering the wound due to rapid epithelization.
10. Press the flap with a gauze soaked in normal saline solution for 10 minutes to prevent dead space and decrease wound swelling and inflammation.



■ Fig. 16:
Press the flap with a gauze soaked in saline solution for 10 min to prevent dead space.



■ Fig. 17:
Cover the wound with COE-PAK and pack it into the interdental space so it will be caught between the undercut.

All of the procedures focus on three key points throughout the treatment: safety, force design and healing (Fig. 19).

Safety: The risk of treatment depends on the depth of impaction and condition of surrounding tissue (Key1-3). Accurate assessment of location and appropriate surgical treatment can minimize risks of complications.

Force design: The proposed force system can provide an additional force system independent from the main archwire and be activated repeatedly and steadily (Key 4-7).

Healing: Post operation wound treatment can improve the result and minimize trauma for patients (Key 8-10).

Conclusion

In this article a simplified method is proposed and step-by-step illustrations on the surgical procedures is provided so doctors can use them as a guideline when approaching this type of cases.

References

1. Kokich VG. Surgical and orthodontic management of impacted maxillary canine. *Am J Orthod Dentofacial Orthop* 2004;126:278-83
2. Su B., Hsu YL, Chang CH, Roberts WE. Soft Tissue Considerations for the Management of Impactions. *International Journal of Orthodontics & Implantology*. 2011;24:50-59
3. Su CW, Hsu YL, Chang CH. 阻生齒的軟組織處理面面觀. *News & Trends in Orthodontics*. 2011;22:54-59
4. Hsu YL, Chang CH, Roberts WE. OrthoBoneScrew. The dream screw for next generation's orthodontists. *International Journal of Orthodontics & Implantology*. 2011;23:34-49
5. Hsu YL, Chang CH, Roberts WE. OrthoBoneScrew. The dream screw for next generation's orthodontists. *News & Trends in Orthodontics*. 2011;22:34-51
6. Chang C. Advanced Damon Course, Beethoven Podcast Encyclopedia in Orthodontics 2012, Newton's A Ltd, Taiwan.
7. Chang C. VISTA Workshop Course, Beethoven Podcast Encyclopedia in Orthodontics 2011, Newton's A Ltd, Taiwan.
8. Yeh HY, Chang C, Roberts WE. Step-by-Step on the Open-Window Technique for Upper Palatal Impaction. *International Journal of Orthodontics & Implantology*. 2011;24:40-43
9. Cheng J, Chang CH. Simplified Open-Window Technique for Palatally Impacted Cuspid. *International Journal of Orthodontics & Implantology*. 2011;25:48-52
10. Chang C, Roberts WE. *Orthodontics, 3D iBooks Ortho.*, Taiwan: Newton's A Ltd, 2012.

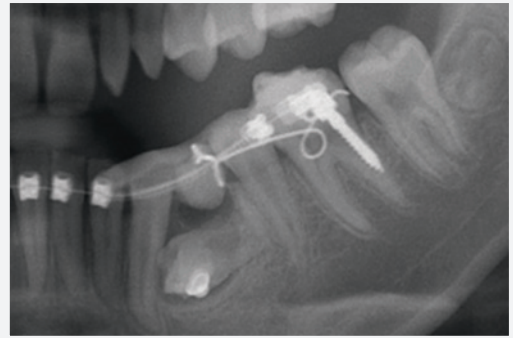


Fig. 18:
Check the final result of the operation on the panorex film.

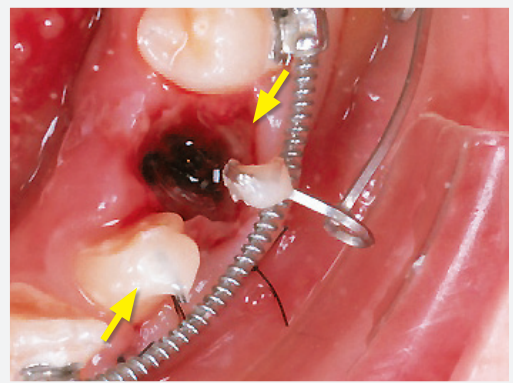


Fig. 19:
The direction of the force system is the key to make the impaction erupt. The horizontal mattress suture and the coronally repositioned flap can improve the outcome of soft tissues.

USC Comprehensive Surgical and Restorative Implant Training Program in Taiwan

南加大植牙專科進修課程 2012

時間：9:00am - 6:00pm

- 07/15 - 07/16, 2012(日、一 | 演講與實作 workshop)
- 08/12, 2012(日 | 視訊教學)
- 09/16 - 09/17, 2012(日、一 | 演講與實作 workshop)
- 10/07, 2012(日 | 視訊教學)
- 11/04 - 11/05, 2012(日、一 | 演講與實作 workshop)
- 12/02, 2012(日 | 視訊教學)
- 01/21-01/22, 2013(一、二 | 美國演講)
- 01/23, 2013(三 | 美國可選修的 cadaver workshop)
- 01/24, 2013(四 | 美國可選修的 cadaver workshop)
- 01/25-01/26, 2013(五、六 | 美國演講，畢業典禮)
- 01/27, 2013(日 | 美國可選修的 cadaver workshop)

地點：集思交通部國際會議中心。台北市中正區杭州南路一段二十四號。(2012年7月到12月)
Millennium Biltmore Hotel Los Angeles. 506 South Grand Avenue. Los Angeles, CA 90071 (2013年1月)

報名費：

台北和美國課程 (包含 USC 牙醫學院發出的培訓證書)

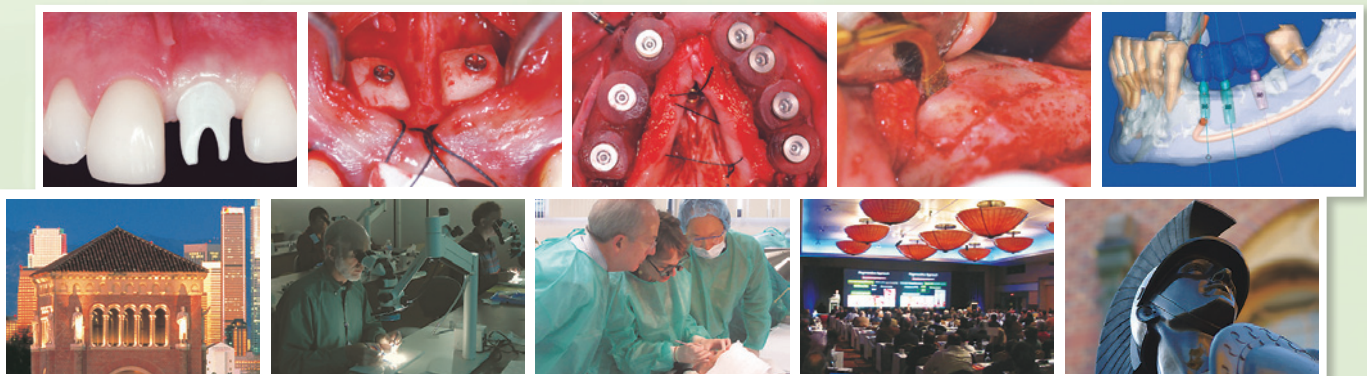- 6/1/12前報名：美金 \$8,500
- 6/1/12後報名：美金 \$9,000

台北課程 (不含 USC 牙醫學院發出的培訓證書)

- 6/1/12前報名：美金 \$5,950
- 6/1/12後報名：美金 \$6,450

可選修的 Cadaver Workshops on Bone and Soft Tissue Grafting 課程 (不含 USC 牙醫學院發出的培訓證書)

- 9/1/12前報名：美金 \$1,115
- 11/1/12前報名：每一堂課美金 \$1,395
- 11/1/12後報名：每一堂課美金 \$1,595



南加大講員陣容

*Homa Zadeh * Avishai Sadan * Baldwin Marchack * Casey Chen * Domenico Cascione
Ilan Rotstein * Yang Chai * Songtao Shi * Parish Sedghizadeh * Ramin Mahallati*

演講嘉賓：*Stephen Wallace * Lyndon Cooper * Fernando Rojas-Vizcaya * Clark Stanford*

• 欲知詳情，請與以下單位聯絡 •

USC 聯絡人：Julie

E-mail : julie.chen@usc.edu Web : www.uscdentalce.org

Tel : +1-213-821-5281

Fax : (07) 615-0913

金牛頓藝術科技 聯絡人：葉芳如

Email : rita@newtonsa.com.tw

Tel : (03) 573-5676

Restoration of the Upper and Lower Dental Arches with Monolithic Zirconia-fixed Detachable Prostheses: Clinical Report after Three Years of Use

Summary

In the case of fixed detachable dental prostheses some problems arose for patients, dental technicians and dentists. The most frequently emerging general problem is loosening or breakage of the occlusal screws. Further problems turned out to be wear and detachment or breakage of the resin teeth from metal acrylic blends, the breakage of porcelain from metal and ceramic or zirconia and ceramic blends as well as breakage of the framework in some free-end prostheses.

For this type of prosthesis it is necessary to leave the implants in a position that enables occlusal or lingual access to not impair the aesthetics.

This clinical report describes the case of a patient with a complete restoration of fixed detachable, maxillary and mandibular prostheses out of 100% zirconia (*monolithic zirconia*). It includes the incisal and occlusal areas on angled dental implants with buccal access and an aesthetic prosthesis solution, for which no clinical complications in the patient's mouth have been reported after 3 years.

Keywords

Dental implants, zirconia framework, fixed detachable prosthesis, monolithic zirconia

Introduction

Restoring the entire mouth of a patient with dental implants and residual dentition is a challenge if there is a strong vertical and horizontal bone resorption, since this includes the '*pink aesthetics*' and restricts the position of the implants. Although it is possible to achieve large transplantations of bone-forming and soft tissue to recover a bone substructure - whereby the implants can be placed into the desired position and suitable soft tissue can be obtained to recover the "*pink aesthetics*" in a natural way - an alternative is to use fixed detachable prostheses which show the function and the "*pink and white aesthetics*", making the case much easier for the patient and less expensive at the same time.

Various materials were used for implementing this kind of restoration with different advantages and disadvantages. We can find prostheses made of metal/acryl, of metal/ceramic and zirconia/ceramic. For more than 21 years titanium frameworks were used as an alternative to cast gold alloys.^{1,2}

Fixed detachable dental prostheses made of metal/acryl pose the following problems: Loosening of the acrylic teeth, a lack of natural colour primarily in the '*pink aesthetics*' area, as well as wear and tear with time, requiring replacement teeth and constant repairs as a consequence. Prostheses made of metal/

Fernando Rojas-Vizcaya, DDS, MS
Adjunct Assistant Professor, University of North Carolina
Founder, the Mediterranean Prosthodontic Institute



porcelain offer excellent aesthetic results, however with the disadvantage that the porcelain can break, the entire restoration becomes endangered and they are therefore considered a difficult solution.

Prostheses made of zirconia/ceramic showed the problem of ceramic breakage or breakage of the zirconia framework and made the repair impossible. In addition, if the implant is in an angled position because of the anatomy of the bone, the access to this implant takes place buccally via the prosthesis in the aesthetic area. In a buccal wall between two restorations or in the connection of restoration to gingiva, it is very difficult to achieve an aesthetic result at the end of the long-term treatment, since it is necessary to implement composites which impair the aesthetics in this area.

Also, for patients with a 'gingiva smile', the treatment of the 'pink aesthetics' with acrylic or ceramic is important.

This report describes the case for a complete restoration using a fixed detachable upper and lower prosthesis. Both upper and lower fixed detachable restorations include the entire occlusal surface, and the incisal edges are made of 100% zirconia (*Prettau zirconia, Zirkozahn*) to prevent breakage, as with conventional ceramic, which is then coloured with

Colour Liquid (*Zirkozahn*) to achieve the desired "pink and white aesthetics". In addition, within the upper section, two sub-structures were made of 100% zirconia (*Prettau zirconia, Zirkozahn*), which, as far as the palatal region is concerned, are screwed at the fixed detachable prosthesis to solve the angulation problem of some implants, which make it necessary to access the restoration through the buccal area. In such a way the advantages are evident in similar cases, where individual facings are cemented in the macro structure, because it is easier to unscrew than to remove the cement when checks need to be made or problems with the implants have to be treated.

This clinical report describes a case where monolithic zirconia was used for this kind of restorations.

Clinical Report

A 52-year-old patient with residual dentition and bone loss due to advanced periodontal disease (*Fig. 1*) without impairment of general health, who would like to have "fixed teeth".

Where advanced bone loss has been detected, an X-ray has to be taken and the possibility of inserting dental implants in the still existing bone will be considered, although not in the lower posterior

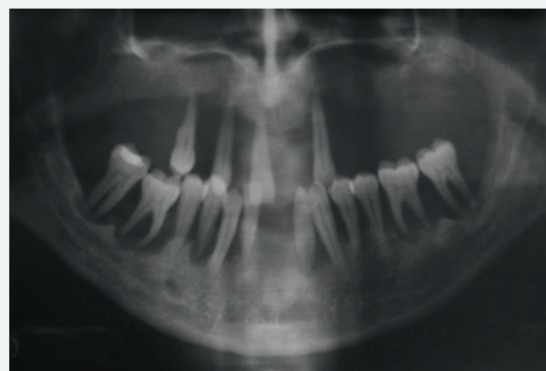
region on both sides. A complete restoration of the entire mouth will be planned by using fixed detachable prostheses, which are supported by dental implants.

The treatment is divided into different phases, in order to control the function and the aesthetic appearance of the patient at any time.

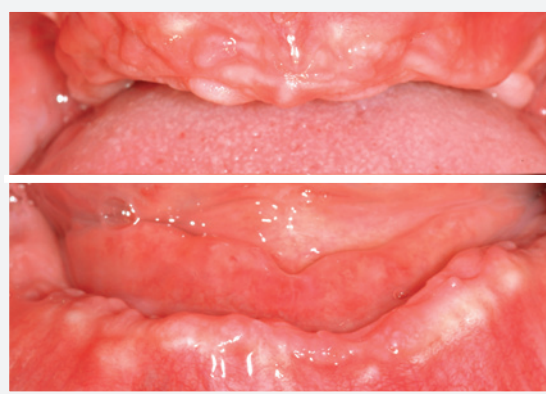
In the first state, tooth extractions are carried out and the positioning of the interim complete denture is made immediately to recover the vertical dimension⁴, and to determine some aspects of the aesthetics.

In the 8th to 12th week stage (Fig. 2) the positioning of the 8 upper and 6 lower Astra-Tech Implants (Astra Tech AB, Mölndal, Sweden) (Fig. 3,) is done by using a duplicate of the prosthesis as a surgical drilling template and then by inserting straight gingiva formers (Healing Abutments Astra Tech AB, Mölndal, Sweden) which show clearly the angulations of some the implants and the future emergence for the buccal areas. After stitching up, the interim complete dentures are adapted, so that they do not touch the healing abutments during the osseointegration process.

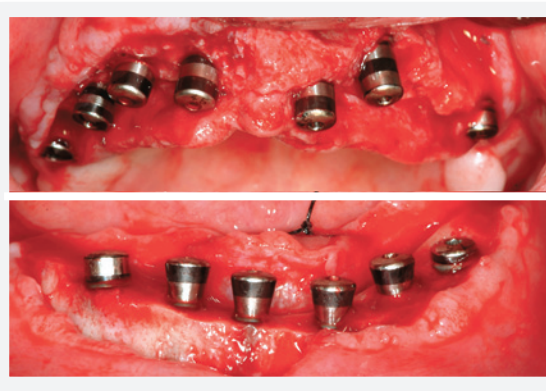
After the osseointegration, the healing abutments are replaced by solid titanium abutments of 3 mm height for screw retained restorations (20° UniAbutments Astra Tech AB, Mölndal, Sweden) in each implant (Fig. 4). The final abutment level impressions



■ Fig. 1



■ Fig. 2

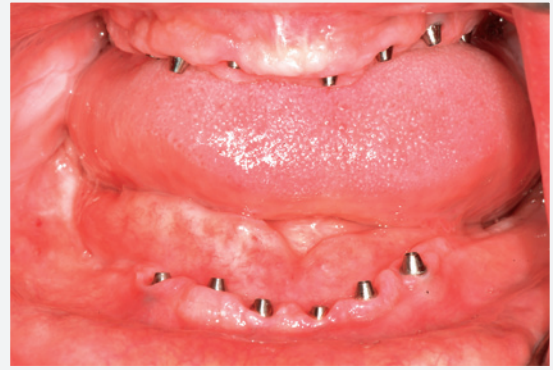

■ Fig. 3

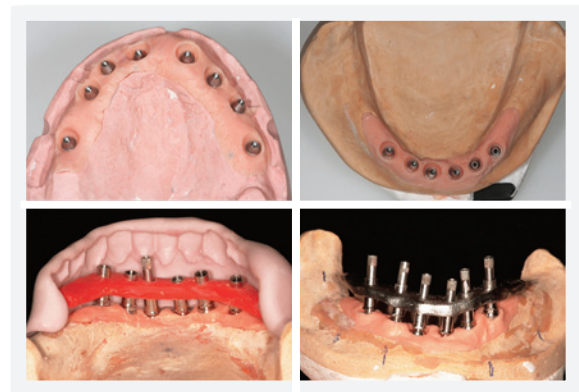
are then taken and the closing copings (20° ProHeal Cap Astra Tech AB, Mölndal, Sweden) are placed on them, in order to cover these abutments.

The maxillary relation is taken with the face-bow and, then the vertical dimension and the bimaxillary relation will be transferred to a semi-adjustable articulator. Two master cast were fabricated. A metal framework was manufactured at the lower fixed detachable prosthesis which is built into the prosthesis together with some temporary cylinders (Temporary Cylinder Uni 20° Astra Tech AB, Mölndal, Sweden). This bar does not have to be fastened to these cylinders; however, the cylinders and the bar are built in the acryl, in order to guarantee a high resistance in the area of the free end prostheses (Fig. 5). Afterwards two fixed detachable provisional upper and lower restorations are manufactured (Fig. 6). Through this, the terminal parameters of aesthetics and function are determined.

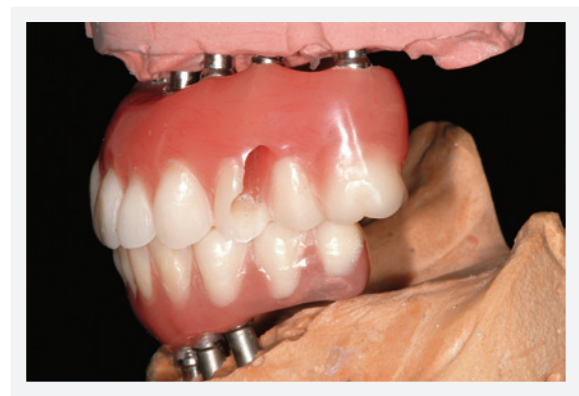The analysis of the "patient smile" showed how the commissural line did not run parallel to the bipupillary line, and the lip showed some asymmetries when relaxing and asymmetrical movements at different moments during the smile, which made the analysis difficult. The necessary modifications are carried out at these provisional fixed detachable restorations; the incisal edges of the central maxillary incisors are shortened and the line of the patient's smile is drawn in relation to the lower lip. The coronal part is also heightened by adding light-cured composites to compensate for the incisal



■ Fig. 4



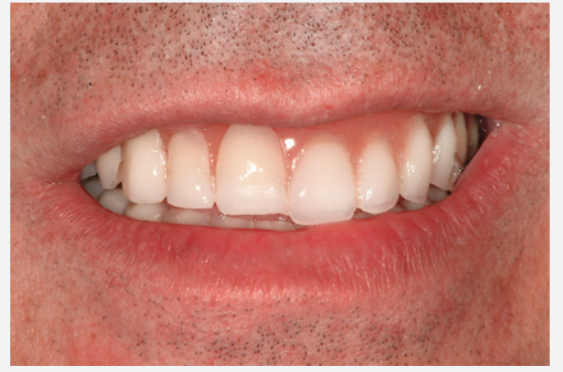■ Fig. 5



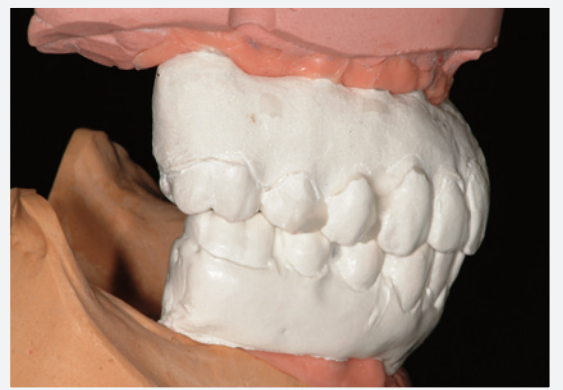■ Fig. 6

wear and to reduce the gingiva area, which becomes visible when smiling (Fig. 7). When all aesthetic and function parameters for the patient were reached, the upper and lower alginate impressions were taken, and the upper and lower models, as a copy of the provisional fixed detachable restorations, were then manufactured. Afterwards the prostheses of the patient are unscrewed and the upper prosthesis is screwed into the articulator and the lower model will be installed. Afterwards the upper model will be mounted with the same vertical dimension against the lower model already installed. From this form the dental technician can manufacture the upper resin prosthesis for the fitting by using the lower model as an antagonist to be able to control the occlusal plane, the middle line and the smile line. As soon as the two prostheses made of white resin (*Frame, Zirkonzahn*) are manufactured (Fig. 8) they will be screwed in the mouth of the patient, in order to evaluate the perfect occlusion and aesthetics, since any kind of changes can still be carried out during this phase of the treatment (Fig. 9).

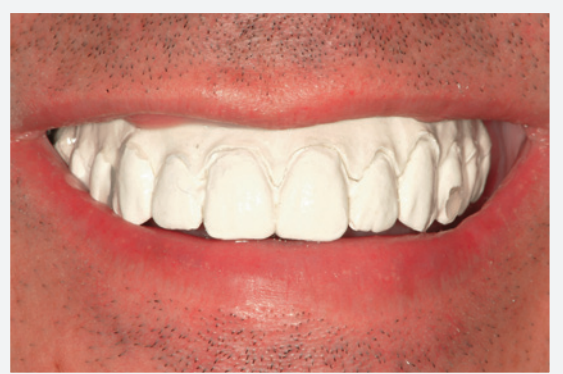After having controlled all aesthetic and functional aspects, the white acryl prostheses are copied into full zirconia prostheses in the laboratory (Figures 10, 11) and then coloured with appropriate colours, selected for teeth and gingiva (Figures 12, 13 and 14). The gingival colour was selected for the patient by means of a colour chart for the pink coloured ceramic (*Ceramic Tissue, Zirkonzahn*).



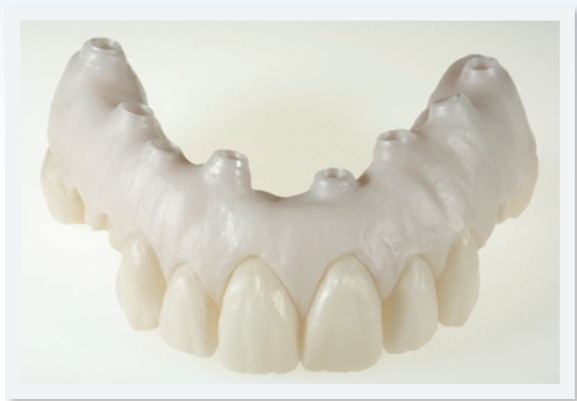■ Fig. 7



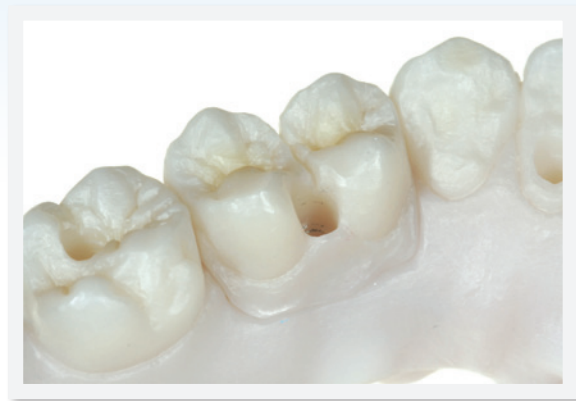■ Fig. 8



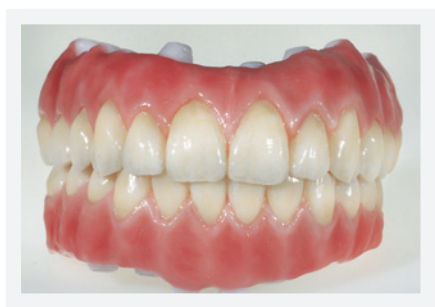■ Fig. 9



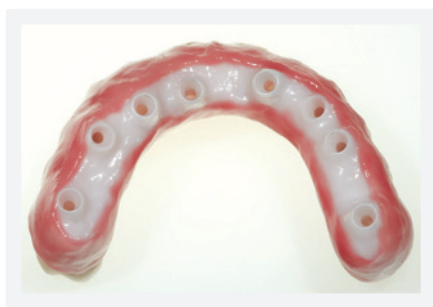■ Fig. 10



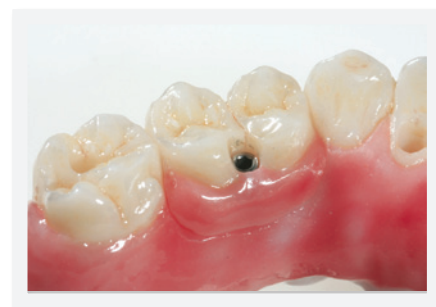■ Fig. 11



■ Fig. 12



■ Fig. 13



■ Fig. 14

The passive fit of the restorations on the abutments can be evaluated in a different way; pressure is applied first on one end abutment and then on the other side⁵ without noticing any movements of the prostheses. Then a visual check is carried out and with the assistance of an explorer, the fit could be evaluated⁶ and, during the radiological analysis,⁷ the continuity between the zirconia prostheses and all abutments will be verified (Fig. 15). By accomplishing



■ Fig. 15

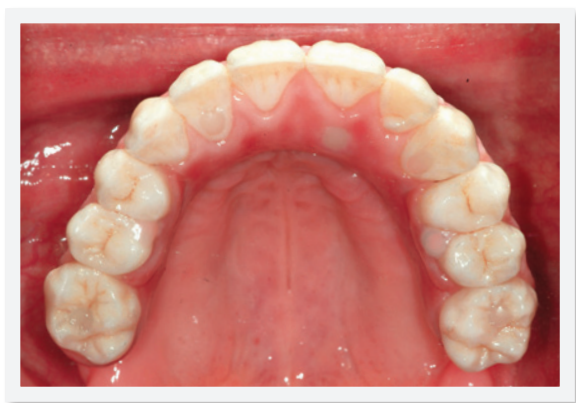the passivity test with only an individual screw (*One screw test*)⁸ in one of the end abutments, no movement in the restoration can be noticed and the restoration remains in its position in the opposite end abutment.

The final lower fixed detachable prosthesis made of 100% zirconia (*Prettau zirconia, Zikon Zahn*) is screwed together and tightened with a torque of 15 Ncm. The screws will then be covered with gutta-percha and the access with pink composite, provided that it is in the area of the gingiva, and with white composite, similar to the colour of the teeth, if the access takes place via the lingual area. In the upper prosthesis, at first the macro structure and then the sub-structures, which cover the access to the angled implants, are screwed together with a torque of 15 Ncm and these sub-structures are also screwed together over the palatal area with a torque of 15

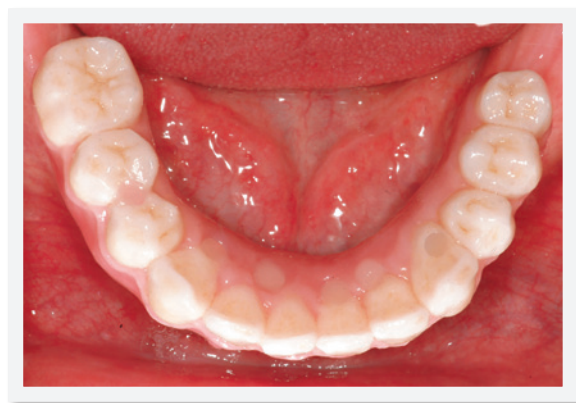Ncm (*Figures 16, 17*). Afterwards the accesses are covered with gutta-percha and composite.

The initial X-ray control (*Fig. 15*) shows the fitting of the fixed detachable restorations on the abutments and the bone at the level of the implants. The X-ray control after 3 years (*Fig. 18*) from the time of the use of the prostheses did not show any changes to the level of the bone compared with the initial X-rays. The soft tissue remained steady, neither an inflammation nor bleeding arose within any region, and in the restorations no change could be determined, neither a breakage within the occlusal or incisal areas nor any wear could be recognized. The patient did not report any problems (*Figures 19, 20*).

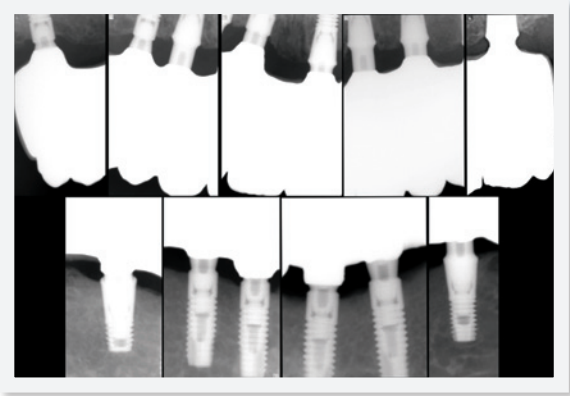
The prosthesis made of 100% zirconia gave the patient both function and aesthetic appearance.



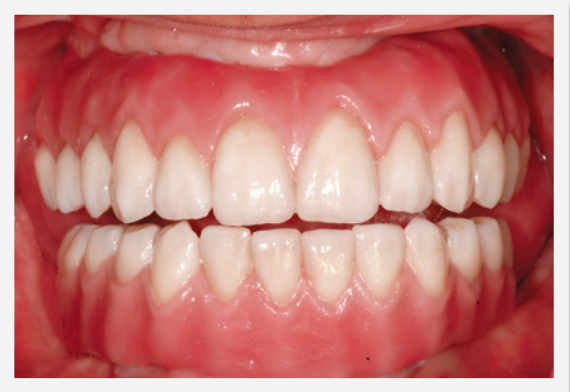■ Fig. 16



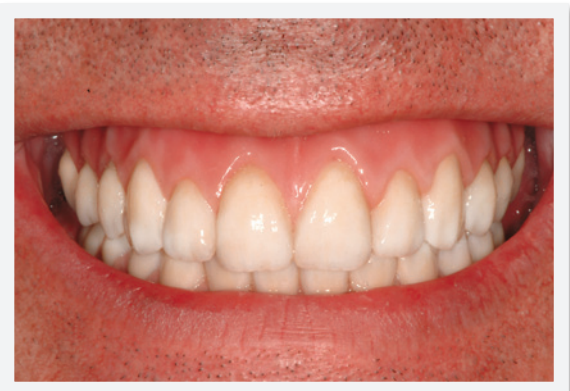■ Fig. 17



■ Fig. 18



■ Fig. 19



■ Fig. 20

Discussion:

Previous reports and studies are about fixed detachable prostheses made of metal/acryl, metal/ceramic or zirconia/ceramic, however, they are not about prostheses made of 100% zirconia. In the case of these studies, which were made with hybrid prostheses using frameworks of various materials, different kinds of complications arose. In 1999, Bergendal reported in a study, performed over a period of 5 years, in which he compared titanium frameworks and gold alloys,³ on several breakages of titanium frameworks and on slightly more breakages of artificial teeth than of teeth made of gold alloys. In 2000, Örtorp and his collaborators reported in a 1 year prospective study on no mechanical complication except for some breakages of the resin facing.⁹ In a prospective study regarding a clinical test over a period of 36 months, Duncan reported in 2003 that sixty-eight per cent of patients who were provided with fixed detachable prostheses had complications. For the majority of patients this concerned a breakage of the resin teeth, more frequently within the front area than within the rear area and with a larger tendency approximately after 1 year of use.¹⁰ In 2009, Örtorp reported in a comparative follow-up study on supervision over a period of 15 years, in which laser welded titanium frameworks were compared with gold alloy frameworks, that the breakage of the resin or acryl teeth and the inflammation of the soft tissue were the most usual complications with hybrid prostheses implemented with titanium frameworks. Breakages

in the titanium framework were detected in 15.5% of the patients. More breakages were detected in the case of titanium work compared with gold alloy work.¹¹

Some clinical reports on the use of porcelain, which was merged with zirconia prostheses, did not result in mechanical complications.

There are only a few reports on hybrid prosthetic restorations with zirconia frameworks. Those, which belong to the FPDs (*fixed partial dentures*), have shown that breakage of the porcelain facing is caused by the strain in the framework, since most of the breakages arose in the interface between framework and the layer of porcelain.^{12,13} There are some long-term clinical studies about frameworks made out of zirconia oxide, which were used in fixed partial prostheses.^{14,15,16} Moreover there are some reports concerning cases with frameworks made out of zirconia on natural teeth¹⁷ and others concerning hybrid prostheses on implants using zirconia frameworks without any complication during a monitoring period of 6 months.^{18,19}

An article in German and French describes the manufacturing process of a complete fixed prosthesis in an edentulous mandible, supported by seven implants. Two prostheses were made, one of a titanium framework with resin veneers and another from zirconia framework, experimentally with ceramic veneers.²⁰

As far as the author has knowledge, no clinical report was published about the complete fixed detachable restoration made of 100% zirconia.

In this case report, no complications were evident after using the prostheses made out of 100% zirconia from a monolithic zirconia over a period of 3 years. There were no breakages in the framework, neither were there breakages in the cusps nor wear or tear in the occlusal surfaces, or loosening of the screws. There was no presence of tartar, and the bone level remained stable during the X-ray analysis of all implants.

In the future long-term studies must be carried out, in order to compare this kind of material with the materials existing on the market and to determine the advantages, which were discussed in this report.

Acknowledgments:

This case was worked on by D.T. George Walcher in the dental laboratory of Enrico Steger, Bruneck, Italy. The temporary fixed detachable prostheses were worked on by D.T. Jorge Cid Yañez in the laboratory of the Mediterranean Prosthodontic Institute, Castellon, Spain. Thank you for your co-operation.

Bibliography

1. Sjögren G, Andersson M, Bergman M. Laser welding of titanium in dentistry. *Acta Odontol Scand* 1988; 46:247–253.

2. Örtorp A, Linden B, Jemt T. Clinical experiences of laserwelded titanium frameworks supported by implants in the edentulous mandible. A 5-year follow-up study. *Int J Prosthodont* 1999; 12:65-72.
3. Bergendal, Palmqvist. Laser-Welded Titanium framework for Implant-Supported Fixed prostheses:A 5-Year Report. *Int J Oral Maxillofac Implants* 1999;14:69-71
4. Turrel AJ. Clinical assessment of vertical dimension. *J Prosthet Dent* 1972;28:238-46.
5. Henry PJ. An alternate method for the production of accurate cast and occlusal records in the osseointegrated implant rehabilitation. *J Prosthet Dent* 1987;69:4-7.
6. Yanase RT, Binon PP, Jemt T, Gulbransen HJ, Parel S. Current issue form. How do you test a cast framework for a full arch fixed implant supported prosthesis ? *Int J Oral Maxillofac Implants* 1994;9:471-4
7. Hollender L, Röckler B. Radiographic evaluation of osseointegrated implants of the jaws. Experimental study of the influence of radiographic techniques on the measurement of the relation between implant and bone. *Dentomaxillofac Radiol* 1980;9:91-5.
8. Tan KB, Rubenstein JE, Nicholls JI, Yuodelis RA. Three-dimensional analysis of the casting accuracy of one piece, osseointegrated implant retained prostheses. *Int J Prosthodont* 1993;6:346-63.
9. Örtorp A, Jemt T. Clinical experiences of computer numeric control-milled titanium frameworks supported by implants in the edentulous jaw: A 5-year prospective study. *Clin Implant Dent Relat Res*, 2000;2(1):2-9
10. Duncan JB, Nazarova E, Vogiatzi T, Taylor TD. Prosthodontic complications in a prospective clinical trial of single-stage implants at 36 months. *Int J Oral Maxillofac Implants* 2003;18:561-565.
11. Örtorp A, Jemt T. Early laser-welded titanium frameworks supported by implants in the edentulous mandible:a 15-year comparative follow-up study. *Clin Implant Dent Relat Res*, 2009,11(4):311-322
12. Flemming GJ, Dickens M, Thomas LJ, Harris JJ. The in vitro failure of all ceramic crowns and the connector area of fixed partial dentures using bilayered ceramic specimens: the influence of core to dentin thickness ratio. *Dent Mater* 2006;22:771-7.
13. Tsumita M, Kokubo Y, Vult von Steyern P, Fukushima S. Effect of framework shape on the fracture strength of implant-supported all-ceramic fixed partial dentures in the molar region. *J Prosthodont* 2008;17:274-85.
14. Sailer I, Fehér A, Filser F, Gauckler LJ, Lüthy H, Hämmerle CH. Five-year clinical results of zirconia frameworks for posterior fixed partial dentures. *Int J Prosthodont* 2007;20:383-8.
15. Kohorst P, Herzog TJ, Borchers L, Stiesch-Scholz M. Load-bearing capacity of allceramic posterior four-unit fixed partial dentures with different zirconia frameworks. *Eur J Oral Sci* 2007;115:161-6.
16. Chang PP, Henegbarth EA, Lang LA. Maxillary zirconia implant fixed partial dentures opposing an acrylic resin implant fixed complete denture: a two-year clinical report. *J Prosthet Dent* 2007;97:321-30.
17. Keough BE, Kay HB, Sager RD. A ten-unit all-ceramic anterior fixed partial denture using Y-TZP zirconia. *Pract Proced Aesthet Dent* 2006;18:37-43.
18. Papaspyridakos P, Lal K. Complete arch implant rehabilitation using subtractive rapid prototyping and porcelain fused to zirconia prosthesis: a clinical report. *J Prosthet Dent* 2008; 100:165-172
19. Hassel AJ, Shahin R, Kreuter A, Rammelsberg P. Rehabilitation of an edentulous mandible with an implant-supported fixed prosthesis using an all-ceramic framework: a case report. *Quintessence Int.* 2008 May;39(5):421-6.
20. Teubner E, Pietrobon N, Lorenzo A, Marinello CP. The interdisciplinary fixed restoration of an edentulous maxilla with a marked resorption of the alveolar crest. A case report. Part II: the definitive restoration *Schweiz Monatsschr Zahnmed.* 2009;119(5):467-82. [Article in French, German]

Newton's A

金牛頓藝術科技

2012 Implant Forum

	日期 (W5)	09:00 ~ 11:00	11:00~ 12:00
		矯正 / 植牙病例分享	ITP vol 2 case 文章導讀
1	2/17	張慧男 醫師	ITP vol 2 case 4
2	3/30	方鐘鼎 醫師	ITP vol 2 case 3
3	4/27	外賓特別演講 曾春祺 醫師	
4	5/18	ITP vol 2 case 5	IAOI case demo
5	6/22	邱上珍 醫師	ITP vol 2 case 16
6	7/27	外賓特別演講 彭玉秋 醫師	
7	8/31	ITP vol 2 case 8	IAOI case demo
8	9/28	ITP vol 2 case 12	IAOI case demo
9	10/19	外賓特別演講 許榮仁 醫師	
10	11/23	外賓特別演講 張燕清 醫師	
11	12/28	張慧男 醫師	ITP vol 2 case 15



南下高雄開業，迄今已逾十五年時間，邱醫師最感受用的，是她在三十五歲開業之初學會矯正，在四十六歲還沒得老花眼時學會了植牙。邱醫師坦言，在職進修必然造成壓力，它可能來自於時間、金錢與家庭，畢竟一天只有二十四小時，但終身學習所創造的成就感與報酬，卻讓她覺得當牙醫「真是好玩」，而且將持續下去，謹此與讀者分享。本文摘錄自2010最新一期《台大牙友》

邱丕霞醫師 邱丕霞牙醫診所負責人



曾春祺醫師與 Implant Forum 學員合影


2012 貝多芬矯正精修班

每月中 週二 上午 9:00-12:00

Part IV

★地點：金牛頓教育中心（新竹市建中一路 25 號 2 樓）

No.	日期 (W2)	精緻完工病例分析 09:00~09:50	精選 C.O. 文章分析 10:00 ~ 10:50	精緻完工技巧 11:00~11:50
34	5/22	Adult Complex Case 1	Ch.13: Timing of Growth Modification Treatment of Transverse Maxillary Constriction (p.495 ~ 510)	Finishing Tip 1
35	6/19	Adult Complex Case 2	Ch.13: Treatment of Class III, Treatment of Class II Problems (p.510 ~526)	Finishing Tip 2
36	7/10	Adult Complex Case 3	Ch.13: Extraoral Force: Headgear Combined Vertical and A-P Problems Facial Asymmetry in Children (p.526 ~ 547)	Finishing Tip 3
37	8/14	Adult Complex Case 4	Ch.14: The First Stage of Comprehensive Treatment (p.551~ 576)	Finishing Tip 4
38	9/18	Adult Complex Case 5	Ch.15: The Second Stage of Comprehensive Treatment (p.577 ~ 601)	Finishing Tip 5
39	10/16	Adult Complex Case 6	Ch.16: The Third Stage of Comprehensive Treatment (p.602 ~ 616)	Finishing Tip 6
40	11/20	Adult Complex Case 7	Ch.17: Retention (p.617 ~ 631)	Finishing Tip 7
41	12/18	Adult Complex Case 8	Ch.18: Adjunctive Versus Comprehensive Treatment ~ Adjunctive Treatment Procedures (p.635 ~ 651)	Finishing Tip 8
42	1/15/13"	Adult Complex Case 9	Ch.18: Comprehensive Treatment in Adults (p.651 ~ 673)	Finishing Tip 9
43	3/19/13"	Adult Complex Case 10	Ch.18: Special Aspects of Orthodontic Appliance Therapy (p.673 ~ 685)	Finishing Tip 10
44	4/16/13"	Adult Complex Case 11	Ch.19: Indications for Orthognathic Surgery ~ Contemporary Surgical Techniques (p.686 ~ 708)	Finishing Tip 11



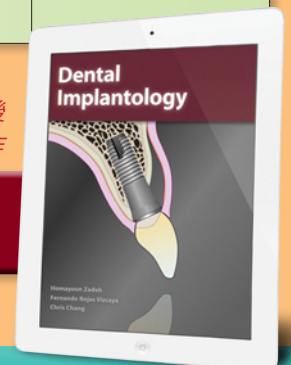
課程目標

藉由精讀 “Contemporary Orthodontics” 協助學員了解古典到現代之文獻，應用於實際病例，並藉由 DI 及 CRE 達成精緻完工 (Excellent Finishing) 之目標。

全球第一本 矯正醫學電子書後
另一曠世鉅作

Dental Implantology
植牙醫學電子書

7/15 全球首賣



金牛頓藝術科技




Authorized Reseller
授權經銷商

星期四

9-5 pm



Keynote
高效簡報學習法



K1 簡報聖經

8/16

看過太多充滿複雜文字和圖表的幻燈片，聽過就忘了的演講嗎？Keynote 系列一的演講要教你如何利用 Keynote，製作出令人目眩神迷、印象深刻的電腦簡報。透過小班教學，貼身指導，務必讓你在八小時裡輕鬆掌握 Keynote 的簡報技巧。

學習重點：1.Keynote 操作入門 2. 演講常見十大謬誤 3. 資料視覺化技巧




K2 Dr.Kokich 令人屏息的十大演講秘訣

9/20

Keynote 系列二位各位介紹世界牙醫界的天王講師 Dr.Kokich 的十大演講秘訣，讓您在進階的課程中更加掌握演講設計的關鍵原則，不但讓你知其然，更知其所以然！

學習重點：1.Dr.Kokich 十大演講秘訣 2. 準備演講的九個步驟 3. 多媒體影片剪輯



K3 賈伯斯令人目眩神迷的五項演講技巧

10/18

總結我們 Keynote 系列的系列三，我們為大家逐步解析跨界演講大師 Steve Jobs 是如何說出打動人心、價值數十億美金的關鍵故事。透過逐步的分析拆解，要讓您也可以成為獨具魅力的演講人。

學習重點：1.Steve Jobs 的五項演講技巧 2. 幻燈片的設計概念 3. 幻燈片修改應用

好康

連續報名三堂課，學費再享 **8** 折優惠！

報名專線：03-5735676

Hours：2-9 pm

上課地點：新竹市建中一路 25 號 (交大華廈) 2 樓

Keynote 高效簡報學習法系列課程

K4 / 5 / 6

簡報繪圖
精修課程

2012

11/17-19

Sat-Mon

9am-5pm

預計招生：限額 25 名

Effective dental presentation in today's digital world requires not only clear clinical photos but also diagrams and animation to engage the audience. Moreover, these visual tools are excellent aids to make your presentation unique and memorable. In this workshop Dr. Rungsi will share his dental illustration experiences and demonstrate step by step how to create an illustration from an initial sketch to a finished piece. Active participation and completion of workshop assignments are required for workshop participants.

TOPICS :

Why will you learn?

- How to use a digital drawing board.
- Design illustration in your Keynote.
- Showcase your own drawing with stunning animation in Keynote.
- Create complicated diagrams using Adobe Illustrator and Photoshop.
- Animation Competition

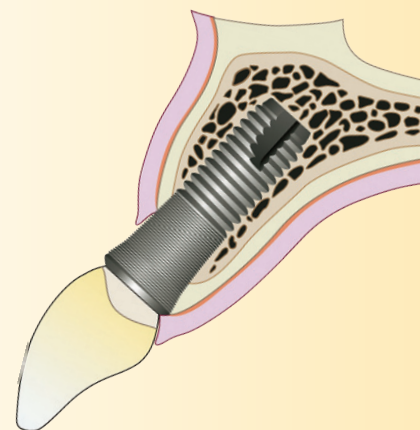
Requirements :

- Mac computer with OSX 10.6 or later
- Digital drawing Tablet (Wacom recommended)
- iWork 09'
- Adobe Illustrator CS4 and Adobe Photoshop CS4 (or later version)



Dr. Rungsi
Thavarungkul

Make Your Presentation
Unique & Memorable !



Newton's A

Feedback on the 3D iBooks Ortho




Dear Chris and Shu-Fen:

Every opportunity I have had to spend time with you both is an absolute pleasure! Thank you for your commitment to the Progressive Study Club and to Orthodontics. You are an inspiration and my idols! We had a great time in Grand Cayman and look forward to the next opportunity to get together. Seems it is not often enough. **Thank you as well for sharing the iBook, "Orthodontics". It is an absolute marvel and I learn something every time I review it.**

I am teaching periodically at Univ. of California, San Francisco Orthodontic Department. I have had a bit of a difficulty getting through the Bureaucracy of the California school system but I will eventually prevail. The Residents are my focus and my commitment and continue to be my reward. I was just there in San Francisco and showed the Residents your book on my iPad. They were very excited about it and are looking forward to the complete addition. While I was showing the book to the faculty a young Doctor, just recently graduated from the school, took a special interest in your book. He said it looked familiar and asked who was the author. I said, Chris Chang. He then said, "Oh I know Chris Chang and Shu-Fen! I have been in their office and home." This young man is James Chen, son in law of Frank Chang, (I think) and visited your office on his last trip to Mainland China, where his family is from and he has relatives. He asked me to say hello and to ask if you are ever in San Francisco if you would consider a visit to the UCSF Orthodontic Department. Perhaps someday this could happen.

Hopefully this note finds you both well and happy. I know you are very busy! I think you do not ever sleep. Thank you for all you do for all of us.

*Until the next opportunity
Your friend,*



John A. Coombs D.D.S.

*Associate Instructor, the Orthodontic Department
at the University of California, San Francisco*



Dear Chris:

Thank you for sending me your textbook. **We are so fortunate that we can bring your energy to our continent. Your work is marvelous. As an ABO examiner I am so impressed with how you formatted the case presentations. It is a compliment and a needed affirmation of standard of care definition.**

I so look forward to getting to know you better. We share numerous treatment interests. To give you an insight into the area of work that I have been involved in this past year, I am sending you some articles through a "drop box" website. You will receive a separate email with instructions on how to access these articles.

Again you are quite generous to send me your textbook. I look forward to applying your principles to my practice and own professional advancement.

*Warmly,
Ron*



Dr. Ronald J. Snyder D.D.S.

*President, Snyder Orthodontics
Midwest Angle Society*




Dear Chris:

How could Teresa and I possibly arrive home without sending you a "thank you" on our first day home? *It was an absolute pleasure meeting you and your wife - especially knowing that I have met the real "Einstein!"*

I can't thank you enough for your generosity in presenting me with the iPad and Book. You can be assured I will be showing everyone at the Study Club. *I am being sincere when I say that after meeting you, I feel like I should be starting all over with my studies.* I was so impressed with your knowledge and enthusiasm - not to mention your wife's beautiful smile. Dr. Roberts must be extremely proud to have associated himself with you.

Anyway, Chris - thank you again for everything. You have so much to offer the orthodontic profession that I predict you will be a worldwide and renowned individual whose name will be remembered long after you have departed this world. I would bet my last dollar on you!

*Best Wishes always! Your friend(s),
Tom (& Teresa)*



Dr. Thomas F. Mulligan D.D.S., M.S.D.
Author, Common Sense Mechanics in Everyday Orthodontics II



Dear Tzu Han:

Although I knew that you will launch the "Orthodontics" book in this March, *I was still surprised with the iPad version of this book. It 's so stunning.* Even though I've been using iBook Author myself, I'm still very much impressed by this book. At first I thought that Newton's A would only publish some chapters of this book in iBook format but your team hit me like a ton of bricks with the complete book in this advanced digital format.

*Great Job, keep going.
So proud to work with all of you.*



Dr. Rungsi Thavarungkul D.D.S.
Guest Editor, International Journal of Orthodontics & Implantology



Chris Chang, DDS, PhD

Learn fast,

Save big!

矯正研習包

Ortho combo

- Damon Q
- Advanced
- Excellent Finishing
- OrthoBoneScrew

USD
1200

From beginners to advanced clinicians, Dr. Chris Chang will share everything you need to know about the combined use of the latest Damon system and orthodontic bone screws in just 45 sessions.

Voiced version in Chinese

USD **1800**

~~USD 1920~~

診所行銷包

E-Clinic combo

- E-consultation:
Ortho, Pedo, Implant
- Assistant

USD
900

Want to stand out in the fierce competition of private practice? The combo features the assistant training program you always dream of as well as informative patient consultation materials. All is ready to be used in your clinic today!

Voiced version in Chinese

USD **1885**

~~USD 2070~~

植牙精進包

Implant combo

- Implant Forum
(Voiced version in Chinese)

22 sessions of clinical discussions on the most current and practical topics in implant dentistry, facilitated by Dr. Chris Chang.

Voiced version in Chinese
only

USD **1100**

~~USD 1200~~

awesome Packages!!

AMAZING DISCOUNT

Awesome combo **USD 1800 !!**

Chinese-version combo **USD 4000 !!** ~~4785~~

Newton's A, Inc.

<http://www.orthobonescrew.com>
E-mail: rita@newtonsa.com.tw

TEL : +886-3-5735676



矯正研習包

- Damon Q
- Advanced
- Excellent Finishing
- OrthoBoneScrew

NTD **50,000**

~~NTD 59,800~~

由矯正名師張慧男醫師深入淺出的生動教學，讓您在短短45堂課的課程裡，完全掌握結合最新的矯正系統Damon以及矯正骨釘OBS的實用治療秘訣。無論是矯正新手或是想要持續進修的專科醫師都不可錯過！

植牙精進包

- Implant Forum

NTD **20,000**

~~NTD 28,600~~

由矯正名師張慧男醫師主持，邀集國內外植牙講師，整理當前植牙的熱門主題，透過22堂課的專題演講和個案分析，讓您在植牙學習之路上不斷精進！

診所行銷包

- E-consultation:
Ortho, Pedo, Implant
- Assistant

NTD **43,000**

~~NTD 48,400~~

還在苦於不知如何利用科技行銷診所特色？推廣專業服務？透過系統化的助理訓練課程，以及囊括「矯正」、「植牙」、「兒童牙科」三領域的**案例解說**和**衛教示範**，讓您輕鬆運用iPad 科技行銷您的專業診所！

awesome
Packages!!

合購超優惠價

NTD **10**萬元!! ~~NTD 113,000~~

請洽 金牛頓 (03)573-5676



視訊
之友

“回娘家”

凡2008年起
曾購買任一系列貝多芬視訊課程
皆可享有右側優惠

▶ **免費更新**課程，包含2011E-Consultation
矯正衛教篇皆有全新有聲檔可供免費更新。
(不含精修VF、植牙論壇VIF)

▶ **無聲升有聲**：凡單購無聲視訊課程，皆可
付些微差額，升級最新有聲課程。

▶ 免費安裝矯正植牙國際 **電子期刊**

▶ **iOS系統健檢**

Orthodontics Hard Copy & e-Book

Beethoven Dental Group, based in Hsinchu, Taiwan, has been serving our community since 1996. In addition to providing comprehensive, patient-centered care, Beethoven continues to transcend itself by delivering dental training courses, engaging in clinical research and regularly publishing world-class journal, *International Journal of Orthodontics and Implantology* (IJOI).

Over the years many complex and excellently finished cases

are published in IJOI. By popular demands a special selection of these cases, *Orthodontics*, is now available in hard copy and electronic (iBooks) edition. Besides well-documented treatment process and analysis, *Orthodontics* is also the world's first interactive orthodontic e-textbook. Once opening this book, your understanding of orthodontics will never be the same!



Use Multi-Touch Technology & Interactive Learning Interface

Rich audio/visual aids-Videos/3D Imaging Multimedia

Enable highlights, flashcards Note

Summary and Quiz Review

Which of the following procedures more complex protocol?

- A. Sinus lift.
- B. Bone grafting.
- C. Ridge augmentation.
- D. All of the above.

SECTION 1 - DIAGNOSIS AND ETIOLOGY

Pre-treatment facial photographs (Fig. 1) showed a slight gummy smile with moderate lower lip protrusion.

The orthodontist planned an adequate root distal movement to maintain the axial inclination of the mandibular second molars.

The overall results were pleasing to both the clinician and the patient. Facial harmony and lower lip protrusion were improved (Fig. 2). Post-treatment intraoral photographs (Fig. 3) and study casts show a slight Class II buccal interdigitation bilaterally. Dental midlines were aligned with the facial midline, and clear overjet and overbite were achieved.

Figure 1.14

The inclination of the occlusal inclination deviation between the occlusal plane and the lip back of molars. It would have been helpful to have panoramic radiographs to recognize the early stages of distally tipping. In conclusion, significant dental and soft-tissue improvement can be expected in young adult Class II patients treated with camouflage orthodontic tooth movement. A wide range of skeletal tilt can be camouflage with tooth movement. Bilateral effects to the periodontium. However, diagnosis, realistic treatment objectives, and mechanics are necessary to prevent undesirable

How much Biological Width?

Subsult Depth

Biological Width

TREATMENT RESULTS

The overall results were pleasing to both the clinician and the patient. Facial harmony and lower lip protrusion were improved (Fig. 1.8). Post treatment intraoral photographs (Fig. 1.6) and study casts show a slight Class II buccal interdigitation bilaterally. Dental midlines were aligned with the facial midline, and total overjet and overbite were achieved.

Amazing Class III Open Bite

▶ e-Book only USD 499 ~~USD 598~~

Amazing combo USD 600 ~~USD 865~~

(Hard Copy & e-Book)

Limited availability!!

buy e-Book and get

ABO Gauge 15

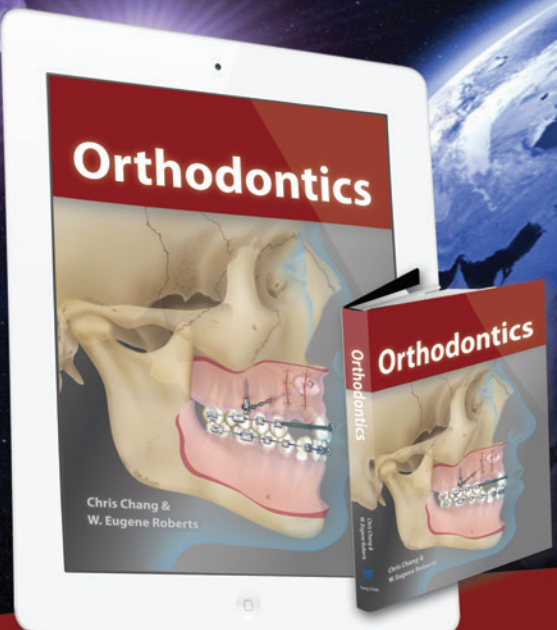
Tel: +886-3-573-5676

PUBLISH YOUR WORLD

iBooks Author

Apple announced its e-book publishing tool, iBooks Author, in January 2012. It is not just a software that empowers users to create their own books but a digital revolution that makes reading/learning fun and efficient with its intuitive interface design, multi-touch, and interactive widgets. Armed with such a powerful software in combination with iPads' dominance in the tablet market, Apple is expected to change the e-textbook market as we know it.

In view of this trend, Beethoven, as leader in the field of digital learning in orthodontics, is now publishing *Orthodontics*, the first orthodontic e-book using iBooks Author technology. Come experience it and learn like you never did before.



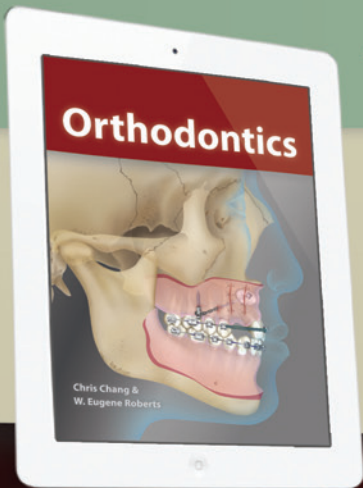
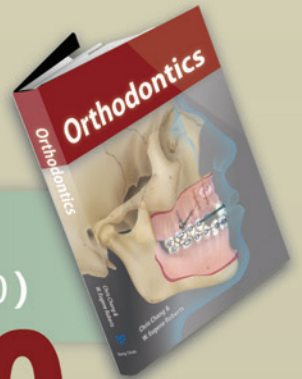
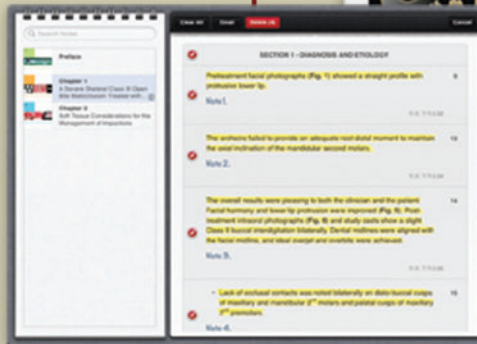
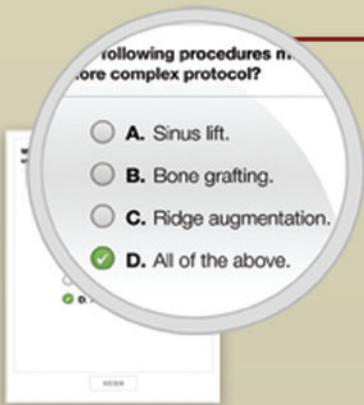
- Beautiful Layout
- Intuitive
- Interactive

全球第一本 iBooks Author 製作

6月底前
預購從速!!!

Orthodontics 矯正醫學電子書

- 多點觸控 & 互動式學習 介面
- 整合圖文、影音、3D模型、投影片等多媒體
- 隨時標記重點，系統自動整理 筆記
- 課後複習且提供隨堂 測驗



精裝本 售價 NTD 8000
電子書 售價 USD 598 (約NTD18,000)

合購優惠價 **NTD 15,000** (現省NTD11,000)

* 電子書於金牛頓門市安裝
* iPad安裝電子書需升級 iOS 5、iBooks 2.0以上版本
(請洽金牛頓服務人員)

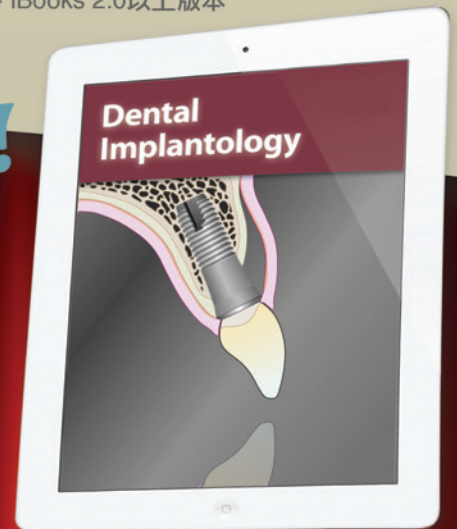
另一曠世鉅著

Coming Soon !!

Dental Implantology

植牙醫學電子書

7/15 全球首賣



歡迎來電預訂並享特別優惠!

版型美觀 直覺操作 互動體驗

* 訂購專線 (03)573-5676

Newton's A, Inc. Email: rita@newtonsa.com.tw http://www.orthobonescrew.com

6-201201 0401-0630



Chris H.N. Chang, DDS, Ph.D. Founder, **Beethoven Orthodontic Center**

- Taiwan Orthodontic specialist
- Author, 3D iBooks Ortho
- Publisher, International Journal of Orthodontics & Implantology
- ABO-Certified Orthodontist
- Ph.D., Dept. Orthodontics, Indiana University-Purdue

The Beethoven Dental Group

A Learning Organization

Tzu Han Huang

Beethoven, a worldly renowned musician, is also the name of a famous dental clinic in Taiwan. If you google it, it ranks the 5th in the research results, with more than 6,000 findings. From this you get an impression of its popularity by the general public on the internet.

The Beethoven Dental Group

The Beethoven is a dynamic team, led by Dr. Chris Chang, with its origin in orthodontics but quickly extending to general practice, pedodontic center, as well as specialized care in periodontics and prosthodontics. The team is consisted of excellent specialists as well as dental assistants. In addition to dental clinics, the Beethoven group established a subsidiary, Newton's A, Inc, whose primary focuses include dental information technology, development of dental equipment and providing dental education. In order to provide more comprehensive dental care, we will open an implant clinic next year.

Beethoven Orthodontic Center-Environment

When you first enter the clinic, you will be immediately greeted by

the beautiful and warm smile of our assistants. We have a very spacious waiting area and consultation space surrounded by lines of bookshelves with a wide selection of books and magazines to entertain you. What's even more precious is the open atmosphere created by French window and ample natural lighting.

Such a stress-free environment is appreciated by not only patients but also doctors who spend all day in the clinic. The greens from the outside is a soothing reminder of another beautiful day at work. The open design of the waiting area aims to create ample space for patients and facilitate communication between parents and doctors. This type of space design also allows a smooth and efficient workflow when patients arrive during peak hours.

The supply station is located at the rear side of the chairs, mainly for equipment and patient records. In addition, the technology structure is built on a Mac-based system, using Apple desktops, iMac, to store patient data, run the customized patient appointment system and its native presentation software, Keynote, to guide clinical consultation. All patients'



Orthodontic Center

records and photos are entered and saved before the end of a clinic session. The saved data is also shared between computers located in the internal network.

Beethoven Orthodontic Center-Operating system

One of the most unique features of the Beethoven clinic is its operating system. The daily average number of patients that enter the clinic is very significant and the combination of residents and specialists change in different days of the week. However, patients can still expect to go through a standard treatment process, fully executed by the doctors and assistants. A key secret weapon is a simple, concise, image-based patient record. You can clearly identify a patient's background, extra-oral, intra-shots, chief complaints, source of referral, treatment plans, all in a piece of A4 size paper. All doctors can easily pick up a patient record and immediately follow the instructions left from the previous visit. Most of all, an ideal treatment outcome can still be obtained despite the changes in doctors. An effective and efficient system should be able to be replicated by different operators, in different location. The aim of the system in Beethoven is to create such a model so doctors can make treatment more easy and predictable.



Dr. Park and the Korean delegates, together with the Beethoven Orthodontic Group's staff.

BEETHOVEN

Continuing Education



Indonesian doctors practicing screw placement on a model.

One may wonder how doctors can continue to update their knowledge and skills in today's busy world. The answer for Beethoven's doctors is the standardized training process. All residents in Beethoven have to complete Beethoven's Comprehensive Damon Q course, the Advanced Damon Course and continue their pursuit of excellence in the Finishing course. Dr. Chang's teaching style is very interactive and engaging, filled with fresh cases. Students constantly find cases they just saw last week or yesterday at the clinic, demonstrated and analyzed in the class next day.

International Course

Beethoven's courses are not only designed for the local doctors; many doctors from overseas also attend the customized international workshop. The response from the participants were so overwhelmingly positive that several of them repeated the class. Besides providing international courses, Dr. Chang is frequently invited to give lectures around the world and bringing the most up-to-date news and internationally renowned speakers back to Taiwan's audience.

International Journal of Orthodontics & Implantology

After over a decade of service to the people in Hsinchu, Dr. Chang has won the trust and support of his patients. In addition to providing orthodontic treatment, Dr. Chang dedicates most of his energy to providing continuing education and devoting himself to academic exchange locally and internationally. In order to provide a platform for dentists to share their clinical experiences, Dr. Chang also publishes a quarterly journal, News & Trends

in Orthodontics, now renamed as International Journal of Orthodontics & Implantology. Famous doctors in Taiwan and abroad frequently share their clinical secrets or summaries of recent lectures in the journal. We hope through this channel we can spread the messages of knowledge sharing and pursuit of excellence to our readers.

The Beethoven Team

The Beethoven team is not only consisted of Dr. Chang himself. We have a team of doctors specializing in pedodontics, prosthetics, periodontics as well as implant therapy. So we can take care of patients from 1 year old to 99 years old. In addition to specialized care, we also have a general practice taking care of patients common dental issues. Through this comprehensive approach, we can provide total care to our patients.

Needless to say, dental assistants play an indispensable role in Beethoven's operating system. When every new patient enters the clinic, he or she will immediately be greeted by a professional assistant whose main function is to provide orthodontic consultation. The assistant will walk you through the consultation process, explain the data she will collect in this visit, including photos and X-rays, and the fees and stages of the treatment process. In terms of controlling the flow of patients during a clinic session, a senior assistant acts as the conductor in the clinic, assigning assistants to each chair and notifying doctors the order of patient sequence. Assistants are the crucial link between doctors and patients. If you think your assistants haven't met your expectations, you can consider signing up for Beethoven's assistant training for them.



The Beethoven team

Andersen Pedodontic Center

Guarding children's dental health

Andersen Pedodontic Center-Introduction

After serving the local community for over a decade, the local community leader approached Dr. Chang to express the community's needs for a doctor who understands children's dental health. At the time when children had toothache, parents have to travel to the crowded city center for treatment. In response to such wishes from his own community, and the repeated requests from parents of his orthodontic patients, he and Dr. Hsu together established "Andersen Pedodontic Center". "Our mission is to create an environment where parents can feel safe, children can experience joy and doctors can provide the best possible care to children", Dr. Hsu said.



Flower-decorated ceiling is what children see during treatment.

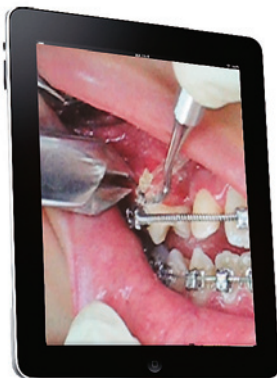Newton's A

Dental education center

The constant dilemma for successful dentists is the conflict between time and need for continuing education. It's almost a luxury to devote one's full attention to a full-day lecture or a new book. Newton's A understands doctors' needs for a more flexible and effective method of learning and has turned Beethoven's excellent teaching materials to videos. Combined with a mobile device, such as iPad or iPod touch, one can learn orthodontics anytime and anywhere. This latest utilization of technology has revolutionized the orthodontic world.

Newton's A-Mobile Learning: Orthodontic Podcast Encyclopedia + iPad

Dr. Chang is the first dentist to combine the three seemingly distinctive but closely related courses, Damon orthodontics, orthodontic bone screws and assistant training into easy viewing educational presentation videos. Using Mac's native presentation software, Keynote, he can instantly record live narration with his slides and turn his lecture into an engaging movie. Students can use these videos as electronic notes, carry them in their iPod or iPad



wherever they are and review the content whenever they want. Whether you are past, current or prospective students of Beethoven, you can use these videos for course preview or review to enhance the learning experience. Since the content is digitalized and frequently updated, students won't have to worry about being outdated once they purchase the course videos.

Newton's A-Effective teaching tools: Mac + Keynote

In addition to produce professional dental educational podcast, Newton's A is also in charge of the design, execution and maintenance of Beethoven's technical environment. For example, recently the chairman of the premier teaching hospitals in Taiwan came to visit Beethoven with his son-in-law from the US. During the visit Dr. Chang performed an out-patient surgery. Some trained assistants provided clinical assistance to Dr. Chang while others took photos and videorecorded the procedures in small segments. Immediately after the surgery, assistants uploaded the patients' photos and videos and organized them in Beethoven's standardized patient record template, utilizing Mac's presentation software, Keynote. So Dr. Chang then used data from the previous visits as well as the procedures that just took place a moment ago to demonstrate to the patient the treatment progress and surgery process instantly. Followed by the presentation to the patient, Dr. Chang used the same file to continue a further in-depth discussion with the chairman.

BEETHOVEN

Andersen Pedodontic Center-Environment

The clinic is named after the famous children's book author, Hans Andersen. The image design of the clinic is inspired by Andersen's most famous fairy tales, the emperor's new clothes, the little match girl and thumbelina. Dr. Hsu hopes visiting the clinic can bring children not just the thought of stinky smell or feary drills but also beautiful stories. Besides the pleasant visual stimulants, the brushing station is designed at three levels to fit the varying heights of children of different development stages.

Andersen-Long-term dental growth data preservation

Andersen sees itself as the long-term guardian of children's dental health. In order to closely monitor patients' growth, we

routinely take intra-oral, extra-oral photos and X-rays to make sure we won't miss the first sign of an emerging problem at a later stage. To achieve this goal, we use high quality digital cameras and wireless memory cards to ensure fast and secure data transmission. Mac's dual operating system allows us to take advantage of both windows and Mac's functions.

Andersen-Children's health education

Prevention is better than cure. This is particularly true for parents battling with young children's cavity. In view of this common challenge for parents, Andersen regularly collaborates with local kindergartens to administer supplemental fluoride. Parents can also play a strong advocate for children's dental health by helping children develop proper concepts and practices of dental hygiene.



A case report as described may take several interns a week to complete in other institutions. With the aid of proper technology, one can finish such tasks in less than 30 minutes.

This wonderful combination of Mac and Keynote makes preparing case reports, producing educational materials or presenting treatment progress to doctors, assistants, patients or parents so easy and effective. The built-in recording function allows presenters to record voiceover as the slides advance so the audience can better appreciate the content.

Newton's A- OrthoBoneScrew

Originated from Beethoven's clinical experiences, Dr. Chang is leading a team of experts from academia and engineering to develop an orthodontic mini anchorage device, OrthoBoneScrew. The research and development team include experts from University of Indiana-Purdue's professor of Emeritus, Dr. Eugene Roberts, Dr. John Lin and Dr. Lin Shan Jie from National Central University in Taiwan. Our products have improved over the last two years and received positive feedback from orthodontists in Taiwan and abroad. The combined use of bone screw and Damon can significantly reduce extraction rates in borderline surgical cases. Cases that traditionally require surgery can achieve satisfactory results with the use of orthodontic bone screws.

Implant Center

Ortho-Implant combined treatment

In recent years Beethoven have seen a growing number of adult patients seeking treatment for missing teeth. This indicates a stronger need for esthetic appearance for adult patients. However, this brings a new set of challenges for orthodontists because the problems are far more complex than creating ideal alignment. Patients often have periodontal problems, multiple missing teeth and the reconstruction of prosthetics or implant placement. Hence, Beethoven believes providing adult patients a comprehensive treatment is our new goal.

Traditionally adult dental treatment can be summarized in two words, periodontics and prosthetics. However, in the era of inter-disciplinary treatment, orthodontics and implantology have become the new two pillars in this treatment structure. Orthodontics can lay a solid foundation to support future implant placement. Therefore, the establishment of the new implant center is to provide a more comprehensive care to our patients in our dental network.

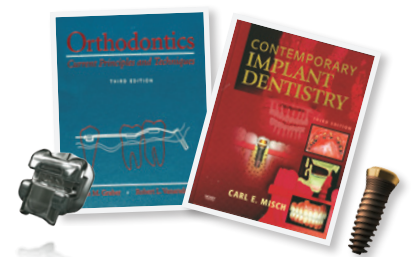
In October, 2011 Newton Implant Center is established to fulfill such needs that were not adequately met previous in the Beethoven. Dental Group. The new Center marks Beethoven's milestone in providing interdisciplinary treatment. Equipped with the latest 3D technology, Newton now has the capacity to provide diagnostic information on impaction for orthodontic treatment, and bone quality assessment for implant therapy. In addition, Newton also applies the latest cloud technology to manage clinical data as well as provide patient consultation and staff continuing education.

BEETHOVEN



"None of these can be possible without my two great mentors", said Dr. Chris Chang. He contributed this recent shift of focus to the inspirations by Dr. Homayoun Zadeh from USC and Dr. Kwang Bum Park from UCLA. Dr. Homa is a strong advocate and dedicated educator on promoting evidence-based implant therapy. Since 2010 Beethoven and USC has collaborated to annually provide a six-month international certificate course to doctors in Taiwan. Armed with solid knowledge foundation, Dr. Park, faculty of UCLA, CEO of Megagene, one of the fastest growing implant cooperation and MIA, one of the largest dental hospitals in Korea, inspired Dr. Chang with his business management wisdom. After two years of immersing himself in the learning of implantology from an orthodontic perspective, Dr. Chang and many of the experts in these two fields, all agree that implant-ortho combined treatment is the future of dentistry. In order to promote the study and practice of implant-ortho combined treatment, Dr. Chang, together with world leaders in orthodontics and implantology, such as Drs. Eugene Roberts, John Lin (林錦榮醫師), Fernando Vizcaya, established International Association of Orthodontists & Implantologists(iAOI) in October, 2011. Beethoven's previous orthodontic journal, News and Trends in Orthodontics(NTO), is now changed to International Journal of Orthodontics & Implantology(iJOI). As member of iAOI, one can view the latest lectures of iAOI's consultants or read all 24 issues of its publications from the comfort of their home or when they are on the go. Learning can never be easier.

"All we doctors do is aimed to provide the best possible care to our patients", Dr. Chang stresses. Based on this philosophy, the core value of the Beethoven Dental Group is education. As medical technology and innovation evolve, doctors need to constantly renew their knowledge and skills through continuing education. We hope doctors sharing the same commitment to quality patient care and passion for learning can join iAOI, the future of dentistry!



e 化示範病例衛教



e-Consultation

矯正 Orthodontic

1. 初診流程
2. 簡易矯正案例
3. 進階矯正
4. Morph 矯正案例
5. 矯正衛教
6. 矯正利器
7. 診間 iPad 運用

Orthodontics

1. Initial consultation
2. Common demo cases
3. Advanced demo cases
4. Morphing cases
5. Orthodontic health education
6. Orthodontic appliance application



植牙 Implant

1. 初診流程
2. 植牙評估流程
3. 植牙案例類型介紹
4. 植牙相關療程介紹
5. 微創手術 VISTA

Implantology

1. Initial consultation
2. Clinical evaluation
3. Common demo cases
4. Introduction of Implant services
5. Minimally invasive surgery : VISTA




兒牙 Pedo

1. 初診流程
2. 治療流程
3. 特殊裝置
4. 潔牙衛教
5. 兒牙常見問題

Pedodontics

1. Initial consultation
2. Treatment process
3. Special appliances
4. Dental hygiene
5. Common Q & A





International **A**ssociation for **O**rthodontists & **I**mplantologists

For more information on benefits and requirements of iAOI members, please visit our official website: <http://iaoi.pro>.

Join the *iAOI*, the future of dentistry!

How to join iAOI?

Certified members of the Association are expected to complete the following three stages of requirements.

1. Member

Doctors can go to <http://iaoi.pro> to apply for membership to join iAOI. Registered members will have the right to purchase a workbook in preparation for the entry exam.

2. Board eligible

All registered members can take the entry exam. Members will have an exclusive right to purchase a copy of iAOI workbook containing preparation materials for the certification exam. The examinees are expected to answer 100 randomly selected questions out of the 400 ones from the iAOI workbook. Those who score 70 points or above can become board eligible.

The exam is one hour and the next session will be held on December 9 in the headquarter of Taiwan Academy of Banking and Finance, Taipei, Taiwan.

3. Diplomate

Board eligible members are required to present three written case reports, one of which has to be deliberated verbally. Members successfully passing both written and verbal examination will then be certified as Diplomate of iAOI.

Ambassador

Diplomates will have the opportunity to be invited to present six ortho-implant combined cases in the iAOI annual meeting. Afterwards, they become Ambassador of iAOI and will be awarded with a special golden plaque as the highest level of recognition in appreciation for their special contribution.

2012

iAOI 年度大會

矯正與植牙的合奏

A Symphony of Orthodontics and Implantology

議程表

 Dr. Thomas Han 美國UCLA 牙周病研究所教授	08:00	iAOI Exam
	09:10	Registration
	09:30	Topic: Anterior Aesthetic Nightmare - Why do they occur? How to Avoid them?
 Dr. Kwang Bum Park 韓國連鎖MIR 牙科醫院聯盟負責人	10:20	Break
	10:40	Topic: Hard Tissue Defect - How to solve it? Is the result ideal?
	11:30	Diplomate Oral Presentation 1 & 2
 張慧男 醫師 新竹貝多芬 齒顎矯正中心負責人	12:10	Lunch
	13:00	Topic: Implant-Ortho combined treatment-I
	13:50	Diplomate Oral Presentation 3 & 4
 林錦榮 醫師 台北林錦榮 齒列矯正中心負責人	14:30	Break
	15:00	Diplomate Oral Presentation 5 & 6
	15:40	Topic: Implant-Ortho combined treatment-II
	16:30	Closing comments and Certificate ceremony

報名費

8月底前

會員
NTD **1,499**
非會員
NTD 3,999

10月底前

會員
NTD **1,999**
非會員
NTD 4,999

11月之後

會員
NTD 2,500
非會員
NTD 6,000

iAOI第一階段Board Eligible資格考

- 時間：12/09 (日) 08:00 ~ 09:10
- 地點：台灣金融研訓院 2F (台北市羅斯福路三段62號)
- 報名方式：網路報名，網址為 <http://iaoi.pro/>
- 報名費用：新台幣 **2000** 元
- iAOI 網站上提供 **題庫** 免費下載，請醫師提早準備！

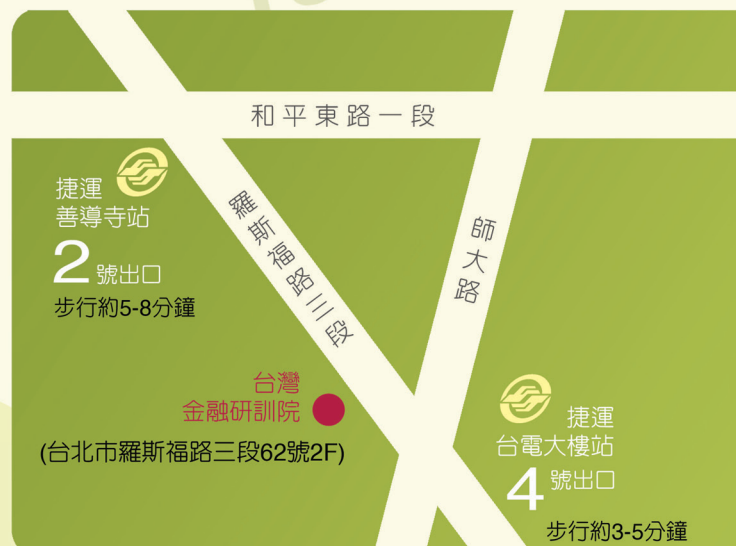考試注意事項：

- 應試者請於 08:20 之前報到完畢。
- **建議使用iPad應試**，無iPad可以筆電代替。
(試題瀏覽與作答形式，係針對iPad而設計)
- 現場無充電設備，請醫師務必確認考試設備電力充足。

服務專線 (03) 573-5676

網路報名 <http://iaoi.pro/>

「會員」為已註冊並繳交2012年費之醫師，
(尚未註冊者請至 <http://iaoi.pro/> 註冊)
其餘皆適用「非會員」價。





Anytime

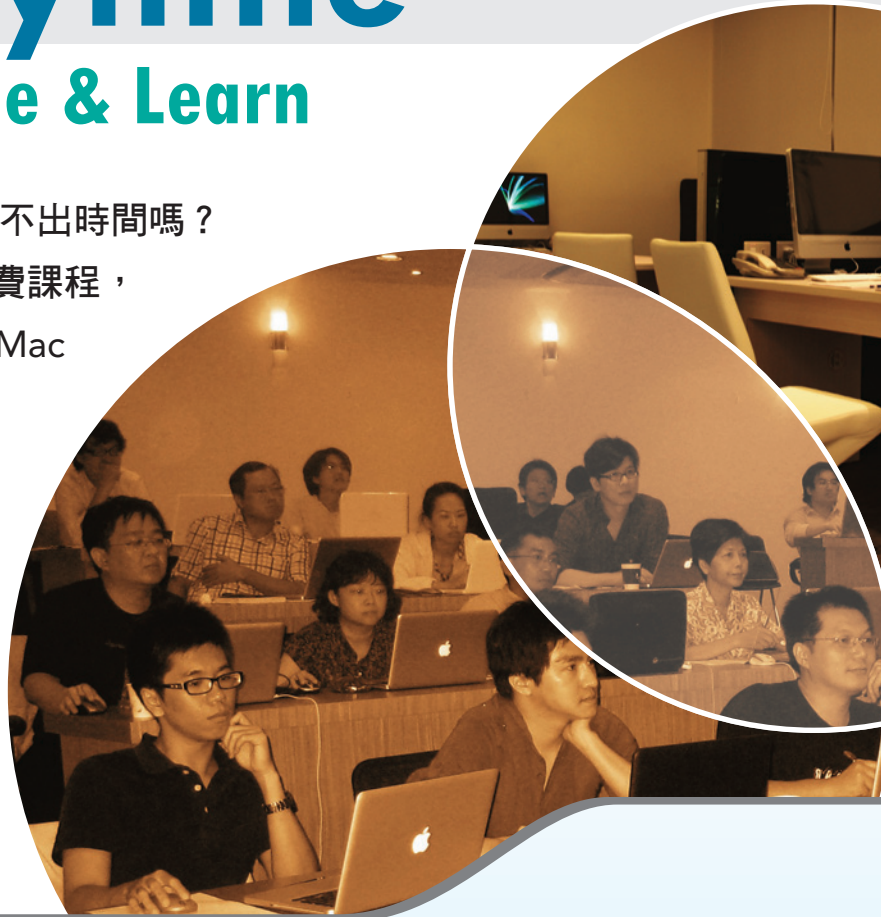Come & Learn

想上 Mac 的課程可是週末總是抽不出時間嗎？
來金牛頓預約最新的免費課程，
讓您 learn Mac

anytime you want!

課程預約專線
03-573-5676

詳細辦法請上
<http://www.newtonsa.com.tw>



Newton's A Summer 12' course schedule

類型	課程名稱	內容	開課日期	上課對象
專業簡報	Keynote 簡報法 series 1 簡報聖經	1. 常見簡報謬誤 2. Keynote 入門	2012/8/16 (四) 09:00 ~ 17:00	科技人、醫師 教師、學生
專業簡報	Keynote 簡報法 series 2 Kokich 的 10 大演講秘訣	1. 多媒體影像處理 2. 簡報設計	2012/9/20 (四) 09:00 ~ 17:00	科技人、醫師 教師、學生
專業簡報	Keynote 簡報法 series 3 How to Wow'em like Steve Jobs?	1. 賈伯斯演講秘訣 2. 簡報設計進階應用	2012/10/18 (四) 09:00 ~ 17:00	科技人、醫師 教師、學生
專業簡報	Keynote 簡報法 4-6 繪圖精修課程	1. How to use a digital drawing board. 2. Design illustration in your Keynote. 3. Showcase your own drawing with stunning animation in Keynote. 4. Create complicated diagrams using Adobe Illustrator and Photoshop. 5. Animation Competition	2012/11/17-19 (四) 09:00 ~ 17:00	科技人、醫師 教師、學生
International	Damon and OBS workshop	1. Damon System 2. OrthoBoneScrew	2012/6/12-14 11/13-15	International Orthodontist

For comfort & retention of elastic chain
磨菇頭部外型

For lever arm to solve impacted tooth
方形角線釘孔

For ease of hygiene control & extra attachment
雙頸部設計



Ortho Bone Screw

矯正專家強烈推薦

Order: +886-3-573-5676 Ms.OBS

For more information, visit <http://orthobonescrew.com>

"From this book we can gain a detailed understanding of how to utilize this ABO system for case review and these challenging clinical cases from start to finish."

Dr. John Jin-Jong Lin, Taipei, Taiwan

"I'm very excited about it. I hope I can contribute to this e-book in some way."

Dr. Tom Pitts, Reno, Nevada, USA

"A great idea! The future of textbooks will go this way."

Dr. Javier Prieto, Segovia, Spain

No other book has orthodontic information with the latest techniques in treatment that can be seen in 3D format using iBooks Author. It's by far the best ever.

Dr. Don Drake, South Dakota, USA

"Chris Chang's genius and inspiration challenges all of us in the profession to strive for excellence, as we see him routinely achieve the impossible."

Dr. Ron Bellohusen, New York, USA

This method of learning is a quantum leap forward. My students at Oklahoma University will benefit greatly from Chris Chang's genius.

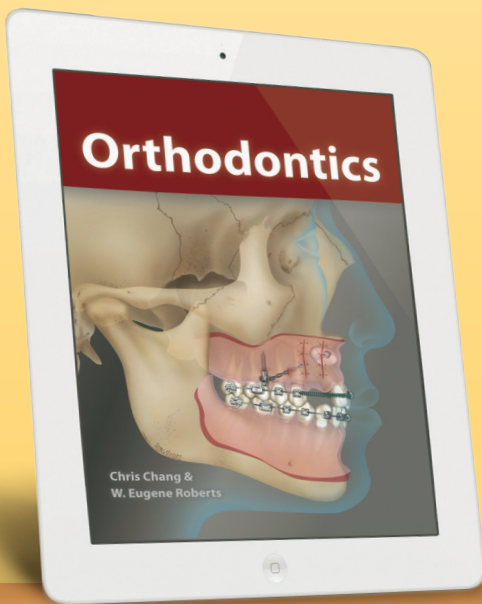
Dr. Mike Steffens, Oklahoma, USA

"Dr. Chris Chang's innovation eBook is at the cutting edge of Orthodontic Technology... very exciting!"

Dr. Doraida Abramowitz, Florida, USA

"Dr. Chris Chang's first interactive digital textbook is ground breaking and truly brilliant!"

Dr. John Freeman, California, USA



"Tremendous educational innovation by a great orthodontist, teacher and friend."

Dr. Keyes Townsend Jr, Colorado, USA

"I am awed by your brilliance in simplifying a complex problem."

Dr. Jerry Watanabe, California, USA

"Just brilliant, amazing! Thank you for the contribution."

Dr. Errol Yim, Hawaii, USA

"Beyond incredible! A more effective way of learning."

Dr. James Morrish Jr, Florida, USA



2012 Beethoven Excellent Finishing course with a special guest, Dr. Rungsi Thavarungkul from Thailand (central in orange shirt).

ISSN 2079-6862

