

**The Wisdom of Managing Wisdom Teeth
Part III: Methods of Molar Uprighting**

Dr. John Lin

**Highly Positioned and Transalveolar
Impacted Maxillary Canine**

Drs. Billy Su, Chris Chang & W. Eugene Roberts

**A Severe Skeletal Class III Open Bite
Malocclusion Treated with Non-surgical Approach**

Drs. Sabrina Huang, Chris Chang & W. Eugene Roberts

IJOI

International Journal of
Orthodontics & Implantology

Vol. 24 Oct. 1, 2011



Drs. John Lin, Kwang Bum Park (front row) with Chris Chang and Mark Ou (back row) in front of a collection of antique orthodontic rare books in the study room of Dr. Chang's. On the desk lay Angle's busts made of bronze and colored glaze.

International Journal of Orthodontics and Implantology is an experience sharing magazine for worldwide orthodontists and Implantologists. Download it at <http://iaoi.pro>

2011~2012

熱愛學矯正

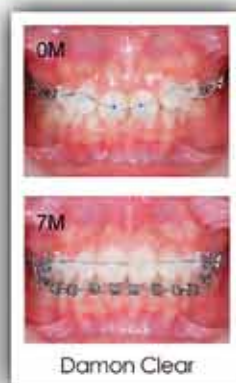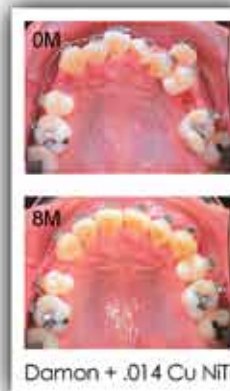張慧男 博士



新竹貝多芬齒顎矯正中心負責人
中華民國齒顎矯正專科醫師
美國齒顎矯正專科醫師學院院士 (ABO)
美國印地安那普渡大學齒顎矯正研究所博士

學會開始做矯正需多久?

39小時讓您入門矯正。本課程採高效學習法及高效矯正簡報法·Keynote·在舒適、輕鬆的環境下，學會簡單有效的矯正方法，教室與診間結合，讓您現學現用，立即熟悉各種習得的技巧，而不需太多課後複習。全程以 In-Office Training 方式，用病例帶動分析、診斷，治療計畫與療程技巧，每一步驟皆以圖片及影片教學，讓您很難錯過任何環節，更沒有聽不清楚或無法理解的可能。為提高課後自我學習及臨床印證之效率，另備有教學電子檔，供學員家中研習。我們的終極目標是：用最短時間、最輕鬆的方式，讓每位學員 - 熱愛矯正學、熱愛學矯正。



Damon矯正課程

【課程】9:00 - 12:00
【實習】另外安排

使用最新一代矯正器 Damon Q 進行課程，
歡迎舊生報名參加。

台北 (二)	台中 (四)	LECTURE	LAB
1 10/4	9/29	理想入門病例 + Damon Q 黏著	Bonding (Damon Q) + BT
2 10/11	10/6	快速矯正療程四部曲	Ceph + Photo
3 11/1	10/20	簡捷有效的錨定系統	Damon + OrthoBoneScrew I
4 11/22	10/27	不拔牙與拔牙分析	Damon + OrthoBoneScrew II
5 12/13	11/24	Damon 診斷流程及微調	Finish Bending
6 1/3/12	12/1	完工檢測及報告示範	Fixed Retainer (FR)
7 1/17	12/15	維持及復發：病例示範	Presentation Demo
8 2/7	12/29	矯正力學及診斷分析 (1)	DDX + Case Reports I
9 2/14	1/5/12	軟硬組織及診斷分析 (2)	DDX + Case Reports II
10 3/20	2/9	兒童矯正及診斷分析 (3)	DDX + Case Reports III
11 3/27	3/1	成人矯正及診斷分析 (4)	DDX + Case Reports IV

矯正植體課程

【課程】9:00 - 12:00
【實習】13:30 - 20:00

矯正植體的操作時機、
植法與實習、個案討論、
臨床跟診及實作示範。

新竹(五) 9/21 (含午、晚餐)

International workshop

Keynote & management
OrthoBoneScrew & Damon

A班 6/12-14

B班 11/13-15

矯正進階課程

【課程】9:00 - 12:00

以病例討論為主軸，培養學員如何正確診斷及快速排除臨床疑點。課程中亦訓練每位學員善用 Keynote。

新竹 (二)	Paper Reviews	Topics & Case Demo
1 9/27	Bracket Placement	Crowding: Ext. vs. Non-ext.
2 10/25	Impacted Canines	Upper Impacted Teeth
3 11/15	Canine Substitution	Lower Impacted Teeth
4 12/6	Missing 2nd Premolar	Missing: Ant. vs. Post.
5 12/27	DI Workshop	Crossbite: Ant. vs. Post.
6 1/10/12	CRE Workshop	Open Bite High Angle
7 4/3	Excellence in Finishing (occlusion)	Deep Bite Low Angle
8 4/10	Excellence in Finishing (esthetics & perio)	Gummy Smile & Canting
9 4/17	Ortho-Perio-Restore Connection	Esthetic Finishing (Transposition)
10 5/8	Adjunct to Perio	Implant-Ortho
11 5/15	Unhappy Patient	IDT - Adult Complex

助理訓練課程

【課程】10:00 - 14:30
【實習】15:00 - 20:00

每梯次共兩堂課程與技術操作，內含
照相技術、Morph 與公關衛教之電腦
資料處理；另安排一次診所見習。

新竹(五) 10/5、12 (含午、晚餐)

課程資訊

上課地點

【台北】
恒毅資訊中心 畢卡索廳
/ 台北市復興北路99號12F
(捷運南京東路站旁)

【新竹】
金牛頓藝術科技公司
/ 新竹市建中一路25號2F

【台中】
中國文化大學台中教育中心
/ 台中市西屯區中港路二段
128之2號3樓

報名專線

湧傑 Yong Chieh

北區
[02] 27788315 楊文君 / 邵美珍

中區
[04] 23058915 張馨云

南區
[07] 5361701 王慧靜

*每次上課請依最新一期IJOI
公告為主

矯正精修課程

【課程】9:00 - 12:00

協助每位學員了解由古典到現代之文獻，進而應用於實際
病例；並藉由DI及CRE讓精修完工 (Excellent Finishing) 變成
易達到的目標。

新竹(二) 精修III 4/19 5/17 6/14 7/12 8/16 9/20 10/18 11/29
12/20 (1、2月休) 3/13/12 4/24

iAOI-together we invent the future.

This month I had a great opportunity to speak at the 2nd Burstone International Biomechanics Symposium in my alma mater, Indiana University. I was invited to speak about the application of TADs on impaction. To my surprise, the audience with primarily orthodontic background responded with the most interests to my combined treatment of VISTA and TADs to solve those tough impacted cuspids. Immediately after my lecture in Indiana, I spoke in the 8th International MegaGen Symposium in Milan to a room full of clinicians in implant therapy, I was able to catch their eye with my lateral window surgery technique, combined with TADs, to treat complex impaction cases.

None of these problems could be solved previously with easy and logical methods, if considering only orthodontic or implant's perspective. However, as we step outside of our traditional boundary of specialties, we are able to generate more innovative and simple treatment options for patients. The positive feedback I received in these two recent lectures reinforces my conviction that the future of dentistry lies in ortho- and implant-combined treatment.

If you have not been a part of the International Association of Orthodontists and Implantologists (iAOI), now is the best time to join. For those who are, I encourage you to challenge yourself to the next level, taking the online entry examination. To better reflect the international nature of this organization, I have invited my mentor in implant dentistry, Dr. Park, to bring his colleagues in Korea, and my young colleagues in Taiwan, to do a full-day case report demonstration on December 18, in Taipei, Taiwan. I strongly believe a well thought of case presentation is the most effective way to reflect and enhance one's treatment quality. I invite you all to come learn about the preparation of this required presentation for iAOI's next level of certification. Let's join to invent the future of dentistry.

Chris HN Chang, DDS, PhD, Publisher

03 Editorial

LIVE FROM THE MASTER

04 The Wisdom of Managing Wisdom Teeth

iAOI CASE REPORT

14 Highly Transalveolar Impacted Maxillary Canine

28 A Severe Skeletal Class III Open Bite Malocclusion

40 Open-Window Technique for Upper Palatal Impaction

FEATURE

46 Utility of Angled Implant for Immediate Replacement

50 Soft Tissue Considerations for the Management of Impactions

60 OthoBoneScrew

68 Cloud Information for Dentistry

INTERDISCIPLINARY TREATMENT

74 Avoiding & Managing Complications Associated with Implant Therapy Part 1

FEEDBACK FROM THE WORLD

86 Feedback from Beethoven's Events



Examiner
Dr. W. Eugene
Roberts



Examiner
Dr. Tom Pitts



Examiner
Dr. John J. J. Lin



Consultant
Dr. Frederick J.
Reggenitter



Consultant
Dr. Tucker Haltom



Consultant
Dr. J. Michael
Steffen



Consultant
Dr. Larry White



Examiner
Dr. Kwang Bum Park



Examiner
Dr. Homa Zadeh



Examiner
Dr. Fernando
Rojas-Vizcaya



Consultant
Dr. Baldwin W.
Marchack



Consultant
Dr. Stephen
Wallace



Consultant
Dr. Mark Y. K. Ou



Guest Editor
Dr. Rungsi
Thavarungkul



Editors (from left to right) :

Yu Lin Hsu, Associate Editor
Tzu Han Huang, Associate Editor
Billy Su, Chief Editor
Sabrina Huang, Associate Editor
Steven Lee, Associate Editor
Dennis Hsiao, Associate Editor
Chester Yu, Chief Editor
Grace Chiu, Associate Editor



Contributors (left to right) :

Dr. Hong Po Chang, Consultant
Dr. Ming Guey Tseng, Consultant
Dr. John Lin, Consultant
Dr. Frank Chang, Consultant
Dr. Johnny Liao, Consultant
Dr. Chris Chang, Publisher

The Wisdom of Managing Wisdom Teeth

Part III. Methods of Molar Uprighting

(A) Introduction

There are many ways of uprighting impacted molars. Many techniques of molar uprighting have been described in literature¹⁻³. Several of them involve removable appliances which require patient cooperation⁴, and/or surgical exposure of the impacted molar, or removing part of the alveolar bone⁵. Through the advancement of wire materials and TADs (*temporary anchorage devices*), the method of molar uprighting has been greatly simplified.

In this article the author summarizes six methods of molar uprighting with detailed diagrams by Dr. Rungsi. The author hopes this article can serve a good clinical reference when selecting an appropriate method for solving difficult impactions.

(B) Methods of Molar Uprighting

(1) Yao-Qiang Miao's method⁶

A-1. A mini-hook is fabricated from a .014" stainless steel wire. Bend the wire into a circle with a diameter of 1.5mm extending in a perpendicular arm 1.5mm in length. At the top of the soldering push-spring arm, bend a hook parallel to the circle. Bond the mini hook at the disto-occlusal side of the impacted molar, with the hook opening mesially.

A-2. Solder an .018" stainless steel wire about 60mm in length, to the middle of the lingual surface of the mesially adjacent molar band. Fabricate a double or triple bend push spring.

B. Activation: Compressing the double or triple loop spring to engage the mini-hook.

C. During treatment: The impacted molar can be uprighted distally.

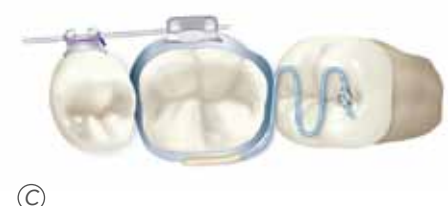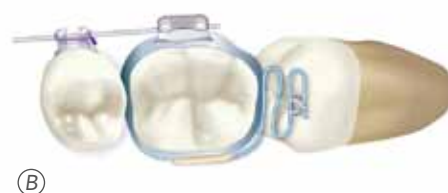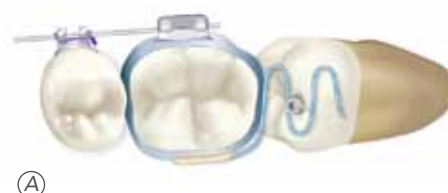Advantages

This procedure is only appropriate when only the disto-buccal part of the molar is impacted applied.

Disadvantages

- (1) Need to construct a push spring and mini-hook.
- (2) Need to band the adjacent molars and cement it.

Miao's Method



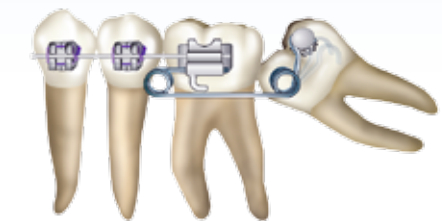
Dr. John Jin-Jong Lin
MS, Marquette University
Chief Consultant of IJOI
President of TAO (2000~2002)
Author of Creative Orthodontics



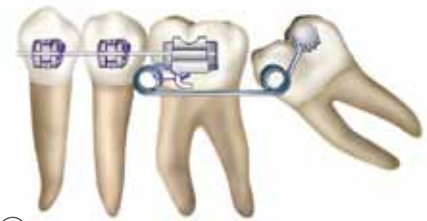(2) Shou-Hsin Kuang's method

- A-1. Bond a lingual button over the disto-buccal of the impacted molar.
- A-2. It needs an additional auxiliary .018" x .025" gingival tube on the adjacent molar.
- A-3. Use a .017" x .025" TMA wire to bend double helix one at the mesial side of the adjacent molar, one at the distal side, and engage the distal hook over the lingual button.
- B. Tie the mesial helix with the hook of the adjacent molar to activate the distal pushing and uprighting force.
- C. The impacted molar was not only pushed distally but also uprighted by the pushing spring.
- D-1. Put lingual buttons over the disto-buccal side of the impacted lower 2nd molars.
- D-2. AIPS stands for Anterior Inserting Pushing Spring. The .017" x .025" TMA AIPS was engaged on the gingival tube of the lower 1st molar, and were activated by tying the ligature wire.
- D-3. After about 6 months in treatment, the impacted 2nd molars were uprighted with AIPS.

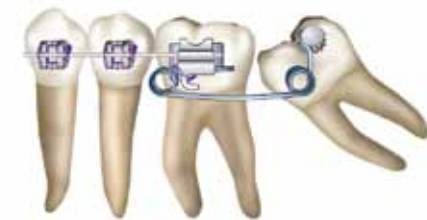
Kuang's Method



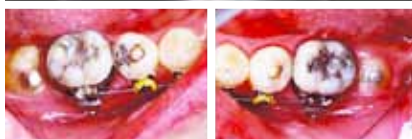
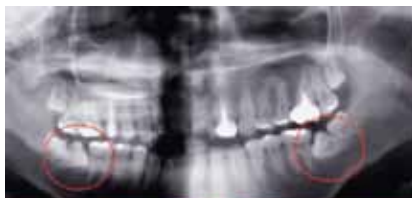
(A)



(B)



(C)



Courtesy of Dr. Shou-Hsin Kuang

(D1)

Molar uprighting with AIPS

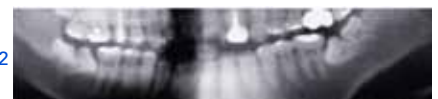Anterior Insertion Pushing Spring



Courtesy of Dr. Shou-Hsin Kuang

(D2)

90.02



90.05



90.09



90.11



Courtesy of Dr. Shou-Hsin Kuang

(D3)

E-1. The pushing springs were engaged in the gingival tube of the lower 1st molar and activated by tying the ligature wire.

E-2. The occlusal view of the AIPS has been engaged and activated.

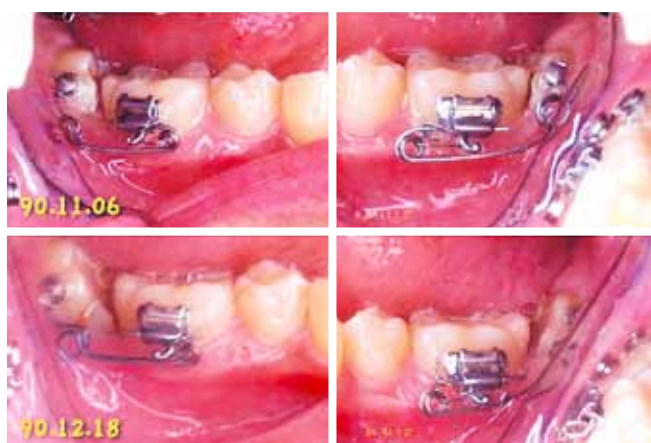
E-3. About 5 months in treatment, the impacted 2nd molars were uprighted, despite the presence of the impacted 3rd molars.

Advantages

- (1) The technique is suitable only when a very small disto-occlusal part of the impacted molar partially erupted.
- (2) The double helix push spring applies a very gentle force on the .017" x .025" TMA wire.

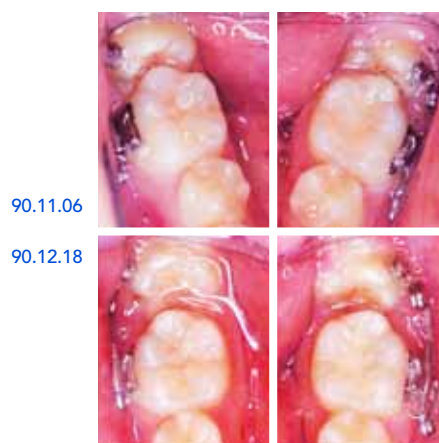Disadvantages

- (1) It is time consuming to bend a double helix push-spring.
- (2) Sometimes the helix will impinge on the soft tissue around the narrow vestibular space buccal to the impacted molar.
- (3) It may catch food debris easily, hygiene instruction is needed.



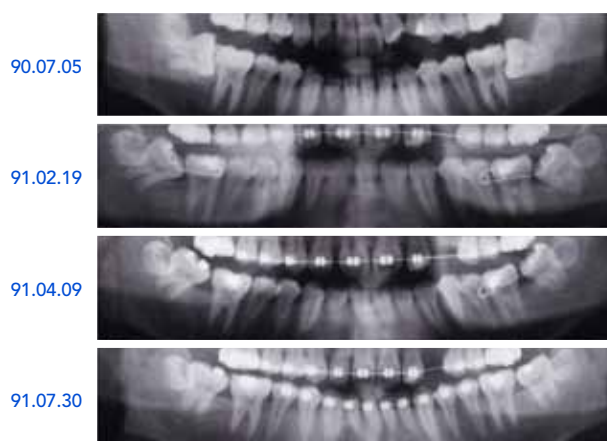
Courtesy of Dr. Shou-Hsin Kuang

(E-1)



Courtesy of Dr. Shou-Hsin Kuang

(E2)



Courtesy of Dr. Shou-Hsin Kuang

(E-3)

(3) Yu-Cheng Liaw's method

A. Construction of a push NiTi wire

- (1) Attach an additional auxiliary .018" x .025" gingival tube over adjacent molar.
- (2) Bond a lingual button over the disto-buccal of the impacted molar.
- (3) Use of a section of .016" x .022" nickel titanium wire, gripping a stop over the distal of the auxiliary tube, and bend a loop over distal end about 5mm distal to the lingual button with the hammerhead plier.

B. Activation: Engaging the push NiTi wire to the lingual button.

C. After treatment the impacted molar uprighted.

D. On the typodont

- (1) The hammerhead plier (Hu-Friedy NiTi tie-back bender plier), .016" x .022" NiTi wire and stopper.
- (2) Put on the stopper and bend a loop on the .016" x .022" NiTi wire with the hammerhead plier.
- (3) Measure the force, about 150~200gm.
- (4) The pushing NiTi wire engaged on the typodont.

E. (A) The NiTi push spring is engaged.

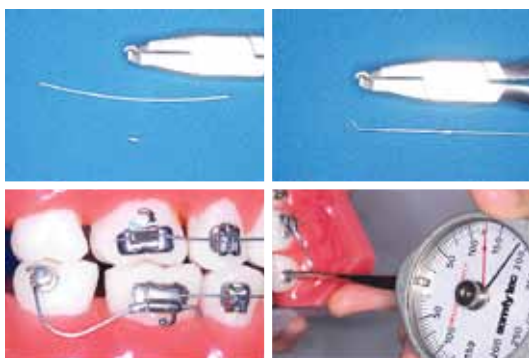
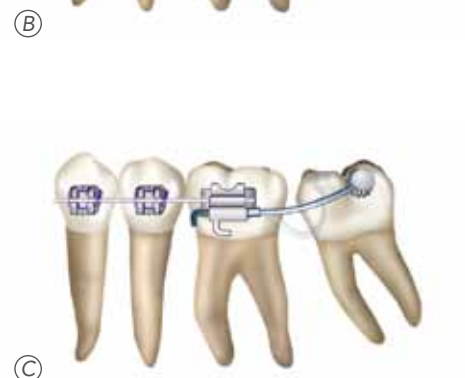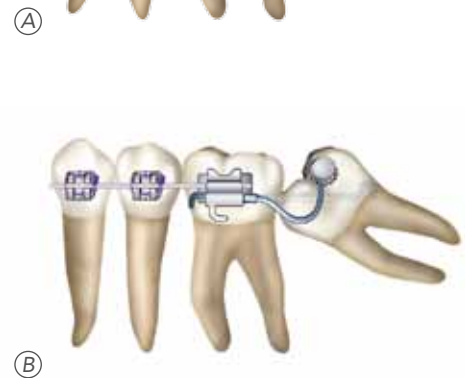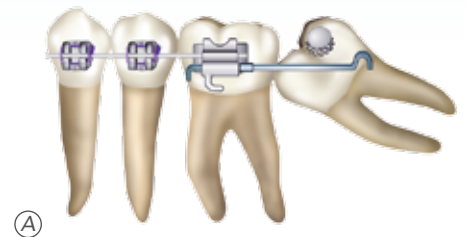
- (B) After 4 months, the impacted 2nd molar was uprighted.

Advantages

- (1) This method is a modification after Kuang's method. Instead of using a .017" X .025" TMA wire with double helix, a straight .016" x .022" NiTi wire is used.
- (2) There is less wire bending involved.
- (3) Only a small part of the disto-occlusal of the impacted molar required to be exposed.

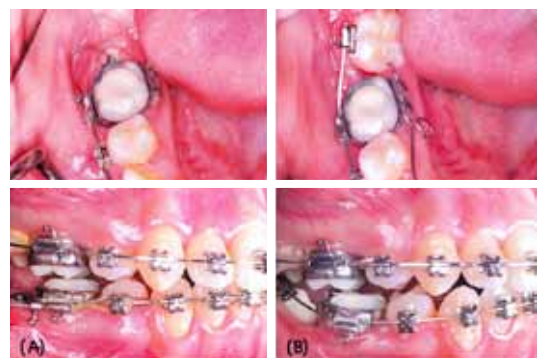Disadvantages

It needs an additional auxiliary tube over the adjacent molar.



Courtesy of Dr. Yu-Cheng Liaw

(D)



Courtesy of Dr. Yu-Cheng Liaw

(E)

(4) Richard Bach's method

- A. Insert a .014" x .025" CuNiTi wire between the mesial side of the impacted molar and the distal side of the adjacent molar.
- B. Bend the wire to the occlusal surface of the adjacent molar and secure the wire over occlusal surface with light cured composite.
- C. About 17 weeks later, the impacted molar can be uprighted.

Advantages

- (1) There is no need to wait for enough exposure of the disto-buccal side of the impacted molar.
- (2) The mechanical design is very simple.
- (3) Surgical exposure is not required in this technique.

Disadvantages

- (1) In Dr. Bach's cases it seems that the impacted molar will be distalize excessively.
- (2) Occlusal interference sometimes occurs due to composite over the occlusal surface of the molar. For open bite cases, this kind of technique should be avoided.

(5) Chris Chang's method

- A-1. Surgically expose the impacted molar and bond a small lingual tube over the distal side of the impacted molar.
- A-2. Put an OBS (*OrthoBoneScrew*) over the distal side of the impacted molar in the retromolar area.
- B. Pull and upright the impacted molar with power chains or elastic threads.
- C. After enough exposure of the crown of the impacted molar, bond a buccal tube and use a NiTi wire to upright the impacted molar.

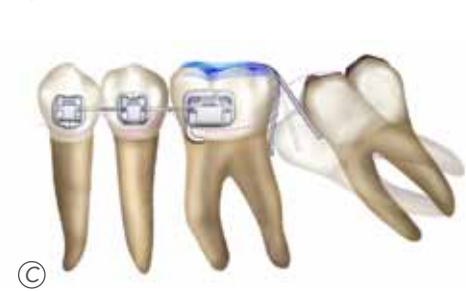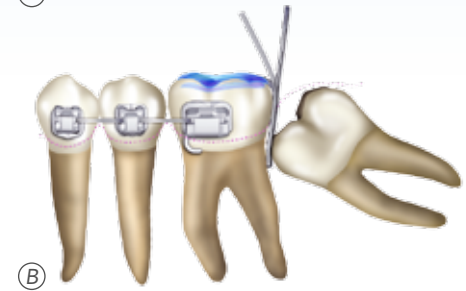
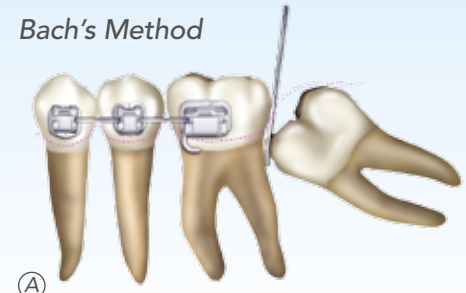
Advantages

This technique is very useful for very deeply impacted molars which can be uprighted over a short period of time.

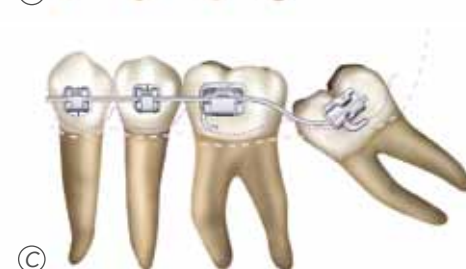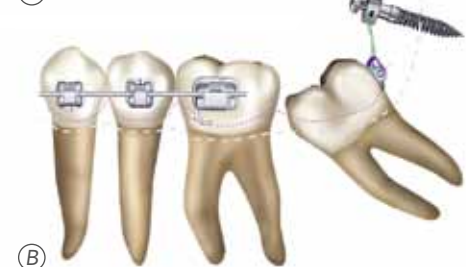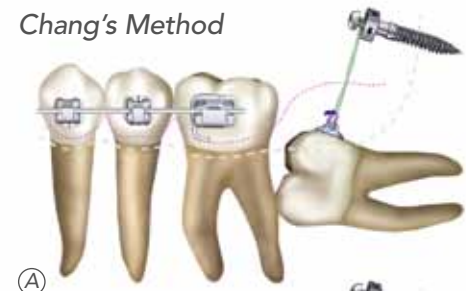Disadvantages

Comprehensive surgical exposure in the retromolar area is a major surgery for patients.

Bach's Method



Chang's Method



(6) John Jin-Jong Lin's method⁷

A. Bonding on the impacted molar

A-1. As long as the exposed disto-buccal surface area of the impacted molar is large enough for bonding a ultra short buccal tube is bonded.

A-2. Use a .014" or .016" Nickel Titanium wire, thread in the open coil spring.

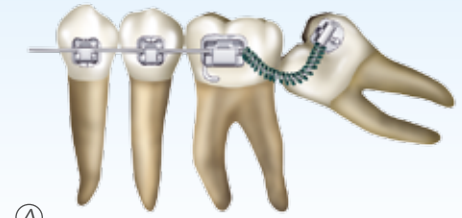
B. The open coil spring is activated between the tubes of two molars.

C. When the impacted molar is distally uprighted, rebond a normal sized buccal tube.

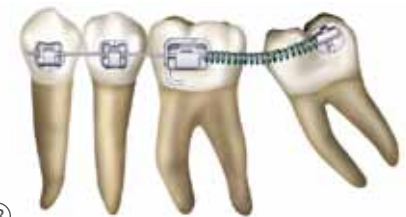D-1. The panoramic film indicates the right upper 1st molar has received endodontic treatment and was poorly restored. The left upper 2nd premolar and right lower 1st molar were removed. Notice the right upper 3rd molar is elongated.

D-2. The elongated right upper 3rd molar was intruded by the miniscrew over palatal side of the elongated 3rd molar, the elongated right upper 3rd molar was intruded, to create enough space to upright the impacted right lower 3rd molar. The molar tube was bonded on the partially erupted right lower 3rd molar.

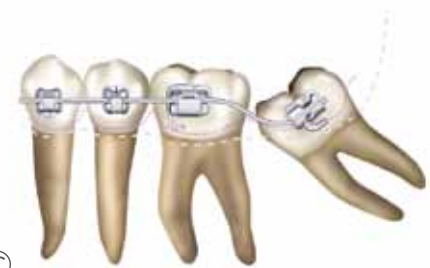Lin's method



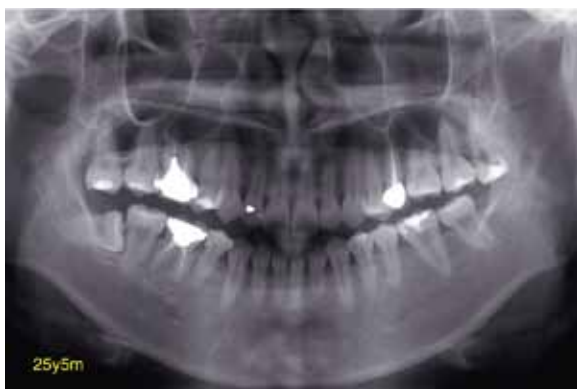(A)



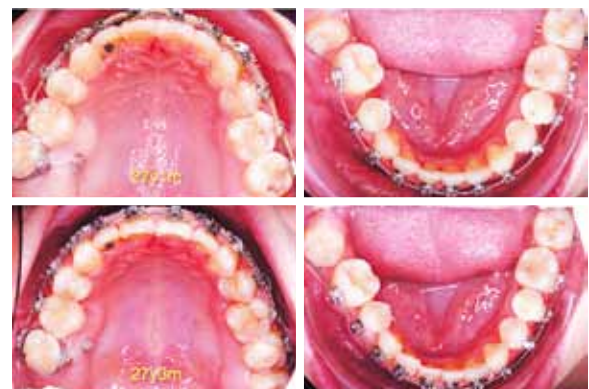(B)



(C)



(D1)



(D2)

D-3. The hanging down lingual cusp of right upper 3rd molar was intruded by the palatal miniscrew. It creates enough space for uprighting the impacted right lower 3rd molar.

D-4. By engaging a NiTi wire into the impacted lower 3rd molar, it was gradually uprighted. For managing this kind of asymmetric molar extraction cases, replacing badly restored 1st molars with good 3rd molars usually takes time. In this case it took more than 3 years. It should be explained to patients in advance!

D-5. 25y5m: poorly restored right upper 1st molar and right lower 1st molar were removed.

26y9m: severely elongated right upper 3rd molar.

27y4m: a severely elongated right upper 3rd molar was intruded with a palatal lingual screw. An open coil spring was used to upright the impacted lower 3rd molar.

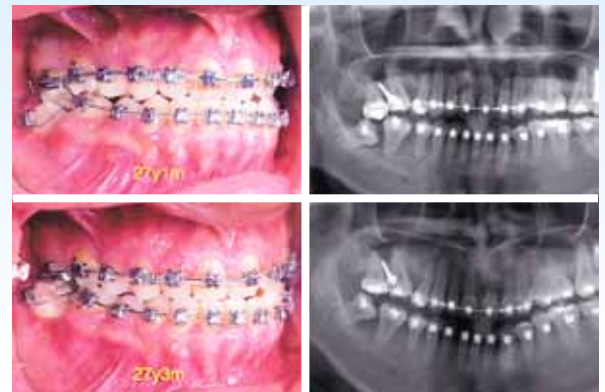28y6m: both upper and lower 3rd molars were aligned into a good position. Notice the much leveled gingival margin of the posterior teeth as long as enough space is provided.

Advantages

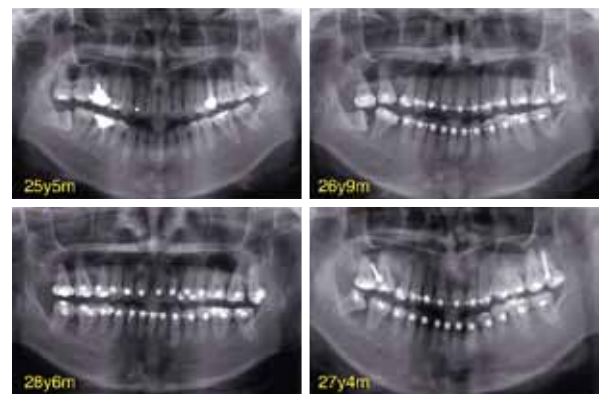
- (1) Surgical exposure is not required in over 95% of impaction cases with sufficient space. Impaction tends to self-erupt as long as enough space is provided.
- (2) There is no auxiliaries required, such as push springs, hooks, mini-screws and molar tubes.
- (3) Patients can follow simple routine orthodontic treatment.

Disadvantages

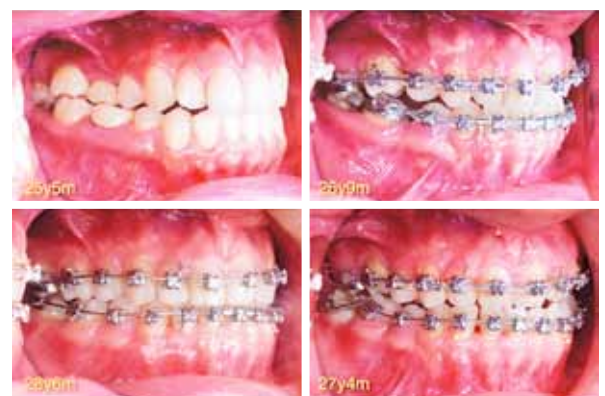- (1) Sometimes the disto-buccal surface of the impacted molar is insufficiently exposed, it will be very difficult to bond the molar tube.
- (2) If the disto-buccal part of the impacted molar is not expose yet, and the patient does not want to wait for too long, surgical exposure will be indicated.



(D3)



(D4)



(D5)

CONCLUSION

Space is the first consideration in treating impaction. Insufficient space is the primary cause for impacted molars. When enough space is created the impacted tooth will erupt by itself. This concept of auto eruption is well discussed in the literature ⁷.

The posterior space can be created by either extraction of the decayed lower 1st molar, 2nd molar, or even directly the impacted 3rd molar. After extraction of one of the molars, there will be enough space for the impacted molar to self erupt. However, it's difficult for the impacted molar to erupt into a perfect situation. As long as the impacted molar's disto-buccal part is erupted, a lingual button or buccal tube can be bonded. The impacted tooth can be uprighted using Miao's, Kuang's, Liaw's or Lin's method.

The impacted molar will erupt partially followed by extraction of a neighboring tooth. If the patient prefers a faster approach, Bach's or Chang's method is more suitable. One can also use Miao's, Kuang's, Liaw's or Lin's method followed by surgical exposure.

ACKNOWLEDGEMENT:

1. Thanks for Dr. Tom Pitts introducing Bach's method in Ormco's Asian master Course on July 21, 2011.
2. Thanks for Dr. Kuang and Dr. Liaw sharing their methods and cases.
3. Thanks for Dr. Chang's OBS technique.
4. Thanks for Dr. Bach's new idea of molar uprighting.
5. Thanks for Dr. Rungsi's great effort to make all the wonderful diagrams for reader easily to follow the real clinical steps by reading the diagrams.
6. Thanks for Tzu Han's perfect English editing.

REFERENCES

1. Shapira, Y.; Borell, G.; Nahlieli, O.; and Kufnec, M.M.: Uprighting mesially impacted mandibular permanent second molars, Angle Orthod. 68:173-178, 1998.
2. Kogod, M. and Kogod, H.S.: Molar uprighting with the piggyback buccal sectional arch wire technique, Am. J. Orthod. 99:276-280, 1991.
3. Majourau, A. and Norton, L.A.: Uprighting impacted second molars with segmented springs, Am. J. Orthod. 107:235-238, 1995.
4. Gazit, E. and Lieberman, M.: A mesially impacted mandibular second molar. Treatment considerations and outcome: A case report, Am. J. Orthod. 103:374-376, 1993.
5. Li, J. Z. : Orthodontic treatment of mesially impacted lower third molar in absence of the lower first molar, Chin. J. Orthod. 7:78-80, 2000.
6. Miao YQ, Zhong H. An uprighting appliance for impacted mandibular second and third molars. J Clin Orthod. 2006 Feb;40(2): 110-6.
7. Lin J J. Do teeth want to be straight? A nonsurgical approach to unerupted teeth. World J Orthod. 2005 Fall; 6(3):248-57.



2012 Beethoven International Damon & OBS Workshop

OrthoBoneScrew and Damon workshop includes two half-day lectures, two half-day chair-side observation sessions, one model practice and one case discussion session.

The costs also covers local transportation, two days of food and two nights of shared accommodation(double occupancy). Airport pick up is available upon request with additional charges.

Cost: USD 1,400;

For May session, register before 4/12 discount \$200 off; before 5/12 discount \$100 off

Keynote Presentation workshop includes a total of 6.5-hours of lecture and hands-on practice, focusing on improving your professional communication skills. The workshop will use Macintosh computers and its presentation software, Keynote 09. The costs also covers one day of food and one night of shared accommodation (double occupancy).

Cost: USD 350

For May session, register before 4/12 discount \$100 off; before 5/12 discount \$ 50 off

Registration:

A 50% deposit is required to confirm registration. To make a payment by wire, please email thhuang@newtonsa.com.tw or call +886-3-5735676



LECTURER: Dr. John Lin

President of the Jin-Jong Lin Orthodontic Clinic. Dr. Lin received his MS. from Marquette University and is an internationally renowned lecturer. He's also the author of

Creative Orthodontics and chief consultant to *International Journal of Orthodontics & Implantology*.

Dear Chris:

I must say what I learnt these few days is possibly much more than what I learn in the past few years. You obviously had surpassed my expectation.

I learn how one could create a kingdom out of a little town; how one could **manage an efficient patient flow in a shortest possible time frame with the biggest possible number**; I further learn that how one should **delegate the works effectively, empower the staff systematically and inspire them spontaneously to be contributory to the growth of the organization**.

I also reckon that effective presentation does not depend on how flowery the language we use but on how we connect to the audience and engage their attention to our flow of thoughts. An effective presentation needs an effective tool to support the deed.



Dr. How Kim Chuan, Malaysia (middle)
President of the Malaysian Dental Association



2012 Workshop Dates: 6/12-14, 11/13-15

LECTURER: Dr. Chris Chang

President of the Beethoven Orthodontic Center. He received his PhD in bone physiology and Certificate in Orthodontics from Indiana University in 1996. As publisher of International Journal of Orthodontics & Implantology, he has been actively involved in the design and application of bone screws.



Day 1

- 13:00—14:00 Welcome Lunch
- 14:00—14:40 Orientation
- 14:40—15:00 Introduction of Beethoven and Anderson Clinic
- 15:00—18:30 Chair-side observation

Day 3

- 14:00—15:30 Introduction of Keynote: Organize your patient files for presentation
- 15:30—15:45 Break
- 15:45—17:00 Key Presentation Principles I

Day 2

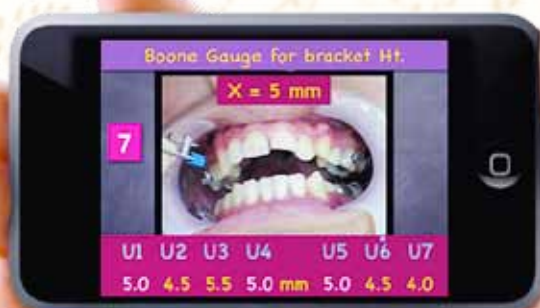- 9:00—10:30 Optimized Orthodontic Treatment I
Dr. Chris Chang
- 10:30—11:00 Break
- 11:00—12:30 Optimized Orthodontic Treatment II
Dr. Chris Chang
- 12:30—13:50 Lunch
- 14:00—15:00 Model Practice
- 15:00—18:30 Chair-side observation

Day 4

- 09:00—10:00 Key Presentation Principles II
- 10:00—10:10 Break
- 10:10—11:30 Make it Visual
- 11:30—13:30 Lunch

Day 3

- 09:00—10:00 6 Essentials of the new Damon Q
- 10:00—10:10 Break
- 10:10—12:30 Damon + Screw Dr. John Lin
- 12:30—13:30 Lunch



iAOI Case Report

Highly Positioned and Transalveolar Impacted Maxillary Canine

HISTORY AND ETIOLOGY

A 13-year-7-month-old female was referred for orthodontic consultation (*Figure 1*). Her chief concern was the edentulous space for an unerupted permanent canine (*Figure 2 and 3*). A specific surgical plan to expose and retract the impacted canine was proposed. There was no contributory medical or dental history. Clinical examination revealed bilateral Class I molar relationship and minor crowding in both arches. The patient was treated to an acceptable result as documented in Figures 4-9, as will be subsequently discussed.

DIAGNOSIS

A pretreatment cone beam computed tomography (CBCT) scan indicated that the canine was horizontally impacted in a high labial position, about 14 mm away from the crest of the alveolar ridge (*Figure 10*). The crown of the horizontal impaction was apical to the adjacent teeth, and its cusp tip was oriented toward the labial.

Skeletal:

Skeletal Class I (SNA 81°, SNB 78°, ANB 3°)

Mandibular plane angle (SN-MP 36°, FMA 31°)

Dental:

Bilateral Class I malocclusion

The overbite and overjet were both 4 mm.

Slight crowding in both the upper and lower arches

Facial:

Straight profile with acceptable lip position

The IBOI Discrepancy Index (DI) was 12 as shown in the subsequent worksheet.

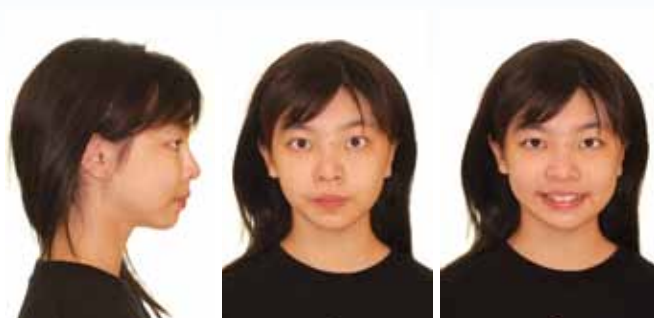

Fig 1. Pretreatment facial photographs

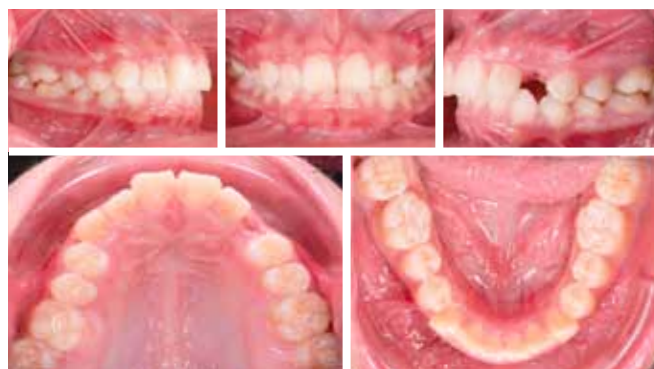

Fig 2. Pretreatment intraoral photographs

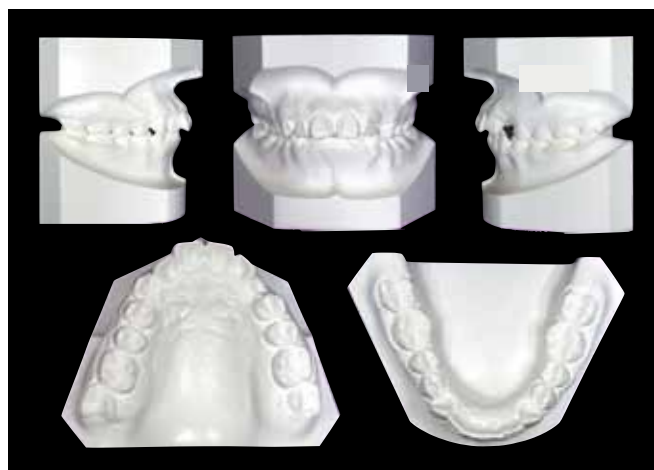

Fig 3. Pretreatment study models

Dr. Billy Su, Director, Newtons Implant Center (right)
 Dr. Chris HN Chang, Director, Beethoven Orthodontic Center (middle)
 Dr. Eugene W. Roberts, Consultant,
International Journal of Orthodontics & Implantology (left)



Fig 4. Posttreatment facial photographs

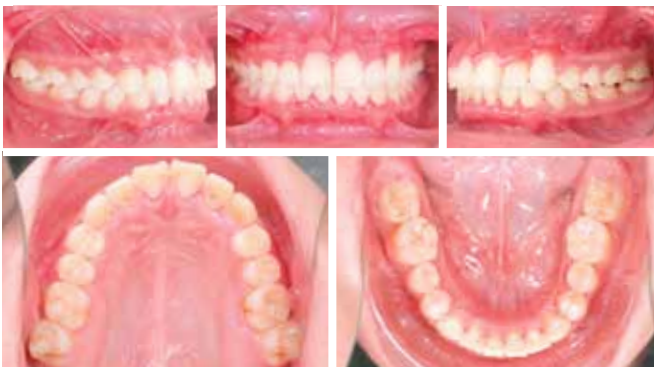

Fig 5. Posttreatment intraoral photographs

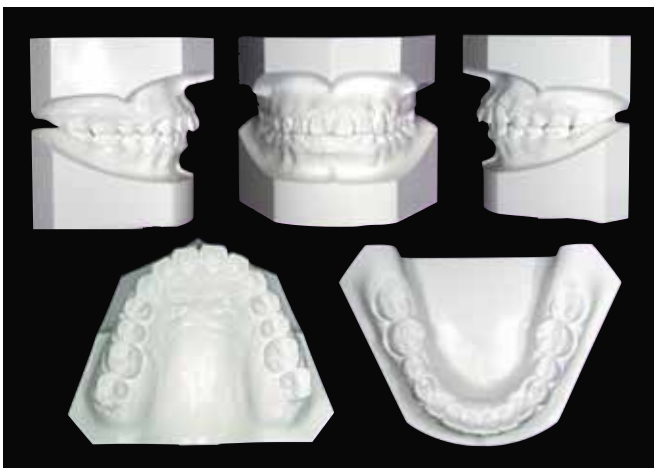

Fig 6. Posttreatment study models

SPECIFIC OBJECTIVES OF TREATMENT

Maxilla (*all three planes*):

- A - P: Maintain
- Vertical: Allow for normal expression of growth
- Transverse: Maintain

Mandible (*all three planes*):

- A - P: Allow for normal expression of growth
- Vertical: Allow for normal expression of growth
- Transverse: Maintain

Maxillary Dentition

- A - P: Maintain
- Vertical: Maintain
- Inter-molar Width: Maintain

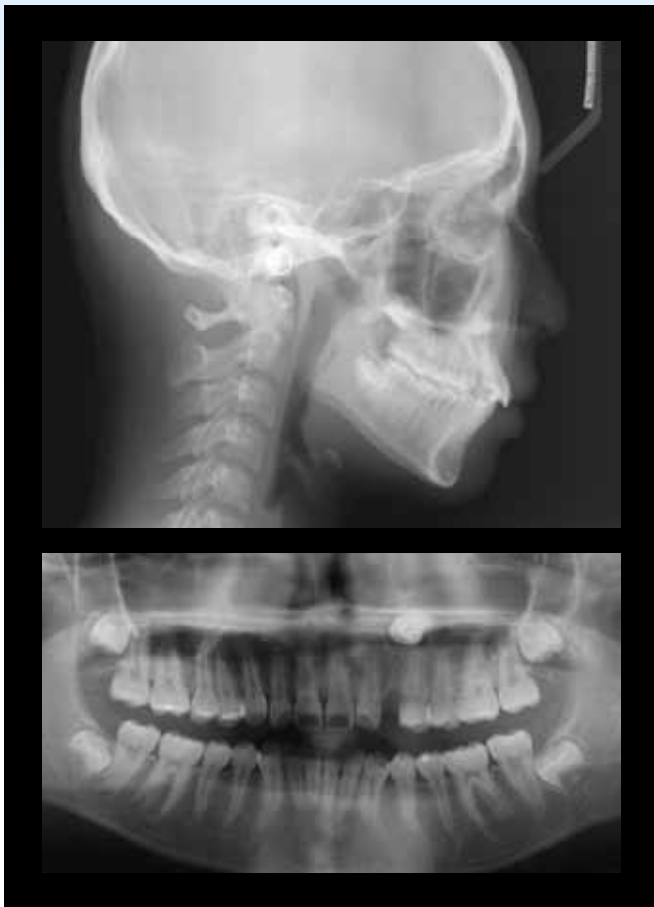Mandibular Dentition

- A - P: Maintain
- Vertical: Maintain
- Inter-molar / Inter-canine Width: Maintain

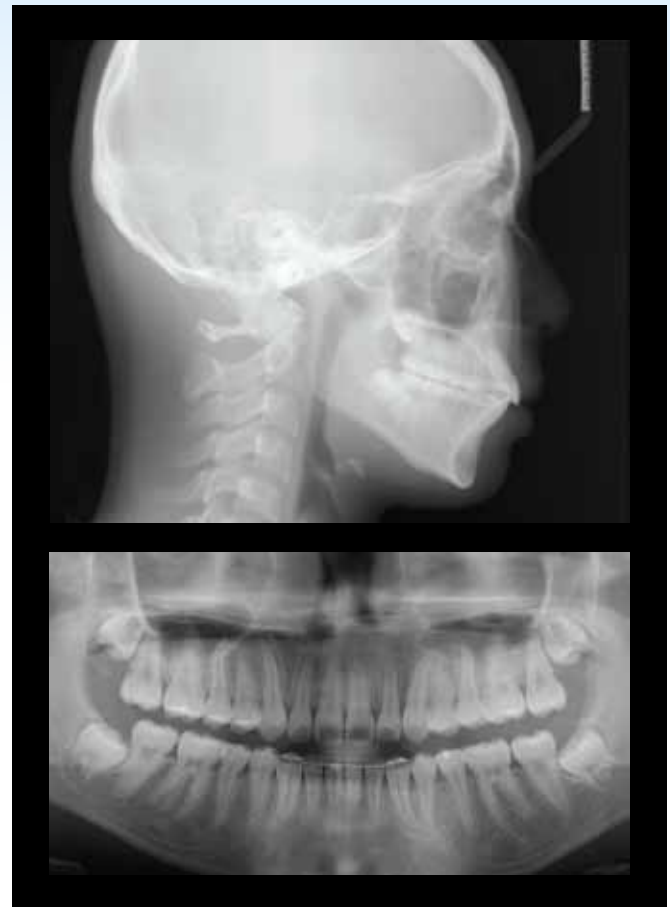Facial Esthetics: Maintain

TREATMENT PLAN

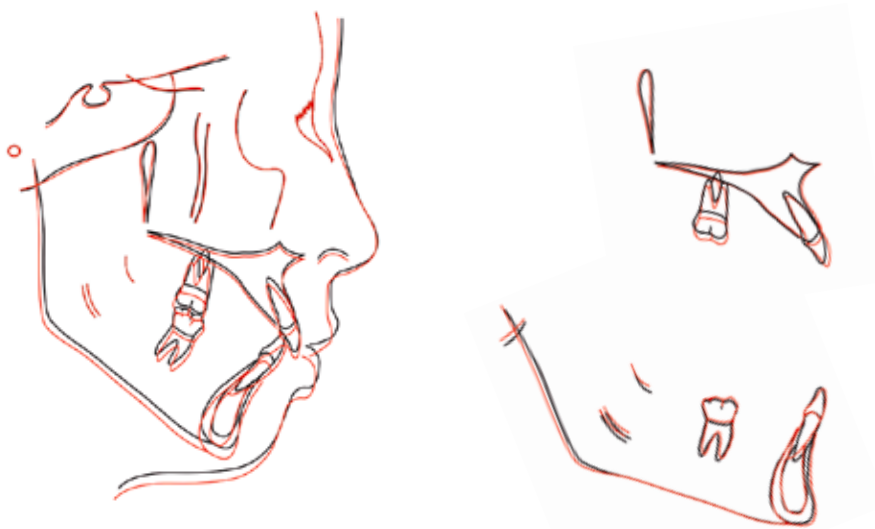
Non-extraction treatment with a full fixed orthodontic appliance was indicated to align and level the dentition. In the initial stage of treatment, space was opened for the impacted canine and the patient was referred for surgical exposure (*Figure 11*). The closed eruption technique (CET) was selected due to the relatively high, horizontal position of the impacted tooth (*above MGJ*). After crown exposure, two buttons were bonded with power-chains (PC) attached, on the lingual and labial surface of the impacted canine (*Figure 12*). To prevent the



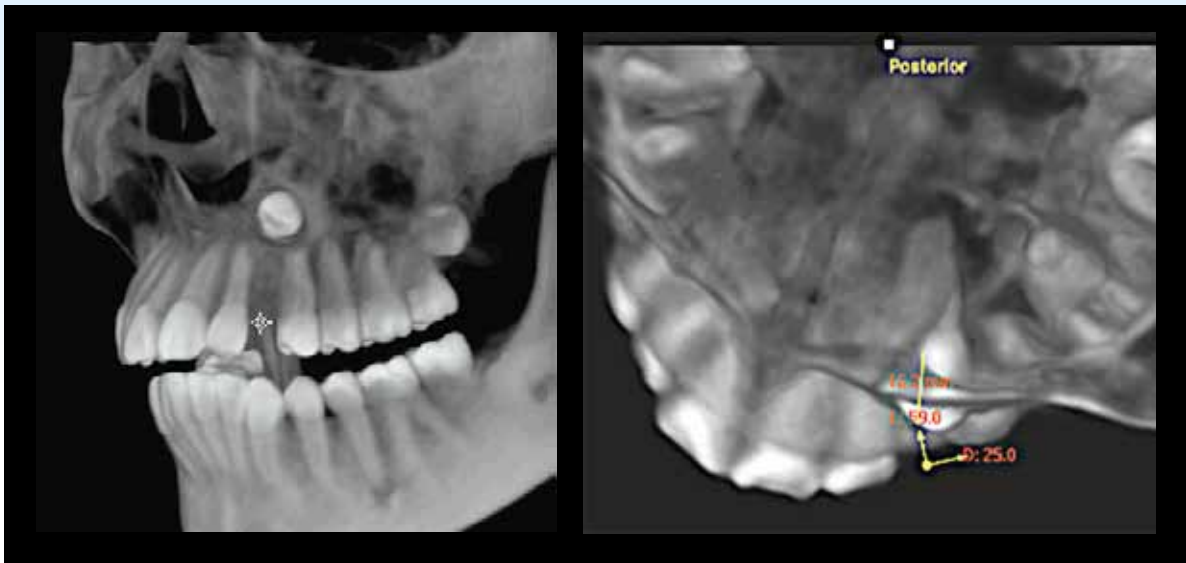
■ Fig. 7. Pretreatment pano and ceph radiographs



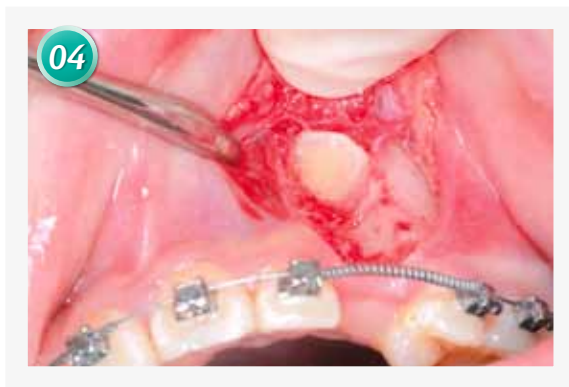■ Fig. 8. Posttreatment pano and ceph radiographs



■ Fig 9. Superimposed tracings

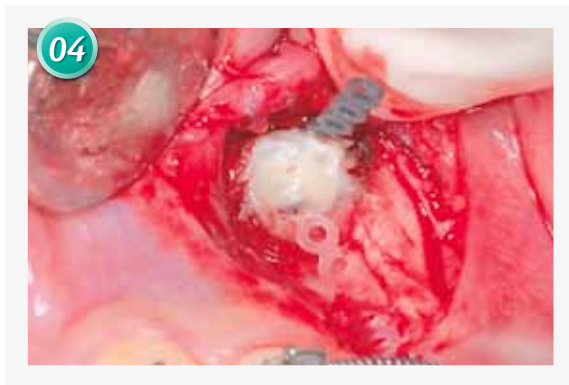

■ Fig. 10. A 13y 7m female with an impaction 14 mm away from the alveolar ridge.



■ Fig. 11.

A flap was used to expose the impaction and remove the bone until CEJ.

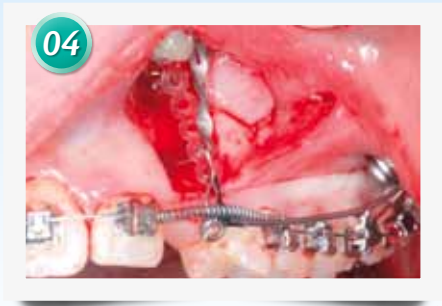

■ Fig. 12.

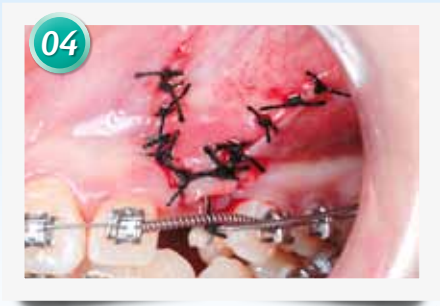
Bond buttons on the labial and buccal side of the impaction and use color-coded power chains as markers.

archwire from deforming and causing iatrogenic tooth movement, the traction anchorage was via an extra-alveolar miniscrew (2x12 mm, OrthoBoneScrew, Newton's A, Inc.) inserted in the infrazygomatic crest (Figure 13). Figure 14 shows primary closure of the wound. The PCs were activated with a lever arm of 17x25 SS (Figure 15) anchored by the miniscrew. The traction force was independent of the rest of the dentition; it was easily activated by adjusting the length of the PC chain and the lever arm in three dimensions (Figure 16). The gingival dynamics and third order control of the recovered canine, illustrated in Figures 17-21, will be described in the discussion section.

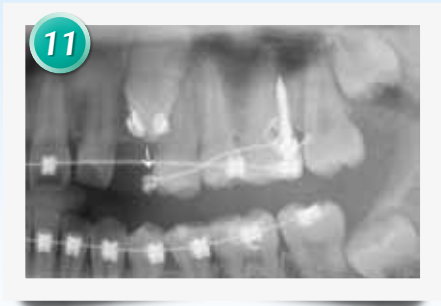Anterior bite turbos were used for correction of the 4 mm overbite (Figure 22). Class II elastics were used to resolve the sagittal occlusal discrepancy, and detailing bends produced the final occlusion. Fixed appliances were removed and the corrected dentition was retained with fixed anterior retainers on the lower arch and a clear overlay on the upper arch.



■ Fig. 13.
Place a miniscrew on the IZC. Create a lever arm and insert it into the screw. Connect the impaction and the screw with power chains on both ends to generate a downward traction force.



■ Fig. 14.
Suture the flap with primary closure.



■ Fig. 15.
11 months in treatment. Provide a continuous downward force by bending the lever arm.

APPLIANCES AND TREATMENT PROGRESS

0.022" slot Damon D3MX brackets (*Ormco*) were selected. After 4 months of creating space with an open coil spring, surgical exposure and orthodontic traction were ready to start. The closed eruption technique was selected due to the relatively high position of the impacted tooth (*>8mm above the MGJ*) (*Figure 10*).

The brackets were debonded from the maxillary left lateral incisor and first premolar, and an open coil spring was placed between adjacent central incisor and 2nd premolar to maintain a pathway for the extrusion of the impacted canine (*Figure 15*). Three dimensional adjustment of the lever arm provided a continuous traction on the impaction for 3 more months to move the canine crown at the level of the occlusal plane.

At the 15th month of the treatment, a panoramic radiograph and intra-oral occlusal photographs were obtained to evaluate root angulation and crown rotation. We removed the buttons, bonded brackets and changed back to the light wire (.014 *NiTi*) for leveling the impaction. The wire sequence was as follows: .014*NiTi*, .014x.025 *NiTi*, .017x.025 *TMA*, and .019x.025 *SS*. Anterior bite turbos with Class II elastics were used to correct the A-P discrepancy and

overbite. The root torque of the impacted canine was corrected with a torquing spring.

One month prior to the completion of active treatment, the upper archwire was sectioned distal to the cuspids. Light vertical elastics (2 oz) were used for final detailing of the buccal segments. After 26 months of active treatment, all appliances were removed; upper clear overlay and lower fixed anterior retainers were delivered for both arches.

CEPHALOMETRIC			
SKELETAL ANALYSIS			
	PRE-TX	POST-TX	DIFF.
SNA°	81°	82°	1°
SNB°	78°	78°	0°
ANB°	3°	4°	1°
SN-MP°	36°	37°	1°
FMA°	31°	32°	1°
DENTAL ANALYSIS			
U1 TO NA mm	5mm	5mm	0mm
U1 TO SN°	110°	112°	2°
L1 TO NB mm	5mm	6mm	1mm
L1 TO MP°	95°	100°	5°
FACIAL ANALYSIS			
E-LINE UL	1mm	0mm	-1mm
E-LINE LL	2mm	2mm	0mm

■ Table 1. Cephalometric summary

RESULTS ACHIEVED

Maxilla (*all three planes*):

- A - P: Maintained
- Vertical: Maintained
- Transverse: Maintained

Mandible (*all three planes*):

- A - P: Favorable growth
- Vertical: Favorable growth
- Transverse: Maintained

Maxillary Dentition

- A - P: Slightly flared incisors - 2 degrees
- Vertical: Extruded, impacted canine recovered and optimally aligned
- Inter-molar / Inter-canine Width: Maintained

Mandibular Dentition

- A - P: Flared incisors - 5 degrees
- Vertical: Intruded incisors; extruded molars
- Inter-molar / Inter-canine Width: Maintained

Facial Esthetics: Improved

RETENTION

The lower fixed retainer 3-3 was bonded on every tooth. An upper clear overlay was delivered. The patient was instructed to wear it full time for the first 6 months and nights only thereafter. The patient was instructed in the home care and maintenance of the retainers.

FINAL EVALUATION OF TREATMENT

The IBOI Cast-Radiograph Evaluation scored at 26 points, which was deemed to qualify as a board case report. The major discrepancies were problems in alignment/rotation, marginal ridge discrepancies, and occlusal relationships. The impacted canine was well aligned, and all of the canine and molar relationships were near ideal. The scar formation on

the gingival texture on #23 was shown (*Figure 25*), and there was more root prominence labial root prominence than for the opposite canine (*Figure 24*). Over-correction of the impacted canine was noted.

Collectively, flaring of the maxillary and mandibular incisors resulted in regaining of space and the overjet was corrected. The use of Class II elastics to anteriorly position the mandibular dentition was necessary, because there was insufficient anterior growth of the mandible. Overall, this difficult impaction case was treated to an appropriate facial and dental result with no iatrogenic problems.

DISCUSSION

Three dimensional CBCT imaging was essential for designing a treatment plan for the impacted canine to reveal the relationships among the impacted tooth, adjacent teeth and the cortical bone. Three types of 3D images are required: 1. 360° rotated animation around the impaction covered with bone. 2. 360° rotated animation around the impaction with the bone covering deleted. 3. Cross-sectioned slice through the impaction. These three images are necessary for selecting an appropriate surgical technique, as well as for designing a precise force system to align the impacted tooth without damaging the roots of adjacent teeth. An additional consideration is the management of the path of tooth movement to avoid inhibition of the recovery by dense cortical bone.¹ Moreover, any obstacles in the designed pathway of eruption should be removed during the surgical procedure.

When dealing with a labial impaction, that is within the alveolar process, retraction with a 3D lever arm and IZC miniscrew is indicated. Since the impaction is well above the mucogingival junction, closed eruption technique and an apically positioned flap (APF) are both important considerations. According

to Dr. Kokich's article in 2004, closed eruption technique is more appropriate than an APF when the impaction is in a high position, such as for the present case, which is 14mm apical to the alveolar crest.

Four types of surgical techniques are applicable for recovering impactions. The open window technique is usually the most ideal for palatal impactions with the potential to spontaneously erupt into oral cavity. Since the palate is covered by keratinized gingiva, there is little consideration for the impact on soft tissue. Closed eruption technique and APF are commonly adopted procedures for buccal and labial impactions. The choice of technique depends on the position of the impaction and the conditions of the soft tissue. However, one of the main problems with the closed eruption technique is the difficulty in tension release. APF shares a similar challenge in wound closure. The apical repositioning makes it difficult to have precise control of the flap margin.

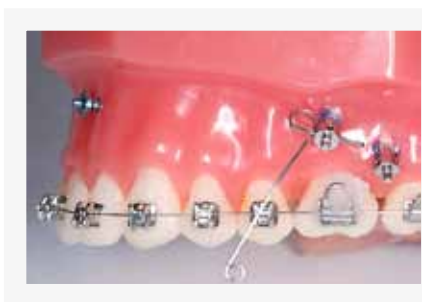To prevent the archwire deformation and unwanted tooth movement, the traction force was produced by a lever arm made of 17x25 SS anchored with a miniscrew (2x12 mm, Stainless Steel, OrthoBoneScrew, Newton's A, Inc.) that is inserted in the infrazygomatic crest (Figure 16). At subsequent visits, the device was reactivated by cutting loops off the power chain

or adjusting the lever arm. The adjacent lateral incisor and first premolar were not bonded nor engaged on the arch wire until the canine had been moved between them.^{2,3,4} This method allows the vulnerable, adjacent teeth to act as free bodies. They are free to move out of the way of tooth movement if they are contacted by the erupting canine, and thereby iatrogenic root resorption.

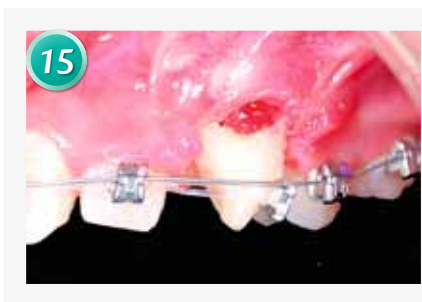During the orthodontic treatment, three stages of soft tissue change can be observed in the process of rapid traction of an impaction: Stage 1. Gingival collar redness ; Stage 2. The red patch ; Stage 3. Keratinization.⁵

Stage 1. Gingival collar redness : During the initial period of rapid forced eruption, a collar of redness is often observed around the gingival margin. This is the color of the non-keratinized epithelium tissue inside of the periodontal pocket (Figure 17). At this stage the pocket depth tends to be high and can be misinterpreted as poor healing or gingival inflammation. Patients should be instructed to maintain proper oral hygiene and this is in fact a normal condition.

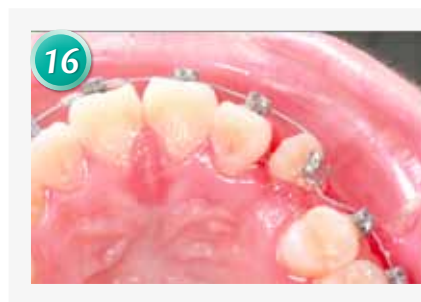Stage 2. The red patch : As the impaction continues to erupt occlusally, a margin of immature-appearing tissue, "the red patch", appears coronal to the



■ Fig 16. 2x12 mm OBS with 3D lever arm



■ Fig. 17.
15 months in treatment. Stage 1. Gingival collar redness. Deep probing depth was noted and careful monitor of oral hygiene was necessary.



■ Fig. 18.
16 months in treatment. Distal-rotated canine was noted. Light round wire .014 NiTi was engaged into bracket.

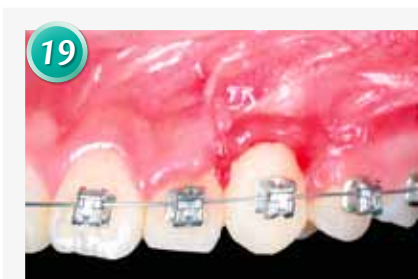original gingival margin. At this stage the probing depth reduces from around 5mm to 3mm, which is in the normal range. However, the color of the gingival margin still tends to be more reddish than surrounding tissue and is easily distinguished from the keratinized gingiva (Figure 19).

Stage 3. Keratinization : When the impacted tooth moves into an ideal position, the surrounding gingival tissue completes its progression of proliferation and maturation. The keratinization of gingiva takes about 28-42 days (Figure 20).

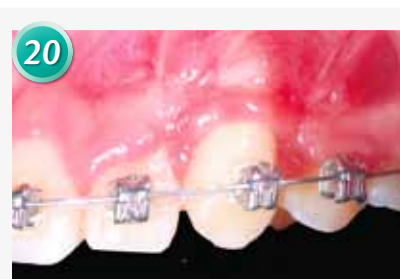The orifice of the gingival sulcus is bound by the tooth surface on one side and sulcular epithelium on the other, the bottom of the sulcus is frequently bordered by epithelium on all sides. The soft tissue wall of the gingival sulcus is lined coronally with nonkeratinizing epithelium, which is deemed the sulcular epithelium. For teeth that are erupted in the presence of soft tissue pocket appear to move coronally for a considerable distance before the gingival margin follows. Concurrently, the pocket depth is reduced and an immature appearing tissue, "red patch", that is sulcular epithelium, has peeled off the tooth surface directly. The nonkeratinized tissue remains erythematous for about 28 to 42 days, until keratinization occurs and it assumes the

appearance of normal gingiva.⁶ It is imperative that all periodontal pathology be under control before any orthodontic treatment is attempted. A chemical agent, such as chlorhexidine, can be used during the active phase of orthodontic treatment to reduce bacterial plaque accumulation, thereby improving the gingival condition and possibly reducing the acute inflammatory process. As a result, patients with a history of periodontal compromise are placed on 0.12% chlorhexidine gluconate (CH) mouthrinse during the course of active eruption of an impaction.

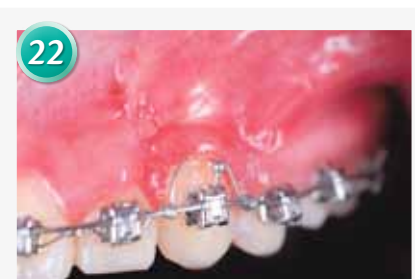
In the 22th month of treatment, insufficient lingual root torque was noted on the recovered impaction. When the impaction forcefully erupted, the root was more labially positioned because of the relatively dense bone on the palatal surface. Hence, it is important to monitor the torque of the impacted tooth in the finishing stage. Torquing springs are useful auxiliaries (Figure 21). Root angulation and torque control, for the transalveolar impacted canine, present significant challenges. There are several methods for solving these problems: 1. Bond the canine with a high torque bracket (*or inverted low torque bracket*). 2. Torque the segmental wire within the canine bracket; 3. add a torquing spring³. The most efficient and effective method to generate favorable torque expression is the use of an



■ Fig. 19.
19 months in treatment. Stage 2. The red patch. As the impaction erupted downward to the occlusal level, the "red patch", appeared coronal to the original gingival margin and probing depth was back to normal 3 mm.



■ Fig. 20.
20 months in treatment. Stage 3. Keratinization. The surround gingival tissue started the progression of proliferation and maturation and the whole process took 28~42 days.



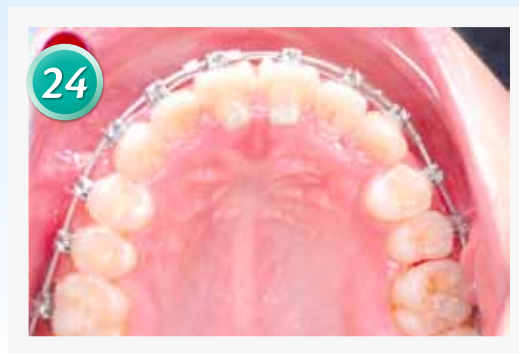■ Fig. 21.
22 months in treatment. Use a single torquing spring (18X25) to increase lingual root torque.

individual root torquing spring. It can be used earlier with light rectangular archwires such as .014x.025 copper NiTi, or the wire segment in the canine slot of the heavy rectangular wire can be rounded with a handpiece in the late stage of treatment.

Class II elastics combined with anterior Bite Turbos were applied for molar extrusion and to bring the mandible forward. These mechanics significantly improved the 4mm overjet and overbite (*Figure 22*).

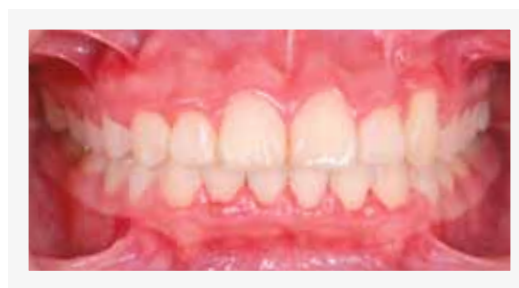
The initial DI score was only 10, indicating a minor to moderate malocclusion for an ABO case report⁷. However, it is necessary to also assess the complexity of a canine impaction, especially when it is 14 mm away from alveolar crest. In this regard, six points were added under the item of the additional treatment complexities to reflect the difficulty for management of a high transalveolar impaction. The final DI score was 16. The IBOI CRE score was 26 points, with most of the points reflecting problems in alignment and marginal ridge discrepancies (*Figures 26 and 27*). Pre-finish casts, obtained about six months before the end of active treatment, would have been helpful in identifying and resolving these finishing problems.

To more thoroughly evaluate the recovery and alignment of an impacted canine, the record of gingival esthetic change after impaction-related surgery is indicated.⁸ The quality of a prosthesis can also be evaluated by the measurement of the white esthetic score. Because of the scar formation, inadequate lingual root torque over impacted canine and disharmony of the curvature of gingival margin over adjacent lateral incisor, 4 points were assessed on the pink esthetic score. The Pink & White esthetic score worksheet⁹ provide a broader array of clinical parameters for patients with impacted teeth. The Pink and White Esthetic Score worksheet is demonstrated at the end of this article.



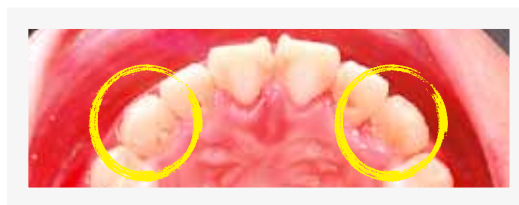
■ Fig. 22.

23 months in treatment. Class II elastics combined with anterior BT were applied for molar extrusion and to bring the mandible forward, which significantly improved the 4mm overjet and overbite.



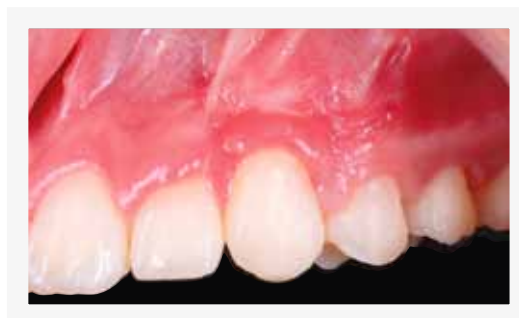■ Fig. 23.

Post-treatment intra-oral frontal photo. Uneven gingival margin level was noted on the upper anterior area. Gingivectomy procedure with diode laser was recommended to patient.



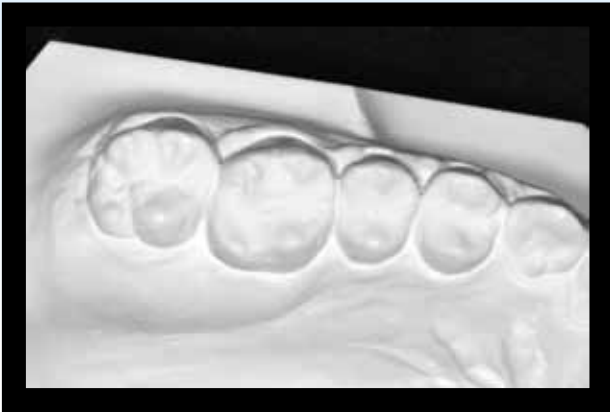■ Fig. 24.

Occlusal view of anterior teeth showed different root torque of bilateral canine. Absence of cingulum indicated insufficient lingual root torque.

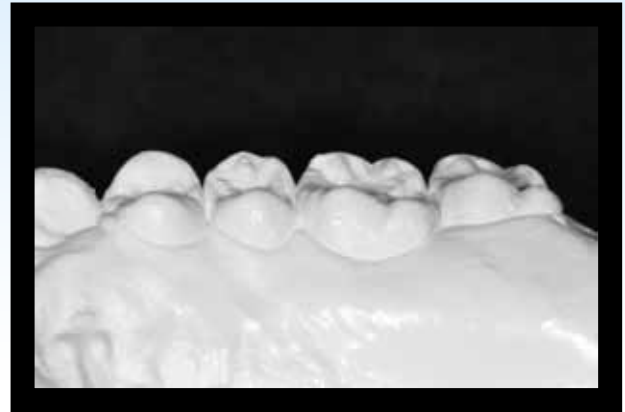

■ Fig. 25.

Buccal view of active treatment for 26 months. Scar formation over mucosa area of impacted canine was noted.



■ Fig. 26. Distal-in 1st molar was noted.



■ Fig. 27.

Marginal ridge discrepancy over 1st and 2nd molars was noted.

CONCLUSION

High, transalveolar impactions are difficult canines to recover. Selection of an appropriate surgical technique depends on the height (*position*) of the impaction and the conditions of the adjacent soft tissue. 3D imaging is particularly helpful for labial impactions or for those deeply embedded in the alveolar process. In this case, we chose the closed eruption technique and used a 3D lever arm to move the impaction occlusally. The adjacent teeth should not be bonded until the canine erupts to prevent iatrogenic root resorption. Moving a transalveolar impaction into the maxillary arch usually results in inadequate lingual root torque on the recovered canine. This third order problem should be addressed with a torqueing auxiliary during orthodontic finishing.

ACKNOWLEDGMENT

Thanks to Ms. Tzu Han Huang for proofreading this article.

REFERENCES

1. Kokich VG. Surgical and orthodontic management of impacted maxillary canine. *Am J Orthod Dentofacial Orthop* 2004; 126:278-83.
2. Niagara K. et al. Impacted maxillary central incisor, canine, and second molar with 2 supernumerary teeth and an odontoma. *Am J Orthod Dentofacial Orthop* 2009; 135:390-9.
3. Tseng SP, Chang CH, Roberts WE. High maxillary canine impaction with mesial and labial displacement. *News & Trends in Orthodontics* 2010; 18:36-44
4. Chang CH. Advanced Damon Course No. 9: Impacted and transposed teeth, Beethoven Podcast Encyclopedia in Orthodontics 2011, Newton's A Ltd, Taiwan
5. Theo M, Ilan S. Forced eruption and implant site development: Soft tissue response. *Am J Orthod Dentofac Orthop* 1997; 112:596-606.
6. Goldman H, Cohen DW. Healing in periodontal surgical wounds. In: *Periodontal therapy* 5th ed. St Louis : CV Mosby; 1973. p. 898.
7. Chang CH. Advanced Damon Course No. 4,5 : DI & CRE Workshop (1)(2)., Podcast Encyclopedia in Orthodontics 2011, Newton's A Ltd, Taiwan.
8. Su B, Chang CH, Roberts WE. Class II Malocclusion Complicated by a Complex Impacted Cuspid; Introduction of the iSAS Method for More Clinical Assessment. *News & Trends in Orthodontics* 2010; 19:32-46.
9. Belser C, Linda G, Francesca V et al. Outcome Evaluation of Early Placed Maxillary Anterior Single-Tooth Implants Using Objective Esthetic Criteria: A Cross-Sectional, Retrospective Study in 45 Patients With a 2- to 4- Year Follow-Up Using Pink and White Esthetic Scores. *J Periodontol* 2009; 80:140-151.

IBOI Discrepancy Index Worksheet

TOTAL D.I. SCORE **16****OVERJET**

0 mm. (edge-to-edge)	=	
1 – 3 mm.	=	0 pts.
3.1 – 5 mm.	=	2 pts.
5.1 – 7 mm.	=	3 pts.
7.1 – 9 mm.	=	4 pts.
> 9 mm.	=	5 pts.

Negative OJ (x-bite) 1 pt. per mm. per tooth =

Total = **2****OVERBITE**

0 – 3 mm.	=	0 pts.
3.1 – 5 mm.	=	2 pts.
5.1 – 7 mm.	=	3 pts.
Impinging (100%)	=	5 pts.

Total = **2****ANTERIOR OPEN BITE**

0 mm. (edge-to-edge), 1 pt. per tooth
then 1 pt. per additional full mm. per tooth

Total = **0****LATERAL OPEN BITE**

2 pts. per mm. per tooth

Total = **0****CROWDING** (only one arch)

1 – 3 mm.	=	1 pt.
3.1 – 5 mm.	=	2 pts.
5.1 – 7 mm.	=	4 pts.
> 7 mm.	=	7 pts.

Total = **4****OCCLUSION**

Class I to end on	=	0 pts.
End on Class II or III	=	2 pts. per side <u> </u> pts.
Full Class II or III	=	4 pts. per side <u> </u> pts.
Beyond Class II or III	=	1 pt. per mm. <u> </u> pts. additional

Total = **0****LINGUAL POSTERIOR X-BITE**1 pt. per tooth Total = **0****BUCCAL POSTERIOR X-BITE**2 pts. per tooth Total = **0****CEPHALOMETRICS** (See Instructions)ANB $\geq 6^\circ$ or $\leq -2^\circ$ = 4 pts.Each degree $< -2^\circ$ x 1 pt. = Each degree $> 6^\circ$ x 1 pt. = **SN-MP** $\geq 38^\circ$ = 2 pts.Each degree $> 38^\circ$ x 2 pts. = $\leq 26^\circ$ = 1 pt.Each degree $< 26^\circ$ x 1 pt. = 1 to MP $\geq 99^\circ$ = 1 pt.Each degree $> 99^\circ$ x 1 pt. = Total = **0****OTHER** (See Instructions)

Supernumerary teeth	<u> </u> x 1 pt. = <u> </u>
Ankylosis of perm. teeth	<u> </u> x 2 pts. = <u> </u>
Anomalous morphology	<u> </u> x 2 pts. = <u> </u>
Impaction (except 3 rd molars)	<u> </u> x 2 pts. = <u> </u>
Midline discrepancy (≥ 3 mm)	@ 2 pts. = 2
Missing teeth (except 3 rd molars)	<u> </u> x 1 pts. = <u> </u>
Missing teeth, congenital	<u> </u> x 2 pts. = <u> </u>
Spacing (4 or more, per arch)	<u> </u> x 2 pts. = <u> </u>
Spacing (Mx cent. diastema ≥ 2 mm)	@ 2 pts. = <u> </u>
Tooth transposition	<u> </u> x 2 pts. = <u> </u>
Skeletal asymmetry (nonsurgical tx)	@ 3 pts. = <u> </u>
Addl. treatment complexities	3 x 2 pts. = 6

Identify: **14 mm highly positioned and transalveolar
impaction**

Total = **8****IMPLANT SITE**

Lip line : Low (0 pt), Medium (1 pt), High (2 pts)	= <u> </u>
Gingival biotype : Low-scalloped, thick (0 pt), Medium-scalloped, medium-thick (1 pt), High-scalloped, thin (2 pts)	= <u> </u>
Shape of tooth crowns : Rectangular (0 pt), Triangular (2 pts)	= <u> </u>
Bone level at adjacent teeth : ≤ 5 mm to contact point (0 pt), 5.5 to 6.5 mm to contact point (1 pt), ≥ 7 mm to contact point (2 pts)	= <u> </u>
Bone anatomy of alveolar crest : H&V sufficient (0 pt), Deficient H, allow simultaneous augment (1 pt), Deficient H, require prior grafting (2 pts), Deficient V or Both H&V (3 pts)	= <u> </u>
Soft tissue anatomy : Intact (0 pt), Defective (2 pts)	= <u> </u>
Infection at implant site : None (0 pt), Chronic (1 pt), Acute (2 pts)	= <u> </u>

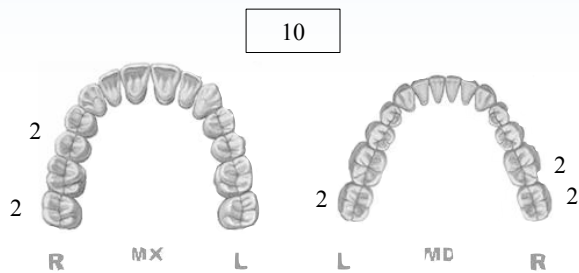
Total = **0**

IBOI Cast-Radiograph Evaluation

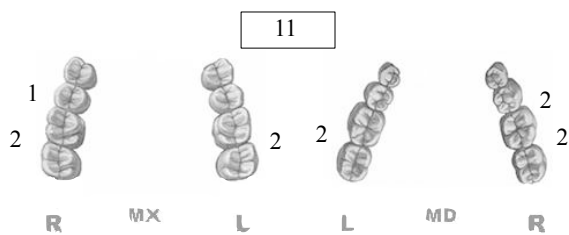
Case # 1 Patient

Total Score: 26

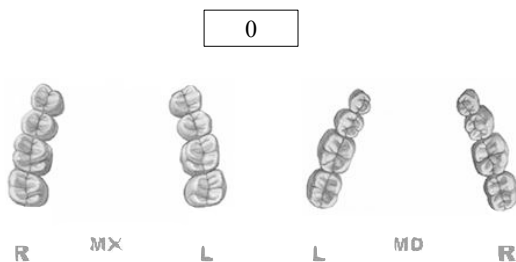
Alignment/Rotations



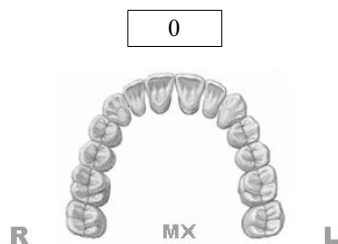Marginal Ridges



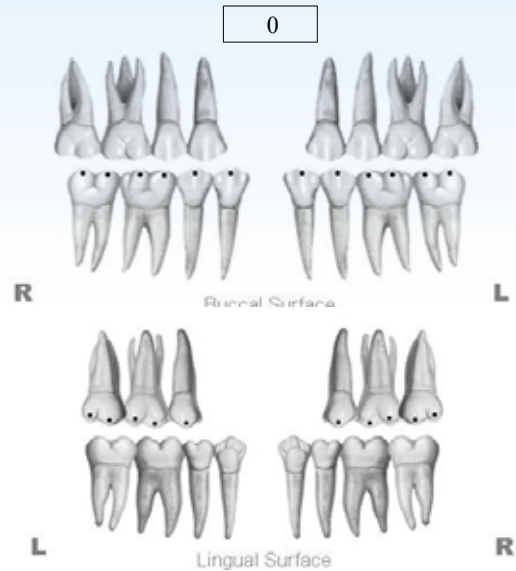
Buccolingual Inclination



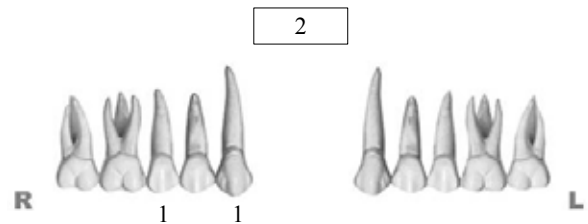
Overjet



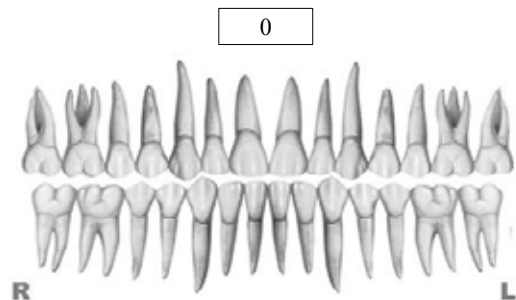
Occlusal Contacts



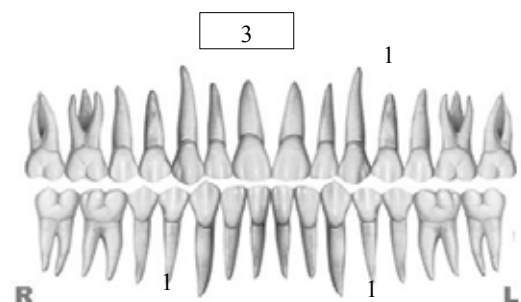
Occlusal Relationships



Interproximal Contacts



Root Angulation

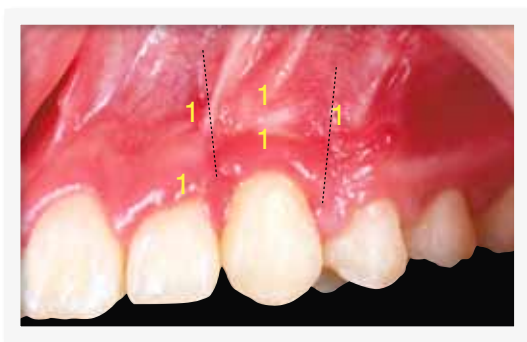
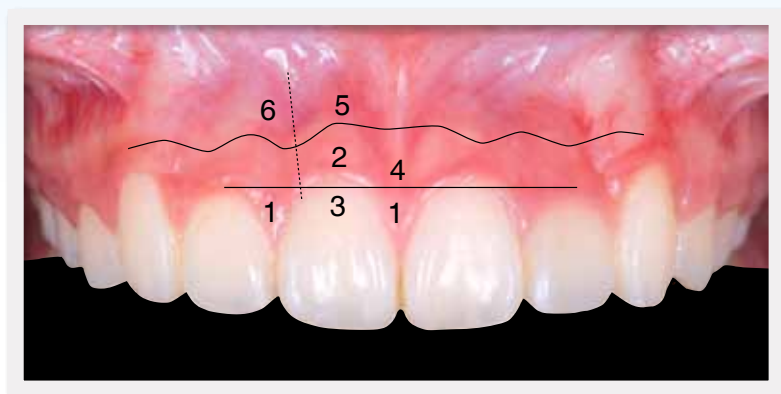


INSTRUCTIONS: Place score beside each deficient tooth and enter total score for each parameter in the white box. Mark extracted teeth with "X". Second molars should be in occlusion.

IBOI Pink & White Esthetic Score

Total Score: = 8

I. Pink Esthetic Score

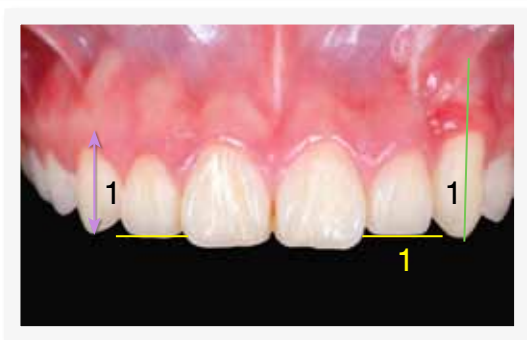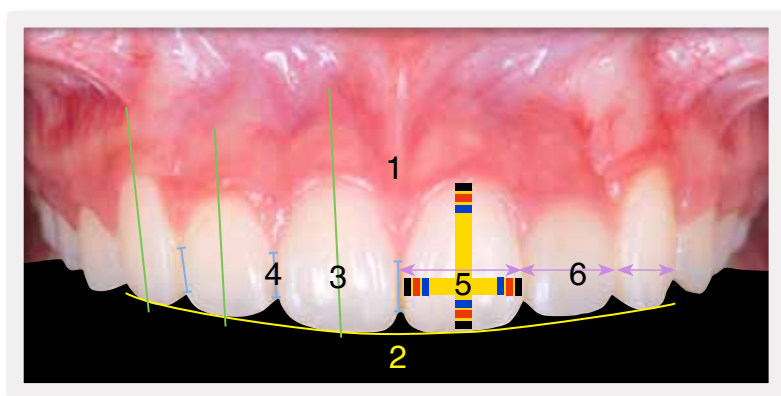


Total = 5

1. M & D Papilla	0	1	2
2. Keratinized Gingiva	0	1	2
3. Curvature of Gingival Margin	0	1	2
4. Level of Gingival Margin	0	1	2
5. Root Convexity (Torque)	0	1	2
6. Scar Formation	0	1	2

1. M & D Papilla	0	1	2
2. Keratinized Gingiva	0	1	2
3. Curvature of Gingival Margin	0	1	2
4. Level of Gingival Margin	0	1	2
5. Root Convexity (Torque)	0	1	2
6. Scar Formation	0	1	2

2. White Esthetic Score (for Micro-esthetics)



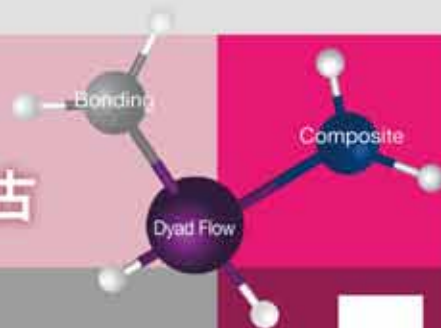
Total = 3

1. Midline	0	1	2
2. Incisor Curve	0	1	2
3. Axial Inclination (5°,8°,10°)	0	1	2
4. Contact Area (50%,40%,30%)	0	1	2
5. Tooth Proportion (1 : 0.8)	0	1	2
6. Tooth to Tooth Proportion	0	1	2

1. Midline	0	1	2
2. Incisor Curve	0	1	2
3. Axial Inclination (5°,8°,10°)	0	1	2
4. Contact Area (50%,40%,30%)	0	1	2
5. Tooth Proportion (1 : 0.8)	0	1	2
6. Tooth to Tooth Proportion	0	1	2

Kerr

A revolutionary new category
of composites has emerged
樹脂革命 獨步千古



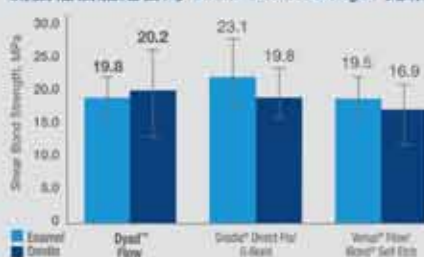
神奇全效
低敏感
流動性樹脂

Dyad

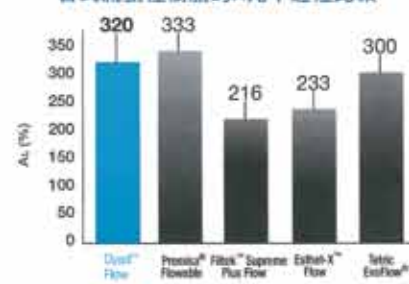
Self-Adhering Flowable Composite

FLOW

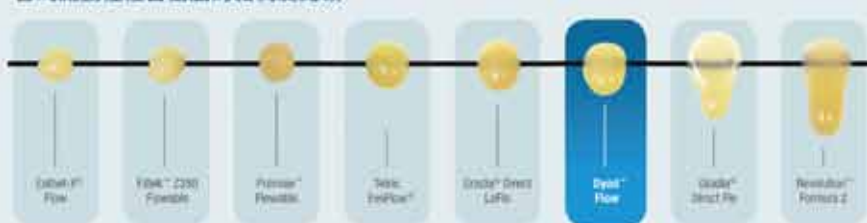
自黏式流動性樹脂與使用自蝕性黏合劑/
流動性樹脂組合的 Shear Bond Strength 比較



各式流動性樹脂的X光不透明度比較



各式流動性複合樹脂的黏稠度比較



將流動性複合樹脂塗於潔淨的玻璃上靜置一分鐘後光潤的結果。

Dyad Flow 適度的流動性不論小窩洞填補或大窩洞底部均適用。

Self-adhering | 自黏性，操作極簡便

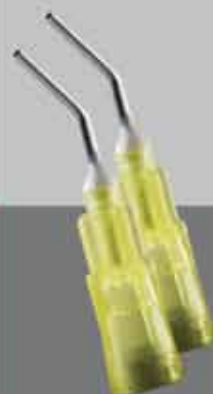High bond strengths to dentin and enamel | 超高黏著強度

Greatly reduces chance of post-op sensitivity | 大大降低術後敏感度

Easy handling | 最適合的操作性和流動性

Low microleakage | 有效減少微滲漏

Excellent mechanical properties | 極佳的物理性質



iAOI Case Report

A Severe Skeletal Class III Open Bite Malocclusion Treated with Non-surgical Approach

This 20-year-8-month-old male presented with a chief concern of “*anterior cross bite and prognathic mandible.*” He has seen at least two other orthodontists and was told that surgery is the only solution for his severe malocclusion. Oral soft tissues, periodontium, frena, and gingival health were all within normal limits. Oral hygiene was excellent. Medical and dental histories were noncontributory.

DIAGNOSIS AND ETIOLOGY

Pretreatment facial photographs (Fig. 1) showed a straight profile with protrusive lower lip. The pretreatment intraoral photographs (Fig. 2) and study models (Fig. 3) revealed a molar relationship of bilateral Class III. The lower dental midline was shifted 1.5 mm to the right of the facial midline. A lingual cross-bite extended from the right 1st molar to the left 1st premolar. There was also an end-to-end cross-bite tendency extending from the left 2nd premolar to the 2nd molar. No contributing habits were reported, but the labial tipping of the mandibular incisors suggests a long-term maxillary lip trap. Intra-oral exam and the panoramic radiograph (Fig. 4) revealed impaction of the right mandibular third molar (#32). All other third molars were missing.

Cephalometric analysis showed a skeletal Class III pattern, due to a prognathic mandible that was manifest as a 7-mm anterior cross bite. The ANB angle was 1.5°, the SN-MP angle was 36°,



Fig 1. Pretreatment facial photographs

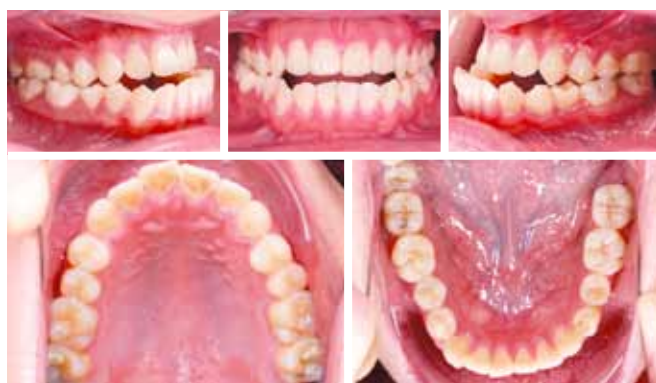

Fig 2. Pretreatment intraoral photographs

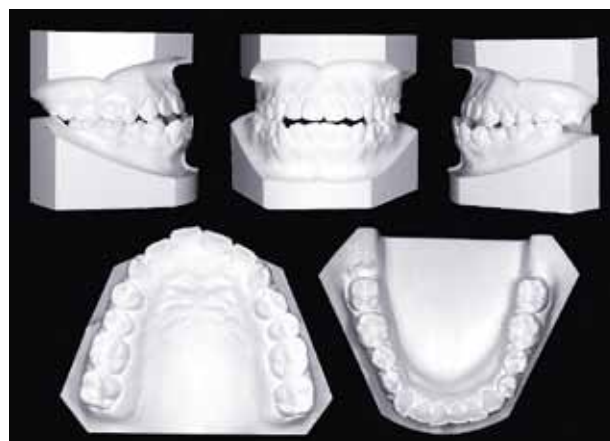

Fig 3. Pretreatment study models

Dr. Sabrina Huang, Lecturer, Beethoven Orthodontic Course (left)
 Dr. Chris HN Chang, Director, Beethoven Orthodontic Center (middle)
 Dr. W. Eugene Roberts, Consultant,
International Journal of Orthodontics & Implantology (right)

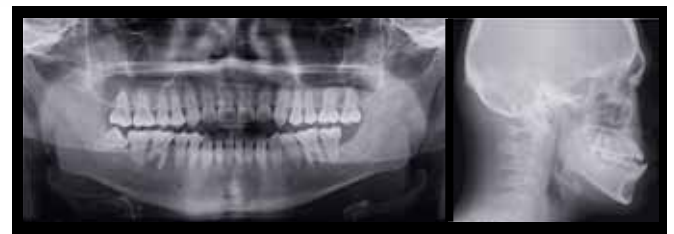

and the lower incisors were inclined 94° to Md plane. The cephalometric values are summarized in the Table entitled Cephalometric Summary. The IBOI (*International Board of Orthodontists and Implantologists*) and American Board of Orthodontics (ABO) discrepancy index (DI) was 71, as documented in the DI worksheet. The patient was successfully treated with a conservative camouflage method as documented in the finish records (Figs. 6-10).

TREATMENT OBJECTIVES

The overall objective of treatment was to keep the vertical dimension of occlusion (VDO), and retract the mandibular incisors, to compensate for the prognathic mandible, in order to achieve a Class I molar and canine relationships with ideal overjet and overbite. The specific treatment objectives were to:

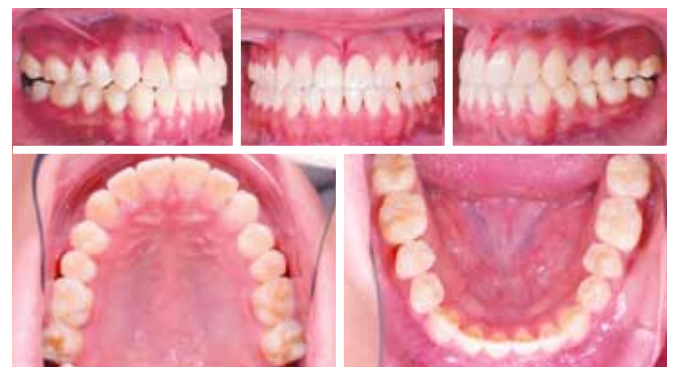- Maintain the A-P position of the maxilla.
- Maintain the position of the maxillary incisors and molars.
- Retract the mandible incisors and molars relative to the apical base of bone.
- Correct the anterior and posterior X-bite and align the midlines.
- Establish a normal overjet and overbite in a mutually protected, Class I occlusion.
- Retract upper and lower lips to improve facial balance.



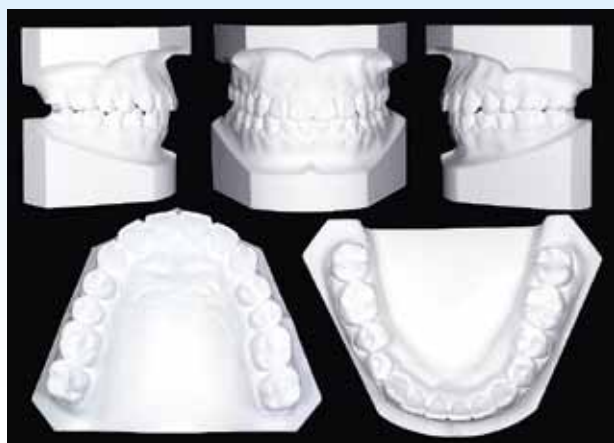■ Fig. 4-5. Pretreatment pano and ceph radiographs



■ Fig 6. Posttreatment facial photographs



■ Fig 7. Posttreatment intraoral photographs



■ Fig 8. Posttreatment study models

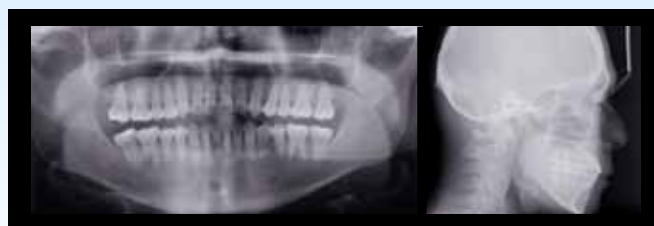TREATMENT ALTERNATIVES

The patient's chief concerns were the anterior cross bite and the difficulty of incising food. Because of the protrusive lower lip and the extreme negative overjet (Fig. 11), an orthognathic surgical option was suggested by two other orthodontists, but the patient deemed that to be too aggressive. Thus a nonsurgical camouflage plan was devised to meet the patient's needs:

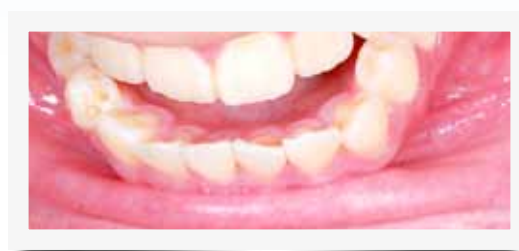1. Extract mandibular right 3rd molar,
2. Place bilateral bone screws in mandibular buccal shelves to ensure maximal retraction of whole mandibular dentition.
3. Remove appliances and retain with upper and lower clear overlay retainers.

TREATMENT PROGRESS

0.022-in Damon Q® standard torque (Ormco) were used. Both arches were bonded and aligned. In the 9th month of treatment, .014 x .025" CuNiTi arch-wires were placed and the buccal shelf bone screws were installed to anchor retraction of the whole mandibular dentition (Fig. 12). In the 12th month of

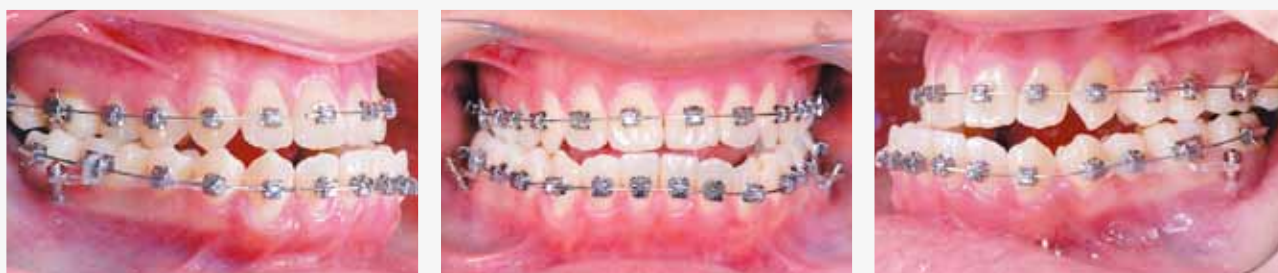

■ Fig. 9-10. Posttreatment pano and ceph radiographs



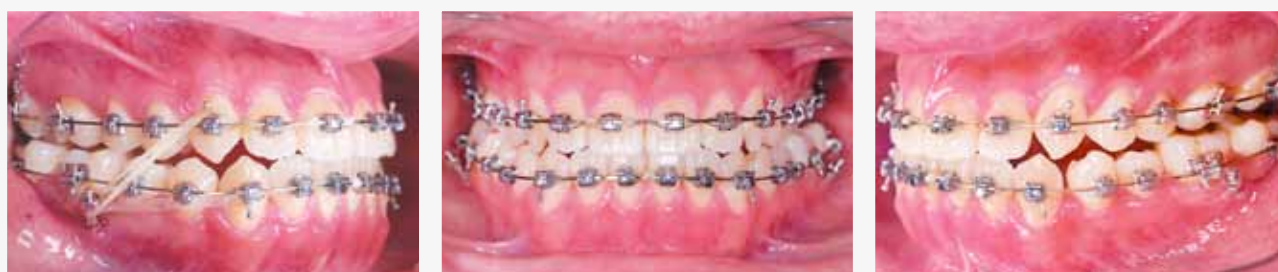■ Fig. 11. Huge negative overjet (-7 mm)

treatment the anterior cross-bite was corrected to almost edge-to-edge position. To resist further lingual tipping of lower incisors, the arch-wire was changed to .017x.025 low friction TMA. In the 14th month of treatment, the upper arch-wire was changed to .017x.025 low friction TMA (Fig. 13). Expansion of upper arch-wire was performed to assist in correction of the bilateral posterior lingual cross bite. Class II elastics (3.5 oz, 3/16") from upper canines to buccal shelf screws were introduced to distally tip the upper incisors to improve his acute naso-labial angle. In the 15th month of treatment, upper arch-wire was changed to .019x.025 SS and .016x.025 SS on lower arch for coordination. In the 19th month of treatment, lingual X-bite was corrected on left side while right side still remained in X-bite position. Cross elastics from upper 1st molars to buccal shelf screws was introduced to establish adequate transverse relation (Fig. 14). Meanwhile, Class II elastics were continued for smile arc enhancement. After the transverse problem has been over-corrected, one month later, a diagnostic impression was taken to evaluate the occlusion for final detailing. At that time, the major problem is



■ Fig 12.

Start whole mandibular arch retraction with 2 OrthoBoneScrews placed on buccal shelf as anchors in 9th month of treatment.



■ Fig 13.

The anterior X-bite was corrected in 14th month of treatment with space still left distal to mandibular left canine. Class II elastics (3.5oz, 3/16") from maxillary canines to buccal shelf screws were introduced to enhance smile arc. Upparch-wire was expanded for correction of posterior lingual X-bite.

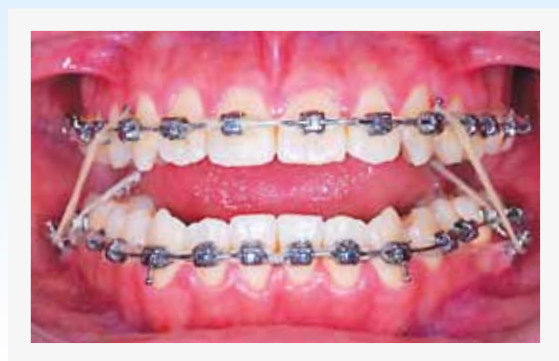
the distal tipping of the mandibular 2nd molars and the resulting open bite in the posterior molar area caused by tip-back effect due to retraction of the lower dentition with anchorage by buccal shelf screws. The archwire failed to provide an adequate root distal moment to maintain the axial inclination of the mandibular second molars. For final settling of the occlusion, the upper arch-wire was sectioned distal to canines and lower archwire was cut distal to 2nd premolars. Vertical elastics (3.5 oz, 1/8") were used in the molar area to finish the occlusion (Fig. 15). The appliance was removed in 21th month of treatment; upper and lower clear, overlay retainers were delivered. Gingivoplasty was performed on the upper central incisors with a diode laser to improve

the crown length-to-width proportion (Fig. 16). The biomechanics associated with retracting the entire mandibular dentition with buccal shelf screws are illustrated in Figure 17 and 18.

TREATMENT RESULTS

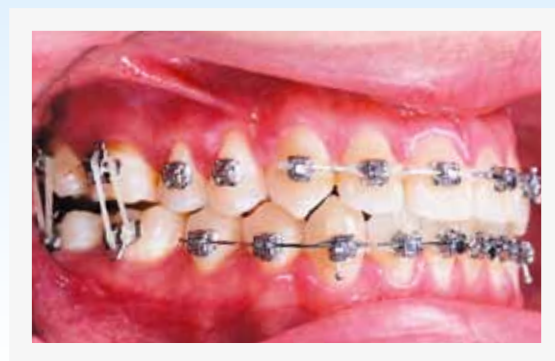The overall results were pleasing to both the clinician and the patient. Facial harmony and lower lip protrusion were improved (Fig. 6). Post-treatment intraoral photographs (Fig. 7) and study casts show a slight Class II buccal interdigitation bilaterally. Dental midlines were aligned with the facial midline, and ideal overjet and overbite were achieved.

Cephalometric analysis and super-impositions (Fig. 19) showed maximal retraction of whole



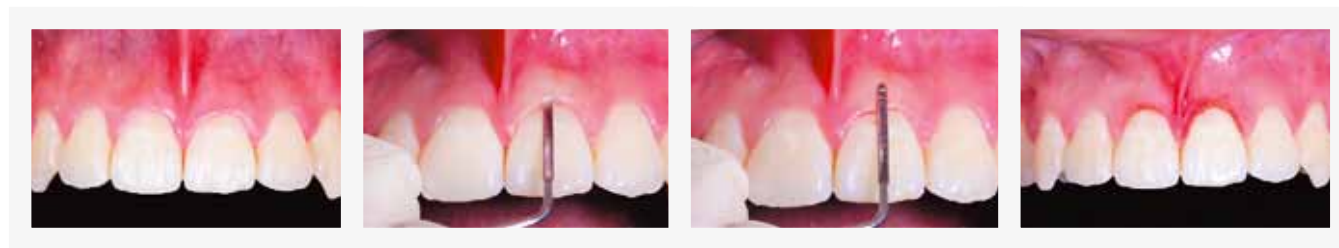
■ Fig 14.

X-elastic from maxillary 1st molars and Class II elastics from maxillary canines to buccal shelf screws were introduced to correct posterior lingual X-bite and for smile arc enhancement.



■ Fig 15.

Finishing elastics. Upper and lower arch-wires were sectioned with posterior vertical elastics (3.5 oz, 1/8") to settle posterior occlusion.



■ Fig 16.

Gingivoplasty was performed for better crown length-to-width proportion. Probing depth revealed 3mm in depth from gingival margin to CEJ. And the CEJ is equal to bone level. And thus indicated delayed apical migration of central incisor gingivae.

mandibular dentition with counterclockwise rotation of mandibular occlusal plane, and a slight opening of the mandibular plane angle. The upper incisor to the SN angle increased from 114° to 115°. The lower incisor to the Md plane angle was decreased from 94° to 90°. The change of profile and inclination of maxillary and mandibular incisors were demonstrated in progress cephalograms (Fig. 20). Critical assessment of this case with the IBOI cast-radiograph method and IBOI Pink & White score resulted in score of 37 and 7, as documented on the form appearing later in this report. CRE score exceeds the usual limit of 26 for an acceptable board case. The following deviations from ideal (*from CRE and Pink & White score*) were noted:

1. Bilateral maxillary 2nd premolars exhibited minor mesial-in rotation.
2. Maxillary left and bilateral mandibular 2nd molars exhibited minor distal-in rotation.
3. Marginal ridge discrepancies existed between #2-3, #3-4, #13-14, #14-15, #18-19, #19-20, #29-30 and #30-31.
4. Lack of occlusal contacts was noted bilaterally on disto-buccal cusps of maxillary and mandibular 2nd molars and palatal cusps of maxillary 2nd premolars.
5. A slight Class II canine relationship was noted bilaterally.
6. Inadequate root parallelism existed between #20-#21, and #30-#31.

7. Uneven level of gingival margin, inadequate axial inclination: #7 and #8, Shorten crown length : #8 and #9, Uneven incisor curve

DISCUSSION

Conservative treatment of a Class III skeletal malocclusion, with marked negative overjet by a non-surgical approach, has long been challenging to orthodontists. The strategy to camouflage a Class III malocclusion usually involves proclination of the maxillary incisors and retroclination of the mandibular incisors to improve the dental occlusion, but that approach may not correct the underlying skeletal problem or facial profile. Clinical studies have shown an increase in the ANB angle, little or no change in the vertical dimension, and decreased concavity of the facial profile with Class III camouflage treatment.¹⁻⁵ However, little information is available in the literature regarding the possible tooth movements to camouflage this type of skeletal malocclusion. In most non-surgical Class III treatment, retraction of the lower incisors is helpful. McLaughlin and Bennet⁶ advise to not retract beyond 80° because of the risk of dehiscence and lack of bone support. Retraction of the lower incisors and Class I molar relationship can be obtained with the assistance of Class III elastics and/or with bone anchorage screws. With bone screw anchorage, the dental discrepancy can often be effectively treated within the limits of skeletal camouflage. And also, compared to Class III elastics, utilization of bony anchorage can avoid the proclination of upper incisors, which contributes to more acute naso-labial angle. In the present case, maximal retraction of whole mandibular dentition was attained with bilateral bone screws, inserted into the mandibular buccal shelves, without adverse effect of his naso-labial angle.

The major limitation of how much one can retract

the entire mandibular dentition is the distance between mandibular 2nd molar and the ascending ramus (Fig. 17). However, little information is available relative to this problem. In the present case, the patient presented with a right mandibular 3rd molar that is inclined mesially. This relationship equates to a distance of at least 10.5 mm⁷ between the mandibular 2nd molar and the ascending ramus. Thus, it is possible to correct the current malocclusion because the negative overjet after 9-months decompensation was 8 mm. In summary, the indications of correcting skeletal Class III malocclusion by retraction of the entire mandibular arch with bony anchorage are :

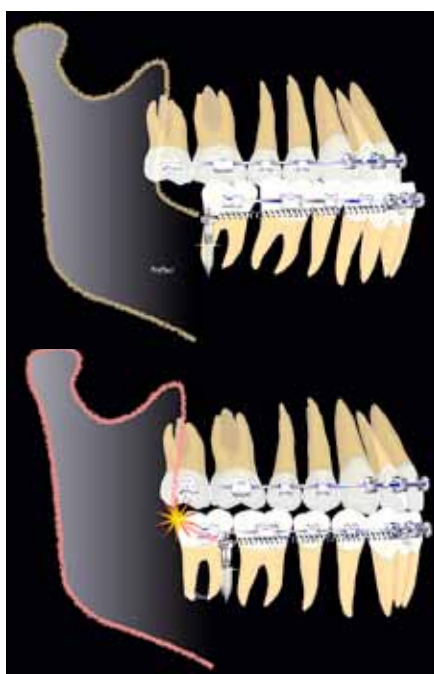
1. good profile, 2. normal A-P position of maxilla, 3. maxillary incisor to nasion-sella line⁸ within 120°, 4. slightly acute naso-labial angle, 5. negative overjet after decompensation of mandibular incisors within 11 mm (*average M-D width of mandibular 1st molar*).

Another concern in treating Class III open bite cases is smile arc enhancement. Class III open bite cases usually have a flat occlusal plane and smile arc. When correcting this kind of malocclusion with long Class III elastics, extrusion of both maxillary molars and mandibular incisors, as well as flaring of maxillary incisors, contributes to counterclockwise rotation of the functional occlusal plane and flattening of smile arc. In the present case, Class III elastics were not utilized to correct the malocclusion, but the treatment still resulted in a flattened smile arc. Retracting the entire mandibular dentition with screws in the buccal shelf results in extrusion of mandibular incisors and tip-back of molars (Fig. 18).^{9, 10, 11} The flexibility of the arch-wire is directly proportional to the degree of distal tipping experience by the terminal molar in the arch. From a biomechanical aspect, retraction of the entire mandibular dentition with buccal shelf anchorage

contributes to the correction of an open bite, but these mechanics do not enhance the smile arc. In this present case, Class II elastics were introduced after the anterior X-bite has been corrected, but it is difficult to extrude maxillary incisors when there is no open bite. Distally tipped 2nd molars contributed to the relatively high score of 37 using the IBOI cast-radiograph method due to poor axial inclination, marginal ridge discrepancies, and lack of intermaxillary tooth contacts. In the 20th month of treatment, diagnostic casts were obtained to plan another 4-6 months for final detailing. Unfortunately, this patient is an overseas Chinese student from Malaysia and he was required to return to his home country because he was unable to obtain a work

visa. Thus, it was necessary for him to return every other week for adjustments during the latter active treatment phase and he was debonded the day before he left Taiwan. Although this case may not be adequate for board certification purposes, both the patient and clinician were satisfied with the final result.

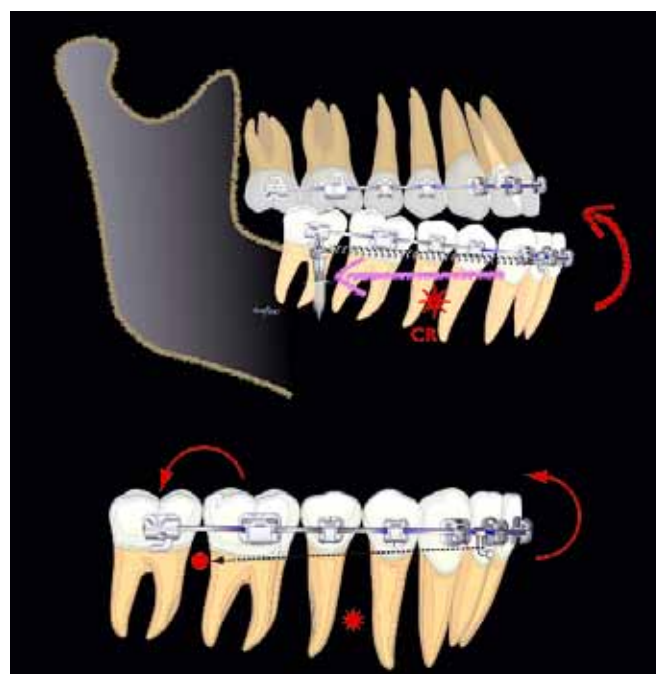
It should be noted that the mandibular arch alignment was similar to the Tweed philosophy of orthodontics finishing. In the denture completion stage of Tweed-Merrifield philosophy,¹² the distal cusps of the 1st and the 2nd molars should be slightly out of occlusion. If the canines and premolars are treated to solid Class I occlusion, the ideal occlusion



■ Fig 17.

The limitation of whole mandibular dentition retraction is the initial molar relationship in related to distance between 2nd molar and ascending ramus.

(Illustration of Dr. Rungsi Thavarungkul)



■ Fig 18.

Retracting whole mandibular dentition with bony anchorage will extrude mandibular incisors and tip the molar back .

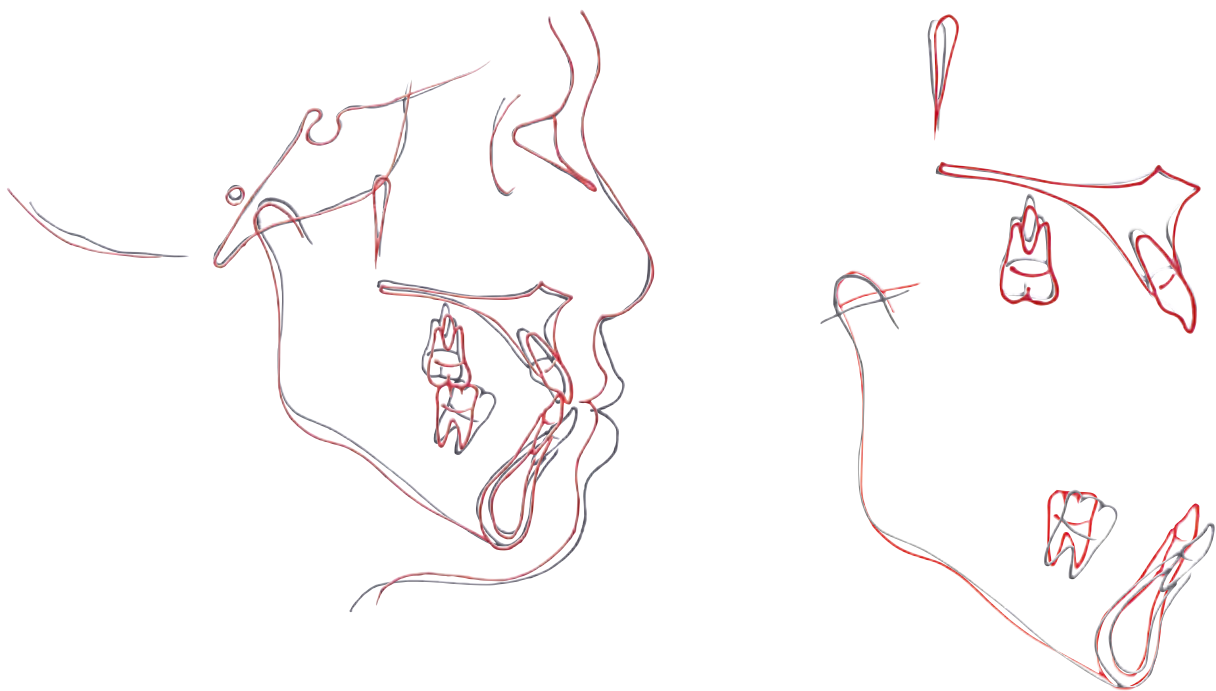
(Illustration of Dr. Rungsi Thavarungkul)

will occur after all treatment mechanics discontinued and uninhibited function and other environmental influences active in the post-treatment period will stabilize and finalize the position of the occlusion. This approach is deemed the “*denture recovery*” stage.¹² If this philosophy can be applied to this Class III non-extraction case, the axial inclination of the 2nd molars will recover because ideal overjet, overbite and buccal interdigitation were achieved. However, to avoid distally tipped mandibular molars, it would be better to retract the mandibular dentition with a stiffer archwire like .016x.025 SS to help prevent rotation of the occlusal plane and the tip back of molars. It would have been helpful to have progress panoramic radiographs to recognize the early stages

of distally tipping. In conclusion, significant dental and soft-tissue improvement can be expected in young adult Class III patients treated with camouflage orthodontic tooth movement. A wide range of skeletal dysplasias can be camouflaged with tooth movement, without deleterious effects to the periodontium. However, proper diagnosis, realistic treatment objectives, and efficient mechanics are necessary to prevent undesirable sequelae.¹³

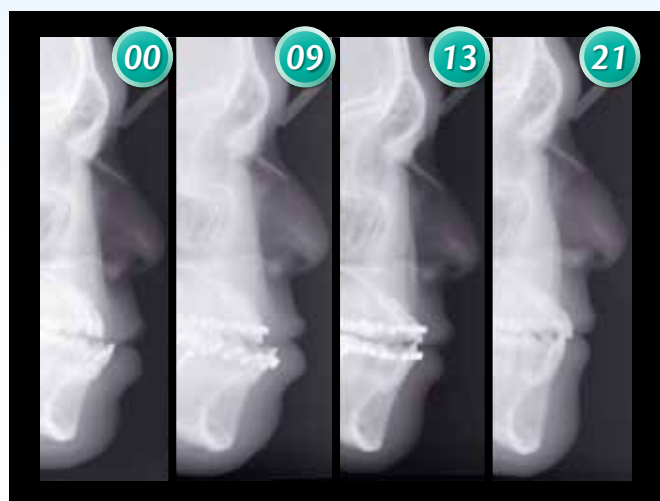
ACKNOWLEDGEMENT

Thanks to Ms. Tzu Han Huang for proofreading this article.



■ Fig 19.

Superimposed tracings. Superimposition on mandible revealed maximal retraction of anterior teeth and extrusion of molars. These contributed to correction of anterior cross-bite and vertical dimension opening.



■ Fig 20.

Progress cephalograms revealed that the anterior X-bite was corrected in 13th month of treatment.

CEPHALOMETRIC

SKELETAL ANALYSIS

	PRE-TX	POST-TX	DIFF.
SNA°	85°	86°	1°
SNB°	83.5°	84°	0.5°
ANB°	1.5°	2°	0.5°
SN-MP°	36°	36°	0°
FMA°	33°	32°	-1°

DENTAL ANALYSIS

U1 TO NA mm	4.5 mm	4.0 mm	-0.5 mm
U1 TO SN°	114°	115°	1°
L1 TO NB mm	12 mm	5.0 mm	-7.0 mm
L1 TO MP°	94°	90°	-4°

FACIAL ANALYSIS

E-LINE(U)	0.5 mm	-2.0 mm	-2.5 mm
E-LINE(L)	3.5 mm	-1.0 mm	-4.5 mm

■ Table . Cephalometric summary

REFERENCES

1. Ngan P. Treatment of Class III malocclusion in the primary and mixed dentitions. In: Bishara SE, editor. Textbook of orthodontics. Philadelphia: W. B. Saunders; 2001. p. 375-6.
2. Costa Pinho T, Torrent J, Pinto J. Orthodontic camouflage in the case of a skeletal Class III malocclusion. World J Orthod 2004; 5:213-23.
3. Lin J, Gu Y. Preliminary investigation of nonsurgical treatment of severe skeletal Class III malocclusion in the permanent dentition. Angle Orthod 2003; 73:401-10.
4. Chang HF, Chen KC, Nanda R. Two-stage treatment of a severe skeletal Class III deep bite malocclusion. Am J Orthod Dentofacial Orthop 1997; 111:481-6.
5. Huang CC. Non-extraction management of skeletal Class III malocclusion with facial asymmetry. News & Trends in Orthodontics 2010; 20:22-3.
6. Bennett J, McLaughlin RP, Trevisi HJ. Systemized orthodontic treatment mechanics. Mosby Inc. London. 2001.
7. Ash MM Jr. Mandibular second molar. In: Ash MM Jr, editor. Wheeler's dental anatomy, physiology and occlusion. 7th ed. Philadelphia: W. B. Saunders; 1993. p. 291-9.
8. Nikia RB et al. , Class III camouflage treatment : what are the limits? Am J Orthod Dentofacial Orthop 2010; 137:9. e1-9. e13
9. Jung MH, Kim TW. Biomechanical Considerations in Treatment with Miniscrew Anchorage. Part 1 The Sagittal Plane. J Clin Orthod. 2008 Feb;42(2):79-83.
10. Nakamura A, Teratani T, Itoh H, Sugawara J, Ishikawa H. Photoelastic Stress Analysis of Mandibular Molars Moved Distally with the Skeletal Anchorage System. Am J Orthod Dentofacial Orthop. 2007; 132:624-9.
11. Lin JJ. Creative Orthodontics : Blending the Damon System & TADs to manage difficult malocclusions. 2nd edition. 2010, Yong Chieh Enterprise Co. , Ltd. , Taiwan
12. Graber T. M. Orthodontics : Current Principles and Techniques. 4th Edition. Chap. 16 The Tween-Merrifield Edgewise Appliance : Philosophy, Diagnosis, and Treatment. 2007, Mosby, Inc, Missouri
13. Chang CH. Finishing Course No. 28 : Tough High Angle. Beethoven Podcast Encyclopedia in Orthodontics 2011, Newton's A Ltd, Taiwan

IBOI Discrepancy Index Worksheet

TOTAL D.I. SCORE 71

OVERJET

0 mm. (edge-to-edge) =
 1 – 3 mm. = 0 pts.
 3.1 – 5 mm. = 2 pts.
 5.1 – 7 mm. = 3 pts.
 7.1 – 9 mm. = 4 pts.
 > 9 mm. = 5 pts.

Negative OJ (x-bite) 1 pt. per mm. per tooth =

Total = 34

OVERBITE

0 – 3 mm. = 0 pts.
 3.1 – 5 mm. = 2 pts.
 5.1 – 7 mm. = 3 pts.
 Impinging (100%) = 5 pts.

Total = 0

ANTERIOR OPEN BITE

0 mm. (edge-to-edge), 1 pt. per tooth
 then 1 pt. per additional full mm. per tooth

Total = 16

LATERAL OPEN BITE

2 pts. per mm. per tooth

Total = 0

CROWDING (only one arch)

1 – 3 mm. = 1 pt.
 3.1 – 5 mm. = 2 pts.
 5.1 – 7 mm. = 4 pts.
 > 7 mm. = 7 pts.

Total = 2

OCCLUSION

Class I to end on = 0 pts.
 End on Class II or III = 2 pts. per side 8 pts.
 Full Class II or III = 4 pts. per side 8 pts.
 Beyond Class II or III = 1 pt. per mm. 8 pts.
 additional

Total = 8

LINGUAL POSTERIOR X-BITE

1 pt. per tooth Total = 7

BUCCAL POSTERIOR X-BITE

2 pts. per tooth Total = 0

CEPHALOMETRICS (See Instructions)

ANB $\geq 6^\circ$ or $\leq -2^\circ$ = 4 pts.

Each degree $< -2^\circ$ x 1 pt. = x 1 pt.

Each degree $> 6^\circ$ x 1 pt. = x 1 pt.

SN-MP

$\geq 38^\circ$ = 2 pts.

Each degree $> 38^\circ$ x 2 pts. = x 2 pts.

$\leq 26^\circ$ = 1 pt.

Each degree $< 26^\circ$ x 1 pt. = x 1 pt.

1 to MP $\geq 99^\circ$ = 1 pt.

Each degree $> 99^\circ$ x 1 pt. = x 1 pt.

Total = 0

OTHER (See Instructions)

Supernumerary teeth x 1 pt. = x 1 pt.
 Ankylosis of perm. teeth x 2 pts. = x 2 pts.
 Anomalous morphology x 2 pts. = x 2 pts.
 Impaction (except 3rd molars) x 2 pts. = x 2 pts.
 Midline discrepancy (≥ 3 mm) @ 2 pts. = @ 2 pts.
 Missing teeth (except 3rd molars) x 1 pt. = x 1 pt.
 Missing teeth, congenital x 2 pts. = x 2 pts.
 Spacing (4 or more, per arch) x 2 pts. = x 2 pts.
 Spacing (Mx cent. diastema ≥ 2 mm) @ 2 pts. = @ 2 pts.
 Tooth transposition x 2 pts. = x 2 pts.
 Skeletal asymmetry (nonsurgical tx) @ 3 pts. = @ 3 pts.
 Addl. treatment complexities 2 x 2 pts. = 4

Identify:

Total = 0

IMPLANT SITE

Lip line : Low (0 pt), Medium (1 pt), High (2 pts) = x 2 pts.
 Gingival biotype : Low-scalloped, thick (0 pt), Medium-scalloped, medium-thick (1 pt), High-scalloped, thin (2 pts) = x 2 pts.
 Shape of tooth crowns : Rectangular (0 pt), Triangular (2 pts) = x 2 pts.
 Bone level at adjacent teeth : ≤ 5 mm to contact point (0 pt), 5.5 to 6.5 mm to contact point (1 pt), ≥ 7 mm to contact point (2 pts) = x 2 pts.
 Bone anatomy of alveolar crest : H&V sufficient (0 pt), Deficient H, allow simultaneous augment (1 pt), Deficient H, require prior grafting (2 pts), Deficient V or Both H&V (3 pts) = x 2 pts.
 Soft tissue anatomy : Intact (0 pt), Defective (2 pts) = x 2 pts.
 Infection at implant site : None (0 pt), Chronic (1 pt), Acute (2 pts) = x 2 pts.

Total = 0

IBOI Cast-Radiograph Evaluation

Case #

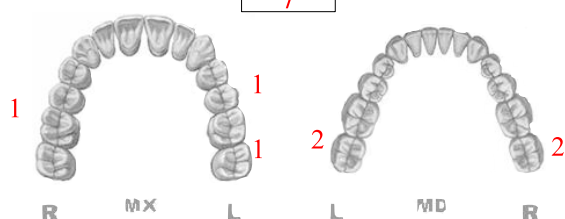
Patient

Total Score:

37

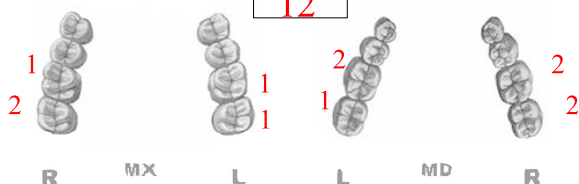
Alignment/Rotations

7



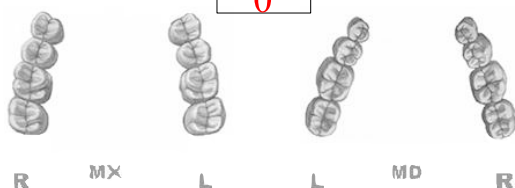
Marginal Ridges

12



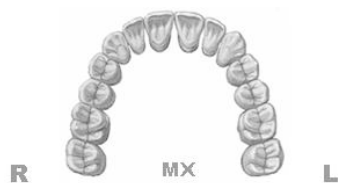
Buccolingual Inclination

0



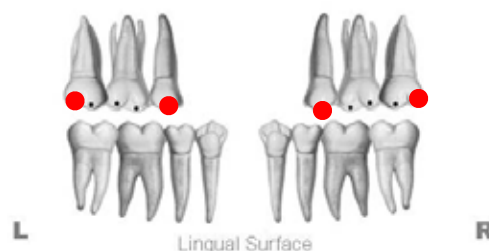
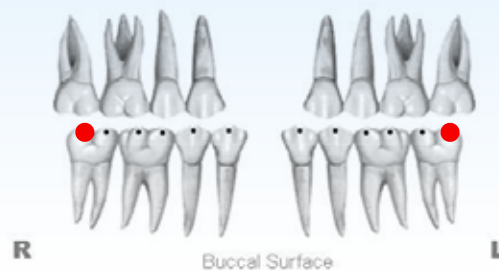
Overjet

0



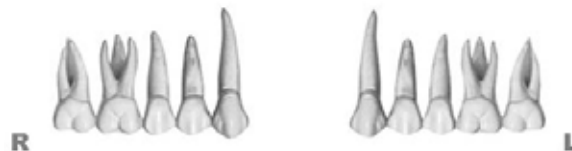Occlusal Contacts

12



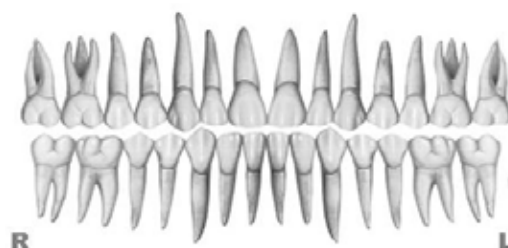
Occlusal Relationships

4



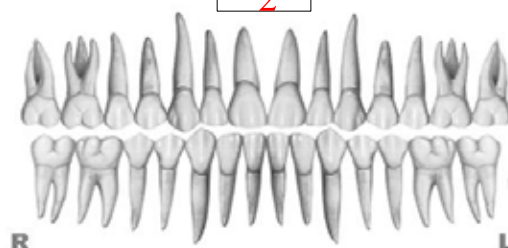
Interproximal Contacts

0



Root Angulation

2

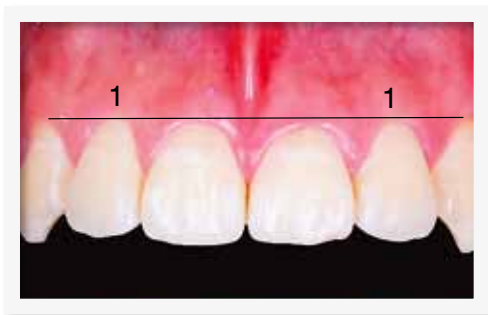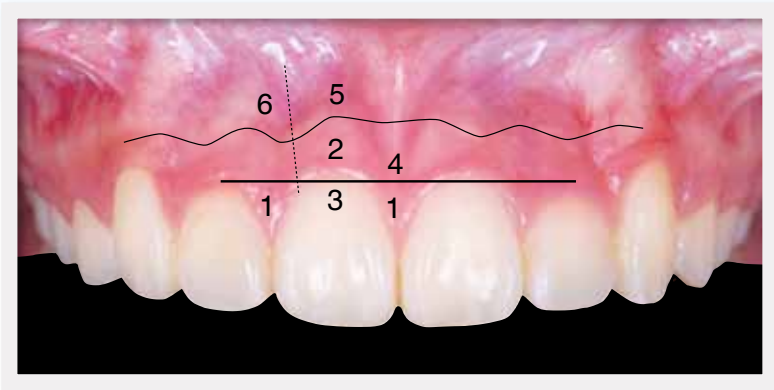


INSTRUCTIONS: Place score beside each deficient tooth and enter total score for each parameter in the white box. Mark extracted teeth with "X". Second molars should be in occlusion.

IBOI Pink & White Esthetic Score

Total Score: = 7

1. Pink Esthetic Score

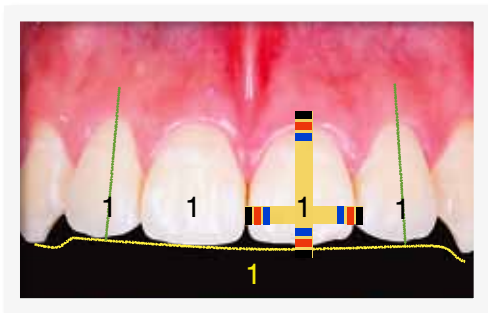
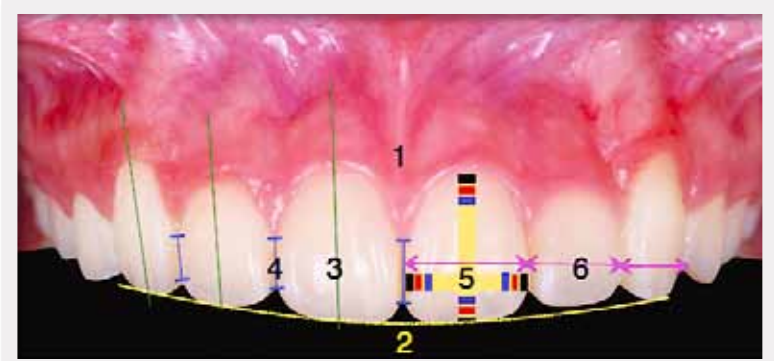


Total = 2

1. M & D Papilla	0	1	2
2. Keratinized Gingiva	0	1	2
3. Curvature of Gingival Margin	0	1	2
4. Level of Gingival Margin	0	1	2
5. Root Convexity (Torque)	0	1	2
6. Scar Formation	0	1	2

1. M & D Papilla	0	1	2
2. Keratinized Gingiva	0	1	2
3. Curvature of Gingival Margin	0	1	2
4. Level of Gingival Margin	0	1	2
5. Root Convexity (Torque)	0	1	2
6. Scar Formation	0	1	2

2. White Esthetic Score (for Micro-esthetics)



Total = 5

1. Midline	0	1	2
2. Incisor Curve	0	1	2
3. Axial Inclination (5°, 8°, 10°)	0	1	2
4. Contact Area (50%, 40%, 30%)	0	1	2
5. Tooth Proportion (1 : 0.8)	0	1	2
6. Tooth to Tooth Proportion	0	1	2

1. Midline	0	1	2
2. Incisor Curve	0	1	2
3. Axial Inclination (5°, 8°, 10°)	0	1	2
4. Contact Area (50%, 40%, 30%)	0	1	2
5. Tooth Proportion (1 : 0.8)	0	1	2
6. Tooth to Tooth Proportion	0	1	2

Step-by-Step on the Open-Window Technique for Upper Palatal Impaction

Beethoven Orthodontic Center



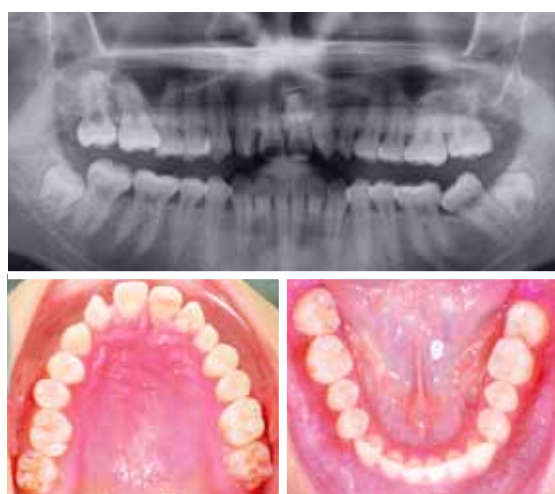Chris H.N. Chang, DDS, Ph.D.
Director,
Beethoven Orthodontic Center

INTRODUCTION

Open window technique is a commonly used surgical option to treat palatally impacted teeth. This article aims to provide step-by-step illustrations on the surgical procedures so doctors can use them as a checklist before approaching this type of cases.

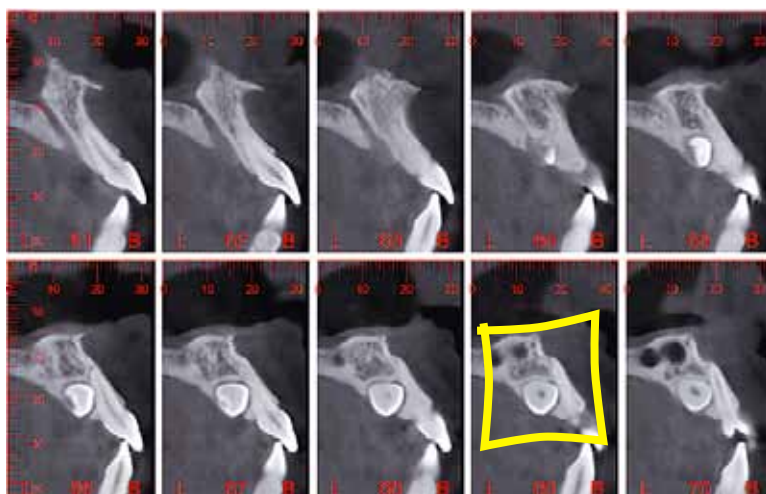
CASE STUDY

An 18-year 2 month old female came for consultation. The panorex film showed an upper impacted canine on the left side and a deciduous canine remaining (Fig. 1). CT scan (*slice view*) indicates that the impaction's crown was on the palatal side of the left central incisor (Fig. 2). This information was used for selecting an appropriate surgical technique. The drawing of the impaction marks the approximate position (Fig. 3). Detailed surgical procedures of this surgery are discussed at below.



■ Fig 1.

Pretreatment pano radiograph & intraoral photographs.



■ Fig 2.

Pretreatment CT image. Slice #69 reveals that the crown of the canine is covered only with soft tissue, no bone on the top of crown.

Dr. Hsin Yin Yeh, Lecturer,
Beethoven Orthodontic Course



SURGERY PROCESS

First, local anesthesia was applied in the surgical site and an explorer was used to mark the location of the crown (Fig. 4). The sensation, when an explorer is in touch with teeth or bone, is different. When an explorer touches teeth, one will feel it is in contact with a smooth surface whereas when contacting bone, one will feel a rough surface.

Second, use a #15 blade to make a cross incision (Fig. 5).

The cross incision divides the surgical site into four quadrants.

Third, use a periosteum elevator to raise the flap (Fig. 6) to have visual access to the crown.

Fourth, use an explorer to confirm the outline of the crown. (Fig. 7). Although the CT image can provide rich diagnostic information on the location of the impaction, its depth from the soft tissue remains to be probed clinically.

Fifth, remove the soft tissue covering the impaction's crown with an electric knife (Fig. 8). In this step, there will be blood oozing that prevents good visual access to the surgical field. A high power suction and an electric knife that facilitates coagulation are helpful tools.

Sixth, use an explorer in a up-down motion to detect the depth and the margin of the covering bone (Fig. 9).

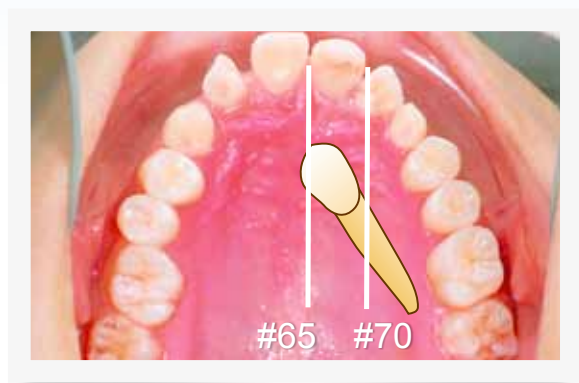


Fig 3.
The drawing of the impaction marks the approximate position

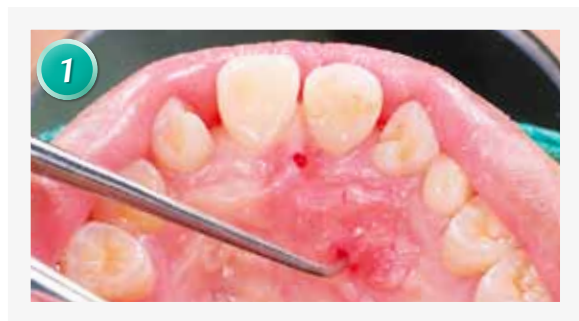

Fig 4.
After applying local anesthesia, use an explorer to mark the crown.

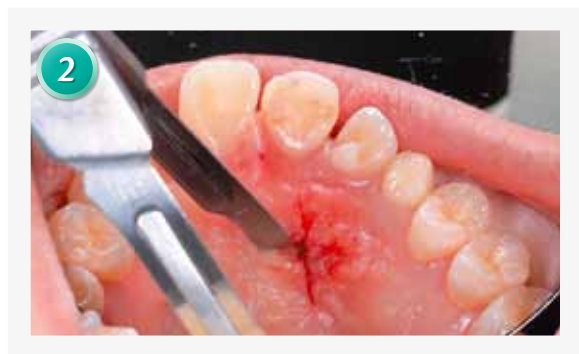

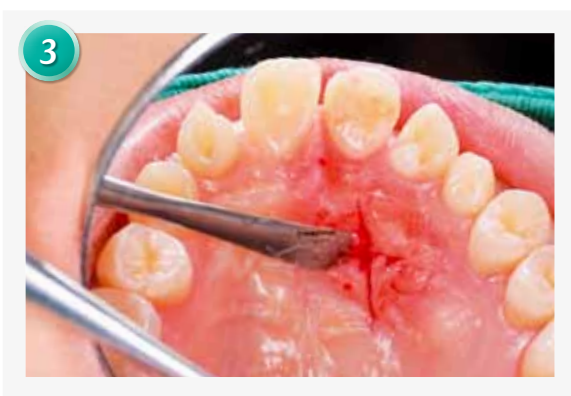
Fig 5.
Use a #15 blade to make a cross incision.

Seventh, remove the covering bone with a high speed handpiece and carbide round burs (Fig. 10). It is sometimes unavoidable to damage the incisive nerve during the surgery when it is near the impaction (Fig. 11). Fortunately, only a minority of patients notice and complain of a temporary loss of sensitivity in the medial anterior part of the palate.

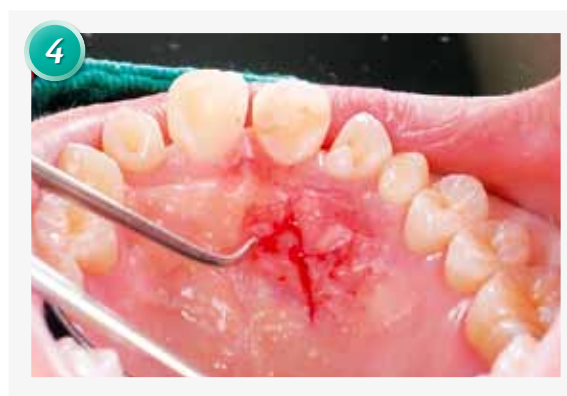Eighth, control bleeding with an electric knife and irrigation with normal saline (Fig. 12).

Ninth, cover the wound with COE-PAK, and use wet gauzes pressing on COE-PAK to adapt it closely to the wound while squeezing blood out. This way it

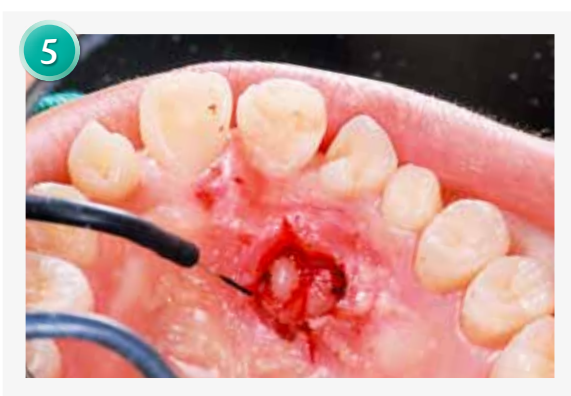can be packed into the interdental space so it will be caught between the undercut. Before applying COE-PAK, spread some vaseline on the gloves as a coating to make them stick proof (Fig. 13, 14). COE-PAK can help stop bleeding and cover the wound. This way patients will feel more comfortable. Most importantly, it will delay soft tissue healing and prevent it from covering the impaction again. On average the epithelium grows at the rate of 1 mm per day, much faster than autoeruption of the impaction. Remove COE-PAK three days after the surgery and monitor the emergence of the impaction (Fig. 15).



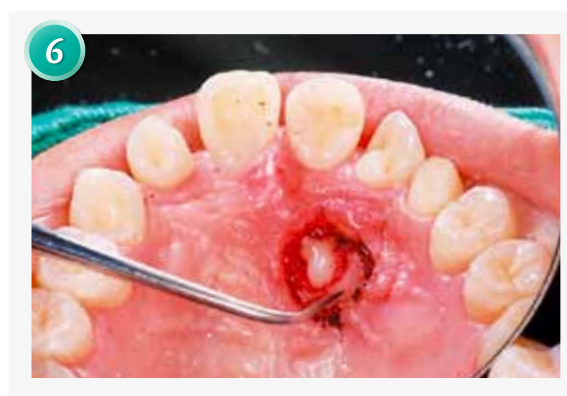■ Fig. 6.
Use a periosteum elevator to raise the flap.



■ Fig. 7.
Use an explorer to confirm the outline of the crown.



■ Fig. 8.
Remove the soft tissue covering the impaction with an electric knife.



■ Fig. 9.
Detect the depth and the margin of the covering bone.

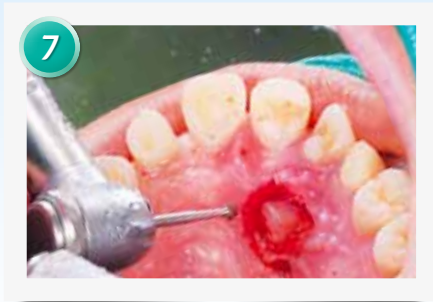


Fig. 10.
Remove the covering bone with a high speed handpiece and carbide round burs.

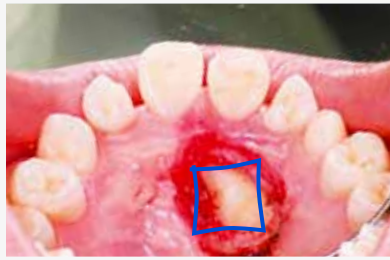

Fig. 11.
The incisive nerve suffers some damage during the surgery due to its proximity to the impaction.

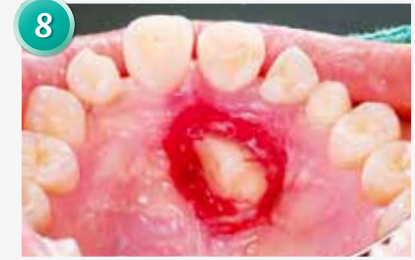

Fig. 12.
Control bleeding with an electric knife.

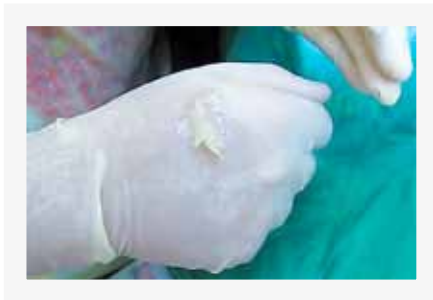

Fig. 13.
Spread vaseline on the gloves as a coating to make them stick proof.

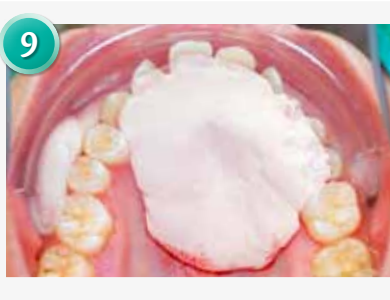

Fig. 14.
Cover the wound with COE-PAK and pack it into the interdental space so it will be caught between the undercut.

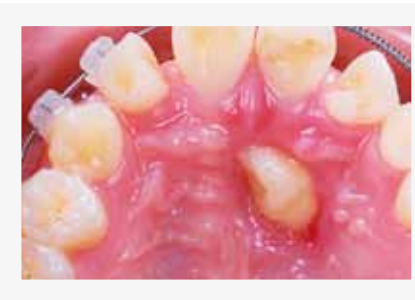

Fig. 15.
One month after the surgery.

CONCLUSIONS

In conclusion, this article attempts to standardize the surgery process of open exposure in order to help palatally impacted maxillary canines to auto-erupt. Furthermore, this standardized process will support research evidence documenting about palatally impacted maxillary canines .

REFERENCES

1. Kokich VG. Surgical and orthodontic management of impacted maxillary canine. Am J Orthod Dentofacial Orthop 2004;126:278-83.
2. Hsu YL, Chang CH, Roberts WE. Ortho Bone Screw. The dream screw for next generation's orthodontists. News & Trends in orthodontics. 2011;23:34-49
3. Su CW, Hsu YL, Chang CH. 阻生齒的軟組織處理面面觀. News & Trends in orthodontics. 2011;22:54-59
4. Tseng SP, Chang CH, Roberts WE. Palatally Impacted Maxillary Canine. News & Trends in orthodontics. 2011;21:26-36
5. E. H. Huizing, J. A. M. de Groot. Functional Reconstructive Nasal Surgery. 2003;25



當修復變成一門藝術，而補綴早已昇華成美學，
牙科被時尚風暴席捲，診間滿溢著華貴氣息！

1

Premisa

奈米三級聚合樹脂 / unidose(4g) 5組

OptiBond All-In-One

光照含氣全效型三合一黏著劑 / 1組

適用一般牙科

YMA 本專案消費可得 1 枚 VISA 贈券

特價 NTS 10,000 (定價 NTS 13,700)



2

Herculite Precis

超手感奈米變色龍樹脂 / unidose(2g) 10組

OptiBond All-In-One

光照含氣全效型三合一黏著劑 / 1組

適用一般牙科

YMA 本專案消費可得 1 枚 VISA 贈券

特價 NTS 10,000 (定價 NTS 13,700)



3

Volume Mixer

全自動印模調合機 / 1台

AlgiNOT

超快速多能(VPS)印模材 / Volume-6箱(36's)

適用印模

YMA 本專案消費可得 6 枚 VISA 贈券

特價 NTS 72,000 (定價 NTS 127,000)



完美的笑容就像在法國墜入愛河一樣輕易，選對矯正器讓你不必虛擲光陰，
人生理應揮霍在更值得的事物上，C'est La Vie!

8

Damon Clear U3-3

戴蒙透明矯正器 / 200顆

Copper Ni-Ti Archwire

超感溫性鎳鈦合金線 / 1盒(10's)

Low-Friction Color TMA Archwire

低摩擦力鈦鎳合金成型線 / 1盒(10's)

適用齒槽矯正治療

YMA 本專案消費可得 8 枚 VISA 贈券

特價 NTS 60,000 (定價 NTS 168,200)



11

Mini Diamond

迷你型金屬矯正器 / 10人份

Copper Ni-Ti Archwire

超感溫性鎳鈦合金線 / 1盒(10's)

TMA Archwire

鈦鎳合金線 / 1盒(10's)

Ti-NB Finishing Archwire

矯正完成期鈦鎳合金線 / 1盒(10's)

Ni-Ti Coil Spring

鎳鈦合金彈簧管 / 1管

適用齒槽矯正治療

YMA 本專案消費可得 3 枚 VISA 贈券

特價 NTS 12,000 (定價 NTS 45,600)

12

Damon Q

迷你舒適型戴蒙快速矯正器 / 10人份

SDC Starter kit (ProStrip)

矯正專用貼面型系統入門組 / 1組

適用齒槽矯正治療

YMA 本專案消費可得 12 枚 VISA 贈券

特價 NTS 60,000 (定價 NTS 188,000)



9

Damon Clear U3-3

戴蒙透明矯正器 / 200顆

Damon Clear Opening Tool

戴蒙透明矯正器專用器械 / 1支

Enlight Sample Kit

光照含氣矯正專用黏著組 / 1組

適用齒槽矯正治療

YMA 本專案消費可得 8 枚 VISA 贈券

特價 NTS 60,000 (定價 NTS 168,800)



10

Damon Clear U3-3

戴蒙透明矯正器 / 200顆

Bite Turbo

咬合專用矯正裝置 / 1盒

Power Chain

矯正專用彈力鏈 / 1卷

Zoo Elastic

黏物圈 / 1盒

適用齒槽矯正治療

YMA 本專案消費可得 8 枚 VISA 贈券

特價 NTS 60,000 (定價 NTS 168,800)



4 EWT Pulp Canal Sealer

長效型氧化鋅根管充填劑 / 1組

Gutta Percha

馬來膠針 / 任選4盒

System B

可調溫式馬來膠針熱熔機 / 1台

適用根管充填

本專案消費可得4枚VISA戳章

折抵NT\$20,000 (定價NT\$68,400)



6 Element Obturation

元素系列 多功能二合一快速根管充填機 / 1台

Buchanan Heat

Pluggers 1~5

導熱式針頭 / 1組(5's)

Gutta Percha

馬來膠針 / Cartridge 1盒

適用根管充填

本專案消費可得5枚VISA戳章

折抵NT\$80,000 (定價NT\$168,800)



5 Sealapex

氫氧化鈣根管充填劑 / 1組

Gutta Percha

馬來膠針 / 任選3盒

Touch'n Heat

馬來膠針熱熔機 / 1台

適用根管充填

本專案消費可得2枚VISA戳章

折抵NT\$10,000 (定價NT\$34,200)



7 Buchanan Hand

Pluggers 0~2

線鉤合金手動填壓器械 / 1組(3's)

Gutta Percha

馬來膠針 / 任選3盒

EWT Pulp Canal Sealer

長效型氧化鋅根管充填劑 / 1組

適用根管充填

本專案消費可得1枚VISA戳章

折抵NT\$5,000 (定價NT\$19,000)



FLY ME TO THE LUXURY DREAM

湧傑夢想旅程 啟航飛行

護照第4季VIP限定 **巴黎奢華之旅**

購物簽證集點，優惠自由運用！

消費即獲VISA戳章！靈活選擇現金折抵、贈品兌換，更可升級VIP！

驚喜連連，四季不間斷！

每季皆有神秘贈品，等你來兌換！

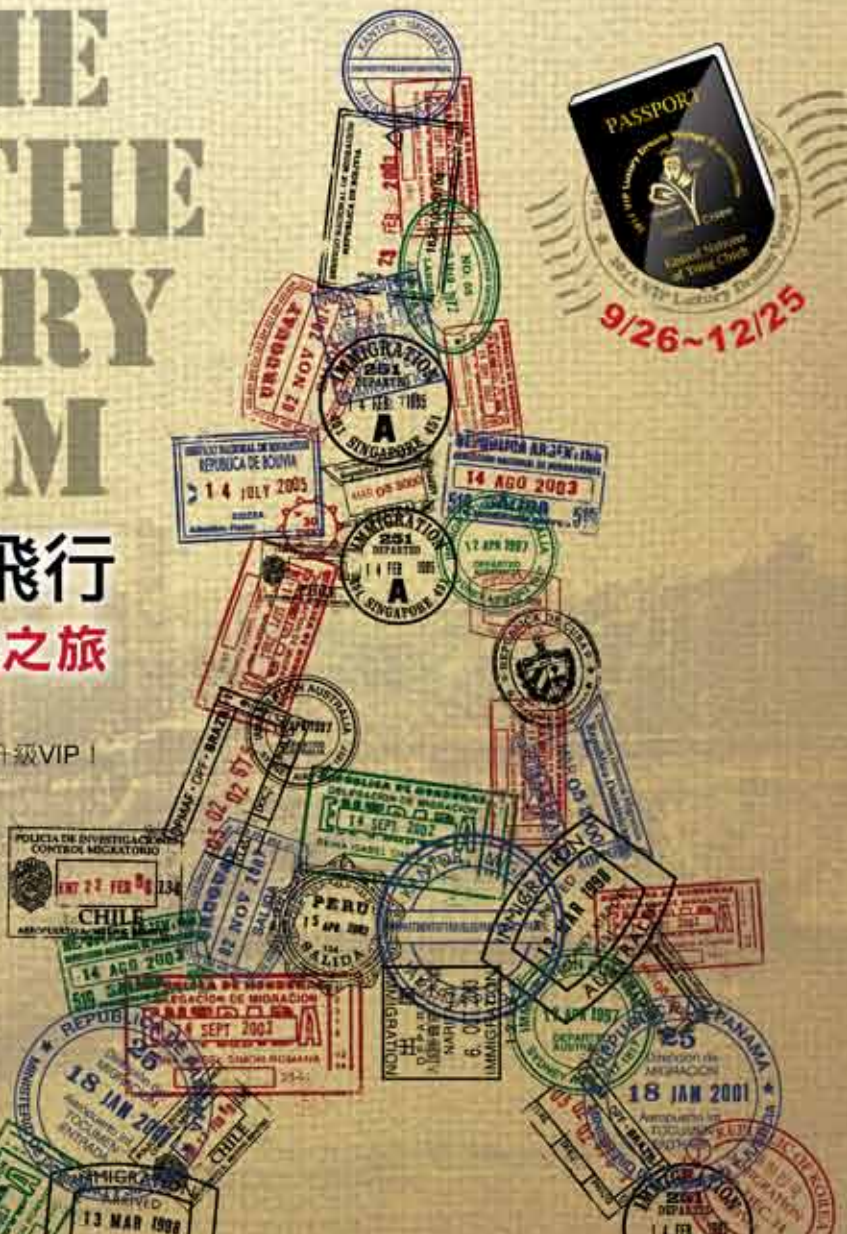2011全年度 湧傑奢華夢想旅程啟程

頂級VIP尊榮禮遇，隆重呈獻專屬禮品！

- 一、VIP享有本護照所有折扣優惠、贈品及VIP專屬禮品，2011整年度全商品定價8折，促銷商品再享95折。
- 二、VIP享有專屬預購，所有促銷案(不限本護照專案)皆可優先購物。
- 三、VIP專屬禮品將於每季初始憑VISA戳章數量兌換。

3張VIP：RIMOWA TOPAS 32"大行李箱

4張VIP：台北巴黎經濟艙來回機票一張



前牙美觀區使用具角度植體立即植牙立即負載之病例報告

Utility of Angled Implant for Immediate Replacement and Immediate Loading in Esthetic Zone- A Case Report

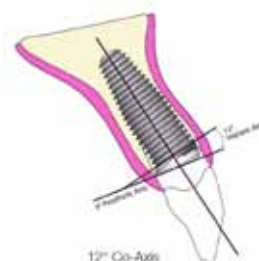
前言

臨床上對無牙區應用多根植體或單一植體支持復形物已經被證明是一項可預測的長期治療方式，立即植牙的操作方式也被證實是相當可靠的方式，而且不論是漸近式受力或立即負載，其成功率也相當高。然而現今植體在美觀區治療的目標不再只是植體骨整合成功，而在最終的結果上植體支持之復形物在口內呈現軟硬組織的和諧外觀。在單一植體治療上追求可預期的美觀結果，醫師在治療前需要考慮到所有影響結果的可能性。此外，手術必須精確執行。在軟組織的處理或植體置位有錯誤，不管軟組織或骨的量是否足夠，也許會導致美觀上的失敗。本案例使用特殊設計平台具有角度的植體，並指出操作時的要點，只要依循操作的原則，便可以更簡單地克服前牙區因為角度所造成的困擾，達到美觀上的需求並符合患者的期待。

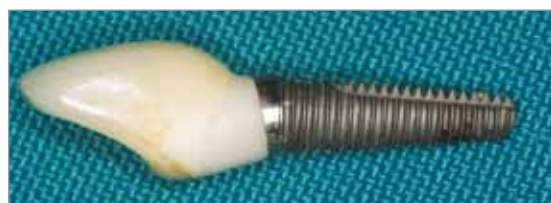材料與方法

平台具有角度的植體

本病例採用內接式 C°-Axis Angled Dental Implant (Southern Implants Inc., USA)，其植體平台具有 12° 的特殊設計，內接部份為三葉設計，因前牙區自然牙牙冠頰側面與牙齒中軸間平均約呈 10°-12° 的角度，所以植體平台以 12° 的特殊設計，可以較容易製作出假牙美觀的自然外展外形，更可以避免假牙頰側過度外展而在植體平台與假牙接合處對軟組織形成根尖向的壓力，進而因過度擠壓而導致軟組織萎縮，形成美觀上的失敗。



■ 植體平台具有 12° 的特殊設計



■ 傳統直筒狀植體（左圖）與具角度植體（右圖）的比較：傳統植體的牙冠頰側必須明顯外展才能達成外形上的需求

患者基本資料

57 歲女性健康患者，無特殊牙科與內科病史。到院主訴為左上第一正中切齒斷裂，患者希望以人工植牙方式修復。

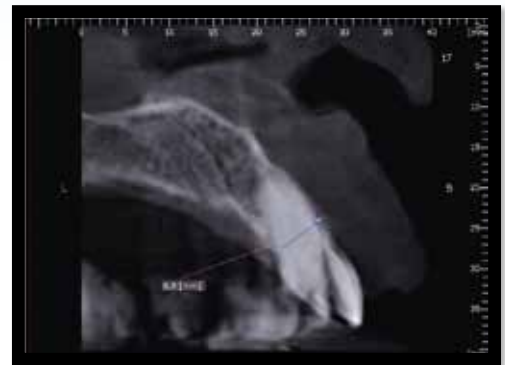文／歐亦焜

美國 UCLA 植牙碩士班結業 / 美國 NYU 植牙專科證書
中華民國臨床植牙醫學會理事 / 中華民國臨床植牙醫學會專科醫師
台灣植體學會專科醫師 / 陽明醫學院牙醫學院學士 / 群盛牙醫診所院長

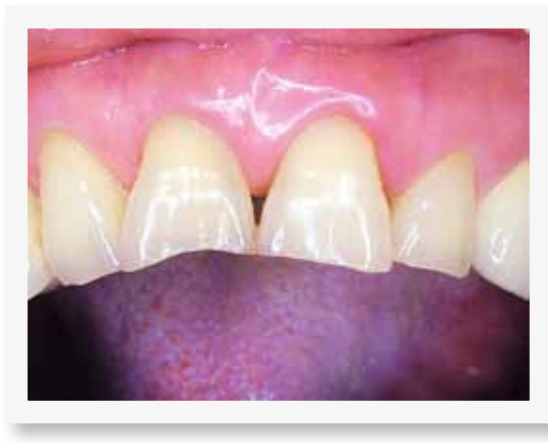

術前評估

- 硬組織的考量：牙根斷裂處並無急性發炎或痛管與化膿症狀，藉由電腦斷層掃描（CBCT）重組影像得知，患部並無骨缺損，頰側骨板厚度約 1 mm，根尖部份無病灶且有 3-4 mm 骨組織可提供植體初級穩定，因此決定以立即植牙的方式進行。
- 軟組織的考量：牙齦型態（gingival biotype）屬於厚型，角化上皮的量足夠，因此以立即植牙的方式可以預期美觀上的需求。



■ 電腦斷層掃描剖面影像：患部硬組織具有足夠的質與量

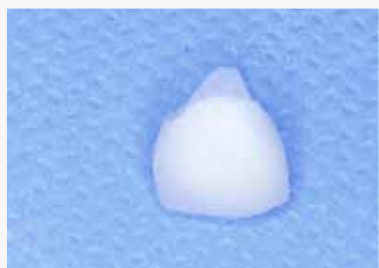

■ 口內臨床照片顯示軟組織的狀況

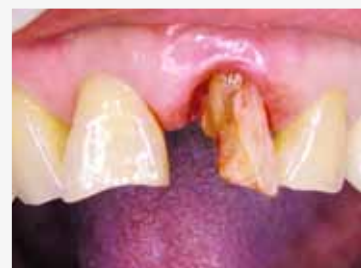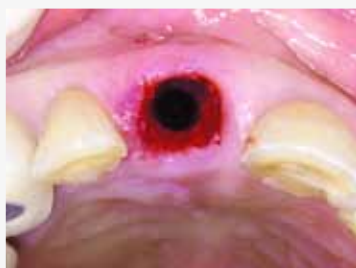綜合軟、硬組織的評估，決定以拔牙後立即植牙的手術進行，若植體穩定性許可將在手術同時，以非功能性立即負載的方式製作固定式臨時假牙，這種操作方式可以縮短整體治療完成的時間，並可以利用臨時假牙達成牙齦塑形，有助於美觀、發音上的需求。

操作流程

- 術前準備：
依照原有牙齒形態，在模型上預先製作空心殼狀臨時牙套。



■ 空心殼狀臨時牙套



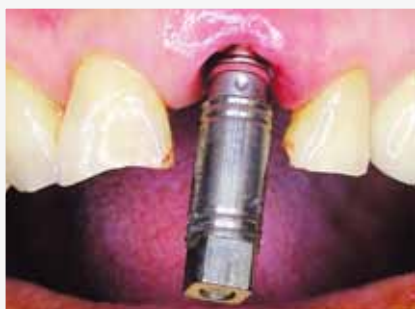■ 無傷害性拔牙

- 無傷害性拔牙 (atraumatic extraction) :

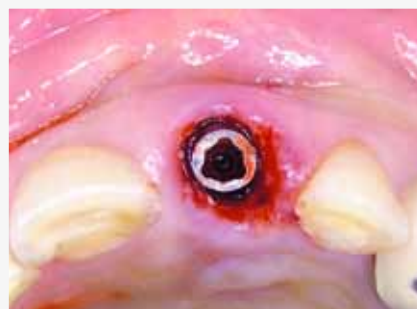以超音波骨刀進行無傷害性拔牙，小心完整地拔除牙根，並確保頰側骨嵴的完整性。

- 植入植體：

使用一般植體進行立即植牙時，定位鑽與平行鑽必須要偏頰側鑽入，將植體放置在偏頰側的位置，但是使用具有角度的植體時，植入方向只要延著拔牙窩的方向攻入，就可以藉由平台的角度克服角度上的問題，選擇植入直徑4.3 mm 的 Co-Axis 植體，攻牙時必須注意植體製放支架上的小凹標記，在最終植入深度時必須要面向頰側，以確保平台位置正確。



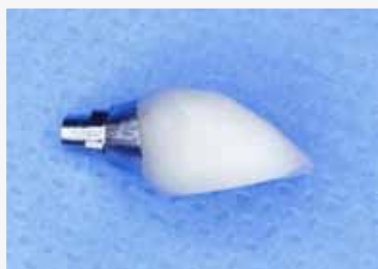■ 植體製放支架上的小凹標記必須要面向頰側



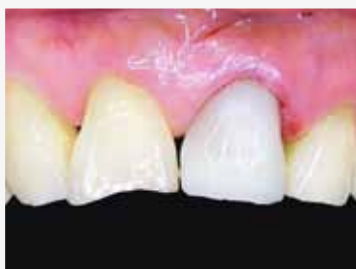■ 植體植入完成咬合面觀

- 製作固定式臨時假牙：

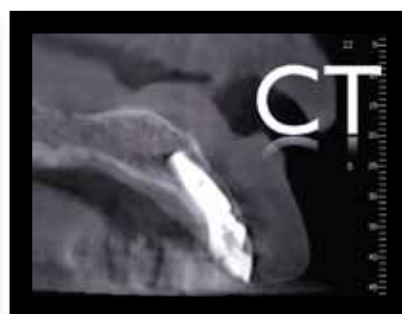接上支台後，以空心殼狀臨時牙套與樹脂完成臨時假牙，並鎖入口內，製作時注意臨時假牙組織側的表面必須非常光滑、外形必須自然外展，與對咬牙及鄰牙間不可接觸。



■ 完成之固定式臨時假牙



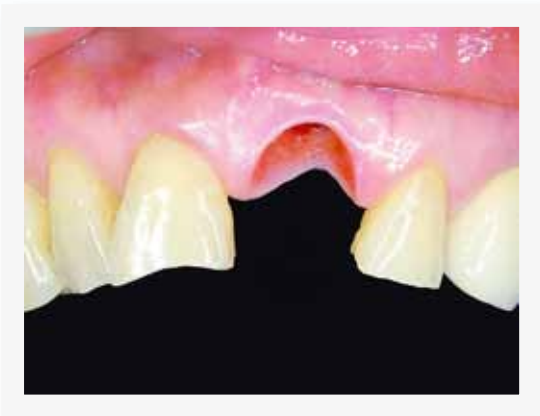■ 臨時假牙完成之口內臨床照片



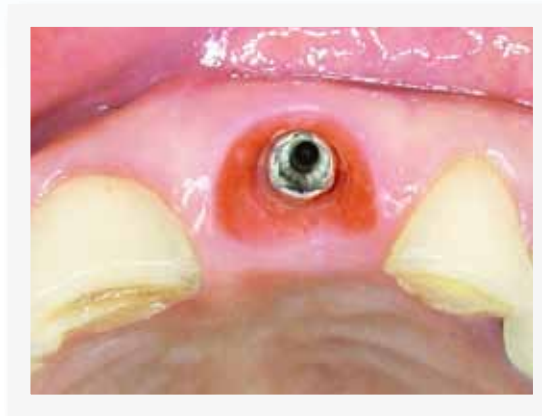■ 手術當天的電腦斷層掃描影像：
植體植入位置平行拔牙窩的軸向、
頰側板完整保存

- 製作固定式永久假牙：

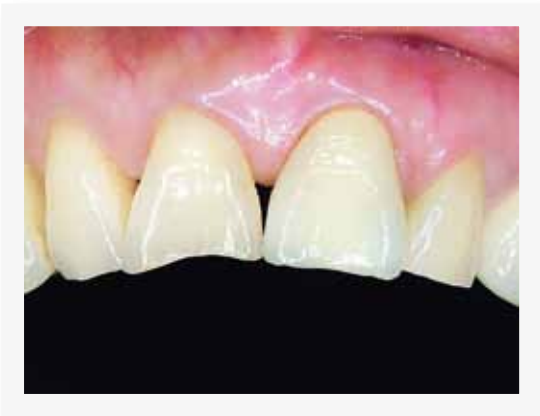經過四個月的癒合期，可以見到軟組織癒合良好，植體平台以上的牙齦組織呈現自然外展並符合牙冠自然的解剖外形，接著以轉移印模的方式進行永久假牙的製作，假牙完成後追蹤半年癒後良好。



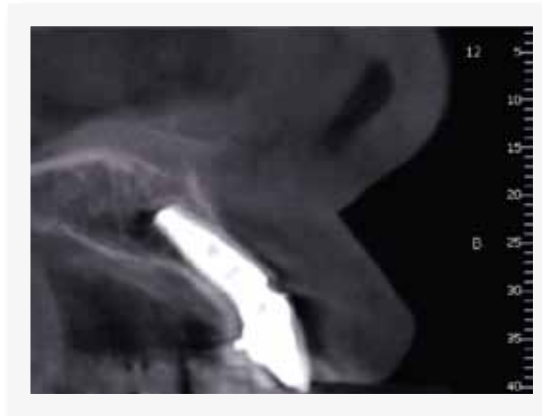■ 植牙手術後四個月之牙齦外觀呈現自然的貝殼形外展



■ 植牙手術後四個月之牙齦咬合面觀呈現自然的解剖外形



■ 假牙完成之口內臨床照片



■ 假牙完成之電腦斷層掃描影像

結論

拔牙後立即植牙並立即負載的手術方式，只要做好術前的評估、手術設計，加上精確的操作，搭配選用具有角度的植體，可以縮短治療期並簡單滿足前牙區美觀上的需求，是一種可預期美觀的操作方式，然而更多、更長期的追蹤仍需進行。

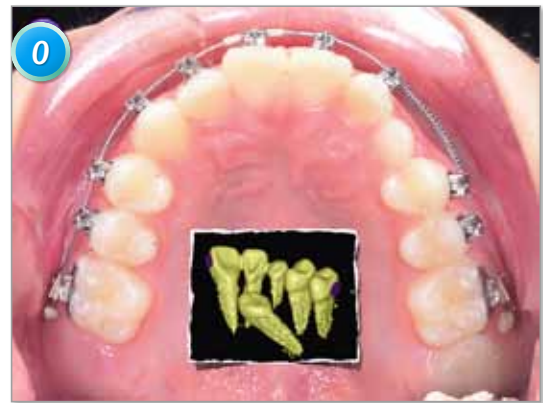Soft Tissue Considerations for The management of Impactions

Treating impacted teeth requires an interdisciplinary approach that involves various aspects of periodontal management, as well as the orthodontic considerations. Hence, patients with impacted teeth usually require a longer period of treatment and may have a compromised result if soft tissue is not carefully managed. To consistently achieve an esthetic result requires a thorough diagnosis, optimal treatment planning, and well-coordinated surgical and orthodontics treatment.¹⁻²

The clinical prevalence of impaction is about 1%. The proportion of maxillary to mandibular impactions is approximately 4 to 1. In maxilla, palatal impactions are more common than labial impactions. Typically a minor surgical procedure may be indicated during or after orthodontic treatment. Different types of surgical techniques will be discussed below.

Open window technique

Dr. Kokich et al.¹⁻² suggested that a palatal impaction will spontaneously erupt after the covering of soft and hard tissue is removed. The preference is to surgically expose palatal impactions early in orthodontic treatment, while space is being created with orthodontic mechanics. The following case report demonstrates the open window technique in an 11-



■ Fig. 1

3-D image clearly indicates the location of the impaction in relation to adjacent teeth.

year 8-month girl, with a palatally-impacted canine in her left anterior maxilla (Fig. 1). The primary canine was extracted and the soft and hard tissue, covering the impaction, were excised. Also, the bone in the planned path of tooth movement was removed with a high speed bur. A periodontal dressing was placed on the exposure to inhibit soft tissue healing to recover the crown of the impacted tooth. Once the canine had erupted, a bracket was bonded on the labial surface to draw the tooth into its ideal position, using a well-designed orthodontics mechanism.

There are two key points for achieving an optimal correction of the impaction without suffering

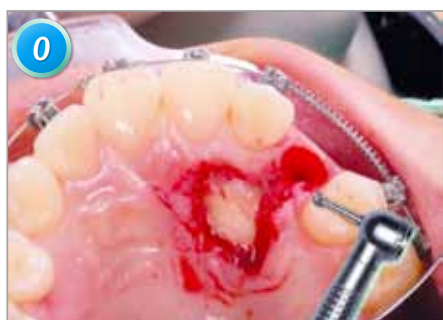

(from left to right) Dr. Chris HN Chang, DDS, PhD. Dr. Chuan Wei Su, DDS, MS. Dr. Yu Lin Hsu, DDS Dr. Eugene W. Roberts, DDS, PhD, DHC (Med)

additional root resorption on adjacent teeth. Therefore, the first key is to not bond a bracket on the tooth adjacent to the traction route, which is usually the maxillary lateral incisor, when a maxillary canine is impacted. This approach allows the tooth to be a free body, so it can move out of the path of tooth movement, when traction is applied to the impacted tooth.³

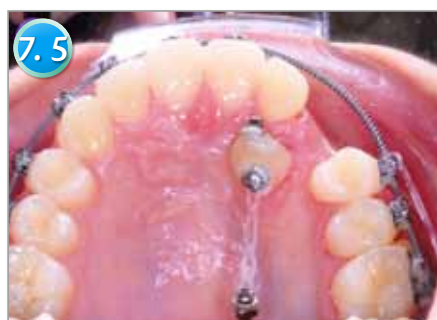The second key is appropriate design for the direction and anchorage of the force system. After the impaction is exposed, determining the direction of traction is straightforward. Typically, there are three anchorage

mechanisms: the main archwire, other teeth, and miniscrews (Fig. 3-4). When moving a recovered impaction toward the alveolar ridge, the bracket usually cannot be placed in an ideal position because of the adjacent soft tissue. A simple gingivectomy (Fig. 5) with a soft tissue laser can solve this problem and facilitate bonding the bracket in an optimal position (Fig. 6). A common problem of palatal impactions is the palatal position of the root after the crown is moved into the alveolar archform. Using a low torque bracket or torquing spring can correct this axial inclination problem and facilitate an esthetic result (Fig. 7).⁴



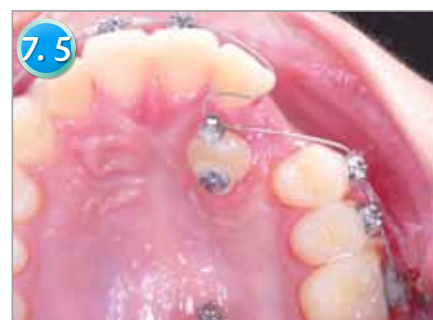■ Fig. 2

Open window technique was used for palatal impaction. The image shows the extraction of primary canine and exposure the crown of the impaction. Followed by the removal of the bone on the traction route, the wound was covered by COE-PACK. And the wound was left open until the eruption of the impaction.



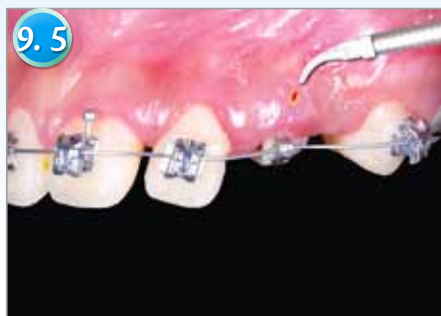■ Fig. 3

Retract the impacted canine with a palatal miniscrew and later rotate the tooth with power chains attached on the button on the buccal side.



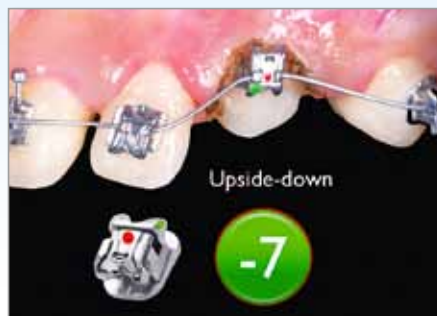■ Fig. 4

Insert a .013 CuNiTi wire into the eyelet on the impaction. To prevent the wire from slipping away, a resin stop was placed on the distal surface of lateral incisor.



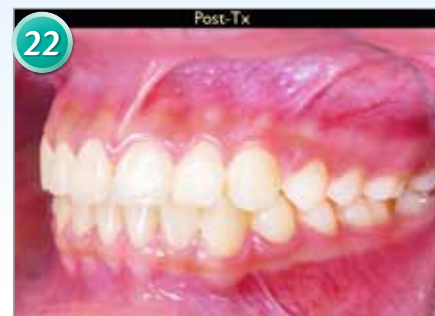■ Fig. 5

As the impaction moves towards the alveolar ridge, sometimes excessive soft tissue will cover the crown of the impaction. A diode laser can be used to remove the excessive issue for bracket placement.



■ Fig. 6

Torque selection should consider the location of the impaction's root. Here low torque is required and can be achieved by placing a high torque bracket upside down.



■ Fig. 7

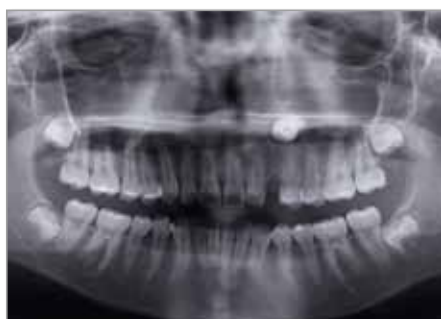Left intra-oral view after 22 months of treatment.

Closed eruption technique

When dealing with a labial impaction, especially near the mucogingival junction (MGJ), closed eruption technique and apically positioned flap (APF) are both considered. According to Dr. Kokich's article in 2004¹ closed eruption technique is more appropriate than APF when the impaction is in a high position.

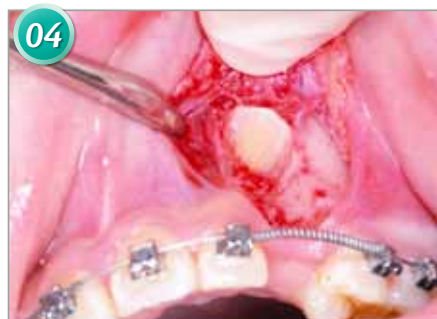A 13-year 7-month girl presented with a labially impacted canine, that was in a high position about

14 mm away from the alveolar ridge (Fig. 8). After 4 months of creating space, surgical exposure and orthodontic traction were ready indicated. The closed eruption technique was selected because the tooth was impacted high above the MGJ (Fig. 9). Two buttons were bonded on the buccal and palatal surfaces of the impacted tooth. Two different colors of power chains were used to provide distinction for the force system (Fig. 10).



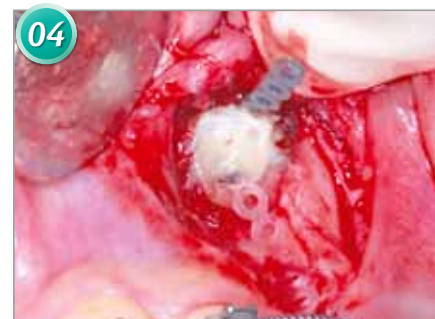■ Fig. 8

A 13y 7m female with an impaction 14 mm away from the alveolar ridge.



■ Fig. 9

A flap was used to expose the impaction and remove the bone until CEJ.



■ Fig. 10

Bond buttons on the labial and buccal side of the impaction and use color-coded power chains as markers.

To prevent the archwire from deforming and causing unwanted tooth movement, the traction force was anchored by a miniscrew (2x12 mm, OrthoBoneScrew, Newton's A, Inc. Taiwan) inserted in the infrazygomatic crest, and the lever arm made of 17x25 stainless steel (SS) (Fig. 11). Fig. 12 shows primary closure of the wound. The traction force was readily activated by adjusting the 3D lever arm (Fig. 13).

Three stages of soft tissue change are commonly observed during the process of traction: Stage 1. Gingival collar redness, Stage 2. The red patch, and Stage 3. Keratinization.⁵

Stage 1. Gingival collar redness : Following the initial period of forced eruption, a collar of redness is often observed around the gingival margin. This is the color of the non-keratinized epithelium tissue, inside of the periodontal pocket (Fig. 14). At this stage the pocket depth tends to be high (~5mm) and can be misinterpreted as poor healing or gingival inflammation. Patients should be instructed to maintain proper oral hygiene and be informed that this is in fact a normal condition.

Stage 2. The red patch : As the impaction continues to erupt downward, the immature-appearing tissue, "the red patch", appears coronal to the original gingival margin. At this stage the probing depth reduces from an initial ~5mm to normal of ~3mm. However, the color still tends to be more reddish and can be easily distinguished from the keratinized gingiva (Fig. 15).

Stage 3. Keratinization : When the impacted tooth is moved into an ideal position, the surrounding gingival tissue progresses from proliferation to maturation. The keratinization of gingiva requires ~28-42 days.

Insufficient palatal root torque often occurs, when buccally impacted teeth are recovered, because the root tends to remain oriented in the original buccal direction. Hence, it is important to monitor the torque of the impacted tooth in the finishing stage. Torquing springs are useful tools in finishing (Fig. 16-17).

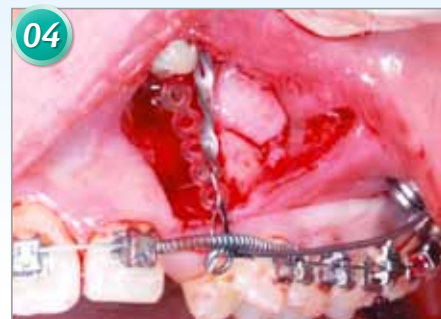

Fig. 11
Place a miniscrew on the IZC. Create a lever arm and insert it into the screw. Connect the impaction and the screw with power chains on both ends to generate a downward traction force.

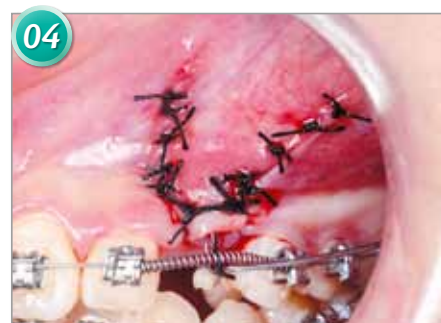

Fig. 12
Suture the flap with primary closure.

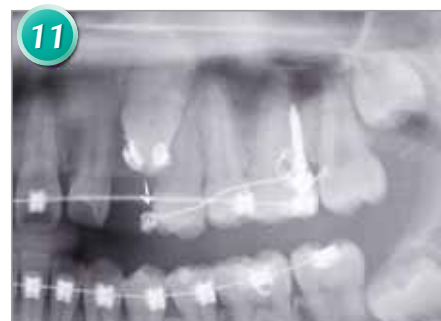
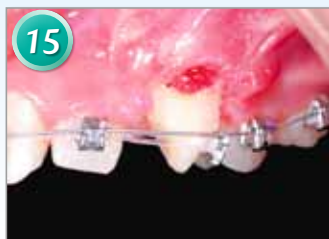
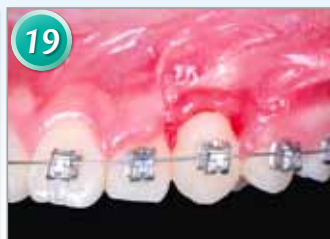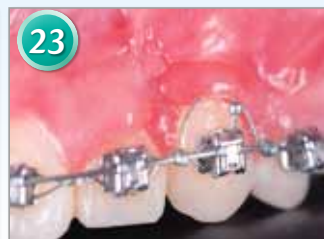Fig. 13
11 months in treatment. Provide a continuous downward force by bending the lever arm.



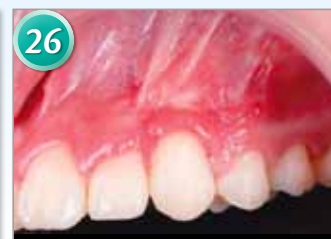■ Fig. 14
15 months in treatment.
Stage 1. Gingival collar
redness.



■ Fig. 15
19 months in treatment.
Stage 2. The red patch.



■ Fig. 16
Use a single torquing spring
(18X25) to increase torque.

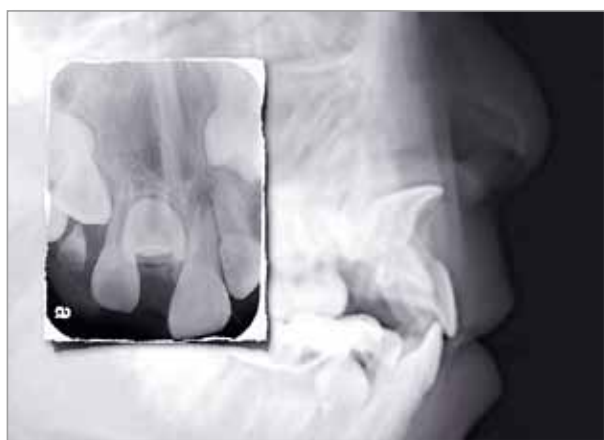

■ Fig. 17
Buccal view of active
treatment for 26 months.

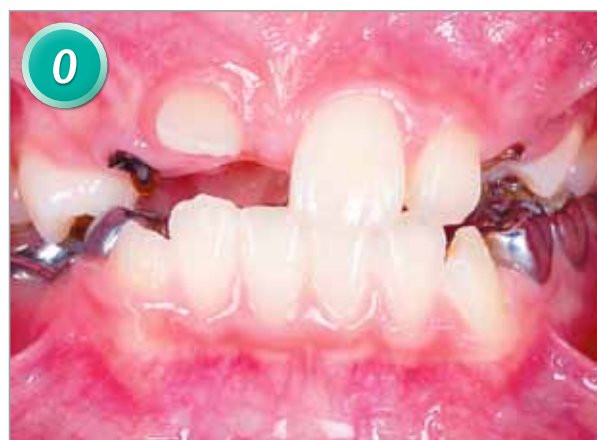Apically positioned flap (APF)

Dr. Kokich¹ suggested that when the position of the labial impaction was near or below the MGJ, the apically positioned flap was indicated. A case with a high position of the impaction was treated using the APF technique. This 9-year 5-month girl had a flared central incisor toward her nasal cavity (Fig. 18-19). After space was created between central and lateral incisors (Fig. 20), the impaction was surgically exposed and bonded with a button on the buccal side (Fig. 21).

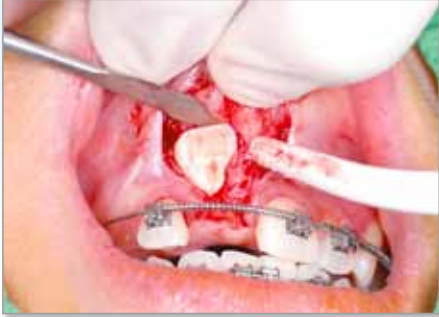When dealing with this type of high impaction, the insufficient quantity of keratinized, attached gingiva is an issue.⁶ To increase the attached gingiva, the flap was designed to be placed more apically (Fig. 22). The scar formation was obvious after healing (Fig. 23). Figure 24 shows that the parallel roots and no signs of root resorption of right central incisor after the orthodontic treatment. However, the mucosal scarring and vestibular reduction are limitations of the APF procedure.



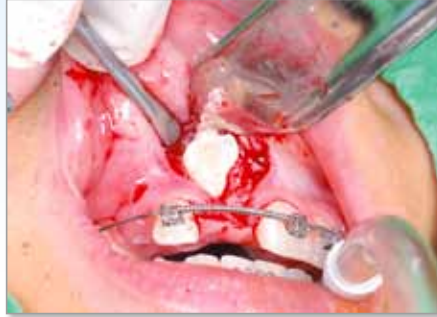■ Fig. 18
A 9y5m girl with a flared central incisor toward nasal cavity.



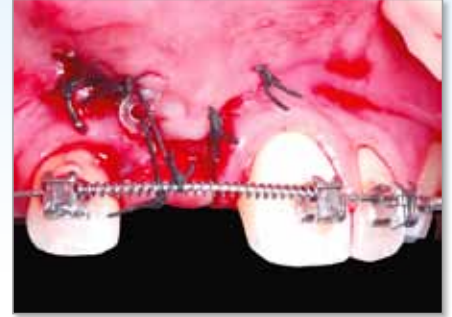■ Fig. 19
Intra-oral view-before treatment.



■ Fig. 20
Surgically exposed the impaction followed by creating space with open-coil springs.



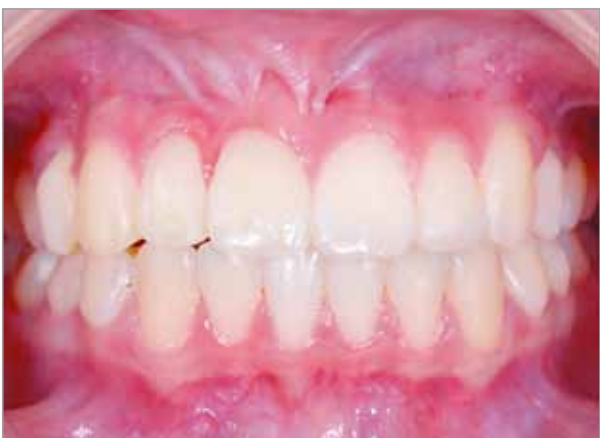■ Fig. 21
Bond a button with power chains on the labial side of the exposed impaction.



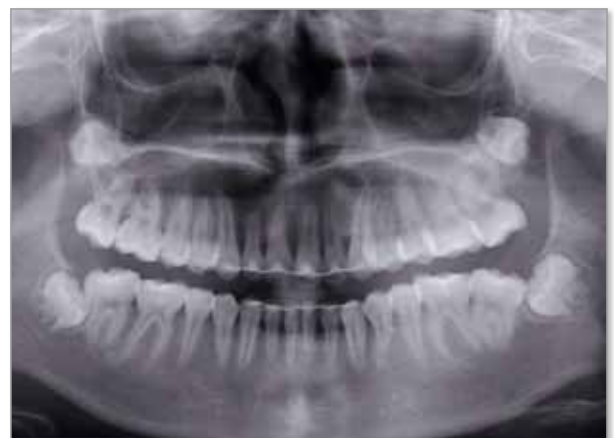■ Fig. 22
Suture the flap more apically.

In this case (Figures 10-24), we can compare the advantages and disadvantages of APF and closed eruption technique. APF can have the benefits of maintaining the depth of the vestibule while increasing the width of keratinized gingiva. However, its secondary healing tends to cause more pain for patients. Meanwhile, closed eruption, although the

primary healing is more comfortable for patients, the width of keratinized gingiva is not increased as a result.⁷ Moreover, the vestibular depth may decrease. In this case APF was preferred because of the critical need for increased keratinized gingiva. In terms of incision design, a vertical parallel incision is suggested to reduce scar formation.



■ Fig. 23
Intra-oral view-30 months in treatment. Visible scar tissue is observed over the surgical area.



■ Fig. 24
The panograph shows no root resorption or dilaceration after 30 months of treatment.

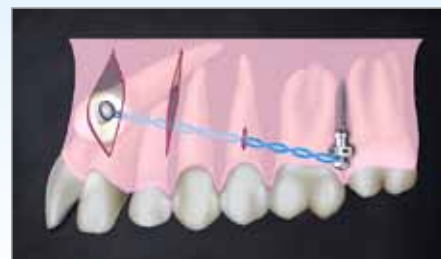Vertical Incision Subperiosteal Tunnel Access (VISTA)

The three surgical techniques previously described in this article are commonly used for impaction treatment. The following technique is traditionally applied for more complex periodontal problems. In the following case presentation, we will demonstrate how to apply it to impaction treatment.

Vertical Incision Subperiosteal Tunnel Access (VISTA) was invented by Dr. Homayoun Zadeh, and later on modified by Dr. Chris Chang for the management of upper buccal impaction (Fig. 25).^{8,9} It involves two vertical parallel incisions between which a tunnel is created for soft tissue augmentation in periodontal problems, or to serve as a traction route for impactions in orthodontic cases.

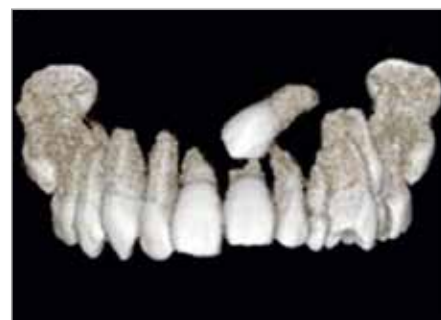An 11-year 1-month old boy presented with an impacted upper left canine positioned on the labial side of the central incisor (Fig. 26). The 3D imaging revealed that half of the root of the central incisor has been resorbed by the impaction (Fig. 27). The treatment plan involves a surgical technique in combination with the design of an orthodontic mechanical force system. Here, the VISTA technique is selected for surgically exposing the impaction. Subsequently, a button is bonded on the crown and an elastic chain(s) is attached to the impacted tooth. The mechanism is anchored with a miniscrew, placed in the infra-zygomatic crest to provide anchorage for traction. The miniscrew, with the elastic chains attached, comprise an efficient force system to retract the impaction. Finally, the bone on the traction route was removed by a #4 carbide round bur to facilitate tooth movement (Fig. 28).

3-D imaging provided clear and accurate information on the location of the impaction. With that knowledge a vertical incision was performed between central and lateral incisor (Fig. 29). One of the unique features of this technique is that it does not involve horizontal incisions, which often disrupt blood supply. Following the initial incision, a periosteal elevator was used to detach the periosteum and expose the impaction (Fig. 30). After exposure,



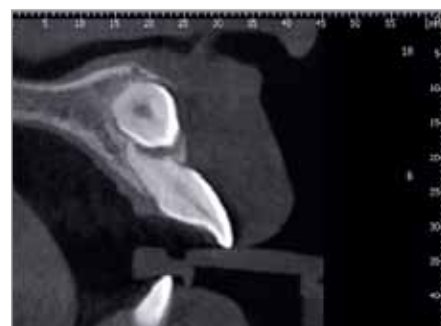
■ Fig. 25

Chris Chang's modified VISTA for the treatment of labial impaction. Note the position of miniscrew on the infrazygomatic crest (IZC) which provides a precise direction of force system to avoid the root resorption of adjacent teeth and facilitates the switch of transposed impaction (Illustrated by Dr. Rungsi Thavarungkul).



■ Fig. 26

A 11y1m boy came with an impacted upper left canine found in the labial side of the central incisor.

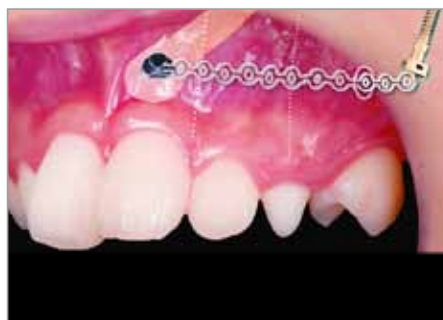

■ Fig. 27

Half of the root of the central incisor has been resorbed as result of the impaction.

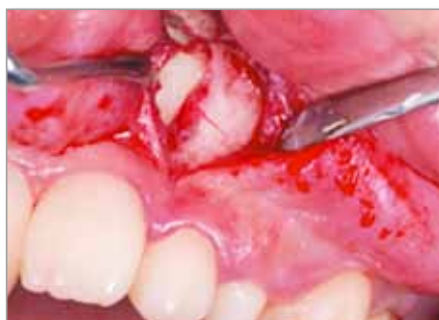bone covering the crown was removed down to the cemento-enamel junction (CEJ). Afterward, a second incision was performed around the corner of primary canine to expose and remove the bone in the proposed path of tooth movement (*traction route*). When the crown was fully exposed, a button was bonded on the labial surface, and power chains were attached to it (Fig. 31). The opposite end of the power chains exited the soft tissue via the distal incision (*tunnel opening*), and

they were attached to a miniscrew that was inserted into the infra-zygomatic crest (Fig. 32). The button, power chains and the miniscrew together formed an independent force system to provide a retraction force, without producing unwanted movement of other teeth. Finally the two vertical incisions were sutured with Nylon 6-0 to insure minimal damage to mucosa (Fig. 33). Figure 34 shows good wound healing of the incision site which provided the exit tunnel for the



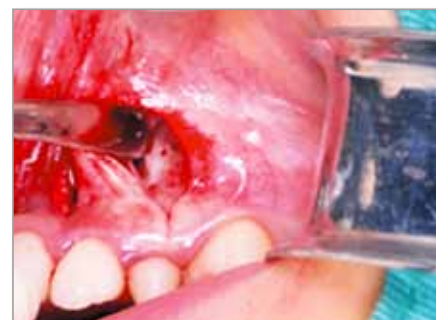■ Fig. 28

Based on the pre-treatment photo the flap and force system design are made. VISTA technique in conjunction with miniscrews are selected.



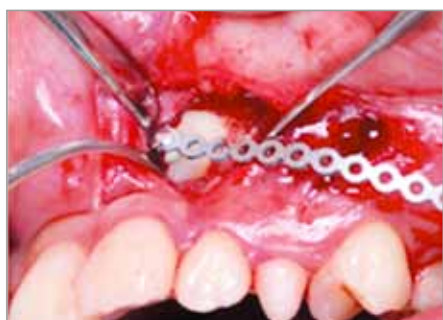■ Fig. 29

The first incision is made to expose the impaction and the bone over the crown will be removed later on.



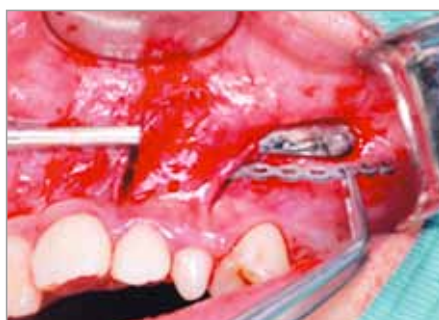■ Fig. 30

The second incision exposes the bone on the traction route which is then removed.



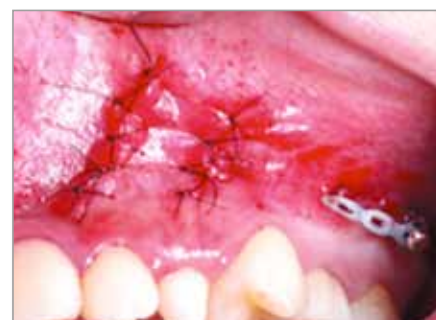■ Fig. 31

Bond a button on the crown and attach power chains.



■ Fig. 32

Pull the other end of the power chain out underneath the tunnel from the second incision.



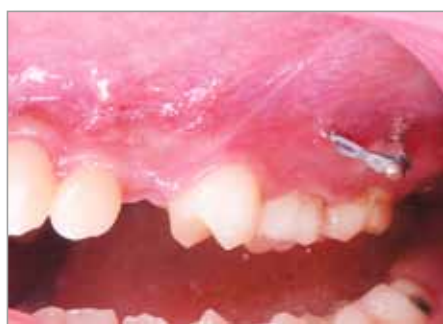■ Fig. 33

The power chain was penetrated through the 3rd small incision hole and attached to the head of the miniscrew on the infra-zygomatic crest. 1st and 2nd incisions were sutured with Nylon 6-0.

power chains. Self-ligated brackets (*Damon Q, Ormco Corporation*) and .014 CuNiTi archwire were applied in the 5th month after the VISTA surgery (Fig. 35). Followed by bracket placement, coil springs were inserted onto the archwire to create space, for the impaction to move into the desired position in the maxillary arch. One should also notice the left central incisor was **not** bonded with a bracket at this point, in order to prevent further root resorption, as a result of orthodontic movement. The lateral incisor had no bracket attached, which allowed for its free movement during traction. In order to prevent the flaring of anterior teeth, the miniscrew was connected to the archwire by light power chains, thereby providing a light retracting force (Fig. 36). After 6 months of active treatment, including the VISTA retraction procedure and two months of

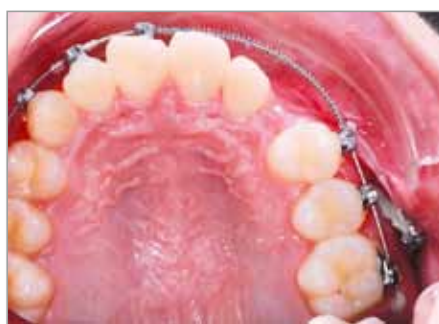orthodontic treatment, the impaction has moved into its desired position and was ready to erupt into the desired position. A series of panoramic x-rays demonstrate this sequence of pre-eruptive tooth movement (Fig. 37-39).

In summary, VISTA is a flapless surgical technique that causes minimal trauma to soft tissue and creates less pain for patients. Without reflecting a flap, the tension of the wound is decreased facilitating closure with direct loop interrupted sutures. The VISTA approach allows for good wound healing and therefore can achieve a more desirable soft tissue result. This method is particularly well suited for surgical management of labial impactions in the esthetic zone.



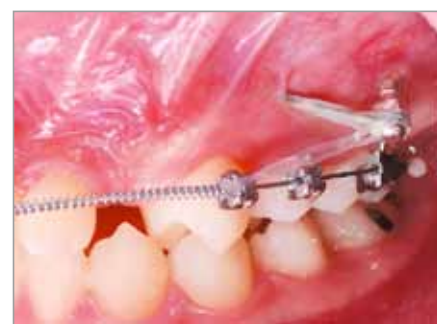■ Fig. 34

This buccal view shows the wound one month after the VISTA surgery.



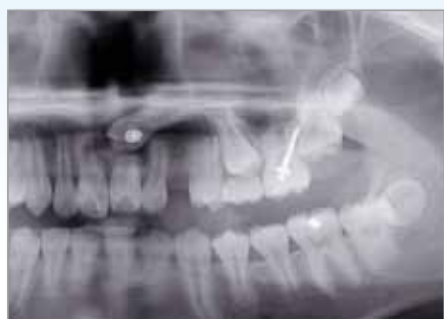■ Fig. 35

The occlusal view of the 5th month showed that the left central and lateral incisor aren't bonded while coil springs are inserted for space creation.



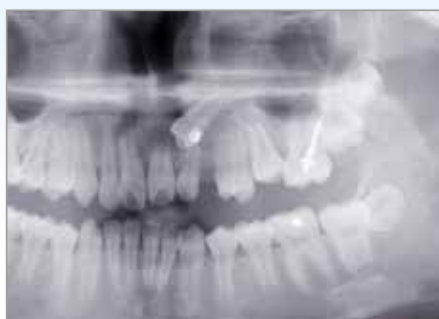■ Fig. 36

6th months in treatment. The soft tissue is intact and in a healthy pink color. A miniscrew on the IZC holds the arch with power chains attached to the bracket.



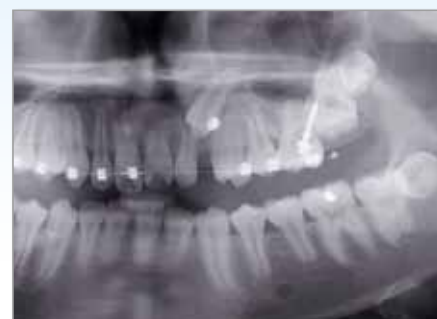■ Fig. 37

The panoramic X ray taken on the day of surgery. The original position of the impaction is around the apex of the central incisor.



■ Fig. 38

The panoramic X ray taken 3 months afterwards showed that the impaction moved distally to the apex of lateral incisor.



■ Fig. 39

The panoramic x ray taken in the 6th month. Here the impaction has moved into the desired position ready to erupt

CONCLUSION

Four types of surgical techniques were discussed to illustrate different applications for impactions in various locations. The open window method is optimal for a palatal impaction, which usually will erupt spontaneously into the oral cavity. Since the palate is covered by keratinized gingiva, there is little problem in achieving an attachment with adequate keratinized gingiva. Closed eruption technique and APF are common procedures for buccal impactions. The choice of technique depends on the height of the impaction and the condition of supporting soft tissue. One of the main problems for closed eruption technique is the difficulty in tension release of the flap. APF shares a similar challenge in wound closure. The apical repositioning makes it difficult to precisely control the flap margin. For a minimally invasive procedure, particularly in the esthetic zone, the VISTA approach provides an excellent alternative for the surgical treatment of labial impactions.

REFERENCES

1. Kokich VG, Surgical and Orthodontic Management of Impacted Maxillary Canines. *Am J Orthod Dentofacial Orthop.* 2004; 126(3): 278-83
2. Kokich VG, Mathews DA. Impacted Teeth: Surgical and Orthodontic Considerations. *Orthodontics and Dentofacial Orthopedics.* Needham Press Inc. , 2001; 395-422
3. Huang CH, Chang CH, Roberts WE. High Maxillary Canine Impaction with Mesial and Palatal Displacement. *News & Trends in Orthodontics.* 2011; 21:38-49
4. Tseng SP, Chang CH, Roberts WE. Palatally impacted maxillary canine. *News & Trends in Orthodontics* 2011; 21:326-36
5. Mantzikos T, Shamus I. Forced Eruption and Implant Site Development: An Osteophysiologic Response. *Am J Orthod Dentofacial Orthop.* 1999; 115(5):583-91.
6. Hsu YL, Chang CH, Roberts WE. Early Intervention for Multiple Impacted Teeth: More Comprehensive Clinical Assessment with the iSAS Method. *News & Trends in Orthodontics.* 2010; 20:32-46.
7. Chang CH. Advanced Damon Course No. 9: Impacted and transposed teeth, Beethoven Podcast Encyclopedia in Orthodontics 2011, Newton's A Ltd, Taiwan
8. Chang HF, Chang CH, Vertical Vertibular Incision Subperiosteal Tunnel Access. *News & Trends in Orthodontics.* 2010; 20:82-85
9. Chang CH. Implant Forum No. 5: VISTA, Beethoven Podcast Encyclopedia in Orthodontics 2011, Newton's A Ltd, Taiwan

OrthoBoneScrew

The Dream Screw for Next Generation's Orthodontists

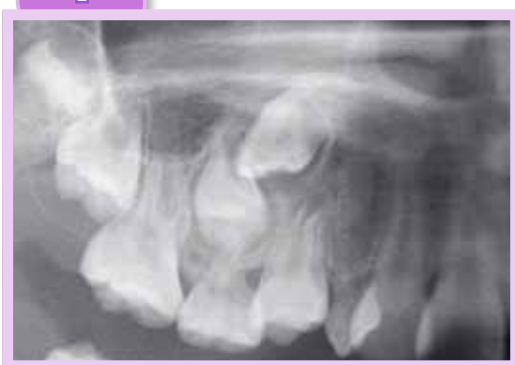Beethoven Orthodontic Center, Taiwan

Yu-Lin Hsu, Chris HN Chang, W. Eugene Roberts

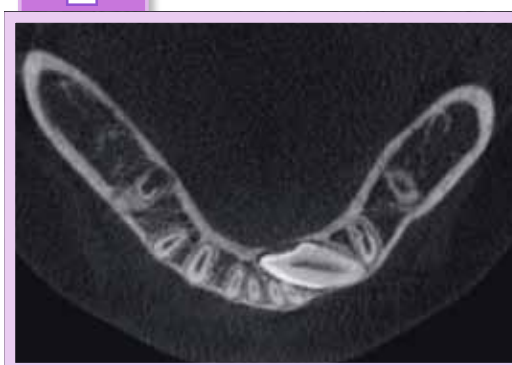Tough Cases Made Easy by OBS



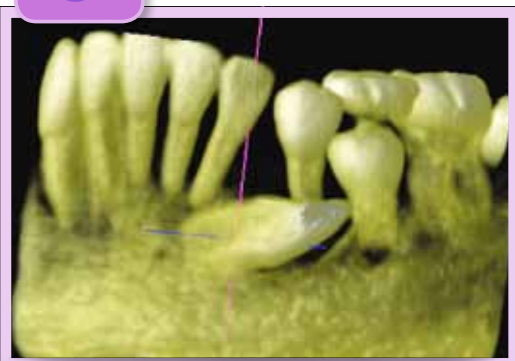1



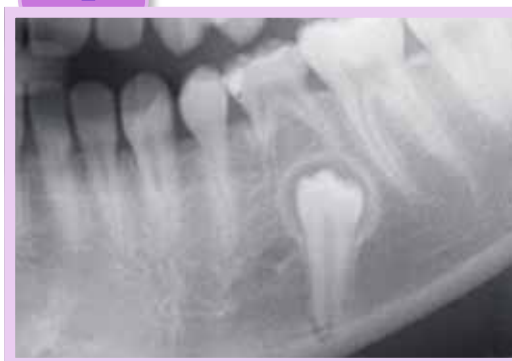2



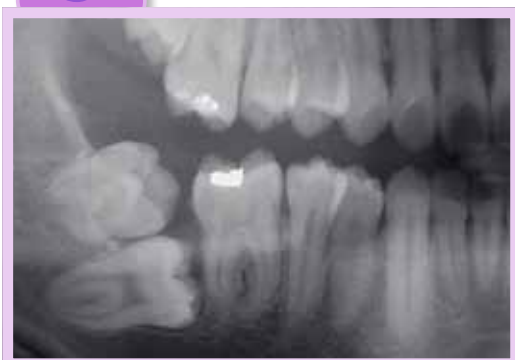3



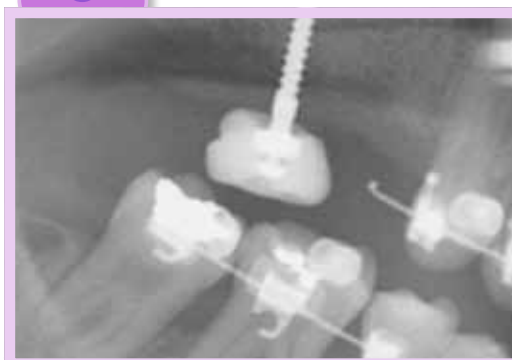
4



5



6



OrthoBoneScrew

Corporate Headquarters
2F, No. 25, Jian-Jhong
First Road, Hsinchu,
Taiwan 300

Tel: +886 3 5735676

Fax: +886 3 5736777

fo@orthobonescrew.com

Upper labially impacted cuspids

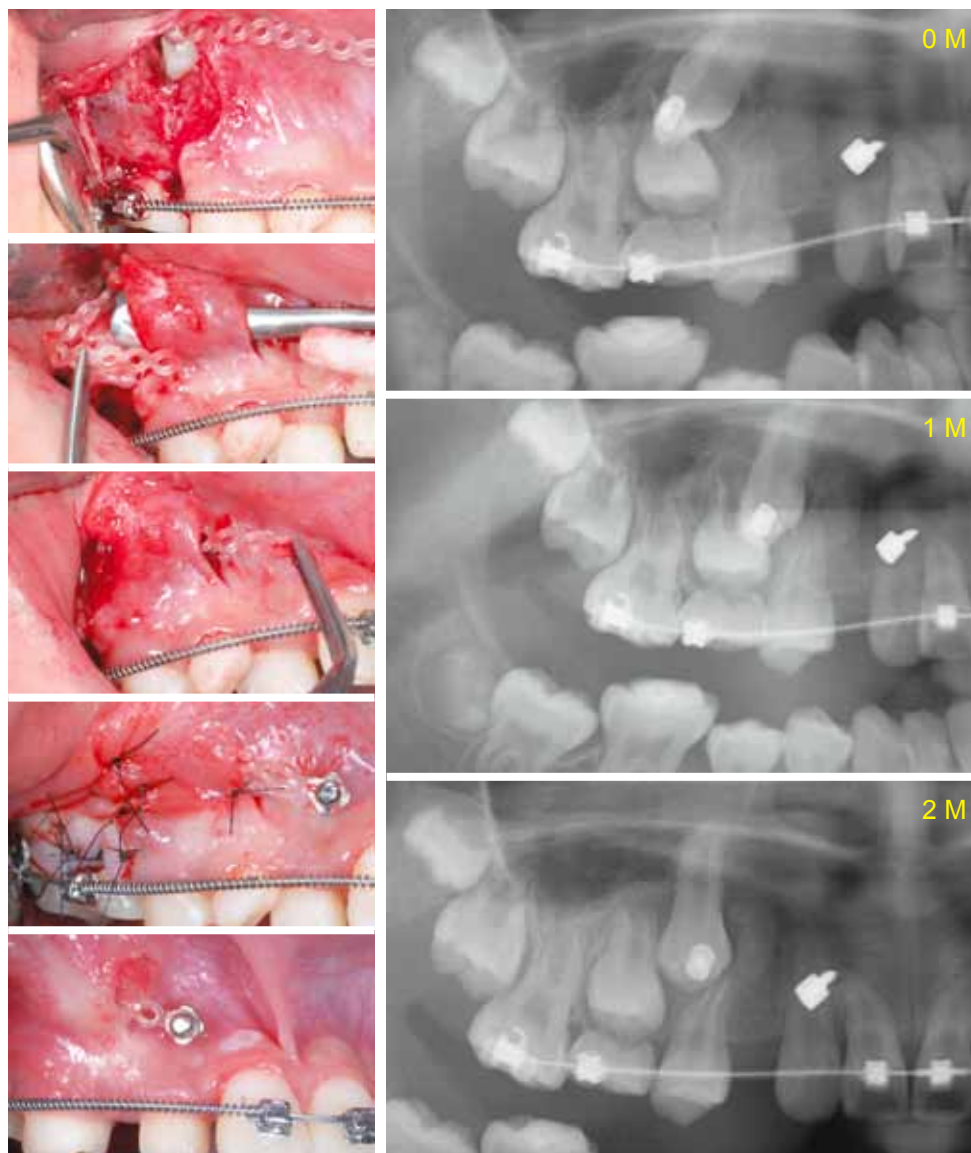
1

A closed eruption technique

Modified from **V**ertical **I**ncision **S**ubperiosteal **T**unnel **A**ccess

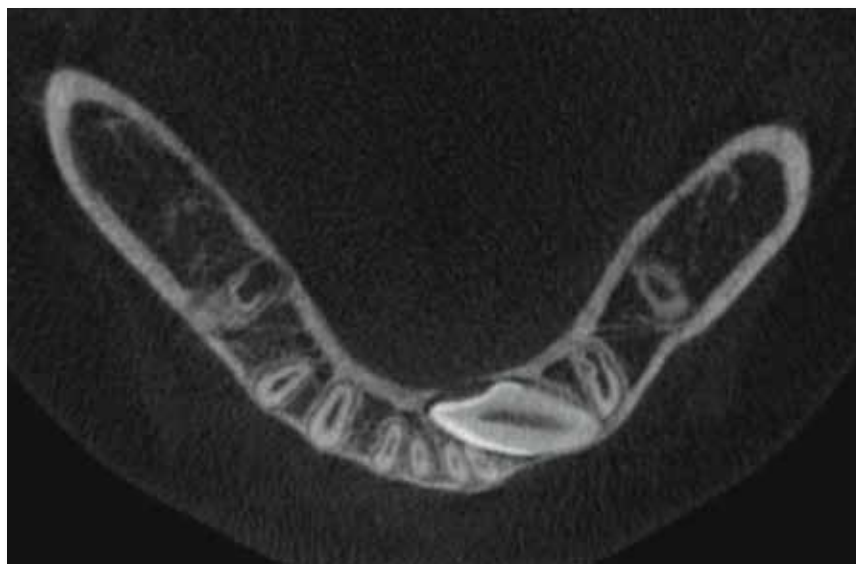
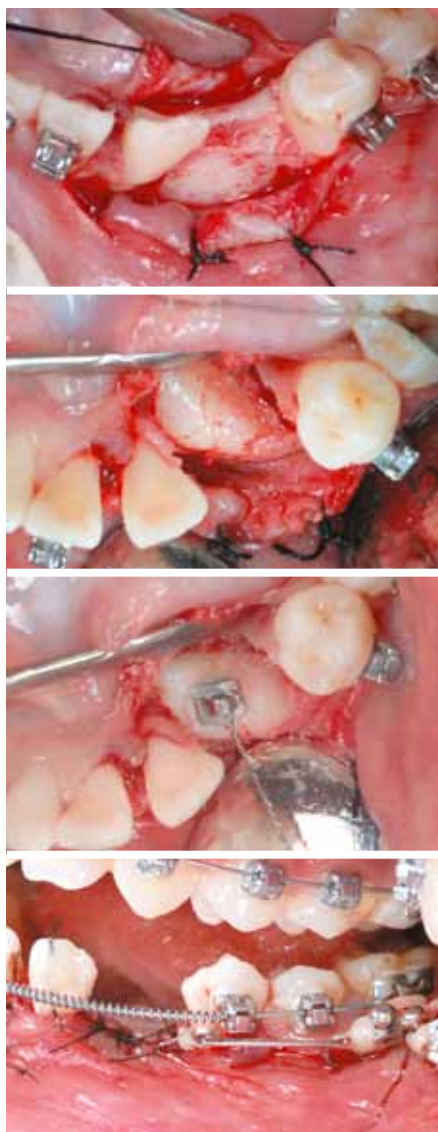VISTA (Dr. Homa Zadeh, USC)

In this case, closed eruption technique was chosen for primary wound healing which is more comfortable than APF. The combination of VISTA technique not only avoid the 2-stage placement of OrthoBoneScrew but also offer a good connection between the OBS and the covered transpositional cuspid. Meanwhile, one should keep OBS as high as possible to make the switch easier. After 2 month-long treatment, this transpositional cuspid has been pulled mesially for 3~4 mm.



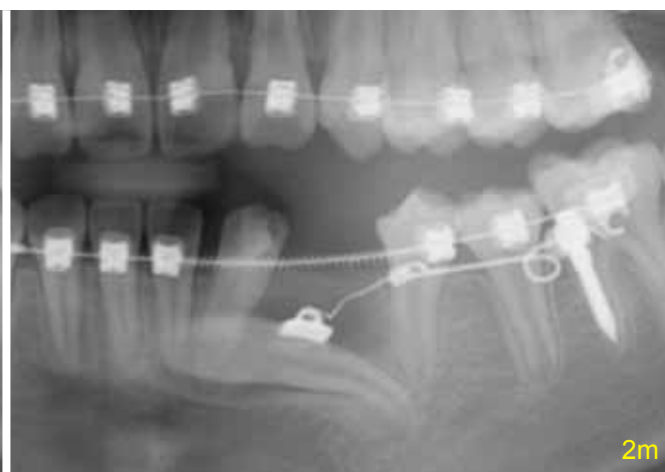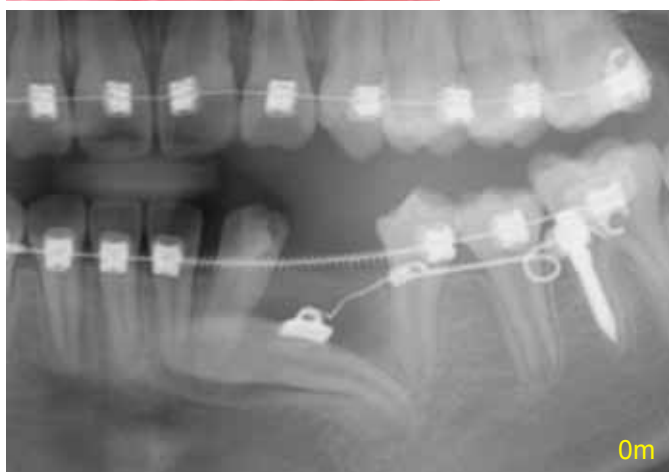Sublingual trans-alveolar impacted cuspids

2



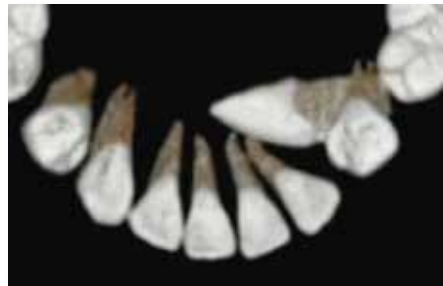
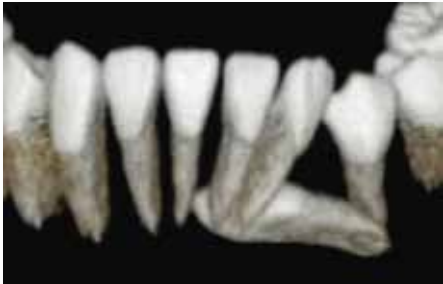1st surgery

The force system was designed to deliver by a 0.019 x 0.025-inch SS lever arm and the OBS which was located at buccal shelf. When this lever arm was inserted in the square hole in the OBS and activated, it could upright the trans-alveolar canine first, then moved buccally, and finally elevated to the reserved canine space. During the exposure surgery, it was important to keep the operation field as superficial as possible on both



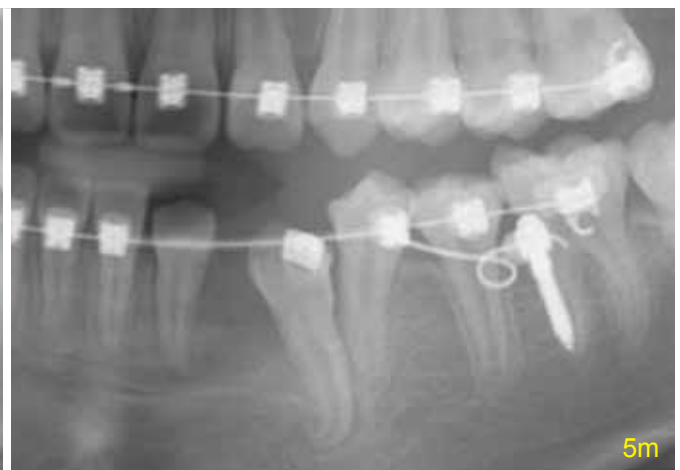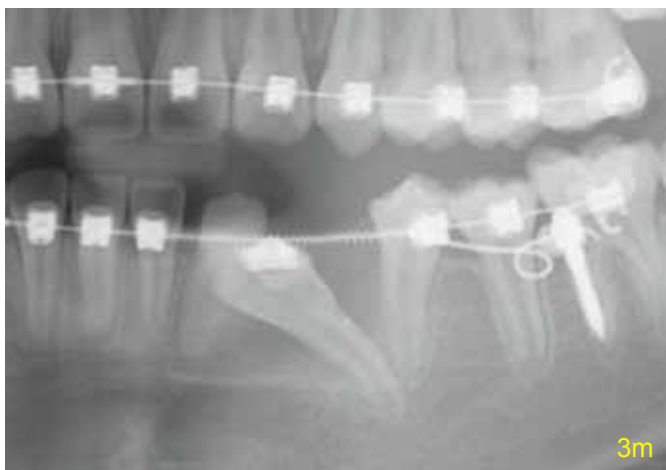
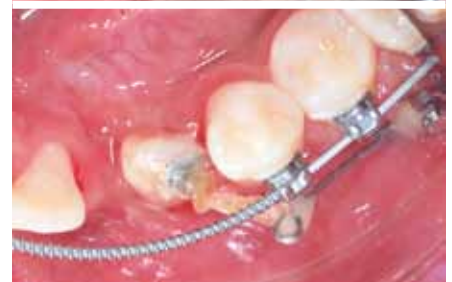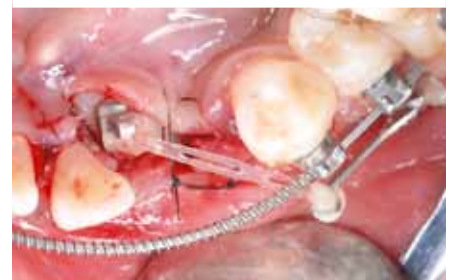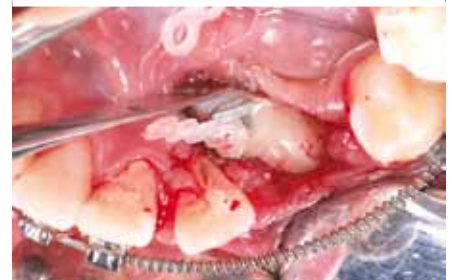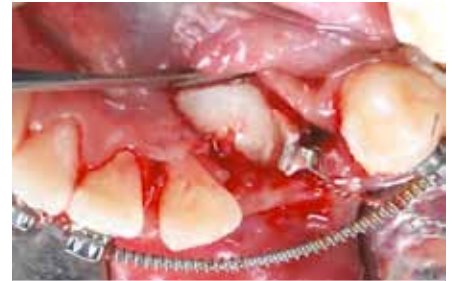Sublingual trans-alveolar impacted cuspids

2



2nd surgery

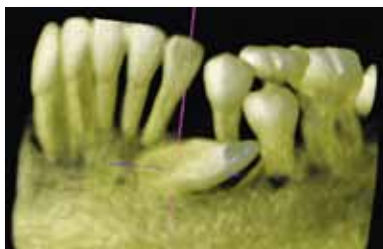
labial and lingual side to avoid cutting the mental nerve and sublingual artery. This safety consideration led to a restricted bonding position of the eyelet on the surface of the root. After 2 months from operation, the horizontal impacted canine was upright successfully, and the 2nd exposure surgery was aimed to change the position of the eyelet to the crown. By adjusting the lever arm, the tip of the impacted canine was shown up in the oral cavity 2 months later.



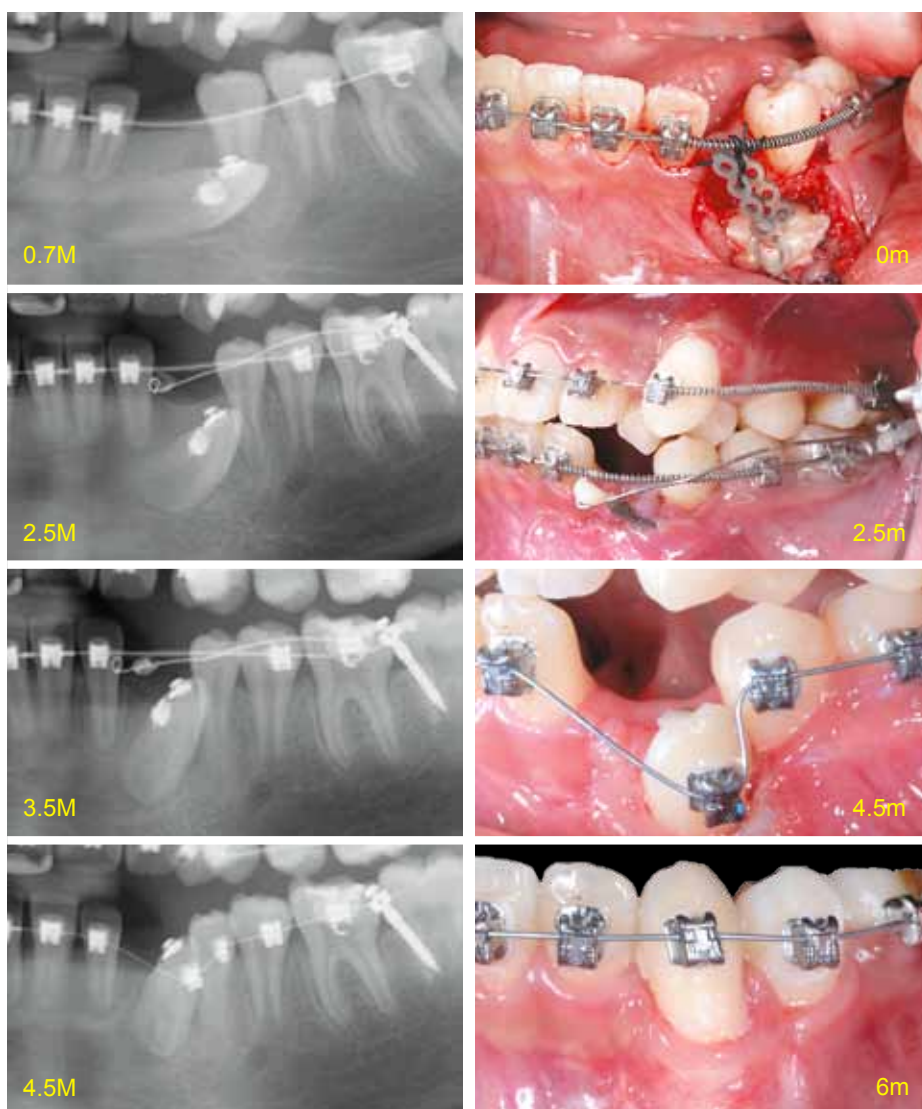
Lower horizontal impacted cuspids

3

Mechanics design:

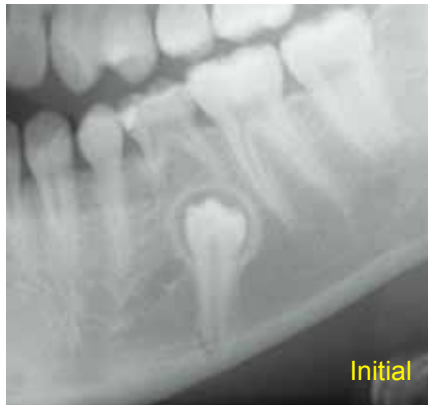

A 0.017 x 0.025-inch TMA lever arm was consisted of a helical coil on one end and helical attachment on the other end. When this lever arm was inserted in the square hole in the **OBS** (*located at buccal shelf*) and activated, it could build a force system which protracted the tip of canine first, then moved buccally, and finally elevated to the reserved canine space. If the mechanics were designed to exert force directly from the main arch wire only, it would have been detrimental to the roots of first premolar. During the follow-up visits, the helix was adjusted without taking it out. After three months from operation, the impacted canine was successfully moved away from the previously impacted site and was ready for bracket bonding.

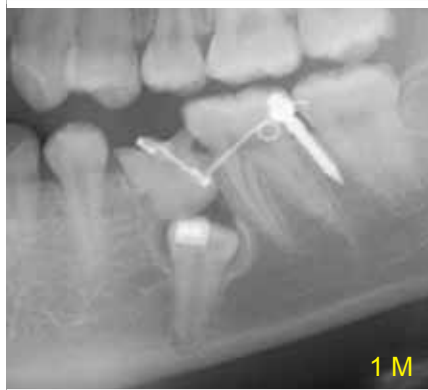


Lower impacted premolar

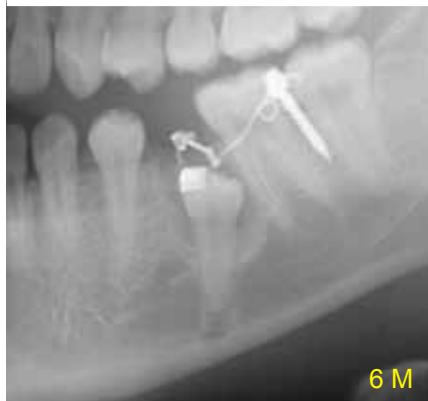4



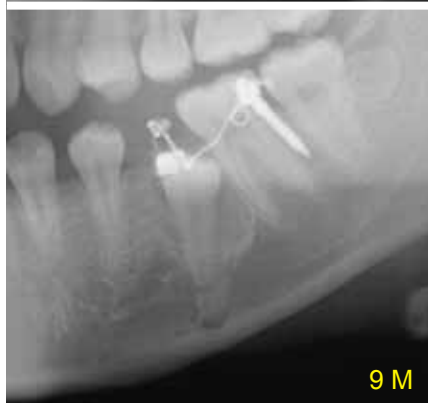Initial



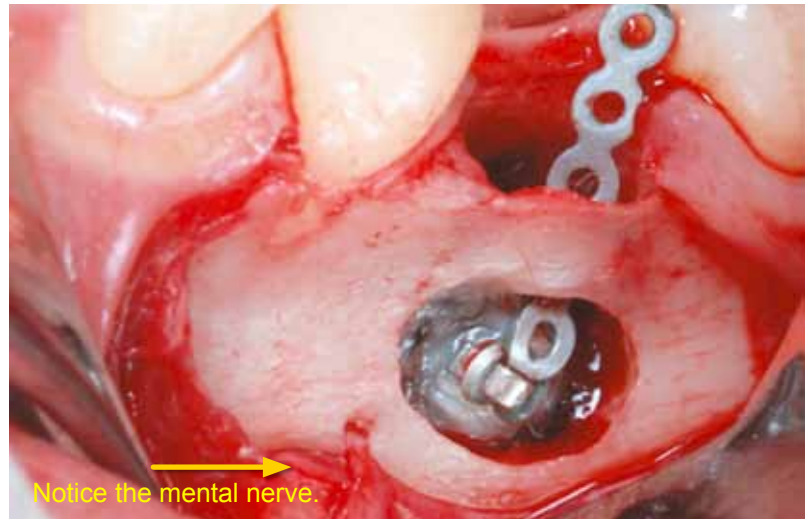1 M



6 M

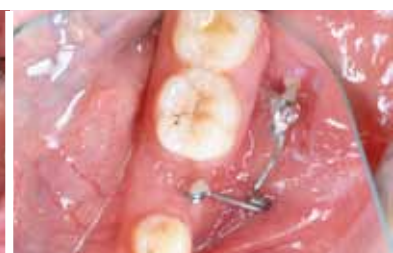
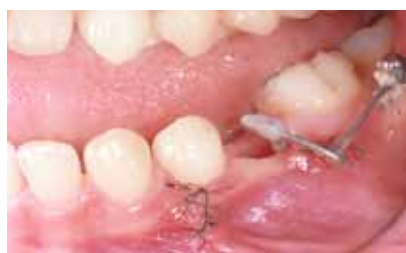
9 M



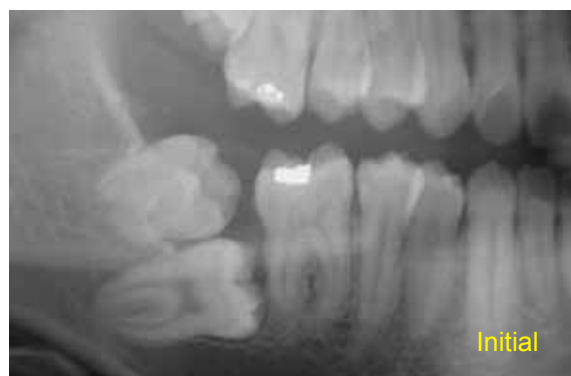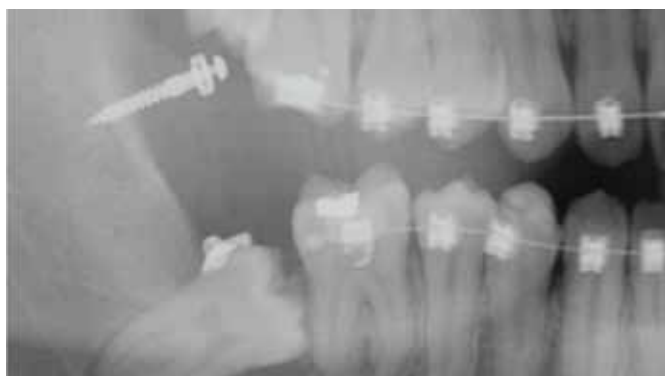Notice the mental nerve.

A 13-year old female had a lower impacted 2nd premolar, approximately 10 mm deep on the left side. The treatment plan was to extract the 2nd primary molar and pull out the 2nd premolar. During the treatment, the 2nd primary molar was first extracted, followed by bonding an eyelet bracket on the surgically exposed 2nd premolar. Meanwhile, the bone surrounding the crown of the second premolar was reduced until reaching CEJ and a lateral window was made for bracket bonding. An eyelet bracket was bonded on the buccal surface of the deeply impacted second premolar. The OBS was inserted on the left buccal shelf area. A power-chain was attached between a 3D lever arm and the eyelet bracket to extrude the second premolar. This 0.017 x 0.025-inch TMA lever arm was consisted of 3 helical coils: one in the middle, two in both ends. When this lever arm was inserted in the square hole of the OBS and activated, it would form a force system which extruded the second premolar directly.

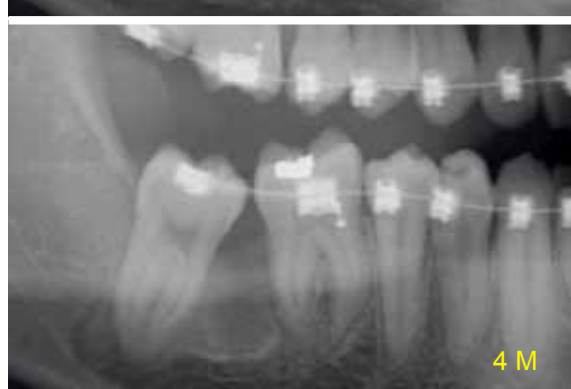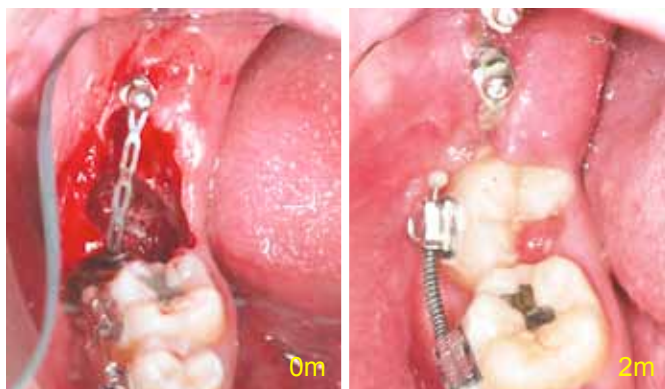

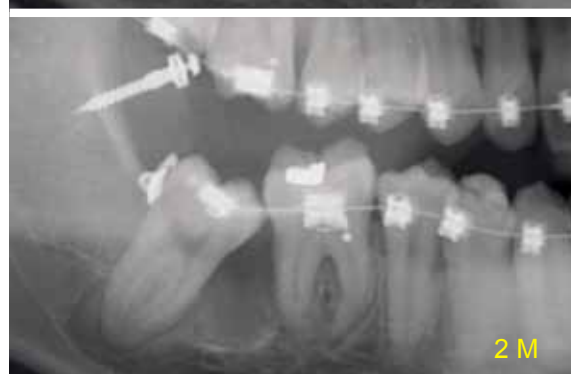
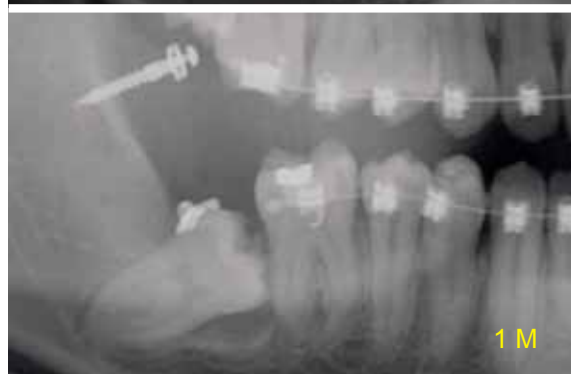Lower impacted molar

5

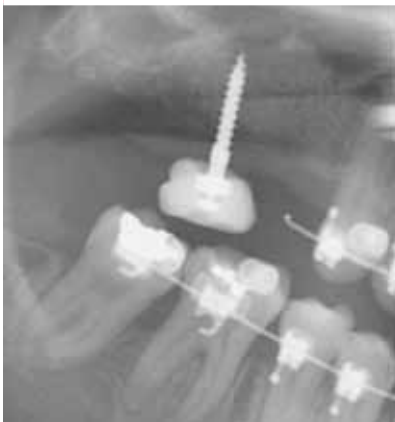
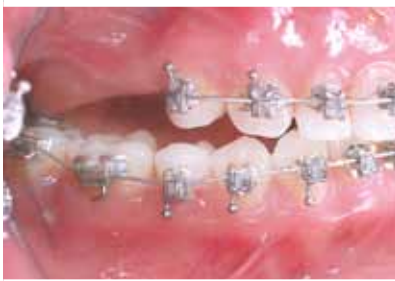
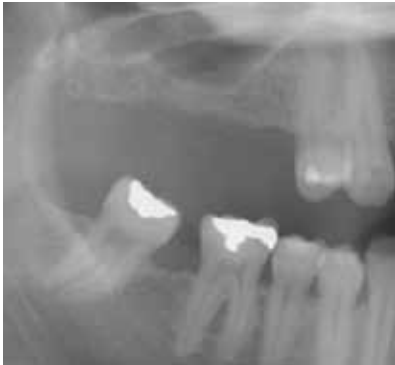A 19-year-and-10-month-old male had lower impacted second and third molars on the right side. The treatment plan was to extract the 3rd molar and upright the 2nd molar. During the treatment, the third molar was first extracted, followed by exposing the second molar surgically. Meanwhile, the bone surrounding the crown of the second molar was removed to CEJ and the second molar was surgically luxated by an elevator. A button was bonded on the distal surface of the second molar. The OBS was inserted on the right ramus of the mandible. An elastic chain was attached between the OBS and the button to upright the second molar. In 4 months, the second molar was uplifted successfully. Finally, a molar tube was bonded for advanced alignment and leveling. An open coil spring was inserted between 1st and 2nd molars to push and upright the 2nd molar.

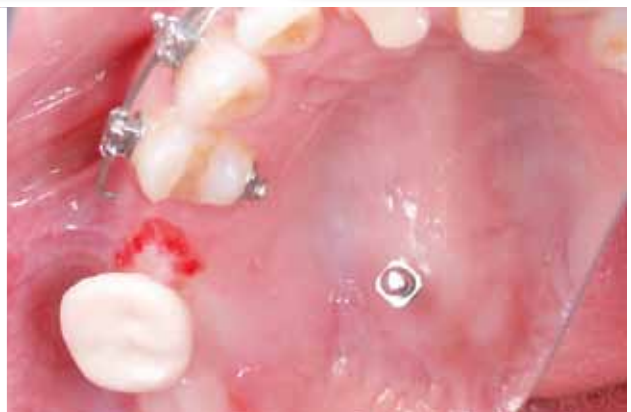
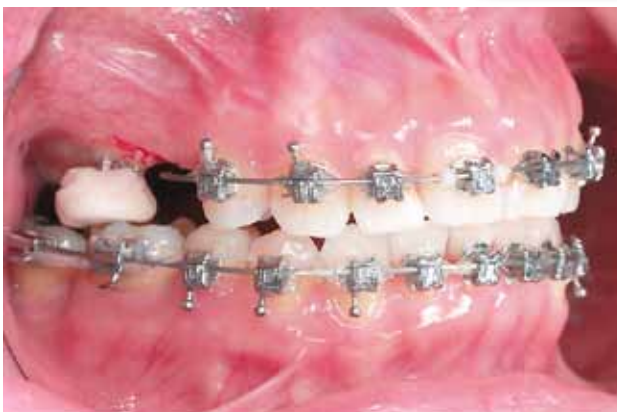
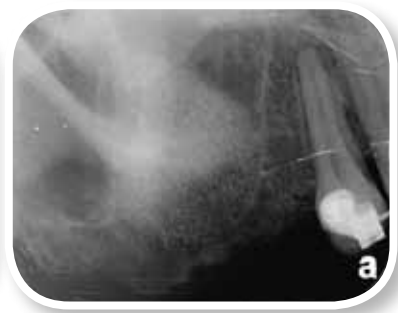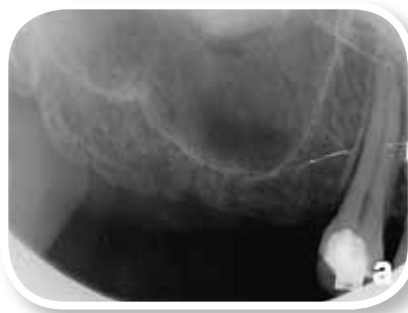More Applications of OBS

Molar intrusion 6



In this case the patient lost the upper right molars. The treatment plan indicated orthodontic treatment to level the lower molars followed by implant therapy. However, the absence of teeth over a long period of time had caused the upper sinus pneumatization. Furthermore, supraeruption of the mandibular molars had left little space for implant placement. Hence, intrusion of the mandibular molars was indicated. The primary concerns included 1. lack of antagonistic force 2. difficulty in simultaneous miniscrew placements on both buccal and lingual side. Considering the objectives of current orthodontic treatment and future implant therapy, a lateral window opening was performed for sinus lifting and bone graft placement. Five months later an OBS was placed with its head covered by GIC to intrude lower molars. OBS was chosen as a preferred alternative than a more permanent dental implant because the implant site couldn't be determined until the active orthodontic treatment was complete. In the event of loosening it is relatively easy to replace. Therefore, OBS provides an easy temporary solution to this type of ortho-implant combined cases.



牙醫雲端資訊整合

金牛頓植牙中心、金牛頓藝術科技
蘇筌瑋、黃思涵、蕭道山

引言

想像您服務的診所看診量龐大，每天都有許多不同的住院醫師和專科醫師輪流到診所支援，診所裡可能有好幾台不同的電腦，有的負責調閱病歷，替患者約診或報到，有的用來對病患做講解，還有一台要專門用來申報健保，如果您突然想要調閱某個病患的資料，您可能要特別跑去某一台電腦才能查詢。透過雲端科技和行動化裝置的搭配應用，想像您在任何一台電腦都可以申報健保，調閱病歷，即時看到病患剛照好的 X 光片，隨手拿起一台 iPad 就可以直接在診療椅旁或是候診區幫病患做療程說明或是衛教，而這些資料的傳遞都是無線且自動完成，心動嗎？這些不再是遙不可及，複雜昂貴的理想。貝多芬牙科集團目前都已經透過結合蘋果電腦和 iPad 的硬體環境，以及煜興 e-Touch 和金牛頓自製的 E-consultation 軟體，讓您隨時隨地都可以輕鬆的為患者提供高品質的服務。

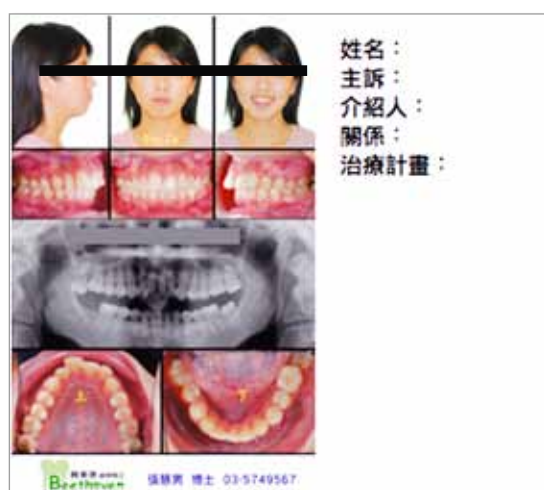電子化圖像病例

貝多芬每日看診的病患量非常多，而且到診所支

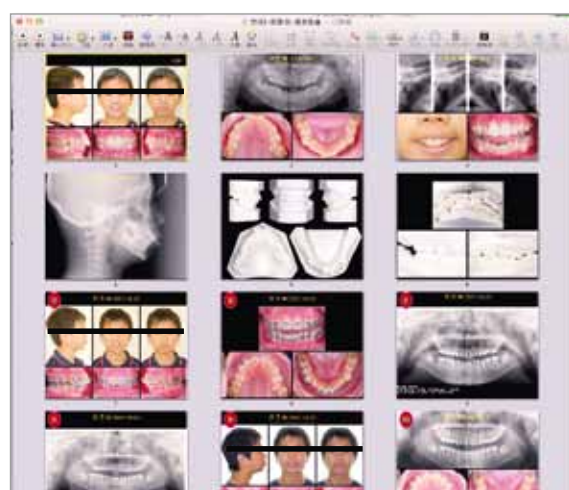
援的住院醫師及專科醫師的組合可能不盡相同，貝多芬獨特的將患者的外觀、口內照片加上拍攝的 X 光資訊，整合成圖像式的病歷上（圖一），圖上可以附註主訴，治療計劃例如矯正拔牙位置、植體數目等，取代文字的敘述，一目了然。此外，藉由雲端科技無線的同步傳遞電子圖像病歷，讓每位治療醫師都能按照治療計劃按部就班的完成對患者的治療，也能將治療的進度回傳至雲端，統一彙整病人各科的治療概況。

雲端資訊分享

當遇到疑難雜症，需要尋求治療上的意見與討論時，我們可以利用蘋果電腦內建的簡報軟體 Keynote 製作成以照片和影片為主的簡報檔案（圖二），當檔案較大時，dropbox（雲端硬碟）可以讓診所間的檔案交換更加便利，也可以輕鬆與其他人分享檔案。以往我們大多使用隨身碟或電子郵件來傳遞資料，但仍會受到距離與檔案大小的限制，或者一定要透過電腦來進行，dropbox 方便大檔案的傳遞，除電腦外，只要下載這個免費軟體，醫師也可以利用 iPhone 或是 iPad 來存取資料。



■ 圖一、整合式圖像病歷



■ 圖二、Keynote 做成的簡報檔案

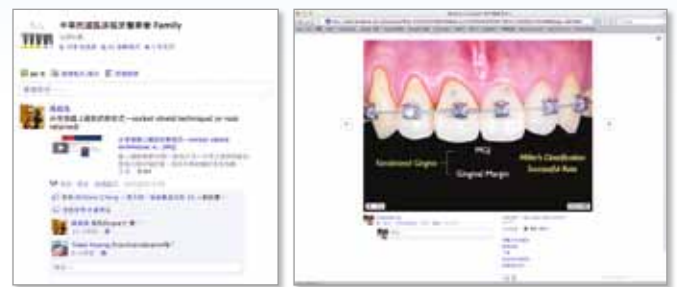我們也可以利用網頁的空間，如在 Facebook 上所成立的矯正或植牙相關社團中（圖三、四），進行病例的討論。同樣利用這樣的網路資源，我們可以在網路上分享研讀的文獻期刊（圖五），更能夠將自己閱讀後的心得利用簡報軟體製作成影片發佈出來（圖六），讓更多的醫師一起學習與加入討論，文獻閱讀因為雲端而成為集體的行動，更能因為分享讓知識傳播至無遠弗屆。

諮詢不受場地限制

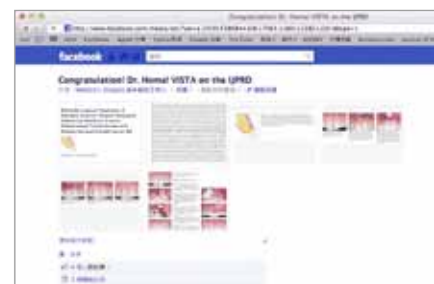透過行動影像裝置（如 iPad）搭載不同類型的示範案例，醫師和助理可以在診療椅上，或是在諮詢桌前，等候區時，隨時隨地的與患者以及家屬進行溝通解說（圖七）。從患者一踏入診所，一開始的環境介紹、就診流程說明、口腔衛教、自費項目解說，我們都製作成簡報，利用電腦或是掌上裝置來說明，讓患者瞭解自己接受的療程，降低患者的疑慮（圖八）。此外，貝多芬利用 iPad 搭配「煜興 eTouch」病人管理系統，除了上述的優點外，還可以即時上傳病患的 X 光片，所以當患者剛由助理引導照完 X 光，回到診療椅時，剛才拍好的 X 光已經出現在醫師手上的 iPad，馬上就可以針對即時的資訊，提供詳盡的診斷計畫。這樣的效率與立即性，有助於提升診所形象並縮短醫師及患者間溝通的距離。

整合健保申報及病歷系統

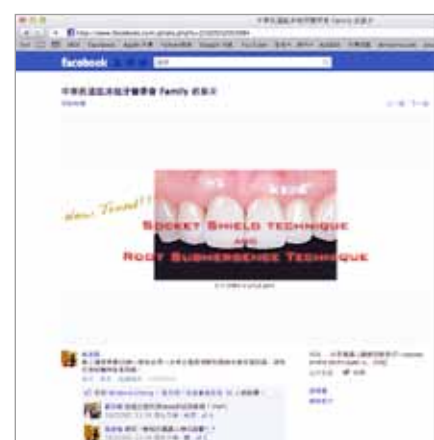除此之外，貝多芬所使用「煜興 eTouch」病人管理系統還能結合現有的健保系統，在前臺掛號的同時，「煜興 eTouch」病人管理系統可在每位醫師及助理的 iPad 上立即顯示就診病人資料，檢視每位病人的相關注意事項與療程記錄，讓醫師對病人的關心更加貼近、親切。同時醫師及助理更可「一次性」地病歷輸入，免去舊系統與新系統上軌所造成的落差。



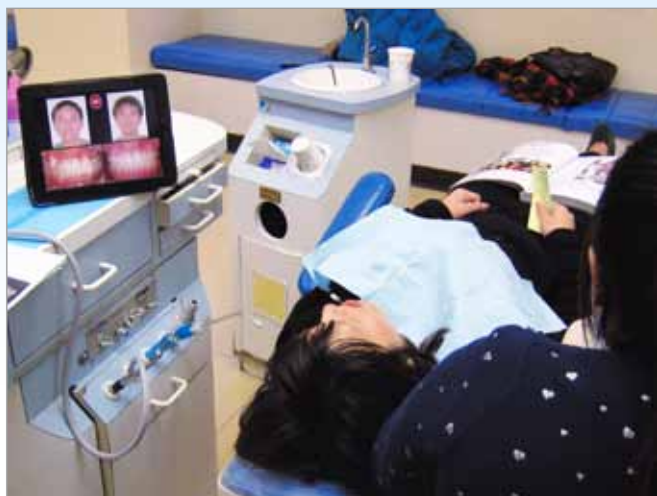圖三、四、在 Facebook 上的矯正或植牙相關社團中，進行病例的討論



圖五、在 Facebook 上分享研讀的文獻期刊



圖六、利用簡報軟體將閱讀心得製作成影片發佈出來



■ 圖七、透過行動影像裝置（如iPad），隨時隨地的與患者以及家屬進行溝通解說



■ 圖八、牙科助理利用 iMac 上的 Keynote 提供病人初診諮詢

學習不分時地

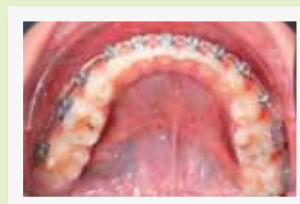秉持著「分享無國界，學習零時差」的概念，貝多芬的負責人張慧男醫師也在今年邀集國內外矯正和植牙界的專家成立了「國際矯正植牙學會」（International Association of Orthodontists and Implantologists，簡稱 iAOI）這個雲端的國際學習組織，希望能夠激勵大家可以輕鬆地不論何時何地都可以線上聆聽精采的演講，接收最新的牙科知識。此外，我們也率先採用在 iPad 上進行學會的入會考試，未來將開放讓國際會員也可以在同一時間進行線上的認證考試。

結語

藉由雲端資訊科技軟體和行動輔具的整合，搭配診所長期累積的優質服務和成功病例，我們可以輕鬆圖七、透過行動影像裝置（如 iPad），隨時隨地的與患者以及家屬進行溝通解說的提昇診所管理的效率，強化與患者溝通的服務品質，也能夠在競爭激烈的牙科醫療環境中，走出自己的風格和特色。面對市面上五花八門的產品如果您覺得困惑不知該如何選擇，希望貝多芬的實務經驗可以給您帶來一些新的思考和刺激。身為診所的經營者，您還在等待什麼呢？

IJOI23 勘誤表

- 1) p14: 倒數第二行 "In moder Damon system, extraction of the lower 3rd molars will make the treatment much simpler by extraction of the lower 3rd molars." 應改為 "In the modern Damon system, extraction of the lower 3rd molars will make the treatment much simpler."
- 2) p20: 倒數第五行 mandibular second molar 之間無須換行。
- 3) p21: specific objectives of treatment 整段刪除。
- 4) p25: fig18 right figure 應更換為右圖。





Congratulations!

Dr. B. Giuliano Maino, the president of 3rd WIOC presented the honorary member plaque to Dr. Eugene Roberts for his great contribution in the field of implant orthodontics.


Dr. Angle's Bust



Contact us to find out how you can read the most famous orthodontic textbook from your iPad, iPod, or computer screen.

Tel: +886 3 5735676
Fax: +886 3 5736777
Contact: info@orthobonescrew.com

Colored Glaze USD 200
Bronze USD 60





星期四

9-5 pm



Keynote
高效簡報學習法



K1 簡報聖經

2011 12/22 • 2012 8/16

看過太多充滿複雜文字和圖表的幻燈片，聽過就忘了的演講嗎？Keynote 系列一的演講要教你如何利用 Keynote，製作出令人目眩神迷、印象深刻的電腦簡報。透過小班教學，貼身指導，務必讓你在八小時裡輕鬆掌握 Keynote 的簡報技巧。

學習重點：1. Keynote 操作入門 2. 演講常見十大謬誤 3. 資料視覺化技巧




K2 Dr.Kokich 令人屏息的十大演講秘訣

2012 1/12 • 9/20

Keynote 系列二位各位介紹世界牙醫界的天王講師 Dr.Kokich 的十大演講秘訣，讓您在進階的課程中更加掌握演講設計的關鍵原則，不但讓你知其然，更知其所以然！

學習重點：1. Dr.Kokich 十大演講秘訣 2. 準備演講的九個步驟 3. 多媒體影片剪輯



K3 賈伯斯令人目眩神迷的五項演講技巧

2012 2/16 • 10/18

總結我們 Keynote 系列的系列三，我們為大家逐步解析跨界演講大師 Steve Jobs 是如何說出打動人心、價值數十億美金的關鍵故事。透過逐步的分析拆解，要讓您也可以成為獨具魅力的演講人。

學習重點：1. Steve Jobs 的五項演講技巧 2. 幻燈片的設計概念 3. 幻燈片修改應用

好康

連續報名三堂課，學費再享 **8** 折優惠！

報名專線：03-5735676

Hours：2-9 pm

上課地點：新竹市建中一路 25 號（交大華廈）2 樓

Keynote 高效簡報學習法系列課程

K4 / 5 / 6
簡報繪圖
精修課程

2012
6/9-11
Sat-Mon

9am-5pm

預計招生：限額 25 名

Effective dental presentation in today's digital world requires not only clear clinical photos but also diagrams and animation to engage the audience. Moreover, these visual tools are excellent aids to make your presentation unique and memorable. In this workshop Dr. Rungsi will share his dental illustration experiences and demonstrate step by step how to create an illustration from an initial sketch to a finished piece. Active participation and completion of workshop assignments are required for workshop participants.

TOPICS :

Why will you learn?

- How to use a digital drawing board.
- Design illustration in your Keynote.
- Showcase your own drawing with stunning animation in Keynote.
- Create complicated diagrams using Adobe Illustrator and Photoshop.
- Animation Competition

Requirements :

- Mac computer with OSX 10.6 or later
- Digital drawing Tablet (Wacom recommended)
- iWork 09'
- Adobe Illustrator CS4 and Adobe Photoshop CS4 (or later version)



Dr. Rungsi
Thavarungkul

Make Your Presentation
Unique & Memorable !

Newton's A

Avoiding & Managing Complications Associated with Implant Therapy Part 1

Dr. Baldwin Marchack



Dr. Baldwin W Marchack
Instructor,
USC Implant Training Program
in Taiwan

我們可以將植牙可能遇到到的併發症分為surgical complications及restorative complications，兩者是互相影響的，今天將以補綴的觀點出發分析原因、解果及處理方式。

最常遇的併發症有：

1. Infection
2. Inflammation
3. Soft tissue prolapse
4. Gingival hyperplasia
5. Gingival recession
6. Porcelain fracture
7. Occlusal overload
8. Poor implant position

一、Infection

植體周圍 infection 造成的 peri-implantitis 處理方式多與手術關係較大，這次演講以補綴的觀點為主所以本次不多做琢磨，但特別提醒的是在任何 corrective surgery 之前，最重要的是以保守的 antibacterial therapy 方式先做處理。Dr. Casey 提到 30% 的病人，40% 的植體會有 peri-implantitis，可見發生率很高。

二、Inflammation

植體周圍發炎的發生原因有四個：牙菌斑堆積、abutment 鬆脫、假牙不密合、黏劑殘留。

1. 牙菌斑堆積：

完整的治療不只是把假牙做好 (proper prosthesis design)，更要教育病人把口腔衛生做好 (圖1)。



楊千瑩 醫師
中國醫藥大學牙醫學士
林口長庚牙科部醫師
台北醫學大學附設醫院廣復科代訓醫師

2. Abutment 鬆脫：

External connection的 植體設計較常發生 abutment 鬆脫，Internal connection 較少發生。如果是 screw type prosthesis，只要把 screw hole 打開重新拴緊或是更換新的 screw 再上 torque 即可，但若是 cement type，screw hole 較難定位者則考慮拆掉重做。

3. Poor fit of margin：

x-ray上即可診斷，多數情況下不會有問題，但若有牙菌斑堆積造成發炎則拆掉重做。

4. Cement retention：

這是所有問題中最嚴重的。Dr. Wilson 在 paper 中提及 81% 的 peri-implantitis 是因為粘劑殘留造成，其中 74% 在黏劑清除後會變好。JP 2009,80,1388-1392

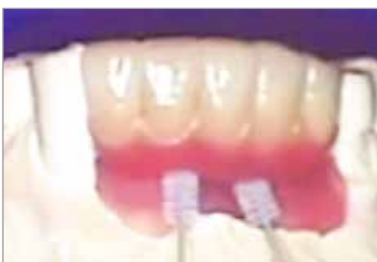以下這個案例(圖2)，是粘劑殘留造成的，處理方式有兩種：

(1) 找到screw hole，拆下來清潔完重新鎖上。

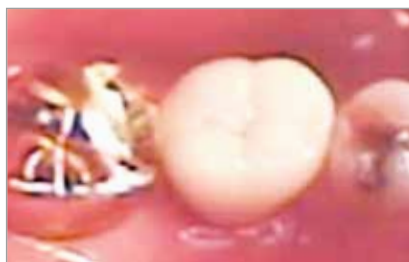(2) 重做。

我們將牙冠拆下來後發現植體位置太深，PD至少8-10 mm(圖3)，如此雖能有很好的形態但cement 清潔不易，於是選擇製作一個 custom abutment，將cement line往上拉到subgingiva 0.5mm(圖4~8)。

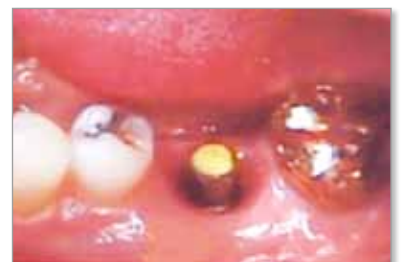Cement去除後，組織自然恢復健康 (圖9)。下面照片中可以清楚看到 abutment gingiva margin 位置的不同 (圖10,11)。



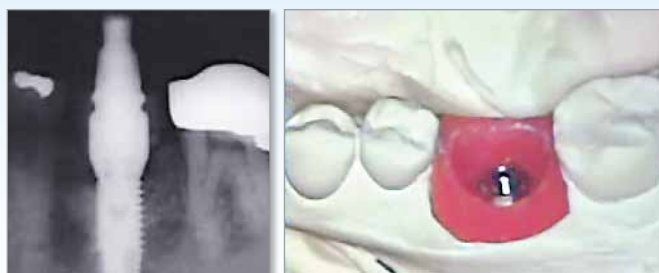■ 圖1：教導病人維持口腔清潔。



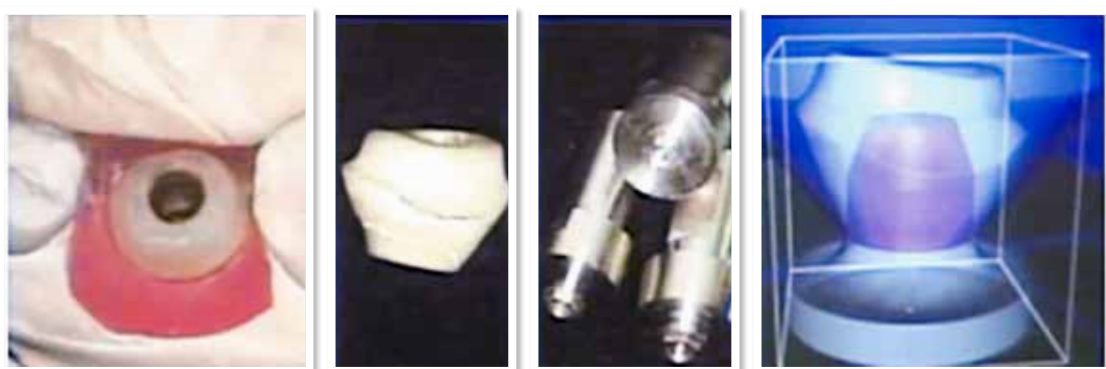■ 圖2：左下六植體假牙完成後，患者抱怨舌側容易流血不舒服。



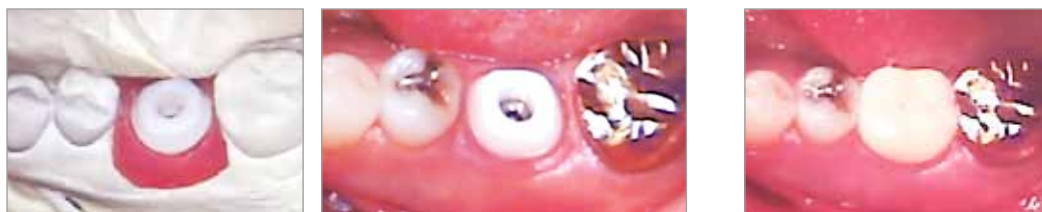■ 圖3：假牙拆除後，可看到相當深的 pocket depth。



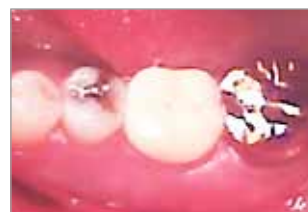■ 圖4、5：裝上pick up coping，重新取模。



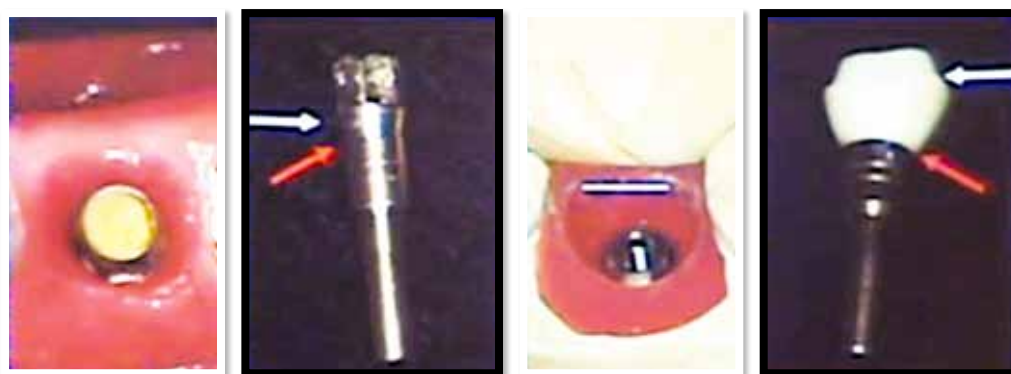
■ 圖6：利用 CAD/CAM tech.，製作 custom abutment，同時將 cement line 往上拉到 subgingiva 0.5mm。



■ 圖7, 8：Zr custom abutment 完成後，在病人口內試戴。



■ 圖9：假牙完成試戴，軟組織逐漸恢復健康。



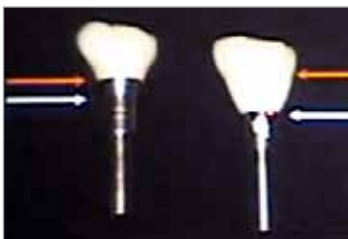■ 圖10：原本 abutment 取出後，IAJ 到 cement line 的距離只有約 3mm，但是軟組織高度約 7~8 mm，改使用 custom abutment 提高高度。

特別一提的是，custom abutment 的材質選擇應是 zirconia，而且必須是 unglazed，如此軟組織才會與之形成 hemidesmoson 的鍵結。Dr. Weland 在 paper 中提出，軟組織與 unglazed zirconia 及 titanium 的結合較為穩定，而 metal alloy 則會有 attachment apical shift 的情形發生。Clin oral implant res 2008 19(7) 635-41)

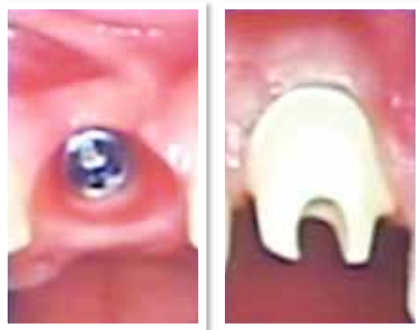Dr. Nakamura 也在文獻中提出，zirconia 表面較不易聚積牙菌斑。Int J Prosthodont 2010;23,288-309

以下兩種情況，建議務必製作 custom abutment。

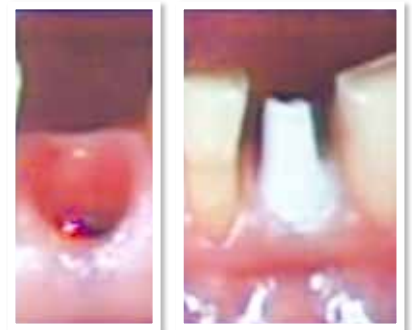1. 軟組織近遠心非常 scallop (圖12)
 2. 軟組織近遠心平坦但植體很深 (圖13) 如何避免粘劑殘留：
 - (1) 使用 custom abutment，控制 margin 的位置
 - (2) 在黏著之前先塞排齦線，避免粘劑留進去
 - (3) 使用 radiopaque 的黏劑，避免 radiolucent 的黏劑
 - (4) 假牙黏著後照張 x-ray 確認
- 還有其他方法嗎？使用 screw retained的prosthesis (圖14)



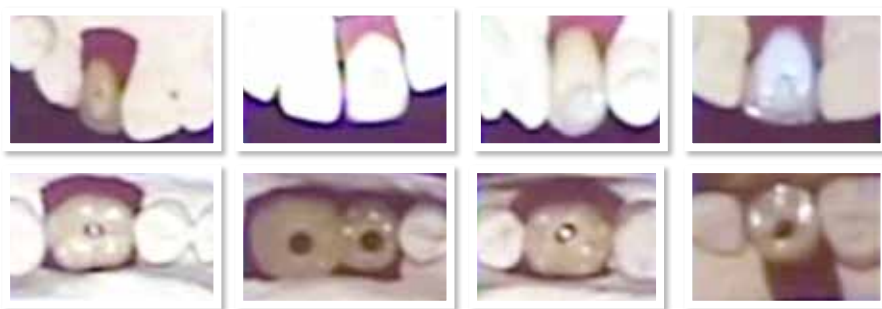
■ 圖11：
新舊 abutment 的比較，可發現明顯的 cement line 位置提高許多。



■ 圖12：軟組織近遠心非常 scallop



■ 圖13：軟組織近遠心flat，植體位置深



■ 圖14：各類前後牙區的screw-retained implant prosthesis

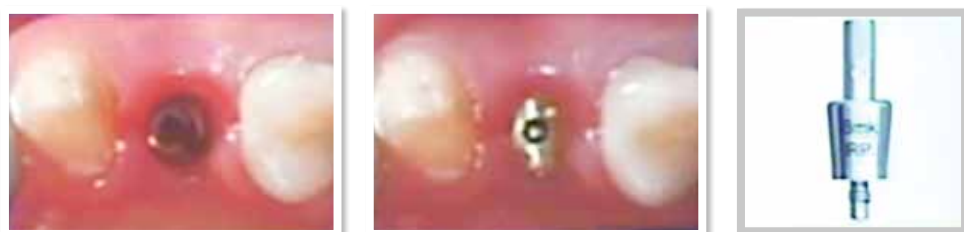Dr. Weber 提及隨著時間，cement-retained crown 的 plaque index 及 bleeding index 會越來越糟，而 screw-retained 的則相反，會越來越好。Clin oral implant res 17 2006 375-379

三、soft tissue prolapse

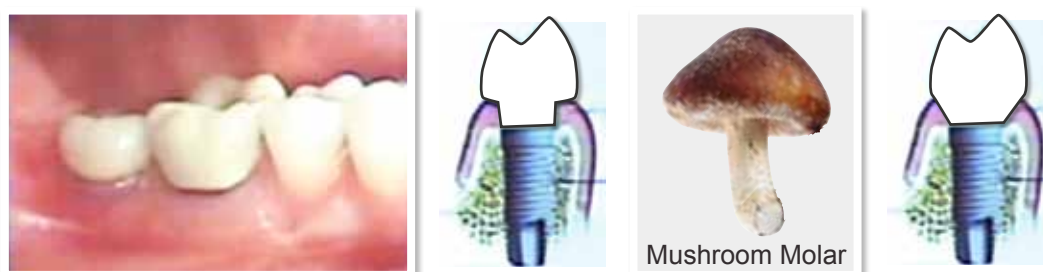
第三個 complication 是 soft tissue prolapse。這裡 Dr. Baldwin 要提醒的是：永遠都要在植體 上面放個東西撐住軟組織。例如：Branemark 有一個 soft tissue plug，只有兩個螺紋，但可以快速方便的鎖上植體，避免軟組織塌陷 (圖 15)。

四、gingiva hyperplasia:

以下的案例是病人抱怨假牙下有臭味、容易塞食物、容易流血、三不五時會腫起來。假牙拆掉後發現假牙呈現 mushroom molar 的形態，重新製作良好形態的假牙問題即消失。



■ 圖 15：當植牙醫師轉給補綴醫師印模準備製作臨時假牙時，為了避免周圍軟組織塌陷，Dr. Baldwin 有時會使用 soft tissue plug 來撐住軟組織形態



■ 圖 16：病人抱怨右下6植體假牙下有臭味、容易塞食物、容易流血、三不五時會腫起來，拆開後發現 transitional profile 處呈現香菇形狀，建議病人補綴物重新製作。

USC Comprehensive Surgical and Restorative Implant Training Program in Taiwan

南加大植牙專科進修課程 2012

時間：9:00am - 6:00pm

07/15 - 07/16, 2012(日、一 | 演講與實作 workshop)
08/12, 2012(日 | 視訊教學)
09/16 - 09/17, 2012(日、一 | 演講與實作 workshop)
10/14, 2012(日 | 視訊教學)
11/04 - 11/05, 2012(日、一 | 演講與實作 workshop)
12/09, 2012(日 | 視訊教學)
01/21-01/22, 2013(一、二 | 美國演講)
01/23, 2013(三 | 美國可選修的 cadaver workshop)
01/24, 2013(四 | 美國可選修的 cadaver workshop)
01/25-01/26, 2013(五、六 | 美國演講，畢業典禮)
01/27, 2013(日 | 美國可選修的 cadaver workshop)

地 點：集思交通部國際會議中心。台北市中正區杭州南路一段二十四號。(2012 年 7 月到 12 月)
Millennium Biltmore Hotel Los Angeles. 506 South Grand Avenue. Los Angeles, CA 90071 (2013 年 1 月)

報名費：

台北和美國課程 (包含 USC 牙醫學院發出的培訓證書)

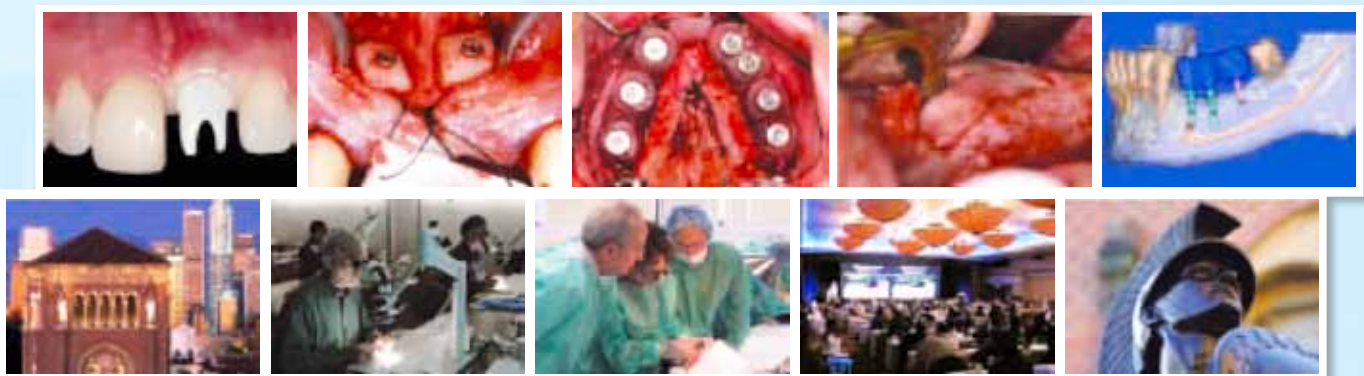- 6/1/12 前報名：美金 \$8,500
- 6/1/12 後報名：美金 \$9,000

台 北 課 程 (不含 USC 牙醫學院發出的培訓證書)

- 6/1/12 前報名：美金 \$5,950
- 6/1/12 後報名：美金 \$6,450

可選修的 Cadaver Workshops on Bone and Soft Tissue Grafting 課程 (不含 USC 牙醫學院發出的培訓證書)

- 9/1/12 前報名：美金 \$1,115
- 11/1/12 前報名：每一堂課美金 \$1,395
- 11/1/12 後報名：每一堂課美金 \$1,595



南加大講員陣容

Homa Zadeh ★ Avishai Sadan ★ Baldwin Marchack ★ Casey Chen ★ Domenico Cascione
Ilan Rotstein ★ Yang Chai ★ Songtao Shi ★ Parish Sedghizadeh ★ Ramin Mahallati

演講嘉賓：Stephen Wallace ★ Lyndon Cooper ★ Fernando Rojas-Vizcaya ★ Clark Stanford

• 欲知詳情，請與以下單位聯絡 •

USC 聯絡人：Julie

E-mail: julie.chen@usc.edu

Tel: +1-213-821-5281

Web: www.uscdentalce.org

Fax: (07) 615-0913

金牛頓藝術科技

聯絡人：黃思涵



Email: thhuang@newtonsa.com.tw

Tel: (03) 573-5676

In Esthetic Implant Dentistry 簡約植牙美學

March
23~25
2012

駕馭複雜・唯有簡單

	3.23 (Fri)	3.24 (Sat)	3.25 (Sun)	Keynote Speakers
08:30 09:00	報到	報到	報到	 Homayoun H. Zadeh, D.D.S., Ph.D. Associate Professor, USC
	"Implant Soft Tissue Management" Lecture & Hand-on	Satellite Symposia 衛星會議	Main Lecture	
12:00 13:30	"Implant Soft Tissue Management" Lecture & Hand-on	Main Lecture	Lunch table clinic Main Lecture	
17:00 18:30		會員大會暨選舉 Gala dinner		
				 Fernando Rojas-Vizcaya, DDS, MS Associate Professor, USC

兩岸牙醫就業論壇



王興 教授
中華口腔醫學會會長

Main Lecture



許榮仁 醫師
大龍、誠悅牙醫專科協同
醫療中心主治醫師



張慧男 醫師
新竹貝多芬
齒顎矯正中心負責人

PreCongress Program



李明科 醫師



陳文惠 醫師



雷曜寧 醫師

義大醫院牙醫團隊+Team Tainan

Venue : 義大醫院微創中心



張慧男 醫師

Newton's A



1.Keynote簡報的極致 2.iPad 行動溝通

101/3/24 (Sat) 09:30-12:30

最強keynote助教協助教學，
歡迎帶助理一起學習！

Keynote課程自備軟、硬體檢查表

- ☐ 蘋果電腦
- ☐ Keynote 09' 軟體
- ☐ 電腦預先充飽電

若無上述軟、硬體，請電金牛頓：
03-5735676，購買電腦另享有特別優惠，
歡迎團購電腦！

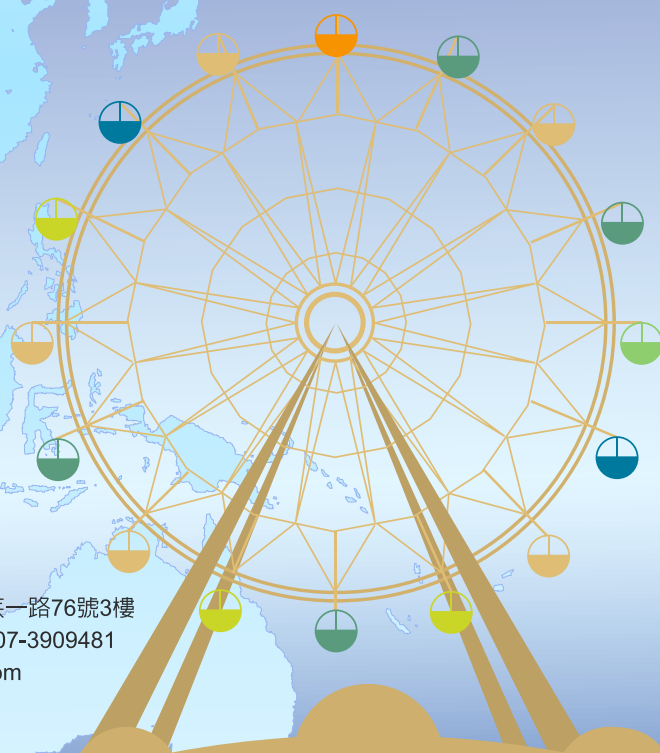
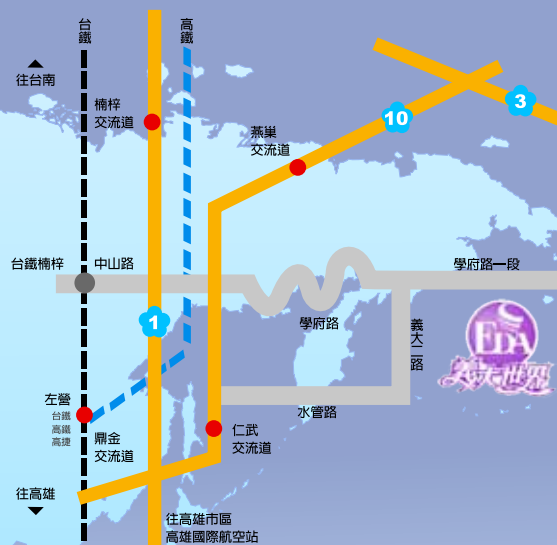
主辦單位：
台灣牙醫植體醫學會

電話：02-23076829 傳真：02-23076986
地址：108 台北市萬華區西園路二段300號8樓
E-Mail：judykung1368@gmail.com
www.taidimplant.org

承辦單位：
南台灣牙醫植體醫學會

地址：807 高雄市三民區民族一路76號3樓
電話：07-3945177 傳真：07-3909481
E-Mail：stcoi2005@gmail.com

義大交通資訊 Map



於金牛頓報名六、日大會活動，
優惠價5000元，報名專線：03-5735676

金牛頓藝術科技 地址：新竹市建中一路25號2樓

義大世界

地址：840 高雄市大樹區三和里學城路一段12號
諮詢專線：0800-656-077

【由仁武交流道下高速公路】

當矯正遇上植牙



2012 *Newton's A* Implant Forum

金牛頓植牙論壇

Implant Technique + DDX + Basic Knowledge

現在的牙科治療已經是各科統合彙整的時代，協同矯正、植體、牙周、補綴讓治療成果臻於完美是我們追求的目標。

邀請您一起迎接「協同性整合」的新牙科時代，讓我們從植體與矯正的對話出發，透過整合各科精華，締造集美觀、功能於一身的全方位治療。張醫師相信，儘管課程內容可能相似，但是貝多芬對於資料的呈現方式不一樣！唯有自己消化吸收後的整理，才是真正屬於自己的難能可貴的經驗，這就是貝多芬精神！

關於植牙論壇的定位與期許：

1. 將目前眾多植牙演講精華，重新整理過在自己的場合報告
2. 提供訓練平台供學員報告自己的case，從中相互學習。
3. 提升助教的演講技巧，培養新講師群。
4. 作為未來IAOI矯正植牙專科醫師考試的考前訓練班。



時間：2012年每月底週五

早上9:00-12:00

地點：金牛頓教育中心

新竹市建中一路25號2樓

費用：25,000元(單次2,500元)

2011/12/31前報名：

22,000元

費用包含講義、視訊

匯款帳號：109-25203060-000

戶名：金牛頓藝術科技股份有限公司

報名：03-573-5676

專線：黃思涵小姐

Join iAOI : <http://iaoi.pro>




2012 Implant Forum

	日期 (W5)	09:00 ~ 11:00	11:00~ 12:00	
		矯正 / 植牙病例分享	IAOI 試題文章導讀	
1	2/17	IAOI case presentation	Modified Drilling Sequence for Immediate Loading	Immediate Implant Loading
2	3/30	IAOI case presentation	Extraction Defect Assessment	Double Layer Tech.
3	4/27	外賓特別演講 曾春祺 醫師		
4	5/18	IAOI case presentation	An Interdisciplinary Approach to the use of Long-term Temporary Restoration	Interdisciplinary Management of Anterior Dental Esthetics
5	6/22	IAOI case presentation	Optimal Gingival Contours for the Single Implant	Screw-Retained Combined Crown-and-Abutment Prosthesis
6	7/27	外賓特別演講 彭玉秋 醫師		
7	8/31	IAOI case presentation	Minimally Invasive Dentistry	Modified Tunnel Technique
8	9/28	IAOI case presentation	Implant or Pontics: Decision Making for Anterior Tooth Replacement	Clinical Crown Discrepancies
9	10/19	外賓特別演講 許榮仁 醫師		
10	11/23	外賓特別演講 張燕清 醫師		
11	12/28	IAOI case presentation	Multidisciplinary Approach Using CAD/CAM Technology	Serial Extraction Protocol



南下高雄開業，迄今已逾十五年時間，邱醫師最感受用的，是她在三十五歲開業之初學會矯正，在四十六歲還沒得老花眼時學會了植牙。邱醫師坦言，在職進修必然造成壓力，它可能來自於時間、金錢與家庭，畢竟一天只有二十四小時，但終身學習所創造的成就感與報酬，卻讓她覺得當牙醫「真是好玩」，而且將持續下去，謹此與讀者分享。本文摘錄自2010最新一期《台大牙友》

邱丕霞醫師 邱丕霞牙醫診所負責人



*I*nternational *A*ssociation for *O*rthodontists & *I*mplantologists

For more information on benefits and requirements of iAOI members, please visit our official website: <http://iaoi.pro>.

Join the *iAOI*, the future of dentistry!

How to join iAOI?

Certified members of the Association are expected to complete the following three stages of requirements.

1. Member

Doctors can go to <http://iaoi.pro> to apply for membership to join iAOI. Registered members will have the right to purchase a workbook in preparation for the entry exam.

2. Board eligible

All registered members can take the entry exam. Members will have an exclusive right to purchase a copy of iAOI workbook containing preparation materials for the certification exam. The examinees are expected to answer 100 randomly selected questions out of the 400 ones from the iAOI workbook. Those who score 70 points or above can become board eligible.

The exam is one hour and the next session will be held on December 18 in Howard Hotel, Taipei, Taiwan.

3. Diplomate

Board eligible members are required to present three written case reports, one of which has to be deliberated verbally. Members successfully passing both written and verbal examination will then be certified as Diplomate of iAOI.

Ambassador

Diplomates will have the opportunity to be invited to present six ortho-implant combined cases in the iAOI annual meeting. Afterwards, they become Ambassador of iAOI and will be awarded with a special golden plaque as the highest level of recognition in appreciation for their special contribution.

iAOI 臨床案例報告示範

12/18
SUN



台北福華文教會館 1 樓 ▶ 前瞻廳 (台北市大安區新生南路三段 30 號)



林錦榮老師



韓國 Dr. Park



歐亦焜 醫師



張慧男 醫師

08:00-09:00 第一階段會員資格考

報名時間：自 100.11.15 (二) 早上 9 點至額滿為止。

報名方式：網路報名。

報名網站：<http://iaoi.pro/>

報名費用：將另行於 iAOI 網站上公告。

報名人數：限額 60 位醫師。

09:00-17:00 Case Report Demo

由張慧男醫師，

率領來自韓國的 11 位醫師 + 6 位優秀的台灣醫師，
呈現精彩的 Case Report，

並邀請國內矯正大師林錦榮老師、

國內植牙大師歐亦焜醫師以及韓國植牙大師 Dr.Park
擔任評論委員，是您不能錯過的精采演說！



Dr. Lee Sang-Taek



Dr. Ha Ju-won



Dr. Han Ung-Taek



Dr. Lim Jin-Su



Dr. Lee Jun-Ho



Dr. Jeong
Cheol-Woong



Dr. Kim
Jong-Cheol



Dr. Han
Chang-Hun



Dr. Jung
Joo-Sung



Dr. Yang
Sung-Woo



Dr. Choi
Jae-Heung



黃瓊嬋 醫師



蘇笙瑋 醫師



吳致賢 醫師



林伯磯 醫師



蕭浩宜 醫師



蔡鎰隆 醫師

08:00-09:00

iAOI online
examination

09:00-09:20

Registration

09:20-10:40

Case report

10:40-11:00

Break

11:00-12:20

Case report

12:20-13:30

Lunch,
UCLA certificate
presentation
ceremony

13:30-14:50

Case report

14:50-15:10

Break

15:10-16:30

Case report

16:30-17:00

Case report &
closing remarks



Feedback from the Vista & Sinus Lift Workshop



第一次接觸到 VISTA 的手術是在南加大的 learning course 看到 Dr. Homa 神乎其技的手術技巧，總覺得手術簡單，但真正的精隨又覺得很遙遠。直到張醫師說有開課並有 hands on 就迫不及待的報名（雖然南加大 2012 1月份有 cadaver 的實習）。

上課時張醫師從他的學習經驗，更有技巧的透過 live surgery 鉅細靡遺的教導 VISTA 的手術過程，輕鬆又幽默的教學方式真的獲益良多。

hands on 時親自用豬頭，羊頭來練習 surgery (包括 VISTA 及 Sinus Lift) 醫師之間互相學習教學相長，更是讓大家覺得不虛此行。

最後張醫師用香吉士來做縫線比賽，讓醫師們學習各種縫線術式的技巧更是一絕，這讓我對植牙的 soft tissue 的處理更上一層樓。

總之這個課程是很值得各位醫師的參與學習，可以讓醫師在植牙牙周甚至矯正的手術運用時更得心應手。



蕭家輝 醫師
星輝牙醫診所



您知道什麼是 VISTA 嗎？您會做 Sinus Lift 嗎？這些在過去多須要口腔外科才可能完成的手術，經由張醫師深入淺出的課程講解，讓我很快的知道，如何去完成 VISTA 及 Sinus Lift。

下午的 Hands-on 實習，則在貝多芬團隊的引導下，經由實際操作演練整個手術過程，讓我不再視此術式為畏途，回家後，不斷重複觀看金牛頓團隊所錄製的視訊內容，如此完整豐富的課程內容及完美有效率的團隊合作學習，就是要您一定學得會！

相信我可以，您也一定做得到！



張銘珍 醫師
禾森牙醫診所

Words from the Founder of Endo-Implantology Institute



The integration of implantology in orthodontic represents the 4th wave of knowledge transfer over the last 40 years. The oral surgeons were the first to integrate the art and science of implantology into their specialty as developed by Professor Branemark. Eventually and a decade later, as this special knowledge expanded beyond the limit of its initial artificial boundaries, a number of pioneer periodontists among whom Dr. Donald Callan started the incorporation and adaptation of implantology in their own specialty. Suffice it to say that this progress was not without generating a storm.



As the dust settled down, and being exposed to an increasing number of challenging endodontic cases, I started to question the validity of applying endodontic techniques based on predictability of outcome. The long term prognosis was becoming the primary concern. The "to re-treat or not to re-treat" rapidly evolved into the "to treat or not to treat" which really meant "to save or not to save" a tooth...that had just been referred for endodontic treatment. Heroic endodontics was at a turning point and there now were alternative treatments, to better serve our patients.

This paradigm shift in endodontic was born and with it a revival of the controversy of whom should have the privilege to practice implantology. In turn you are embarking in the courageous journey to integrate implantology into orthodontic. As Mahatma Gandhi also experience: *"First they ignore you, then they laugh at you, then they fight you, then you win."*

My warmest congratulation and encouragement for the first issue of the International Journal of Orthodontics and Implantology.

Wishing you the best to you and your journal for this journey of discovery and enlightenment.

Jerome H. Stroumza DDS MS DSc.

Founder of the EndoImplantolgy Institute, San Francisco, California USA
Faculty, Department of Orthodontics, School of Dentistry Indiana University

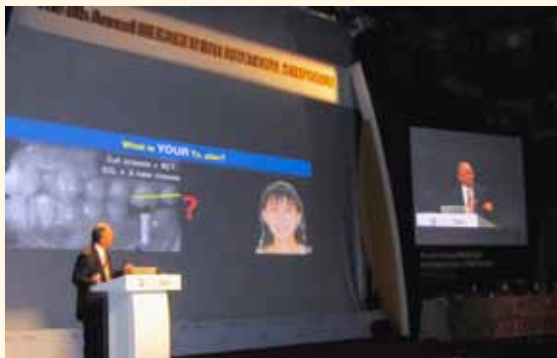Feedback from the 8th International MegaGen Symposium



Every implant therapy should be proceeded with orthodontic therapy for optimal prosthetic location. *The best way is simplest way, and simplest way is the best way in most cases. Dr. Chang is gifted in making orthodontic therapy as easy and simple as possible.* I agree with Dr. Chang that the most minimally invasive approach in implant therapy is no implant surgery by closing the space with orthodontics!



Dr. Samuel Lee
Harvard University



Dr. Chris Chang was speaking on Ortho-Implant connection in Milan at the 8th International MegaGen Symposium.



張醫師：

我是宏達電，你肯定會記得我的…哈哈！真的很感謝你，讓我能夠有自信的展現我的笑容。那天下飛機，家人看到我都說我變好看了，牙齒都到了該到的位置，好整齊（聽了好爽），你是怎麼辦到的？我說，因為我有一個很聰明很厲害的醫師。哈哈！然後一些朋友看到我，看到我都有一點驚訝。朋友說：你甚麼時候去開刀的？我說沒有，我只是矯正。酷吧！張醫師，我都說你厲害了吧！哈哈！

現在我每天都有乖乖的戴維持器，除了吃飯，刷牙以外，都戴著，就擔心牙齒會回到以前那樣。之前你給我的兩幅維持器，第一幅（拆矯正器當天給的）我戴上去比較舒服，不會有緊緊的感覺。第二幅（隔天拿的），戴上去後有一點緊，但是過後就ok了，這樣是正常的嗎？我每天交替戴，這樣ok嗎？

Dr. Chang, thank you so much! I really appreciated that your amazing hands to help me solve this difficulty work. Thank you!

Regards,

Honda

※本迴響作者之案例可參閱本期iAOI case：A Severe Skeletal Class III Open Bite Malocclusion Treated with Non-surgical Approach pp. 28-39

Beethoven Scholarship Reports



文馨的見習心得：

這三天我見識到一位令人驚訝、無比佩服的牙醫師。張醫師非常有創意，並且膽大心細，許多以前從沒想過的矯正方式在他手下好像變的也沒那麼困難。除了他本身知識、技術超群外，他還開辦了許多課程，提供願意學習的人許多機會，並且強調讓學習者多加練習、當場學會，是一個真正想要傳達知識的人。令人驚訝的還有助理的訓練，在張醫師的診所，可以看到非常能幹的助理幫張醫師分攤了許多工作（無論是製作病例、療程講解都“amazing”），讓他能夠專注在“只有他能做”的事上，節省了許多時間，讓他可以同時處理很多case又不至於錯亂。



除了張醫師的技術、診所的管理外，令我印象深刻的還有 keynote 的教學，以前總覺得電腦好難用，但就像張醫師說的，把難用的東西變簡單才是好的軟體，這個教學真是開了我的眼界。另外就是教我們寫履歷，一直到上了那堂課才知道自己的自傳還有許多可進步的空間，這些都是在學校學不到的。

謝謝張醫師，提供這麼棒的獎學金，不只讓我們開了眼界，也告訴我們什麼是好的學習態度，我永遠都會記得張醫師說的：每天做一點對的事情，累積起來絕對會有成就。

國防醫學院牙醫學系 李文馨



活動心得：

很榮幸能獲選參加貝多芬的獎學金見習，這三天豐富的行程讓我大開眼界，也感觸良多；即使已經在學校上過一整學年的課程，卻從來不曉得矯正是如此的簡單、直覺。

參觀安徒生兒童牙醫診所，和實地在貝多芬矯正中心見習，讓我們對專科診所的環境和經營有了深度的體驗；簡報訓練以及個人履歷撰寫要點的資訊課程，訓練如何表達自己，在求職的起跑點就能先跨出勝利的一步。這些對我們在未來的求學上有很大的幫助。

然而，在這趟見習之旅最讓我印象深刻的，是張慧男醫師所分享的成功哲學—『持續思考』。書讀得越多，思想難免都會被教科書所框架，這時候我們所要做的不是墨守成規，而是思考怎麼樣才能夠突破傳統，提供病患更簡單快速的治療。

感謝貝多芬給了我這麼棒的見習機會，期許自己未來也能夠像張醫師一樣，將所學回饋給更多的人。

祝 身體健康 事業蒸蒸日上



高雄醫學大學牙醫學系 李雙安

Feedback from the Keynote Workshop



參加了這次課程，才發現本來已經很好用的 Keynote，還有許多『隱藏秘訣』能讓操作更直覺、效果更流暢，實在非常感謝 Dr. Rungsi 及張醫師給大家這個機會，讓我們的 Keynote 功力又大大進步，也謝謝金牛頓辛苦的助教群！！

周思婷

高雄醫學大學附設中和紀念醫院牙科部



怎麼會有這麼棒、宛如藝術畫般的矯正用插圖？！怎麼會有那麼令人驚艷、歎為觀止的 keynote 呈現？！自從多年前有幸拿到 Dr. Rungsi 的 slides，他的美圖和動畫呈現，幾乎出現在我的每次演講當中！閒暇之餘，拆解 Rungsi 的 slides 也是我最大的樂趣～而今，大師的高效繪圖簡報 workshop，全球首度在台開課。昨兒個還在瞻仰、臨摹的大師與作品，今天真人現身、面前指導！！兩天下來，不時的驚歎與狂喜，原來圖像是這般巧妙的製作、而動態表現又是如此耗神。而現在，我完全學會與掌握了！！（握拳狀仰天大吼……）

Photoshop 的新課程，將在明年中舉辦。屆時，又會得到 Rungsi 大師多少的功力貫注，真是太讓人期待了～～



吳致賢 醫師
高美牙醫診所



過去常讚嘆張醫師的某些幻燈片為何可以畫得這麼漂亮，後來漸漸知道某些圖片是出自 Dr. Rungsi 的電腦繪圖，在金牛頓的安排之下，終於可以親身向 Dr. Rungsi 學習。

這兩天的高效繪圖簡報 workshop，真是個快樂的學習，我也第一次使用到繪圖板，利用軌跡弧線畫出各種牙齒的形狀，其他諸如 3D 的立體氣球等，更是過程中的高潮，期待明年中的 Keynote 6 課程。

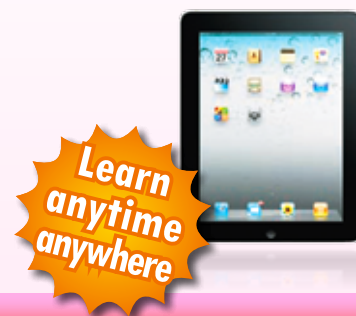

蔡誼德 醫師
欣典牙醫診所

Keynote 簡報繪圖精修課程 k4-k6 將於2012年6月9-11日開課，
欲報名從速，以免向隅！

貝多芬六大視訊系列課程

Beethoven Orthodontic Podcast Encyclopedia



10 Damon Q. Damon 矯正有聲基礎視訊課程十一大系列：

Session 1: <i>Ideal Case and Bracket Boding for beginners</i>	Session 7: <i>Retention and Relapse : Secrets of Constant Light Force</i>
Session 2: <i>4 stages of Orthodontics</i>	Session 8: <i>Case Demo and Analysis (1)</i>
Session 3: <i>Fast and Precise Anchorage</i>	Session 9: <i>Case Demo and Analysis (2)</i>
Session 4: <i>Extraction vs. Non-extraction analysis</i>	Session 10: <i>Case Demo and Analysis (3)</i>
Session 5: <i>Damon Diagnosis and Fine Adjustment</i>	Session 11: <i>Case Demo and Analysis (4)</i>
Session 6: <i>Biomechanics and Finish Examination</i>	

10 A. 矯正有聲進階視訊課程系列：

Session 1: <i>Crowding: Ext. vs. Non-Ext.</i>	Session 7: <i>Low vs. High Angle & Gummy Smile</i>
Session 2: <i>(U) Impacted Teeth: Ant. vs. Post</i>	Session 8: <i>Root Resorption & Relapse</i>
Session 3: <i>(L) Impacted Teeth: Ant. vs. Post</i>	Session 9: <i>Ortho & Perio</i>
Session 4: <i>Missing: Ant. vs. Post.</i>	Session 10: <i>Implant - Ortho</i>
Session 5: <i>Crossbite: Ant. vs. Post</i>	Session 11: <i>IDT</i>
Session 6: <i>Deep Bite vs. Open Bite</i>	

10 OBS. 有聲植體視訊課程系列：

Eng. C 有聲助理視訊課程五大系列：

Session 1: <i>Understanding Damon Instruments & Photography</i>	Session 4: <i>Impression; Retainer</i>
Session 2: <i>Initial Consultation; Treatment Intro; X-Rays</i>	Session 5: <i>Miniscrew; Damon Morph; Keynote OHI</i>
Session 3: <i>Bonding; Recognizing Damon wire;</i>	

F. 有聲精修視訊課程系列(一)：

Session 1: <i>Introduction of excellent finishing</i>	Session 7: <i>Impacted canine</i>
Session 2: <i>Concepts of growth & development</i>	Session 8: <i>ABO demo</i>
Session 3: <i>Early stage of development</i>	Session 9: <i>Orthodontic treatment planning</i>
Session 4: <i>Later stage of development</i>	Session 10: <i>Retrospect & prospect</i>
Session 5: <i>Etiology of orthodontic problems</i>	Session 11: <i>Class II low angle</i>
Session 6: <i>Orthodontic diagnosis</i>	

IF. 有聲植牙論壇系列：

Session 1: <i>Implant desgin</i>	Session 7: <i>Esthetic implant</i>
Session 2: <i>GBR</i>	Session 8: <i>Sinus Lift</i>
Session 3: <i>Immediate implantation</i>	Session 9: <i>STM</i>
Session 4: <i>Intrusion & forced eruption</i>	Session 10: <i>Save vs extraction</i>
Session 5: <i>Vista</i>	Session 11: <i>Prosthesis and sinus lifting</i>
Session 6: <i>Ortho-Implant Posterior</i>	



貝多芬創辦人：張慧男醫師

- 中華民國齒顎矯正專科醫師
- 美國齒顎矯正專科醫師學院院士 (ABO)

- International Journal of Orthodontics & Implantology 發行人
- 美國印地安納普渡大學齒顎矯正研究所博士

貝多芬牙科團隊 A Learning Organization

文 / 陳建綱、徐玉玲、黃思涵、蘇荃瑋

引言

貝多芬，是世界知名的音樂家，但是在台灣，他同時也是一家牙醫診所的名字。在知名的搜尋引擎 Google 中鍵入關鍵字「貝多芬」，在第五個順序就會自動出現「貝多芬牙醫」，點入之後有將近六千筆的結果，可見民眾在網路上想要去了解「貝多芬牙醫」的熱烈程度。

貝多芬牙醫團隊簡介

貝多芬牙科團隊是由張慧男醫師領導，從矯正牙科出發，包含「貝多芬一般牙科」、「安徒生兒童牙科」牙周病專科、鑲復專科等牙醫專科醫師及優秀的牙醫助理團隊所組成。此外，強調以「學習」為核心價值的貝多芬團隊還另外成立「金牛頓藝術科技」，專職負責牙醫資訊科技，醫療器材研發以及牙科教育推廣的工作。為了能提供更完整的牙科照顧，我們也即將在明年成立「植牙中心」，希望能讓有缺牙困擾的民眾更全面的治療環境。

貝多芬矯正中心-環境介紹

一進到貝多芬矯正牙科，櫃台美麗

而親切的助理立即起身招呼，眼前寬敞的候診區以及初診病患的諮詢台，周圍不僅有整排的書櫃，有各種張醫師精選的書刊提供候診病患自由選擇，最難能可貴的是大面積的落地窗，讓光線自然而豐富的灑入，舒適而且無壓。

向內進入看診區，同樣的還是一整排的落地窗，這對於整天在診所內工作的牙醫師而言，這真是一個天堂！因為只要自然的一抬頭，就可以看到窗外中庭的綠樹，可以讓工作中的壓力與緊張感自然的舒緩；看診區是開放式的安排，且前方有足夠的陪診空間，方便醫師與家長溝通，或是讓候診病患能 standby，這樣的設計方便順暢的處理大量病患。

診療台後方的供應區，主要是擺放看診器械及病歷資料，讓所有的治療過程都能有足夠的後援，供應區台面上的 Apple 桌上型電腦 iMac 也提供醫師在治療時所需要的資訊，而櫃台掛號資訊系統也整合在 iMac 裡面了，病患看診結束，助理也及時的將病歷記錄和照片輸入完成。當然囉，所有的工作站之間都是內部網路連線的，這樣，不管醫師走

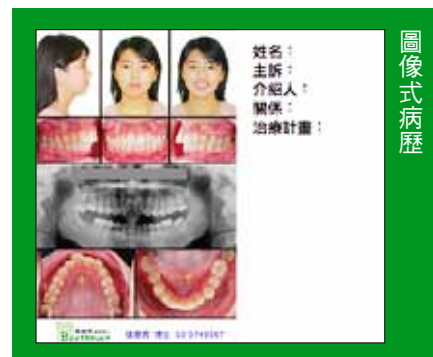

診療區

到哪裡，只要有電腦，配合診療過程，所有的病例資料都可以一覽無遺。

貝多芬矯正中心-診療運作系統

貝多芬矯正最值得研究的，應該是它的診療運作系統。診所內的每日看診病患量非常大，而且每天到診所內支援的住院醫師及專科醫師組合都不相同，但是對於病患的處理卻都能依照標準作



圖像式病歷

業流程，按步就班的貫徹張醫師為病人量身訂作的治療計畫，而且效率依然一流！這要歸功於精簡明瞭的病歷設計，不論病患的外觀、口內照片、主訴、基本資料、治療計畫、拔牙位置、特殊發現等，都整合在一張病歷紙上，一目了然！每位住院醫師只要看到病歷上的指示，依照標準操作方式完成每個病例每次的調整，不管是由誰操作，治療的結果都能成就完美。這表示，只要診斷正確，貝多芬矯正牙醫的標準作業流程如果複製到其他牙醫診所，每一位醫師都能如此輕鬆、快樂、有效率的完成矯正治療！



韓國名醫 Dr. Park 夫婦（前排左一、左二）訪貝多芬。

貝多芬團隊 BEETHOVEN

OBS 繼續教育



印尼國際班醫師認真在模型上練習植入迷你骨釘。

也許大家都會有疑問，住院醫師的訓練不是應該經過4~5年嗎？為什麼大家都這麼快的進入狀況呢？我想答案應該是「標準訓練流程」。所有的住院醫師都需要經過張醫師的矯正基礎班、進階班的訓練，然後繼續在精修班中逐漸精進成熟。張醫師的教學活潑而且與門診同步，您很難看到萬年不變的教材幻燈片，因為張醫師自己一直在進步。我們會看到就在上個禮拜或是昨天門診中遇到的病例，及時的套入當天的課程主題，而且更令人驚奇的是，當天上完的課程，下午的門診病患裡就有同一類型的病例，真是現學現用零時差！

貝多芬矯正中心-國際化課程

張醫師所設計的課程，不光適合國內醫師，就連國外的醫師也都踴躍報名參加 international workshop，每個梯次的報名都非常踴躍，學員們結業後都說還要再來參加，可見張醫師的課程魅力非常吸引人！張醫師也同時與國際接軌，國際間的演講邀約不斷，漸漸的成為另一個台灣之光！另外，每每只要有國際學者到台灣演講，張醫師有機會都會邀請他們參觀診所，張醫師會為他們簡報介紹診所的運作以及訓練課程，我們看到這些國際大師他們專注而且驚訝的表情，相信貝多芬牙醫在他們心中都留下了深刻的印象。

貝多芬矯正中心-出版專業刊物

International Journal of Orthodontics & Implantology

貝多芬矯正中心經過張醫師十幾年來的經營，深獲病人的信任與支持，除了提供矯正專業服務外，張醫師也致力於繼續教育的開辦以

及國內外學術活動的交流。為了让更多牙醫師能有一個實務交流平台，張醫師也出版了一份著重牙科實務經驗分享以及報導國外矯正新知的季刊「International Journal of Orthodontics & Implantology」，邀請國內外知名牙醫師分享他們臨床上的秘訣，並且透過此平台也讓貝多芬矯正的理念能夠透過教育，傳達給認同這份精神的醫師，並且對學習充滿熱忱，不斷精進。

貝多芬醫療團隊

貝多芬醫療團隊，當然不是由張醫師一個人單打獨鬥，我們面對的是廣泛的病人群，年齡從0歲到99歲。沒關係，小的可以送到安徒生兒童牙醫，年長者有廣復專科解決您「無牙」的問題，牙周病及植牙方面有牙周專科醫師，其餘如口腔外科及根管治療、一般牙科都有專人負責，因為都是團隊內轉診，團隊醫師群共同來照顧，對於治療計畫的擬定及溝通較為直接且方便，對於病患的照顧當然是無微不至。

當然，有一群像貝多芬牙醫的全能助理是必要的。助理群也是貝多芬牙醫治療標準流程的重要關鍵！每一位新病人從進入診所開始，就由專業的公關組助理引導填寫基本資料，並介紹環境及諮詢流程，並且拍攝收集病患的口外及口內照片、取模。而在每日的門診治療流程，則由資深的助理組長來指揮，跟診助理引導回診病患就診前刷牙，看診前對病患的關心及詢問，器械準備好了之後由住院醫師先執行治療計畫，之後由張醫師檢查、微調。最後再由助理來指導病患口腔衛教，橡皮筋的佩戴、術後注意事項…等等，然後結束回診流程。助理在病患及醫師之間，扮演重要的關鍵角色，就像鋼筋永遠需要水泥一樣，如果您診所的助理還沒能達到您的理想，請參加貝多芬舉辦的專業助理訓練班吧！



貝多芬醫師團隊。

貝多芬團隊 BEETHOVEN

安徒生兒童牙科 守護孩子口腔的健康

安徒生兒童牙科 - 緣起

在貝多芬矯正中心與一般牙科深耕新竹公學新村社區多年後，社區的里長跑來跟貝多芬院長張醫師反應說，社區的孩子牙齒痛都需要跑到市區才能得到專科的照顧，里長代表社區的家長們希望貝多芬也能在社區開一個專門為兒童設計的兒童牙科。因為聽到社區民眾的心聲，以及許多在貝多芬做矯正的家長也在反應一樣的需求，2008年元旦我們開設了「安徒生兒童牙科」。安徒生的院長徐玉玲醫師表示，安徒生的理念是希望能塑造一個父母安心，孩子開心的看牙環境，提供永續優質的服務，照護不僅是孩子的口腔生理與心理的健康。



診療台頂上就是繽紛的花朵，讓孩子徜徉在童話的懷抱裡。

金牛頓藝術科技 牙醫科技教育中心

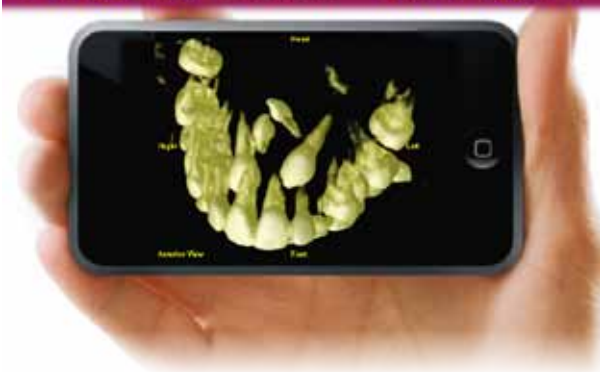成功的牙醫師們經常要面臨的兩難就是，想學的新技術這麼多，永遠抽不出足夠的時間讓我們好好坐下來，完整地聽一場演講或是從頭到尾讀完一本新書。金牛頓藝術科技將貝多芬精湛的臨床技術以及完整的教學系統，透過蘋果科技的硬體 iPod touch 以及軟體 Podcast，變成隨時隨地可以學習矯正的行動學習工具，已經掀起國際矯正界的一場學習旋風。

金牛頓藝術科技-

行動學習 iPod touch + 視訊課程

張慧男醫師率先研發將 Damon 高效矯正、迷你骨釘 OrthoBoneScrew 以及助理訓練這三種屬性完全不同，但是又與牙醫師在職教育密切相關的課程，透過蘋果電腦內建的簡報軟體 Keynote，製作成以照片和影片為主的簡報檔案，再透過軟體本身內建的轉檔功能，將平時授課的電腦簡報內容轉化為視訊影片，並安裝在 iPod touch 或 iPad 裡。不論是已經上過課希望溫故知新，或是沒時間親自來上課的牙醫師，都可以透過反覆觀看這些包含清楚分解動作的視訊影片，來增強高效學習的效果。由於 iPod 視訊課程是完全數位化的內容，也方便日後任何的修改和更新，所以完全不用擔心一旦有新的修正或改變，過去已經購買的珍貴資料就變成明日要被淘汰過期的垃圾。

What is Your Tx. Plan?



安徒生兒童牙科 - 環境介紹

診所以經典童話作家安徒生命名，將耳熟能詳的故事，如國王的新衣、賣火柴的小女孩、拇指姑娘融入診所的場景中，並結合童趣的想像信手塗鴉，留予親子間歡欣共處的童話氛圍。希望在寶貝的成長過程中，看牙不只是為了健康，也能是一件有趣、親子同樂的經驗。從依孩童身高設計不同高度的刷牙檯面，兒童專屬的廁所，到兒童專屬的遊戲區和閱讀區，安徒生從許多細節裡體現一個以兒童為中心的診療環境。

安徒生兒童牙科 - 長期完整保留兒童口腔資料

對兒童牙科而言，安徒生希望能提供的是長期照護，因為生長的過程中，除了心理上漸漸與小朋友建立關係之外，在口腔顏面發育的部份更希望能透過口內外照片的收集與追蹤，充分掌握整體口腔健康，骨骼生長的情況。所以，為了達成這個目的，每位孩子的資料完整收集，電腦傳輸方式以及大量資

訊的統整合理，安徒生都採用最先進的軟硬體技術，高畫質數位單眼相機與即時無線傳輸直接到個人病歷，以及蘋果電腦方便的雙作業系統界面功能，兼顧健保作業及儲存個人影音記錄等作業系統。一點一滴地保存所有小朋友的生長及看牙記錄，藉以提升學術及研究與服務品質。

安徒生兒童牙科 - 兒童衛教

預防勝於治療，尤其是幫年紀尚幼的孩子處理蛀牙更是一項挑戰父母與醫師心臟的浩大工程，有鑑於此，衛生健康教育應向下紮根，所以安徒生兒童牙科除了現在已有幼稚園定期來院檢查塗氟之外，希望還能定期為社區媽媽充實口腔知識以及提供一對一教學，幫助媽媽們從小幫助孩子養成正確的觀念與習慣。另外與孩子口腔健康有切身相關的領域，就是乳牙幹細胞的培養。有鑑於國內外此方面的研究發展已漸臻於成熟，聰明的爸媽除了自寶寶出生後打好口腔健康的基礎，更要懂得保存未來的本錢。

金牛頓藝術科技- 教學利器蘋果電腦+Keynote

金牛頓除了提供牙科專業視訊課程外，也負責設計、規劃、維護貝多芬牙醫團隊的教學資訊環境。舉例來說，日前台大張心涪主任帶著目前仍在美國接受矯正專科訓練，正好回台休假的女婿來參觀貝多芬。診所當天剛好有一個門診手術的個案，訓練有素的助理們有些協助醫師執行臨床上的步驟，有些則進行手術過程的攝影及錄影。待手術過程結束後，助理立刻就將手術的照片放入病人專屬的 Keynote 簡報檔案中，連同病人過去的病例照片，以及剛才的手術錄影畫面，一起整理在這個病人的電子病例檔案中。執刀的醫師則立刻在電腦銀幕上秀出這個病人的治療歷程，向病患及家屬說明治療的進程以及療效，之後則繼續利用這個案例與張醫師進行深度的專業個案討論。討論結束後立刻將這個案例的電子檔燒成光碟，讓張醫師和他的女婿可以帶回去做進一步的研究。

一般醫師可能認為這需要幾個實習醫師花上一個星期才能做出來的病例報告，利用適當的科技工具，這一切在短短

的30分鐘內就全部完成了，不論是與病人，家屬溝通，訓練新進醫師、助理或與其他資深醫師進行專業討論，蘋果電腦加上 Keynote 的組合，讓進行個案討論和製作專業訓練教材，變得輕而易舉。再搭配 Keynote 最新加入的即時錄音功能，醫師教學講解的內容可以透過電腦內建的麥克風錄下來，透過影片轉檔的功能，新製作好的教學內容就可以放入 iPod，讓你立刻隨身帶著走。

金牛頓藝術科技- 研發迷你骨釘 OrthoBoneScrew

由貝多芬矯正中心的實務經驗出發，張慧男醫師領導開發矯正用的迷你骨釘，金牛頓的研發團隊包含國內外學界專家如 University of Indiana-Purdue 牙醫所所長 Dr. Eugene Roberts 教授，中央大學林上智教授，以及國內知名矯正醫師林錦榮醫師等。兩年來不斷改進，深受國內醫師的喜愛。透過矯正骨釘的使用，可以大大減少因為矯正需要拔牙的機率，傳統上某些特殊需要接受手術矯正的案例也可以透過骨釘獲得不錯的治療效果。

貝多芬團隊 BEETHOVEN

金牛頓植牙中心 毋需再為缺牙遮掩 牙周照護的守護者

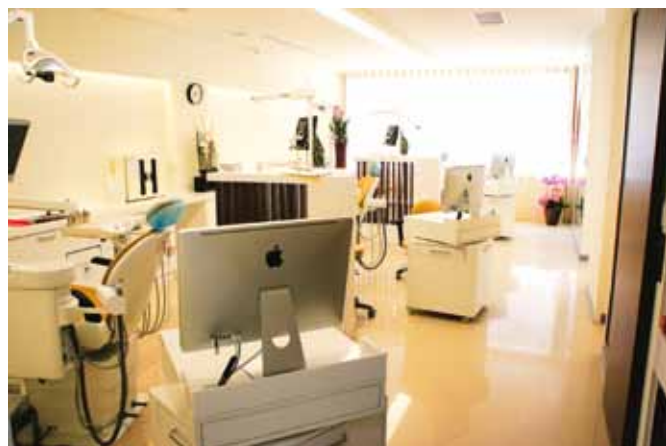

過去一般認為成人的牙科治療只需要兩個專科；牙周與補綴，但我們現處於強調 inter-disciplinary 科際間協同治療的時代，其中，矯正與植牙更是扮演了協同治療中最重要的兩個支柱，矯正提供了地基，植牙則是房子的樑柱。因此，金牛頓植牙中心的成立，是為了要提供病人更完善的治療，以及建構更完整的貝多芬醫療專業體系。在各科統和彙整的時代，協同矯正、植牙、牙周、補綴讓治療成果臻於完美是我們不斷追求的目標。



植牙中心承襲著貝多芬體系一貫的明亮且視線延伸的看診空間、自在輕鬆的候診區域，我們更期望植牙中心的成立象徵貝多芬體系邁向科際整合的下一個里程碑，除了配置3D斷層設備，提供矯正關於阻生齒方位的診斷以及植牙時骨質骨量相關資訊等跨科的支援外，也擔任貝多芬體系各專科診所間雲端 e 化的後勤，以蘋果電腦為媒介，將2D X光，3D斷層，電子病歷，跨科治療計畫擬定，患者解說與案例介紹，案例整理，教育課程訓練於雲端整合，跨科分享共同資源，利用科技的運用提高就診效能與促進科際協同。

張醫師曾與我們分享到他人生重要的轉變點，那就是遇見 USC 的 Dr. Homa 與 UCLA 的 Dr. Park！透過矯正與植牙跨科的交流，相互激盪絢麗的火花，並一同思考著整合的未來性。因此決定在今年成立了國際矯正植牙學會 iAOI (International Association of Orthodontists & Implantologists)，也將原先矯正趨勢雜誌 NTO 創新改變成 iJOI (International Journal of Orthodontics & Implantology)。金牛頓植牙中心將繼承貝多芬體系的核心價值：終生學習，更以落實教育當做成立的最高宗旨，透過學會的建立，讓各個醫師擁有相互溝通分享的舞台，張醫師相信，唯有在學會課程中將自己的病歷報告給參與的醫師分享，才會真正的將自己治療心得內化成有系統的 SOP。透過一次次的整理，相互討論，無形中提昇了醫師的專業能力，醫療品質也相對提昇。這亦是張醫師執業多年秉持著的精神“點滴改進，盡心盡力”。期望對學習有相同熱忱的醫師能夠一起加入我們，一起為提昇醫療品質做努力。



e 化示範病例衛教

e-Consultation



矯正 Orthodontic

1. 初診流程
2. 簡易矯正案例
3. 進階矯正
4. Morph 矯正案例
5. 矯正衛教
6. 矯正利器
7. 診間 iPad 運用

Orthodontics

1. Initial consultation
2. Common demo cases
3. Advanced demo cases
4. Morphing cases
5. Orthodontic health education
6. Orthodontic appliance application



植牙 Implant

1. 初診流程
2. 植牙評估流程
3. 植牙案例類型介紹
4. 植牙相關療程介紹
5. 微創手術 VISTA

Implantology

1. Initial consultation
2. Clinical evaluation
3. Common demo cases
4. Introduction of Implant services
5. Minimally invasive surgery : VISTA



兒牙 Pedit

1. 初診流程
2. 治療流程
3. 特殊裝置
4. 潔牙衛教
5. 兒牙常見問題

Pedodontics

1. Initial consultation
2. Treatment process
3. Special appliances
4. Dental hygiene
5. Common Q & A





Anytime

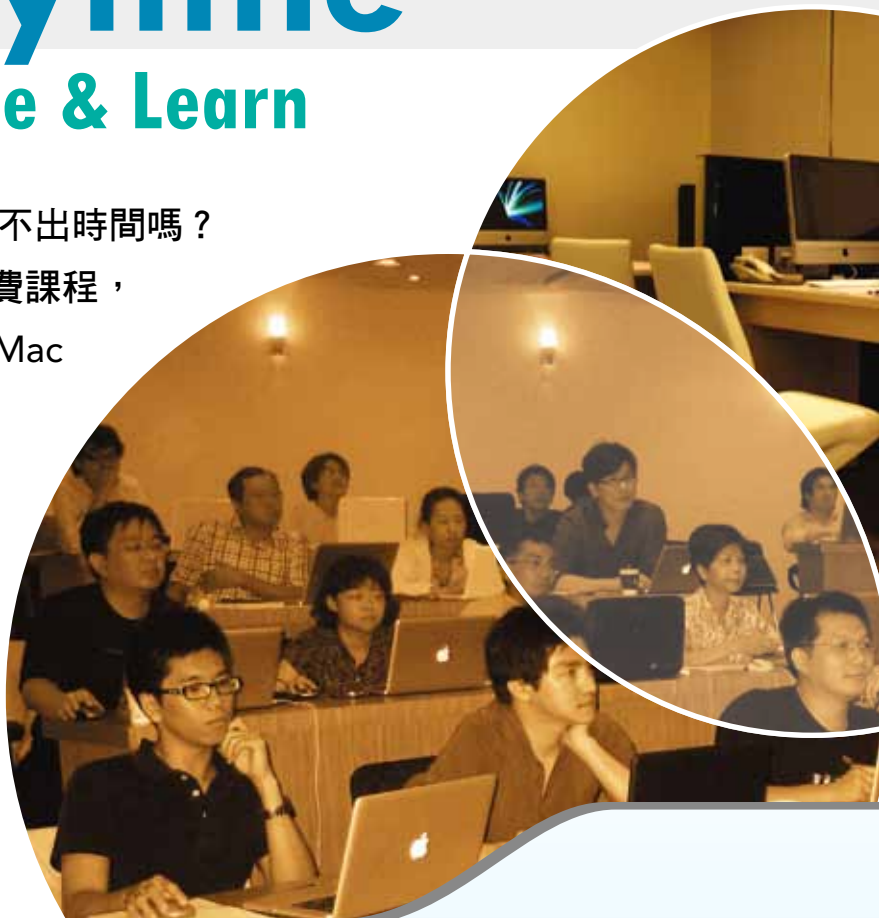Come & Learn

想上 Mac 的課程可是週末總是抽不出時間嗎？
來金牛頓預約最新的免費課程，
讓您 learn Mac

anytime you want!

課程預約專線
03-573-5676

詳細辦法請上
<http://www.newtonsa.com.tw>



Newton's A Winter 11' course schedule

類型	課程名稱	內容	開課日期	上課對象
專業簡報	Keynote 簡報法 series 1 簡報聖經	1. 常見簡報謬誤 2. Keynote 入門	12/22、2012/8/16 (四) 09:00 ~ 17:00	科技人、醫師 教師、學生
專業簡報	Keynote 簡報法 series 2 Kokich 的 10 大演講秘訣	1. 多媒體影像處理 2. 簡報設計	2012/1/12、9/20 (四) 09:00 ~ 17:00	科技人、醫師 教師、學生
專業簡報	Keynote 簡報法 series 3 How to Wow'em like Steve Jobs?	1. 賈伯斯演講秘訣 2. 簡報設計進階應用	2012/2/16、10/18 (四) 09:00 ~ 17:00	科技人、醫師 教師、學生
專業簡報	Keynote 簡報法 4-6 繪圖精修課程	1. How to use a digital drawing board. 2. Design illustration in your Keynote. 3. Showcase your own drawing with stunning animation in Keynote. 4. Create complicated diagrams using Adobe Illustrator and Photoshop. 5. Animation Competition	2012/6/9,10,11 (四) 09:00 ~ 17:00	科技人、醫師 教師、學生
International	Damon and OBS workshop	1. Damon System 2. OrthoBoneScrew	2012/6/12-14 11/13-15	International Orthodontist

For comfort & retention of elastic chain
磨菇頭部外型

For lever arm to solve impacted tooth
方形角線釘孔

For ease of hygiene control & extra attachment
離頸部設計



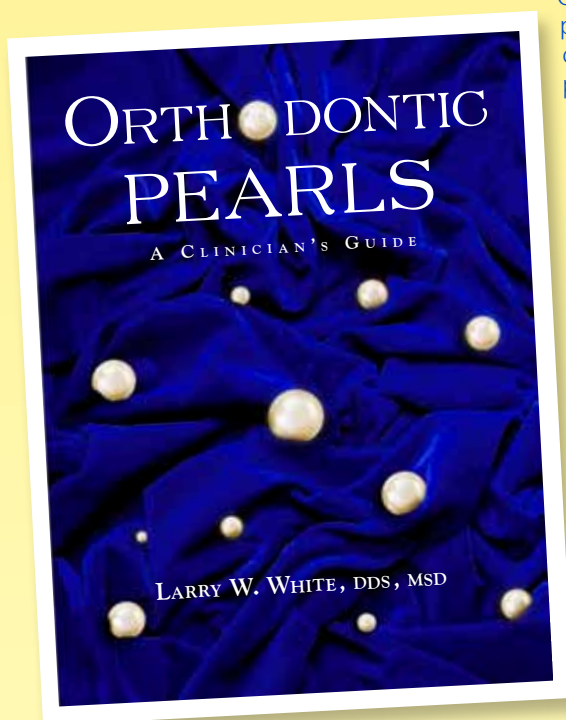
Ortho Bone Screw

矯正專家強烈推薦

Order: +886-3-573-5676 Ms.OBS

For more information, visit <http://orthobonescrew.com>

Orthodontic Pearls *A Clinician's Guide*



Orthodontic Pearls satisfies a longtime professional goal of collecting and publishing some of the best and most useful “little ideas” that orthodontic clinicians use to simplify and improve the therapies they deliver to their patients. Some of these “pearls” have become such an important and ubiquitous part of doctors’ therapeutic routines that they no longer feel special in any way, but they are, and they will prove absolutely new and useful to other doctors.

The entire book rests on the premise that all of us are a lot smarter than any single one of us. By training and patient expectation, dentists are therapists, and most of the pearls will relate to therapeutic remedies for orthodontic problems, but while encouraging doctors and office personnel to participate in this enterprise, I purposely did not try to limit the subjects they would address. Any and all ideas that expedite and simplify the delivery of orthodontic treatment to patients were welcomed. You will read tips on patient management, diagnosis and treatment planning, compliance issues, personnel solutions, and office management in addition to orthodontic therapies.

Orthodontic Pearls purposely has no chapters nor a firm structural organization. The pearls have a chronological arrangement — I inserted the images and narratives as I discovered or received them. Some donors shared single ideas, while others supplied multiple pearls at different times and sometimes all at once. This offers readers the most eclectic array of orthodontic nuggets ever accumulated in one publication, and one which I hope will enrich orthodontists and their patients for years to come.

Larry W. White, DDS, MSD



Drs. Charlie Burstone (front left), Katherine Kula (front central), Eugene Roberts (front right)

Dr. Chris Chang (back central) was invited to speak in the 2nd Burstone International Biomechanics Symposium, together with experts from Japan, Korea and the US, on TADs.

