

Simplified Mechanics for Gummy Smile Correction

Abstract

This case report describes the interdisciplinary treatment of a 25-year-old woman presenting with chief complaints of bimaxillary protrusion and excessive gingival display ("gummy smile"). She was dissatisfied with her previous non-extraction orthodontic treatment, rendered at age 10. The Discrepancy index (DI) for this severe malocclusion was 21. Orthodontic treatment involved extraction of four premolars to correct protrusion, and skeletal anchorage via four miniscrews (2 anterior and 2 posterior) to intrude the entire maxillary arch. Space closure utilizing maxillary extra-alveolar (E-A) bone screws reduced lip protrusion and the anterior miniscrews were used to intrude the maxillary incisors. Following orthodontics, surgical crown lengthening was performed in the maxillary anterior segment. 32 months of interdisciplinary treatment resulted in a near ideal result as evidenced by a Cast-Radiograph Score (CRE) of 15 and Pink & White (dental esthetic) score of 3. (Int J Ortho Implantol 2017;47:72-91)

Key words:

Class I malocclusion, bimaxillary protrusion, surgical crown lengthening, self-ligating appliance, gummy smile

History and Etiology

A 25-year-old woman presented with a history of non-extraction orthodontic treatment, and a labial frenectomy to close the diastema between the upper central incisors, at age 10. The current concerns were bimaxillary protrusion and a gummy smile (Fig. 1). A functional exam documented lip incompetence with a hyperactive mentalis muscle to achieve lip closure. Clinical examination revealed a severe bimaxillary protrusion, gummy smile, lip incompetence and short clinical crowns. Mild crowding was noted in the lower dentition (Figs. 2 and 3). Comprehensive orthodontic treatment and surgical crown lengthening resulted in a pleasing outcome as documented in Figs. 4-9.

Diagnosis

Skeletal:

1. Slightly retrusive mandible (SNA 78°, SNB 75°, ANB 3°)
2. High mandibular plane angle (SN-MP 41°, FMA 32°)

Dental:

1. Class I molar relationship, midlines were coincident
2. Short clinical crowns due to altered passive eruption, type I, B
3. Overjet (5mm)

Dr. Chris Lin,

Associate editor, Beethoven Orthodontic Course (Left)

Dr. Yvonne Wu,

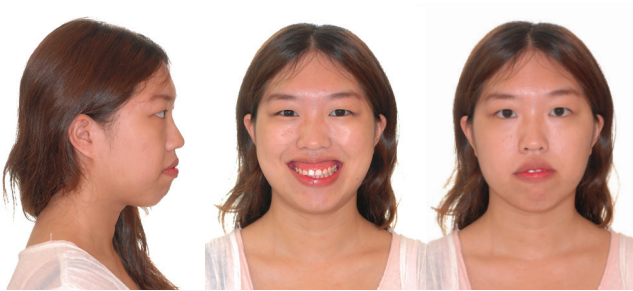Board eligible, Beethoven Orthodontic Course (Center Left)

Dr. Chris Chang,

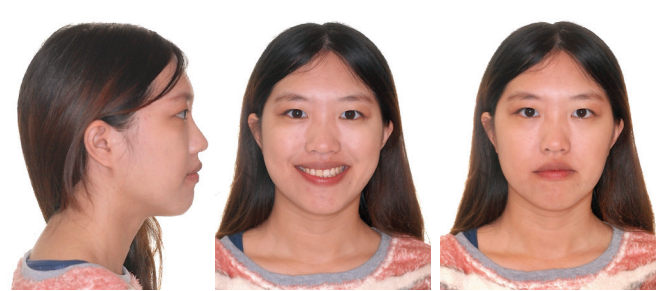*Founder and president, Beethoven Orthodontic Center, Hsinchu, Taiwan
Publisher, International Journal of Orthodontics & Implantology (Center Right)*

Dr. W. Eugene Roberts,

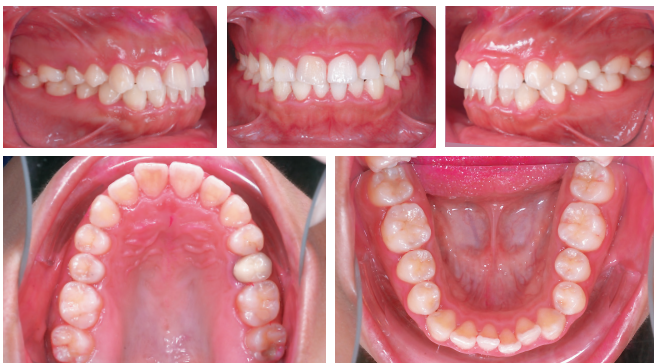Editor-in-chief, International Journal of Orthodontics & Implantology (Right)



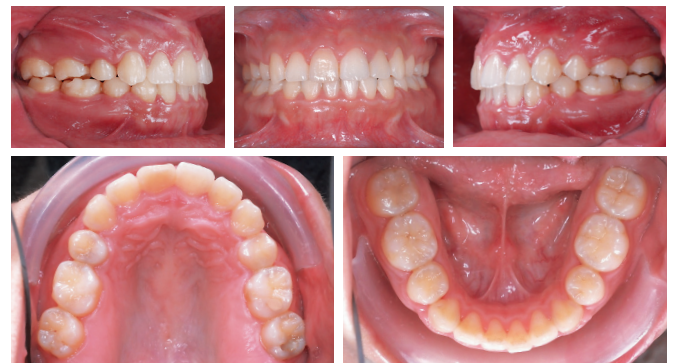■ Fig. 1: Pre-treatment facial photographs



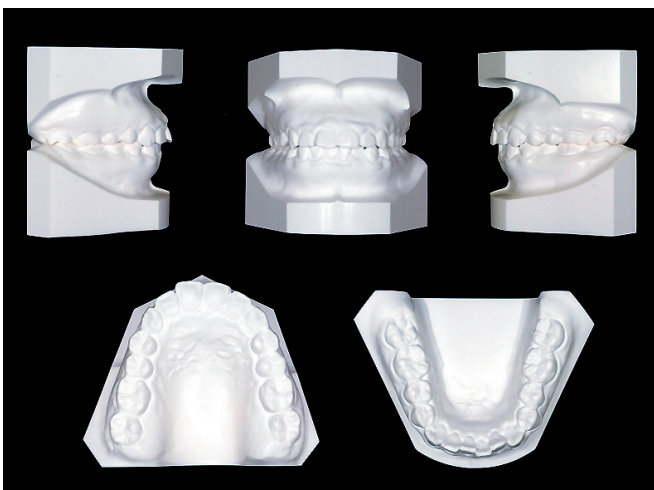■ Fig. 4: Post-treatment facial photographs



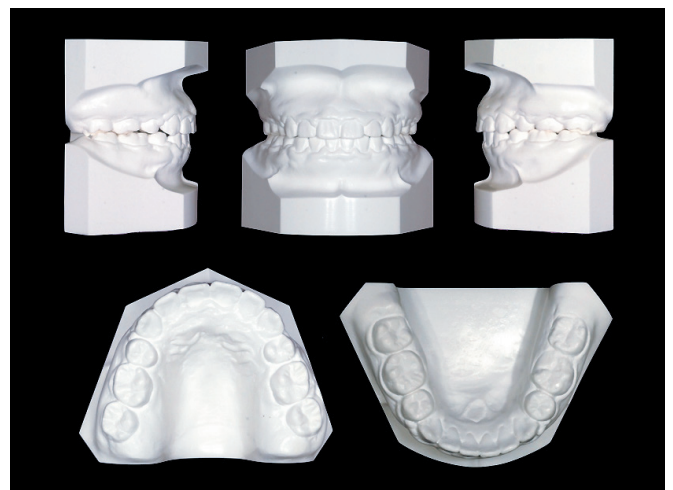■ Fig. 2: Pre-treatment intraoral photographs



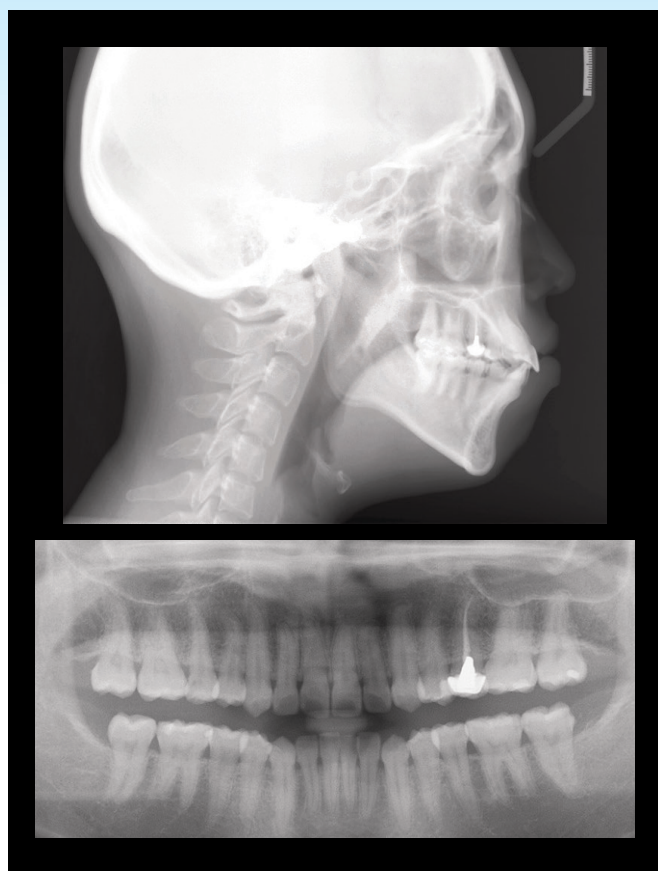
■ Fig. 5: Post-treatment intraoral photographs



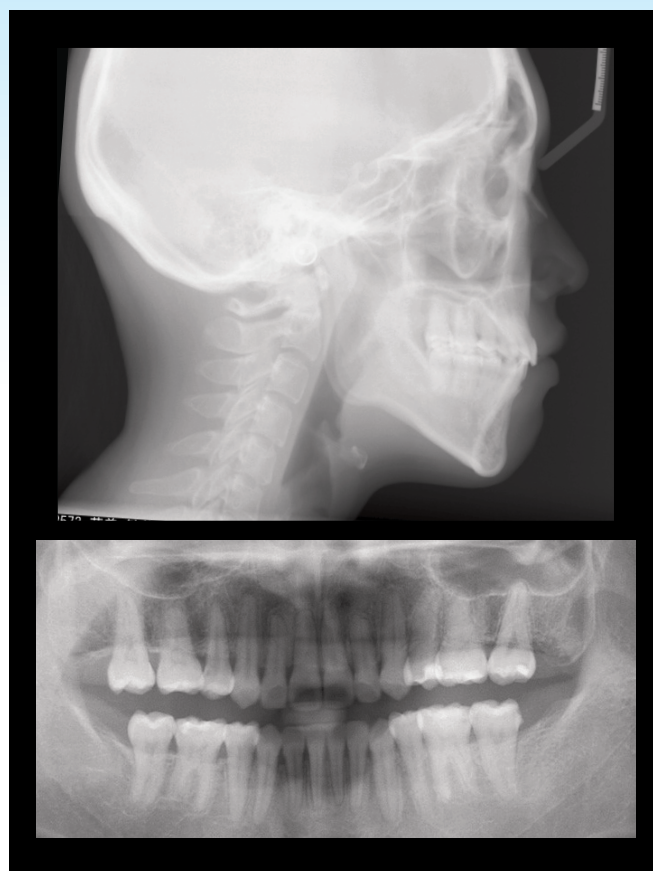
■ Fig. 3: Pre-treatment study models (casts)



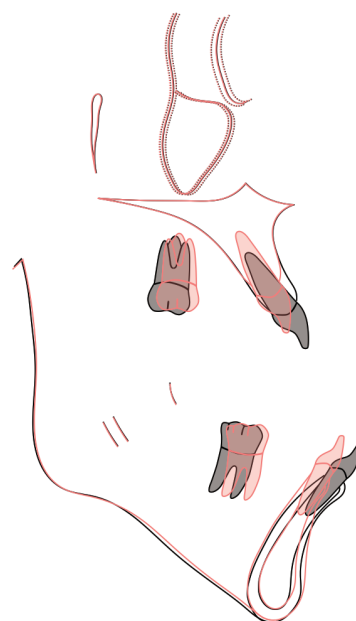
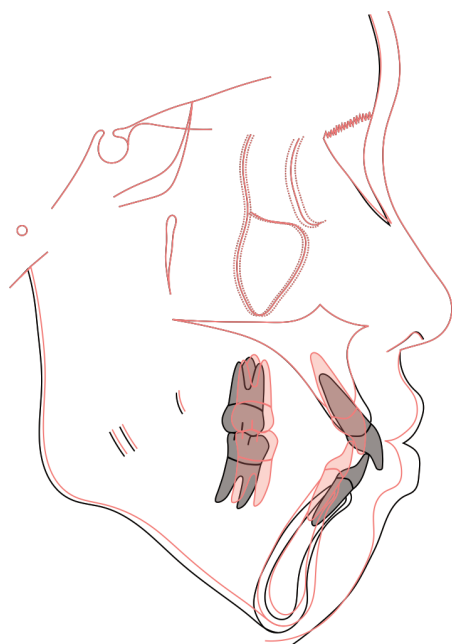■ Fig. 6: Post-treatment study models (casts)



■ **Fig. 7:**
 Pre-treatment lateral cephalometric and panoramic radiographs reveal root canal treatment in tooth #13. Bimaxillary protrusion and lip strain on closure is noted in the cephalometric view.



■ **Fig. 8:**
 Post-treatment lateral cephalometric and panoramic radiographs document the orthodontic result.



■ **Fig. 9:** Superimposed on the anterior cranial base, maxilla and mandible.

CEPHALOMETRIC			
SKELETAL ANALYSIS			
	PRE-Tx	POST-Tx	DIFF.
SNA° (82°)	78°	74°	4°
SNB° (80°)	75°	74°	1°
ANB° (2°)	3°	0°	3°
SN-MP° (32°)	41°	40°	1°
FMA° (25°)	32°	31°	1°
DENTAL ANALYSIS			
U1 To NA mm (4 mm)	10 mm	8 mm	2 mm
U1 TO SN° (104°)	110°	103°	7°
L1 To NB mm (4 mm)	8 mm	4 mm	4 mm
L1 TO MP° (90°)	95°	87°	8°
FACIAL ANALYSIS			
E-LINE UL (2-3 mm)	2 mm	-1 mm	3 mm
E-LINE LL (1-2 mm)	6 mm	1 mm	5 mm

■ Table 1: Cephalometric summary

Facial:

1. Convex profile with protrusive lips
2. Excessive maxillary gingival display when smiling

As shown in the subsequent worksheet, the American Board of Orthodontics (ABO) Discrepancy Index (DI) was 21. Cephalometric values are summarized in Table 1.

Specific Objectives of Treatment

Maxilla (all three planes):

- A - P: *Retract*
- Vertical: *Intrude*
- Transverse: *Maintain*

Mandible (all three planes):

- A - P: *Maintain*
- Vertical: *Decrease the vertical dimension of the occlusion (VDO)*
- Transverse: *Maintain*

Maxillary Dentition:

- A - P: *Retract incisors*
- Vertical: *Intrude the entire maxillary dentition, particularly the incisors*
- Inter-molar / Inter-canine Width: *Modest increase to articulate with the lower arch*

Mandibular Dentition:

- A - P: *Retract the mandibular incisors*
- Vertical: *Maintain*
- Inter-molar / Inter-canine Width: *Modest increase as buccal segments are uprighted*

Facial Esthetics:

- Retract lips and achieve lip competence

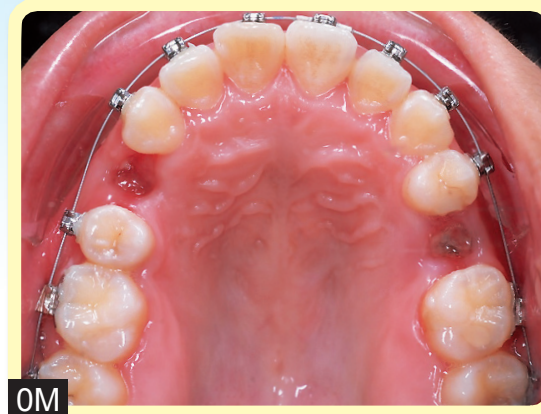Treatment Plan

Extract one premolar in each quadrant (*teeth #5, 13, 21 and 28*). Bond all permanent teeth with the 0.022-in Damon Q® (Ormco, Glendora, CA) self-ligating bracket system. Use the stainless steel OrthoBoneScrew® (OBS) (Newton's A, Ltd., Hsinchu, Taiwan) anchorage system as follows: 1. 2x12mm screws in each infrazygomatic crest (IZC) to serve as E-A anchorage to retract and intrude the maxillary arch, and 2. 1.5x8mm interradicular screws bilaterally between the roots of the maxillary central and lateral incisors to intrude the maxillary anterior segment. When optimal alignment is achieved, remove all fixed appliances and fabricate clear overlay retainers.

Correct maxillary anterior dental and soft tissue proportions with a surgical crown lengthening procedure.

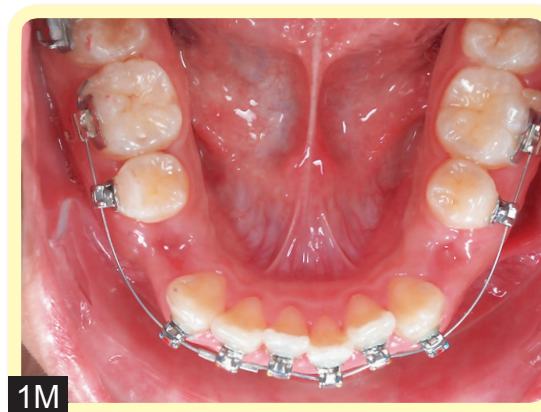Appliances and Treatment Progress

Following premolar extractions, the 0.022-in Damon Q® system was bonded on all maxillary teeth, using high torque brackets in the anterior segment (Fig. 10). The following month, standard torque brackets were bonded on all mandibular teeth (Fig. 11). The wire sequence in the upper arch was: 0.014-in CuNiTi, 0.014x0.025-in CuNiTi, 0.017x0.025-in TMA, 0.019x0.025-in SS. The wire sequence in the lower arch was similar except that the final wire was 0.016x0.025-in SS. After the 0.019x0.025-in SS arch wires were inserted into the maxillary arch, power chains and Class II elastics (Ormco 1/4-in 3.5-oz, Fox) were applied to close all spaces. Twelve months into active treatment, a 2x12mm OBS was placed in each IZC for posterior maxillary anchorage, and two 1.5x8mm miniscrews were inserted between the upper central and lateral incisors (Fig. 12). Retracting the entire maxillary dentition with bony anchorage rotates the arch and extrudes the maxillary incisors, but OBS anchorage between the maxillary central and lateral incisors counteracts the anterior extruding force, resulting in intrusion of the entire maxilla¹ (Figs. 13-15). Thus, the four OBS fixtures are a temporary anchorage device (TAD) to intrude the entire maxilla to help correct gummy smile. In the 23th month of treatment, two anterior bite turbos were bonded on the palatal surface of the maxillary central incisors and Class II elastics (3.5-oz) were used. The short anterior crowns appeared even shorter during the intrusion phase because of gingivitis (Fig. 16).



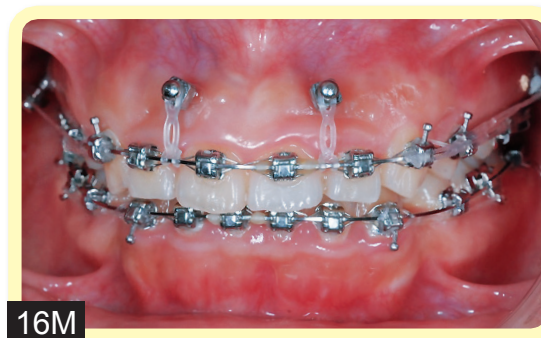■ Fig. 10:

The maxillary right first (#5) and left second (#13) premolars were extracted and high torque brackets were bonded on the incisors.



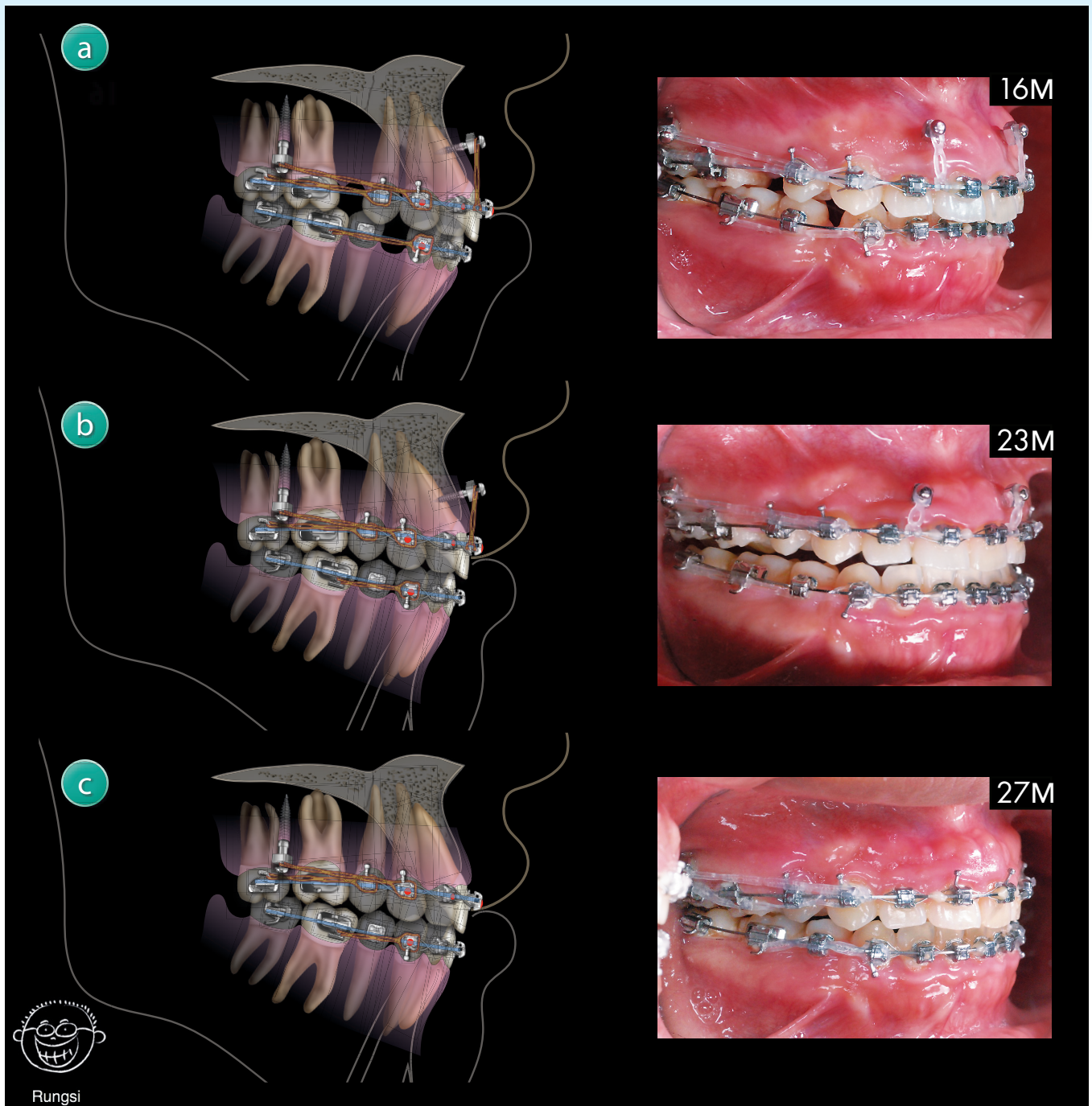
■ Fig. 11:

The lower arch was bonded one month after the upper arch. Standard torque brackets were used on all teeth. Note that both first premolars were extracted.



■ Fig. 12:

Inter-radicular OBSs were inserted between the central and lateral incisors, and E-A OBSs were inserted in the zygomatic crests. Incisor intrusion was accomplished with elastomer chains.

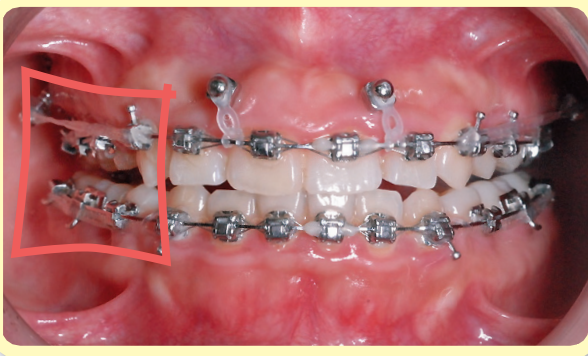


■ **Fig. 13:** Diagrams and corresponding photographs illustrate the mechanics employed at progressive stages of treatment:

- a. At 16 months the occlusal plane was gradually steepening.
- b. At 23 months anterior bite turbos were bonded on the palatal surfaces of the maxillary central incisors.
- c. In the 27th month, retraction force from the IZC miniscrews closes upper space but also provides lingual crown torque to the upper incisors.

In the 24th month of treatment, the anterior OBSs were removed and the upper arch wire (0.019x0.025-in SS) was expanded to improve the posterior occlusion (Fig. 14). Class II elastic and anterior U shape vertical elastics were used from the 24th month until the 31th month.

In the 31th month of treatment, the arch wire was sectioned distal to the maxillary canines and bilateral rectangular shaped Fox (1/4-in 3.5-oz) elastics were utilized to settle the posterior occlusion.

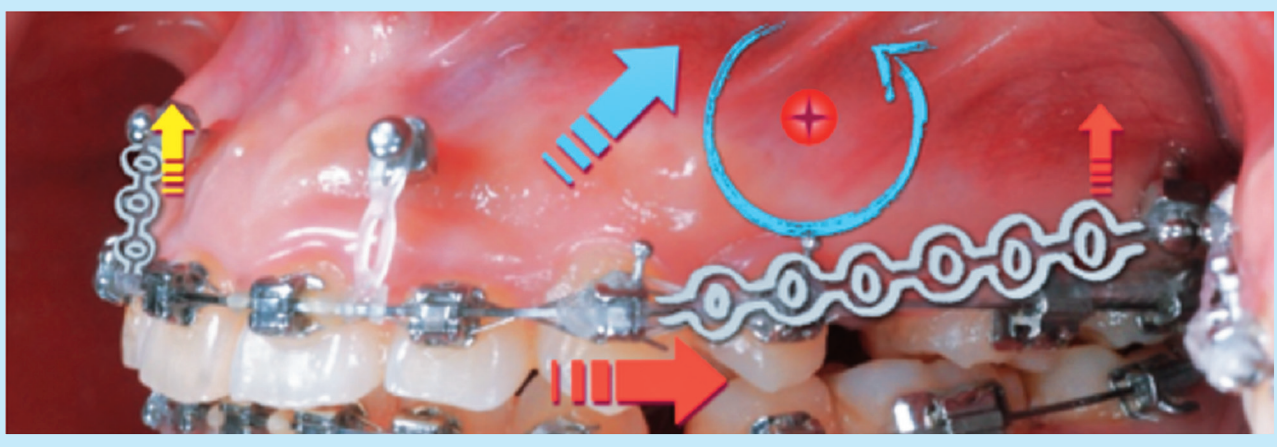


■ Fig. 14:
As extraction space was closed, the right buccal segment tended toward crossbite, so the archwire was expanded.

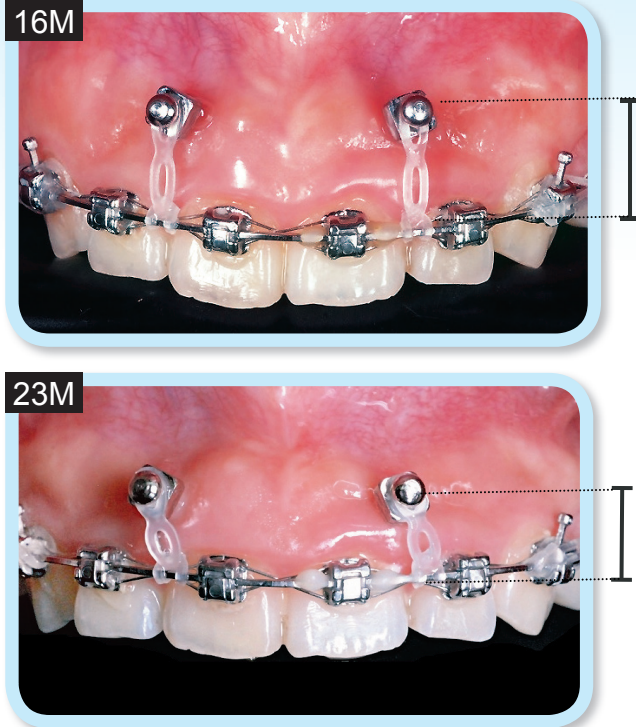
After orthodontic treatment was complete, surgical crown lengthening (Figs. 17-19) was performed to establish proper crown heights and proportions. The total active treatment time was 32 months.

Retention

Prior to debonding, all finishing discrepancies were assessed such as axial inclination of maxillary molars (Fig. 20). Many of these residual problems were corrected with posterior vertical elastics after the archwire was cut distal to the canines. After all labial appliances were removed, fixed retainers were bonded from 2-2 in the maxillary arch. Upper and lower clear overlay retainers were delivered. The patient was instructed to wear them full time for the first 6 months and nights only thereafter. Instructions were provided for home dental care, as well as for maintenance of the retainers.



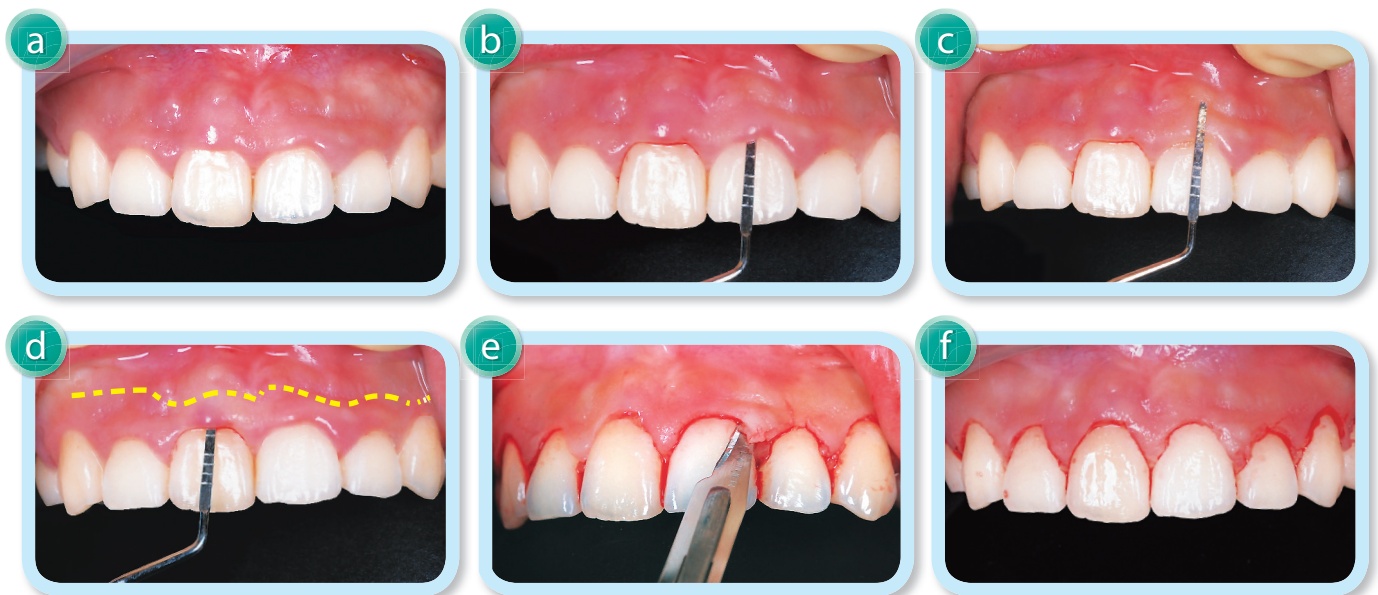
■ Fig. 15:
The force systems provided by the four OBSs and their overall effect on the maxillary arch are complex. The yellow arrow on the left indicates the intrusive force applied to the incisors. The large red arrow is the retraction force anchored by the IZC OBS. The small red arrow is the intrusive component on the posterior maxillary segment. The large blue arrow is the net resultant force on the maxilla, and the blue circular arrow represents the moment of the retraction force around the center of resistance of the maxilla (red dot with a cross).



■ **Fig. 16:**
The distance of 3mm between the screws and main arch wire from 16th to 23rd month have been reduced.

Surgical crown lengthening process

According to Graber and Salama classification, This patient was classified to vertical maxillary excess degree II and corresponding treatment was periodontal and restorative therapy.¹⁰ The procedure indicated is illustrated in Figs. 17-19. Under local anesthetic, the width of the dentinogingival complex was measured by sounding to bone with a periodontal probe (Figs. 17b, c and 19). Then the relationship of the cemento-enamel junction (CEJ) to the osseous crest was mapped, and the width of the keratinized gingiva was determined (Fig. 17d). Although not necessarily essential for periodontal health, 2mm or more of keratinized gingiva certainly improves esthetics and is helpful for maintaining effective hygiene.² If there is not enough keratinized gingiva following the osteoplasty phase of the surgical crown lengthening procedure, an apically positioned flap is indicated.



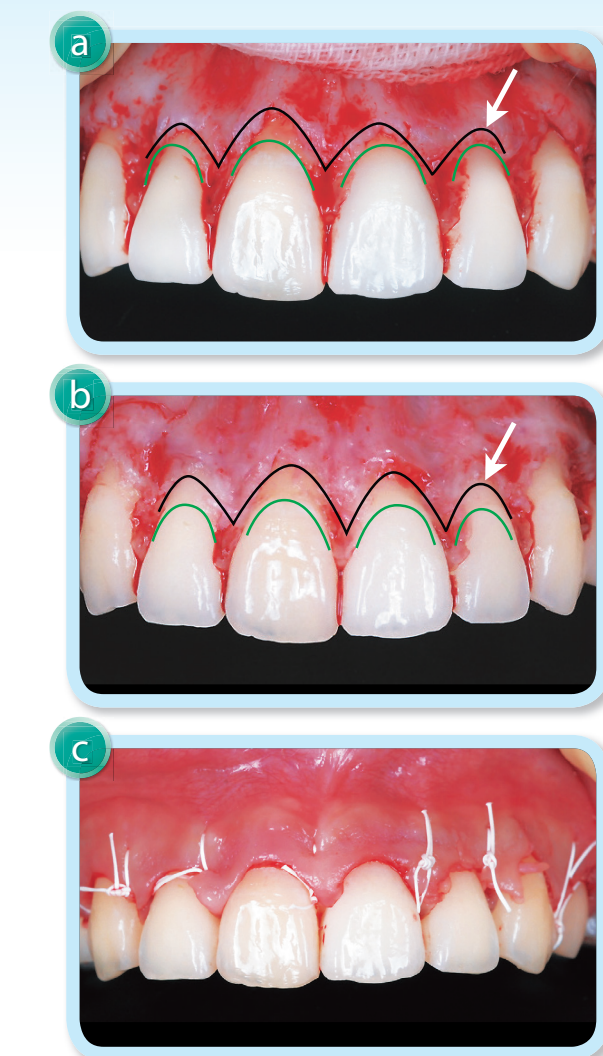
■ **Fig. 17:**
The surgical crown lengthening procedure for short clinical crowns (a) begins with bone sounding (b) relative to the attached gingiva (c). The width of the attached gingiva is mapped with a dotted line (d). The gingivectomy is performed with a No. 15 blade (e) and the increased crown exposure (f) is assessed relative to the width of the remaining attached gingiva.

Excess gingiva was resected using an intrasulcular incision to establish the desired crown length. In the absence of severe dental attrition, the CEJ was the best anatomical reference for the gingivectomy (Fig. 17) and the osteotomy (Fig. 18) to provide for an adequate biologic width. Once the desired crown exposure was achieved, the gingival flap was raised and bone removal was performed with a #5 round carbide bur to establish a uniform biologic width (CEJ to alveolar crest) of at least 2.5mm for the anterior teeth. For example, there was only 1mm of biologic width along some aspects of the facial surface of tooth #9 (Fig. 18a). So trimming bone to establish a uniform biologic width of 2.5mm was essential for long-term gingival health. Finally the flap was repositioned to the crowns and sutured about 0.5mm coronal to the CEJ (Fig. 18c).

Final Evaluation of Treatment

Alignment: the ABO Cast-Radiograph Evaluation (CRE) score was 15 points, which is an excellent result for a malocclusion presenting with a DI=21. Most of the residual alignment problems were due to bracket positioning errors. The importance of precise bracket placement cannot be overemphasized.

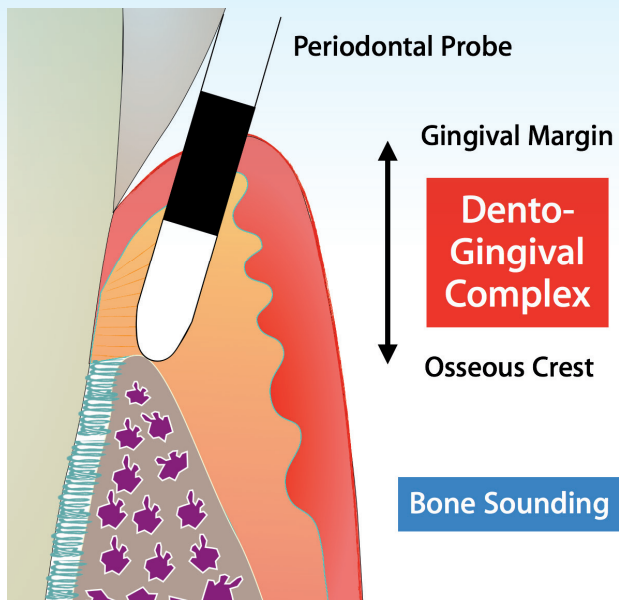
Esthetics: the Pink and White Dental Esthetics score was assessed before and after crown lengthening surgery. The Pink Esthetics score (*gingival aspects*) significantly improved from 4 to 2 points because of the surgical crown lengthening. Residual discrepancies post-operatively were the curvature and level of the gingival margins. Selective gingivectomy with a dioxide laser is indicated to



■ Fig. 18:

Green lines represent the CEJs and black lines are the alveolar bone level before osteoplasty (a). The white arrow (a) shows that the biologic width of #10 was only ~1mm (b). After osteoplasty (b) the biologic width was corrected to 2.5mm, and the gingiva was sutured with #4 Gore-Tex® (Gore Medical Products, Flagstaff, AZ).

resolve these problems. The White Esthetics score (*dental aspects*) also improved from 3 points to 1 after crown lengthening surgery. The incisal curve remained uneven due to the attrition of tooth #9. Direct bonding with composite resin and/or selective grinding is indicated.



■ Fig. 19:

The dentogingival complex can be measured by bone sounding with a periodontal probe. The dimensions of the normal dento-gingival complex are approximately 3.0mm buccally and lingually, with a mean of 4.5 to 5.0mm interproximally.³

Overall, the maxillary dentition was intruded and the anterior teeth were retracted (Fig. 9). The gummy smile and the protrusive lips were significantly improved (Fig. 4). The patient was well satisfied with the result.

Discussion

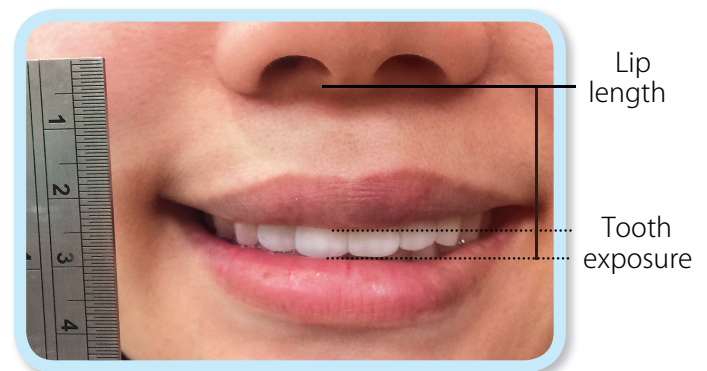
From an esthetic perspective, the ideal is 1-2mm of gingival display when smiling.⁴ Excessive gingival exposure when smiling may be localized or involve all of the maxillary teeth. A "gummy smile," may have both an extra-oral and intra-oral etiology.⁵

Extra-oral causes:

1. **Short Upper Lip:** Lip length is normally about one third of lower facial height. Clinically, lip

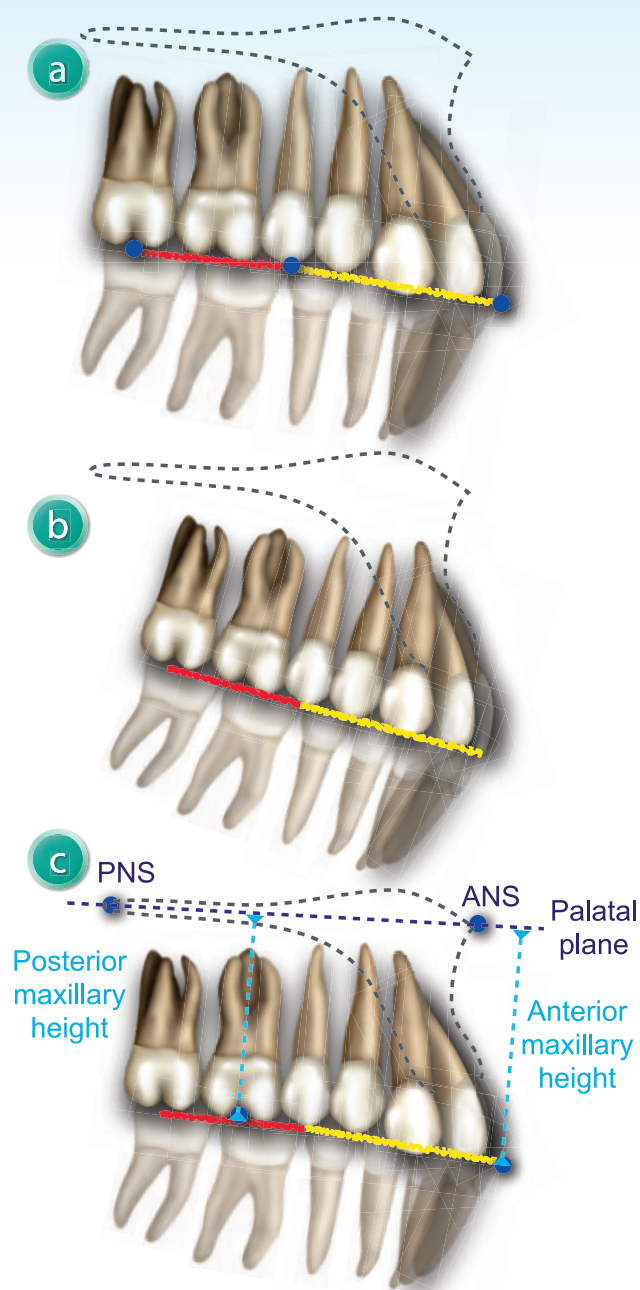
length is measured from subnasale to the inferior border of the upper lip (Fig. 20). Individuals with less than 20mm of lip length are usually classified as having a short lip.⁶

2. **Hypermobile Upper Lip (HUL):** The average lip mobility from repose and a full smile is ~6-9mm. The distance the upper lip travels when smiling is determined by measuring from a baseline, which is the lip position at rest; measure the distance from the maxillary incisor edge to the lower border of the lip on the lateral cephalometric film or the facial photograph if the incisor is visible. Then measure the distance from the incisor edge to the inferior border of the lower lip on the facial photograph when smiling. If the total distance that the lip travels when smiling is greater than ~ 6-9mm, the diagnosis is hypermobile lip. The underlying etiology is usually hyperactivity of the upper lip elevator muscles.



■ Fig. 20:

Ideal lip length in young adult females is from 20 to 22mm, whereas it is from 22 to 24mm in young adult males.⁶



■ Fig. 21: Occlusal plane canting in the sagittal plane:

- In anterior dentoalveolar extrusion (ADE), only the anterior portion of the occlusal plane is canted inferiorly.
- Vertical maxillary excess (VME) involves inferior positioning of both the anterior and posterior segments with a flat but often steep occlusal plane.
- Anterior and posterior maxillary height are measured cephalometrically as shown.^{7,8}

3. Anterior Dentoalveolar Extrusion (ADE):

This condition may be associated with incisor attrition and/or a deep bite (Fig. 21a). As the maxillary incisors extrude to make contact (*passive eruption*), there is excessive gingival display and a curvature of the occlusal plane, which is associated with a disharmony between the anterior and posterior segments.² This condition can be corrected by intruding the upper anterior teeth with miniscrew anchorage.⁶

4. Vertical Maxillary Excess (VME):

The maxilla is more inferiorly positioned due to increased lower facial height and there may be a cant in the occlusal plane. The average anterior maxillary height is 29.7mm,⁶ whereas the average posterior maxillary height is 20.6mm.⁹ The current patient's anterior and posterior maxillary heights were 29 and 25mm respectively, which is not consistent with either ADE or VME. However, these cephalometric measurements are only averages. A thorough diagnosis for an individual patient must be more comprehensive. Gummy smile is a clinical impression, not a cephalometric value.

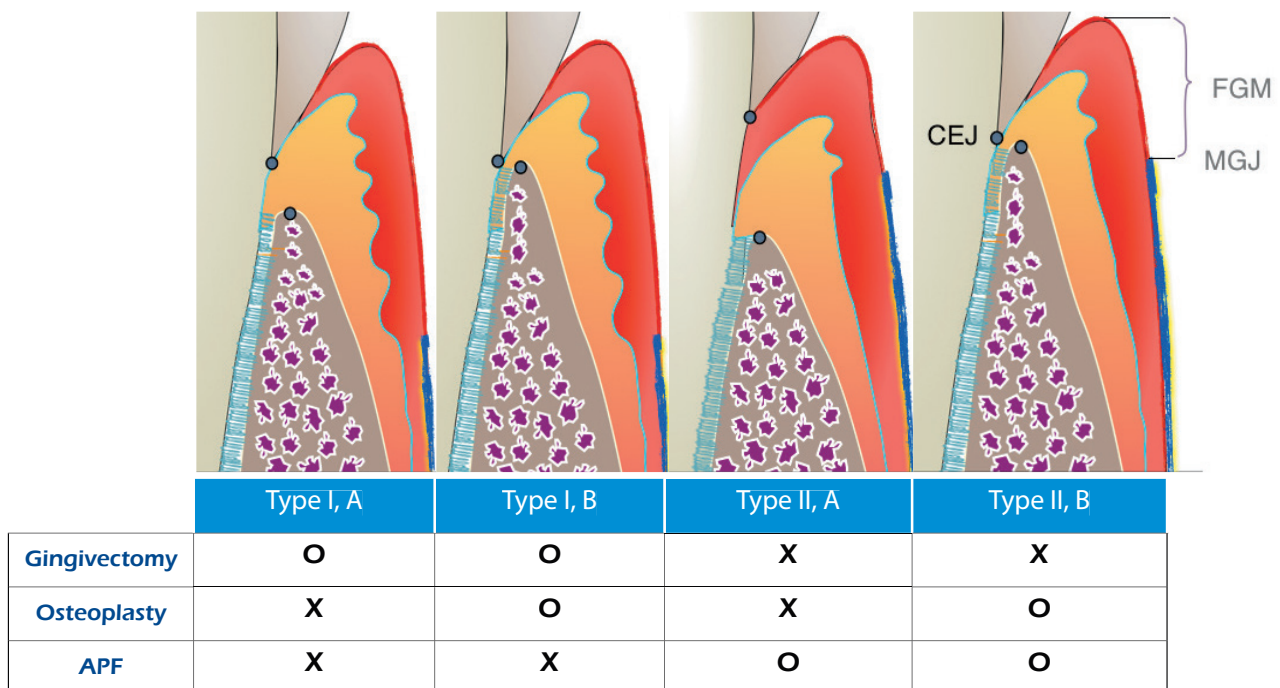
Garber and Salama (2000)¹⁰ classified the degree of VME and corresponding treatment modalities. The alternative to orthognathic surgery was the use of bilateral anterior and posterior miniscrews to achieve intrusion of the anterior teeth and retraction of the entire arch. Once anterior teeth were intruded to the desired level, trimming the upper incisors to the desired height and a crown lengthening procedure were indicated to provide an optimal esthetic result. Furthermore, for the patients with more than 5mm gingival display, lip reposition surgery and

Botox® (Allergan Inc. Irvine, CA) injection are viable alternatives to orthognathic surgery.^{11,12}

Intra-oral causes:

- 1. Gingival Enlargement:** Enlarged gingival tissues may be due to infection or sensitivity to medication (e.g. *phenytoin, cyclosporine, calcium channel blockers etc*). The treatment for this condition should focus on oral hygiene, but a gingivectomy may be necessary in some cases.¹
- 2. Altered Passive Eruption:** Tooth eruption is divided into two phases: active and passive eruption. Active eruption is the movement of the teeth in the direction of the occlusal plane, whereas passive eruption is the exposure of the teeth by apical migration of the gingiva.¹³ Tooth

eruption continues throughout life and the level of free gingival margin varies accordingly. Goldman and Cohen (1968)¹⁴ coined the term "altered passive eruption" for failure of the gingival margin to recede to a level apical to the cervical convexity of the crown. Volcansky and Cleaton-Jones (1976)¹⁴ reported that 12.1% of 1,025 patients with a mean age of 24.2 years \pm 6.2 years displayed altered passive eruption.¹⁴ It is more prevalent in women than in men. Depending on the level of mucogingival junction (MGJ) and alveolar bone crest, there are four types of altered passive eruption: Type IA, type IB, type IIA and type IIB (Fig. 22).¹⁵ The difference between Class I and II is the width of keratinized gingiva (*soft tissue*). The difference between subtype A and B is the level of alveolar bone crest. For the current patient, bone



■ Fig. 22:

Classification of altered passive eruption is important for determining the most appropriate surgical procedure(s) to correct it.¹⁵

sounding favored a diagnosis of type IB, which can be reliably treated with gingivectomy and osteoplasty (Figs. 23 and 24).

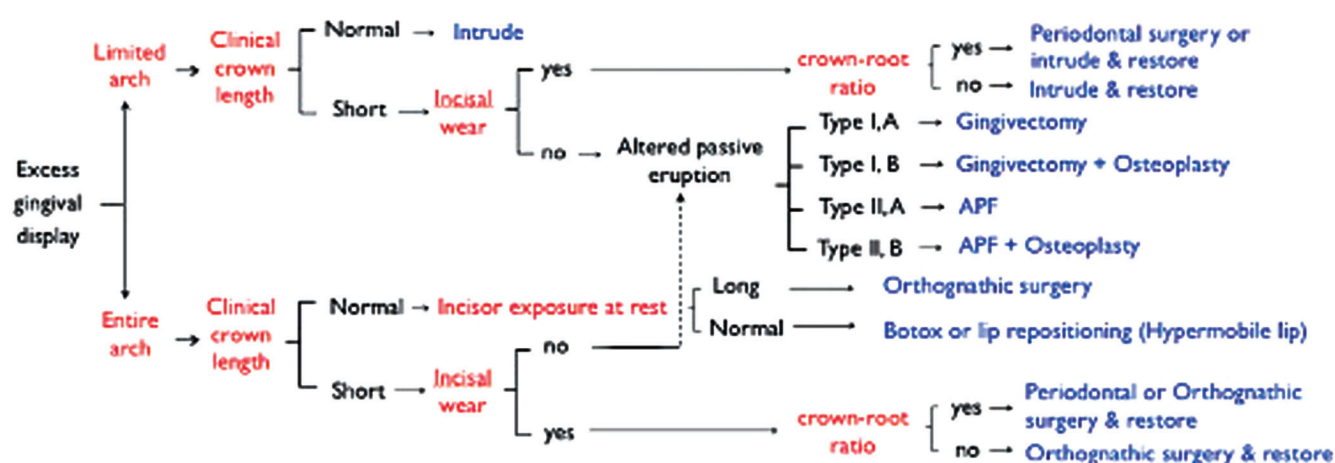
Decision tree⁵:

The occlusal plane favors ADE (Fig. 21a) because only the anterior segment was tilted inferiorly. For VME (Fig. 21b) both the anterior and posterior occlusal planes are inferiorly positioned, and the occlusal plane is flat. ADE can often be treated with orthodontic intrusion but VME may require orthognathic surgery, usually a Lefort 1 osteotomy.

Clinical crown length measurement using a gauge or periodontal probe is the second determinant of an effective decision making process. When compared to normal crown length of a central incisor (~11mm) a patient's incisors can be classified as short, average or long.

Incisal wear is the third determinant. If there is excessive dental attrition, it is important to intrude the affected teeth to correct the level of the gingiva, and then restore the incisors to normal length. Since a history of excessive incisal wear is usually associated with nocturnal parafunction, it is essential to retain the patient with a Hawley bite plate that slightly opens the posterior bite. The bite plate should be worn at night indefinitely to protect the restorations.

Incisor exposure when resting is the fourth determinant. If the patient cannot completely close the lips in repose, and incisor exposure at rest is more than 2mm, VME is the probable diagnosis, and orthognathic surgery may be necessary. If the patient can close the lips at rest, but the gingival display is over 4 mm when smiling, the diagnosis is hypermobile lip. Botox® injections and/or surgical lip repositioning is suggested.^{11,12}

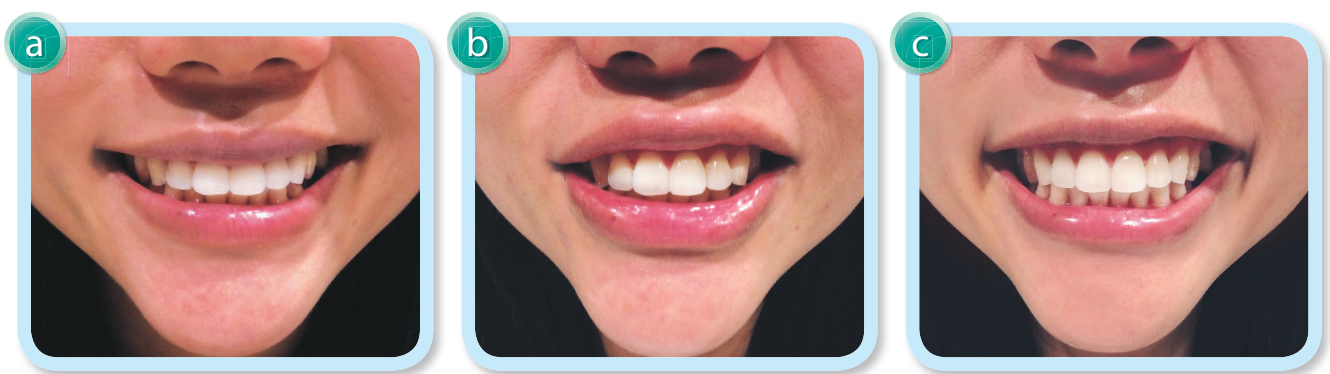


■ Fig. 23:

The decision tree is a flow chart for assessing excessive gingival display to determine the most appropriate clinical management for a specific problem. The five determinants for decision making are: extent of the excessive gingival display, clinical crown length, incisal wear, incisor exposure at rest, and the crown-root ratio.⁵

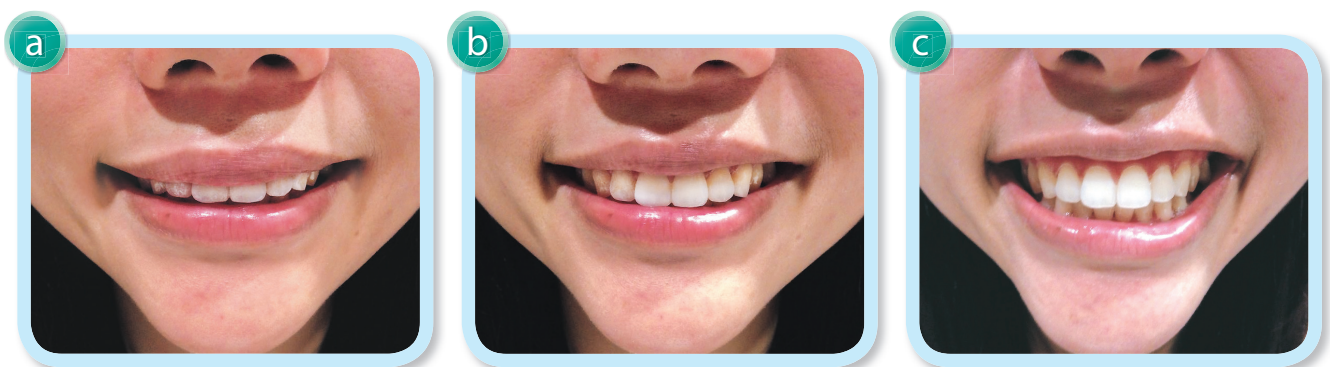The crown to root ratio is the fifth determinant. If the alveolar bone supporting tooth roots is adequate, the overall treatment time can be reduced by surgical crown lengthening without orthodontic intrusion.

A comprehensive diagnosis and effective treatment plan for gummy smile requires a careful analysis of the five determinants of the decision tree.⁵ For the present patient, the findings were VME, short clinical crown length, and no incisal wear. So the diagnosis



■ Fig. 24: Smile type is classified as follows:¹⁶

- Commissure smile is a Cupid's Bow configuration that is seen in ~67% of the population. The corners of the mouth are elevated and projected anteriorly by the levator muscles of the upper lip. The teeth are exposed in a smile arc with a base at the incisal edge of the maxillary central incisor.
- Cuspid smile is seen in ~31% of the population. The shape of the lips is commonly visualized as a diamond. The levator labii superior muscles contract first, exposing the maxillary cuspids, then the corners of the mouth contract projecting the lips upward and outward.
- Complex smile is seen in ~2% of the population. The shape of the lips are typically illustrated as two approximating chevrons. The levators of the upper lip and corners of the mouth contract simultaneously with the depressors of the lower lip, to expose all the upper and lower teeth.



■ Fig. 25: Smile line is classified as follows:¹⁷

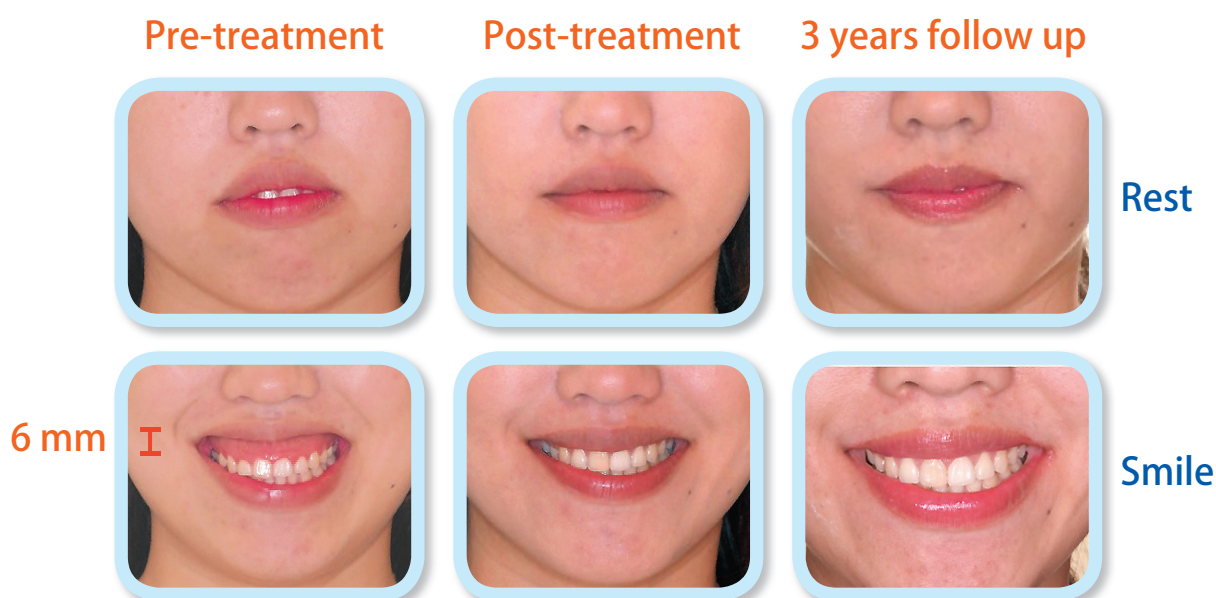
- Low smile line, exposing less than 75% of the maxillary incisors and no gingiva, is seen in 20.48% of the population.
- Average smile line, exposing 75-100% of the maxillary anterior teeth along with interproximal gingiva, is seen in 68.94% of the population.
- High smile line, exposing 100% of the anterior segment along with a contiguous band of gingiva, is seen in 10.57% of the population.

was altered passive eruption (Fig. 23). Measuring the width of keratinized gingiva and bone sounding determined that the present case was type I B, and the corresponding treatment following completion of orthodontics was gingivectomy and osteoplasty (Figs. 22 and 23). Using the decision tree (Fig. 23), the dental practitioner may approach this type of patient with confidence.

Philips¹⁶ established a plastic surgery classification based on three smiling patterns: commissure, cuspid or complex smile. The variation among these smile types is due to the differential function of facial muscle groups. The esthetic appearance of gingival tissue varies widely and must be specifically evaluated for each individual.

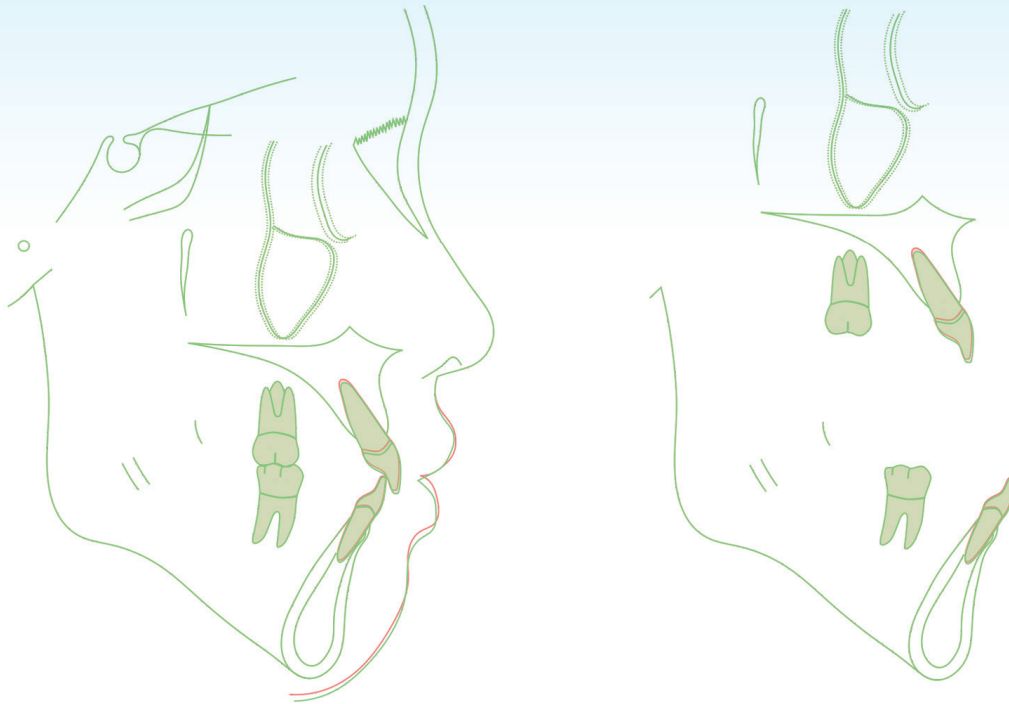
Tjan and Miller¹⁷ published a dental smile classification system that distinguished individuals with a low, average and high smile line, based on the amount of dental and gingival exposure during a natural full smile (Fig. 25). The high smile line, also known as a gummy smile, is generally an esthetic concern which is twice as common in women compared to men. The authors¹⁷ proposed that women have a shorter upper lip than men, but this hypothesis was not confirmed in subsequent studies.¹⁸

Kaya and Uyar¹⁹ found that the dominant factors affecting the perception of smile attractiveness are smile arc and gingival display. Furthermore, flat smile arcs are preferred when there is insufficient gingival display, but the vaulted smile arc is preferred with



■ Fig. 26:

Pre- and post-treatment images of the current patient's smile. The gummy smile has been improved remarkably by orthodontics and surgical crown lengthening.



■ Fig. 27:

Superimposed on the anterior cranial base, maxilla and mandible. The upper and lower dentition remain stable. No relapse was noted.

excessive gingival display. In an aging study, Vig and Brundo²⁰ reported that the maxillary central incisor exposure gradually decreases over time and is accompanied by a corresponding increase in mandibular tooth exposure.

With respect to the current patient, a high smile line was changed to average by intruding the entire maxillary arch with anterior and posterior OBS anchorage (Fig. 26). The treatment effect is similar to a LeFort I osteotomy and result is stable, thereby offering patients a viable alternative (Fig. 27). Combining intrusion and surgical crown lengthening produced an attractive smile without the cost, morbidity and potential complications of orthognathic surgery.

Conclusion

Darwin²¹ stated that we all smile in the same language. The smile is the most recognized human expression. However, excessive gingival display is a major concern for many patients who subsequently seek esthetic dental treatment. By measuring a set of pretreatment parameters, an accurate diagnosis is achieved for guiding conservative treatment that is effective for alleviating gummy smiles.

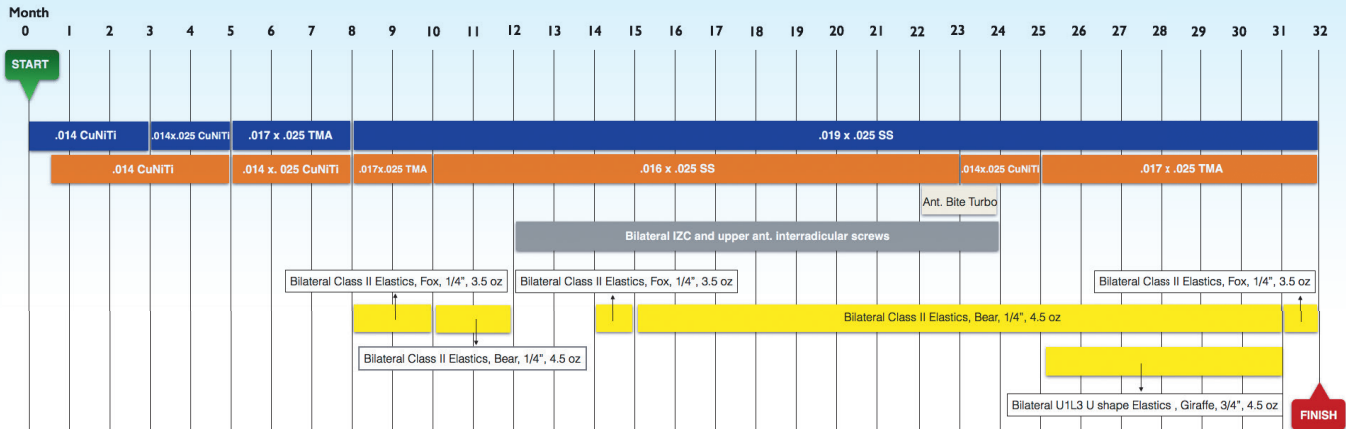
Acknowledgment

Thanks to Mr. Paul Head and Dr. Bill Su for proofreading this article and Dr. Rungsi and Dr. CK Chen for sharing their ideas and material.

Archwire Sequence Chart

Clinicians: Dr. Chris Chang
Patient: A2573 Miss Fang

■ Maxillary Archwire ■ Bite Turbo ■ Miniscrew
■ Mandibular Archwire ■ Elastics



References

- Lang NP, Loe H. The relationship between the width of keratinized gingiva and gingival health. *Journal of Periodontology* 1972;43:623-627.
- Yeh HY, Chang CH, Robert WE. Implant-orthodontic combined treatment for gummy smile with multiple missing teeth. *Int J Ortho Implantol* 2013;32:16-32.
- Kois J. Altering gingival levels. The restorative connection. 1. Biologic variables. *J Esthet Dent* 1994;6:3-9.
- Hulsey CM. An esthetic evaluation of lip-teeth relationships present in the smile. *Am J Orthod Dentofac Orthop* 1970; 57:132-144.
- Chen CK. Diagnosis and therapy of gummy smile. *Beethoven Podcast Encyclopedia in Implant Forum No.38*. Hsinchu: Newton's A Ltd; 2013.
- Peck S, Peck L, Kataja M. The gingival smile line. *Angle Orthod* 1992;62:91-100. Discussion 1-2.
- Wu H, Lin J, Zhou L, Bai D. Classification and craniofacial features of gummy smile in adolescents. *J Craniofac Surg* 2010;21:1474-1479.
- Fushima K, Kitamura Y, Mita H, Sato S, Suzuki Y, Kim YH. Significance of the cant of the posterior occlusal plane in class II division 1 malocclusions. *Eur J Orthod* 1996;18:27-40.
- Janson GR, Metaxas A, Woodside DG. Variation in maxillary and mandibular molar and incisor vertical dimension in 12-year-old subjects with excess, normal, and short lower anterior face height. *Am J Orthod Dentofacial Orthop* 1994;106:409-18.
- Garber DA, Salama MA. The aesthetic smile: diagnosis and treatment. *Periodontol* 2000 1996;11:18-28.
- Simon Z, Rosenblatt A, Dorfman W. Eliminating a gummy smile with surgical lip repositioning. *Journal of Cosmetic Dentistry* 2007;23:100-108.
- Polo M. Botulinum toxin type A (Botox®) for the neuromuscular correction of excessive gingival display on smiling (gummy smile). *Am J Orthod Dentofacial Orthop* 2008;133:195-203.6
- Newman MG, Takei HH, Carranza FA. *Carranza's Clinical Periodontology*. 9th ed. Saunders; 2002. p. 31.
- Cohen E. *Atlas of cosmetic and reconstructive periodontal surgery*. 3rd ed. BC: Decker; 2007. p. 259.
- Ezquerria F, Berrazueta MJ, Ruiz-Capillas A, Arregui JS. New approach to the gummy smile. *Plast Reconstr Surg* 1999;104:1143-1150. Discussion 51-2.
- Philips E. The classification of smile patterns. *J Can Dent Assoc* 1999;65:252-254.
- Tjan A, Miller G. Tjan AHL, Miller GD. Some esthetic factors in a smile. *J Prosthet Dent* 1984;51:24-28.
- Peck S, Peck L, Kataja M. Some vertical lineaments of lip position. *Am J Orthod Dentofacial Orthop* 1992;101:516-524.
- Kaya B, Vyar R. Influence on smile attractiveness of the smile arc in conjunction with gingival display. *Am J Orthod Dentofacial Orthop* 2013;144(4):541-547.
- Vig RG, Brundo GC. The kinetics of anterior tooth display. *J Prosthet Dent* 1978;39:502-504.
- Darwin C. The expression of the emotions in man and animal. Chapter 14. London: John Murray; 1872. p. 347-366.



Discrepancy Index Worksheet

TOTAL D.I. SCORE **21**

OVERJET

0 mm. (edge-to-edge)	=	
1 – 3 mm.	=	0 pts.
3.1 – 5 mm.	=	2 pts.
5.1 – 7 mm.	=	3 pts.
7.1 – 9 mm.	=	4 pts.
> 9 mm.	=	5 pts.

Negative OJ (x-bite) 1 pt. per mm. per tooth =

Total = **2**

OVERBITE

0 – 3 mm.	=	0 pts.
3.1 – 5 mm.	=	2 pts.
5.1 – 7 mm.	=	3 pts.
Impinging (100%)	=	5 pts.

Total = **2**

ANTERIOR OPEN BITE

0 mm. (edge-to-edge), 1 pt. per tooth
then 1 pt. per additional full mm. per tooth

Total = **0**

LATERAL OPEN BITE

2 pts. per mm. per tooth

Total = **0**

CROWDING (only one arch)

1 – 3 mm.	=	1 pt.
3.1 – 5 mm.	=	2 pts.
5.1 – 7 mm.	=	4 pts.
> 7 mm.	=	7 pts.

Total = **7**

OCCLUSION

Class I to end on	=	0 pts.
End on Class II or III	=	2 pts. per side 2 pts.
Full Class II or III	=	4 pts. per side pts.
Beyond Class II or III	=	1 pt. per mm. pts. additional

Total = **2**

LINGUAL POSTERIOR X-BITE

1 pt. per tooth Total = **0**

BUCCAL POSTERIOR X-BITE

2 pts. per tooth Total = **0**

CEPHALOMETRICS (See Instructions)

ANB $\geq 6^\circ$ or $\leq -2^\circ$ = 4 pts.

Each degree $< -2^\circ$ x 1 pt. =

Each degree $> 6^\circ$ x 1 pt. =

SN-MP

$\geq 38^\circ$ = **2 pts.**

Each degree $> 38^\circ$ x 2 pts. =

$\leq 26^\circ$ = 1 pt.

Each degree $< 26^\circ$ x 1 pt. =

1 to MP $\geq 99^\circ$ = 1 pt.

Each degree $> 99^\circ$ x 1 pt. =

Total = **2**

OTHER (See Instructions)

Supernumerary teeth	x 1 pt. =	
Ankylosis of perm. teeth	x 2 pts. =	
Anomalous morphology	x 2 pts. =	
Impaction (except 3 rd molars)	x 2 pts. =	
Midline discrepancy (≥ 3 mm)	@ 2 pts. =	
Missing teeth (except 3 rd molars)	x 1 pts. =	
Missing teeth, congenital	x 2 pts. =	
Spacing (4 or more, per arch)	x 2 pts. =	
Spacing (Mx cent. diastema ≥ 2 mm)	@ 2 pts. =	
Tooth transposition	x 2 pts. =	
Skeletal asymmetry (nonsurgical tx)	@ 3 pts. =	
Addl. treatment complexities	3 x 2 pts. = 6	

Identify: **Severe gummy smile and bimaxillary protrusion**

Total = **6**

IMPLANT SITE

Lip line : Low (0 pt), Medium (1 pt), High (2 pts) =

Gingival biotype : Low-scalloped, thick (0 pt), Medium-scalloped, medium-thick (1 pt), High-scalloped, thin (2 pts) =

Shape of tooth crowns : Rectangular (0 pt), Triangular (2 pts) =

Bone level at adjacent teeth : ≤ 5 mm to contact point (0 pt), 5.5 to 6.5 mm to contact point (1 pt), ≥ 7 mm to contact point (2 pts) =

Bone anatomy of alveolar crest : H&V sufficient (0 pt), Deficient H, allow simultaneous augment (1 pt), Deficient H, require prior grafting (2 pts), Deficient V or Both H&V (3 pts) =

Soft tissue anatomy : Intact (0 pt), Defective (2 pts) =

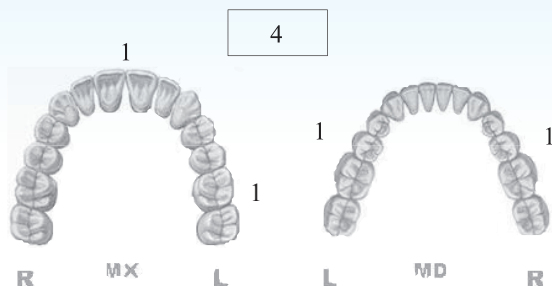
Infection at implant site : None (0 pt), Chronic (1 pt), Acute (2 pts) =

Total =

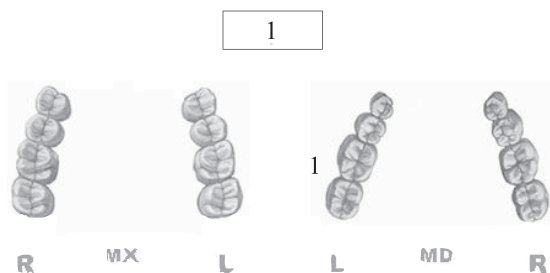
Cast-Radiograph Evaluation

Total Score: 15

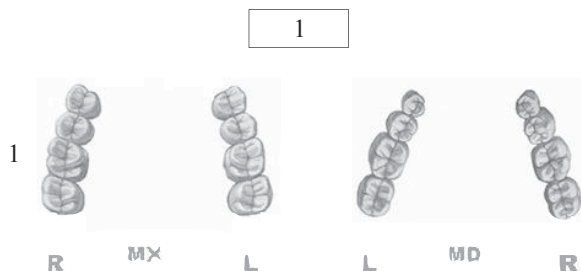
Alignment/Rotations



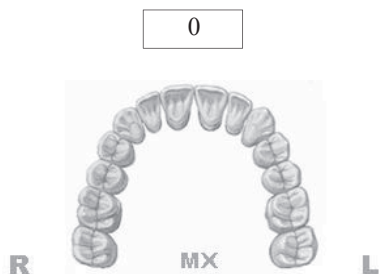Marginal Ridges



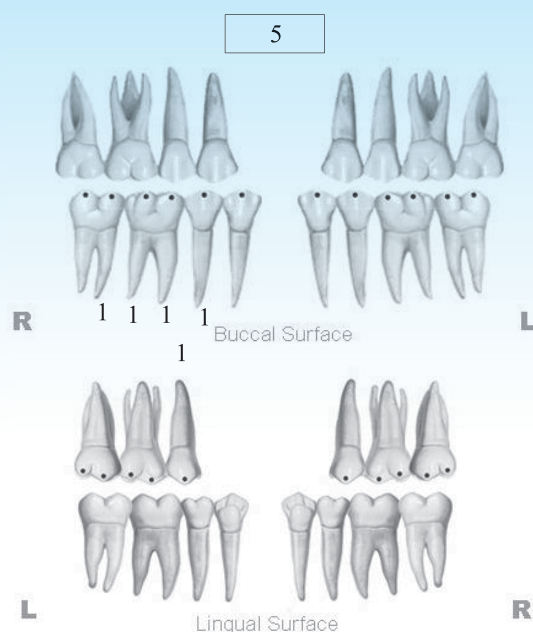
Buccolingual Inclination



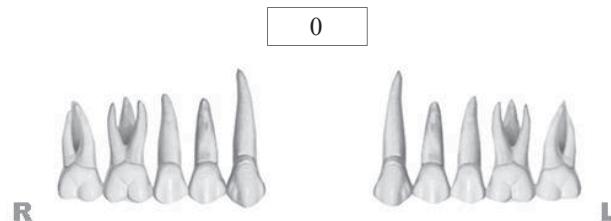
Overjet



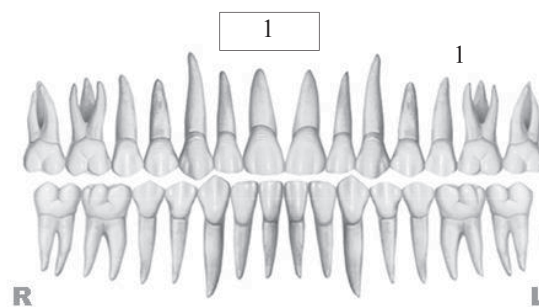
Occlusal Contacts



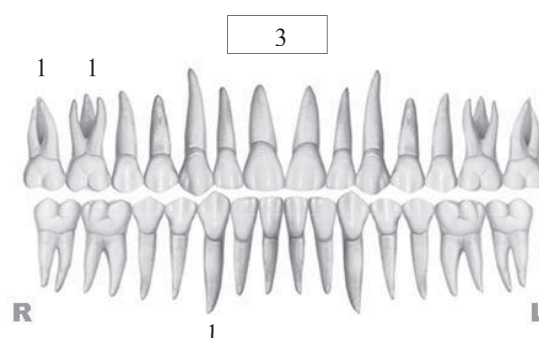
Occlusal Relationships



Interproximal Contacts



Root Angulation

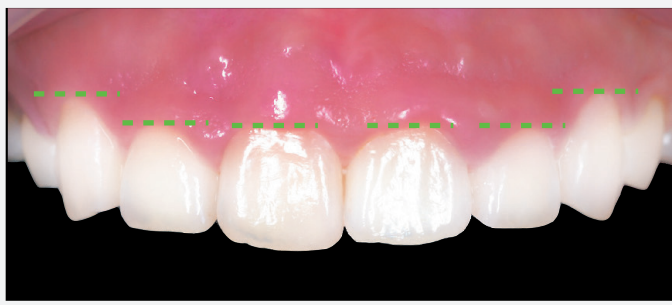
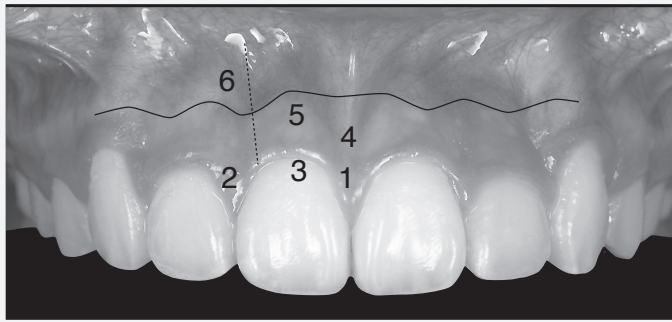


INSTRUCTIONS: Place score beside each deficient tooth and enter total score for each parameter in the white box. Mark extracted teeth with "X". Second molars should be in occlusion.

IBOI Pink & White Esthetic Score (Before Surgical Crown Lengthening)

Total Score: = **7**

1. Pink Esthetic Score



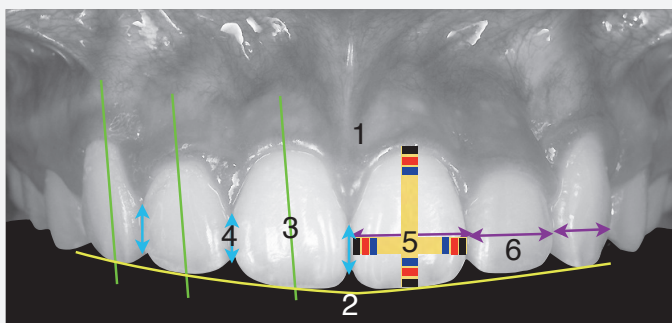
1. M & D Papillae	0	1	2
2. Keratinized Gingiva	0	1	2
3. Curvature of Gingival Margin	0	1	2
4. Level of Gingival Margin	0	1	2
5. Root Convexity (Torque)	0	1	2
6. Scar Formation	0	1	2

Total = **4**

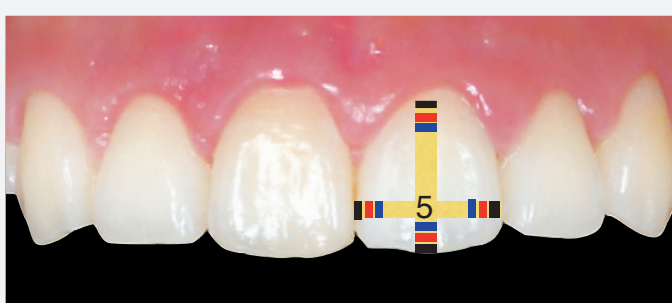
1. M & D Papilla	0	1	2
2. Keratinized Gingiva	0	1	2
3. Curvature of Gingival Margin	0	1	2
4. Level of Gingival Margin	0	1	2
5. Root Convexity (Torque)	0	1	2
6. Scar Formation	0	1	2

2. White Esthetic Score (for Micro-esthetics)

Total = **3**



1. Midline	0	1	2
2. Incisor Curve	0	1	2
3. Axial Inclination (5°, 8°, 10°)	0	1	2
4. Contact Area (50%, 40%, 30%)	0	1	2
5. Tooth Proportion (1:0.8)	0	1	2
6. Tooth to Tooth Proportion	0	1	2



1. Midline	0	1	2
2. Incisor Curve	0	1	2
3. Axial Inclination (5°, 8°, 10°)	0	1	2
4. Contact Area (50%, 40%, 30%)	0	1	2
5. Tooth Proportion (1:0.8)	0	1	2
6. Tooth to Tooth Proportion	0	1	2