Crowded Class II Division 2 Malocclusion

Clinicians: Drs. Chris Chang, Hsin-Yin Yeh, Sophia Pei-Wen Shu, W. Eugene Roberts
Patient: Miss Jhan

Pre-treatment Diagnosis

An 18 year old female presented with Class II Division 2 (*Class II/2*) malocclusion, deep overbite, severe crowding, and everted lower lip. Despite an overall retrognathic pattern, the first molars were Class I, because of blocked-in lower second premolars. Cephalometric radiography revealed a severe skeletal malocclusion (*ANB 9°*) attributable to a protrusive maxilla (*SNA 84°*) and retrognathic mandible (*SNB 75°*). The panoramic radiograph showed congenitally missing maxillary right third molar, but the other third molars were developing normally. Although extraction of upper 4s and lower 5s was indicated, the patient preferred a non-extraction approach.

Initial

Facial/Soft Tissue/Macroesthetics

Convex profile with retrognathic chin, relatively protrusive upper lip, and everted lower lip.

Smile/Miniesthetics

The smile was unattractive due to lingually tipped maxillary central incisors, labially displaced maxillary lateral incisors, and excessive gingival display.

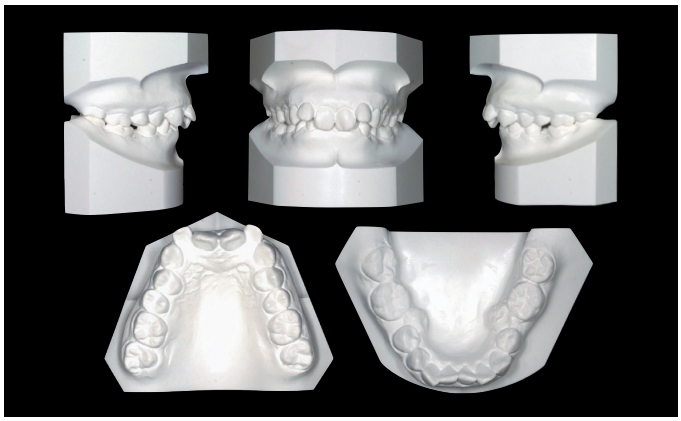

Appliance Used:

Damon® Clear™ upper anterior brackets and Damon® Q™ upper posterior and lower brackets.

Teeth/Microesthetics

The esthetic zone was compromised by irregular gingival margins, variable axial inclinations, severe crowding, localized gingivitis, and abnormal interproximal contacts.

Treatment Objectives and Plan

The treatment objectives were to achieve an ideal correction of facial and dental esthetics, while controlling lower facial height (*LFH*), vertical dimension of occlusion (*VDO*), and the mandibular plane angle (*FMA*). Utilize a full fixed, self-ligation appliance (*Damon Clear and Damon Q*), with the archwire sequence and auxiliaries as specified in Table 1. Place open coil springs between the mandibular first premolars and first molars to open space for the mandibular second premolars. Install anterior bite turbos (*BTs*) on the lingual surface of both maxillary central incisors, and use light short Class II elastics for posterior dental extrusion and intermaxillary correction. Insert extra-alveolar (*E-A*) bone screws in the infrazygomatic crests (*IZC*) bilaterally, to retract the maxillary buccal segments to attain a Class I relationship. Detail the alignment with bracket rebonding as needed, finishing bends and vertical elastics.

Table 1: Damon Q Variable Torque Employed

U1s: Standard torque (+15˚)

U2s: Standard torque (+6˚)

U3s: Standard torque (+7˚)

L2-2s: Low torque (-11˚)

L3s: Standard torque (+7˚)

Remove appliances and retain the corrected dentition with upper and lower fixed anterior retainers, augmented with clear overlay retainers in both arches.

Treatment Sequence

0 Month

U: Direct bonded brackets 7-7, engaged an .013" Optimal Force CuNiTi archwire from 6-6, and placed crimped stops mesial-distal to the right lateral incisor.

0 Month

1 Month

U: Placed drop-in hooks on first premolars.

L: Direct bonded 7-7, engaged an .014" Optimal Force CuNi-Ti archwire from 6-6, crimped stops mesial-distal to the right lateral incisor, and placed open coil springs L4s and L6s.

U/L: Early light short elastics from upper first premolar to lower first molar, bilaterally (*Quail, 3/16", 2 oz, full time*).

1 Month

3 Months

U: Bonded anterior BTs on both central incisors.

L: Transitioned to an .018" CuNiTi archwire.

U/L: Maintained the elastics from upper first premolar to lower first molar, bilaterally (*Quail, 3/16", 2 oz, full time*).

3 Months

7 Months

U: Transitioned to an .014 x .025" CuNiTi archwire.

L: Activated open coil springs.

U/L: Class II elastics from upper canine to lower molar, bilaterally (*Parrot, 5/16", 2 oz, full time*).

7 Months

11 Months

U: 2x12 mm stainless steel mini-screws (*OrthoBoneScrew®, Newton's A Ltd., Hsinchu, Taiwan*) were inserted in the IZCs, bilaterally. Elastomeric chains anchored by the bone screws retracted the upper dentition.

L: Activated open coil springs.

U/L: Stop elastics, lip incompetence noted

11 Months

14 Months

U: Maintained elastomeric chains from IZC screws to the upper canines to retract the upper dentition.

L: Bonded L5s, engaged an .014" Optimal Force CuNiTi archwire from 5-5, and bonded a button on the lingual surface of each lower right second premolar.

U/L: Crossbite elastics from buccal side of upper right second premolar to lingual side of lower right second premolar (*Chipmunk, 1/8", 2 oz, full time*).

14 Months

16 Months

U: Transitioned to an .017 x .025" TMA archwire, and placed elastomeric chains from the bone screws to the upper canines, bilaterally to retract the upper dentition.

L: Transitioned to an .014 x.025" CuNiTi archwire.

U/L: Elastics from IZC bone screws to lower canines (*Fox, 1/4", 3.5 oz, full time*).

22 Months

U: Transitioned to an .019 x .025" pre-torqued CuNiTi archwire, and placed elastomeric chains from IZC bone screws to the upper canines, bilaterally to retract the upper dentition.

L: Transitioned to an .017 x .025" TMA archwire.

U/L: Elastics from IZC bone screws to lower canines, bilaterally (*Fox, 1/4", 3.5 oz, full time*).

22 Months

26 Months

U: Elastomeric chains from the IZC bone screws to the upper canines, bilaterally to retract the upper dentition.

L: Molar-to-molar elastomeric chains.

U/L: Elastics from IZC bone screws to lower canines, bilaterally (*Fox, 1/4", 3.5 oz, full time*).

26 Months

31 Months

U: Archwire was sectioned distal to the canines, and drop-in hooks were inserted into the first and second premolar brackets.

L: Placed drop-in hooks on first and second premolars.

U/L: Continuous intermaxillary elastics (*Ostrich, 3/4" , 2 oz, full time*) were prescribed to settle the occlusion.

31 Months

32 Months

Removed all appliances and fixed retainers (*Retainium*) were bonded on upper 2-2 and lower 3-3. Upper and lower clear overlay retainers (*Essix*) were delivered. The patient was instructed to wear them full time for the first 6 months and nights only thereafter.

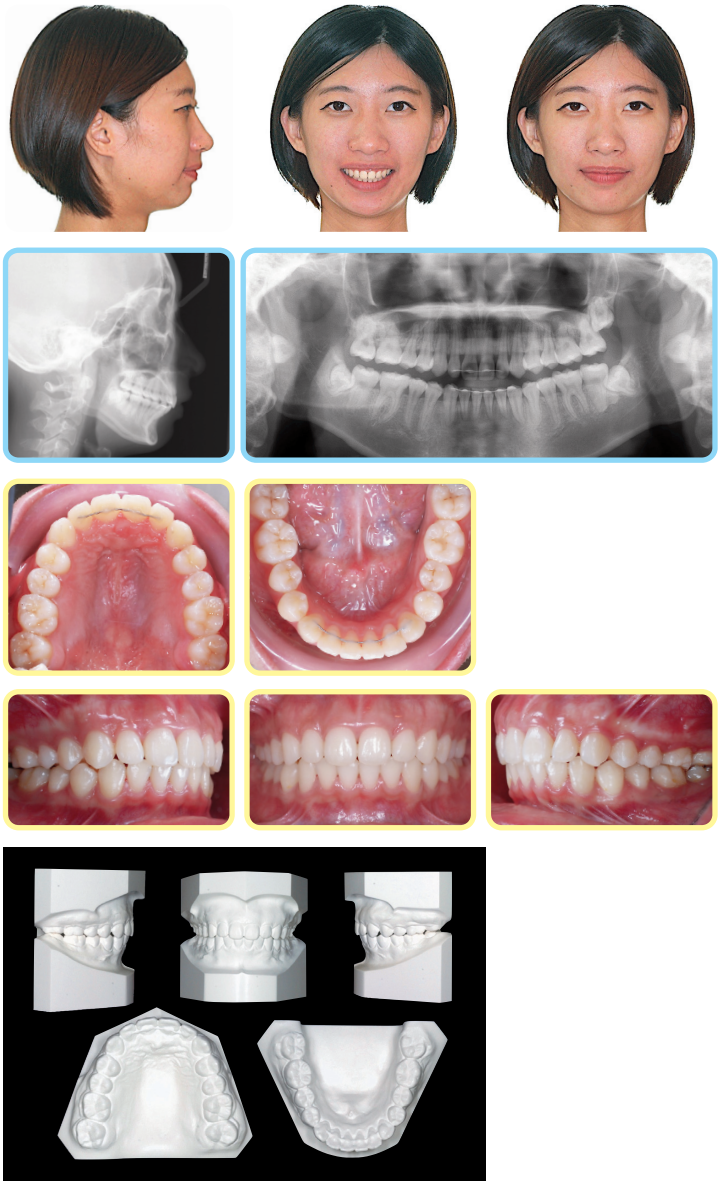

32 Months-Treatment Complete

39 Months Follow-up

There was a slight openbite between second molars on the left side, but all other dentofacial corrections were relatively stable, as finished.

39 Months follow-up

Case Discussion

The patient was pleased with the treatment results because the dental alignment and smile esthetics were near ideal. All treatment goals were achieved except for an increase in the VDO and LFH, as evidenced by a steepened mandibular plane angle (*FMA 34˚*) and excessive lower incisor angulation (*L1 to MP 109˚*). Despite these cephalometric concerns, post-treatment facial form was acceptable.

Skeletal Class II Div 2 malocclusion is difficult to treat and has a high risk of relapse. Depending on age and growth potential of the patient, there are several treatment options, such as: 1. non-extraction with temporary anchorage devices (*TADs*), 2. extraction of maxillary first

CEPHALOMETRIC SUMMARY			
SKELETAL ANALYSIS			
	PRE-Tx	POST-Tx	DIFF.
SNA° (82°)	84˚	84˚	0˚
SNB° (80°)	75˚	75˚	0˚
ANB° (2°)	9˚	9˚	0˚
SN-MP° (32°)	34˚	38˚	4˚
FMA° (25°)	30˚	34˚	4˚
DENTAL ANALYSIS			
U1 TO NA mm *(4 mm)*	-3 mm	-1 mm	2 mm
U1 TO SN° (110°)	84˚	103˚	19˚
L1 TO NB mm *(4 mm)*	4 mm	7 mm	3 mm
L1 TO MP° (90°)	95˚	109˚	14˚
FACIAL ANALYSIS			
E-LINE UL *(-2 mm)*	2 mm	0 mm	2 mm
E-LINE LL *(0 mm)*	1 mm	1 mm	0 mm

Table 2: Cephalometric Summary

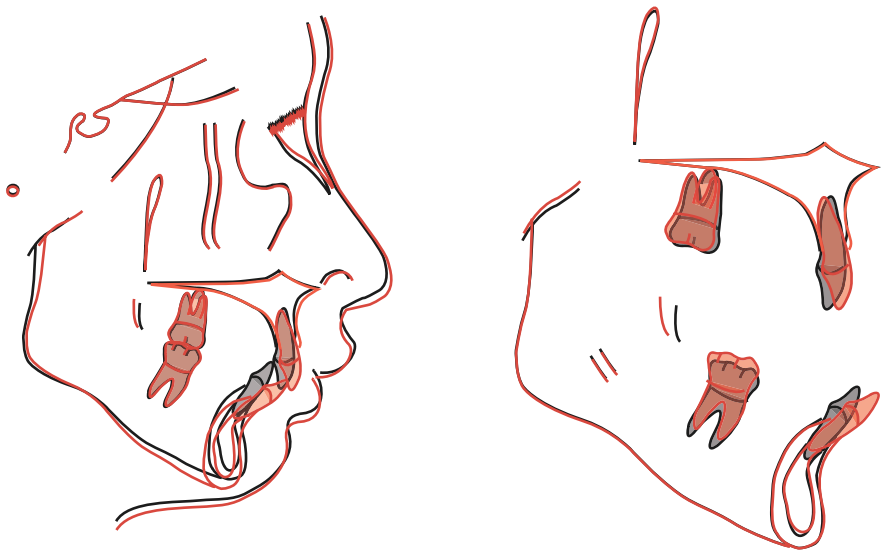

Superimposed cephalometric tracings

premolars and mandibular second premolars, and 3. orthognathic surgery for mandible advancement. The patient preferred nonsurgical orthodontic treatment to minimize the risk of facial compromise. Extraction treatment for Class II Div 2 may flatten the facial profile and deepen the bite. The patient's pre-treatment cephalometric radiograph showed a slightly protruded upper lip due to the flaring of the upper lateral incisors and relatively narrow arches. A non-extraction treatment plan was the patient's choice, so the Damon self-ligating system with extra-alveolar (*E-A*) TADs was indicated.

Variable torque brackets were particularly advantageous for aligning the upper arch, but the low torque brackets failed to prevent flaring of the lower incisors. The BTs and Class II elastics opened the LFH 4°. Transient incompetence lips were noted at 9 months into treatment. The bite opening facilitated the alignment of the severe skeletal malocclusion (*ANB 9°*), but resulted in intermaxillary alignment problems. It was necessary to increase the axial inclination of the lower incisors to prevent an opening of the overjet because the upper incisors were flared 19°.

Anterior BTs are excellent tools for the correction of deep bite if opening the bite and posterior mandibular rotation are acceptable mechanics. Fortunately, the transient incompetent lips noted at 9 months resolved by the end of treatment at 32 months. They are easy to use and decrease the treatment time for many patients. Early light Class II elastics play an important role in correcting deep bite without decreasing the smile arc. The light force reduces the side effects of the horizontal component of force, which can produce unnecessary tipping of the teeth. For the present patient, anterior BTs and Class II elastics resolved the overjet problem, but extruded the mandibular molars, which increased the mandibular plane angle due to posterior rotation of the mandible.

Anchorage is challenging for skeletal Class II Div 2 malocclusion. En masse movement of the anterior segment and improvement in the facial profile was accomplished with E-A anchorage via IZC bone screws. This minimally invasive method reduced treatment time and simplified the mechanics, but failed to control the LFH and VDO. Permanent retention is indicated for maintaining the camouflage correction of this severe skeletal Class II Div 2 malocclusion.

What I Should Do Differently Today?

In retrospect, repositioning the lower second molar brackets was indicted for more mesial-in rotation and extrusion. Increased torque for maxillary incisor brackets was needed for correction of their axial inclination. However, the principal problem was a lack of lower posterior anchorage to retract the buccal segments to make space for the blocked in lower second premolars. IZC bone screws can be used to retract the mandibular arch, but there is an extrusive component on the mandibular anterior segment. Mandibular Buccal Shelf (*MBS*) bone screws are ideal sagittal anchorage for retracting molars and preventing extrusion. The combined use of IZC and MBS bone screws provides anchorage in all four posterior quadrants to improve the skeletal and facial result when treating severe skeletal malocclusion.

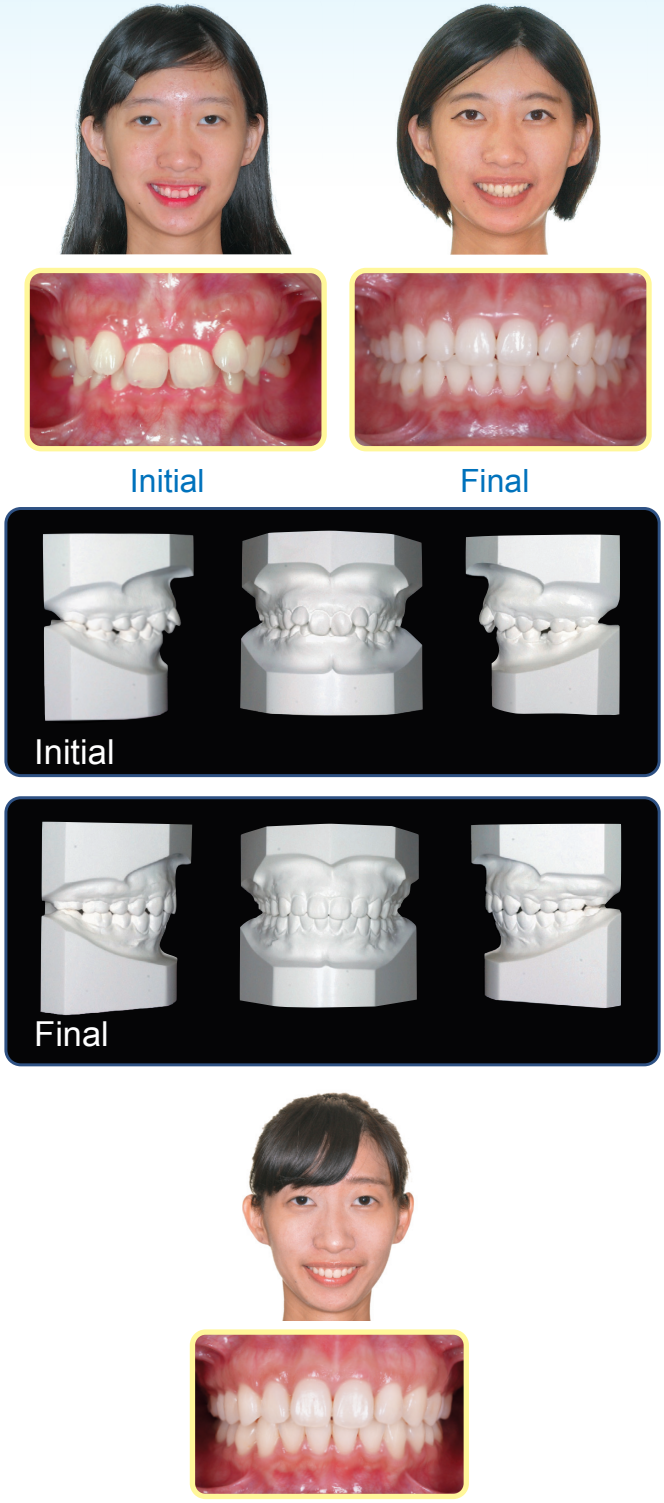

■ *39 Months Follow-up*

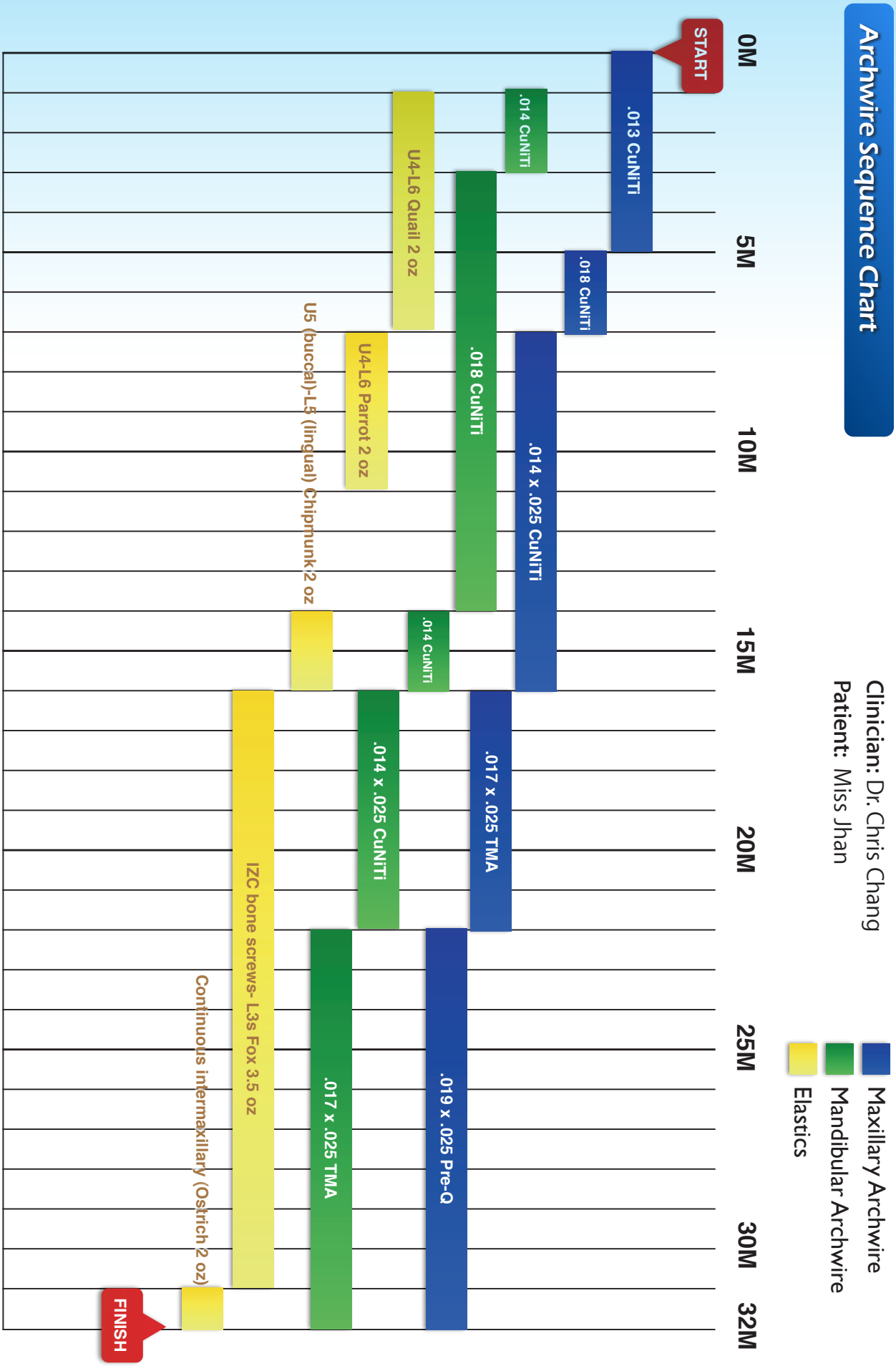
Archwire Sequence Chart
Clinician: Dr. Chris Chang
Patient: Miss Jhan
Maxillary Archwire
Mandibular Archwire
Elastics
0M
5M
10M
15M
20M
25M
30M
32M
START
.013 CuNiTi
.018 CuNiTi
.014 CuNiTi
.014 x .025 CuNiTi
.018 CuNiTi
U4-L6 Quail 2 oz
U4-L6 Parrot 2 oz
U5 (buccal)-L5 (lingual) Chipmunk 2 oz
.014 CuNiTi
.017 x .025 TMA
.014 x .025 CuNiTi
.019 x .025 Pre-Q
.017 x .025 TMA
IZC bone screws- L3s Fox 3.5 oz
Continuous intermaxillary (Ostrich 2 oz)
FINISH