

Atypical Extraction of Adult Orthodontic Treatment

History and Etiology

A 27-years-old female was referred by her dentist for orthodontic consultation (Fig. 1). Her chief concern was maxillary anterior crowding and missing mandibular teeth (Figures 2, 3). There were no contributory medical problems. Clinical exam indicated that the bilateral maxillary lateral incisors were in cross-bite and mandibular left 1st molar and right 1st premolar were missing (Fig. 2). The patient was treated to an acceptable result as documented in Figs. 4-9. The cephalometric and panoramic radiographs document the pre-treatment conditions (Fig. 7) and the post-treatment results (Fig. 8). The cephalometric tracings before and after treatment are superimposed in Fig. 9. The details for diagnosis and treatment will be discussed below.

Diagnosis

Skeletal:

Skeletal Class I (SNA 79°, SNB 77°, ANB 2°)

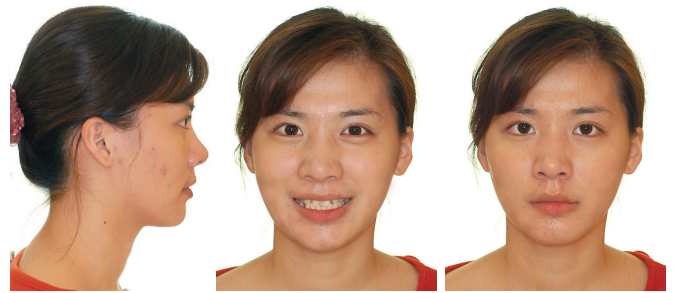Mandibular plane angle (SN-MP 40°, FMA 33°)

Dental:

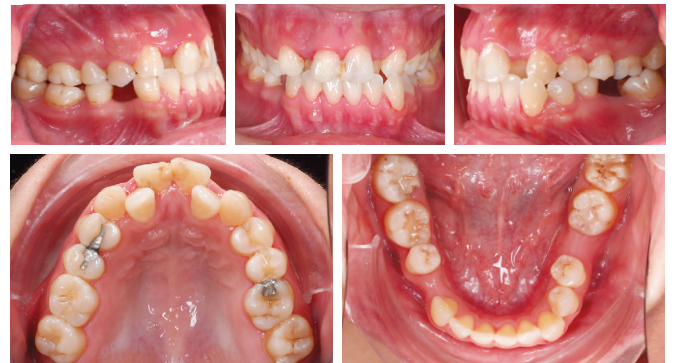Right Class II molar relationship, left Class I canine relationship.

Maxillary bilateral cross-bite of the lateral incisors associated with severe crowding of ~7mm (Fig. 10).

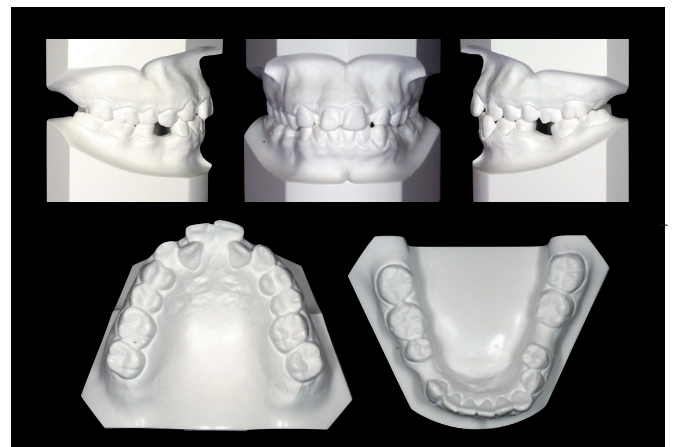Mandibular left 1st molar and right 1st premolar were missing; redundant space of ~13mm.



■ Fig. 1: Pretreatment facial photographs



■ Fig. 2: Pretreatment intraoral photographs

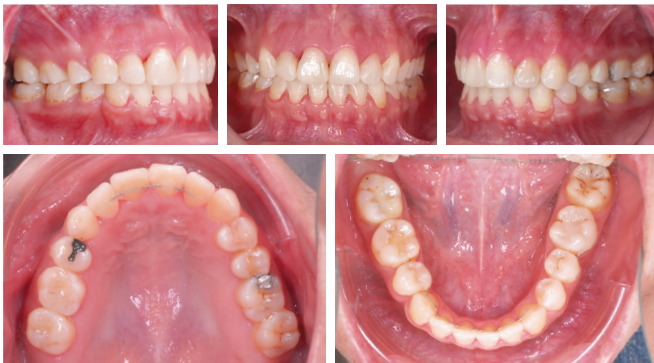

■ Fig. 3: Pretreatment study models

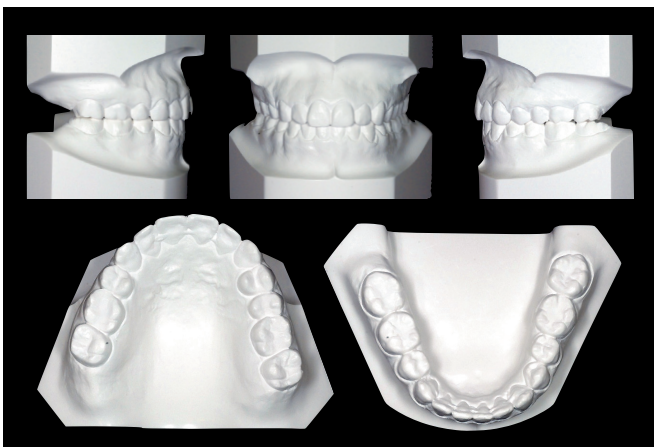Dr. Ming-Jen Chang, Lecturer, Beethoven Orthodontic Course (left)
 Dr. Chris Chang, Director, Beethoven Orthodontic Center (middle)
 Dr. W. Eugene Roberts, Consultant,
International Journal of Orthodontics & Implantology (right)



■ Fig. 4: Posttreatment facial photographs



■ Fig. 5: Posttreatment intraoral photographs



■ Fig. 6: Posttreatment study models

Facial:

Acceptable profile with acceptable lip position.
 The ABO Discrepancy Index (*DI*) was 24 as shown in the subsequent worksheet.

Specific Objectives of Treatment

Maxilla (*all three planes*):

- A - P: Modest retraction
- Vertical: Maintain
- Transverse: Maintain

Mandible (*all three planes*):

- A - P: Modest expansion
- Vertical: Maintain
- Transverse: Maintain

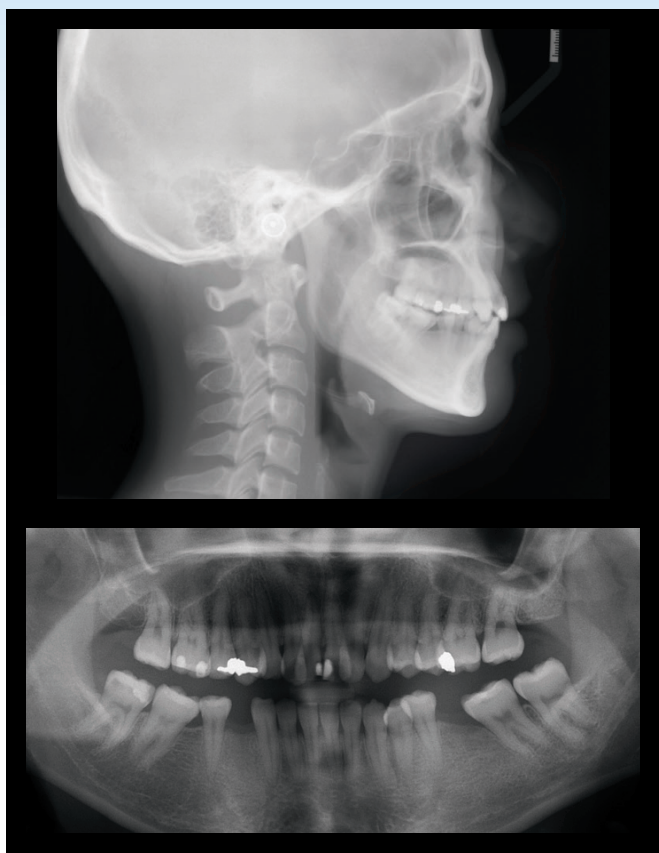
Maxillary Dentition

- A - P: Retract incisors
- Vertical: Maintain
- Inter-molar Width: Expand to correct the palatally displaced left 1st molar

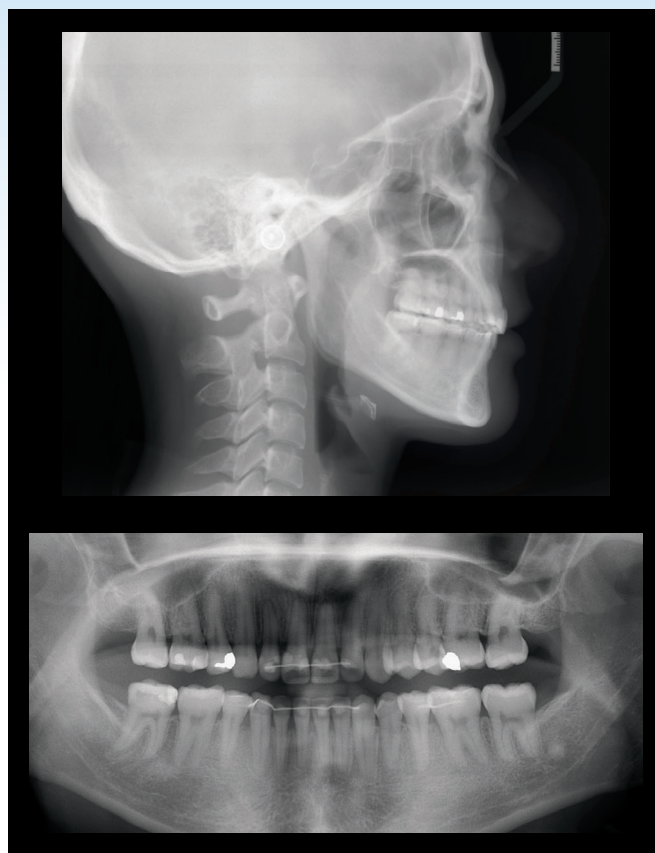
Mandibular Dentition

- A - P: Close edentulous spaces
- Vertical: Maintain
- Inter-molar / Inter-canine Width: Round out the arch over the apical base of bone

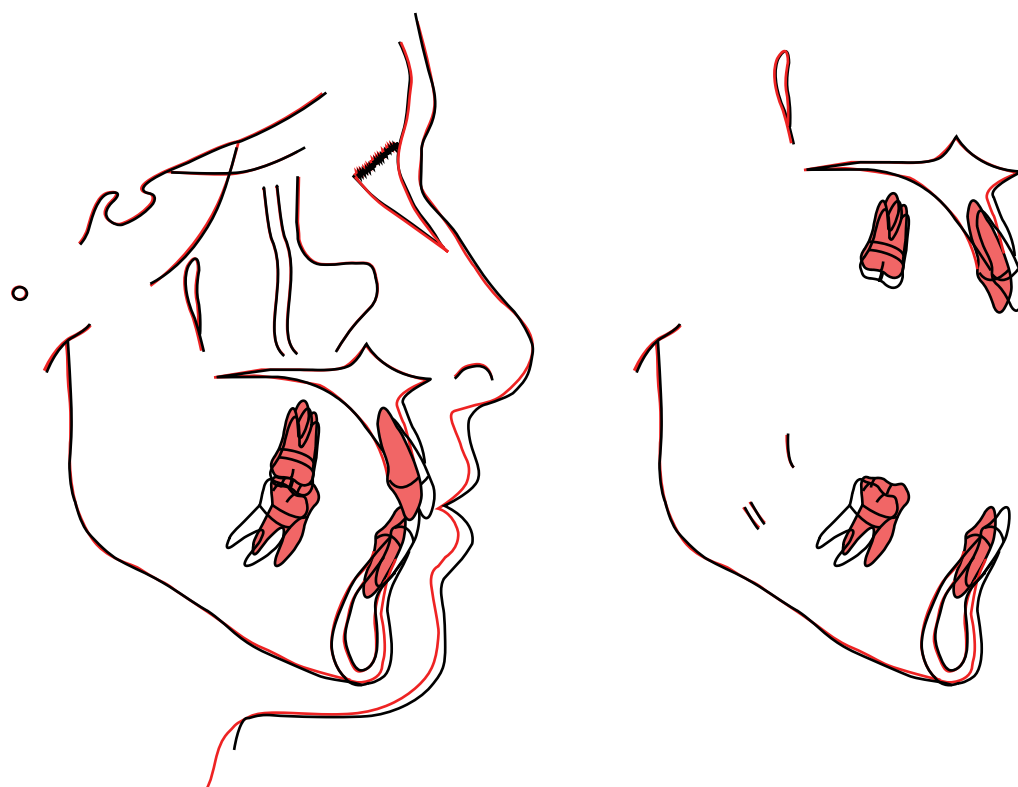
Facial Esthetics: Maintain



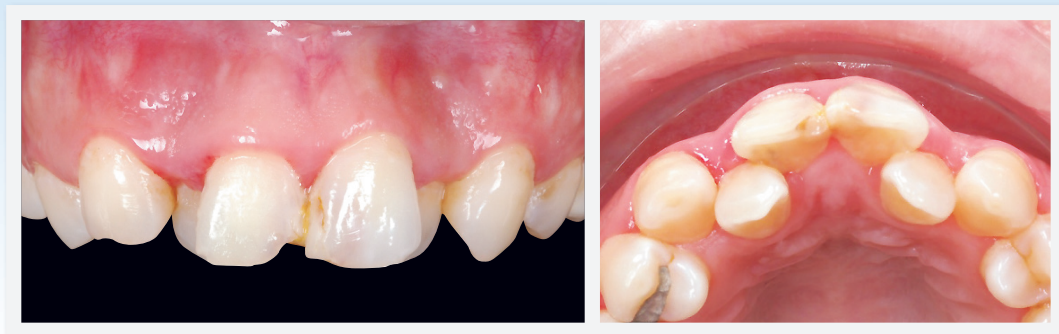■ Fig.7: Pretreatment pano and ceph radiographs



■ Fig. 8: Posttreatment pano and ceph radiographs



■ Fig. 9: Superimposed tracings showed retraction of upper & lower incisors.



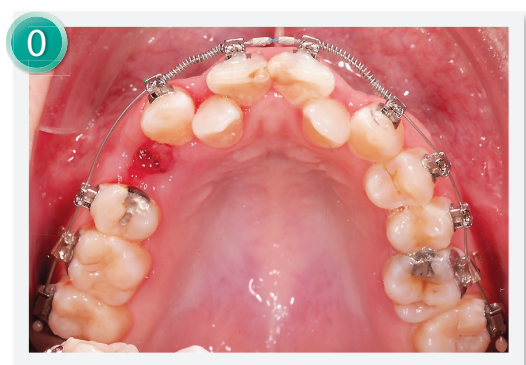■ Fig. 10: Bilateral lateral incisors cross-bite. Severe crowding about 7mm in upper arch.

Treatment Plan

Extraction treatment with a full fixed orthodontic appliance was indicated to align and level the maxillary dentition and close mandibular edentulous spaces. In the initial stage of treatment, the upper right 1st premolar was extracted to relieve maxillary anterior crowding (Fig. 11).

Posterior bite turbos assisted in anterior cross-bite correction. Class II elastics were used to resolve the sagittal occlusal discrepancy, and detail bending and settling elastics were planned to produce the final occlusion. The fixed appliances were removed and

the corrected dentition was retained with a fixed anterior retainer in both arches: 1. maxillary right lateral incisor to left lateral incisor, 2. mandibular right canine to left canine, and 3. mandibular left 2nd premolar to 2nd molar. Clear overlay retainers were later delivered for both arches.



■ Fig. 11:
Extraction of upper right 1st premolar to relieve upper anterior crowding.

CEPHALOMETRIC			
SKELETAL ANALYSIS			
	PRE-Tx	POST-Tx	DIFF.
SNA°	79°	78°	1°
SNB°	77°	76°	1°
ANB°	2°	2°	0°
SN-MP°	40°	39.5°	0.5°
FMA°	33°	32.5°	0.5°
DENTAL ANALYSIS			
U1 TO NA mm	6 mm	4 mm	2 mm
U1 TO SN°	99°	92°	7°
L1 TO NB mm	6 mm	4 mm	2 mm
L1 TO MP°	90°	83.5°	6.5°
FACIAL ANALYSIS			
E-LINE UL	-4 mm	-6 mm	2 mm
E-LINE LL	-1 mm	-4 mm	3 mm

■ Table. Cephalometric summary

Appliances and Treatment Progress

A .022" slot Damon D3MX bracket system (*Ormco*) was used. The maxillary arch was bonded with standard torque brackets in the anterior segment, and open coil springs were placed bilaterally between the central incisors and canines to open space for correction of the lateral incisors cross-bite (*Fig. 12*). After three months of initial alignment and leveling, the bilateral lateral incisors were bonded with reversed standard torque brackets, and the mandibular arch was bonded with high torque brackets on canines & standard torque on incisors (*Fig. 13*). The posterior bite turbos were placed on the maxillary 1st molars to open the bite and reduce the occlusal interference blocking the correction of the bilateral cross-bite of the lateral incisors (*Figs. 13 and 14*). The initial archwires were .014 CuNiTi. Following correction of the anterior cross-bite, an open coil spring was placed between the maxillary central incisors to open space for restorations.

Eight months after the initiation of treatment, the round wires were replaced with rectangular .014x.025 CuNiTi wires. In the same appointment, the open coil spring already opened adequate space between the maxillary central incisors for restoration of normal dental morphology (*Fig. 15*). Four months later, .016x.025 pre-Q archwires were used on both maxillary and mandibular arches, and the maxillary anterior segment was ligated with a figure-eight tie of an .012" stainless steel ligature. Then anterior bite turbos were placed on the palatal side of maxillary central incisors to correct anterior deep bite (*Fig. 16*).

Class II elastics were used from the upper left canine to the lower left 2nd molar to correct the midline deviation. In the fifteenth month of treatment, the .019x.025 pre-Q archwires were used to adjust the torque control of anterior segments in both arches (*Fig. 17*). Two months later, .019x.025 SS archwires were placed, and closed coil springs were used to close the mandibular arch spaces (*Fig. 18*). At the finishing stage, a panoramic radiograph was taken to evaluate bracket positions relative to the axial inclinations of all teeth (*Fig. 19*). Bracket repositions were performed as indicated. A torquing spring was placed on the upper left canine to move the root palatally, as the maxillary arch was leveled (*Fig. 20*).

After 29 months of active treatment, all appliances were removed. Three weeks after fixed appliance removal, a gingivectomy of maxillary incisors was performed with diode laser to improve incisal exposure (1:0.8) (*Fig. 21*). The corrected dentition was retained with fixed anterior retainers on both arches: 1. maxillary right lateral incisor to left lateral incisor, 2. mandibular right canine to left canine and 3. mandibular left 2nd premolar to 2nd molar. Clear overlay retainers were delivered on both arches.

Results Achieved

Maxilla (*all three planes*):

- A - P: Retracted
- Vertical: Maintained
- Transverse: Maintained

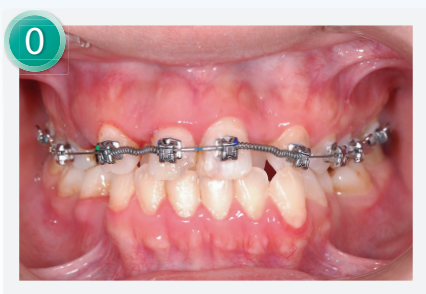

Fig. 12:
The upper arch was bonded and the open coil springs were placed between bilateral central incisors and canines.

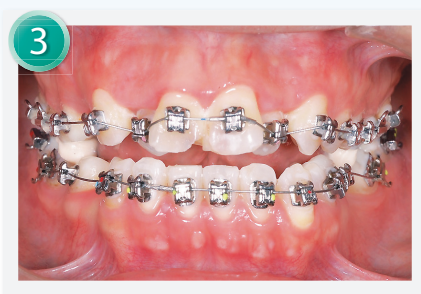

Fig. 13:
The bilateral lateral incisors were bonded with reversed standard torque brackets and the mandibular arch was bonded with high torque brackets.

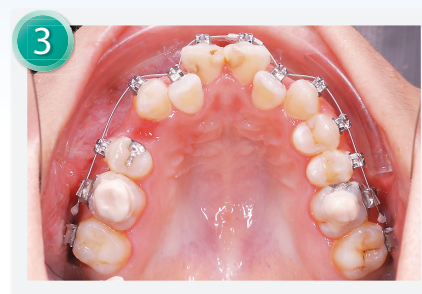

Fig. 14:
The posterior bite turbos were placed on the maxillary 1st molars to protrude bilateral lateral incisors.

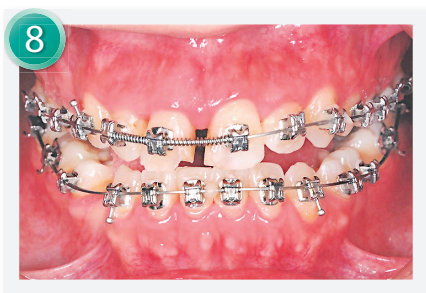

Fig. 15:
The open coil spring already opened the middle space for restoration of the two central incisors.

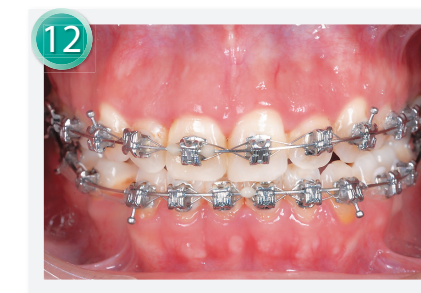

Fig. 16:
The anterior six teeth were fixed by figure-eight ligature wires. Then the anterior bite turbos were placed on the palatal side of upper central incisors to correct anterior deep bite.

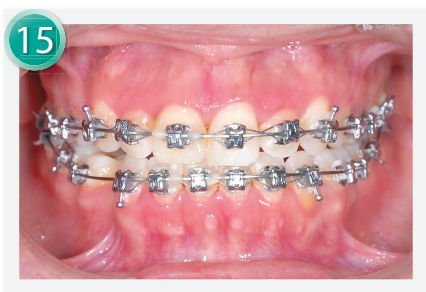
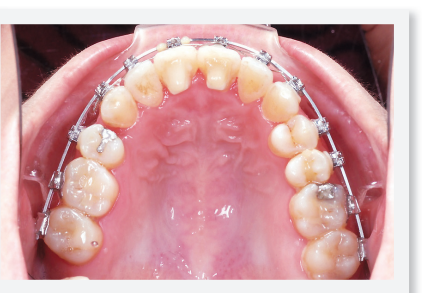
Fig. 17:
The .019x.025 pre-Q archwires were used to adjust the torque control of the anterior four teeth on both arches.

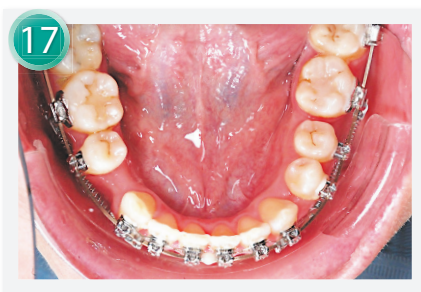


Fig. 18:
The closed coil springs were put over lower dentition on both sides for closing the extraction spaces.

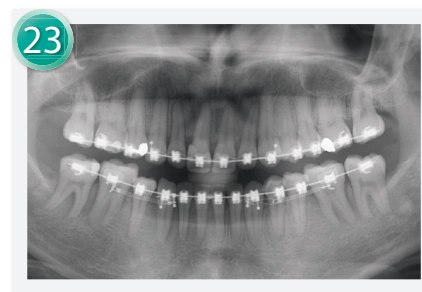
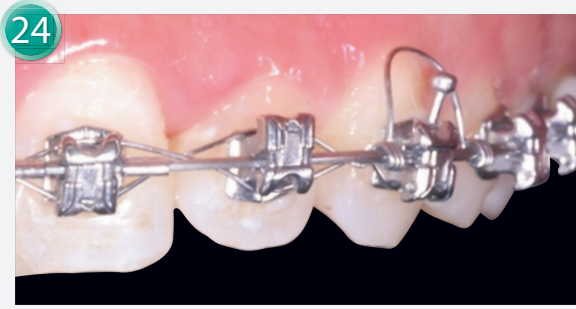
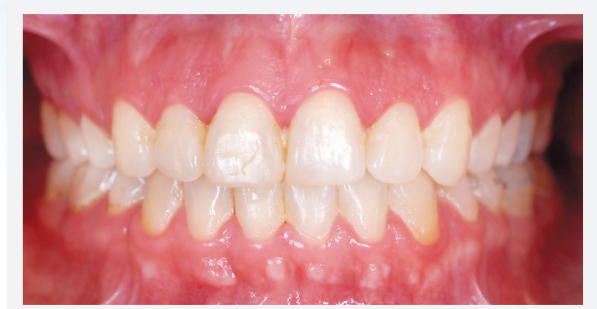

Fig. 19:
The panoramic radiograph was indicated to check the root angulation.



■ Fig. 20:
Use a torquing spring to increase palatal root torque.



■ Fig. 21:
Post-treatment intra-oral frontal photo.

Mandible (all three planes):

- A - P: Retracted
- Vertical: Maintained
- Transverse: Maintained

Maxillary Dentition

- A - P: Retracted
- Vertical: Maintained
- Inter-molar / Inter-canine Width: Maintained

Mandibular Dentition

- A - P: Retracted
- Vertical: Maintained
- Inter-molar / Inter-canine Width: Maintained

Facial Esthetics: Upper and lower lips were retracted consistent with acceptable facial form.

Retention

The maxillary fixed retainer was bonded on all incisors. An anterior mandibular fixed retainer was bonded on all teeth from canine to canine. In addition, a mandibular posterior retainer was bonded from the 2nd premolar to 2nd molar. Upper

and lower clear overlay retainers were delivered. The patient was instructed to wear them full time for the first 6 months and nights only thereafter. The patient was instructed in the home care and maintenance of the retainers.

Final Evaluation of Treatment

The ABO Cast-Radiograph Evaluation score was 21 points. The major discrepancies were unevenly marginal ridges (8 points) and occlusal contacts (6 points).

Alignment and restorative recontouring of the upper anterior incisors, and closure of lower extraction spaces helped resolve the patient’s chief complaints. The excessive spaces of the lower extraction site was eliminated, but long-term retention will be necessary to prevent relapse.

Overall, there was significant improvement in both dental esthetics and occlusion. The profile was treated to an appropriate result with no esthetic problems.

Discussion

Stepovich¹ concluded that spaces of 10mm or more can be closed in adults, but retaining the closed spaces was difficult. In the present case, the spaces was 13mm. As such, a fixed buccal retainer was placed from the left second premolar to second molar in the mandibular arch to prevent the space from reopening.

Roberts² described the bone physiology of second and third mandibular molars when protracted into a missing first molar space. The relatively flat roots of the molars move through the center of the alveolar process by resorbing primarily trabecular bone on the mesial surface and forming cortical bone on the distal surface of each root. For the first few millimeters of tooth movement, the molars move rapidly. However, as the trailing root engages the cortical bone formed by the leading root, the rate of molar protraction decreases until space closure is accomplished.

Vanarsdall and Swartz³ described the common sequelae for a missing mandibular first molar as (1) mesially inclined second and/or third molars, (2) distal drift of the premolars, (3) extrusion of the maxillary molars, (4) altered gingival form with constriction of the edentulous ridge, (5) infrabony defect mesial to the inclined molar, (6) stepped marginal ridges, (7) food impaction, and (8) posterior collapse. However, the negative sequelae in the maxillary arch are usually less severe than in the mandibular arch. Many clinicians still believe that when the buccolingual width of the alveolar ridge is constricted, the second molar cannot be move mesially. However, Roberts² has demonstrated

that even severely atrophy extraction sites can be closed if the teeth moved into the extraction site are periodontally healthy.

Moreover, there might be an incomplete space closure. For the present patient, the 13mm space was closed in the posterior region of the mandible. If the edentulous ridge is at least half the width of the teeth being moved into the ridge, then the remodeling process would probably be successful.⁴ However, if the edentulous ridge is less than half the width of the tooth root, then a dehiscence in the bone is likely to form over the labial or lingual surfaces of the root.⁵ When closing first molar spaces in the mandible, young adults generate more alveolar bone than older adult patients. Furthermore, retention of space closure is more difficult for older adult patient than for younger adults.

Edwards⁶ suggested that excess gingival tissue could be a factor associated with residual spaces and advocated the surgical removal of any tissue that accumulates interproximally during treatment, as originally described by Casko et al.⁷

To achieve an optimal result for the present patient, the initial step was extraction of right upper first premolar and alignment of upper teeth. Coil springs were used for opening spaces. Meanwhile, posterior bite turbos facilitated the protrusion of cross-bite teeth. Anterior bite turbos were used to solve anterior deep bite, always in conjunction with early light short elastics. The panoramic radiographs were useful for checking the root angulation. To achieve excellence finishing results, diode soft tissue laser was applied to improve tooth proportion.

The curvature and level of the gingival margin were acceptable. With regard to the upper esthetic zone, the maxillary dental midline was 1.5mm to the right of the facial midline and the axial inclination of right lateral incisor was too distal. The Pink & White esthetic score worksheet listed below provides a broad array of clinical parameters for evaluation of patients with esthetics concerns.

The ABO CRE score was 21, with most of the points reflecting problems in marginal ridges. If a panoramic radiograph had been used earlier in the treatment, bracket rebonding might have facilitated a more complete correction of the marginal ridges and occlusal contacts.

Conclusion

Atypical extraction is common in orthodontic treatment of adults. Closing posterior spaces for these patients is important because lower posterior teeth play an important role in occlusal function, particularly with respect to maintaining the vertical dimension of occlusion. Axial inclination problems are best identified with a panoramic radiograph after leveling of both arches. Repositioning malaligned brackets early in treatment facilitates optimal second order alignment. The root torque spring is ideal for controlling root angulation in the buccolingual plane. Coil springs are very effective for opening and closing space, as required. Early light short elastics helped correct the midline discrepancy.

This difficult malocclusion ($DI = 24$) was treated to

an acceptable result ($CRE = 21$). The patient and the clinician were pleased with the treatment result.

Acknowledgment

Thanks to Ms. Tzu Han Huang for proofreading this article.

References

1. Stepovitch MI. A clinical study on closing edentulous spaces in the mandible. *Angle Ortho* 1979;49:227-33.
2. Roberts WE. Rate of translation of mandibular molars using implant-anchored mechanics. *Angle Ortho* 1996;66:331-37.
3. Vanarsdall RL, Swartz ML. Molar uprighting, Ormco catalog NO. 740-0014, Glendora, Calif, 1980, Ormco Corporation.
4. Kokich VG, Kokich VO. Interrelationship of orthodontics with periodontics and restorative dentistry. In: Nanda, R. *Biomechanics and Esthetic Strategies in Clinical Orthodontics*. St. Louis: Elsevier;2005:18.
5. Kokich VG, Mathews DP, Spear FM. Inheriting the Unhappy Patient: An interdisciplinary Case Report. *Advanced Esthetics & interdisciplinary Dentistry* 2005;1:12-20.
6. Edwards JG. The prevention of relapse in extraction cases. *Am J Ortho* 1971;60:128-141
7. Casco JS, et al. Objective grading system for dental casts and panoramic radiographs. *Am Orthod Dentofacial Orthop* 1998;114:589-599.
8. Liang JY, Chang CH, Roberts WE. Chapter 6: Correction of Bimaxillary Protrusion with Closing of Premolar & Molar Extraction Spaces. *Orthodontics Vol.I*. 2012;87-100
9. Chang CH. Advanced Damon Course No. 8: Excellence in Finishing, Beethoven Podcast Encyclopedia in Orthodontics 2011, Newton's A Ltd, Taiwan.
10. Chang CH. Advanced Damon Course No. 4,5 : DI & CRE Workshop (1)(2). Podcast Encyclopedia in Orthodontics 2011, Newton's A Ltd, Taiwan.
11. Chang CH. Basic Damon Course No.5: Finish Bending. Podcast Encyclopedia in Orthodontics 2011, Newton's A Ltd, Taiwan.
12. Huang S, Pitts T. Secrets of Excellent Finishing. *News & Trends in Orthodontics* 2009;14:6-23.

IBOI Discrepancy Index Worksheet

TOTAL D.I. SCORE = 24

OVERJET

- 0 mm. (edge-to-edge) =
- 1 – 3 mm. = 0 pts.
- 3.1 – 5 mm. = 2 pts.
- 5.1 – 7 mm. = 3 pts.
- 7.1 – 9 mm. = 4 pts.
- > 9 mm. = 5 pts.

Negative OJ (x-bite) 1 pt. per mm. per tooth =

Total = 7

OVERBITE

- 0 – 3 mm. = 0 pts.
- 3.1 – 5 mm. = 2 pts.
- 5.1 – 7 mm. = 3 pts.
- Impinging (100%) = 5 pts.

Total = 0

ANTERIOR OPEN BITE

0 mm. (edge-to-edge), 1 pt. per tooth
then 1 pt. per additional full mm. per tooth

Total = 0

LATERAL OPEN BITE

2 pts. per mm. per tooth

Total = 0

CROWDING (only one arch)

- 1 – 3 mm. = 1 pt.
- 3.1 – 5 mm. = 2 pts.
- 5.1 – 7 mm. = 4 pts.
- > 7 mm. = 7 pts.

Total = 4

OCCLUSION

- Class I to end on = 0 pts.
- End on Class II or III = 2 pts. per side 2 pts.
- Full Class II or III = 4 pts. per side pts.
- Beyond Class II or III = 1 pt. per mm. pts. additional

Total = 2

LINGUAL POSTERIOR X-BITE

1 pt. per tooth Total = 1

BUCCAL POSTERIOR X-BITE

2 pts. per tooth Total = 0

CEPHALOMETRICS (See Instructions)

ANB $\geq 6^\circ$ or $\leq -2^\circ$ = 4 pts.

Each degree $< -2^\circ$ x 1 pt. =

Each degree $> 6^\circ$ x 1 pt. =

SN-MP $\geq 38^\circ$ = 2 pts.

Each degree $> 38^\circ$ 2 x 2 pts. = 4

$\leq 26^\circ$ = 1 pt.

Each degree $< 26^\circ$ x 1 pt. =

1 to MP $\geq 99^\circ$ = 1 pt.

Each degree $> 99^\circ$ x 1 pt. =

Total = 6

OTHER (See Instructions)

- Supernumerary teeth x 1 pt. =
- Ankylosis of perm. teeth x 2 pts. =
- Anomalous morphology x 2 pts. =
- Impaction (except 3rd molars) x 2 pts. =
- Midline discrepancy (≥ 3 mm) @ 2 pts. =
- Missing teeth (except 3rd molars) 2 x 1 pts. = 2
- Missing teeth, congenital x 2 pts. =
- Spacing (4 or more, per arch) 1 x 2 pts. = 2
- Spacing (Mx cent. diastema ≥ 2 mm) @ 2 pts. =
- Tooth transposition x 2 pts. =
- Skeletal asymmetry (nonsurgical tx) @ 3 pts. =
- Add. treatment complexities x 2 pts. =

Identify:

Total = 4

IMPLANT SITE

- Lip line : Low (0 pt), Medium (1 pt), High (2 pts) =
- Gingival biotype : Low-scalloped, thick (0 pt), Medium-scalloped, medium-thick (1 pt), High-scalloped, thin (2 pts) =
- Shape of tooth crowns : Rectangular (0 pt), Triangular (2 pts) =
- Bone level at adjacent teeth : ≤ 5 mm to contact point (0 pt), 5.5 to 6.5 mm to contact point (1 pt), ≥ 7 mm to contact point (2 pts) =
- Bone anatomy of alveolar crest : H&V sufficient (0 pt), Deficient H, allow simultaneous augment (1 pt), Deficient H, require prior grafting (2 pts), Deficient V or Both H&V (3 pts) =
- Soft tissue anatomy : Intact (0 pt), Defective (2 pts) =
- Infection at implant site : None (0 pt), Chronic (1 pt), Acute(2 pts) =

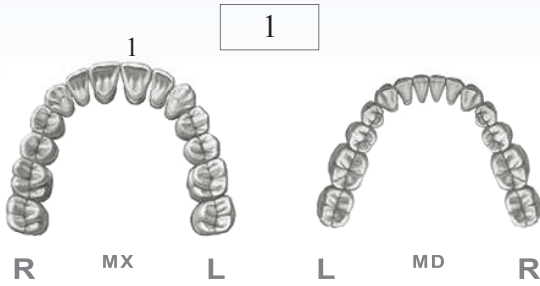
Total = 0

IBOI Cast-Radiograph Evaluation

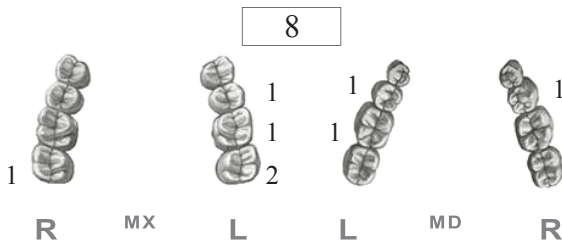
Case # 1 Patient

Total Score: **21**

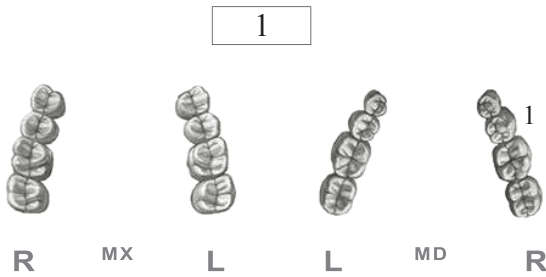
Alignment/Rotations



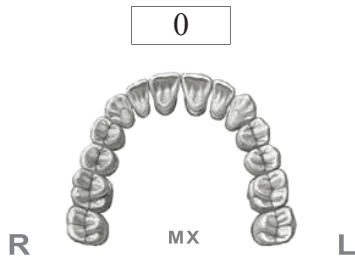
Marginal Ridges



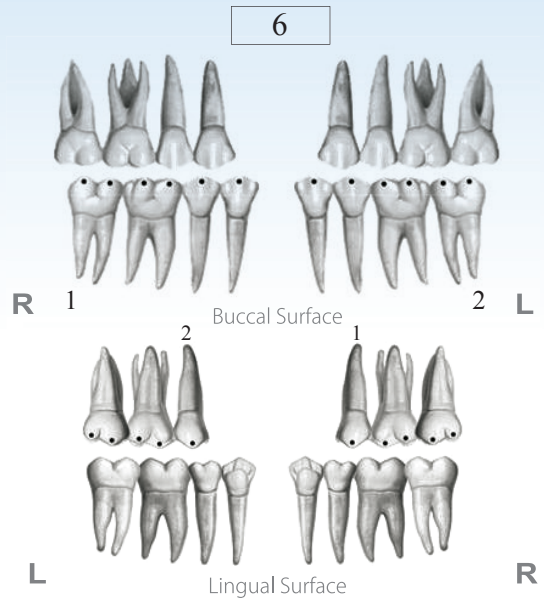
Buccolingual Inclination



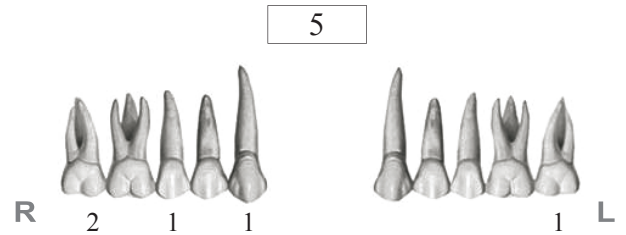
Overjet



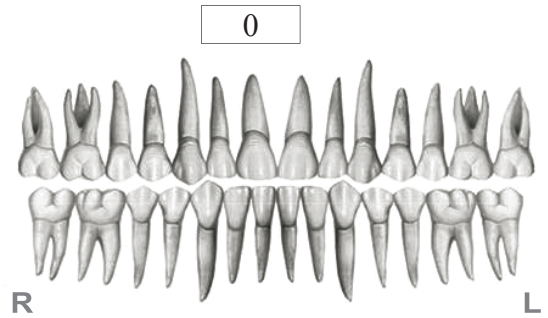
Occlusal Contacts



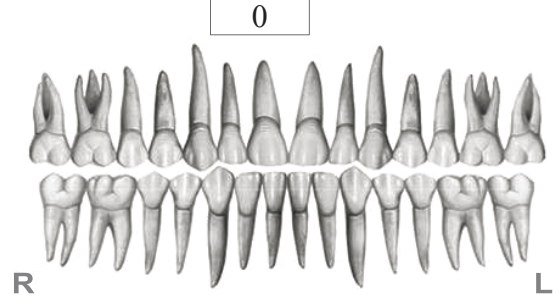
Occlusal Relationships



Interproximal Contacts



Root Angulation

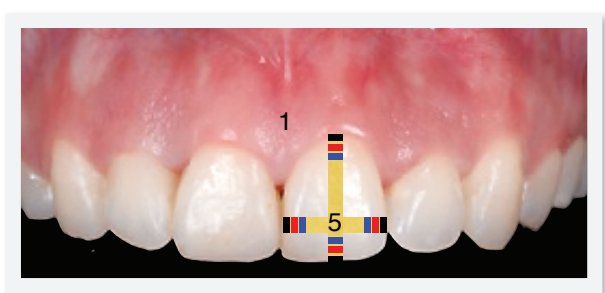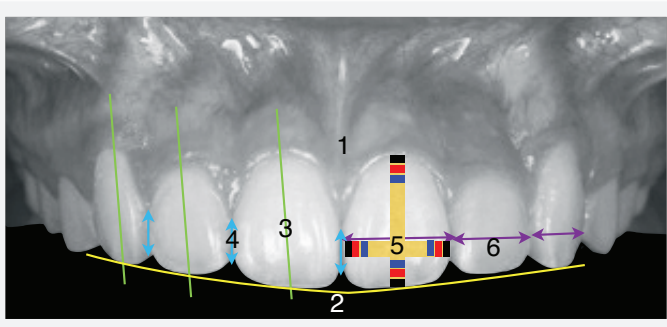
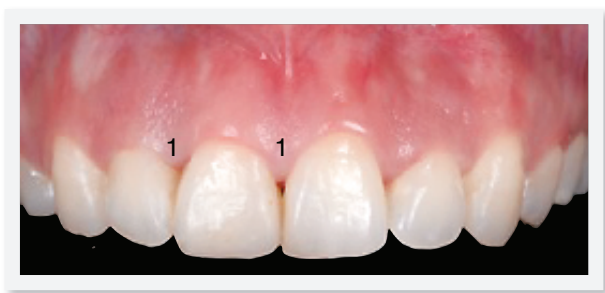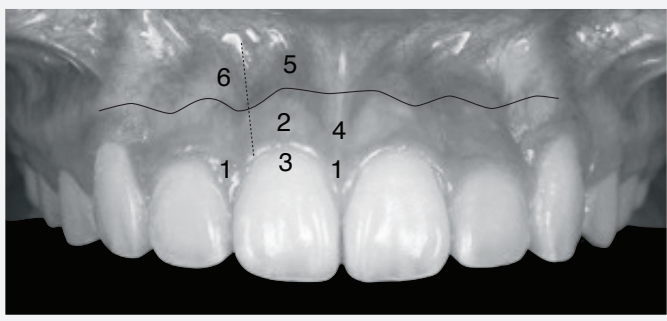


INSTRUCTIONS: Place score beside each deficient tooth and enter total score for each parameter in the white box. Mark extracted teeth with "X". Second molars should be in occlusion.

IBOI Pink & White Esthetic Score

Total Score: = 4

1. Pink Esthetic Score



Total = 2

1. Mesial Papilla	0	1	2
2. Distal Papilla	0	1	2
3. Curvature of Gingival Margin	0	1	2
4. Level of Gingival Margin	0	1	2
5. Root Convexity (Torque)	0	1	2
6. Scar Formation	0	1	2

1. M & D Papilla	0	1	2
2. Keratinized Gingiva	0	1	2
3. Curvature of Gingival Margin	0	1	2
4. Level of Gingival Margin	0	1	2
5. Root Convexity (Torque)	0	1	2
6. Scar Formation	0	1	2

Total = 2

1. Tooth Form	0	1	2
2. Mesial & Distal Outline	0	1	2
3. Crown Margin	0	1	2
4. Translucency (Incisal third)	0	1	2
5. Hue & Value (Middle third)	0	1	2
6. Tooth Proportion	0	1	2

1. Midline	0	1	2
2. Incisor Curve	0	1	2
3. Axial Inclination (5°, 8°, 10°)	0	1	2
4. Contact Area (50%, 40%, 30%)	0	1	2
5. Tooth Proportion (1: 0.8)	0	1	2
6. Tooth to Tooth Proportion	0	1	2