

# The Wisdom of Managing Wisdom Teeth

## Part III. Methods of Molar Uprighting

### (A) Introduction

There are many ways of uprighting impacted molars. Many techniques of molar uprighting have been described in literature<sup>1-3</sup>. Several of them involve removable appliances which require patient cooperation<sup>4</sup>, and/or surgical exposure of the impacted molar, or removing part of the alveolar bone<sup>5</sup>. Through the advancement of wire materials and TADs (*temporary anchorage devices*), the method of molar uprighting has been greatly simplified.

In this article the author summarizes six methods of molar uprighting with detailed diagrams by Dr. Rungsi. The author hopes this article can serve a good clinical reference when selecting an appropriate method for solving difficult impactions.

### (B) Methods of Molar Uprighting

#### (1) Yao-Qiang Miao's method<sup>6</sup>

A-1. A mini-hook is fabricated from a .014" stainless steel wire. Bend the wire into a circle with a diameter of 1.5mm extending in a perpendicular arm 1.5mm in length. At the top of the soldering push-spring arm, bend a hook parallel to the circle. Bond the mini hook at the disto-occlusal side of the impacted molar, with the hook opening mesially.

A-2. Solder an .018" stainless steel wire about 60mm in length, to the middle of the lingual surface of the mesially adjacent molar band. Fabricate a double or triple bend push spring.

B. Activation: Compressing the double or triple loop spring to engage the mini-hook.

C. During treatment: The impacted molar can be uprighted distally.

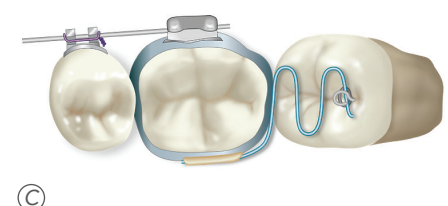
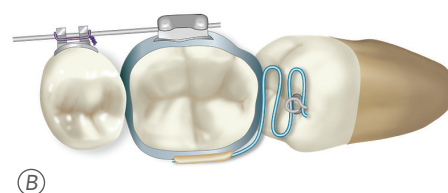
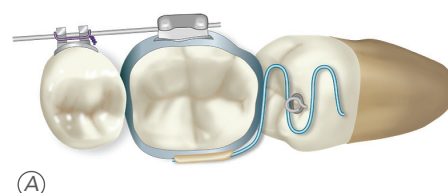
#### Advantages

This procedure is only appropriate when only the disto-buccal part of the molar is impacted applied.

#### Disadvantages

- (1) Need to construct a push spring and mini-hook.
- (2) Need to band the adjacent molars and cement it.

Miao's Method



Dr. John Jin-Jong Lin  
MS, Marquette University  
Chief Consultant of IJOI  
President of TAO ( 2000~2002 )  
Author of Creative Orthodontics



## (2) Shou-Hsin Kuang's method

A-1. Bond a lingual button over the disto-buccal of the impacted molar.

A-2. It needs an additional auxiliary .018" x .025" gingival tube on the adjacent molar.

A-3. Use a .017" x .025" TMA wire to bend double helix one at the mesial side of the adjacent molar, one at the distal side, and engage the distal hook over the lingual button.

B. Tie the mesial helix with the hook of the adjacent molar to activate the distal pushing and uprighting force.

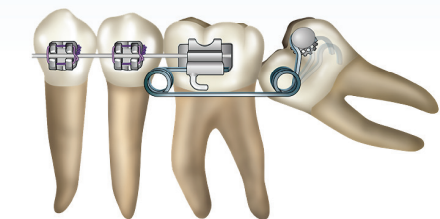
C. The impacted molar was not only pushed distally but also uprighted by the pushing spring.

D-1. Put lingual buttons over the disto-buccal side of the impacted lower 2<sup>nd</sup> molars.

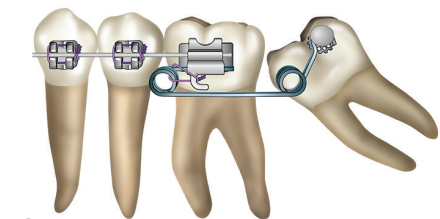
D-2. AIPS stands for Anterior Inserting Pushing Spring. The .017" x .025" TMA AIPS was engaged on the gingival tube of the lower 1<sup>st</sup> molar, and were activated by tying the ligature wire.

D-3. After about 6 months in treatment, the impacted 2<sup>nd</sup> molars were uprighted with AIPS.

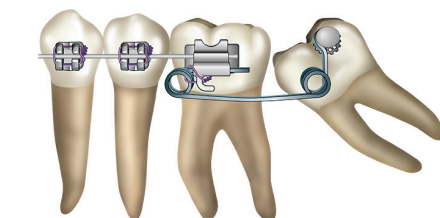
### Kuang's Method



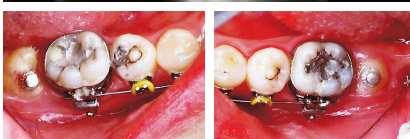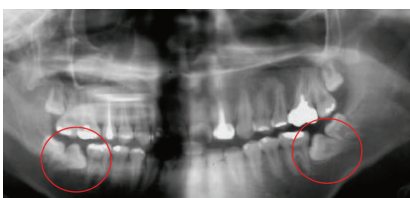
(A)



(B)



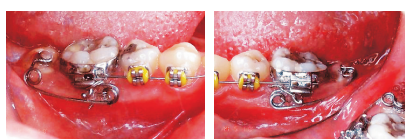
(C)



Courtesy of Dr. Shou-Hsin Kuang

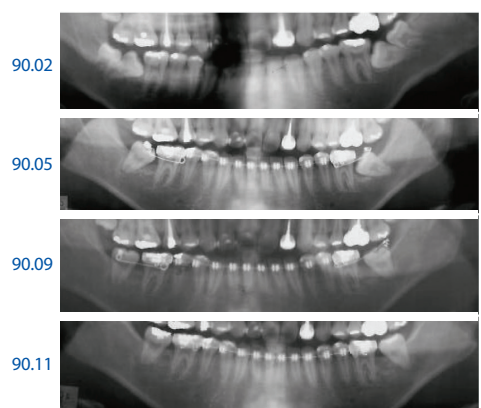
(D1)

### Molar uprighting with AIPS Anterior Inserting Pushing Spring



Courtesy of Dr. Shou-Hsin Kuang

(D2)



Courtesy of Dr. Shou-Hsin Kuang

(D3)

E-1. The pushing springs were engaged in the gingival tube of the lower 1<sup>st</sup> molar and activated by tying the ligature wire.

E-2. The occlusal view of the AIPS has been engaged and activated.

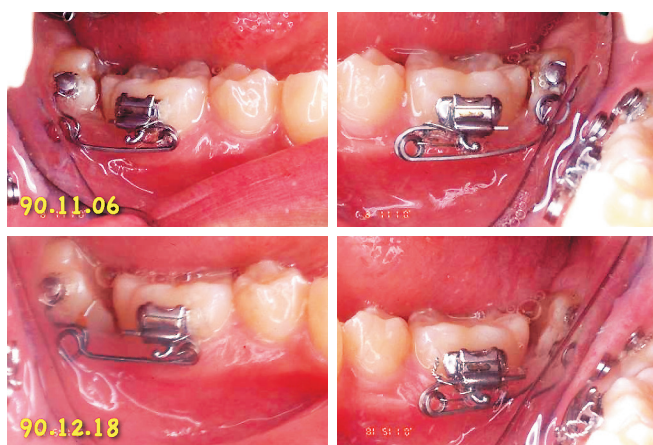
E-3. About 5 months in treatment, the impacted 2<sup>nd</sup> molars were uprighted, despite the presence of the impacted 3<sup>rd</sup> molars.

#### Advantages

- (1) The technique is suitable only when a very small disto-occlusal part of the impacted molar partially erupted.
- (2) The double helix push spring applies a very gentle force on the .017" x .025" TMA wire.

#### Disadvantages

- (1) It is time consuming to bend a double helix push-spring.
- (2) Sometimes the helix will impinge on the soft tissue around the narrow vestibular space buccal to the impacted molar.
- (3) It may catch food debris easily, hygiene instruction is needed.

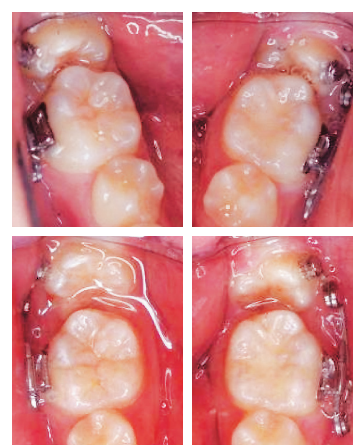


Courtesy of Dr. Shou-Hsin Kuang

(E-1)

90.11.06

90.12.18



Courtesy of Dr. Shou-Hsin Kuang

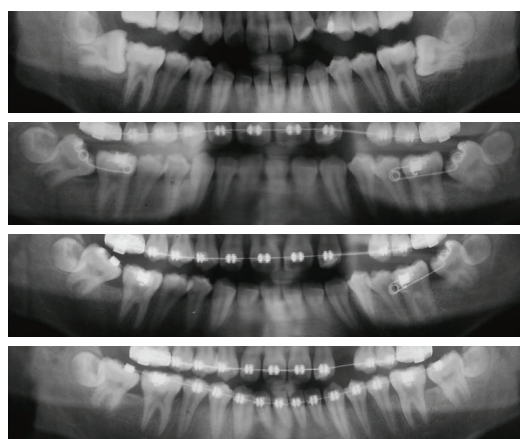
(E2)

90.07.05

91.02.19

91.04.09

91.07.30



Courtesy of Dr. Shou-Hsin Kuang

(E-3)



### (3) Yu-Cheng Liaw's method

#### A. Construction of a push NiTi wire

- (1) Attach an additional auxilliary .018" x .025" gingival tube over adjacent molar.
- (2) Bond a lingual button over the disto-buccal of the impacted molar.
- (3) Use of a section of .016" x .022" nickel titanium wire, gripping a stop over the distal of the auxilliary tube, and bend a loop over distal end about 5mm distal to the lingual button with the hammerhead plier.

#### B. Activation: Engaging the push NiTi wire to the lingual button.

#### C. After treatment the impacted molar uprighted.

#### D. On the typodont

- (1) The hammerhead plier (Hu-Friedy NiTi tie-back bender plier), .016" x .022" NiTi wire and stopper.
- (2) Put on the stopper and bend a loop on the .016" x .022" NiTi wire with the hammerhead plier.
- (3) Measure the force, about 150~200gm.
- (4) The pushing NiTi wire engaged on the typodont.

#### E. (A) The NiTi push spring is engaged.

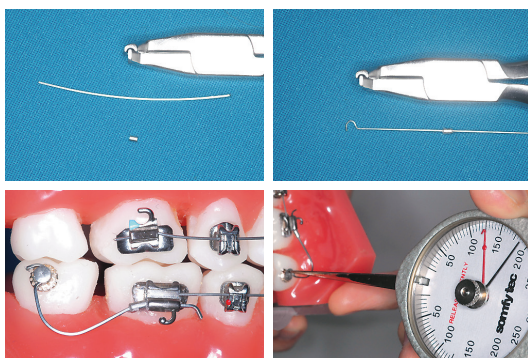
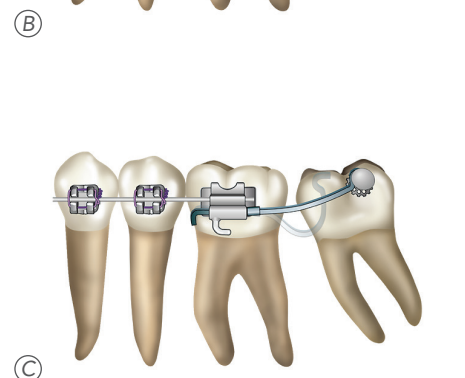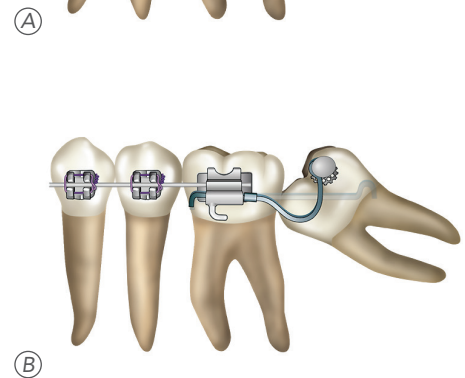
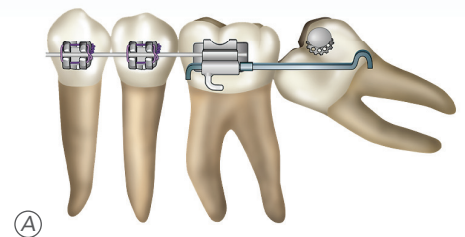
- (B) After 4 months, the impacted 2<sup>nd</sup> molar was uprighted.

#### Advantages

- (1) This method is a modification after Kuang's method. Instead of using a .017" X .025" TMA wire with double helix, a straight .016" x .022" NiTi wire is used.
- (2) There is less wire bending involved.
- (3) Only a small part of the disto-occlusal of the impacted molar required to be exposed.

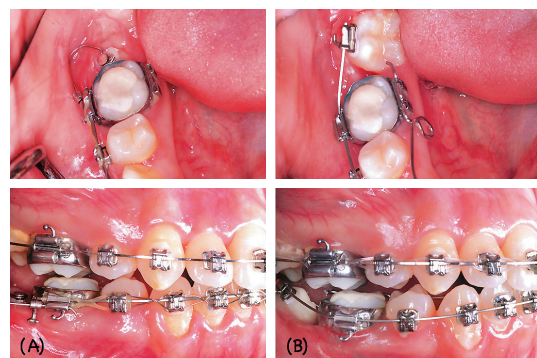
#### Disadvantages

It needs an additional auxiliary tube over the adjacent molar.



Courtesy of Dr. Yu-Cheng Liaw

(D)



Courtesy of Dr. Yu-Cheng Liaw

(E)

#### (4) Richard Bach's method

- A. Insert a .014" x .025" CuNiTi wire between the mesial side of the impacted molar and the distal side of the adjacent molar.
- B. Bend the wire to the occlusal surface of the adjacent molar and secure the wire over occlusal surface with light cured composite.
- C. About 17 weeks later, the impacted molar can be uprighted.

##### Advantages

- (1) There is no need to wait for enough exposure of the disto-buccal side of the impacted molar.
- (2) The mechanical design is very simple.
- (3) Surgical exposure is not required in this technique.

##### Disadvantages

- (1) In Dr. Bach's cases it seems that the impacted molar will be distalize excessively.
- (2) Occlusal interference sometimes occurs due to composite over the occlusal surface of the molar. For open bite cases, this kind of technique should be avoided.

#### (5) Chris Chang's method

- A-1. Surgically expose the impacted molar and bond a small lingual tube over the distal side of the impacted molar.
- A-2. Put an OBS (*OrthoBoneScrew*) over the distal side of the impacted molar in the retromolar area.
- B. Pull and upright the impacted molar with power chains or elastic threads.
- C. After enough exposure of the crown of the impacted molar, bond a buccal tube and use a NiTi wire to upright the impacted molar.

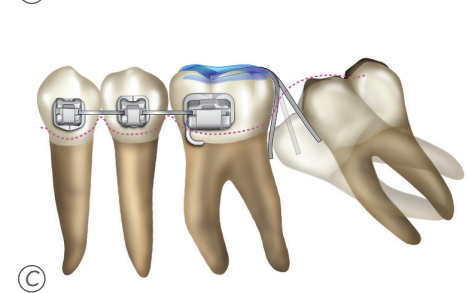
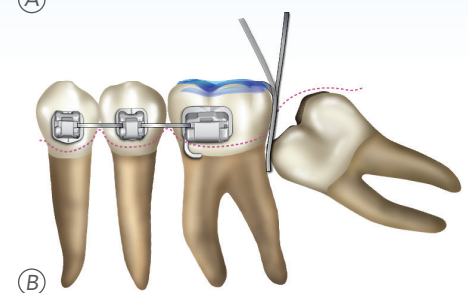
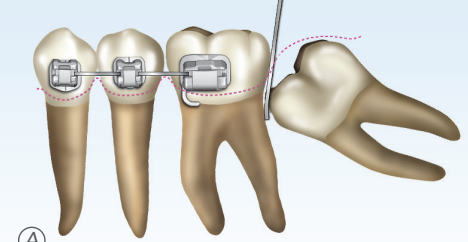
##### Advantages

This technique is very useful for very deeply impacted molars which can be uprighted over a short period of time.

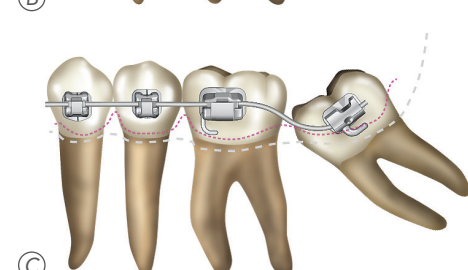
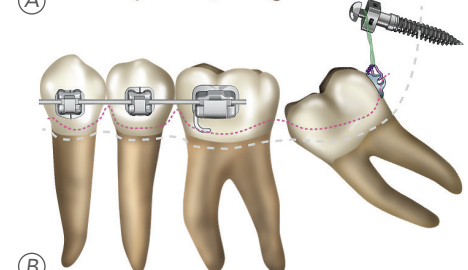
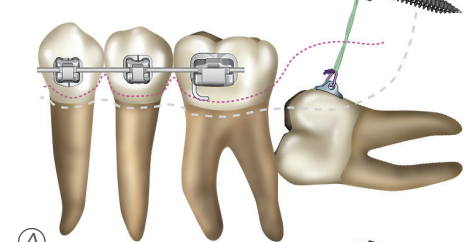
##### Disadvantages

Comprehensive surgical exposure in the retromolar area is a major surgery for patients.

Bach's Method



Chang's Method



**(6) John Jin-Jong Lin's method<sup>7</sup>**

A. Bonding on the impacted molar

A-1. As long as the exposed disto-buccal surface area of the impacted molar is large enough for bonding a ultra short buccal tube is bonded.

A-2. Use a .014" or .016" Nickel Titanium wire, thread in the open coil spring.

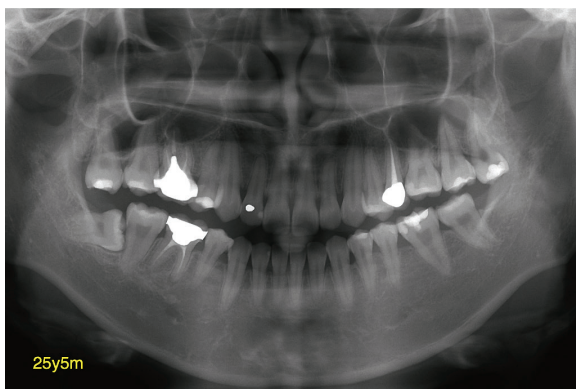
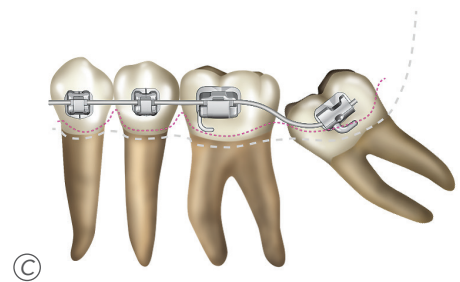
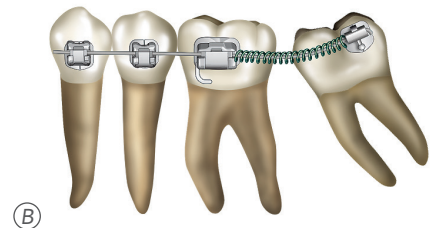
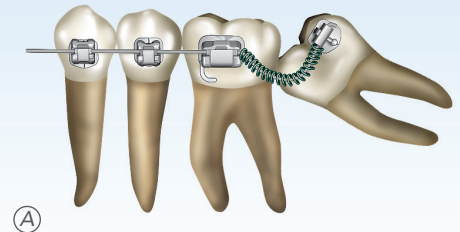
B. The open coil spring is activated between the tubes of two molars.

C. When the impacted molar is distally uprighted, rebond a normal sized buccal tube.

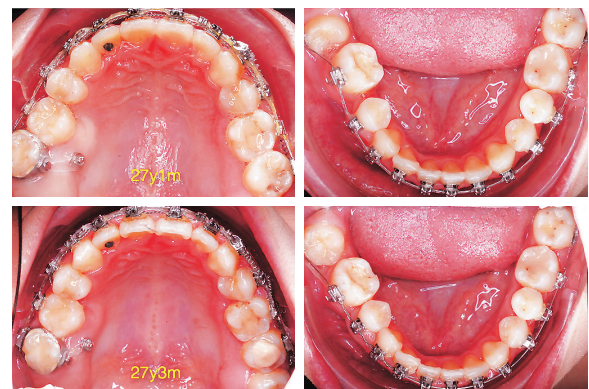D-1. The panoramic film indicates the right upper 1<sup>st</sup> molar has received endodontic treatment and was poorly restored. The left upper 2<sup>nd</sup> premolar and right lower 1<sup>st</sup> molar were removed. Notice the right upper 3<sup>rd</sup> molar is elongated.

D-2. The elongated right upper 3<sup>rd</sup> molar was intruded by the miniscrew over palatal side of the elongated 3<sup>rd</sup> molar, the elongated right upper 3<sup>rd</sup> molar was intruded, to create enough space to upright the impacted right lower 3<sup>rd</sup> molar. The molar tube was bonded on the partially erupted right lower 3<sup>rd</sup> molar.

Lin's method



①



②



D-3. The hanging down lingual cusp of right upper 3<sup>rd</sup> molar was intruded by the palatal miniscrew. It creates enough space for uprighting the impacted right lower 3<sup>rd</sup> molar.

D-4. By engaging a NiTi wire into the impacted lower 3<sup>rd</sup> molar, it was gradually uprighted. For managing this kind of asymmetric molar extraction cases, replacing badly restored 1<sup>st</sup> molars with good 3<sup>rd</sup> molars usually takes time. In this case it took more than 3 years. It should be explained to patients in advance!

D-5. 25y5m: poorly restored right upper 1<sup>st</sup> molar and right lower 1<sup>st</sup> molar were removed.

26y9m: severely elongated right upper 3<sup>rd</sup> molar.

27y4m: a severely elongated right upper 3<sup>rd</sup> molar was intruded with a palatal lingual screw. An open coil spring was used to upright the impacted lower 3<sup>rd</sup> molar.

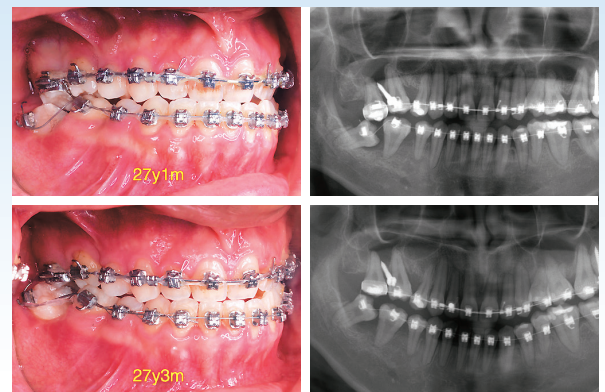
28y6m: both upper and lower 3<sup>rd</sup> molars were aligned into a good position. Notice the much leveled gingival margin of the posterior teeth as long as enough space is provided.

### Advantages

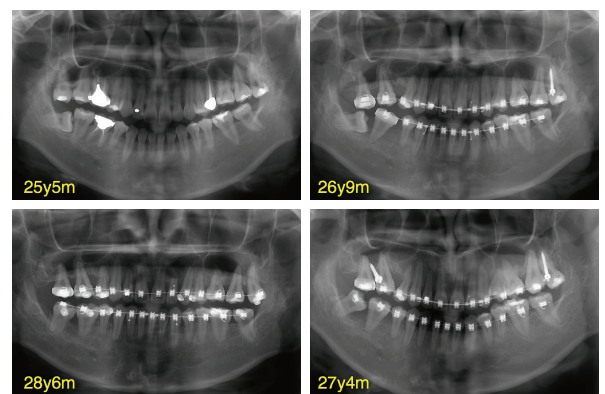
- (1) Surgical exposure is not required in over 95% of impaction cases with sufficient space. Impaction tends to self-erupt as long as enough space is provided.
- (2) There is no auxiliaries required, such as push springs, hooks, mini-screws and molar tubes.
- (3) Patients can follow simple routine orthodontic treatment.

### Disadvantages

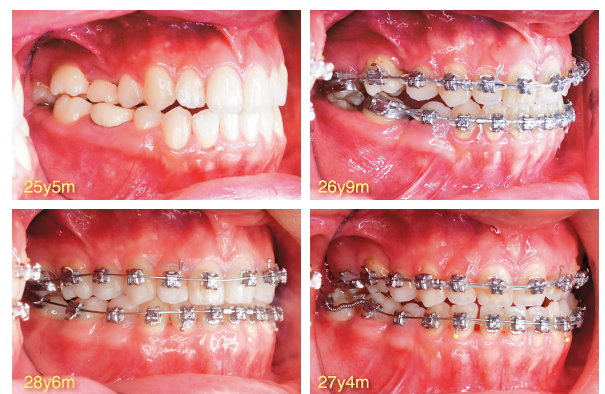- (1) Sometimes the disto-buccal surface of the impacted molar is insufficiently exposed, it will be very difficult to bond the molar tube.
- (2) If the disto-buccal part of the impacted molar is not expose yet, and the patient does not want to wait for too long, surgical exposure will be indicated.



(D3)



(D4)



(D5)

## CONCLUSION

Space is the first consideration in treating impaction. Insufficient space is the primary cause for impacted molars. When enough space is created the impacted tooth will erupt by itself. This concept of auto eruption is well discussed in the literature <sup>7</sup>.

The posterior space can be created by either extraction of the decayed lower 1<sup>st</sup> molar, 2<sup>nd</sup> molar, or even directly the impacted 3<sup>rd</sup> molar. After extraction of one of the molars, there will be enough space for the impacted molar to self erupt. However, it's difficult for the impacted molar to erupt into a perfect situation. As long as the impacted molar's disto-buccal part is erupted, a lingual button or buccal tube can be bonded. The impacted tooth can be uprighted using Miao's, Kuang's, Liaw's or Lin's method.

The impacted molar will erupt partially followed by extraction of a neighboring tooth. If the patient prefers a faster approach, Bach's or Chang's method is more suitable. One can also use Miao's, Kuang's, Liaw's or Lin's method followed by surgical exposure.

## ACKNOWLEDGEMENT:

1. Thanks for Dr. Tom Pitts introducing Bach's method in Ormco's Asian master Course on July 21, 2011.
2. Thanks for Dr. Kuang and Dr. Liaw sharing their methods and cases.
3. Thanks for Dr. Chang's OBS technique.
4. Thanks for Dr. Bach's new idea of molar uprighting.
5. Thanks for Dr. Rungsi's great effort to make all the wonderful diagrams for reader easily to follow the real clinical steps by reading the diagrams.
6. Thanks for Tzu Han's perfect English editing.

## REFERENCES

1. Shapira, Y.; Borell, G.; Nahlieli, O.; and Kuftinec, M.M.: Uprighting mesially impacted mandibular permanent second molars, Angle Orthod. 68:173-178, 1998.
2. Kogod, M. and Kogod, H.S.: Molar uprighting with the piggyback buccal sectional arch wire technique, Am. J. Orthod. 99:276-280, 1991.
3. Majourau, A. and Norton, L.A.: Uprighting impacted second molars with segmented springs, Am. J. Orthod. 107:235-238, 1995.
4. Gazit, E. and Lieberman, M.: A mesially impacted mandibular second molar. Treatment considerations and outcome: A case report, Am. J. Orthod. 103:374-376, 1993.
5. Li, J. Z. : Orthodontic treatment of mesially impacted lower third molar in absence of the lower first molar, Chin. J. Orthod. 7:78-80, 2000.
6. Miao YQ, Zhong H. An uprighting appliance for impacted mandibular second and third molars. J Clin Orthod. 2006 Feb;40(2): 110-6.
7. Lin J J. Do teeth want to be straight? A nonsurgical approach to unerupted teeth. World J Orthod. 2005 Fall; 6(3):248-57.