

## IBOI Pink & White esthetic score

### 1. Pink esthetic score

The gingival response to an anterior esthetic evaluation is assessed by the Pink Esthetic Score (PES) from clinical photography according to six variables scored from 0→2:

1. Mesial & distal papillae,
2. Keratinized gingiva,
3. Curvature of the gingival margin,
4. Level of the gingival margin,
5. Root convexity(torque),
6. Scar formation.

1. The mesial and distal papillae are assessed for a complete papilla (score 0), incomplete papilla, (score 1), or absence of a papilla( score 2).
2. The keratinized gingiva is scored by the thick biotype (score 0), thin biotype (score 1) or absence of the keratinized gingiva (score 2).
3. The curvature of the gingival margin, also defined as the line of emergence of the gingival margin, is evaluated as being identical to comparative teeth (score 0), slightly different (score 1), or markedly different (score 2).
4. The level of the gingival margin is scored by comparison to the contralateral tooth in terms of an identical vertical level (score 0), a slight ( $\cong 1\text{ mm}$ ) discrepancy (score 1), or a

major ( $\cong 1\text{ mm}$ ) discrepancy (score 2).

5. The root convexity (*labial prominence*) combines three additional specific soft tissue parameters as one variable: Normal labial prominence (score 0), Bulky, gum overgrowth (score 1), depressed concavity or gum recession (score 2).
6. The scar formation is scored by the absence of scar (score 0), partial presence (score 1), and apparent presence (score 2).

### 2. White esthetic score

The white esthetic score can be separated into anteriors segment evaluation and single one from clinical photography. For micro-esthetic, six variables scored from 0→2:

1. Midline,
2. Incisor curve,
3. Axial inclination,
4. Contact area,
5. Tooth proportion,
6. Tooth to tooth proportion.

For single crown, there are also six variables:

1. Tooth form,
2. Mesial & distal outline,
3. Crown margin,
4. Translucency,



Dr. Bill Su, Director, Newtons Implant Center

5. Hue & Value,
6. Tooth proportion.

For macro-esthetic score:

1. The midline: upper midline equal to lower midline (score 0), midline off <3mm, (score 1), or midline  $\geq$  3mm (score 2).
2. The incisor curve is scored by smooth curve (score 0), uneven curve (score 1) or missing/crowding dentition (score 2).
3. The axial inclination, align with standard angulation 5°, 8°, 10° : (score 0), slightly different: (score 1), or crowding/spacing: (score 2).
4. The contact area, the ratio of the contact area to crown length from central incisor to canine are 50% : 40% : 30% (score 0), unsymmetry of the contact area on right and left anterior segment (score 1), slight prolong of contact area (score 2)
5. The tooth proportion: For upper incisors, following the ratio of 1 : 0.8 (score 0), shorter crown length (score 1), longer crown length (score 2).
6. Tooth to tooth proportion, following the golden proportion ( 1.6:1:0.6 ): (score 0), a slight discrepancy (score 1), missing/crowding: (score 2).

### White esthetic score for single restoration:

A score of 2, 1, or 0 is assigned to all six parameters. Thus, in case of an optimum implant/tooth restoration, a minimum total WES of 0 is recorded. All six parameters are assessed by direct comparison with the natural, contralateral reference tooth, estimating the degree of match or eventual mismatch. In the case of an optimum duplication of the esthetically relevant features inherent to the control tooth, a minimum WES score of 0 is possible.

### 3. Implant position

An evaluation of the recovery and result of an implantation requires an assessment of gingival esthetic change after surgery and prosthesis design. (the IBOI Pink & White Esthetic Score). Implant position and abutment selection are also major concern for esthetic result. We add these two items into IBOI esthetic score. (the IBOI Implant-Abutment Transition & Position Analysis: 1. Implant position. 2. implant/abutment/prosthesis connection.).

Implant position: there are five keys we should consider during implant placement.

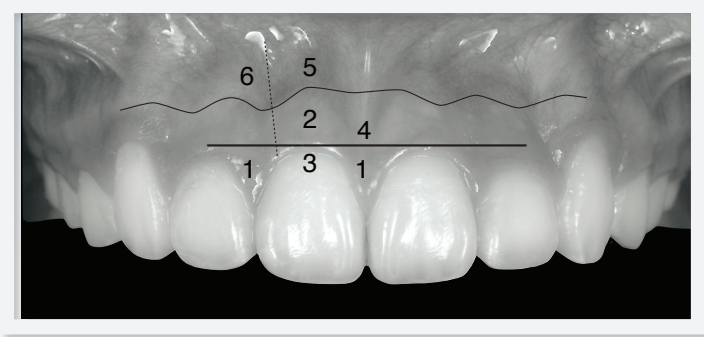
1. M-D position: drilling hole always keeps it in the center of designed crown (score 0), shift to one side (score 1), close and touch to adjacent tooth (score 2).
2. B-L position: it's important to preserve 2mm buccal bone thickness after implant

# IBOI Pink & White Esthetic Score

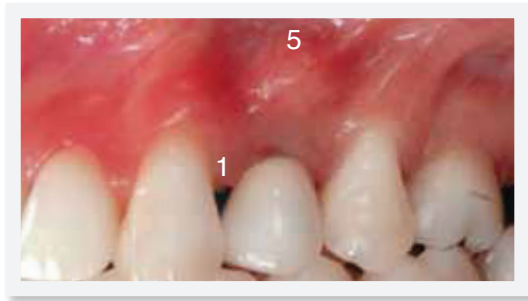Total Score: =

## 1. Pink Esthetic Score

Total =



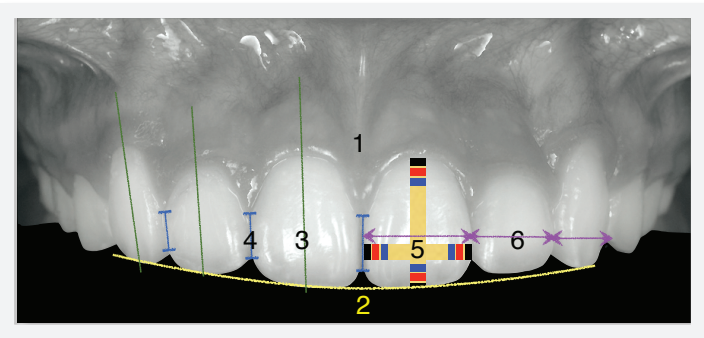
1. M & D Papilla	0	1	2
2. Keratinized Gingiva	0	1	2
3. Curvature of Gingival Margin	0	1	2
4. Level of Gingival Margin	0	1	2
5. Root Convexity ( Torque )	0	1	2
6. Scar Formation	0	1	2



1. M&D Papilla	0	1	2
2. Keratinized Gingiva	0	1	2
3. Curvature of Gingival Margin	0	1	2
4. Level of Gingival Margin	0	1	2
5. Root Convexity ( Torque )	0	1	2
6. Scar Formation	0	1	2

## 2. White Esthetic Score ( for Micro-esthetics )

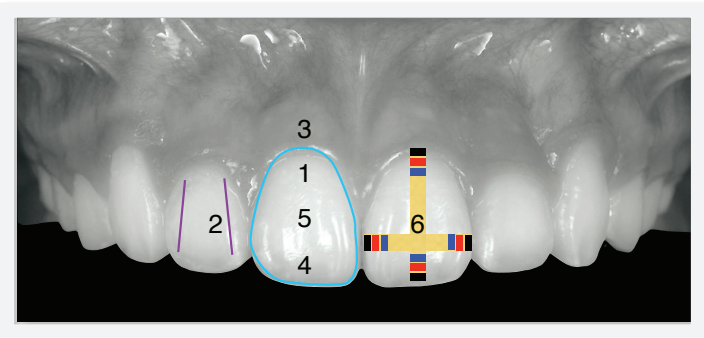
Total =



1. Midline	0	1	2
2. Smile Arc	0	1	2
3. Axial Inclination	0	1	2
4. Contact Area	0	1	2
5. Tooth Porportion	0	1	2
6. Tooth To Tooth Proportion ( 1.6:1:0.6 )	0	1	2

## 2. White Esthetic Score ( for Single-implant )

Total =



1. Tooth Form	0	1	2
2. Mesial & Distal Outline	0	1	2
3. Crown Margin	0	1	2
4. Translucency ( Incisal thrid )	0	1	2
5. Hue & Value ( Middle third )	0	1	2
6. Tooth Proportion	0	1	2

placement (*score 0*). If the buccal bone plate is less than 2mm, the options are: (a) place the implant more lingually, (b) choose a smaller diameter implant fixture, and/or (c) augment buccal bone with GBR procedure to improve buccal bone thickness. The buccal bone plate exists and less than 2mm (*score 1*) and there is no buccal bone plate (*score 2*).

3. Depth: the implant fixture should be placed 3mm below the future crown margin (*score 0*), sulcus depth 2mm or > 4mm (*score 1*), and deeper than 1mm or > 4mm (*score 2*).
4. Angulation: the implant axis should be parallel with the adjacent teeth (*score 0*). It's important to place guide pin and take peri-apical X-ray film to check the axis before implant insertion. Especially in orthodontic case, after opening space, the patient should be referred for X-ray taking to check the root axis of the adjacent teeth. If the root apex are too close, it's difficult for surgeon to insert the implant without damage the root apex. The tilted angulation is between 8 ~ 15 degree (*score 1*), more than 15 degree (*score 2*).
5. Distance to adjacent anatomy: for single implant, fixture should be at least 1.5mm away from adjacent teeth to preserve the proximal bone level (*score 0*), less than 1.5mm (*score 1*), touch to adjacent tooth or other important anatomy (*score 2*).

#### 4. Implant/abutment/prosthesis connection

Implant-abutment transitional contour: there are nine factors would affect final esthetic result:

1. Fixture cervical design.
2. Platform switching.
3. I-A connection type.
4. Abutment selection.
5. Screw hole position.
6. Marginal bone loss.
7. Sulcus height.
8. Modified gingival contour.
9. Crown margin fitness.

We evaluate the last four items in the scoring system.

1. Fixture cervical design:  
For esthetic consideration, we can select bone level implant which has no smooth collar on the cervical portion of the fixture.
2. Platform switching
3. I-A connection type  
(*E: external connection, I: internal connection*):  
For example: EZ Plus implant has platform switching design, which maintains crestal bone, and in addition, it incorporates an 11° morse taper, producing a conical seal which forms a cold weld between the abutment and the implant. The platform switching and morse taper design prevent microgap

movement and allow for a beautifully keratinized tissue response.

#### 4. Abutment selection

(S: screw-retained, C: cement-retained):

For cement-retained abutment, there are many choices for different situation: one-piece, two-piece, milling, UCLA, customized abutment according to different clinical situations.

#### 5. Screw hole position

(B: buccal site, L: lingual site):

In this case, screw hole was left on the labial surface of abutment. The screw-retained prosthesis will cause un-esthetic appearance because of obvious screw hole while patient smile.

#### 6. Marginal bone loss:

There is no bone loss at the time of crown delivery (score 0). According to ICOI, Consensus conference meeting, 2007, defined the criteria of successful implant as:

- a. No pain or tenderness upon function.
- b. 0 mobility.
- c. <2mm radiographic bone loss from initial surgery.
- d. No exudates history. <2mm bone loss at the time of crown delivery (score 1), and more than 2mm bone loss (score 2).

#### 7. Soft tissue height: The ideal sulcus depth around implant was about 3mm for biologic

width (score 0), less than 3mm (score 1), more than 3mm (score 2).

#### 8. Modified gingival contour: If papillae are insufficient and caused the dark triangle condition, the CAD/CAM customized abutment can be useful to the move the crown emergence close to the natural teeth to achieve the best interproximal contact. This design will insure us to regain the interdental papilla (*implant crown interproximal contact measured to the crestal bone of adjacent teeth is less than 5mm the papilla will be restored 95% of the time*) to ensure papilla comes back. We use papillae height to measure the modified gingival contour: 90% papillae fill (score 0), papillae less than 100% fill (score 1), no papillae (score 2).

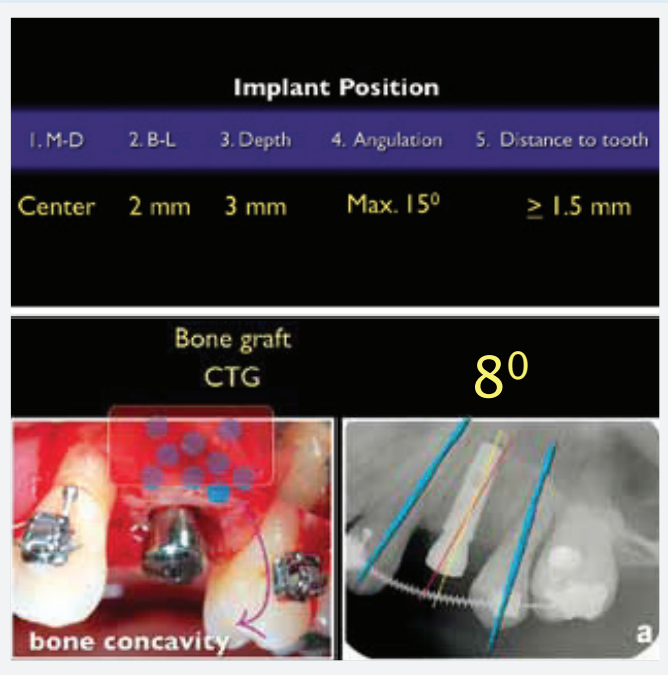
#### 9. Crown margin fitness: From periapical film, we can check the integrity of crown margin to abutment. 100% fitness (score 0), small gap (score 1), the crown doesn't sit on the abutment (score 2).

## References

1. Buser D. Outcome Evaluation of Early Placed Maxillary Anterior Single-Tooth Implants Using Objective Esthetic Criteria: A Cross-Sectional, Retrospective Study in 45 Patients With a 2- to 4- Year Follow-Up Using Pink and White Esthetic Scores. *J Periodontol* 2009;80:140-151.
2. Urs C. Belser, Daniel Buser et al. Outcome evaluation of early placed maxillary anterior single-tooth implants using objective esthetic criteria: A cross-sectional, retrospective study in 45 patients with a 2- to 4- year follow-up using pink and white esthetic scores. *J Periodontol* 2009;80:140-151.
3. Grunder U, Gracis S, Capelli M. Influence of the 3-D Bone-

# IBOI Implant-Abutment Transition & Position Analysis

## 3. Implant Position



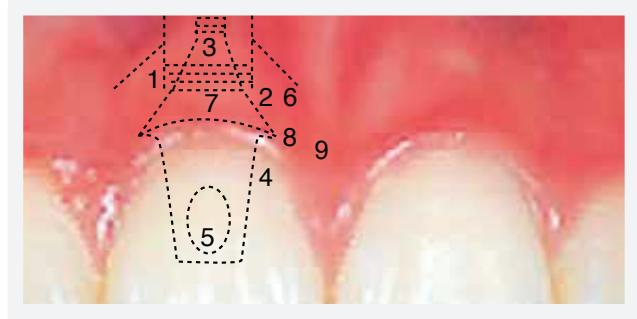
Total =

1. M & D ( Center )	0	1	2
2. B & L ( Buccal 2 mm )	0	1	2
3. Depth ( 3 mm )	0	1	2
4. Angulation ( Max. 15° )	0	1	2
5. Distance to Adjacent Anatomy	0	1	2

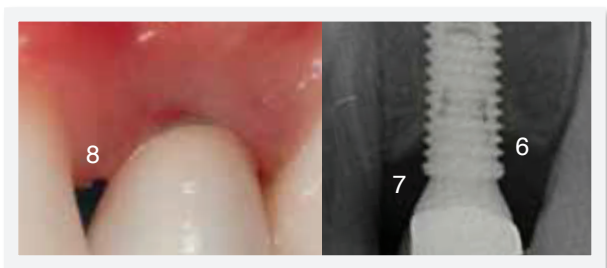
1. M & D ( Center )	0	1	2
2. B & L ( Buccal 2 mm )	0	1	2
3. Depth ( 3 mm )	0	1	2
4. Angulation ( Max. 15° )	0	1	2
5. Distance to Adjacent Anatomy	0	1	2

Total =

## 4. Implant/Abutment/Prosthesis Connection



E: external connection,  
 I: internal connection,  
 S: screw type,  
 C: cement type,  
 P: palatal/central,  
 B: buccal



1. Fixture Cervical Design	N	Y	
2. Platform Switch	N	Y	
3. I-A Connection Type	E	I	
4. Abutment Selection	S	C	
5. Screw Hole Position	P	B	
6. Marginal Bone Loss	0	1	2
7. Soft Tissue Height	0	1	2
8. Modified Gingival Contour	0	1	2
9. Crown Margin fitness	0	1	2

1. Fixture Cervical Design	N	Y	
2. Platform Switch	N	Y	
3. I-A Connection Type	E	I	
4. Abutment Selection	S	C	
5. Screw Hole Position	P	B	
6. Marginal Bone Loss	0	1	2
7. Soft Tissue Height	0	1	2
8. Modified Gingival Contour	0	1	2
9. Crown Margin fitness	0	1	2

Implant Relationship on Esthetics. *Int J Periodontics Restorative Dent* 2005;25:113-119.

4. Chang CH. e 2B-3D rule for implant planning, placement and re oration. *Int J Ortho Implantol* 2012;27:96-101.